

We are IntechOpen, the world's leading publisher of Open Access books Built by scientists, for scientists

6,900

Open access books available

185,000

International authors and editors

200M

Downloads

Our authors are among the

154

Countries delivered to

TOP 1%

most cited scientists

12.2%

Contributors from top 500 universities



WEB OF SCIENCE™

Selection of our books indexed in the Book Citation Index
in Web of Science™ Core Collection (BKCI)

Interested in publishing with us?
Contact book.department@intechopen.com

Numbers displayed above are based on latest data collected.
For more information visit www.intechopen.com



Five Fluorouracil, Hyaluronidase, and Triamcinolone in the Nasal Region

Guillermo Blugerman, Diego Schavelzon and Gabriel Wexler

Additional information is available at the end of the chapter

<http://dx.doi.org/10.5772/62068>

Abstract

Introduction: The use of five fluorouracil (5 FU) as antifibrotic started in the 1960s, in the hands of ophthalmologists, to prevent adherence after glaucoma and pterigion surgery. In 1999, Fitzpatrick presented his experience in keloids and hypertrophic scars, making a great contribution to their treatment. Fibroblasts' main function is collagen synthesis; in vicious scar the amount of collagen is normal, but what is altered is the ratio between collagen subtypes. The use of triamcinolone, the previous standard treatment, produced different degrees of atrophy and telangiectasias.

Technique: Infiltration is done in the center of fibrosis, weekly for the first month, then every 15 days until reaching the desired result. Softening, loss of volume and retraction are seen since the first session. Also pain and itching disappears.

Histopathology: Biopsy of treated scars has organized collagen fibers and less fibroblasts compared to nontreated scars.

Clinical applications: hypertrophic scars or keloids fixed to deep planes, "supratip" post-rhinoplasty fibrosis, post-rhinoplasty fibrosis (as preparation for other treatments), foreign body granulomas, and post-burn retractions. The use in supratip deformity when secondary to rhinoplasty fibrotic scar has proven very effective, and also as preparation for surgical (secondary rhinoplasty) and nonsurgical (bioplasty) procedures.

Conclusion: Our experience in the treatment of nasal scars, fibrosis, and retraction with 5 FU is favorable. The results of infiltration with 5FU, hyaluronidase and triamcinolone in low dose have clinical and histological demonstration of collagen synthesis reduction and reorganization of collagen cicatrized fibers.

Keywords: Corticosteroids, fibrosis, fibrosis histopathology, fibrosis treatment, five fluorouracil, fibroblasts, foreign body granulomas, healing, hyaluronidase, hypertrophic scar, keloids, nasal aesthetics, nasal dermatology, nasal deformity, nasal reconstruction, post-rhinoplasty fibrosis, burn sequelae, scar, scarring disorders, supratip deformity

1. Introduction

Since Fitzpatrick [1] published his work with five fluorouracil (5FU) in 1999, we included it in our daily practice. The most frequent use of this drug is for treatment and prevention of hypertrophic scars, keloids, and foreign body granulomas [2].

The particular anatomy of the skin in each nasal subunit makes scarring process completely different among them (Fig. 1). The skin of the tip is thick, has follicular units, and sebaceous glands, whereas the dorsum skin is thin with almost no subcutaneous tissue. Because of these, the nasal tip skin reacts violently to injury, with an important inflammatory process and residual edema that generates unaesthetic deformities. The dorsum skin reacts softly to injuries, with light inflammation and scarring, but strong adherence to deep structures due to its thin composition. The etiologies of scarring in the nose are:

- Congenital (angioma)
- Traumatic
- Surgical
- Infectious
- Implants

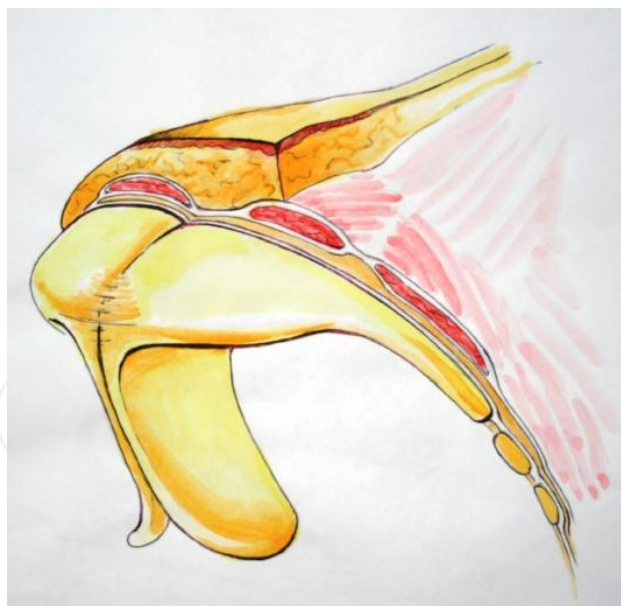

Figure 1. Anatomical structure of nasal tip and dorsum.

Fibroblasts' proliferation and migration play a major role in wound healing. Their main metabolic function is collagen, elastin, and proteoglycans synthesis. Fibroblasts' suppression in hypertrophic scars and keloids is essential since collagen synthesis is increased by 14% and 20%, respectively, compared to normal skin. Other studies show a higher amount of fibroblasts

without significant increase in collagen synthesis but with altered proportions between collagen I, III, and IV. These studies also show an increased production of fibronectin by fibroblasts. The local increase of collagenase inhibitors has also been reported.

Local steroids have been the gold standard treatment for nasal inflammatory and fibrotic processes for years, but its use has important side effects and complications. Triamcinolone usually generates different grades of skin atrophy and telangiectasias in the nasal tip and ala.

5 FU is a citostatic antimetabolite drug that inhibits cell proliferation by:

- Inhibition of thymidylate synthase avoiding DNA synthesis
- Incorporation in RNA and DNA altering its function
- Interference with glycosyltransferases altering cell membranes (Fig. 2)

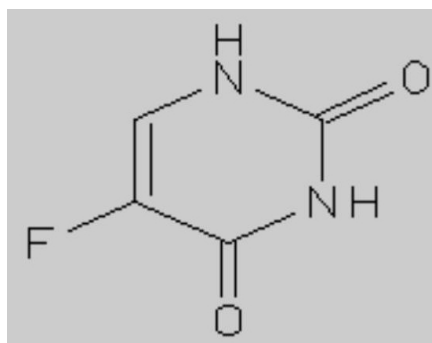


Figure 2. Molecular structure of 5 FU.

It has been proved in laboratory tests that 5 FU produces a slight reduction of collagen synthesis in normal fibroblasts but a drastic reduction in altered ones, as in Dupuytren illness [3]. Apparently, it also inhibits the collagen synthesis stimulation effect of TGF1 (transforming growth factor).

5 FU has been used for years in treatment of premalignant and malignant lesions of skin and mucosa due to its selective toxicity for dysplastic epithelium and fibroblasts. The first application of 5 FU was as an antifibrotic to prevent fibrous scarring after glaucoma surgery and to avoid relapse in pterigion surgery in the 1960s [4, 5, 6, 7, 8, 9]. In February of 1999, its use was reported to prevent fibrous adherence after tendon reconstructive surgery. One month after Fitzpatrick published his 7-year experience of over a thousand patients with 5 FU in hypertrophic scars and keloids. This magnificent work encouraged our team to include it in our office with positive results. Since Lambros published his work in 2004 [10], our team also added hyaluronidase. This last is an enzyme that increases connective tissue permeability by hyaluronic acid hydrolysis. Hyaluronic acid is a polysaccharide of connective tissue and other specialized tissues as the umbilical cord and the vitreous humor. Hydrolysis is done between the C1 of glucosamine and C4 of glucuronic acid. This reduces temporarily the intercellular cement viscosity, promoting diffusion of injected solution, exudates, and transudates facilitating absorption.

Triamcinolone is a steroid; it diffuses through cell membranes binding with cytoplasmic receptors that are translocated to the nucleus generating the transcription of proteins that are responsible for their effects. It reduces tissue response to inflammation, reducing its symptoms without treating the specific cause. To do this it reduces the white blood cell (WBC) migration to the affected tissue. The most important effects are:

- Inhibition of phagocytosis
- Inhibition of liberation of lysosomal enzymes and inflammatory mediators
- Reduction of capillary permeability and WBC adhesion to capillary endothelium
- Reduction of blood concentration of T-cells, eosinophils, and monocytes
- Reduction of immunoglobulin binding with cellular receptors

In the past 14 years, we have been using a preparation of 5FU, hyaluronidase, and triamcinolone for the nasal area, and we have not had the complications and side effects observed with steroids monotherapy.

2. Technique

5 FU (Fluorouracil- Filaxis 500mg) is presented commercially as ampoules of 10 ml containing 50 mg per ml. Triamcinolone (Kenacort-A-BSM) is used in its acetone form of 40mg/ml and is commercialized in ampoules of 1ml (Fig. 3). Hyaluronidase (Unidasa Roux Ocefa) is commercialized in ampoules that contain 500 UI of testicular ovine freeze-dried powder hyaluronidase. We use 2.7 ml of 5 FU and 0.3ml of triamcinolone to reconstitute hyaluronidase (5 FU solution). For the application, a 0.3 or 0.5 ml Luer lock syringe and 30 G needle are preferred. This allows a better dosage and correct plane of infiltration. We have never used more than 0.5 ml of the solution in the nasal area per session. The infiltration is done with multiple punctures in the “heart” of the fibrotic lesion. In the first month, one session is done per week; then it is spaced to every fifteen days. The improvement is evaluated with three parameters: hardening reduction, loss of volume, and reduction of cutaneous retraction. Positive changes are observed since the first session, not only in the above parameters but also in aesthetics and pain-itching symptomatology. Some cases are complemented with kinesiology treatment in order to obtain a better functional and cosmetic result.

3. Histopathology

If after finishing the treatment a surgical procedure was needed to improve the result, the surgical piece was sent to the pathologist and compared to nontreated scarring tissue resections. Results informed reduction of fibrosis and rearrangement of collagen tissue in the treated pieces. These results are illustrated in the images. In the tissue of the right side of the scar proliferation of fibrous tissue, great amount of fibroblasts and collagen fibers forming tangles

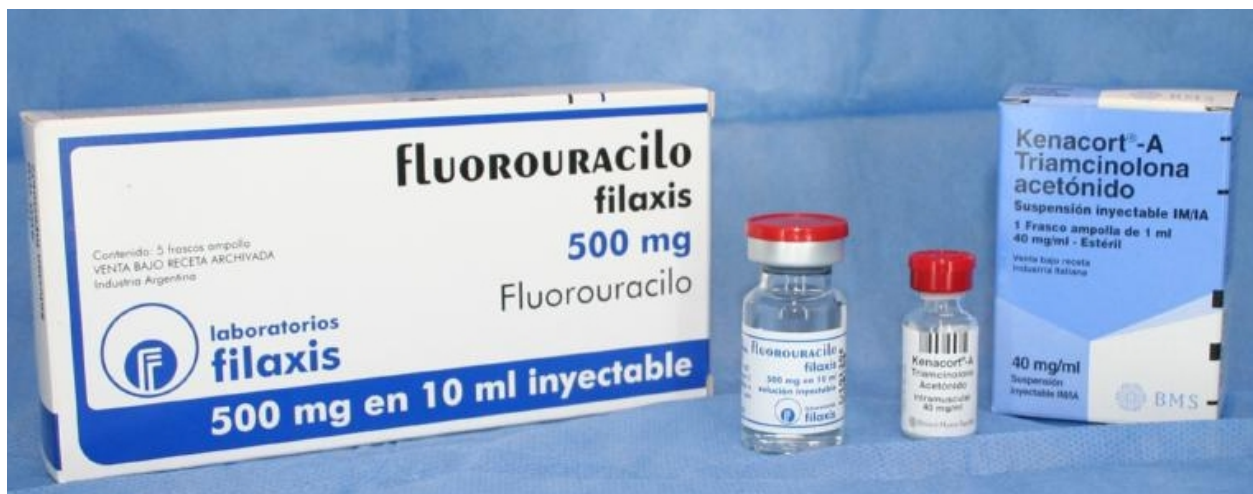

Figure 3. Commercial presentations of 5 FU and triamcinolone

is seen (Fig. 4). In the tissue of the left, treated with 5 FU solution, there are less fibroblasts, and the collagen fibers adopt a parallel disposition (Fig. 5).

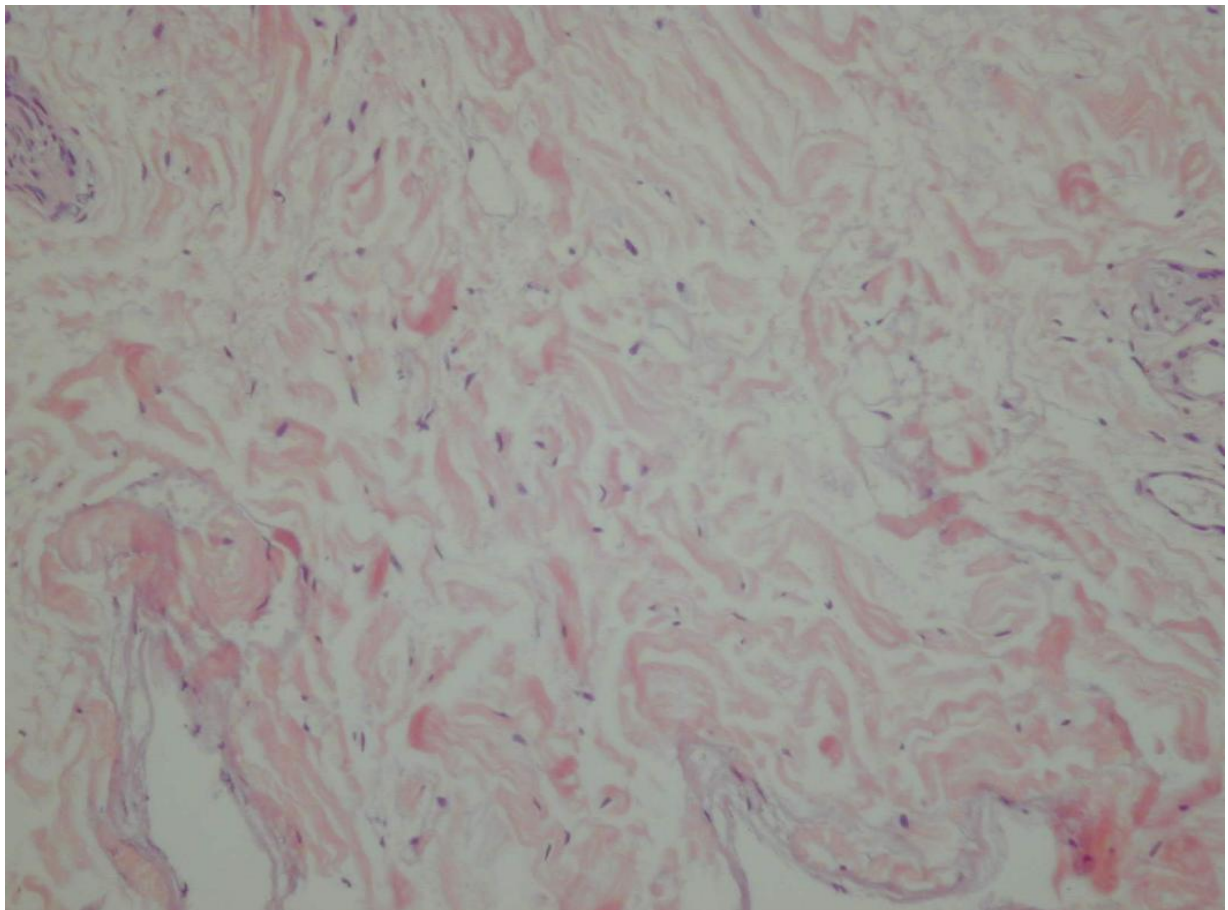


Figure 4. Microscopic image of fibrosis without any infiltration treatment (left).

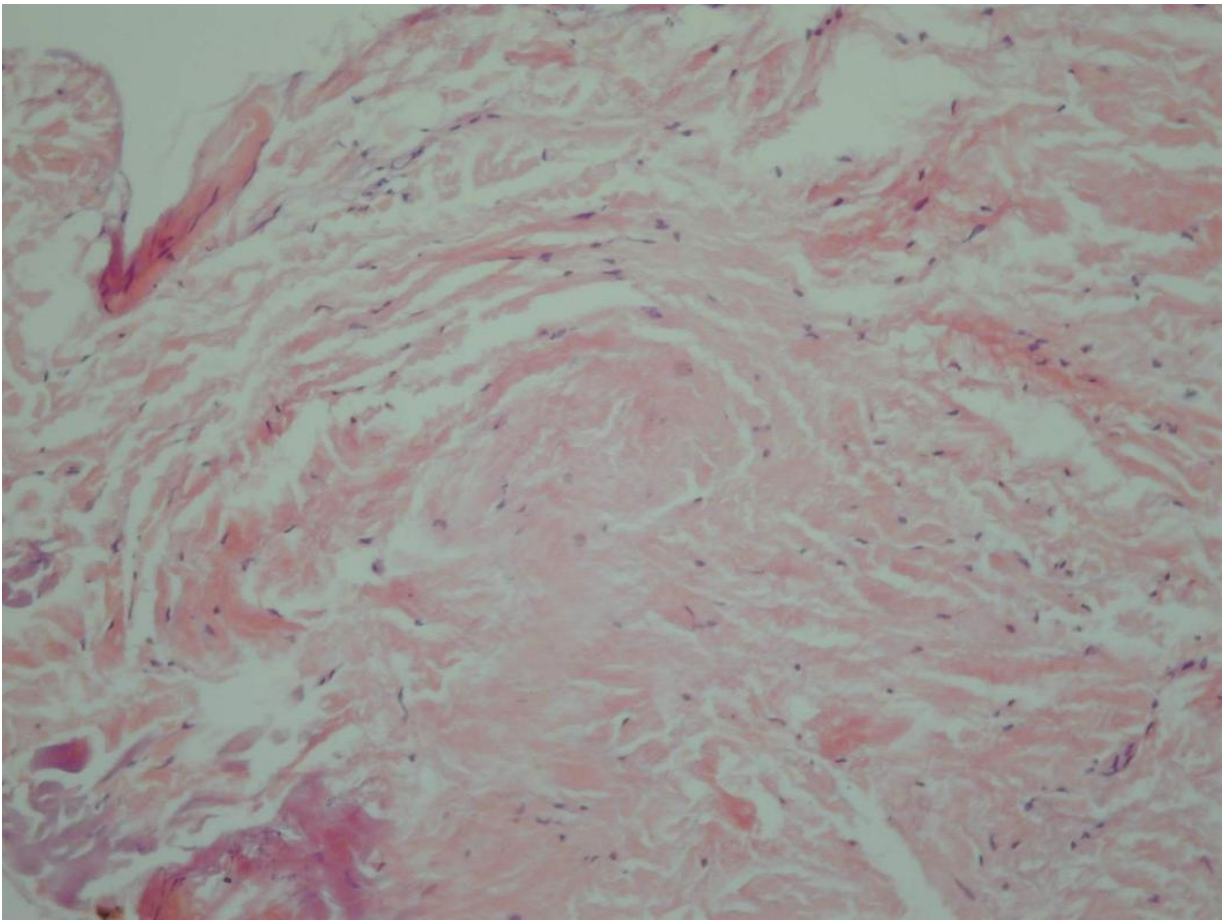


Figure 5. Microscopic image of fibrosis after infiltration with 5 FU (right).

4. Clinical applications

- Hypertrophic scars or keloids fixed to deep planes
- “Supratip” post-rhinoplasty fibrosis
- Post-rhinoplasty fibrosis (as preparation for other treatments)
- Foreign body granulomas
- Post-burn retractions

4.1. Hypertrophic scars or keloids fixed to deep planes

The nose, being a mid-facial and projected structure, is exposed to trauma that leaves scarring sequels in the skin. Traumatic scarring if healed by second intention generates unaesthetic scars. The use of 5 FU, triamcinolone, and hyaluronidase for hypertrophic scars and keloids in the nasal area is in our hands more effective and safe than the use of steroids alone. When

these scars are fixed to deep planes, the infiltration is done as preparation to subcision and then a filler as Polymethylmetacrylate (PMMA) is used to prevent the relapse of the adherence (Figs. 6 and 7).

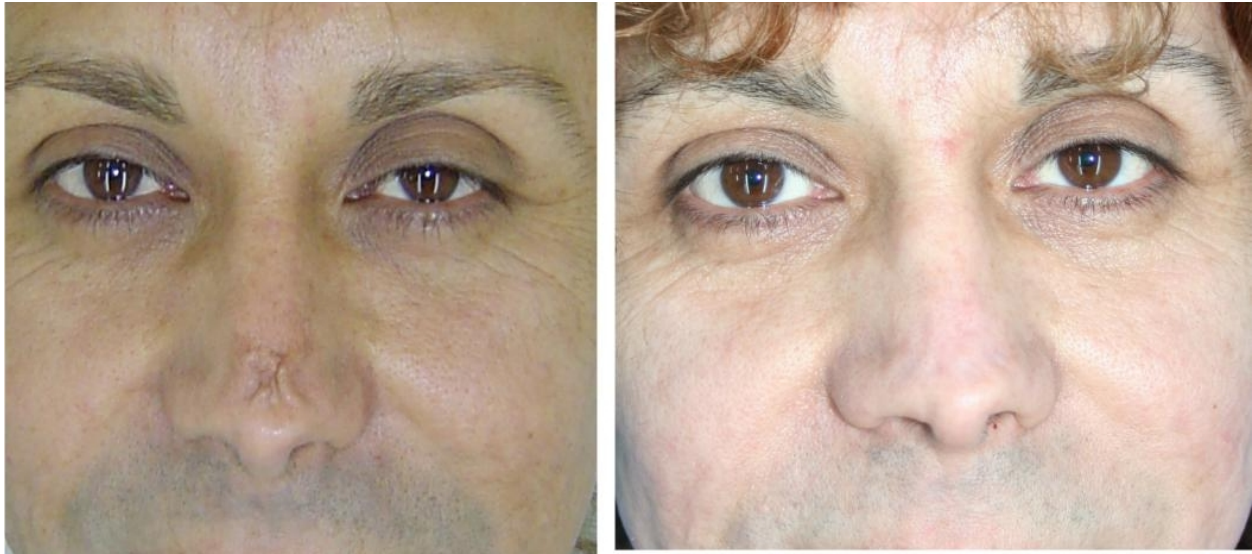

Figure 6. Nasal tip scar after cartilage graft infection and extrusion. Frontal view before and after 5 FU injection and dermabrasion.

4.2. “Supratip” post-rhinoplasty fibrosis

One of the most frequent complications of rhinoplasty is the healing fibrosis that is formed over time, known as “fibrous supratip.” It can be the result of a badly executed rhinoplasty or defective healing process. It is very frequent among beginners and even experts still have this complication. There are many causes of supratip deformity and each demands a specific treatment. Bahman Guyuron [11] conducted a clinical and histological study to unmask the surgical causes of this deformity. This study shows that clinical supratip is observed in 9% of primary and 36% of secondary consults of rhinoplasty. In primary cases, the deformity is the result of: tip inadequate projection, caudal dorsum overprojection, lateral inferior cartilages cephalic orientation, or a combination of these. In secondary cases, the deformity is the result of: subcorrection or overcorrection of caudal dorsum, overresection of medial valve, subprojected tip, or a combination of these. The histopathological study of the supratip soft tissue demonstrated significant fibrosis in 14 of 16 secondary patients and 13 of 23 primary patients. The supratip deformity can be avoided through appropriate resection of caudal dorsum (in order not to leave dead space), nasal tip projection, and joining with stitches the subcutaneous tissue over the cartilages in the supratip area. When diagnosed early, if the tip has adequate projection and the supratip tissue can be collapsed by pressure, the elective treatment is compressive tape. If after 6 weeks the response is not positive, 0.2–0.4 ml of 5 FU solution is injected in the deep (Figs. 8 and 9) subcutaneous tissue. This infiltration can be repeated monthly until reaching the desired result. (The judicious use of 5 FU solution can help in most supratip deformities caused by fibrosis when the caudal septum and the tip cartilages are strong. If the cartilaginous frame is weak, infiltration will not solve the problem.)

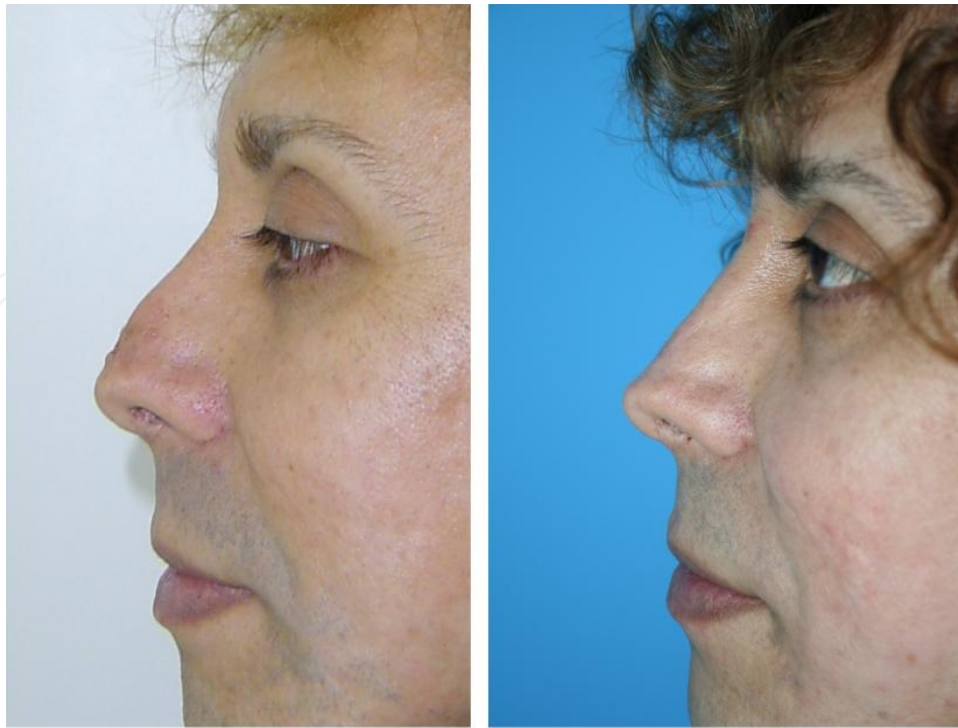

Figure 7. Nasal tip scar after cartilage graft infection and extrusion. Lateral view before and after 5 FU injection and dermabrasion.

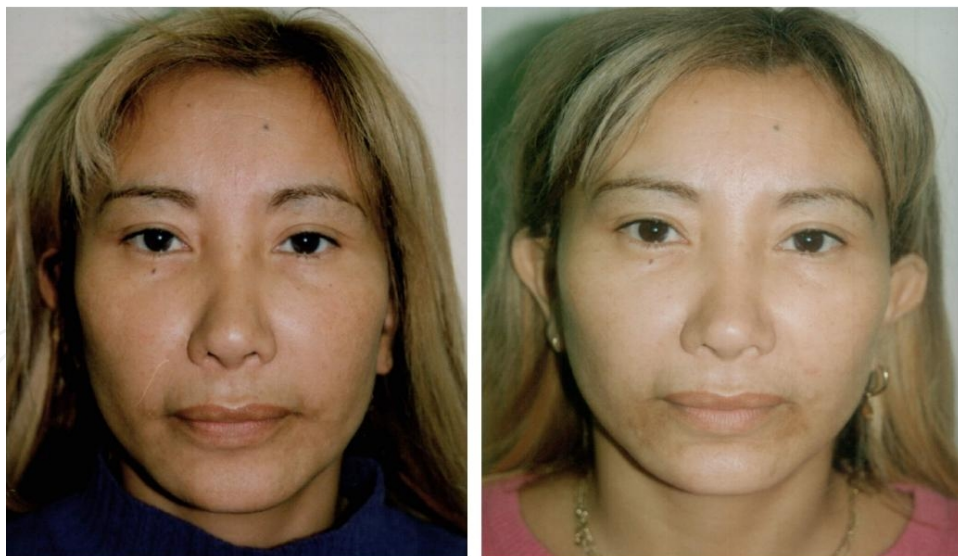

Figure 8. Fibrose supratip after previous procedure solve after 5 year with 0.3 ml of 5 FU single injection. Frontal view.

Infiltration can reduce a big supratip to a small one but with an important risk of skin atrophy.

Other authors such as Gruber [12] prefer to start with infiltration after 4–6 weeks of surgery, when most edema has disappeared. He uses 1–2 mg of triamcinolone (0.1–0.2 cc of triamcinolone 10 mg/cc) in the supratip or other fibrous area. Pastorek [13] uses small steroids doses

during and immediately after surgery, having excellent results in his hands. If a severe supratip deformity is the consequence of inadequate cartilage resection or subprojection of the tip, a surgical correction or bioplasty is needed. Sheen [14] suggested in 1979 that most supratip deformities were caused by caudal dorsum overresection. He proposed then the use of cartilage graft to correct this deformity.

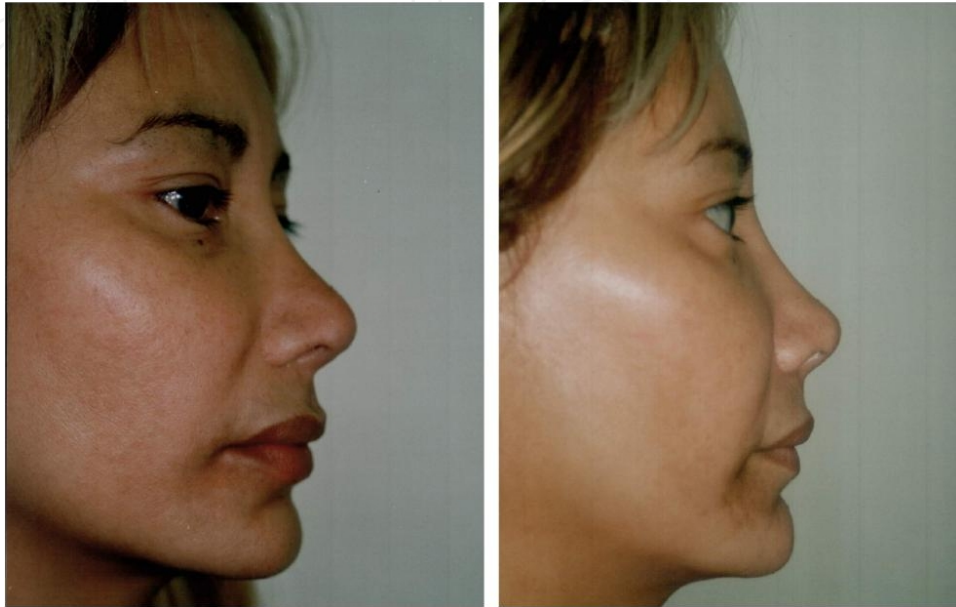

Figure 9. Fibrose supratip after previous procedure solved after 5 years with 0.3 ml of 5 FU single injection. Frontal view. Lateral view.

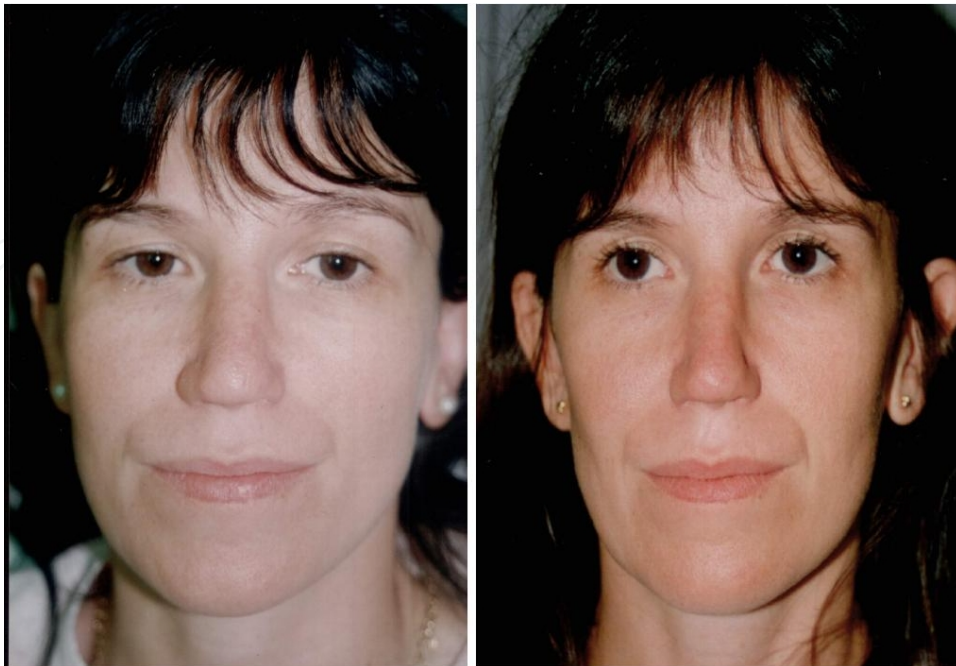

Figure 10. Patient with 3 previous rhinoplasties. Three applications of 5 FU solution were done.

Nowadays, it is widely accepted that healing fibrotic tissue formed to fill the dead space is the most frequent cause of supratip deformity post-rhinoplasty. But it was not until Guyuron's work that this was scientifically confirmed.

4.3. Post-rhinoplasty fibrosis, as preparation for other treatments

After several surgical procedures, the nose can be involved in different grades of fibrosis, turning the skin hard and inelastic. Before performing a secondary rhinoplasty or a bioplasty, we prefer preparing the area with some applications of the 5 FU solution, in order to soften the tissue (Fig. 10).

4.4. Foreign body granulomas

The use of fillers in the nasal area is a very popular method to correct slight deformities. There are many different materials and each of them produces a different degree of fibrotic reaction in the tissue. In most cases, this is a controlled reaction and leads to the expected result. But in some cases, an overreaction of patient immune system, bad application technique, or the chemistry of the material used provoke the formation of foreign body granulomas, resulting in unaesthetic deformities.

The use of triamcinolone in these cases can generate skin atrophy, thus turning the deformity more visible. When the filler used is hyaluronic acid, pure hyaluronidase should be infiltrated as stated by Brody [15] and Hirsch [16]. Infiltration is done with 100 UI in the area of hyaluronic acid excess (Fig. 11). This dissolves the acid, solving the fibrosis. When alloplastic materials were used, we preferred the 5 FU solution for infiltration because it does not have the side effects of steroids monotreatment. The application has a double effect, the pharmacological effect of the drugs, and the mechanical effect of disruption by the fluid pressure.

4.5. Post-burn retractions

The nasal skin usually gets affected in facial burns. The scarring retraction can deform the tip, ala, or both, stretching the nostrils. We use the 5 FU solution infiltration in these fibrous areas in order to increase the tissue elasticity and prepare them for secondary procedures as PMMA bioplasty or compound auricular graft.

5. Complications

The use of 5 FU solution, in young patients mostly, can cause tissue necrosis. This is relatively frequent in keloid treatment, resulting in ulcers or brown stains in the application spots. However, in the nasal region we have not observed this complication, mainly because of the low dosage. In this way, by using a progressive treatment instead of an aggressive one, side effects are kept to the minimum.

6. Conclusions

Through this chapter, we have presented our experience in the treatment of scars, fibrosis, retractions, and deformities over the nasal skin. The results of our 14-year experience with 5 FU solution (5 FU, triamcinolone, and hyaluronidase) have the histopathological demonstration of effectiveness in collagen fibers synthesis reduction and fiber rearrangement, thus explaining the positive clinical effect.

Author details

Guillermo Blugerman^{1*}, Diego Schavelzon¹ and Gabriel Wexler²

*Address all correspondence to: blugerman@centrosbys.com

1 Plastic Surgery Department of Centros ByS, Centros B&S de Excelencia en Cirugía Plástica, Argentina

2 Universidad Nacional del Nordeste, Argentina

Conflict of interest

The Authors declare no conflict of interest.

Informed consent was obtained from patients included in the chapter.

References

- [1] Fitzpatrick R. Treatment of inflamed hypertrophic scars using intralesional 5-FU. *Dermatol Surg.* 1999;25(3):224-232.
- [2] Blugerman G. Keloids and Hipertrofic scars. Congreso de Cirugía Plástica del Cono Sur, Porto Alegre, Brasil, Mayo 2001.
- [3] Jemec, B., C. Linge, et al. The effect of 5-fluorouracil on Dupuytren fibroblast proliferation and differentiation. *Chir Main* 2000;19(1):15-22.
- [4] Blugerman G., Schavelzon D. Intralesional use of 5-FU in subcutaneous fibrosis. *J. Drugs Dermatol.* 2003; 2: 169-171
- [5] Yamamoto T., Varani J., Soong H.K., Lichter P.R. Effect of 5-fluorouracil and mitomycin on cultured rabbit subconjunctival fibroblast. *Ophthalmology* 1990;97:1202-1210.
- [6] Yeatts R.P., Ford J.G., Stanton C.A., Reed J.W. Topical 5-fluorouracil in the intra epithelial neoplasia of the conjuntiva and cornea. *Ophthalmology* 1995; 102:1388-1344.

- [7] Lee D.A., Shapourifar-Tehrani S., Kitada S. The effect of 5-fluorouracil and cytarabine on human fibroblasts from Tenon's capsule. *Invest Ophthalmol Vis Sci*. 1990;31:1848-1855.
- [8] Schellini Silvana A. Uso do 5-fluorouracil no intra-operatório da cirurgia do pterígio. *Arq Bras Oftalmol*. 2000 63(2): 111-114.
- [9] Acali Augustine et al. Decrease in adhesion formation by a single application of 5Fluorouracil after flexor tendon injury. *Plast Reconstr Surg*. 1999;103(1):151-158.
- [10] Lambros V. The use of hyaluronidase to reverse the effects of hyaluronic acid filler. *Plast Reconstr Surg*. 2004; 114(1):277.
- [11] Guyuron, Bahman. Supratip deformity: A closer look. *Plast Reconstr Surg*. 2000.105(3):1140-1151.
- [12] Gruber, Ronald P. MD. Supratip deformity: A closer look by Bahman Guyuron, MD, Louis DeLuca, MD, and Richard Lash, MD. *Plast Reconstr Surg*. 2000 105(3): 1152-1153.
- [13] Pastorek, N. Surgery of the Nasal Tip. Presented at the Dallas Rhinoplasty Symposium, Dallas, Texas, March, 1999.
- [14] Sheen, J.H. A new look at supratip deformity. *Ann Plast Surg*. 1979;3(6):498-504.
- [15] Brody, H.J. The use of hyaluronidase in the treatment of granulomatous hyaluronic acid reactions or unwanted hyalronic acid misplacement. *Dermatol Surg*. 2005;31(8 Pt 1):893-897.
- [16] Hirsch R.J. Correcting superficially placed of Hyaluronic Acid. *Skin Aging*. 2007;15 (1):36-38.