

We are IntechOpen, the world's leading publisher of Open Access books Built by scientists, for scientists

6,900

Open access books available

186,000

International authors and editors

200M

Downloads

Our authors are among the

154

Countries delivered to

TOP 1%

most cited scientists

12.2%

Contributors from top 500 universities



WEB OF SCIENCE™

Selection of our books indexed in the Book Citation Index
in Web of Science™ Core Collection (BKCI)

Interested in publishing with us?
Contact book.department@intechopen.com

Numbers displayed above are based on latest data collected.
For more information visit www.intechopen.com



Columella Sliding for Nasal Tip Projection Using Septocolumellar Transmucosal Mattress Sutures

Nikolay P. Serdev

Additional information is available at the end of the chapter

<http://dx.doi.org/10.5772/62063>

Abstract

In author's hands, columella sliding is a surgical technique to correct unaesthetic/unwanted depression or projection of the nasal tip. The tip can be increased or decreased by a simple mini-invasive technique during primary or secondary rhinoplasty as well as by a separate procedure. Main aim of the technique is to obtain the aesthetic 30° angle between dorsum and profile line and correct volume of the nasal tip at the line of the beauty triangle. It is possible to change the projection of the nasal tip using a retrocolumellar incision, to slide columella against septum upward or downward and fix the new position with 2–3 transmucosal columella-septal sutures. The stitches will be removed after 2–3 weeks, which is enough for columella to heal stable initially to septum. Columella sliding is an important technique to obtain a dorsoprofile angle of 30°, which is an aesthetic rule. The technique is atraumatic, mini-invasive, nearly bloodless. The procedure is very well tolerated by patients: there is no need of casts, tampons, and patients return to social life almost immediately.

Keywords: Rhinoplasty, columella sliding, retrocolumellar incision, columella-septal incision, mattress transmucosal suture, columella sliding upward, columella sliding downward, no downtime, atraumatic

1. Introduction

1.1. Surgical procedure

Nasal tip projection determines how far out from the face the tip protrudes. The author accepts that the correct position of the nasal tip is in close relation to the 30° dorsoprofile or dorsoalar angle [1-5], where the alar line refers to a vertical line drawn through the point where the alar base attaches to the cheek and establishes the straight profile line. A 30° dorsoalar angle is accepted as aesthetic.

When a retrocolumellar incision is present, 2–3 mattress transmucosal sutures are passed from columella caudal surface to a higher point of caudal septum to give projection to the nasal tip. (Figure 1). Vice versa, the columella is sutured to lower points of the septum to lower the projection of the tip in selected cases. The suture is used as well in cases of hanging columella after artistic excision of retrocolumellar mucosa and eventually part of caudally projected septum. The sutures are removed after 2 weeks. This time is observed to be enough to form a stable fibrosis and give a permanent result. Patients have to prevent the nasal tip from trauma. The depressor septi nasi muscle is responsible for smiling deformity. Excision of the depressor nasi muscle or botox injections could help additionally in this regard. Patients are asked to reduce wide opening of the mouth and too much laughing, in order to prevent from depressing the tip during the early post-op and healing period.

The author has experienced no complication with any of the above-described transcutaneous and transmucosal sutures in more than a thousand operated cases. Sutures can be placed at any time as ambulatory procedures with no downtime.

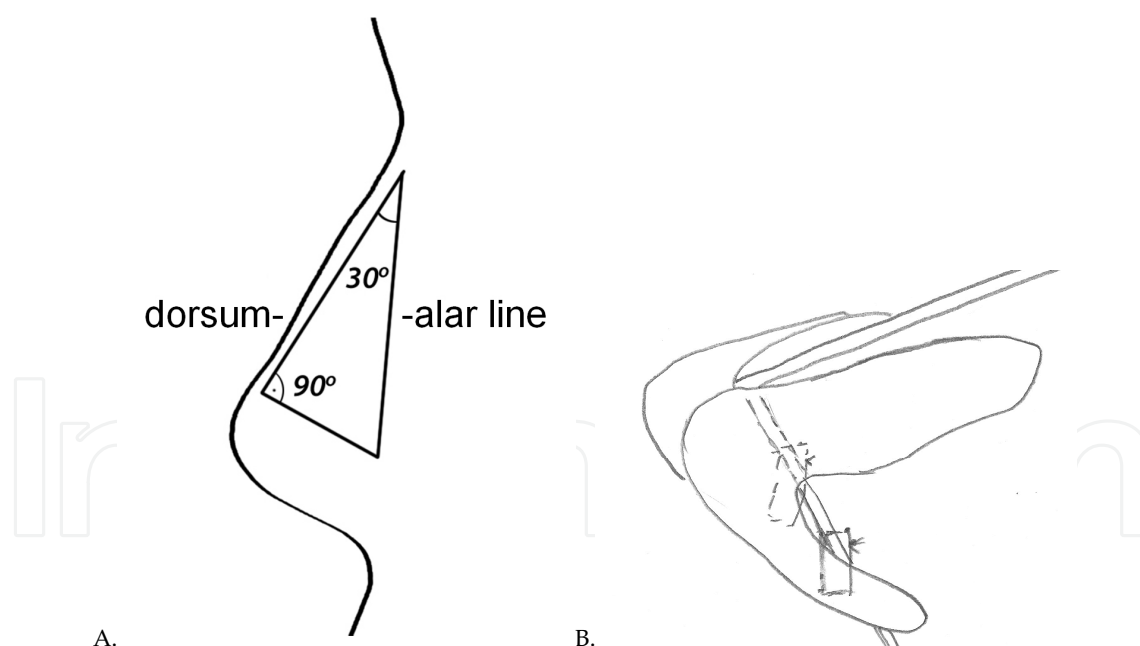


Figure 1. A. The position of the nasal tip implements the proper formation of the 30° dorsoalar angle, which is responsible for how far from the face the tip is positioned. **B.** When a retrocolumellar incision is present, 2–3 mattress transmucosal sutures are passed from columella caudal surface to a higher point of caudal septum to give projection to the tip. Vice versa, the columella is sutured to lower points of the septum to lower the projection of the tip in selected cases. The suture is used as well in cases of hanging columella after artistic excision of retrocolumellar mucosa and eventually part of caudally projected septum.

2. Clinical cases



Figure 2. A. Before. Aquiline long nose. No aesthetic proportions are present. B. After. Day 1 after T-excision for nasal tip rotation, humpectomy, digital fracture, and columella sliding for exact tip projection; simultaneous chin augmentation by Serdev Suture® and lower lip scar excision. Atraumatic surgery, no plaster, no tampons. The skin color tape will be removed on day 3. There is no bruising due to atraumatic technique. On day 1, patients visit the clinic to clean the nose, remove the crust. On the question why she has used make up, she answered that she feels beautiful.

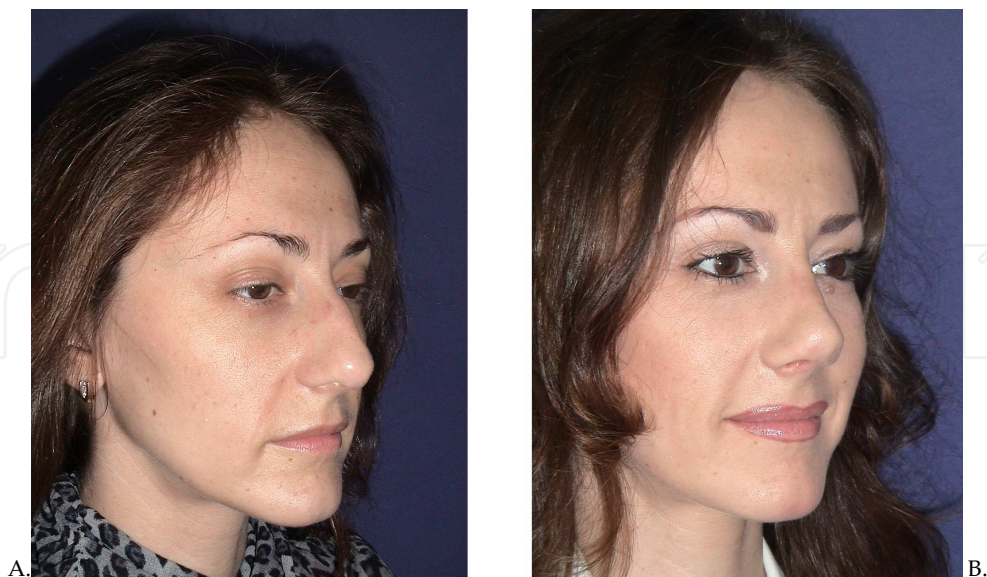

Figure 3. A. Before. Aquiline long nose. No aesthetic proportions are present. B. Day 4 after T-excision for nasal tip rotation, humpectomy, digital fracture, and columella sliding for exact tip projection. Better self-confidence, still some nearly invisible edema, no bruising. Beautification without additional surgeries due to correct proportions, volumes, and angles.

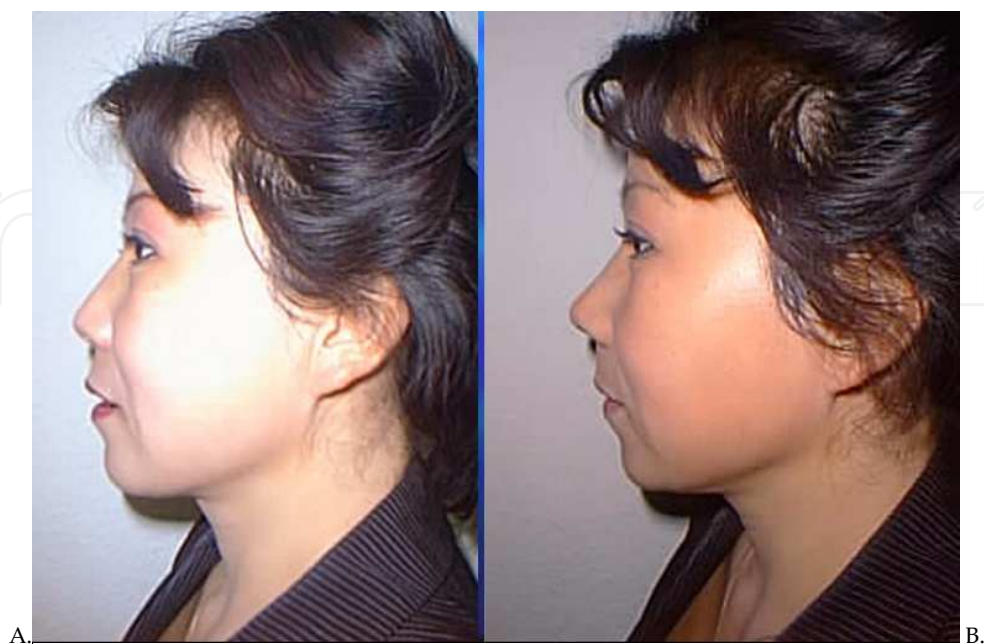

Figure 4. A. Before. Asian patient with a typical, very acute dorsoprofile angle, and low position of the nasal tip. B. After columella sliding for tip projection as a separate procedure. A correct 30° dorsoprofile angle is obtained, which changes positively the flat appearance of the Asian face.

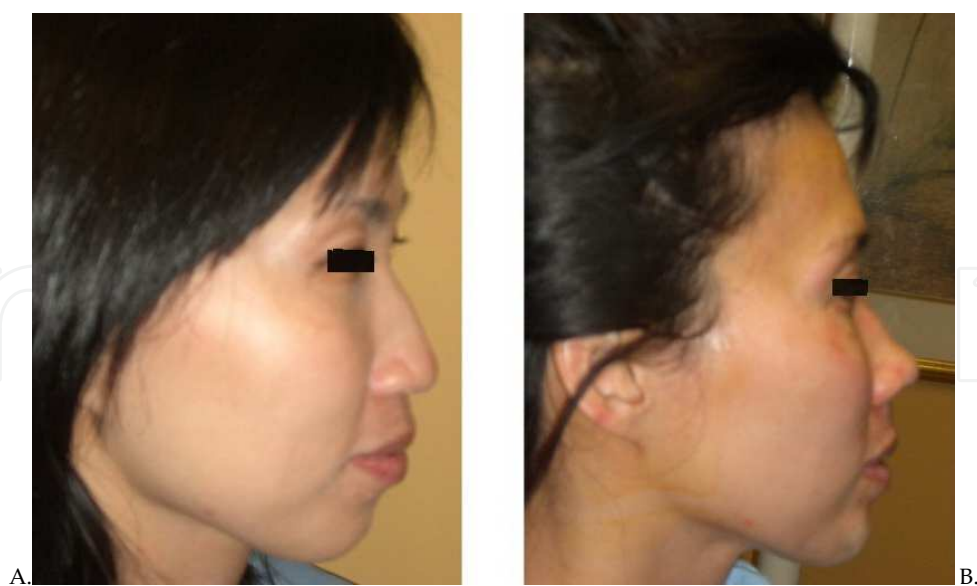


Figure 5. A. Asian patient with an aquiline long nose and retrograde chin. B. Immediately after T-excision for nasal tip rotation, columella sliding for tip projection, and chin enhancement with Serdev Suture® for straight profile. Correct proportions, volumes, and angles lead to beautification.

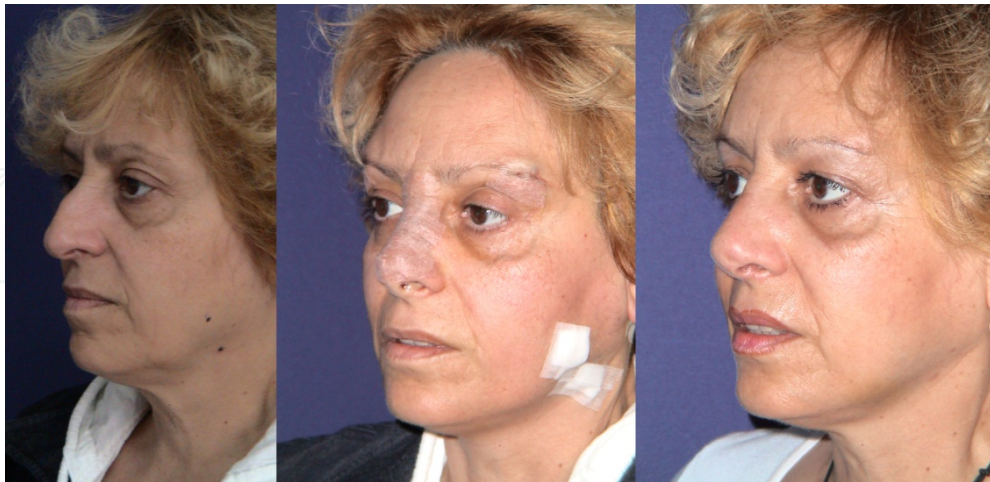

Figure 6. A. Before. Aging face and aquiline long nose. No aesthetic proportions are present. **B.** Immediately after Serdev Suture® temporal, medial, and lower face and neck lifts, and rhinoplasty: T-excision for nasal tip rotation, humpectomy, digital fracture, and columella sliding for tip projection. **C.** After 18 months. Correct proportions and dorsoprofile angle. Rejuvenation and beautification are present.



Figure 7. A. Before. Incorrect proportions, Aquiline long nose, low eyebrows, retrograde chin. **B.** After rhinoplasty including T-excision, humpectomy, digital fracture and columella sliding for correct proportion and angles, along with simultaneous brow lift and chin enhancement using Serdev Suture® techniques. Beautification as a result of correct proportions, volumes, and angles.

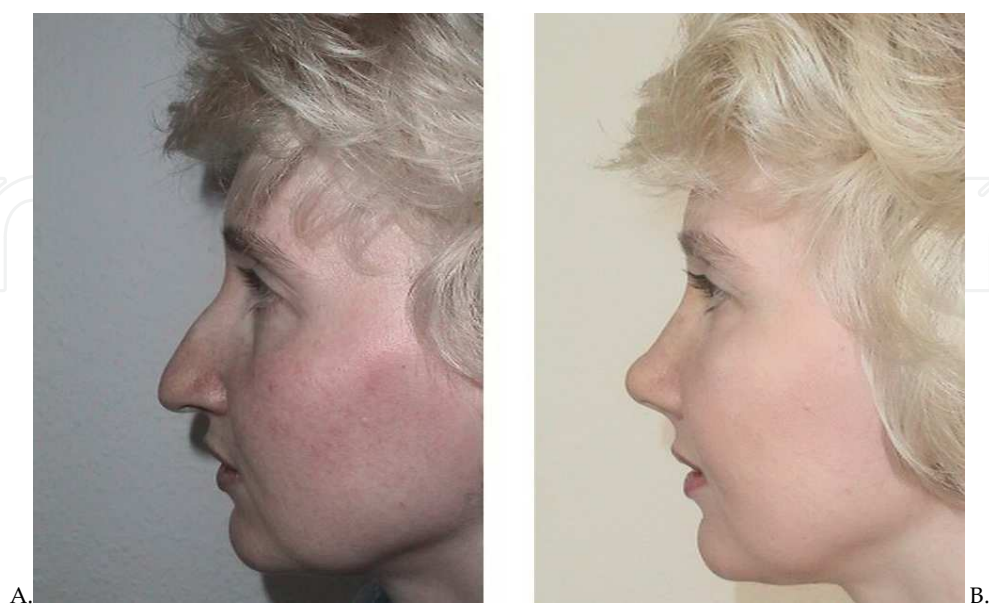

Figure 8. A. Before. Incorrect proportions, aquiline long nose. B. After rhinoplasty, including T-excision, hump removal, digital fracture and columella sliding for correct proportion and angles. Beautification as a result of correct proportions, volumes, and angles.

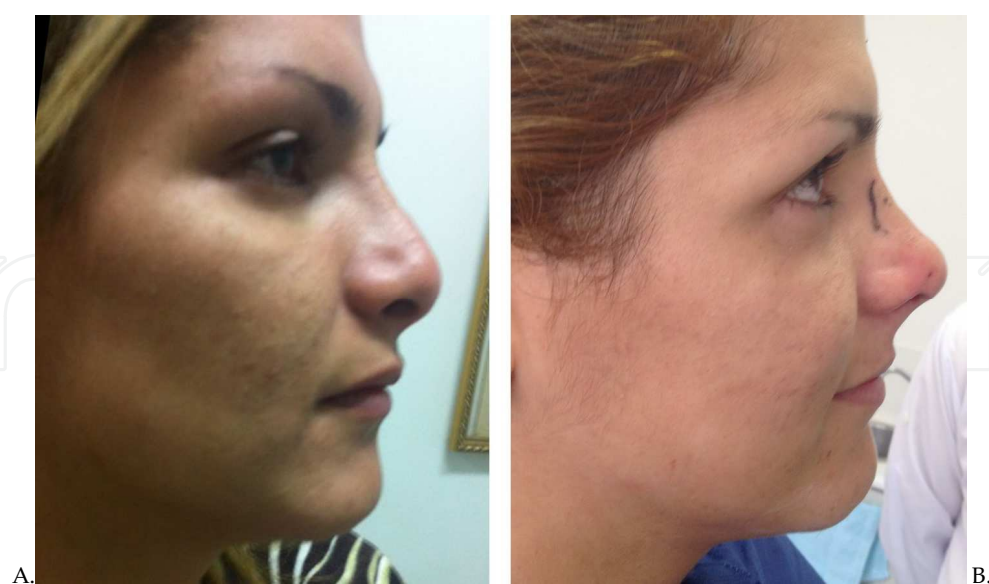

Figure 9. A. Before. Secondary case with short columella and incorrect acute dorsoprofile angle. B. After columella sliding for correct nasal tip projection and dorsoprofile angle of 30° .

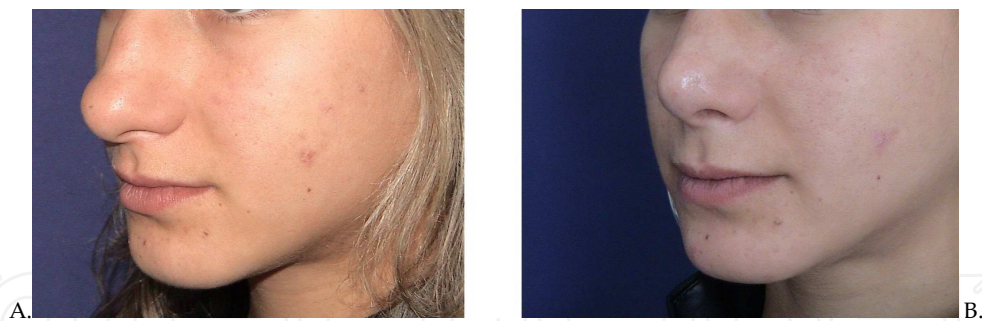

Figure 10. **A.** Before. Incorrect proportions, long nose with a bulbous tip and columella hanging.. **B.** After rhinoplasty, including T-excision, hump removal, digital fracture, and columella sliding downward for correct reduction of the nasal tip projection.

3. Conclusion

Columella sliding is a very useful mini-invasive technique to control position of the nasal tip as an independent procedure or as a part of primary or secondary rhinoplasties. It is simple, atraumatic, and very well accepted by patients. There are no known complications and the columella is fixed and heals in the new position in 2–3 weeks. There is no bruising, no need of tapes, tampons, or casts. Downtime is minimal and patients can return to social life almost immediately.

Author details

Nikolay P. Serdev*

Address all correspondence to: serdev@gmail.com

New Bulgarian University, Sofia, Medical Centre “Aesthetic Surgery and Aesthetic Medicine,” Sofia, Bulgaria

References

- [1] Serdev NP. Sliding of the Columella by the Serdev Technique. Live Surgery Workshop, The International Academy of Aesthetic Surgery and Aesthetic Medicine, Kru-lig Clinic, Caracas, Venezuela, Nov. 1999
- [2] Serdev NP. Principles of Face Beautification. Third World Congress of the International Society of Aesthetic Surgery, Tokyo April 8-10, 2000

- [3] Serdev NP. Rhinoplasty for Beautification. Asia Pacific Craniofacial Association. Third Conference, Shanghai, P.R. China, Oct. 30–Nov. 1, 2000
- [4] Serdev NP. Beautification rhinoplasty. *Int J Cosm Surg* 2001; 1(3): 257-311
- [5] Serdev NP. Aesthetic surgery methods for face beautification. *Int J Cosm Surg* 2001; 1(3): 188-256
- [6] Serdev NP. Serdev techniques in beautification rhinoplasty: T-zone excision, columella sliding, Serdev sutures. *Int J Cosm Surg* 2008; 8(1):388-469
- [7] Serdev NP. Nasal tip refinement, rotation, projection, alar base narrowing In: Serdev NP, Ed. *Serdev Sutures® Face and Body Lifts and/or Volumising*. Marllor editions, Italy, 2013: 75-81
- [8] Serdev NP. Serdev Sutures® in middle face 4. Beautification rhinoplasty – tip rotation and refinement, alar base narrowing. In: Serdev NP, Ed. *Miniinvasive Face and Body Lifts – Closed Suture Lifts or Barbed Thread Lifts*. Intech, Rijeka, 2013. Available from <http://www.intechopen.com/books/miniinvasive-face-and-body-lifts-closed-suture-lifts-or-barbed-thread-lifts/serdev-sutures-in-middle-face>.
- [9] Serdev NP. Course: Beautification rhinoplasty, t-zone excision, columella sliding, suture methods, updates in IV sedation and analgesia 2005; 23. 02. Available from: <http://ijcs.org/courses/2005/90/index.php>