

# We are IntechOpen, the world's leading publisher of Open Access books Built by scientists, for scientists

6,900

Open access books available

185,000

International authors and editors

200M

Downloads

Our authors are among the

154

Countries delivered to

TOP 1%

most cited scientists

12.2%

Contributors from top 500 universities



WEB OF SCIENCE™

Selection of our books indexed in the Book Citation Index  
in Web of Science™ Core Collection (BKCI)

Interested in publishing with us?  
Contact [book.department@intechopen.com](mailto:book.department@intechopen.com)

Numbers displayed above are based on latest data collected.  
For more information visit [www.intechopen.com](http://www.intechopen.com)



---

# **T-Excision for Nasal Tip Rotation**

---

Nikolay P. Serdev

Additional information is available at the end of the chapter

<http://dx.doi.org/10.5772/62061>

---

## **Abstract**

Authors “T-excision” for nasal tip rotation is used to reduce long noses as an independent procedure or as a part of primary or secondary rhinoplasties. It consists of “en bloc” excision of the cephalic part of the greater alar cartilages and elongated caudal septum, using: 1) total retrocolumellar incision, prolonged in transcartilaginous incisions, through opposite nostrils, leaving only skin intact; 2) septal incision, perpendicular to dorsum to form correct dorsum length, prolonged into intercartilaginous incisions, through opposite nostrils, leaving only skin intact. Thus, the cephalic strip resection is done en bloc with the unnecessary excessive and prolonged septum and soft tissue. Two, three mattress transmucosal septocolumellar sutures for 2–3 weeks are enough to support healing. The T-excision technique is mini-invasive, nearly bloodless, and time-saving. It is safe; well-tolerated by patients; there is no pain after surgery; no need of plaster, tampons, and bandages. Patients can return next day to social life and work.

**Keywords:** Rhinoplasty, long nose, T-excision en bloc, mini-invasive technique, elongated septum, primary or secondary, retrocolumellar incision, transcartilaginous incision, intercartilaginous incisions, perpendicular to dorsum septal incision, no downtime

---

## **1. Introduction**

Facial analysis is critical in rhinoplasty. This procedure is not an operation of a separated nose; it is an artistic surgery to give aesthetic proportions and angles, as well as properly localized volumes as an aesthetic part of the whole face, which is the goal of beautification. Patient's age, sex, skin quality, ethnicity should be considered. Nasal tip position has great importance in all cases of rhinoplasty and especially in cases of long and nonproportional nose. Cephalic strip resection of the lower lateral cartilages is performed to achieve upward tip rotation. The “en bloc” T-excision technique for adjustment of nasal tip involves new understanding of well-known incisions, based on anatomical knowledge and specific surgical skills. It minimizes trauma, it is nearly bloodless, achieving acceptable beautifying postoperative result with no

downtime for the patient, requiring no plaster, no tampons, and nearly immediate return to work and social life. This technique prevents cartilages from iatrogenic trauma and devascularization and thus permits faster healing and a stable result. It includes cephalic strip resection and septal shortening (caudal septum and/or retrocolumellar mucosal elongation) en bloc.

## 2. Anatomy

The **greater alar cartilages (lower lateral cartilages)** are situated below the upper lateral nasal cartilages, forming the columella and the wings of the nostrils. The medial crura are loosely connected with the corresponding portion of the opposite cartilage. Together with the septum they stabilize the columella. In Caucasians, the columella is stable, unlike Asians, Afro-Americans, and Latino-Americans.

The author's observations in Caucasian, Asian, and Afro-American noses show that the proper dorsocolumellar angle is very near to  $90^\circ$ . Angles different from the right angle change the aesthetic proportions and disbalance the beauty triangle [1-9].

## 3. Tip rotation

Using the tripod concept, a long nose has longer superior legs (lateral crura of greater alar cartilages) and shorter central leg (medial crura and columella). Thus, the shortening of the lateral crura (cephalic strip resection of the lower lateral cartilages) gives upward tip rotation. (**NB:** Projection of the nasal tip is described by the author in the chapter, "Columella Sliding for Nasal Tip Projection.")

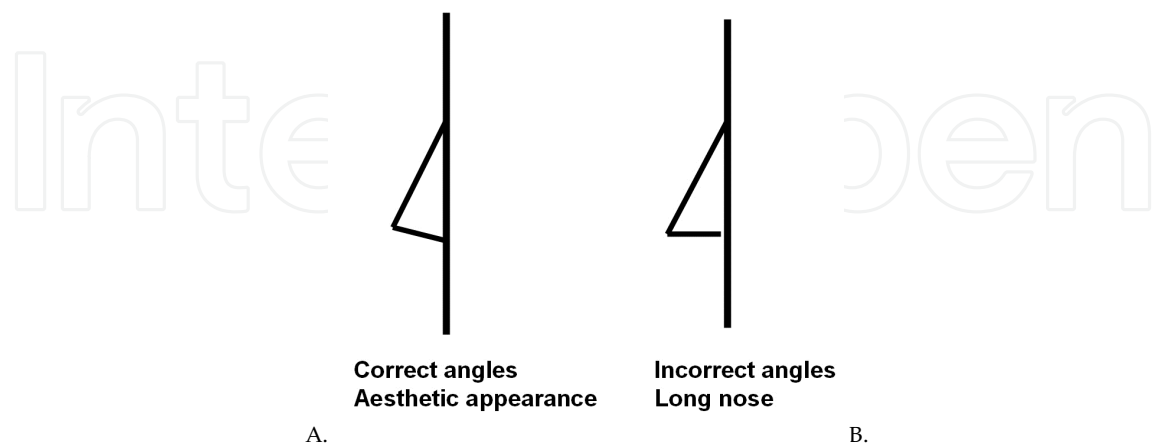
Tip rotation is also related to "position of the tip to the alar crease." The angle at the nasal tip has been described as the wide angle between the vertical line passing through the alar crease and a second line that is drawn from the alar crease to the nasal tip, on lateral view. The ideal tip angle is described to be  $105^\circ$  in females and  $100^\circ$  in males [7-9].

The author's opinion is that such description can hardly guide a surgeon during the process of operation. His observation is that angles that are too different from the right angle at the nasal tip disrupt the aesthetic proportions and the "beauty triangle" composed of both cheeks and chin (Figures 17, -11). If the angle is more acute, the nose appears to be long and disproportional to the whole face, and the nasal tip (when seen enface) hangs into the area of the upper lip. If the tip angle is obtuse, the nose appears short and over-rotated, as in some Asian and Afro-American noses.

## 4. Patient consent

If the tip angle is correct, the nostrils in enface aspect are slightly visible. Usually, patients with long noses, who have never seen their nostrils, have difficulty in accepting that nostrils should

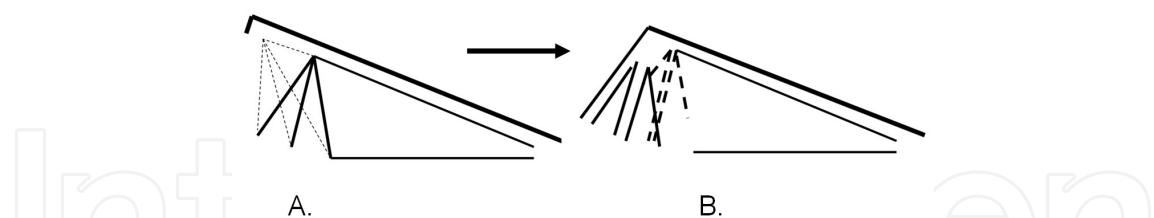
be a bit visible in frontal aspect. It should be clearly explained that in order for the nostrils to be invisible, the tip angle should be sharp (about  $70^{\circ}$ ), which is not appropriate and the nose looks long in relation to the face (Figure 1). Patients should be informed, confident, and motivated for this change.




**Figure 1.** A. Correct aesthetic proportions and angles. The nose is proportional – 1/3 of the face. Correct  $30^{\circ}$  dorsoprofile angle and nasal tip angles. Nostrils should be a bit visible from a frontal view. B. Visibly incorrect length, angles, and lack of aesthetic section of nose and face. The nostrils are not visible from a frontal view. Long nose.

#### 4.1. Design of the T-excision technique

Excision of the cephalic part of the **greater alar cartilages**, including unnecessary prominent caudal part of septum, permits rotation of the tip, i.e., shortening the length of the nose. The T-excision technique described below is made en bloc, using a closed rhinoplasty approach.



**Figure 2.** T-excision drawing. A. Schematic excision of 3 triangles – 2 lateral triangle excisions and one medial triangle excision perpendicular to the nasal dorsum. B. Result after tip rotation gives correct tip position and angles.



**Figure 3.** A. Schematic pyramid in a long nose. B. T-excision en bloc, including cephalic part of the greater alar cartilages and elongated caudal septum. C. Tip of the nose rotates easily. D. Two to three transmucosal mattress sutures of columella to caudal septum are enough to hold the tip in position and guarantee good fixation for healing. Stitches are removed after 2–3 weeks.

## 5. T-excision: Surgical technique

The initial local infiltration of anesthesia should not deform the nasal tip.

### 5.1. First incision

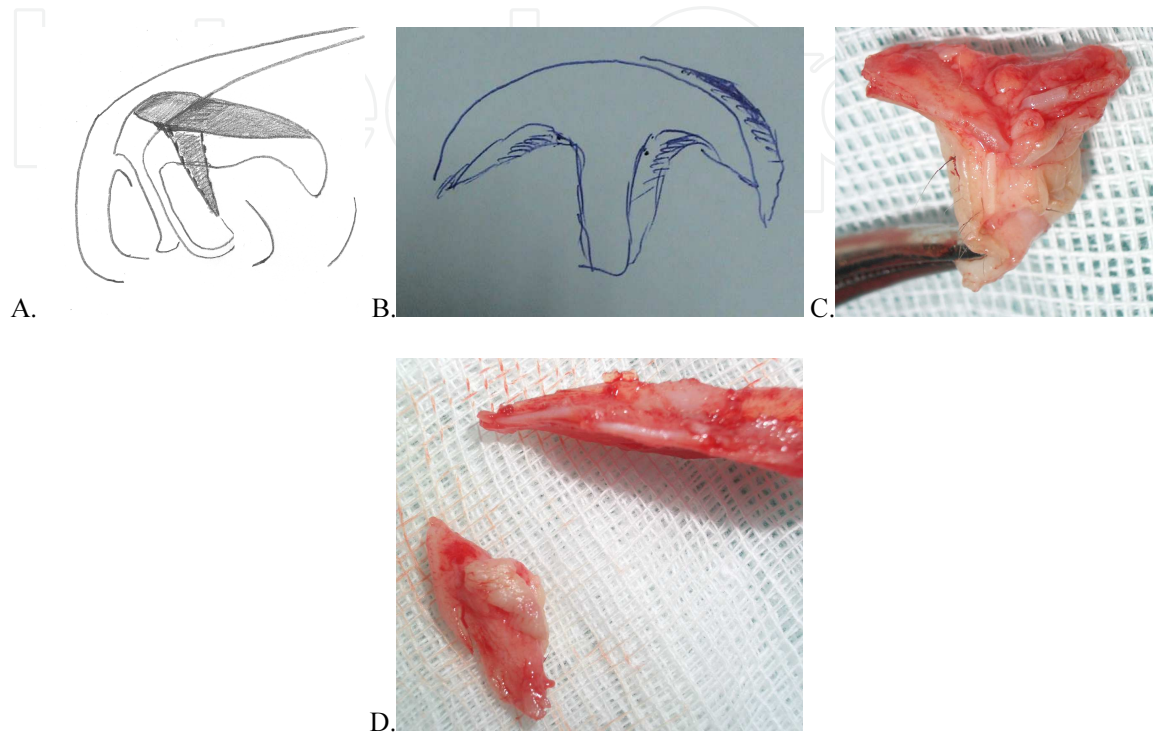
A **total retrocolumellar incision** is performed to separate the columella from the septum. In cases of dropping columella, this incision should follow a desired design. To remove dropping columella, the incision should leave an equal thickness along the length of the columella. Any other form should be previously designed according to patient's desire and informed consent. The **retrocolumellar incision** is then **prolonged into transcartilaginous incision**, which separates the lateral wing of the greater alar cartilage in cephalic and distal parts. In the past, the author used methylene blue dye to mark the transcartilaginous incision, but it is not always easy to exactly reflect the line that has been drawn on the external skin. Actually, this is not totally necessary, because the transcartilaginous incision is a prolongation of the retrocolumellar incision in each nostril, parallel to the nostril border. The transcartilaginous incision is performed in each nostril through the opposite nostril, using the opening of the retrocolumellar incision – this gives better visibility to the surgeon and permits for better orientation. This incision cuts mucosa and cartilages, leaving the skin intact. To be precise, both alae nasi are held with thumb and index of the other hand, feeling the scalpel below the skin with the fingertips. Transcartilaginous incisions should be located 4–5 mm cephalic to the caudal margin of the lateral crus of the lower cartilages. Finishing both transcartilaginous incisions and leaving only the skin intact, one has separated the lateral wings of the greater alar cartilage in cephalic and distal parts, whereupon the cephalic parts will be removed with the T-excision en bloc.

### 5.2. Second incision

The reduction of the length of the nose in the caudal septum region is selective. The second incision line is a **“90°-to-dorsum” septal incision**, starting from a selected dorsum point in a downward direction, perpendicular to the nasal dorsum to meet the retrocolumellar incision (forming the medial excision triangle), which usually happens above the nasal spine. This incision is total, including caudal septum and both sides of mucosa at once (or, in many cases, only elongated mucosa). The “90°-to-dorsum” septal incision is then prolonged into intercartilaginous incisions in both nostrils, each one through the opposite nostril using the opening of the “90°-to-dorsum” septal incision. The intercartilaginous incision should be placed minimum 2 mm caudal to the valve on the lateral crura side, in order to prevent nasal valve stenosis. The intercartilaginous incision in this technique leaves intact only the skin under the fingertips of the guiding hand, as described above. Intercartilaginous incisions meet the transcartilaginous incisions laterally, forming the 2 lateral triangles of the T-excision. Thus, cephalic parts of greater alar cartilages are separated together with the unnecessary elongated septum (or only mucosa), forming 3 triangles of the “T-excision en bloc”: two lateral triangles in the nostrils and one medial triangle in the septal retrocolumellar part. The tissue of the “T-

excision en bloc” is still fixed to the alar skin from which it will be separated and removed by using blunt tip scissors, guided by the other hand to prevent the alar skin from trauma.

The surrounding skin is slightly undermined with the scissors in 2–3 mm distance to permit rotation of the nasal tip and skin adaptation.

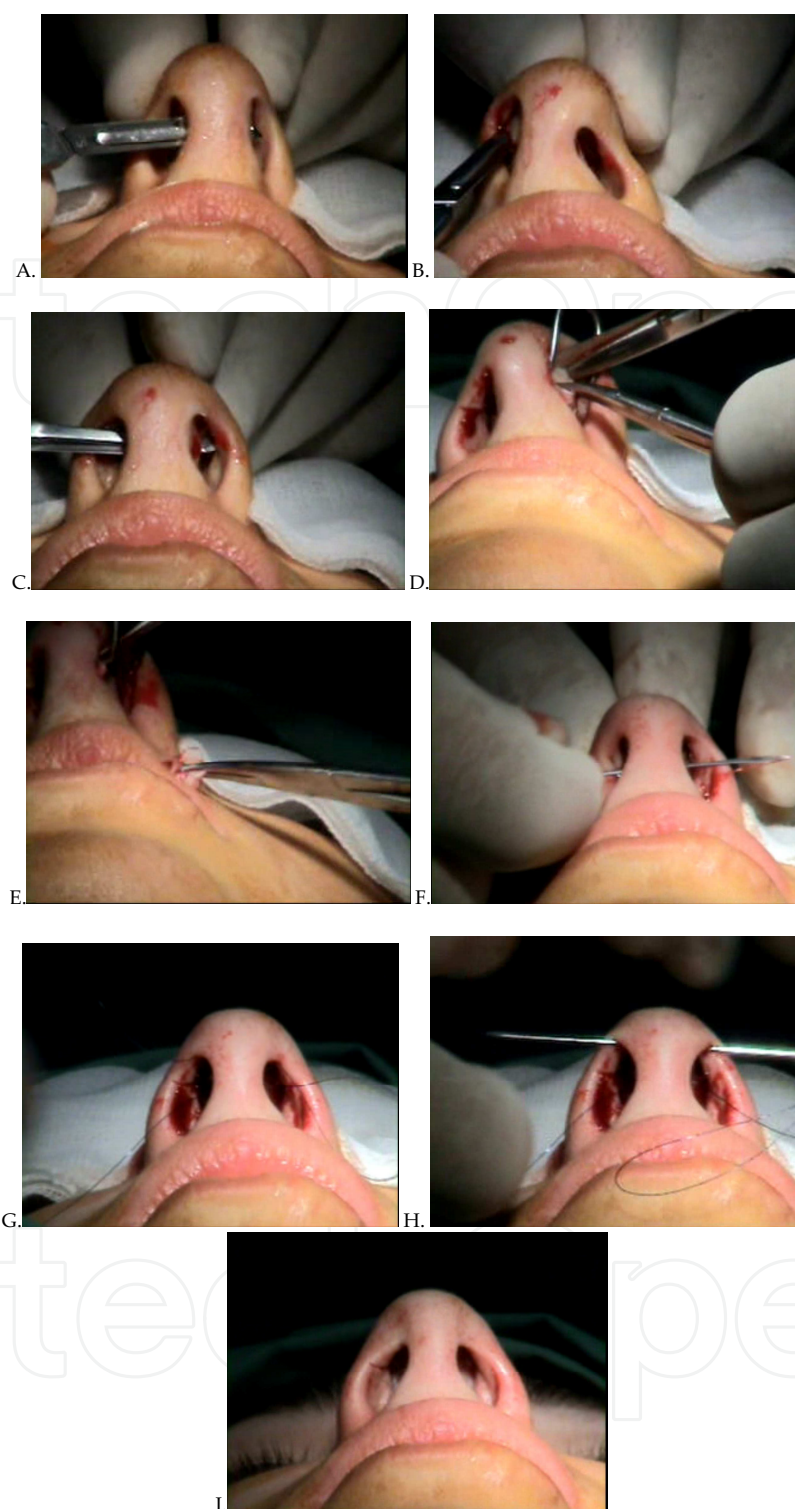


**Figure 4.** T-excision en bloc of 3 triangles: **A.** Transcartilaginous and intercartilaginous incisions form the 2 lateral triangles of the T-excision. The retrocolumnellar and the “90°-to-dorsum” septal incision form the medial triangle of caudal septum excision. The 2 lateral triangles should include the cephalic strip of greater alar cartilages. **B.** Scheme of excised tissue. **C.** Excised T-formation en bloc. This particular T-excision en bloc includes caudal septum in the medial triangle and cephalic part of the greater alar cartilages in the lateral triangles. **D.** Humpectomy and T-excision will give the new profile form of the nose.

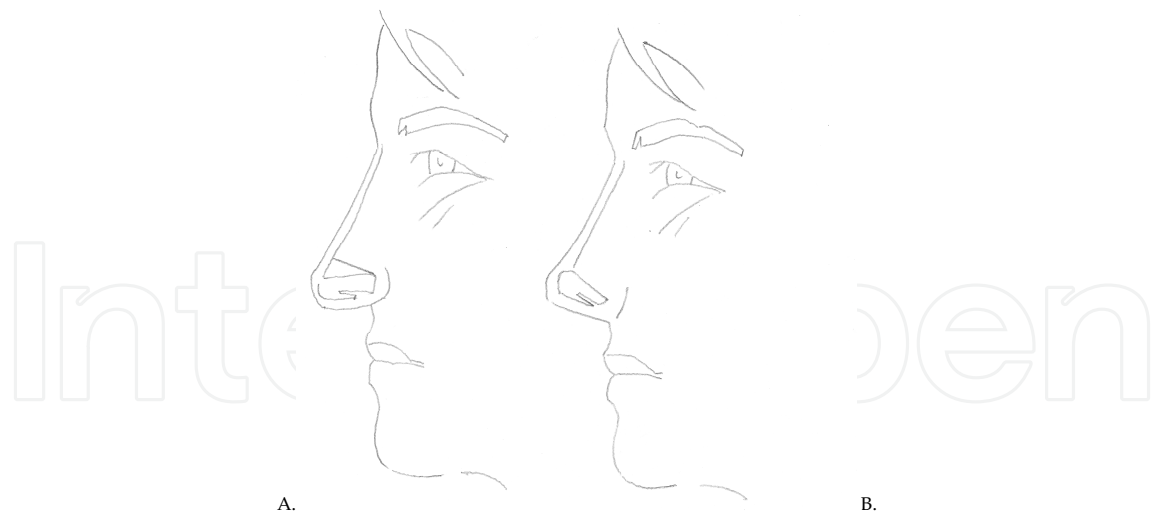T-excision could be used separately in long noses, or as a part of rhinoplasty with hump removal and other additional techniques. The operation is ambulatory, under local anesthesia. The author uses additional IV sedation. The procedure is almost bloodless and atraumatic. Two to three transmucosal mattress sutures are used to fix columella to septum. Stitches are removed after 2–3 weeks, if not absorbed. There is no need of any bandages or tampons. Patients return to their social life almost immediately.

In aesthetics, there is another important aspect – the “beauty triangle,” forming the mid and lower face beauty. It includes the two cheekbones and the chin. The tip of the nose should not disrupt the upper line of the triangle connecting the projection of the two cheekbones, i.e., its prominence has to be on the line between the two cheekbones. Thus, the nasal tip presents an important aesthetic facial volume, forming a straight line together with the volume of the cheekbones (Figure 7).

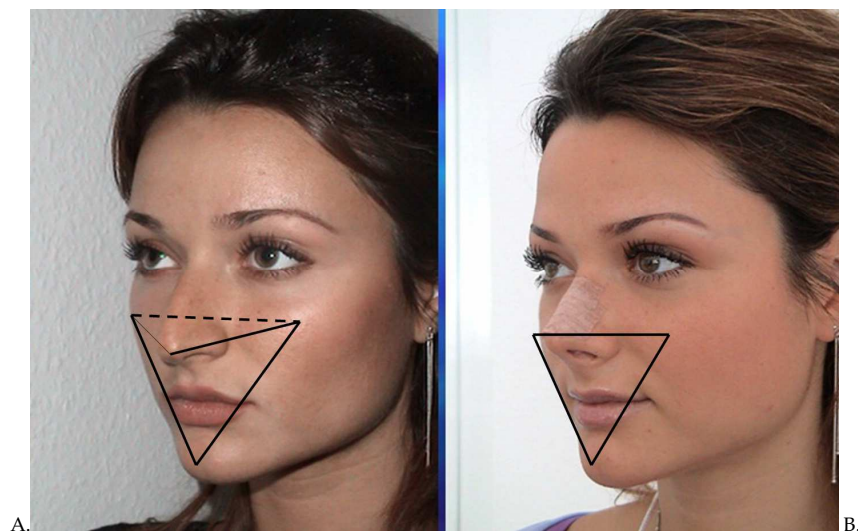




**Figure 5.** **A.** Total retrocolumellar incision. **B.** The retrocolumellar incision is prolonged into intercartilaginous incisions both sides through the opposite nostril, using the opening of the retrocolumellar incision. **C.** Second septal perpendicular to dorsum incision. It will be prolonged into 2 intercartilaginous incisions. **D.** The T-Excision en bloc is separated from the dorsal skin with a blunt tip scissor. **E.** The T-excision is separated and removed, **F.** The transmucosal mattress suture is performed horizontally if the dome is symmetric (or parallel to the asymmetry). **G.** The transmucosal septocolumellar suture is ready to be knotted. **H.** Transmucosal domal suture of medial crura for tip refinement. **I.** Result after atraumatic, nearly bloodless T-excision procedure for nasal tip rotation.



**Figure 6.** A. The unnecessary length of septum will be resected. B. The nasal tip is rotated and a correct tip angle is obtained, adapting the nose into 1/3 of the length of the face.



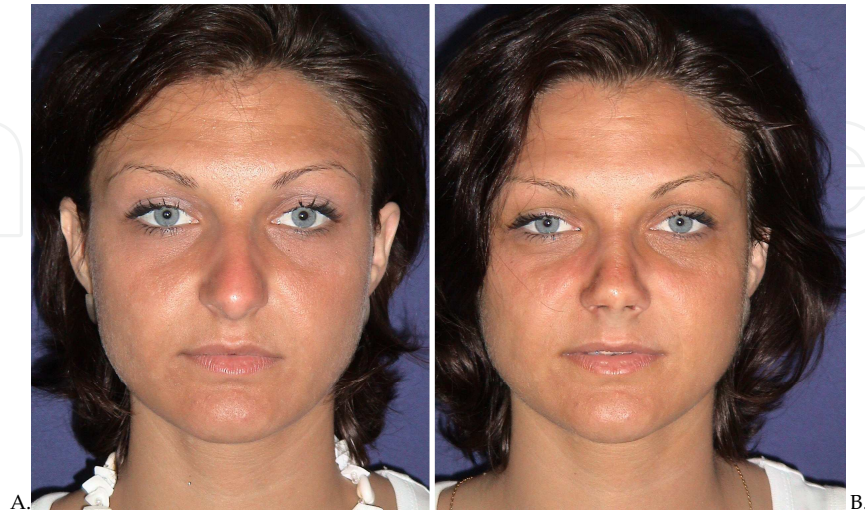**Figure 7.** A case of a long nose. A. Before. The long nose causes incorrect facial proportions. The beauty triangle is disrupted, forming 2 incorrect triangles. The facial features of the patient's face are nice but nearly invisible because of the long and disproportional nose. B. After T-excision for nasal tip rotation and columella sliding for tip projection. The nose is shortened to fit into 1/3 of the face. Correct aesthetic proportions (three equal parts of the face), correct 30° dorsoprofile angle, and nasal tip volume on the line of the cheekbone prominence. The tape is not necessary – it was requested by the patient (a ballerina) to make the operation visible and thus protect her from trauma at work. The result is beautification of the face by correct proportions and angles and visible beauty triangle.

## 6. Clinical cases

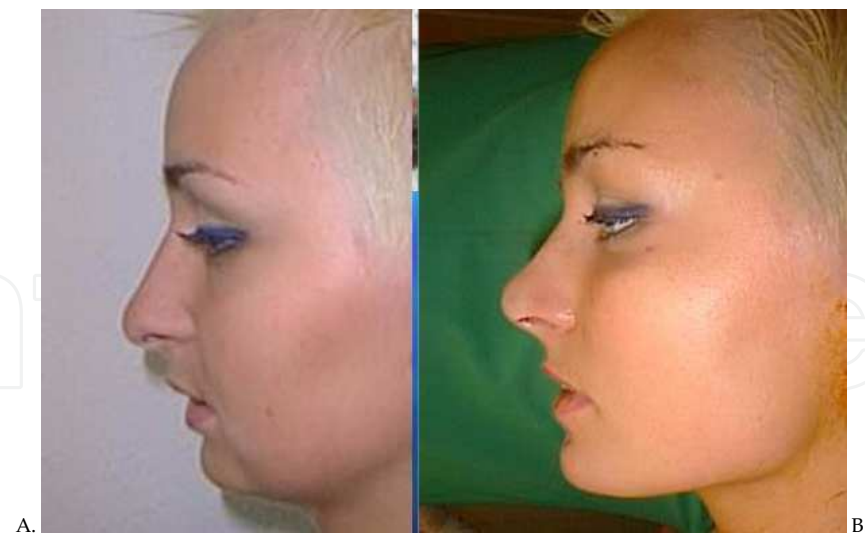Immediately after operation, local anesthesia and postoperative edema raise the dorsum and make the nasolabial angle obtuse, which gives an impression of over-rotation of the nasal tip.



It is a false impression. With the diminishing of the edema in the first 5–7 days, the correct angle takes shape and the tip falls into place.

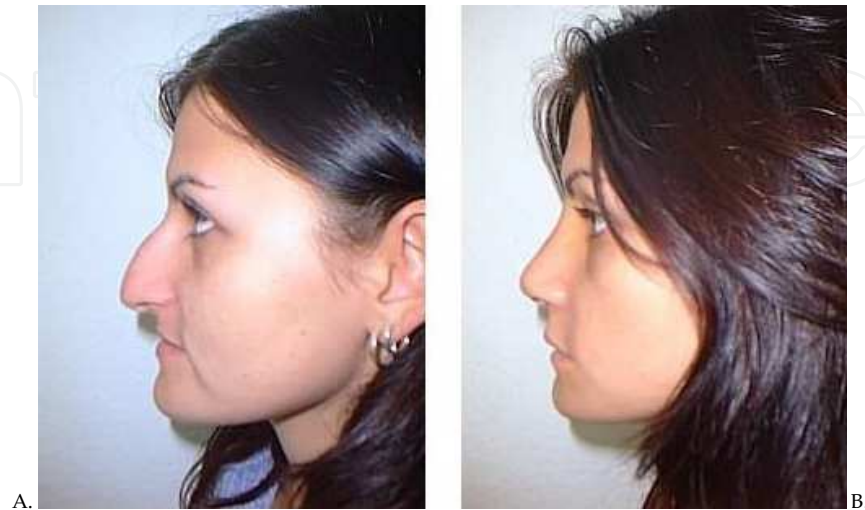

**Figure 8.** T-excision for nasal tip rotation. Immediate result in a case of a long and disproportional nose. **A.** Before. Long nose with hanging columella, resulting in a disproportional face, containing some nice features, nearly invisible to observers. **B.** After. Immediate result, a few minutes after T-excision, nasal tip and lower third refinement by transcutaneous Serdev Sutures®. Swelling could be visible to specialists but not to the public. Aesthetic proportions (three equal parts of the face) are present. The result is beautification of the face – previously invisible beauty is now demonstrated.

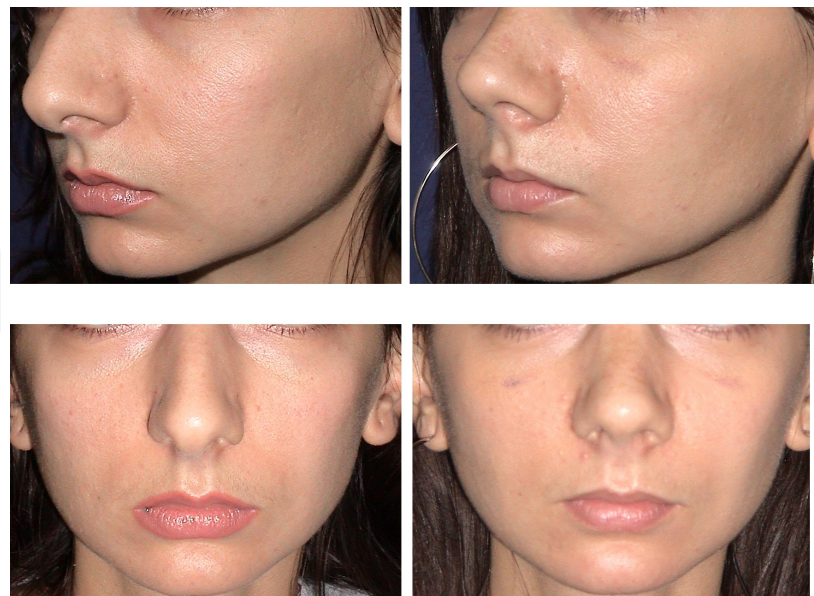

**Figure 9.** Immediate result (Braunol disinfection is still not totally cleaned) after nasal tip rotation by T-excision and chin enhancement by Serdev Suture® in a case of a long nose, small chin (retrognathia), and improper ratio in the lower part of the face (between upper lip and chin); **A.** Before. The upper face is nice, but the nose is long, the chin is small and disproportional. Straight line of the noble profile is missing. Due to short mandible and reduced skeleton support, surrounding and submandibular tissue is hanging; **B.** After. Immediate result after T-excision for nasal tip rotation, columella sliding for tip projection and chin augmentation collecting her own tissue using Serdev Suture® volumizing method. Correct volumes are visible – nasal tip on the line of the cheekbone prominence. The result includes: proper

aesthetic proportions of the face (three equal parts of the face); tip is correctly rotated; and the nose is proportional. The tip is projected to fit to the proper  $30^\circ$  dorsoprofile angle; the chin is augmented using her own collected tissue, without foreign materials; jaw line and submandibular line are stretched; lower face proportions are corrected: lip to chin ratio (incl. lower lip) is 1:2; straight noble profile is present. The immediate result presents the beauty of the face.



**Figure 10.** **A.** Before. Aquiline long nose, short upper lip, and prognatic jaw. **B.** One year after T-excision for nasal tip rotation, humpectomy, digital fracture instead of lateral osteotomy, caudal septum and nasal spine resection for upper lip elongation, upper lip volumizing by Serdev Suture®. Changes include: proper angles of the nose; it occupies 1/3 of the face, correct aesthetic proportions of the face (three equal parts); the upper lip is elongated and brought forward (thus, the prognatic jaw is included in the correct proportions); proportions of the lower face are in a good ratio; a straight noble profile is present. The result is beautification of the face.



**Figure 11.** A disproportionally long nose is shortened by tip rotation via T-excision to obtain 3 equal parts of the face with correct angles of the nose.

## 7. Conclusion

Beautification is a work of art. Rhinoplasty, including shortening of a long nose, aims at obtaining exact aesthetic proportions, volumes, and angles of the face. The nose cannot be separated aesthetically. T-excision en bloc, including cephalic strip and elongated caudal septum resection can rotate the nasal tip to obtain correct proportions of the face. The procedure takes a very short time, even shorter than a medical injection rhinoplasty. It is atraumatic, nearly bloodless, does not require plaster fixation, tampons, and downtime. The results are permanent.

Patients return to work and social life almost immediately. There is no bruising. Edema is not visible for observers. Swelling can minimally change the tip position only in the first 5–7 days. After that it becomes natural and in the right position. T-excision is the shortest rhinoplasty procedure to correct long noses and dropping columella, with the most stable and permanent results, due to very small or lack of trauma to the greater alar cartilages and surrounding tissue.

### 7.1. In cases of over-rotation or short upper lip

If the upper lip is shortened by a too long septum or shortening of the whole pyramid of the nose is necessary, the prominent posterior septal angle can be excised, together with the prominence of the anterior nasal spine. This maneuver deepens the nasolabial angle. It elongates the upper lip and can also correct an over-rotated nasal tip (see Chapter 2)

## Author details

Nikolay P. Serdev\*

Address all correspondence to: serdev@gmail.com

New Bulgarian University, Sofia, Medical Centre “Aesthetic Surgery and Aesthetic Medicine,” Sofia, Bulgaria

## References

- [1] Serdev NP. Principles of Face Beautification. Ier Congreso Internacional De Medicina y Cirugia Cosmetica, The South American Academy of Cosmetic Surgery, Buenos Aires – Argentina, Oct. 31–Nov. 1, 1999
- [2] Serdev NP. Sliding of the Columella by the Serdev Technique. Live Surgery Workshop, The International Academy of Aesthetic Surgery and Aesthetic Medicine, Krulig Clinic, Caracas, Venezuela, Nov. 1999

- [3] Serdev NP. Principles of Face Beautification. Third World Congress of the International Society of Aesthetic Surgery, Tokyo April 8-10, 2000
- [4] Serdev NP. Rhinoplasty for Beautification. Asia Pacific Craniofacial Association. Third Conference, Shanghai, P.R. China, Oct. 30–Nov. 1, 2000
- [5] Serdev NP. Beautification rhinoplasty. *Int J Cosm Surg* 2001; 1(3): 257-311
- [6] Serdev NP. Aesthetic surgery methods for face beautification. *Int J Cosm Surg* 2001; 1(3): 188-256
- [7] Serdev NP. Serdev techniques in beautification rhinoplasty: T-zone excision, columella sliding, Serdev sutures. *Int J Cosm Surg* 2008; 8(1):388-469
- [8] Serdev NP. Nasal tip refinement, rotation, projection, alar base narrowing In: Serdev NP, Ed. *Serdev Sutures® Face and Body Lifts and/or Volumising*. Marllor editions, Italy, 2013: 75-81
- [9] Serdev NP. Serdev Sutures® in middle face 4. Beautification rhinoplasty – tip rotation and refinement, alar base narrowing. In: Serdev NP, Ed. *Miniinvasive Face and Body Lifts – Closed Suture Lifts or Barded Thread Lifts*. Intech, Rijeka, 2013. Available from <http://www.intechopen.com/books/miniinvasive-face-and-body-lifts-closed-suture-lifts-or-barbed-thread-lifts/serdev-sutures-in-middle-face>.
- [10] Daniel RK. Tip. In: *Rhinoplasty: An Atlas of Surgical Techniques*. New York, Springer-Verlag New York Inc; 2002; pp. 59-139

