

We are IntechOpen, the world's leading publisher of Open Access books Built by scientists, for scientists

6,900

Open access books available

186,000

International authors and editors

200M

Downloads

Our authors are among the

154

Countries delivered to

TOP 1%

most cited scientists

12.2%

Contributors from top 500 universities



WEB OF SCIENCE™

Selection of our books indexed in the Book Citation Index
in Web of Science™ Core Collection (BKCI)

Interested in publishing with us?
Contact book.department@intechopen.com

Numbers displayed above are based on latest data collected.
For more information visit www.intechopen.com



Medical Rhinoplasty – The Treatment of Mimical Patients

Alessio Redaelli

Additional information is available at the end of the chapter

<http://dx.doi.org/10.5772/62071>

Abstract

The plunging tip of the nose is a diffused cosmetically annoying problem. The medical rhinoplasty is a useful tool for the repair/reshaping of the plunging tip of the nose when the genesis is mimical. Botulinum toxin is used to repair this deformity. The anatomical details, the preparation of the materials, and the technique are discussed in this chapter with all the details that will permit the readers to understand and repeat the technique.

Keywords: Nasal profile, botulinum toxin A, mini-invasive rhinoplasty, nasal tip, muscles, nasal angles, depressor septi nasi, levator labii alaeque nasi, Dante's nose, plunging tip, hyper-projected nose, hypoprojected nose, aesthetics, beauty, aging

1. Introduction

The nose has always been one of the most important organs of our being. It characterizes indelibly our future habits from the very beginning of our life (such as the incredible example of salmon's olfactory imprinting at birth known as natal homing or natal philopatry: the homing process by which they travel for thousands of miles to breed in that particular stream where they were born) until death when we feel that particular smell of death [7,9].

In Chinese face reading, the nose is considered to be the money spot, especially during the ages of 41 to 50.

There is no place in the world where I go, where I am not asked to improve the appearance of the nose, no matter what the race, Asian or European, Afro-American or Japanese.

The nose determines the facial symmetry in a peremptory manner and represents our inner and outer bow. It is certainly one of the most exposed parts of our face to the attention of our partners, when we meet them for the first time. And this was especially true in the past centuries where also the figureheads (figureheads of ships) that adorned the bow of the ship

put clearly in evidence the importance of nose (Fig.1), the bow of our thinking and being. It is therefore not strange that the technique published by me back in 2008 is today definitely one of the most widespread and known techniques of facial rejuvenation.



Figure 1. Figureheads of ships.

The facial aging is mainly due to three factors: the first is certainly the important reduction of volumes, the second the mimical movements with the arising of all the wrinkles on the face, and the third is due to the tone of the skin and subcutaneous tissue.

The exact understanding of the genesis of the defects we see all over the face provides the base for the treatments that we then adopt to repair these defects and the nose, of course, underlies these rules.

Knowing exactly when nasal defects became part of official medicine is impossible to date with precision. Egyptians 3000 years ago already knew about nasal surgery, also because of their important experience in embalming the dead. Even in China, because of the tradition of cutting the nose of adulterers, and many other types of criminals, there was a culture in the treatment of nasal defects. In the later period of the Middle Ages, several of these techniques became obsolete. But with the Renaissance there was a new impetus, particularly in Italy with the famous school of the Brancas, in Sicily and Gaspare Tagliacozzi (Bologna) [1]. The Branca and Gaspare Tagliacozzi both are very famous for the so-called flap Italian (Fig. 2).

Probably, Jaques Joseph is the father of the modern surgical rhinoplasty, finding also a new method to reshape/repair the abnormally enlarged nasal wings (negroid nose) in black people (1904). But the first real medical rhinoplasty was most probably performed by the Belgian doctor Broeckaert [2] in 1901 (Fig. 3).

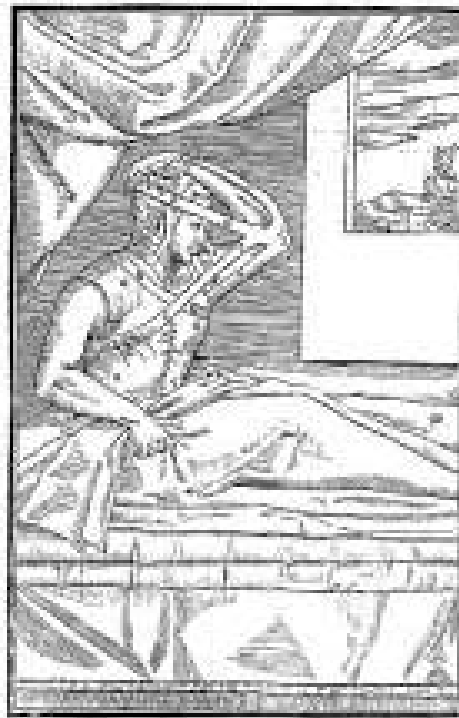

Figure 2. “Flap Italian.”

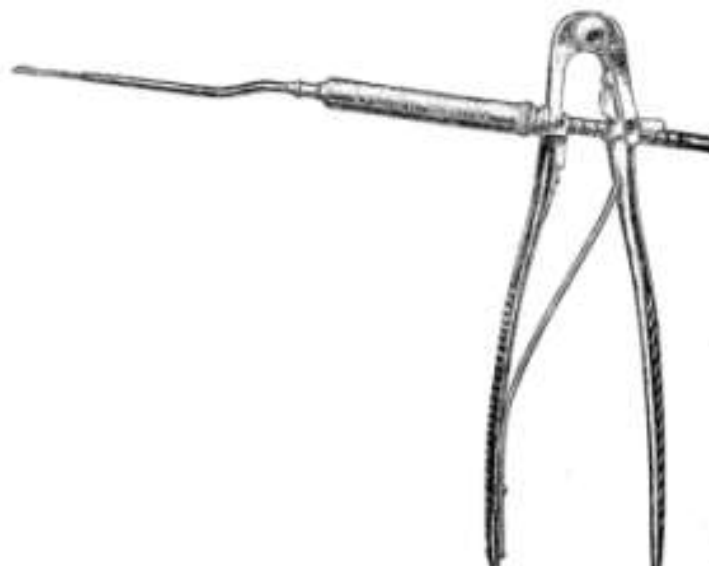


Figure 3. Broeckaert's syringe.

This doctor had invented a special syringe which was used to inject liquid paraffin (obtained also by pressure) in the soft tissues: here, I do not mention the side effects. We arrive finally to the present day with a huge improvement in all surgical techniques and with the advent of mini-invasive techniques and also of medical rhinoplasty, to be performed exclusively with medical techniques and, in detail, with the combination of botulinum toxin and fillers.

In my experience, over 80% of patients who arrive in our medical studies have major or minor nasal defects but only a small part of these patients, around 15–20%, agree to surgery. Others hesitate to meet the doctor for fear of undergoing an invasive and potentially dangerous procedure or because the defect, although sometimes clearly felt, is still very mild.

Finally, I want to mention that the nose is subject of the important phenomenon of aging just like all other areas of the face. It can get to present a drop of the tip up to 3–4 mm. In addition, a surgical nose perfectly corrected, and beautiful for a long time postsurgery, may after a few years begin to present some skeletonization that can be cured with a resorbable filler.

The main indications for medical rhinoplasty are:

- Aesthetical patients: mimical, volumetrical, and for deep bridge enhancement in Far East and African races.
- Surgical patients: the gold standard for correction is surgery, but they do not accept this solution, and so with medical rhinoplasty we can strike a good compromise.
- Postsurgical patients: to improve all those little postsurgical defects, once the object of a very difficult postsurgical reintervention.
- Functional patients: affected by atrophic rhinitis and atrophic generic problems to get a thicker mucosa.

In this chapter, we will focus mainly on patients with mimical deformity.

2. Anatomy

A quick reminder about anatomy [4,5,9,10] will be useful to readers. The skeleton is described in Fig. 4. Its main parts are the nasal bones, the alar triangular cartilages, the minor alar cartilages, and finally the Great (or major) alar cartilage. The vascularization starts from the lateral nasal vessels and columellar vessels arriving from the external carotid artery and the angular vessels arriving from the internal carotid artery and finally the dorsal nasal artery arriving from the frontal lobe. It is important during all the techniques described in this section to pay particular attention to these vessels that must not be injected.

In the nasal base, triangular, visible from the inferior projection, we can find in the middle the columella, while laterally the nasal wings are well-delineated by the lateral, intermediate, and medial crus of the greater alar cartilage.

The nasal muscles are visible in Fig. 5. The depressor septi nasi muscle and the levator labii alaeque nasi are most important for medical rhinoplasty. The depressor septi nasi muscle has a vector of contraction parallel to the columella and pushes the nasal tip toward the maxillar bone. The levator labii alaeque nasi (elevator of the lip and nasal wings), instead, elevates the nasal wings, contemporaneous with the lip. So we can describe a real rotational movement that characterizes some individuals (Fig. 6).

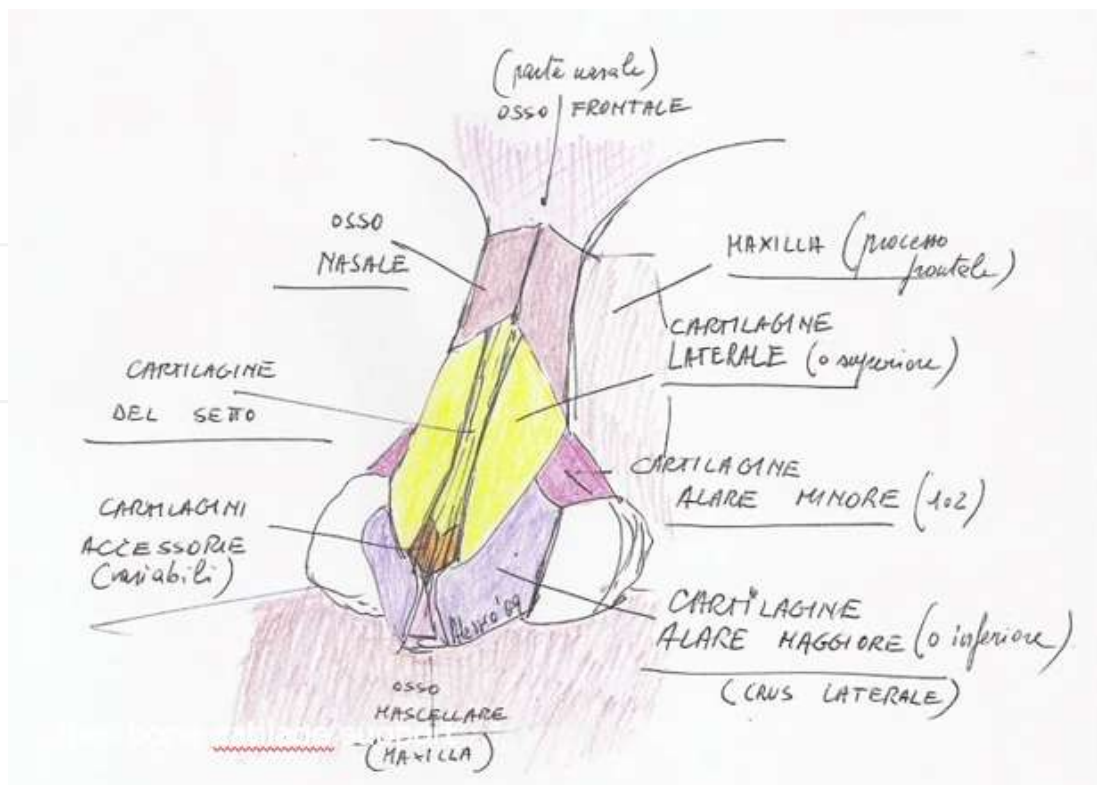


Figure 4. Bones and cartilages of the nose.

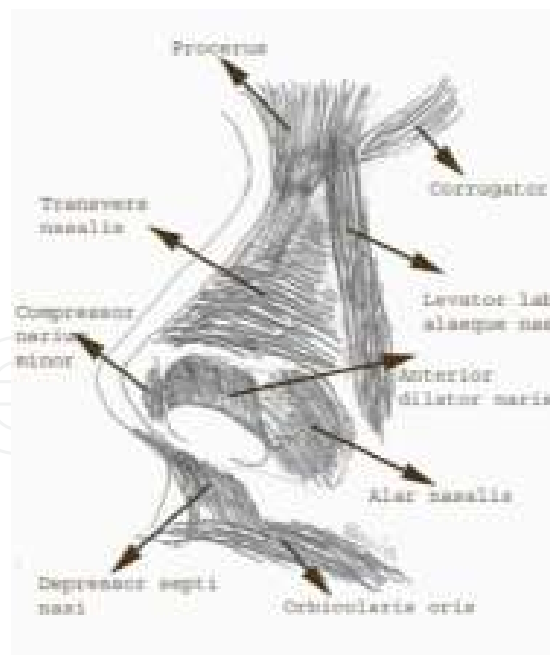


Figure 5. Bones and cartilages of the nose.

The superficial layer is characterized deeply by a superficial fascia that covers all the nasal muscles, extension of the facial SMAS. The subcutaneous layer and epidermis are characterized

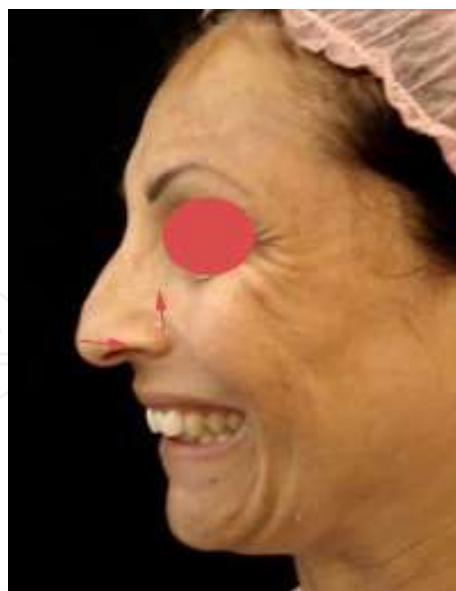

Figure 6. Nasal motion arrows.

by a thick and less adherent skin at the root of the nose, a very thin and more adherent skin in the middle, and finally a thicker and also adherent skin that covers the tip of the nose.

3. Aesthetical study

The aesthetical study is based as always on strict rules. All the measures of the face have been described many centuries ago by Italian scientists like Leonardo da Vinci and must be exactly known by every doctor who wants to use this technique.

The main nasal points of interest are described in Fig. 7. The nasal area is from the Glabella to the Nasal spin through Nasion, Rhinion, and Nasal tip.

In the same figure, it is possible to study the main nasal angles: nasofrontal angle, from 115° to 135° ; dorsal angle, normally straight or slightly lower; nasolabial angle, from 90° to 110° .

In the perfect aesthetical indication, the nasofrontal and nasolabial angles are slightly reduced, while the dorsal angle is a bit increased (see Fig. 7).

Table 1 lists the main aesthetical indications.

The nose is generally connected to all other areas of the face, particularly the malar area, the lips, and the chin [10]. In particular, Angle's classes are of great importance. I will not dwell too much on their description since this can be studied accurately in many specific texts. I would only emphasize on the importance of Ricketts' e-line, which connects the tip of the nose with the Pogonion. It will always be of great importance to control the real projection of the chin and areas around the nose. It will be of evidence how even a rather long and hyperpro-

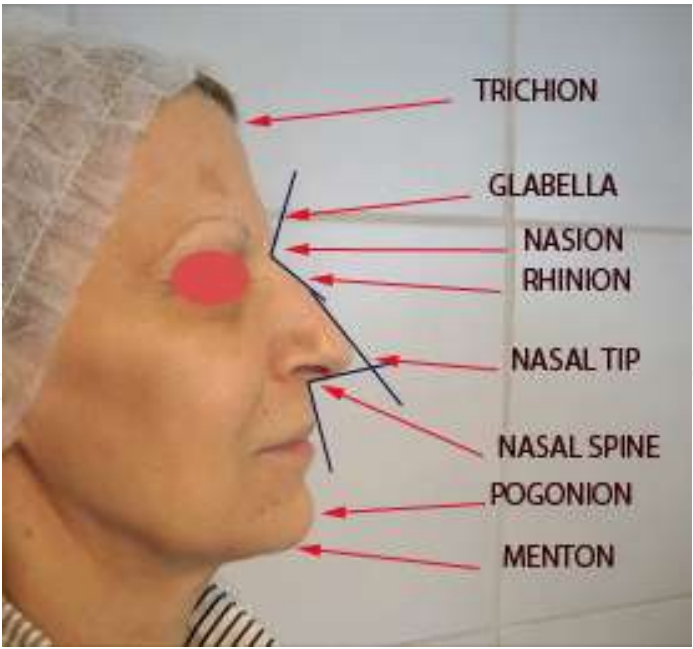

Figure 7. Nasal points of interest.

SO WHEN WE TREAT THE NOSE

- when there is a visible problem
- when the nasofrontal angle is reduced
- when the naso labial angle is reduced
- when the nasal cartilages are too visible
- in all short noses
- in all long noses when we can reduce it

Table 1. Aesthetical indications.

jected nose may be such that, in some cases, for an opposite hypoprojection of the zygomatic-malar and mental areas, for example, in a second skeletal class. (Fig. 8)

4. Treatment of mimical patients

In a wide number of studies, it is confirmed that about 60% of patients with the typical plunging tip of the nose present a really mimical genesis for the hyperactivity of the depressor septi nasi (depressor of the nasal tip) or the levator labii alaeque nasi (elevator of the lip and nasal wing). The treatment of these patients is based on the use of Botulinum toxin A.

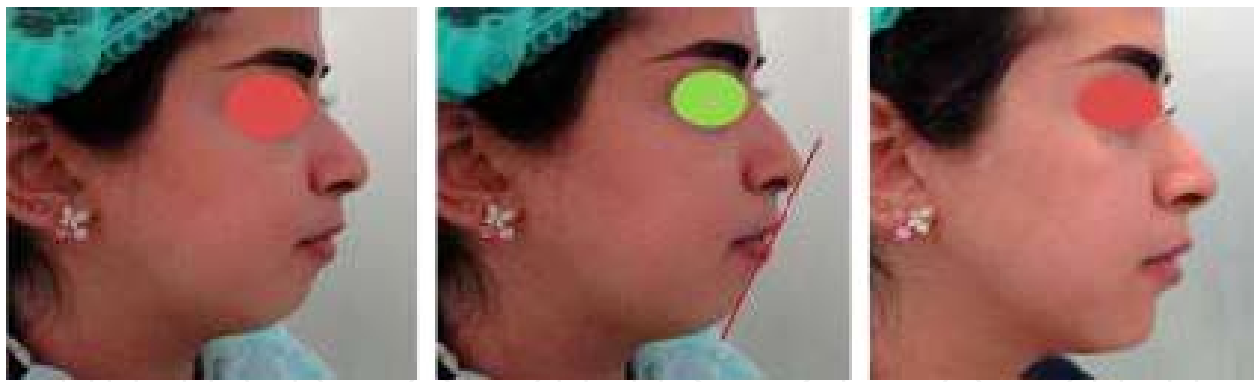

Figure 8. The importance of the chin. An interesting case of a Middle Eastern patient, 2' skeletal class, who was treated with a filler on the chin, before and after treatment. It is immediately possible to see how many changes occur as well as the projection of the nose, and overall changes on the whole face.

Botulinum Toxin A (BTxA) is a neurotoxin approved in many countries and also in Europe. Its "On-Label" use is in the glabellar region. Other uses and also the treatment of mimical patients with the plunging nasal tip, include an "Off-Label" indication.

While for an "On-Label" treatment, the informed consent could even be oral (although I always ask the patient to sign up in writing anyway), in all "Off-Label" indications I remind all readers that the informed consent must necessarily be in writing.

All classical contraindications of BTxA must be completely investigated and as always in medicine a complete anamnesis must be done. We cannot treat patients with myasthenia and myastenic form syndromes (Lambert Eaton) and patients who are allergic to components of the product.

Patients requiring a fine control of the movements of the upper lip, and peri-oral area, like the players of musical instrument or singers, are a strict contraindication.

4.1. Materials approved in Europe

The materials approved in Europe (Fig. 9) are:

- **Vistabel/Vistabex/Cosmetic Botox:** Derived from **Botox**, Allergan, Irvin California. It can be stored in the refrigerator between 2° and 8° and it is in vials of 50 or 100 U.
- **Azzalure:** Distributed in Europe by Galderma, directly derives from **Dysport**, Ipsen. It is moderately stronger than Botox; it must be stored in a refrigerator between 2° and 8° and is available in vials of 125 U.
- **Bocouture:** Distributed in Europe by Merz, directly derives from Xeomin. In Europe, it is available in vials of 50 U. It can be stored at room temperature.

The different preparations are not interchangeable and the specific units are diverse, just like their action in the tissues.



Figure 9. Materials approved in Europe.

4.2. Preparation of materials

All the materials are in a dry-vacuum vial and must be prepared just prior to the treatment. For the dilution, physiological solution is normally used [3,8].

Vistabel 50 U is diluted with 1.25 ml (1 U in 0.025 and 4 U in 0.1 ml). Azzalure 125 U is diluted with 0.63 ml (5 U in 0.025 and 20 U in 0.1 ml). Bocouture 50 U is diluted with 1.25 U (1 U in 0.025 and 4 U in 0.1 ml)

In particular conditions (for particularly fine areas as for example the mouth, to treat very thin muscles, etc.), it is possible to dilute less to obtain a very concentrated material. If we dilute less or more, the U contained in the final solution will be accordingly different.

Why do I often dilute less? What is the philosophy behind this concept? If the readers check the specifications in the leaflet inside the vials, they will find that some side effects such as headache, ocular disorders such as blepharo-ptosis, and eyelid edema are likely to occur (between 1/10 and 1/100). I believe that these side effects can be due to the excessive dilution. This can lead to an excessive spread of the toxin in anatomical regions that are too close not to be affected by its effect (such as the upper eyelid). This can happen especially in some patients with particular kind of atonic tissues. Prudence in aesthetic medicine is one of the most important issues to follow.

Finally, I want to highlight the syringe I use normally, a 0.5 ml syringe for diabetes or, better, a 0.3 ml syringe for diabetes with inserted needle 30 G x 8 mm. The demi-type syringe is perfect (Fig. 10).

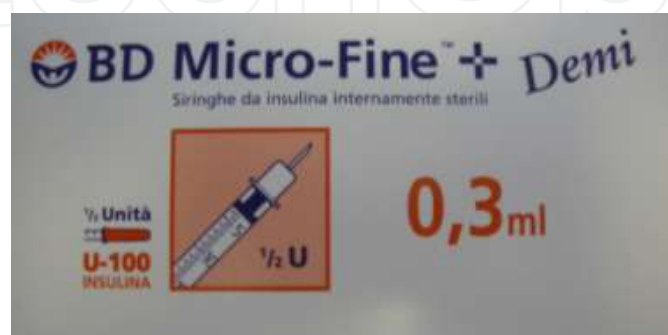

Figure 10. A demi-type 0.3 syringe.

4.3. Study of patients

Before the treatment of mimical patients, it is mandatory to completely study their movement, to exactly understand if there is an indication to the treatment and which muscles must be injected. For this reason, we have a moment that is so important to understand the movements: the first 2 or 3 minutes of the visit, when we give our hand to the patient and she/he is completely natural, and moves without being conscious of being observed.

In these first moments of the visit we have the opportunity to see the nasal tip that is much depressed in mimical patients, and especially if we have to see the rotational movement, we speak few lines before.

In the majority of patients, we can see the typical movement of the depressor septi nasi: the tip of the nose is pushed down toward the maxillar bone (Fig. 11 b). In such patients, it is possible to see also the contemporary movement of the levator labii alaeque nasi as the nasal wings can arise. At the same time, the nasolabial angle tends to reduce, much lower than 90°.

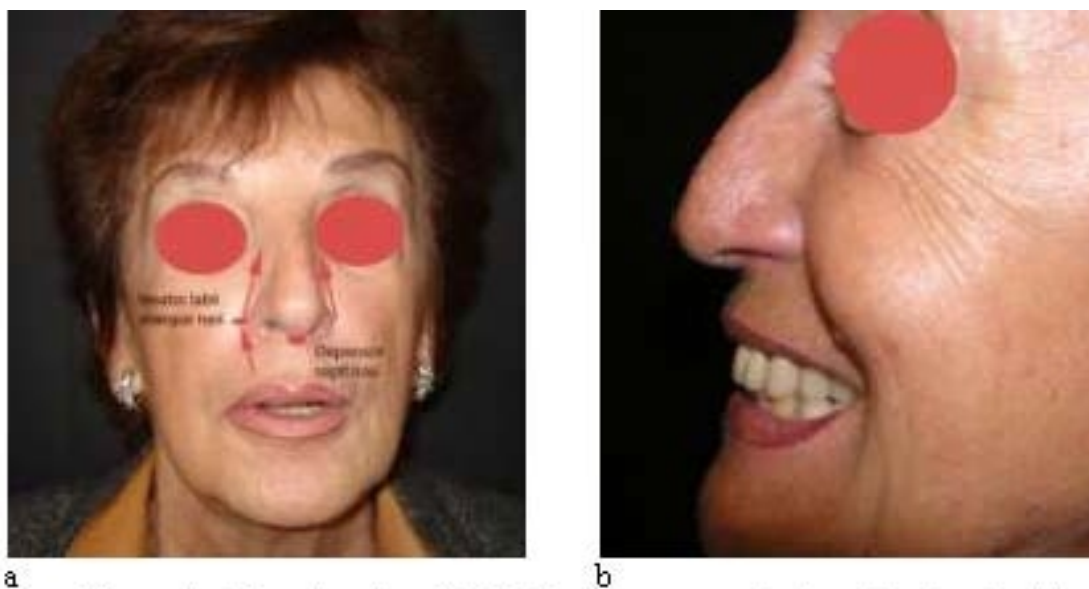

Figure 11. A mimical patient is studied before the treatment in frontal projection (a) and in profile (b)

4.4. Treatment of the “Depressor septinasi” muscle

The depressor septi nasi muscle, as described earlier, is inserted on the maxillar bone at the nasal spine. Its fibers rise toward the nasal tip through the columella [8,9].

This treatment is based on the injection of fibers or in the columella or at the nasal spine. I normally use a 0.5 ml syringe for diabetes. I inject 4 U Vistabel/Bocouture or 10U Azzalure.

The left hand opens the side of the columella to be injected, making also a light rotation of the nasal base.

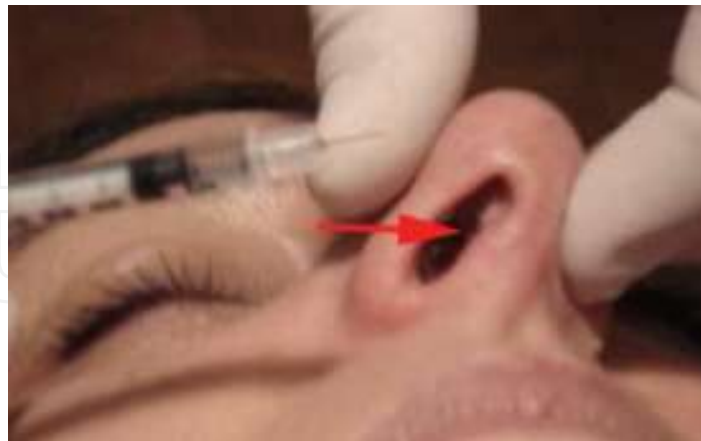

Figure 12. Injection of the columella.

The other hand holds the syringe and injects perpendicularly to the columella axis (Fig. 12). If we inject the muscle along the columella, the risk of affecting nearby muscles is usually nil.

It is possible also to inject the muscle at the nasal spine (Fig. 13). In this case, it is possible also that a very small quantity of toxin can spread in some fibers of the nearby muscles, especially the Buxinator muscle that makes the deep muscular layer around the lips. This is the reason why some patients come back for a retouch 15 days later, reporting sometimes that they feel a bite in their cheeks: the buxinator muscle, for some days, partially loses its precision in keeping food under the teeth. It disappears by time and a useful advice for patients regarding this possible side effect is to pay attention to chewing.

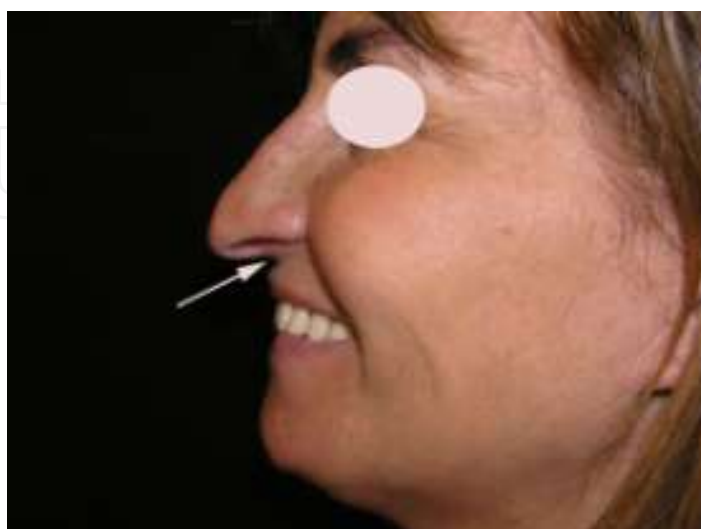

Figure 13. The nasal spine.

4.5. Treatment of the “elevator of the lip and nasal wing” muscle

In Fig. 13, it is possible to see the important elevation of the nasal wing up and laterally, clearly visible in the profile projection. This is very important especially in black and Far East races, where the widening of the nasal base while smiling is very typical.

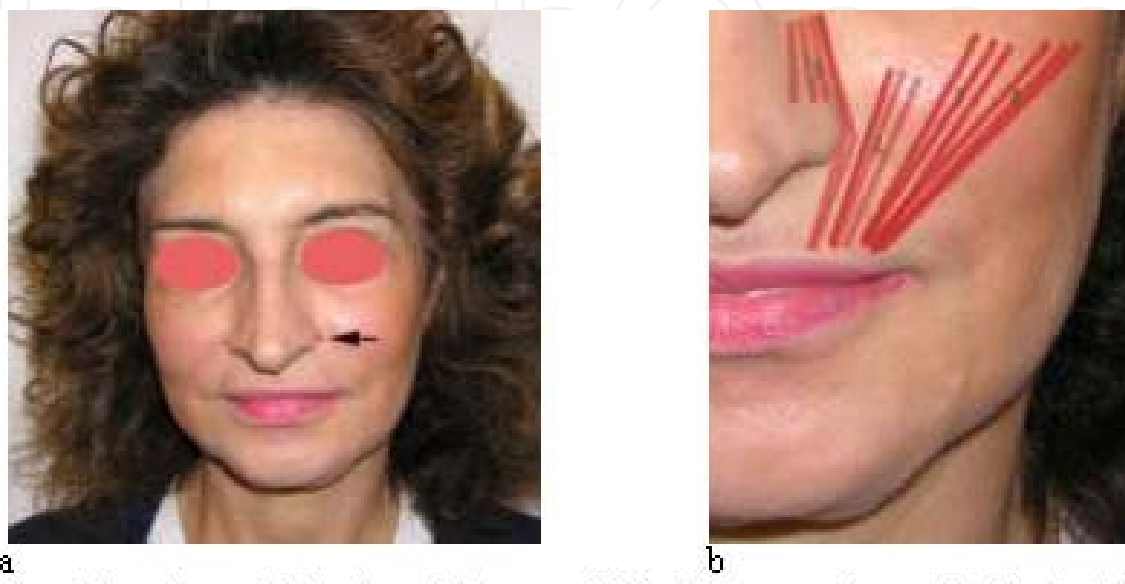


Figure 14. Points of injection of “levator labii alaeque nasi” muscle (a). In (b) it is possible to see the position of the elevator muscles of the upper lip: 1 – levator labii alaeque nasi, 2 – elevator of the lip, 3 – zygomaticus minor, 4 – zygomaticus major.

In Fig. 14a and b, it is possible to see the injection points and the elevator muscles of the upper lip.

Normally, I inject at the elevator of the lip and nasal wing at their half, just laterally to the nasal wings, as visible in Fig. 14a. It is important to remain medially, since just laterally to this muscle we find the elevator of the lip [8,9].

As has been said many times, it is of great importance to study the patients. So, if we have a concomitant gummy smile, the risk of injections will be very low. Otherwise, if we do not want definitely a lip lowering, we will remain totally in the “elevator of the lip and nasal wing” [8].

So if we have a concomitant gummy smile, we want a greater spread of the toxin and I dilute with the normal dilution (1.25 ml for Vistabel/Bocouture and 0.63 for Azzalure) or even more.

If, instead, I want to avoid any spreading in nearby muscles I will dilute the material with a lesser quantity of physiological water (1 ml for Vistabel/Bocouture and 0.5 for Azzalure).

There is no real rule about the number of Units to use, but if we want to remain prudent I suggest the readers not inject more than 4 U Vistabel/Botox/Bocouture/Xeomin or 5 U Azzalure/Dysport.

Example 1:

In the case of a 63-year-old patient who comes to me for the treatment of BTxA for facial wrinkles, in the study prior to treatment it is possible to clearly see the depression of the nasal tip by muscular genesis.

She has a good indication for the treatment of nasal depression muscles.

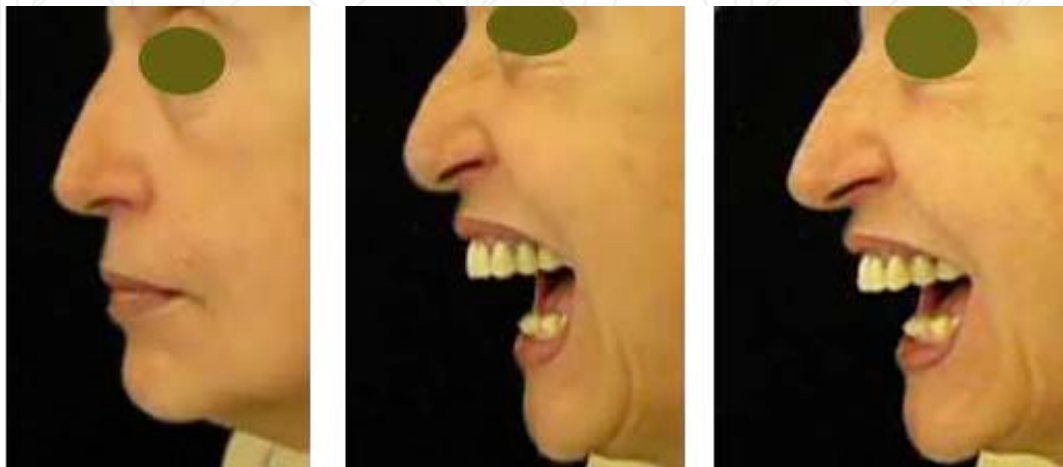


Figure 15. The patient is studied before in basic position (a), during movement (b), and after 15 days (c).

The patient was treated only in the columellar injection point with 2 U Vistabex per side. I used a 0.5 ml syringe and the dilution used was with 1.25 ml.

I probably made a mistake not to treat also the levator labii alaeque nasi, since the movement was very important and especially after 15 days it was more visible, compared with the image of the movement before the procedure.

Author details

Alessio Redaelli*

Address all correspondence to: mail@docredaelli.com

Visconti di Modrone Medical Center, Milan, Italy

References

- [1] Tagliacozzi G. De curtorum chirurgia per insitionem. Venezia; 1597.
- [2] Broeckaert J. Prothèse nasale au moyen d'injections de paraffine. Gand; 1901.

- [3] Redaelli A. Botulinum toxin dilution: our technique. *J Cosm Laser Ther* 2003; 5: 218–219.
- [4] Dayan SH, Kempiners JJ. Treatment of the lower third of the nose and dynamic nasal tip ptosis with Botox. *Plast Reconstr Surg* 2005; 115(6): 1784–1785.
- [5] Rohrich RJ, Huynh B, Muzaffar AR, et al. Importance of the depressor septi nasi muscle in rhinoplasty: anatomic study and clinical application. *Plast Reconstr Surg* 2000; 105(1): 376–383; discussion 84–88.
- [6] Redaelli A. *The Aesthetic Medicine*. Firenze: See-Editrice; 2009.
- [7] Redaelli A. Medical rhinoplasty with hyaluronic acid and botulinum toxin A: a very simple and quite effective technique. *J Cosm Dermatol* 2008; 7, 210–220.
- [8] Redaelli A. *The Botulinum Toxin A in Aesthetic Medicine, for the Treatment of Hyperhidrosis and in Odontostomatology: Basic Principles and Clinical Practice*. 2nd ed. Firenze: OEO; 2012.
- [9] Redaelli A., Braccini F. *The Medical Rhinoplasty: Basic Principles and Clinical Practice*. Firenze: OEO; 2010.
- [10] Redaelli A, Braccini F. *Facial Aging: Medical, Surgical and Odontostomatological Solutions*. Firenze: OEO; 2011.