

We are IntechOpen, the world's leading publisher of Open Access books Built by scientists, for scientists

6,900

Open access books available

186,000

International authors and editors

200M

Downloads

Our authors are among the

154

Countries delivered to

TOP 1%

most cited scientists

12.2%

Contributors from top 500 universities



WEB OF SCIENCE™

Selection of our books indexed in the Book Citation Index
in Web of Science™ Core Collection (BKCI)

Interested in publishing with us?
Contact book.department@intechopen.com

Numbers displayed above are based on latest data collected.
For more information visit www.intechopen.com



Intra-Articular Autologous Platelet Concentrate (APC) in the Treatment of Induced Knee Osteoarthritis (OA) in Rabbits — An Arthroscopic Evaluation

Cleuza Maria de Faria Rezende, Fabíola Paes Leme, Gilcinea Santana, Esteban Osório Carmona and Jessica Alejandra Castro Varón

Additional information is available at the end of the chapter

<http://dx.doi.org/10.5772/62158>

Abstract

The treatment of osteoarthritis is a constant challenge in veterinary and human medicine. It is a disabling disease of widespread occurrence, whose primary purpose of treatment has been the relief of pain and improvement or maintenance of joint function. New therapeutic alternatives are continuously researched around the world. Among the alternatives is the use of autologous platelet concentrate (APC) or platelet rich plasma (PRP) intra-articular. CAP may have an important role in modifying therapy of osteoarthritis. It is easy to use and relatively low cost, which has led to research interest and to a wide clinical application. Clinical use has shown positive results, but standardized scientific studies and continued evaluation of the treatment are lacking. Many questions remain unanswered. Arthroscopy is a diagnostic and therapeutic method that can help to understand the action of this therapy. Experimental studies show marked reduction of synovitis, which explains the improvement observed in clinical cases.

Keywords: Arthroscopy, cellular therapy, regenerative medicine, cranial cruciate ligament, osteoarthritis, rabbit

1. Introduction

Osteoarthritis (OA) is a progressive disease that is painful and disabling. The available treatments for OA are unsatisfactory. The early diagnosis and monitoring of OA progression and treatment persist as challenges. Joint injuries represent a large percentage of cases in the treatment routines of veterinary hospitals. Such injuries may be due to trauma or diseases such as hip or elbow dysplasia, or they may have an immune-mediated origin. All species may be

affected, but due to their greater contact with humans, dogs and cats are the animals most often referred for treatment. However, treatment is often given late, which reduces the chances of effectively controlling the problem and makes these animals candidates for prosthesis or even euthanasia.

One of the most common causes of lameness in dogs is the complete or partial rupture of the cranial cruciate ligament (CCLr[1–3]), whereby joint instability induces inflammatory and cellular changes causing synovitis, osteoarthritis, meniscal injury, and joint dysfunction.[2] OA results from a complex interaction between biochemical and biomechanical factors and possible changes involving all tissues such as the articular capsule and the subchondral bone and ligaments, resulting in the destruction of articular cartilage.[4–7] Changes in the articular surface are the most well documented histologically and biochemically.[8]

Although it is a constant topic of constant studies, OA research remains challenging. The primary goal of treatment has been pain relief to maintain or improve joint function[9] using, among others, polysulfated glycosaminoglycan, chondroitin sulfate, and intra-articular hyaluronic acid, which can reduce pain and inflammation and restore the articular environment.[2] Although these substances are employed frequently in treatment routines, they do not always have the desired effect and they do not satisfactorily control the development of the injury. NSAIDs are also used in an attempt to decrease inflammation and pain, but these drugs usually offer little benefit in the control of the disease and may have deleterious effects on joints and other body systems.[10–12]

In the absence of effective control of the degenerative process, new alternative therapies have been proposed based on the intra-articular application of different types of autologous cells obtained from different sources, whose action is the improvement of the recovery of damaged tissues. These cells contain growth factors that have the ability to proliferate and differentiate into different cell types that can modulate tissue recovery. These new therapies are known as regenerative therapy and tissue engineering.[13–15]

One type of cell therapy is autologous platelet concentrate (APC) or platelet-rich plasma (PRP). The literature[16–20] reports the benefit of its use in the repair and healing of sick or injured tissues. According to Everts et al.[21] autologous platelet concentrate is employed in different clinical situations, but scientific evidence supporting its action is lacking. The correct management technique of blood samples and the proper preparation of the APC are required to avoid inconsistent results. Factors such as blood collection, the quality of APC, the platelet count, the platelet activation, the methodology, and whether it is autologous or homologous may influence the results. Despite the lack of the standardization of the techniques employed, the literature reports promising clinical results in humans[22–24], horses[25–27], and dogs.[13,16,28,29]

Clinical studies have shown early recovery and pain relief, as observed in the evaluation of dogs after receiving treatment for a rupture of the cranial cruciate ligament[13,29] and the fragmented coronoid process.[13,28,29] Because APC stimulates the healing of tissue, it has been used to treat different joint injuries, such as osteoarthritis, osteochondrosis, hip and elbow dysplasia, chondral defects, tendinitis, bursitis, menisci injuries, muscle injuries, wounds, and

fractures, and it has been used as an adjunct in the treatment of the rupture of the cruciate ligament.[22,16,28,29,25,30,18,31,32] The results may vary depending on the severity of the case[33] and the method for obtaining the APC.

Different in vitro and in vivo studies show the potential effect of the APC when associated with cartilage-repair techniques or the conservative treatment of OA. Autologous platelet concentrate increases chondrocyte synthesis capabilities including the regulation of gene expression, proteoglycan production, and the deposition of collagen type II.[34–37] When associated with chondrocyte transplantation, it induces repair tissue proliferation similar to hyaline tissue with increased proteoglycan and the deposition of collagen type II by chondrocytes.[38,39] In experimental osteochondral defects in rabbits, Sun et al.[36] reported increased regeneration of cartilage and increased production of glycosaminoglycans in the extracellular matrix in the rabbits that received intra-articular APC. Kwon et al.[33] showed that APC intra-articular injection influenced the regeneration of cartilage in all degrees of severity of OA in rabbits' knees but that the regenerative power was higher in moderate than in mild injuries. The use of intra-articular APC represents an alternative treatment that seems effective, easy to use, and relatively inexpensive, which has aroused the interest of researchers for clinical use.[40]

2. Autologous Platelet Concentrate (APC)

APC or platelet-rich plasma (PRP) is defined as a substrate that contains a platelet concentration above basal levels. Platelets are a source of important growth factors and other molecules that affect chemotaxis, differentiation, proliferation, and cell synthesis activity, thus regulating physiological remodeling and tissue repair.[41–44] The properties of APC are based on the production and release of multiple growth factors and cell differentiation. After platelet activation occurs, these growth factors are released, including a growth factor beta transformer (TGF- β), a growth factor derived from platelets (PDGF), a fibroblast growth factor (FGF), a vascular endothelial growth factor (VEGF), a growth factor for connective tissue (CTGF), and a hepatocyte growth factor (HGF).[40,13,42] These growth factors have various functions and operate in conjunction with other types of cells and pro-inflammatory substances to regenerate tissues. Studies have shown that PDGF promotes collagen synthesis and TGF- β stimulates chondrogenesis.[46,47] Based on this assumption, the autologous platelet concentrate has been employed in different clinical situations with satisfactory results.

In dogs, the APC is prepared from the whole blood of the patient, 8.5 mL of which is collected via venipuncture and placed into tubes containing 1.5 mL of sodium citrate. It is then subjected to centrifugation.[13] There are different ways to obtain APC.[48–50] It can be prepared by automated methods, semi-automated methods, or the simplest way, that is, the tube method with single[13,29,51] or double centrifugation.[42] The most important method to prepare platelet concentrate is to ensure that in addition to concentrating a high number of platelets, it allows for obtaining live and inactivated platelets.[25,52] The basic principle of the APC action is to mimic the natural way of healing by organizing the elements that

influence healing and taking the place of injured molecules, thereby facilitating the functional recovery of tissues.[53]

3. Platelet activation

The substances most commonly used to activate platelets in APC for clinical purposes are thrombin and calcium salts.[22,54,55] In a study by Silva et al.[16, 56, 57] and Silva,[13] there was no difference between the concentrations of growth factors in APC supernatants activated with gluconate, calcium chloride, thrombin, or batroxobin, suggesting that the APC can be activated with any of these substances in dogs and cats. Considering the cost-benefit ratio, calcium gluconate is the best option. Platelet activation is performed with 10% calcium gluconate or chloride at a ratio of 1 mL of concentrate to 0.1 mL of activating substance.[16,25]

Although experimental studies have shown the positive effect of APC employment on the return of functioning after ligament injuries, traumatic injuries to the articular cartilage, and fractures, controversy remains regarding its action on articular tissues.[58,30,48] The objective of this study was to evaluate, through video-arthroscopy, the effect of APC in experimental OA in rabbits.

4. Materials and methods

The project was approved by the Ethics Committee on Animal Use (ECAU) of the Federal University of Minas Gerais under No. 63/2014. The study used 14 rabbits of the New Zealand breed. The rabbits were young adult males with a mean body weight of 3.0 kg. The inclusion criteria were an overall healthy state and no changes in the locomotor system. The animals were kept in individual 60 cm x 60 cm x 37 cm cages with access to water *ad libitum* and food twice daily, according to specific nutritional needs. The rabbits were subjected to a cranial cruciate ligament section guided by video-arthroscopy, and after 21 days, all rabbits underwent an intra-articular joint stabilization that was also guided by video-arthroscopy. Immediately after the stabilization, they were injected with APC or lactated Ringer solution in the joint. The animals were divided into two groups: the control group (I), which received 0.5 mL of lactated Ringer solution, and the treated group (II), which received 0.5 mL of APC activated with 10% calcium gluconate. The arthroscopic evaluation was performed at the time of the ligament section, 21 days and 15 days after stabilization and the intra-articular injection of lactated Ringer solution or APC. Postoperative analgesia was made with tramadol (Teuto-Cristalpharma, Brazil), at a dose of 1 mg/kg subcutaneously every 12 hours for three days, and anti-inflammatory therapy, with meloxicam (Ourofino, Brazil) at a dose of 0.2 mg/kg intramuscularly every 24 hours for three days after the section. The same treatment was made after joint stabilization at 21 days. Prophylactic therapy with cephalexin (Aspen-Pharma, Brazil) was given before joint stabilization.

During surgery, anesthesia consisted of pre-medicating the rabbits with midazolam (Cristália, Brazil) and methadone (Cristália, Brazil) at a dose of 1 mg/kg intramuscularly, 15 mg/kg

ketamine, and an anesthetic blockade of the sciatic and femoral nerves with lidocaine (Cristália, Brazil) without vasoconstrictor at a dose of 5 mg/kg, maintained with isoflurane anesthesia. The heart rate, respiratory rate, blood pressure, and blood gases were monitored. The arthroscopic procedure was carried out in accordance with Beale et al.[59] After the suprapatellar recess was punctured and synovial fluid was harvested, the joint cavity was distended with 3 mL of lactated Ringer solution. A medial parapatellar stab skin incision was made, and the joint capsule was penetrated using a number 11 scalpel blade. Then, a blunt trocar locked in the arthroscopic sleeve penetrated the joint capsule. The blunt obturator was replaced by a 1.9 mm arthroscope (Storz, Germany) following the examination of the entire joint, including the evaluation of medial and lateral compartments, the intercondylar notch, cruciate ligaments, the synovial membrane, and the suprapatellar pouch. The same procedure was performed immediately using a 2.7 mm arthroscope (Storz, Germany).

Joint stabilization was carried out as described by Schawalter & Gitterle[60] after the arthroscopic evaluation at 21 days.

5. Collecting blood samples and APC preparation

We used the single-tube method of centrifugation, in accordance with Silva.[13] We modified the centrifugation time to 7 minutes to obtain a higher concentration of platelets in the rabbits. Plasma fractions with platelet concentrations between 1.5 and 2.5 times the baseline of the whole blood were considered APC. To perform the APC, 7 mL of blood was collected from the jugular vein of the rabbits in Group II and deposited in 8.5 mL tubes that contained ACD-A as an anticoagulant solution (trisodium citrate 22 g/L; citric acid 8 g/L; and dextrose 24.5 g/L). The samples were processed immediately after harvesting. CBC was performed to assess the baseline levels of the platelets in whole blood. The blood in ACD-A tubes was centrifuged at 191 g for 7 minutes at room temperature (Centribio- 80-2B, China). Using catheter number 22 and a 3 mL syringe, the first approximately 100 µL of the red fraction below the blood-plasma interface and the first 900 µL of plasma above the same interface were collected. The autologous preparations obtained were analyzed by automated blood count volumetric impedance. Each sample was analyzed three times, and the average was taken as a measurement sample. Additionally, 2 mL of whole blood in EDTA tubes was collected for CBC and biochemistry. In the prepared platelet and whole blood, the number of platelets; the hematocrit concentration; white blood cells; the absolute and relative values of lymphocytes, monocytes, granulocytes; the mean platelet volume; and the platelet distribution index were assessed. Just before the APC injection, it was activated with 10% calcium gluconate at a ratio of 0.1 mL to 1.0 mL of APC.

6. Results and discussion

Among the joint injuries observed in our clinical routine, the rupture of the cranial cruciate ligament is the most common, followed by elbow and hip dysplasia. The inevitable conse-

quence of these changes is that OA, as reported in the literature,[2,11,12] is commonly treated continuously with so-called chondroprotective agents and analgesics. The emotional effect on the owner is considerable, and the financial costs are significant. Considering the actions of growth factors on tissues,[41,45,46,42,43] the purpose of using the APC is to promote joint recovery, heal tissues, and facilitate a painless functional recovery. Positive outcomes of APC use could be a sharp reduction in, or even the elimination of, the use of anti-inflammatory drugs, which have serious side effects. However, standardized studies on its action on tissues and the evolution of treatment are lacking. One of the great difficulties in the treatment of OA is the sequenced monitoring of their effects.

Although many studies on the degenerative process have been conducted, little is known about the molecular mechanisms that can be affected and modified by some type of therapy. Adding to this, the difficulty is the need for an early diagnosis and the evaluation of treatment.[61]

The changes associated with the degenerative process have a strong effect on patients by reducing their ability to use their joints due to pain. Unfortunately, when these changes are severe enough to be recognized clinically, they are irreversible with the treatments available today.

Joint changes can be monitored with minimally invasive surgery via arthroscopy.[62,63] Arthroscopy allows for a detailed evaluation of joint structures, for the identification of morphological changes, and, as a minimally invasive technique, for serial interventions.[64,65] It is therefore a way to track in vivo evolution of articular processes and their treatment. The limitations in second arthroscopic evaluation in clinical practice and the diversity of clinical situations[13,16,28,29] indicate the need for research that continuously assesses the process and treatment, as was performed in the first stage of this study. One of the difficulties encountered in this experimental model was the minimum quantity of synovial fluid in healthy joints, that is, 0.1 to 0.2 mL, which prevented the evaluation of the parameters. However, in the 21-day allotted time to start the evaluation of the degenerative process, joint effusion was observed in all animals with an average harvest of 0.55 mL. In the group treated with APC, effusion was reduced at 15 days after the intra-articular injection of APC, with an average harvest of 0.35 mL. In the control group, despite the joint stabilization, outpouring continued, with an average harvest of 0.62 mL.

Protein levels also showed a decrease after the intra-articular injection of APC. After 21 days, the average levels of protein were 3.7 g/dL (normal <2.5), and at 15 days after treatment, an average of 3.0 g/dL was observed. In the same observation period, the protein levels in the synovial fluid of the control group were 3.9 g/dL on average.

The protocol that was proposed by Silva[13] and modified in this research (1 minute was added in the centrifugation time) was effective in concentrating the platelets of rabbits. The concentration of platelets in the APC ranged from 1.5 to 2.5 times the baseline levels in whole blood with an average of 1.8 times (Tab.1).

However, the concentration proposed in the literature, that is, three to five times, was not reached.[66–68] A second spin could possibly elevate this concentration to the levels proposed

in the literature, but the purpose of this study was to evaluate the action of this concentrate obtained simply and economically through monitoring by video-arthroscopy.

Baseline means values in total blood								
	WBC	RBC	HGB	PLT	MPV	%LYM	%MO	%GR
Average	6,16	5,28	9,48	169,85	5,85	43,97	5,94	50,1
Baseline means values in APC								
	WBC	RBC	HGB	PLT	MPV	%LYM	%MO	%GR
Average	0,39	0,03	0,11	312,85	5,88	***	***	***

WBC: leukocytes; RBC: erythrocytes; HGB: hemoglobin; PLT: platelets; MPV: mean platelet volume; LYM: lymphocytes; MO: monocytes; GR: granulocytes; ***= Value not detected by the device.

Table 1. Baseline total cell count in blood and APC in rabbits with femorotibiopatellar OA induced at 21 days after the rupture of CCLr

The role of leukocytes in APC is also a subject that requires further research, but their presence in a low concentration is considered favorable.[25] Clinical outcomes at 15 days after injection of the APC were also favorable in the experimental model, confirming owners’ reports of clinical improvement in dogs after the first application of the APC. It is necessary, however, to conduct an assessment to track their in vivo effect, with the least possible morbidity.

Arthroscopy is a diagnostic tool that allows for tracking the evolution of an articular injury and the effect of treatment, but its clinical use for this purpose has limited application, leading to evaluation in an experimental model. The arthroscopic evaluation was initiated with a 1.9 mm arthroscope, but the 2.7 arthroscope enables a more detailed visualization of structures. Manipulation, however, was harder because of the instrument's size in relation to the rabbit’s joints.

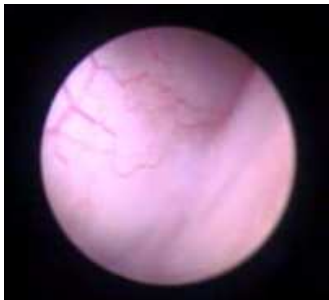The arthroscopic evaluation showed different aspects between the groups, with a reduction of synovitis, a smooth synovial capsule, a lower degree of bleeding, less hypertrophy in the villi, smooth cartilage, and less evidence of fibrillation in the treated group than in the control group (Figs. 1, 2, 3, 4).

The results of the clinical evaluation showed that joint manipulation was painless during ambulation in the treated group. The arthroscopic evaluation showed the explanation for this result. A clinical response was observed in our routine in different situations, such as the relief of pain and the early recovery of limb function after rupture, CCLr treatment and functional limb return in cases of hip dysplasia, and joint pain of an unknown cause. Favorable results were also obtained in five cases of severe hip dysplasia, in which one joint was treated by triple pelvic osteotomy, and the other was subjected to treatment with three injections of APC at intervals of 15 days. The dogs recovered functional activity of the nonoperated limb, and it lasted one year. The owners reported improvement after the first injection.

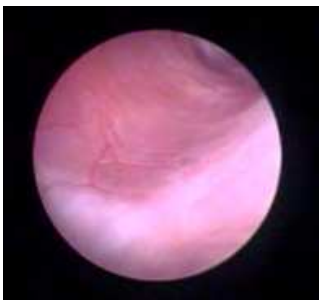
It is important to consider how to obtain the APC and make sure that the concentrate has the required amount of platelets and that it is viable. The method used was the same standard as used in previous studies.[13,29]

The early diagnosis of joint injury is undoubtedly an important factor in controlling subsequent degenerative lesions, but this is not the clinical reality. Therefore, other forms of controlling or even inhibiting the degenerative process should be investigated. The monitoring of disease progression and the response to treatment requires knowledge about the disease to guide the conduct of treatment with more effective results.

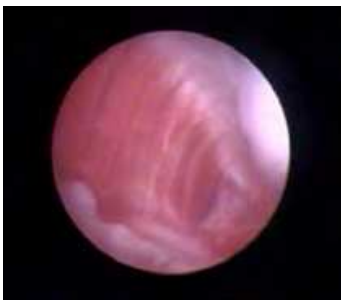Other studies on the use of autologous APC, APC banks, the influence of platelets concentration in the resolution of lesions, the range of applications, the need for repetition in the protocol, and APC's effect on fracture healing are future prospects of this research group.



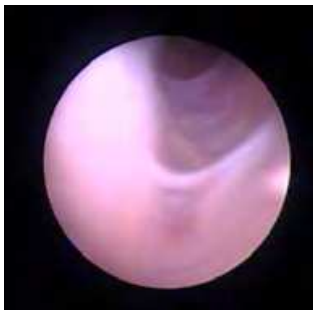a



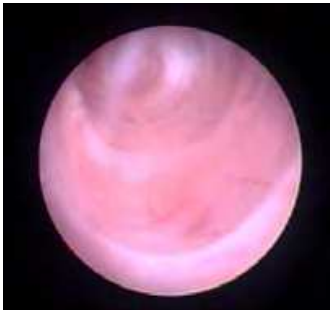b



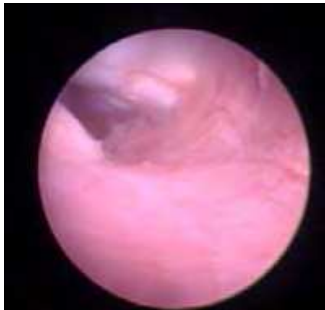
c



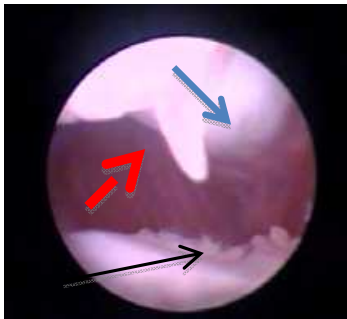
d



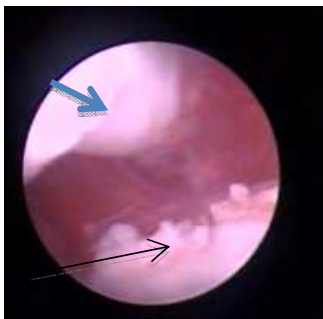
e



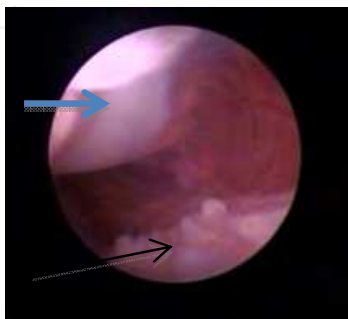f



g



h



i

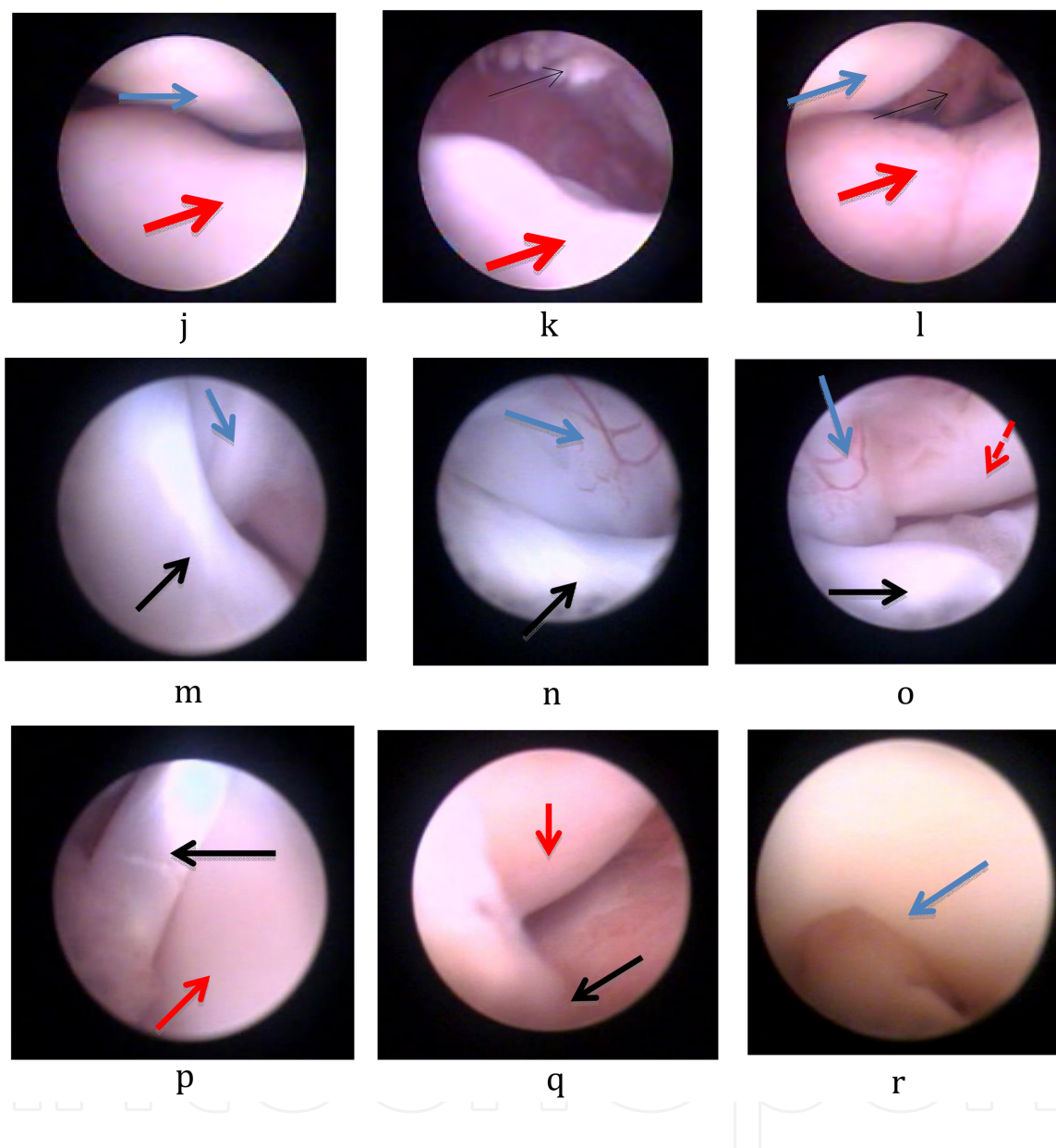
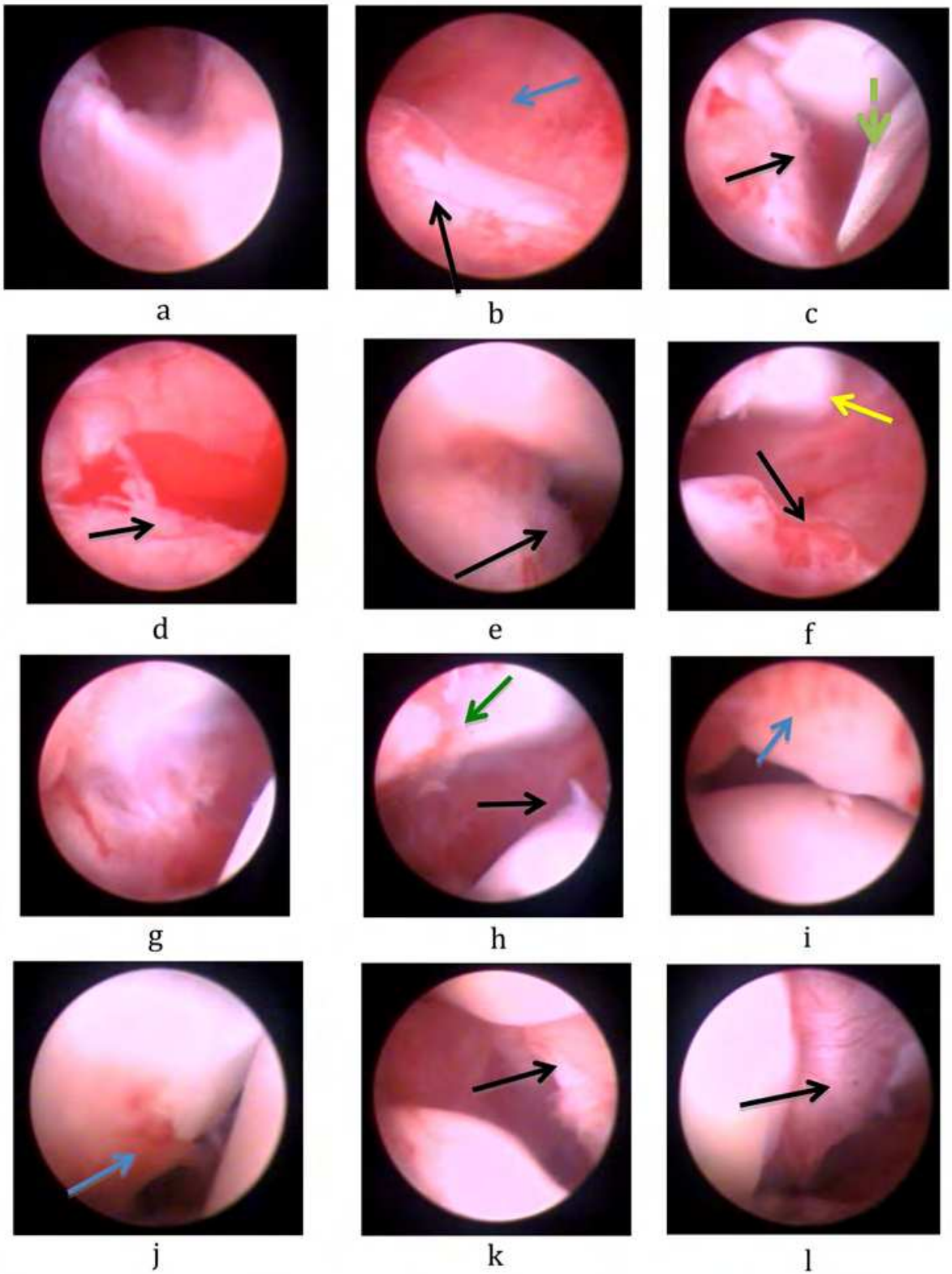


Figure 1. Arthroscopic aspects of the femorotibiopatellar joint of rabbits just before CCLr. a, b, c - the lateral compartment: smooth lateral synovial membrane, pink, with a slight vascularization and an absence of villi; d, e, f - medial compartment: smooth medial synovial membrane, pink, with slight vascularization and absence of villi; g, h, i - suprapatellar pouch: insertion of the patellar tendon (blue arrows), villus in the insertion of the patellar tendon (red arrow), presence of tissue in suprapatellar pouch (long arrow); j, k, l - patellofemoral joint: patella (blue arrow), trochlear surface (red arrow), villi in the insertion of the patellar tendon (thin black arrow); m, n, o - cranial cruciate ligament (black arrow), bright, without vascularization; m, n, o - cruciate caudal ligament (blue arrows) bright (m), with discrete vascularization (n, o), medial condyle (red dotted arrow); p - long extensor digital tendon (black arrow); lateral femoral condyle (red arrow); q - long extensor digital tendon - tibial insertion (black arrow); r - intercondylar notch, smooth and open (blue arrow).



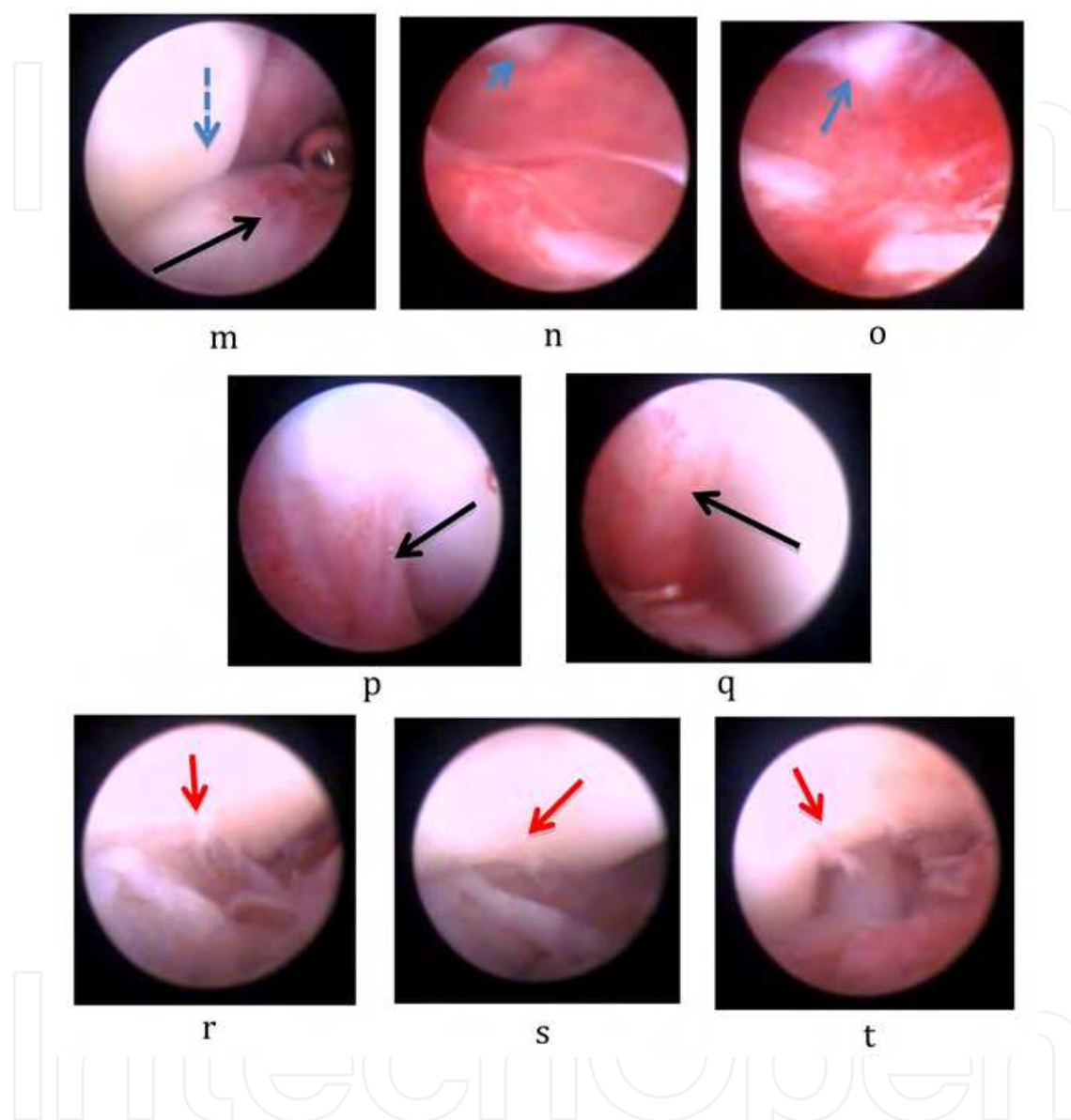
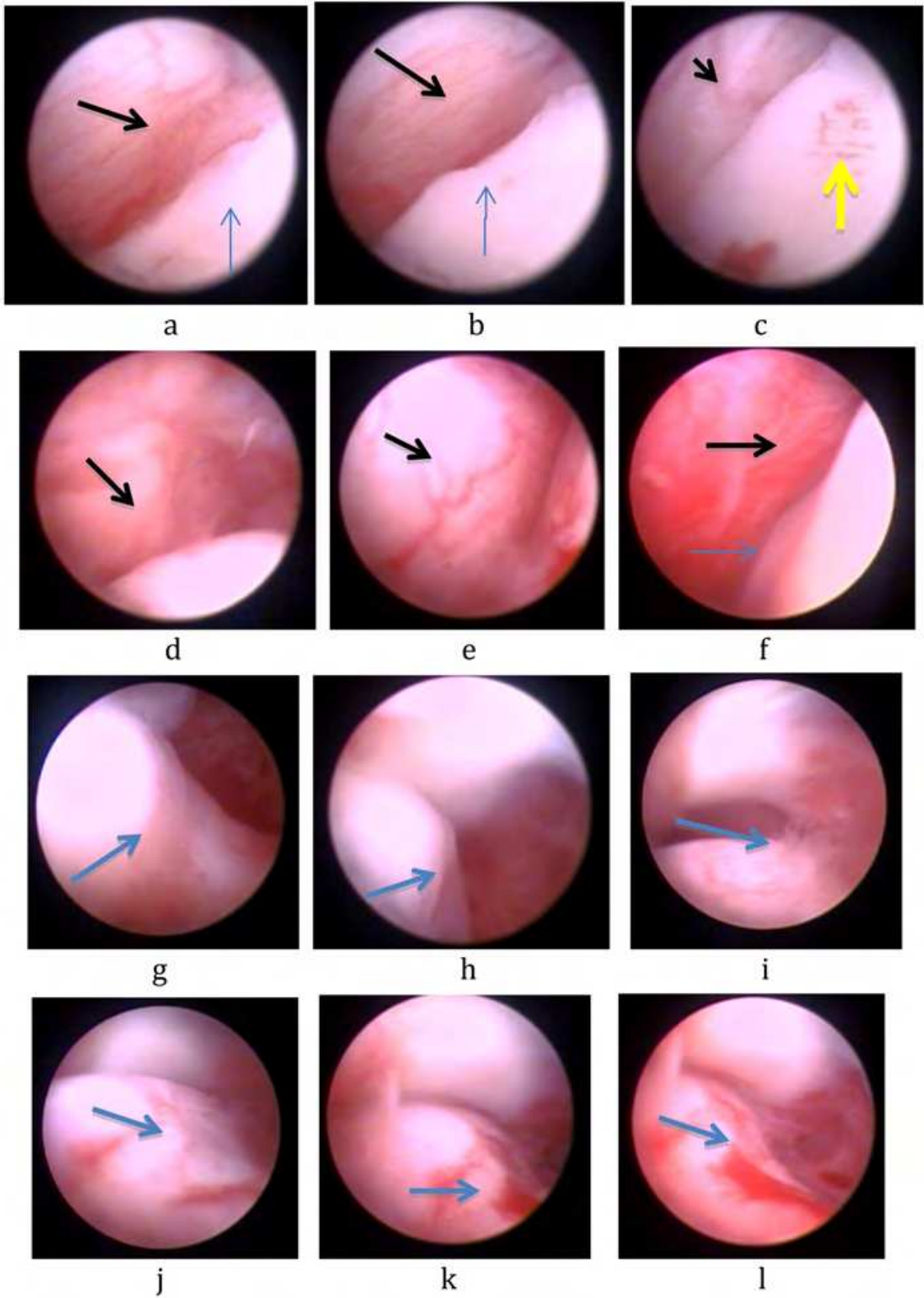
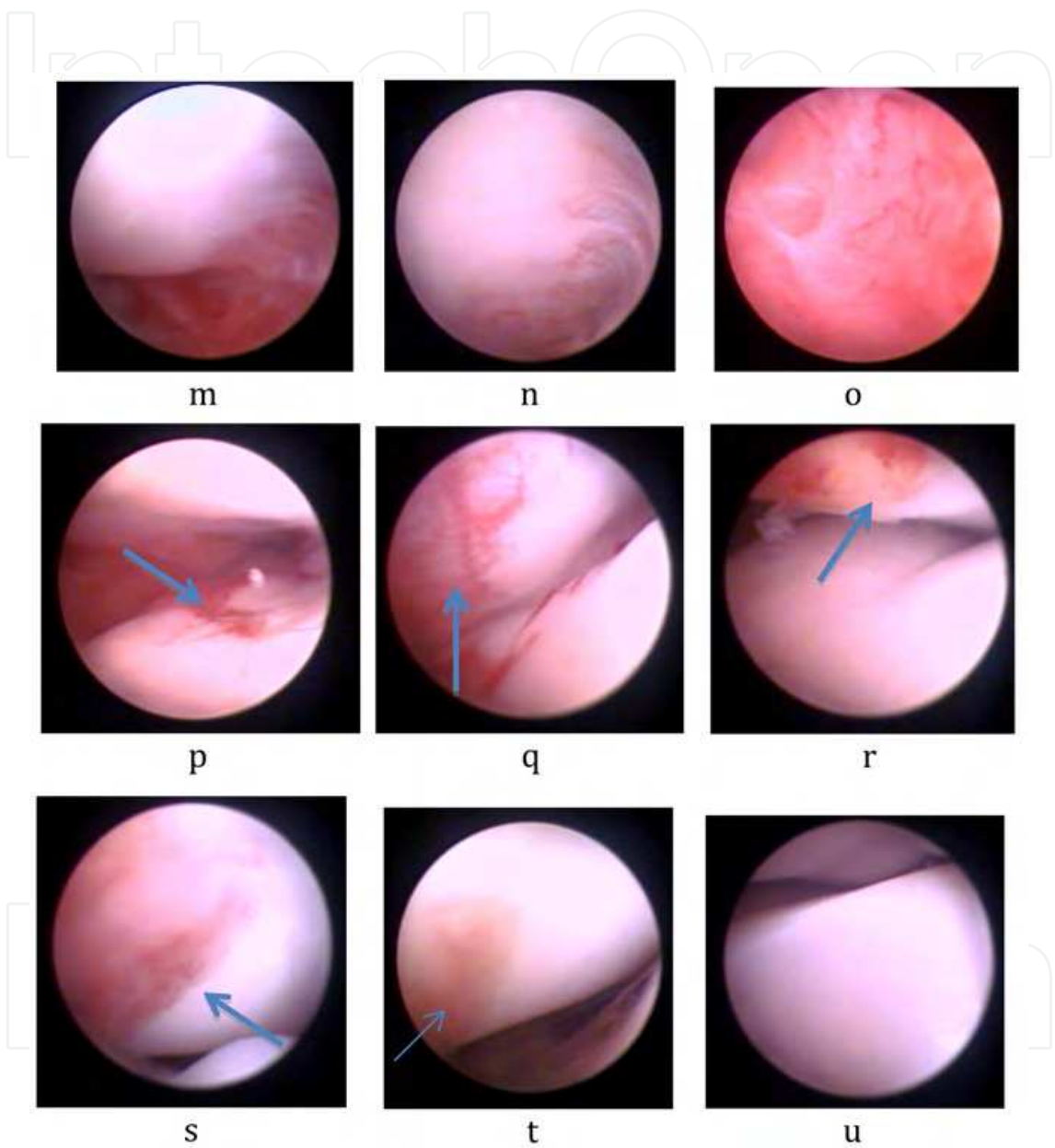


Figure 2. Arthroscopic aspects of the femorotibiopatellar joint of rabbits 21 days after the rupture of the cranial cruciate ligament. a, b, c - medial compartment: a - synovium, b- synovial membrane hyperemia (blue arrow), insertion of articular capsule - tissue formation (black arrow), c - villi, needle for drainage (dotted green arrow); d - suprapatellar pouch, clot presence, villus (black arrow); e - proximal medial condyle - villi and vascularization (black arrow); f - surface erosion of the proximal medial condyle (black arrow), insertion of the patellar tendon (yellow arrow); g - lateral compartment: hyperemic synovial membrane; h - proximal lateral condyle - tissue formation (black arrow), neovascularization in the patellar tendon insertion (green arrow); i, j - neovascularization in the patella (blue arrow); k, l - villi in the patellar insertion of the patellar tendon (black arrows); m - proximal medial condyle - vascularization (black arrow), patella (blue dotted arrow); n, o - suprapatellar pouch - neovascularization, patella (blue arrows); p, q - insertion of the long extensor digital tendon - neovascularization (black arrows); r, s, t - irregular intercondylar notch, fibrillation (red arrows).





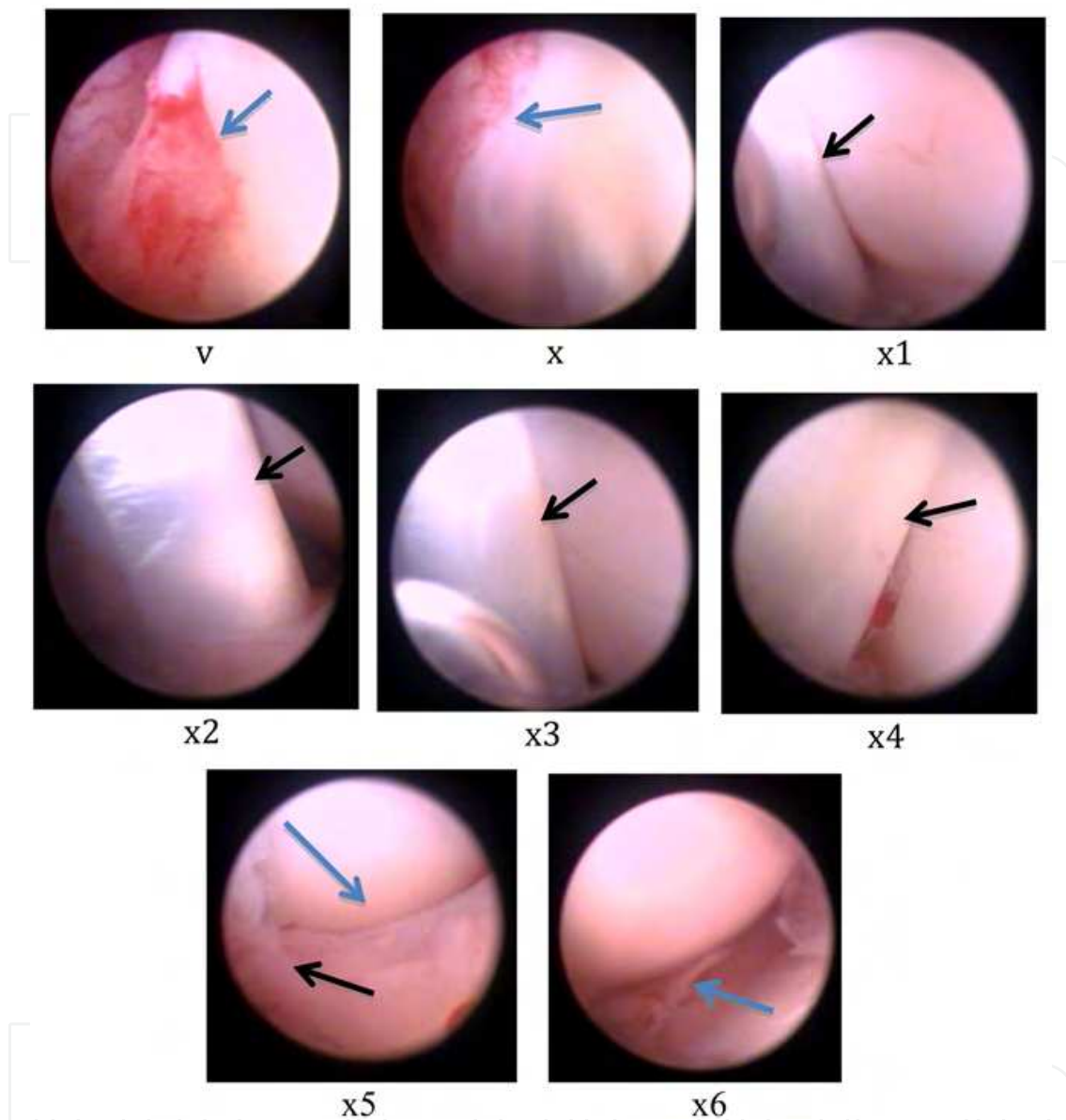
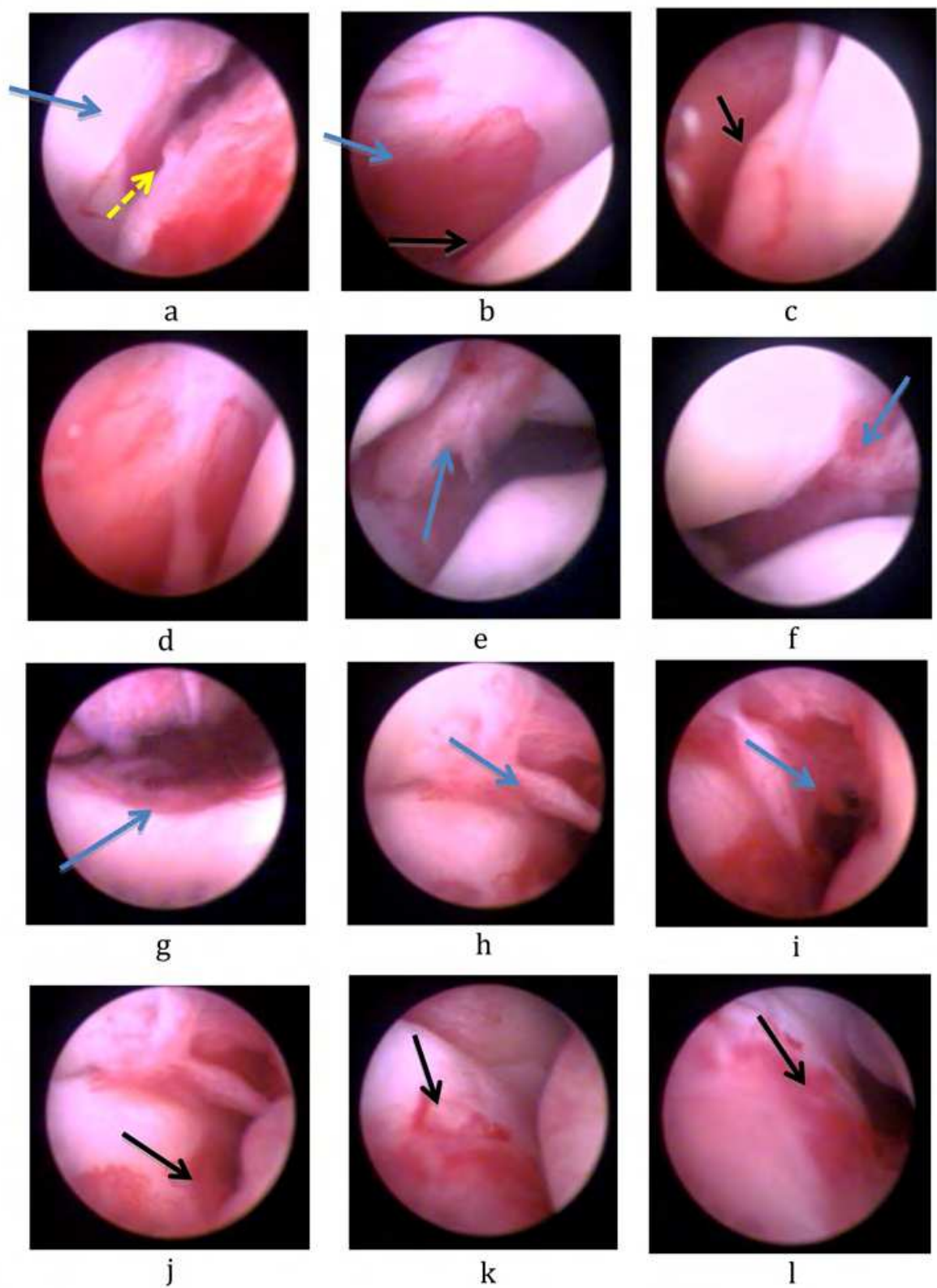


Figure 3. Arthroscopic aspects of femorotibiopatellar joint of rabbits 15 days after joint injection of autologous platelet concentrate. a, b, c, d, e, f - lateral compartment: synovial membrane (black arrows), lateral condyle, slight increase in the capsule insertion (blue arrows), neovascularization in the condyle (yellow arrow); d, e, f - lateral synovium (black arrows), lateral condyle, slight increase in the insertion of the capsule (blue arrow); g, h, i - medial compartment: g - slight irregularity in the medial condylar edge, h - capsule insertion (blue arrow), i - fibrillation in the proximal medial condyle; j, k, l - different aspects of the insertion of the capsule, fibrillation (blue arrow); m, n, o - different aspects of the medial synovial membrane; p - suprapatellar pouch; q, r, s, t - patellar neovascularization - different aspects; u - patellofemoral joint - smooth cartilage without change; v, x - neovascularization in the insertion of the long extensor digital tendon (blue arrow); x1, x2, x3 - long extensor digital tendon, middle-proximal third, bright (black arrows); x4 - long extensor digital tendon opaque (black arrow); x5 - smooth medial condyle (blue arrow), tissue formation, intercondylar notch (black arrow); x6 - partial projection of the medial horn meniscus (blue arrow).



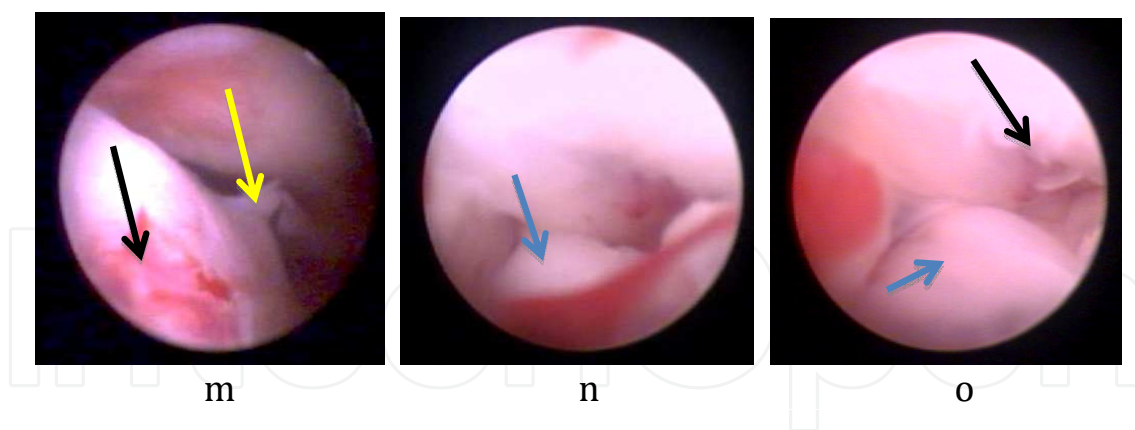


Figure 4. Arthroscopic aspects of femorotibiopatellar joint of rabbits 15 days after articular injection of lactated Ringer solution (control). a, b, c, d - lateral compartment: synovial membrane (blue arrows), lateral condyle - capsule insertion (yellow arrow), neovascularization, tissue formation; b - lateral femoral condyle, capsule insertion; c - osteophytes (black arrow); d - hyperemia of the synovial membrane; e, f - villi in the insertion of the patellar tendon (blue arrows); g - suprapatellar pouch - hyperemia (blue arrow); h, i, j, k, l, m - medial compartment: h, i - villi in the insertion of the patellar tendon (blue arrows); j, k, l, m - neovascularization in the capsule insertion (black arrows), tissue formation at the edge of the medial condyle (yellow arrow); n, o - intercondylar notch: fascia lata autograft (blue arrows), fibrillation in the intercondylar notch (black arrow).

Acknowledgements

This work was supported by CNPQ (Brazilian Council of Research and Development) and FAPEMIG (Foundation support to the Minas Gerais Research).

Author details

Cleuza Maria de Faria Rezende*, Fabíola Paes Leme, Gilcinea Santana, Esteban Osório Carmona and Jessica Alejandra Castro Varón

*Address all correspondence to: cleuzaufmg@gmail.com

Department of Veterinary Medicine and Surgery, Veterinary School, Universidade Federal de Minas Gerais, Belo Horizonte, Minas Gerais, Brazil

References

- [1] Doom, M.; De Bruin, T.; De Rooster, H. et al. Immunopathological mechanisms in dogs with rupture of the cranial cruciate ligament. *Vet. Immunol. Immunopathol.* 2008; 125: 143-161. DOI: 10.1016/j.vetimm.2008.05.023

- [2] Canapp Jr., S.O. The canine stifle. *Clin. Tech. Small Anim. Pract.* 2007; 22: 195-205. DOI: 10.1053/s.ctsap.2007.09.008
- [3] Johnson, J.A.; Austin, C.; Breur G.J. Incidence of canine appendicular musculoskeletal disorders in 16 veterinary teaching hospitals from 1980 through 1989. *Vet. Comp. Orthop. Traumatol.* 1994; 7: 56-59. DOI: 10.1111/j.1532-950X.2006.00226.x
- [4] Rayward, R.M.; Thomson, D.G.; Davies, J.V. et al. Progression of osteoarthritis following TPLO surgery: a prospective radiographic study of 40 dogs. *J. Small Anim. Pract.* 2004; v. 45: 92-97. DOI: 10.1111/j.1748-5827.2004.tb00208.x
- [5] Innes, J.F.; Bacon, D.; Lynch, C. et al. Long-term outcome of surgery for dogs with cranial cruciate ligament deficiency. *Vet. Rec.* 2000; 147: 325-328. DOI: 10.1136/vr.147.12.325.
- [6] Johnston, S.A. Osteoarthritis: joint anatomy, physiology, and pathobiology. *Vet. Clin. N. Am. Small Anim. Pract.* 1997; 27: 699-723. DOI: 10.1016/j.cvsm.2015.06.
- [7] Pond, M.J.; Nuki, G. Experimentally-induced osteoarthritis in the dog. *Ann. Rheum. Dis.* 1973; 387-388. DOI:10.1136/annrheumdis-2015-208300
- [8] Fernandes, J.C.; Martel-Pelletier, J.; Pelletier, J.P. The role of cytokines in osteoarthritis pathophysiology. *Biorheology.* 2002. 30:237-246. DOI: 10.5435/JAAOS-22-01-29
- [9] Rezende, U.M.; Gobbi, R.G. Tratamento medicamentoso da osteoartrose do joelho: drogas modificadoras da doença. *Rev. Bras. Ortop.* 2009; 44: 14-19. ISSN 0102-3616... <http://dx.doi.org/10.1016/j.rbo.2012.08.006>
- [10] Filho, M.M.; Rahal, S.C. O uso de anti-inflamatórios inibidores cox-2 seletivos na osteoartrite canina. *Veterinária e Zootecnia.* 2008; 15: 407-415. ISSN 0102-5716
- [11] Clark, T.P. The clinical pharmacology of ciclooxigenase-2-selective and dual inhibitors. *Vet. Clin. N. Am. Small Anim. Pract.* 2006; 36: 1061-1085. DOI: doi.org/10.1016/j.cvsm.2006.07.001
- [12] Lees, P.; Landoni, M.F.; Giraudel, J. et al. Pharmacodynamics and pharmacokinetics of nonsteroidal anti-inflammatory drugs in species of veterinary interest. *J. Vet. Pharmacol. Ther.* 2004; 27: 479-490. DOI: 10.1111/jvp.12196. ISSN 0140-7783
- [13] Silva, R.F. Caracterizações celular e ultra-estrutural do concentrado de plaquetas em cães e gatos e avaliação do seu efeito na osteoartrose em cães. 2012. 88f. Tese (Doutorado em ciência animal). Escola de Veterinária, Universidade Federal de Minas Gerais, Minas Gerais, 2012
- [14] Huang, T.F.; Chen, Y.T.; Yang, T.H. et al. Isolation and characterization of mesenchymal stromal cells from human anterior cruciate ligament. *Cytotherapy.* 2008; 10: 806-814. DOI: <http://dx.doi.org/10.1080/14653240802474323>

- [15] Petrigliano, F.P.; McAllister, D.R.; Wu, B.M. Tissue engineering for anterior cruciate ligament reconstruction: a review of current strategies. *J. Arthrosc. Relat. Surg.* 2006; 22: 441-451. ISSN 1526-3231
- [16] Silva, R.F.; Rezende, C.M.F.; Carmona, J.U. Use of intra-articular autologous concentrates as coadjuvants in the surgical arthroscopy treatment of elbow dysplasia in a bitch. *Arch. Med. Vet.* 2013; 45: 213-217. DOI: ISSN 0301-732X/ISSN 0717-6201
- [17] Stief, M.; Gottschalk, J.; Ionita, J.C.; Eispánier, A.; Oechtering, G.; Bötcher, P. Concentration of platelets and growth factors in canine autologous conditioned plasma. *Vet. Comp. Orthop. Traumatol.* 2011; 24:122-125. DOI: 10.3415/VCOT-14-12-0182
- [18] Neumann, S.; Viefhues, G. Intraartikuläre Injection von autologem Thrombozytenkonzentrat bei der OCD. *Veterinär Spiegel.* 2010; 1: 22-26. DOI: 10.1055/s-004-28203
- [19] Argüelles, D.; Carmona, J. U.; Climent F.; Munoz, E.; Prades, M. Autologous platelet concentrates as a treatment for musculoskeletal lesions in five horses. *Vet. Rec.* 2008; 81: 208-211. DOI: 10.1136/vr.h347
- [20] Anitua, E.; Sanchez, M.; Nurden, A.T. et al. Platelet-released growth factors enhance the secretion of hyaluronic acid and induce hepatocyte growth factor production by synovial fibroblasts from arthritic patients. *Rheumatology.* 2007; 46: 1769-1772. DOI: 10.1093/rheumatology/keu484
- [21] Everts, P.A.M.; Knape, J.T.A.; Weibrich, G.; Schönberger, J.P.A.M.; Hoffmann, J.; Overdevest, E.P.; Henk, A.M.; Van Zundert, A. Platelet-rich plasma and plasma gel: a review. *J. Am. Soc. Extracorp. Technol.* 2006; 38: 174-187. DOI: 10.3732/ajb.0900091
- [22] Sánchez, M.; Delgado, D.; Sánchez, P.; Fiz, N.; Azofra, R.; Orive, G.; Anitua, E.; Padilla, S. Platelet rich plasma and knee surgery. *BioMed Res. Int.* 2014. Article ID 890630, 10 pages. DOI: 10.1155/2014/890630
- [23] Rodriguez, J.; Palomar, M.A.; Torres, J. Plasma rico en plaquetas: fundamentos biológicos y aplicaciones en cirugía maxilofacial y estética facial. *Rev. Esp. Cir. Oral Maxilofac.* 2012; 34: 8-17. DOI: 10.1016/j.maxilo.2011.10.007
- [24] Oates, T.W.; Rouse, C.A.; Cochram, D.L. Mitogenic effects of growth factors on human periodontal ligament cells in vitro. *J. Periodontal.* 1993; 64: 142-148. DOI: 10.1111/jre.12257
- [25] Carmona, J.U.; López, C. Autologous platelet concentrates as a treatment for shoulder injury in a horse. *J. Equine Vet. Sci.* 2011; 31: 506-510. DOI: 10.1016/j.physletb.2010.09.059
- [26] Carmona, J.U.; Argüelles, D.; Climent, F.; Prades M. Autologous platelet concentrates as a treatment of horses with osteoarthritis: a preliminary pilot clinical study. *J. Equine Vet. Sci.* 2007; 27: 167-170. DOI: 10.1016/j.physletb.2010.09.059
- [27] Carmona, J.U. Use of autologous platelet concentrates for the treatment of musculoskeletal injuries in the horse: preliminary clinical studies and cellular and molecular

evaluation of equine platelet concentrates obtained by single and double centrifugation tube methods. 2006. 100 f. Dissertação (Doutorado em Veterinária) Faculty of Veterinary medicine, Universitat Autònoma de Barcelona, Barcelona, 2006

- [28] Silva, R.F.; Carmona, J.U., Rezende, C.M.F. Uso de plasma rico em plaquetas intra-articular como tratamento pós-cirúrgico da ruptura do ligamento cruzado cranial num cão. *Arq. Bras. Med. Vet. Zootec.* 2012; 64: 847-852. DOI: 10.1590/s0102-09352012000200030
- [29] Silva, R.F.; Rezende, C.M.F.; Carmona J.U. Uso de concentrados autólogos de plaquetas intrarticulares como coadyuvantes en el tratamiento quirúrgico de la rotura del ligamento cruzado anterior en una perra. *Arch. Med. Vet.* 2011; 43: 313-316. ISSN 0301-732X/ISSN 0717-6201
- [30] Milano, G.; Sanna Passino, E.; Deriu, L. et al. The effect of platelet rich plasma combined with microfractures on the treatment of chondral defects: na experimental study in a sheep model. *Osteoarthr. Cartil.* 2010; 18: 971-980. DOI: 10.1016/j.joca.2010.03.013
- [31] Murray, M.M.; Splinder, K.P.; Devin, C. et al. Use of collagen-platelet rich- plasma scaffold to stimulate healing of central defect in the canine ACL. *J. Orthop. Res.* 2006; 24: 820-830. DOI: 10.1002/(ISSN)1554-527X
- [32] Zachos, T.A.; Bertone, A.L. Growth factors and their potential therapeutic applications for healing of musculoskeletal and other connective tissues. *Am. J. Vet. Res.* 2005; 66: 727-728. DOI: 10.1186/1297-9716-44-24
- [33] Kwon, D.R.; Park, G.Y.; Lee, S.U. The effects of intra-articular platelet-rich plasma injection according to the severity of collagenase-induced knee osteoarthritis in a rabbit model. *Ann. Rehabil. Med.* 2012; 36: 458-465. DOI: 10.5535/arm.2012.36.4.458
- [34] Park, S.I.; Lee, H.R.; Kim, S. et al. Time sequential modulation in expression of growth factors from platelet rich plasma (PRP) on the chondrocyte cultures. *Mol. Cell Biochem.* 2012; 361: 9-17. DOI: 10.1007/s11010-011-1081-1
- [35] Saito, M.; Takahashi, K.; Aray, Y. et al. Intraarticular administration of platelet-rich plasma biodegradable gelatin hydrogel microspheres prevents osteoarthritis progression in the rabbit knee. *Clin. Exp. Rheumatol.* 2009; 27: 201-207. ISSN 0770-3198 (Print) 1434-9949 (Online)
- [36] Sun, Y.; Feng, Y.; Zhang, C.Q. et al. The regenerative effect of platelet-rich plasma on healing in large osteochondral defects. *Int. Orthop.* 2010; 34: 589-597. DOI: 10.1007/s00264-009-0793-2
- [37] Akeda, K.; An, H.; Okuma, M. et al. Platelet-rich plasma stimulates porcine articular chondrocyte proliferation and matrix biosynthesis. *Osteoarthr. Cartil.* 2006; 14: 1272-1280. DOI: 10.1016/j.joca.2006.05.008

- [38] Filgueiras, R.R.; Del Carlo, R.J.; Alves, N.P. et al. Platelet rich plasma associated with heterologous fresh and thawed chondrocytes on osteochondral lesions of rabbits. *Arq. Bras. Med. Vet. Zootec.* 2014; 66: 177-184. ISSN 0103-0935
- [39] Smyth, N.A.; Murawski, C.D.; Fortier, L.A. et al. Platelet-rich plasma in the pathologic process of cartilage: review of basic science evidence. *Arthroscopy.* 2013; 29: 1399-1409. DOI: 10.1016/j.arthro.2013.03.004
- [40] Civinini, R.; Nistri, L.; Martini, C.; Redl, B.; Ristori, G.; Innocenti M. Growth factors in the treatment of early osteoarthritis. *Clin. Case Miner. Bone Metab.* 2013; 10: 26-29. DOI: 1138/ccmbm/2014.11.3.165
- [41] Chung, R.; Foster, B.K.; Xian, C.J. Preclinical studies on mesenchymal stem cell-based therapy for growth plate cartilage injury repair. *Stem Cells Int.* 2011; 2011: 570125. DOI: 10.4061/2011/570125
- [42] Argüelles, D.; Carmona, J.U.; Pastor, J.; Iborra, A.; Viñals, L.; Martínez P.; Bach, E.; Prades, M. Evaluation of single and double centrifugation tube methods for concentrating equine platelets. *Res. Vet. Sci.* 2006; 81: 237-245. DOI: 10.1016/j.physletb.2010.09.059
- [43] Anitua, E.; Andia, I.; Ardanza, B. et al. Autologous platelets as a source of proteins for healing and tissue regeneration. *Thromb. Haemost.* 2004; 91: 4-15. DOI: 10.1111/jth.12857
- [44] Carmona, J.U.; Argüelles, D.; Prades, M. Transforming growth factor beta-3 and nitric oxide levels in four autologous platelet concentrates and plasma derived from equine blood. *Arch. Med. Vet.* 2008; 40: 155-160. ISSN 0301-732X/ISSN 0717-6201
- [45] Fortier, L.; Barker, J.; Strauss, E.; MacCarrel, T.; Cole, B. The role of growth factors in cartilage repair. *Clin. Orthop. Relat.* 2011; 469: 2706-2715. DOI: 10.1016/j.actbio.2015.01.010
- [46] Fan, J.; Gong, I.; Ren, L. et al. In vitro engineered cartilage using synovium derived mesenchymal stem cells with injectable gellan hydrogels. *Acta Biomater.* 2010; 6: 1178-1185. DOI: 10.1016/j.actbio.2009.08.042
- [47] Kurth, T.; Hedbom, E.; Shintani, N. et al. Chondrogenic potential of human synovial mesenchymal stem cells in alginate. *Osteoarthr. Cartil.* 2007; 15: 1178-1189. DOI: <http://dx.doi.org/10.1016/j.joca.2007.03.015>
- [48] Weibrich, G.; Kleis, W.K.; Hitzler, W.E.; Hafner, G. Comparison of the platelet concentrate collection system with the plasma-rich in growth factors kit to produce platelet rich-plasma: a technical report. *Int. J. Oral Maxillofac. Implants.* 2005; 29: 118-123. DOI: 10.11607/jomi.2015.1
- [49] Sutter, W.W.; Kaneps, A.J.; Bertone, A.L. et al. Comparison of hematologic values and transforming growth factor- β and insulin-like growth factor concentration in

- platelet concentrates obtained by use of buffy coat and apheresis methods from equine blood. *Am. J. Vet. Res.* 2004; 65: 924-930. DOI: 10.1111/j.1939-1676.2009.0335.x
- [50] Carter, C.A.; Jolly, D.J.; Worden, C.E. et al. Platelet rich-plasma gel promotes differentiation and regeneration during equine wound healing. *Exp. Mol. Pathol.* 2003; 74: 244-255. DOI: 10.1006/exmp.2001.2380
- [51] Silva, R.F.; Rezende, C.M.F.; Paes-Leme, F.O.; Carmona, J.U. Evaluación del método del tubo para concentrar plaquetas caninas: estudo celular. *Arch. Med. Vet.* 2011; 43: 95-98. ISSN 0301-732X/ISSN 0717-6201
- [52] Marx, R.E. Platelet-rich plasma: evidence to support its usage. *J. Oral Maxillofac. Surg.* 2004; 62: 489-496. DOI: 10.1016/j.joms.2014.08.011
- [53] Anitua, S.; Prado, R.; Sanchez, M. et al. Platelet-rich plasma: preparation and formulation. *Oper. Tech. Orthop.* 2012; 22: 25-32. DOI: 10.1053/j.oto.2012.01.004
- [54] Mazzuco, L.; Balbo, V.; Cattana, E.; Borzini, P. Platelet-rich plasma and platelet gel preparation using platelex. *Vox Sang.* 2008; 94: 202-208. DOI: 0.1111/vox.12093
- [55] Roberts, D.E.; Archibald, M.N.; Ratna, B. Mechanism of collagen activation in human platelets. *J. Biol. Chem.* 2004; 279: 19421-19430. DOI: 0.1074/jbc.P114.609743
- [56] Silva, R.F.; Carmona, J. U.; Rezende, C.M.F. Comparison of the effect of calcium gluconate and batroxobin on the release of transforming growth factor beta1 in canine platelet concentrates. *BMC Vet. Res.* 2012; 8: 121-128. DOI: 10.1186/1746-6148-8-212
- [57] Silva, R.F.; Álvarez, M.E.; Rios, D.L.; López, C.; Carmona, J.U.; Rezende, C.M.F. Evaluation of the effect of calcium gluconate and bovine thrombin on the temporal release of transforming growth factor beta 1 and platelet-derived growth factor isoform BB from feline platelet concentrates. *BMC Vet. Res.* 2012; 8: 212. DOI: 10.1186/1746-6148-8-212
- [58] Patel, S.; Dhillon, M.S.; Aggarwal, S. et al. Treatment with platelet-rich plasma is more effective than placebo for knee osteoarthritis : a prospective, double-blind, randomized trial. *Am. J. Sports Med.* 2013; 41: 356-364. DOI: 10.1177/0363546514537991
- [59] Beale, S.B.; Hulse, A.D.; Schultz, K.S. et al. *Small animal arthroscopy*. Philadelphia: Saunders; 2003. pp. 117-157. ISBN 0-7216-8969-8
- [60] Schawalder, P.; Gitterle, E. Eigene methoden zur operativen rekonstruktion bei rupturen des vorderen und hinteren kreuzbandes. *Kleintierpraxis.* 1989; 7: 323-330. ISSN 0023-2076
- [61] Zhai, G.; Eshghi, E.A. Biomarkers for osteoarthritis: investigation, identification and prognosis. *Curr Biomark. Find.* 2012; 2: 19-28. DOI: 10.2147/CBF.S27901
- [62] Borges, N.F.; Rezende, C.M.F.; Melo, E.G.; Malm, C.; Gheller V.A.; Doretto, J.V. Video-artroscopia da articulação fêmoro-tíbio-patelar em cães após secção do ligamento

- cruzado cranial guiada por artroscopia. *Arq. Bras. Med. Vet. Zootec.* 2008; 60: 1035-1044. DOI: 10.1590/S0102-09352013000300013
- [63] Rezende, C.M.F.; Melo, E.G.; Malm, C.; Gheller, V.A. Tratamento artroscópico da fragmentação do processo coronóide da ulna/Arthroscopical treatment of fragmented medial coronoid process (FCP) of the ulna. *Arq. Bras. Med. Vet. Zootec.* 2012; 64: 09-14. ISSN 1678-4162
- [64] Van Ryssen, B.; Van Bree, H. Diagnostic and surgical arthroscopy in small animals. In: Bloomberg, M.S.; Dee, J.F.; Taylor, R.A., editors. *Canine sports medicine and surgery*. Philadelphia: Saunders; 1998. pp. 250-254. DOI: ISBN 0-7216 5022-8
- [65] Rezende, C.M.F.; Melo, E.G.; Madureira, N.G.; Freitas, P.M. Artroscopia da articulação fêmoro-tíbiopatelar de cão. *Arq. Bras. Med. Vet. Zootec.* 2006; 58: 841-848. DOI: 10.1590/S0102-09352013000300013
- [66] Kon, E.; Filardo, G.; Di Matteo, B. et al. Platelet-rich plasma in sports medicine: new treatment for tendon and cartilage lesions. *Oper. Tech. Orthop.* 2012; 22: 78-85. ISSN 1048-6666 (Print); 1558-3848 (Electronic)
- [67] Flores, J.R.; Gallego, M.A.P.; García-Denche, J.T. Plasma rico en plaquetas: fundamentos biológicos y aplicaciones en cirugía maxilofacial y estética facial. *Rev. Esp. Cir. Oral Maxilofac.* 2012; 34: 8-17. DOI: 10.1016/j.maxilo.2011.10.007
- [68] Carrasco, J.; Bonnete, D.; Gomar, R. Plasma Rico en Plaquetas vs. Plasma rico en factores de crecimiento. *Rev. Esp. Cir. Osteoartic.* 2009; 46: 127-140. ISSN 0304-5056