Chapter 8

Medical Application of Nonwoven Fabrics - Intra-abdominal Spacers for Particle Therapy

Ryohei Sasaki, Hiroaki Akasaka, Yusuke Demizu, Sachiko Inubushi, Tianyuan Wang and Takumi Fukumoto

Additional information is available at the end of the chapter

http://dx.doi.org/10.5772/61787

Abstract

The authors aimed to introduce a medical application for nonwoven fabric as spacers in particle therapy. Particle therapy, exhibiting more focused effects on target tissues, has emerged as a promising treatment modality. However, close proximity of tumor tissue and adjacent organs makes delivery of curative doses to the tumor difficult because severe radiation morbidities might occur. A method using surgically placed GORE-TEX sheets as a spacer has been reported. Although this method provides for separation of adjacent organs, the material is not resorbed. To overcome these anatomical and therapeutic difficulties, and to deliver effective radiation doses to treat upper abdominal tumors, we have developed a nonwoven fabric spacer composed of bioabsorbable suture material. The absorbable polyglycolic acid (PGA) spacer had water-equivalent, biocompatible, and thickness-retaining properties. Although further evaluation is warranted in a clinical setting, the PGA spacer may be effective to block particle beams and to separate normal tissues from the radiation field. These findings suggest that the nonwoven-fabric PGA spacer might become a useful device in particle therapy.

Keywords: Spacer, polyglycolic acid, pancreatic cancer, particle therapy, bioabsorbability

1. Introduction

Two of the properties of nonwoven fabrics that have justified previous use in medical products are economic viability in single-use scenarios and reliable performance [1]. The design and

performance characteristics of these products—which come into close contact with the human body—are driven by their end use, which determines the desired function and barrier, absorption, and strength properties, and the fact that any chemical additives need to be biocompatible. Nonwoven products remain the component of choice for providing appropriate protection because of their ability to create barriers due to either the structure of the nonwoven material itself or an additional active coating for personal protective apparel. Nonwoven materials are also beginning to play a role in extracorporeal devices, such as artificial lungs, hearts, and kidneys, as well as in ligament repairs and other skeletal scaffolds, yet these uses are still rare compared with their other uses [2].

Radiotherapy is one of the strategies used against several cancers, and X-ray or particle beams are mainly used for cancer treatment. Particle therapy, exhibiting more focused effects on target tissues, has emerged as a promising treatment modality. Several systematic reviews associated with proton or carbon-ion beam therapy discuss the extensive use of particle therapy to treat various malignant tumors, including chordoma, ocular melanoma, and prostate cancer [3–5]. Several studies have indicated the efficacy of proton therapy for the treatment of hepatocellular carcinoma or pancreatic cancer [6–9]. However, in certain cases, it is difficult to deliver curative doses of radiation to treat upper abdominal tumors without damaging adjacent radiosensitive organs, such as the duodenum, jejunum, and stomach. To overcome these anatomical difficulties and to deliver effective radiation doses to treat upper abdominal tumors, nonwoven fabric barriers have been applied as spacers to separate tumors and adjacent organs [10, 11].

2. Medical application of nonwoven fabric spacers

Nonwoven fabric is a fabric-like material manufactured from long fibers bonded together by chemical, mechanical, heat, or solvent treatment. The performance characteristics of nonwoven fabrics vary according to the material components and the manufacturing process. A characteristic of nonwoven fabrics is not to have directionality for strength or growth. In addition, specific features of nonwoven fabrics include "water absorbency," "chemical resistance," "breathability," "abrasion resistance," and "flexibility." These characteristics of nonwoven fabrics support their use as surgical gowns and hats, masks, drapes, water-absorbing mats, and machine covers. The GORE-TEX sheet is a waterproof, breathable fabric membrane and has been widely used in permanent implants, including the artificial blood vessel, for many years. The GORE-TEX sheet was the first nonwoven fabric to be applied as a spacer in the field of particle therapy [10–12] (Figure 1). The use of this spacer allows the application of particle therapy in cases in which particle therapy may result in severe incurable damage to adjacent organs. However, although the GORE-TEX spacer is useful during the period of particle therapy, it becomes a foreign body after the therapy [12]. Problems related to the ongoing presence of the spacer may be avoided by removal during a second surgery, but repeated operations might be a risk for the patient.

http://dx.doi.org/10.5772/61787

3. Usefulness of nonwoven fabric spacers in the treatment of pancreatic cancer

Despite recent progress in treatment options for pancreatic cancer, survival rates have failed to show any significant improvement [13]. Among these modalities, resection is the only curative treatment for pancreatic cancer, but only 10%–15% of patients have operable tumors [14, 15]. The remaining patients cannot undergo resection because of local invasion or distant metastasis at the time of diagnosis [16]. Local invasion is found in approximately 40% of patients with pancreatic cancer at the time of presentation and most commonly includes the superior mesenteric vessels or the celiac trunk [17].

Chemoradiotherapy with concurrent 5-fluorouracil was historically considered the standard therapy for locally advanced pancreatic cancer [18]. Recently, successful results have been reported with the use of a combination of gemcitabine and proton therapy to treat this type of advanced pancreatic cancer. However, reductions of the irradiation doses and target fields were necessary because approximately 10% of the patients subsequently developed Grade 3 or higher gastric ulcers several months after completing the therapy [9]. In such cases, surgical placement of a spacer between the pancreas and the gastrointestinal tract might be an effective option to reduce gastrointestinal toxicity and allow the continued use of high doses of radiation.

Among pancreatic cancers in various regions, good candidates for spacer placement are unresectable pancreatic body and tail cancers. Pancreatic head cancer is not amenable to this treatment strategy because the pancreatic head cannot be separated from the duodenum.

The treatment strategy aims to keep the gastrointestinal tract away from the irradiation field by spacer placement and to allow the application of proton-beam radiotherapy with curative intent. The GORE-TEX sheets and the omentum are superimposed and applied as a spacer to maintain a safety margin of approximately 10 mm from the gastrointestinal tract. The spacer is finely fixed to the retroperitoneum, peritoneum, stomach, and surrounding tissues using 4-0 nylon to avoid hernia formation. The use of absorbable sutures for the fixation must be avoided because it leads to migration of the spacer. In the treatment of pancreatic body and tail cancers, target gastrointestinal tract components to be protected by spacer placement include the stomach, duodenum, small, jejunum, and colon. Of note, the protection of the duodenal bulb and horizontal part of the duodenum in the region of the Treitz ligament is of particular importance. The spacer placement surgery is a first step to allow proton-beam radiotherapy, and no part of the tumor is resected during this procedure.

Until the end of 2013, 8 patients with unresectable pancreatic body and tail cancers were treated by spacer placement and particle therapy as phase I and phase II trials. One-year and 2-year survival rates were 87.5% and 43.8%, respectively. These patients were free from complications associated with the gastrointestinal tract.

We believe that surgical spacer placement can be used to maintain a safety margin around the gastrointestinal tract. In consequence, full-dose particle-beam radiotherapy for pancreatic body and tail cancers can be achieved without serious toxicities.

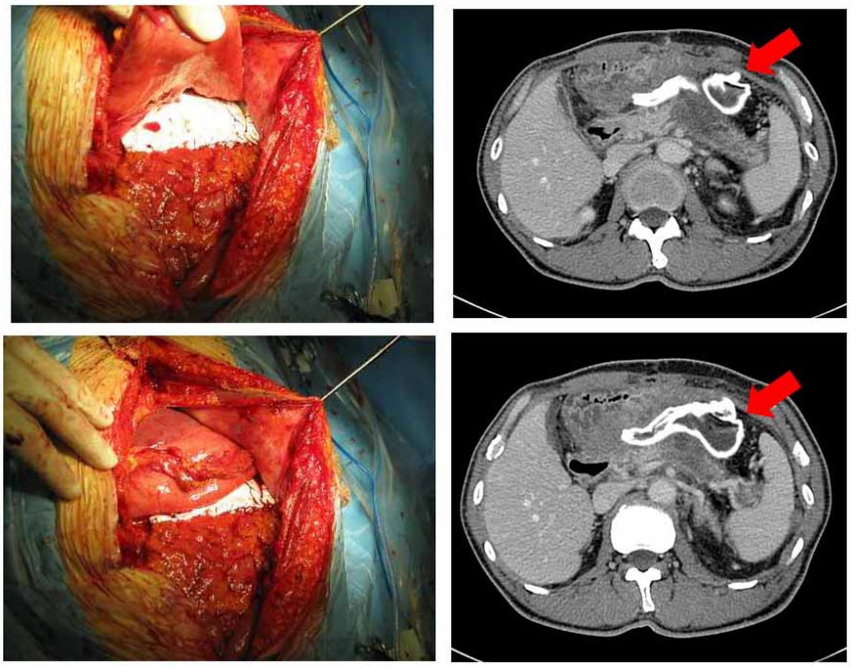

Figure 1. A case of pancreatic body cancer in which a GORE-TEX spacer was placed before the application of proton-beam therapy. The left panels show perisurgical images during the placement of the GORE-TEX spacer. The right panels show computed tomography images, including tumors, liver, adjacent organs, and the GORE-TEX spacer (arrows) after the surgery.

4. Novel nonwoven fabric bioabsorbable spacer for particle radiotherapy

The purpose to produce a bioabsorbable nonwoven fabric spacer is to overcome problems associated with nonabsorbable GORE-TEX spacer [19]. The nonabsorbable GORE-TEX spacer might cause serious complications after the completion of particle therapy. On the other hand, although previous investigators have reported usefulness of gel spacers for separation of prostate and rectum [20, 21], those spacers are inappropriate for the upper abdomen, which contains lots of free space. Therefore, at present, a nonwoven fabric bioabsorbable spacer is necessary and appropriate for the separation of tumor and adjacent organs of upper abdomen malignancies.

The process for producing the nonwoven fabric involves entangling threads in 3 dimensions with a needle-punching process and other methods [22, 23]. Spacer placement during radiotherapy is a promising method designed to allow increased tumor dose while limiting radiation exposure to adjacent organs. The spacer exhibits excellent properties related to bioabsorbability, biocompatibility, thickness retention, and water equivalency according to physical and animal experiments (Figure 2). The reason and the advantage for the use of PGA to construct this nonwoven fabric spacer are that PGA is one of the most widely studied polymers and has excellent mechanical properties and biological affinity [24, 25]. Historically, PGA has played a central role in surgery since its development as the first synthetic absorbable

http://dx.doi.org/10.5772/61787

suture material in 1962 [26]. The PGA is absorbed in 60–90 days after insertion in the body. It is hydrolyzed without any phagocytosis, which results in a weaker immune response than that of absorbable organic sutures [27]. The degradation of PGA generally involves random hydrolysis of their ester bonds. Under physiologic conditions, PGA is also degraded by certain enzymes, especially those with esterase activity [28, 29]. The attractiveness of PGA as a biodegradable polymer in medical application is that its degradation product glycolic acid is a natural metabolite [29]. The glycolic acid is nontoxic and can enter the tricarboxylic acid cycle, after which it is excreted as water and carbon dioxide. Part of the glycolic acid is also excreted in urine [26, 28].

As for PGA sutures, Chu et al. have reported a simple degradation mechanism via homogeneous erosion [30–32]. The degradation process occurs in two stages, the first involves the diffusion of water into the amorphous regions of the matrix and simple hydrolytic chain scission of the ester groups. The second stage of degradation involves largely the crystalline areas of the polymer, which becomes predominant when the majority of the amorphous regions have been eroded. It is important to note that PGA nonwoven fabric spacer is comprised of the PGA suture mainly with a 3-dimensional needle-punching process. Therefore, the degradation mechanism of the content of the PGA spacer could be same as PGA sutures. However, it is possible that because the volume of PGA polymers in the PGA spacer is quite large, inflammatory biological responses might be different from that of relatively small volume of PGA suture (Figure 3).

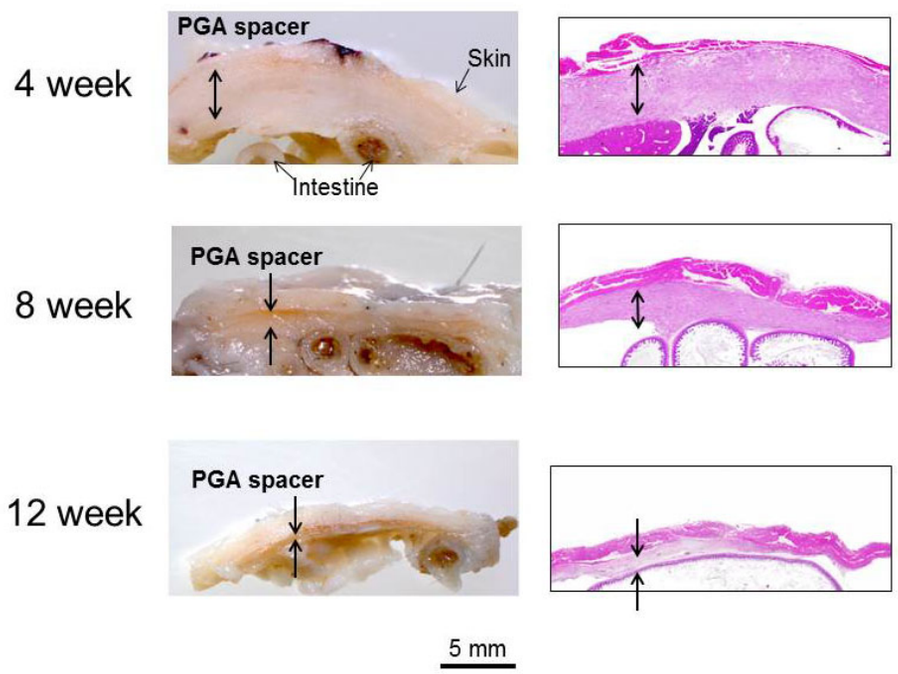

Figure 2. Macroscopic features of a novel nonwoven-fabric bioabsorbable spacer composed of surgical polyglycolic acid (PGA) sutures in the rat abdomen. The left panels show images of formalin-fixed specimens showing the abdominal wall, implanted PGA spacer, and adjacent intestines. The right panels show images of the same specimens stained with hematoxylin and eosin (HE). These images indicate that the PGA spacer was absorbed gradually.

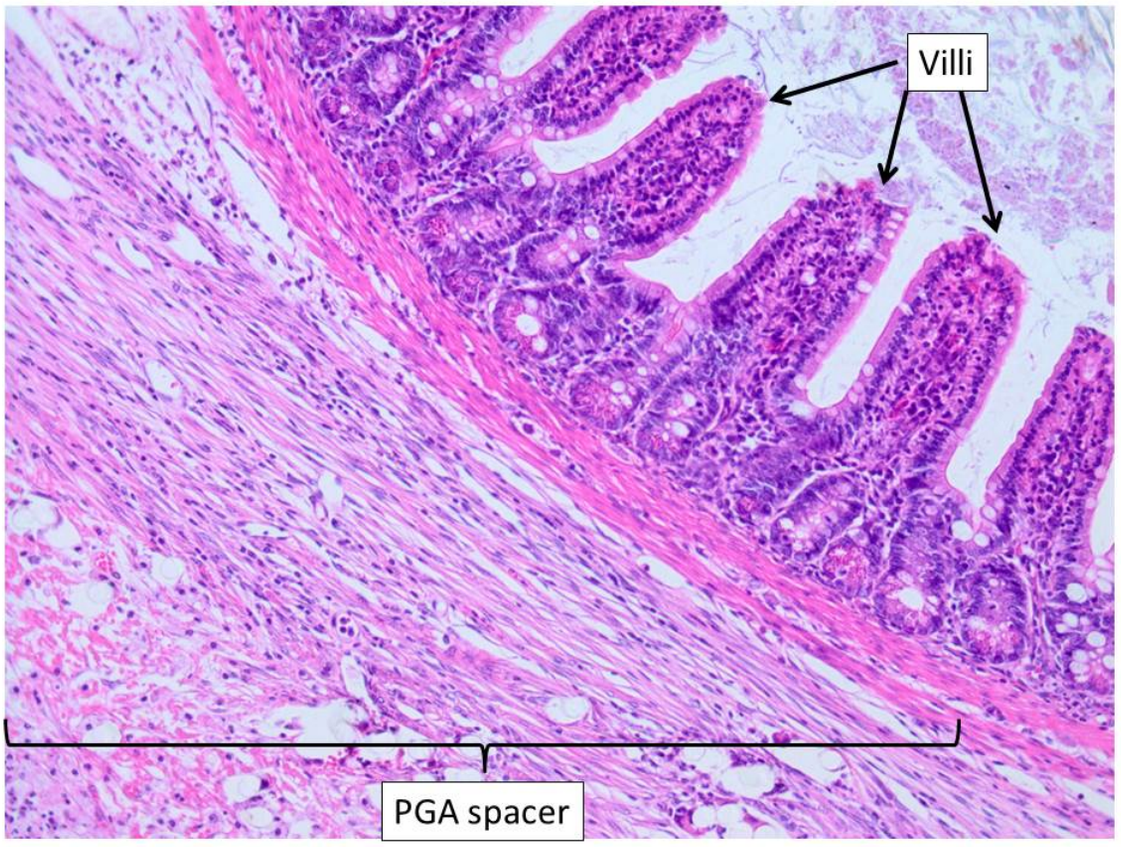

Figure 3. Microscopic features of the PGA bioabsorbable spacer implanted in the rat abdomen. In the surface of the PGA spacer, inflammatory response was observed. There were degraded PGA fibers, lymphocyte, and macrophage observed in the surface. Interestingly, very few cell infiltrations were observed in the body of the PGA spacer

Although there is no clear definition of a bioabsorbable nonwoven fabric spacer reported, an optimal bioabsorbable spacer must have thickness-retaining and water-equivalency properties according to treatment duration [19]. In particle therapies, because treatment protocols take 2–7 weeks [5, 33], a spacer that maintains its thickness for the duration of or slightly longer than the treatment period seems to be ideal. From our investigation, the percentage of thickness retention of the PGA spacer varies according to the concentration of the PGA sutures. The PGA spacer product with 0.2 g/cm^3 of PGA sutures retains more than 90% thickness for 8 weeks. Therefore, this PGA spacer could be applied in various protocols in particle therapy. The bioabsorbable PGA spacer might become a useful device and expand indications for particle therapy.

5. Future direction of medical application of bioabsorbable nonwoven fabric spacers

Adhesions after surgery might lead to serious complications [34, 35]. In the pelvic and abdominal sites, these complications might lead to small-bowel obstruction, infertility, chronic

http://dx.doi.org/10.5772/61787

pelvic pain, and difficulty with further surgical access. Therefore, regarding spacer placement, it is necessary to minimize adhesions between the spacer and surrounding organs. In our preclinical study, the efficacy and the safety of a bioabsorbable spacer composed of PGA sutures were investigated in several animal models [19]. The PGA nonwoven fabric spacer exhibited excellent properties, no toxic effects in the animals, and negligible adhesion formation. However, different conditions between experimental animals and clinical settings might affect outcomes, and adhesion formation may be different in the presence of malignant tumors.

Therefore, if it is necessary to improve properties of the nonwoven fabric PGA spacer, next-generation spacers are expected to avoid adhesion as far as possible. A promising method might be to combine an anti-adhesion material with the PGA spacer. In our recent observation using a healthy rat model, adhesion was significantly decreased, and no exceptional toxicity risk was observed compared with the control group. In the future, less-invasive methods, including endoscopic surgery, might be applied for implantation of the spacer.

6. Conclusion

The absorbable PGA spacer had water-equivalent, biocompatible, and thickness-retaining properties. Although further evaluation is warranted in a clinical setting, the PGA spacer may be effective to block particle beams and to separate normal tissues from the radiation field. These findings suggest that the nonwoven fabric PGA spacer might become a useful device in particle therapy.

Author details

Ryohei Sasaki[1*], Hiroaki Akasaka[1], Yusuke Demizu[2], Sachiko Inubushi[1], Tianyuan Wang[1] and Takumi Fukumoto[1]

*Address all correspondence to: rsasaki@med.kobe-u.ac.jp

1 Divisions of Radiation Oncology and of Hepato-Biliary-Pancreas Surgery, Kobe University Graduate School of Medicine, Kobe City, Hyogo, Japan

2 Department of Radiology, Hyogo Ion Beam Medical Center, Hyogo, Japan

References

[1] Ziegenfus T. Maintaining specialty textiles quality. Textile World. 2005;4:155.

[2] Visser LC, Arnoczky SP, Caballero O, et al. Growth factor-rich plasma increases tendon cell proliferation and matrix synthesis on a synthetic scaffold: an in vitro study. Tissue Engineering Part A. 2010;16:1021–1029.

[3] Brada M, Pijls-Johannesma M, De Ruysscher D. Proton therapy in clinical practice: current clinical evidence. Journal of Clinical Oncology. 2007;25:965–970.

[4] De Ruysscher D, Mark Lodge M, Jones B, et al. Charged particles in radiotherapy: a 5-year update of a systematic review. Radiotherapy and Oncology. 2012;103:5–7. DOI: 10.1016/j.radonc.2012.01.003

[5] Tsujii H, Kamada T. A review of update clinical results of carbon ion radiotherapy. Japanese Journal of Clinical Oncology. 2012;42:670–685. DOI: 10.1093/jjco/hys104

[6] Nakayama H, Sugahara S, Fukuda K, et al. Proton beam therapy for hepatocellular carcinoma located adjacent to the alimentary tract. International Journal of Radiation, Oncology, Biology, Physics. 2011;80:992–995. DOI: 10.1016/j.ijrobp.2010.03.015

[7] Mizumoto M, Okumura T, Hashimoto T, et al. Proton beam therapy for hepatocellular carcinoma: a comparison of three treatment protocols. International Journal of Radiation, Oncology, Biology, Physics. 2011;81:1039–1045. DOI: 10.1016/j.ijrobp.2010.07.015

[8] Klein J, Dawson LA. Hepatocellular carcinoma radiation therapy: review of evidence and future opportunities. International Journal of Radiation, Oncology, Biology, Physics. 2013;87:22–32. DOI: 10.1016/j.ijrobp.2012.08.043

[9] Terashima K, Demizu Y, Hashimoto N, et al. A phase I/II study of gemcitabine-concurrent proton radiotherapy for locally advanced pancreatic cancer without distant metastasis. Radiotherapy and Oncology. 2012;103:25–31. DOI: 10.1016/j.radonc.2011.12.029

[10] Komatsu S, Hori Y, Fukumoto T, et al. Surgical spacer placement and proton radiotherapy for unrespectable hepatocellular carcinoma. World Journal of Gastroenterology. 2010;16:1800–1803.

[11] Fukumoto T, Komatsu S, Hori Y, et al. Particle beam radiotherapy with a surgical spacer placement for advanced abdominal leiomyosarcoma results in a significant clinical benefit. Journal of Surgical Oncology. 2010;101:97–99. DOI: 10.1002/jso.21417

[12] Ogino T, Sekimoto M, Nishimura J, et al. Intraluminal migration of a spacer with small bowel obstruction: a case report of rare complication. World Journal of Surgical Oncology. 2012;10:30. DOI: 10.1186/1477-7819-10-30

[13] Hidalgo M. Pancreatic cancer. New England Journal of Medicine. 2010;362:1605–1617.

[14] Conlon KC, Klimstra DS, Brennan MF. Long-term survival after curative resection for pancreatic ductal adenocarcinoma. Clinicopathologic analysis of 5-year survivors. Annals of Surgery. 1996;223:273–279.

[15] Chua YJ, Cunningham D. Adjuvant treatment for resectable pancreatic cancer. Journal of Clinical Oncology. 2005;23:4532–4537.

[16] D'Souza MA, Shrikhande SV. Pancreatic resectional surgery: an evidence-based perspective. Journal of Cancer Research and Therapy. 2008;4:77–83.

[17] Mancuso A, Calabrò F, Sternberg CN. Current therapies and advances in the treatment of pancreatic cancer. Critical Reviews in Oncology/Hematology. 2006;58:231–241.

[18] Moertel CG, Frytak S, Hahn RG, et al. Therapy of locally unresectable pancreatic carcinoma: a randomized comparison of high dose (6000 rads) radiation alone, moderate dose radiation (4000 rads + 5-fluorouracil), and high dose radiation + 5-fluorouracil: the Gastrointestinal Tumor Study Group. Cancer. 1981;48:1705–1710.

[19] Akasaka H, Sasaki R, Miyawaki D, et al. Preclinical evaluation of bioabsorbable polyglycolic acid (PGA) spacer for particle therapy. International Journal of Radiation, Oncology, Biology, Physics. 2014;90:1177–1185. DOI: 10.1016/j.ijrobp.2014.07.048

[20] Susil RC, Mcnutt TR, Deweese TL, et al. Effects of prostate-rectum separation on rectal dose from external beam radiotherapy. International Journal of Radiation Oncology, Bioliogy, Physics. 2010;76:1251–1258.

[21] Pinkawa M, Corral NE, Caffaro M, et al. Application of a spacer gel to optimize three-dimensional conformal and intensity modulated radiotherapy for prostate cancer. Radiotherapy and Oncology. 2011;100:436–441.

[22] Gunatillake PA, Adhikari R. Biodegradable synthetic polymers for tissue engineering. European Cells and Materials. 2003;5:1–16.

[23] Williams DF. Clinical Implant Materials, 2. Boca Raton, FL: CRC Press; 1981.

[24] Larobina D, Mensitieri G, Kipper MJ, et al. Mechanistic understanding of degradation in bioerodible polymers for drug delivery. AIChE Journal. 2002;48:2960–2970.

[25] Park TG, Cohen S, Langer R, et al. Poly(L-lactic acid)/pluronic blends: characterization of phase separation behavior, degradation, and morphology and use as protein-releasing matrices. Macromolecules. 1992;25:116–122.

[26] Singh V, Tiwari M. Structure-processing-property relationship of poly(glycolic acid) for drug delivery systems 1: synthesis and catalysis. International Journal of Polymer Science. Volume 2010. Article ID 652719, 23.

[27] Craig PH, Williams JA, Davis KW, Magoun AD, Levy AJ, Bogdansky S, et al. A biologic comparison of polyglactin 910 and polyglycolic acid synthetic absorbable sutures. Surgery, Gynecology, and Obstetrics. 1975;141:1–10.

[28] Williams DF, Mort E. Enzyme-accelerated hydrolysis of polyglycolic acid. Journal of Bioengineering. 1977;1(3):231–238.

[29] Gunatillake PA, Adhikari R. Biodegradable synthetic polymers for tissue engineering. European Cells and Materials. 20030;5:1–16.

[30] Chu CC. An in-vitro study of the effect of buffer on the degradation of poly(glycolic acid) sutures. Journal of Biomedical Materials Research. 1981:15: 19–27.

[31] Chu CC. The *in-vitro* degradation of poly(glycolic acid) sutures—effect of pH. Journal of Biomedical Materials Research. 1981;15: 795–804.

[32] Chu CC. Hydrolytic degradation of polyglycolic acid: tensile strength and crystallinity study. Journal of Applied Polymer Science. 1981;26: 1727–1734.

[33] Klein J, Dawson LA. Hepatocellular carcinoma radiation therapy: review of evidence and future opportunities. International Journal of Radiation, Oncology, Biology, Physics. 2013;87:22–32.

[34] Al-Jaroudi D, Tulandi T. Adhesion prevention in gynecologic surgery. Obstetrical and Gynecological Survey. 2004;59:360–367.

[35] Fazio VW, Cohen Z, Fleshman JW, et al. Reduction in adhesive small-bowel obstruction by Seprafilm® adhesion barrier after intestinal resection. Diseases of the Colon and Rectum. 2006;49:1–11.