

# We are IntechOpen, the world's leading publisher of Open Access books Built by scientists, for scientists

6,900

Open access books available

185,000

International authors and editors

200M

Downloads

Our authors are among the

154

Countries delivered to

TOP 1%

most cited scientists

12.2%

Contributors from top 500 universities



WEB OF SCIENCE™

Selection of our books indexed in the Book Citation Index  
in Web of Science™ Core Collection (BKCI)

Interested in publishing with us?  
Contact [book.department@intechopen.com](mailto:book.department@intechopen.com)

Numbers displayed above are based on latest data collected.  
For more information visit [www.intechopen.com](http://www.intechopen.com)



---

# Optical Coherence Tomography for the Assessment of Coronary Plaque Vulnerability

---

Takao Hasegawa and Kenei Shimada

Additional information is available at the end of the chapter

<http://dx.doi.org/10.5772/61615>

---

## Abstract

Optical coherence tomography (OCT) is a high-resolution imaging technology, which can provide detailed observation of the vulnerable coronary atherosclerotic plaques in clinical settings. The current understanding of the major cause of acute coronary syndrome is that it results from plaque rupture of a vulnerable plaque. OCT can provide detailed observation of the vulnerable coronary plaque. The main findings of vulnerable plaque by OCT are considered to be a lipid-rich plaque, a thin-cap fibroatheroma, microchannel structure, spotty calcification, macrophage infiltration, and cholesterol crystal. These features observed by OCT can provide cardiologists to consider pathological mechanisms of coronary atherosclerosis and suitable medical and interventional treatments for vulnerable patients. In this review, we will discuss the characteristics of OCT assessment for coronary atherosclerosis and the clinical impacts of OCT imaging for the treatment of coronary artery disease.

**Keywords:** Optical coherence tomography, Coronary artery disease, Vulnerable plaque

---

## 1. Introduction

Optical coherence tomography (OCT) is an optical analog of intravascular ultrasound (IVUS) that allows physicians to visualize various morphological features of coronary atherosclerotic plaques *in vivo*. Recently, several vulnerable features of coronary atherosclerosis have been suggested in both histopathological and clinical studies with the emerging use of OCT. The main findings of vulnerable plaque by OCT are considered to be a lipid-rich plaque, a thin-cap fibroatheroma (TCFA), microchannel structure, spotty calcification, macrophage infiltration, and cholesterol crystal. We describe the features of vulnerable plaques by OCT and the impact of OCT findings for diagnosis and clinical treatment.

OCT is a high-resolution intracoronary imaging technology with near-infrared light to produce cross-sectional images of coronary artery disease. The spatial resolution of OCT, nearly 10  $\mu\text{m}$  on the lateral axis, is almost 10 times greater than that of IVUS. OCT could provide detailed plaque morphology near to pathological assessment. More than 70% of acute coronary syndrome (ACS) was caused by plaque rupture, and nonruptured type (plaque erosion or calcified nodules) was shown in 30% of ACS. OCT is able to visualize vulnerable plaque which was prone to plaque rupture possibly agree with autopsy findings. Vulnerable feature by OCT were a lipid-rich plaque, a TCFA, vasa vasorum, spotty calcification, macrophage infiltration, cholesterol crystal. We describe the natural history of vulnerable plaques and the clinical impact of each vulnerable feature detected by OCT images.

Recent studies have shown that vulnerable plaques could develop not only in native coronary arteries but also in the neointima after coronary stent implantation. OCT studies have reported the development of neoatherosclerosis changes within both bare-metal stents and drug-eluting stents after stent implantation. Neoatherosclerosis includes lipid accumulation, calcium deposition, macrophage infiltration, and development of neovascularization within neointima area of the stent. These changes after stent implantation could play an important role in the development of late stent failure (late stent restenosis and late stent thrombosis).

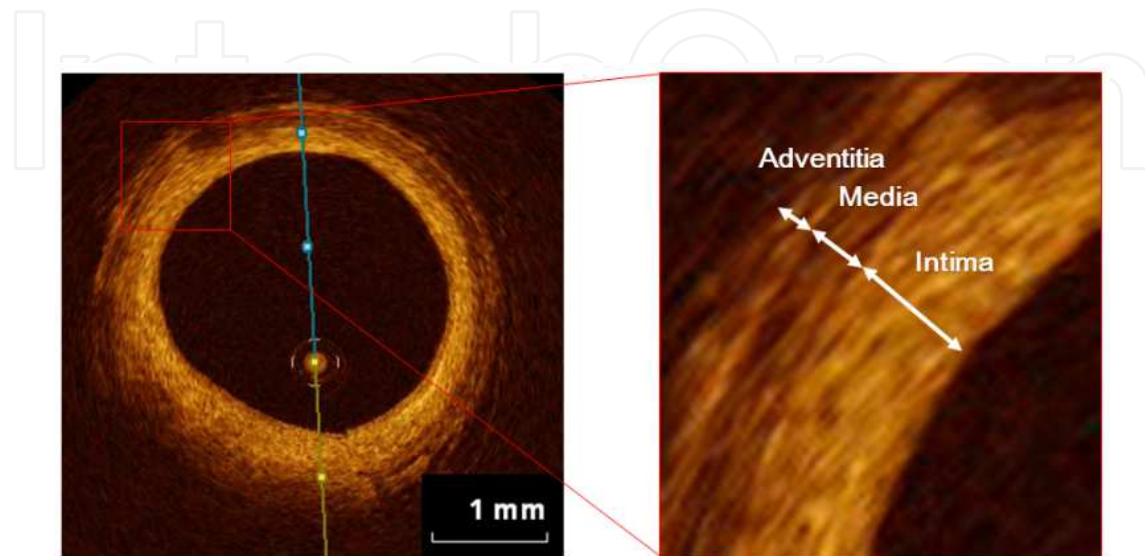
Primary percutaneous coronary intervention (PCI) is widely performed for patients with coronary artery disease. Sometimes, no-reflow phenomenon occurred during PCI, and no-reflow is associated with poor functional and clinical patient outcomes when compared with patients with adequate reflow. Recent studies have shown that some vulnerable findings (lipid-rich plaque, TCFA, and spotty calcification) are predictors of no-reflow phenomenon. We describe how to treat vulnerable plaques during PCI with OCT.

Optimal medical therapy (OMT) is regarded as one of the effective treatments for the stabilization of coronary artery plaques, and it reduces the risk for coronary events and mortality. However, cardiovascular events occur in some patients even with OMT; the residual risk has become a problem. OCT detects and follows vulnerable plaque serially. Dyslipidemia is a strong risk for coronary artery disease and promotes coronary atherosclerosis. We describe the impact of oral lipid-lowering agents on stabilizing vulnerable plaques with OCT.

## 2. Optical coherence tomography technology

OCT is a new high-resolution intracoronary imaging technology based on near-infrared interferometry. As near-infrared light is unable to penetrate red blood cells (RBCs), OCT imaging is needed to remove RBCs in the coronary artery with a bolus injection of contrast medium. The high pull-back speed of OCT enables cardiologists to assess the long coronary plaque components in a few seconds. At present, 2 types of OCT systems, Frequency Domain OCT (St. Jude Medical, ST. Paul, Minnesota, USA) and Frequency Domain Optical Imaging (Terumo, Tokyo, Japan) are available for clinical use. The spatial resolution of OCT, nearly 10  $\mu\text{m}$  on the lateral axis, is almost 10 times greater than that of IVUS. As shown

in Figure 1, OCT visualizes 3-layer structures of coronary artery. OCT-imaging technology allows cardiologists to examine tissue characterization of coronary atherosclerotic lesions *in vivo*.

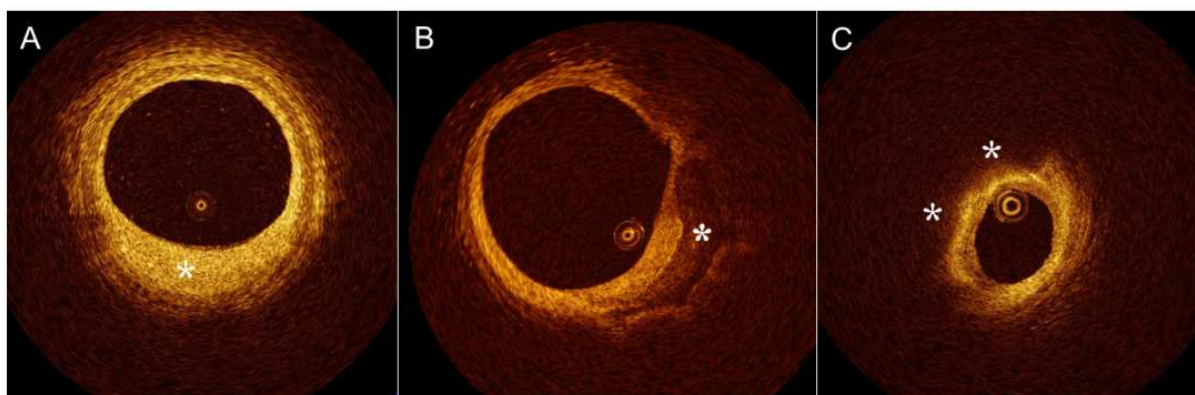


**Figure 1.** Representative optical coherence tomography images of the three layers of the vascular wall. Optical coherence tomography could identify the three layers of the vascular wall.

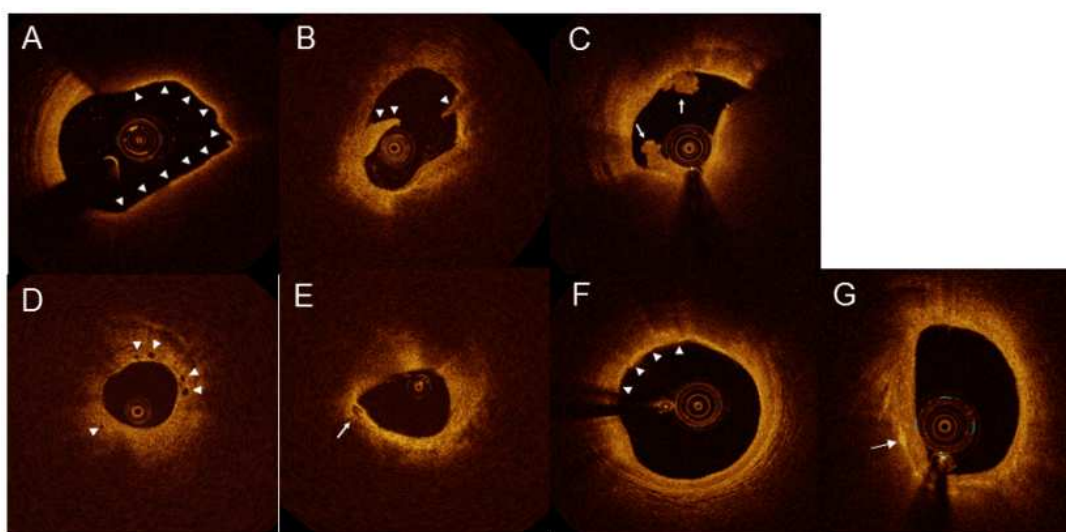
### 3. Coronary plaque vulnerability by OCT

Recently, several vulnerable features of coronary atherosclerosis have been suggested in both histopathological and clinical studies with the emerging use of OCT [1-3]. The ability of OCT in tissue characterization of coronary atherosclerotic lesions has been well-validated in clinicopathological studies [4-6]. OCT could provide detailed plaque morphology near to pathological assessment. OCT can provide three morphological features of coronary atherosclerosis: fibrous plaques, calcified plaques, and lipid-rich plaques (Figure 2). Fibrous plaque is defined as homogeneous, signal-rich regions with low attenuation. Calcified plaque is defined as well-delineated, signal-poor regions with sharp borders. Lipid-rich plaque is defined as signal-poor regions with diffuse borders.

The current understanding of the major cause of ACS is that it results from rupture of a vulnerable plaque. OCT is a high-resolution imaging technology that can provide detailed observation of the vulnerable coronary plaque. The main findings of vulnerable plaque by OCT are considered to be a TCFA, ruptured plaque, intracoronary thrombus, vasa vasorum, spotty calcification, macrophage infiltration, and cholesterol crystal (Figure 3).



**Figure 2.** Plaque morphology by optical coherence tomography. (A) Fibrous plaque is defined as homogeneous, signal-rich regions with low attenuation. (B) Calcified plaque is defined as well-delineated, signal-poor regions with sharp borders. (C) Lipid-rich plaque is defined as signal-poor regions with diffuse borders.



**Figure 3.** Vulnerable findings of optical coherence tomography images in coronary plaques. (A) Thin-cap fibroatheroma (TCFA), (B) Ruptured plaque, (C) Intracoronary thrombus, (D) Vasa vasorum, (E) Spotty calcification, (F) Macrophage infiltration, (G) Cholesterol crystal.

### 3.1. Thin-cap fibroatheroma

TCFA is considered when the fibrous cap thickness is  $\leq 65 \mu\text{m}$  in the lipid-rich plaque. OCT-TCFA has relationship with several characteristics of vulnerable plaque in the other intracoronary imagings, such as attenuated plaque by gray-scale IVUS, necrotic plaque by virtual histology IVUS, and yellow plaque by intracoronary angioscopy [7-9]. Fibrous cap thickness is associated with serum C-reactive protein, oxidized low-density lipoprotein, and insulin resistance [10-12]. OCT-TCFA is a predictor of ACS and consequent plaque progression [13, 14].



### 3.2. Ruptured plaque

Ruptured plaque is defined as an intimal interruption and cavity formation in the plaque. OCT enables detection of ruptured plaque more frequently than IVUS. OCT examination after thrombus aspiration in patients with ACS revealed that 73% of patients showed ruptured plaque, and the mean thickness of the ruptured fibrous cap was 49  $\mu\text{m}$  [15]. Ruptured plaque was often observed in non-culprit lesions of ACS especially in diabetic patients, which showed development of pan-coronary atherosclerosis.

### 3.3. Intracoronary thrombus

Intracoronary thrombus is a major cause of ACS, which is identified as an irregular high- or low-backscattering mass protruding into the lumen. OCT can distinguish between thrombus white and red thrombus [16]. White thrombus presents with a low-backscattering structure. Red thrombus presents with a high-backscattering structure with signal-free shadowing.

### 3.4. Vasa vasorum

Vasa vasorum plays a pivotal role in coronary plaque growth by increasing red blood cells, thereby supplying inflammatory cells and cytokines into the plaque. Sluimer et al. revealed that vasa vasorum was increased in advanced plaques compared with early plaques in a human histological study [17]. OCT has been proposed as a high-resolution imaging modality that can identify vasa vasorum as microchannels with tiny black holes (50-100  $\mu\text{m}$ ). The proliferation of vasa vasorum has been identified recently as a common feature of vulnerable plaque [18]. Kitabata et al. demonstrated increase of vasa vasorum counts in TCFA [19]. An observational study of OCT revealed that the presence of vasa vasorum in the plaques was also associated with positive remodeling and elevated high-sensitive C-reactive protein levels. The OCT evaluation of vasa vasorum counts might be helpful for assessing plaque vulnerability.

### 3.5. Spotty calcification

Clinical observations have suggested that the culprit lesions responsible for ACS are generally less calcified than those responsible for stable angina pectoris (SAP), indicating that calcium renders plaques more, rather than less stable [20]. However, the pattern of plaque calcification may also matter; a small amount of calcium was reported as a characteristic of vulnerable plaque that contributes to plaque instability. A pathological study by Burke et al. demonstrated that plaque rupture and TCFA, considered to represent vulnerable plaque, were most frequently associated with spotty calcification [21]. Previous IVUS studies have revealed a positive relationship in patients with acute myocardial infarction (AMI) between small and discrete calcifications within an arc of less than 90°, the presence of a fibrofatty plaque, and positive remodeling of the culprit arterial segment [22]. Recently, two OCT clinical studies as for spotty calcification (with an arc of <90°) have been reported. Kataoka Y et al. showed that plaques containing spotty calcification exhibited a greater lipid plaque volume, thinner fibrous caps ( $89.0 \pm 31.6 \mu\text{m}$  vs.  $136.5 \pm 32.5 \mu\text{m}$ ,  $P = 0.002$ ) and a higher prevalence of vasa vasorum

(45.9% vs. 17.7%,  $P = 0.007$ ) in the culprit lesion of SAP patients [23]. Another study reported by Mizukoshi M et al. showed that in the ACS patients compared with SAP patients spotty calcification was more frequently observed in the ACS patients compared with SAP patients and located close to the luminal surface [24]. Thus, spotty calcification detected by OCT was positive relationship with plaque vulnerability.

### 3.6. Macrophage infiltration

Degradation of the fibrous cap matrix by macrophages is associated with atherosclerotic plaque instability [25]. Macrophages infiltration detected by OCT were observed as a “bright spot,” with a high signal variance from the surrounding tissue. Tearney et al. [26] and MacNeill et al. [27] described OCT was capable to evaluate cap macrophage content accurately. High degree of positive correlation was observed between OCT and histological measurements of macrophage density in fibrous cap ( $r < 0.84$ ,  $P < 0.0001$ ). OCT provided detection of cap macrophage density  $>10\%$  with 100% sensitivity and specificity [19].

### 3.7. Cholesterol crystal

Previous studies demonstrated that cholesterol crystallization is higher in vulnerable pathological examination [28]. Kellner-Weibel et al. suggested that, within the lesion, macrophages may have the pivotal role in initial nucleation and subsequent growth of cholesterol crystals [29]. Meanwhile, it has been shown that phagocytosis of cholesterol crystals by macrophages causes and advances an inflammation in the atherosclerotic plaques [30, 31]. OCT-imaging system with high-resolution could visualize structures suggestive of accumulations of cholesterol crystals *in vivo* [6]. Cholesterol crystal by OCT was defined as a thin linear region of high density without attenuation [32]. Clinical OCT studies have suggested that cholesterol crystals frequently coexist with the major findings of vulnerable plaque (spotty calcification, vasa vasorum, and lipid-rich plaque), and are often seen in poorly controlled diabetic patients [32].

## 4. In-stent neoatherosclerosis

In-stent neoatherosclerosis has been reported several years after drug-eluting stent (DES) and bare-metal stent (BMS) implantation. Neoatherosclerosis is more frequent and occurs earlier in patients undergoing DES implantation than those treated with BMS [33]. Neoatherosclerosis includes lipid accumulation, calcium deposition, macrophage infiltration, neovascularization within neointima, and results in very late stent failure including late stent thrombosis and in-stent restenosis [34]. OCT studies have reported that in both BMS and DES, neointima in the stent often comprises lipid-laden tissue in late phase of stent implantation and that expansion of neovascularization from peri-stent to intra-intima leads to atherosclerotic progression of neointima [35, 36]. Although the causes of neoatherosclerosis are unknown, Kato et al. recently showed that predictors of neoatherosclerosis are old stent age  $\geq 48$  months, DES usage, age  $\geq 65$  years old, current smoking, and chronic kidney disease [37].

## 5. Relationship vulnerable plaque by OCT and no-reflow phenomenon

Primary PCI is widely performed for patients with coronary artery disease. Sometimes, no-reflow phenomenon occurred during PCI in both patients with ACS and SAP, and no-reflow after PCI is associated with poor functional and clinical patient outcomes when compared with patients with adequate reflow [38, 39]. Thus, accurately detecting high-risk lesions of no-reflow phenomenon is warranted for interventional cardiologists. Recent OCT studies have shown that some vulnerable findings (lipid-rich plaque, TCFA, and spotty calcification) are predictors of no-reflow phenomenon. Ikenaga et al. showed that length of lipid pool was longer in the ST-segment resolution (-) group than in the ST-segment resolution (+) group in patients with ST elevation myocardial infarction ( $10.1 \pm 2.8$  mm and  $7.8 \pm 3.2$  mm,  $p = 0.02$ ) [40]. Lee et al. showed that TCFA was associated with cardiac troponin I elevation after PCI and the presence of TCFA was an independent predictor of periprocedural myocardial infarction (odds ratio, 10.47; 95% confidence interval, 3.74–29.28;  $P < 0.001$ ) [39]. Tanaka et al. showed that TCFA was more often observed in the no-reflow group than in the reflow group (50% vs. 16%,  $P = 0.005$ ) and the frequency of the no-reflow phenomenon increased according to the size of the lipid arc in the culprit lesion in patients with ACS (Lipid arc 1–90°, 4.7%; 91–180°, 35%; 181–360°, 75%) [41]. Furthermore, Ueda et al. showed that colocalization of TCFA and spotty calcification was an independent predictor of PCI-related cardiac troponin T elevation (odds ratio 8.40, 95% confidence interval 1.65–52.78,  $P < 0.01$ ) [42]. Thus, OCT could be a useful tool for risk stratification of PCI.

## 6. Considering optimal medical therapy for vulnerable plaque with OCT

Atherosclerosis has an important inflammatory component and acute cardiovascular events can be initiated by inflammatory processes occurring in vulnerable plaques. The current understanding of the major cause of ACS is that it results from rupture of a vulnerable plaque. OCT is a high-resolution imaging technology that can provide detailed observation of the vulnerable coronary plaque. TCFA is the most typical OCT findings as a vulnerable plaque. OMT is regarded as one of the effective treatments for the stabilization of coronary vulnerable plaques, and it reduces the risk of coronary events and mortality. Intensive lipid-lowering therapy with statins is regarded as one of the effective treatments for the stabilization of coronary artery plaques, and reduces the risk for coronary events and mortality [43]. Serial OCT observations could explain this efficacy of statin therapy. Takarada et al. showed that statin therapy for 9 months after the onset of AMI significantly increased the fibrous-cap thickness in patients with hyperlipidemia ( $151 \pm 110$   $\mu$ m to  $280 \pm 120$   $\mu$ m,  $P < 0.01$ ) [44]. However, cardiovascular events occur in some patients even with statin therapy, and residual risk has become a problem. Habara et al. showed the effect of ezetimibe in addition to fluvastatin on the progression of coronary vulnerable plaque evaluated by OCT. The change in the fibrous cap thickness was significantly greater in the ezetimibe and fluvastatin group than in the fluvastatin alone group ( $0.08 \pm 0.08$  mm vs  $0.04 \pm 0.06$  mm,  $P < 0.001$ ) [45]. The Japan EPA (eicosapentaenoic acid) Lipid Intervention Study, which was a large randomized clinical



trial, showed that purified EPA administration along with statin therapy reduced the incidence of coronary events by 19% [46]. Hasegawa et al. showed that lower EPA/AA ratio was associated with higher vulnerability of coronary plaques by OCT examination. The low EPA/AA group had wider maximum lipid arc ( $114.0 \pm 94.8^\circ$  vs.  $56.4 \pm 66.0^\circ$ ,  $p = 0.0097$ ), longer lipid length ( $4.8 \pm 4.5$  mm vs.  $1.6 \pm 2.6$  mm,  $p = 0.0037$ ), and thinner fibrous cap ( $69.3 \pm 28.3$   $\mu\text{m}$  vs.  $113.3 \pm 46.6$   $\mu\text{m}$ ,  $p = 0.005$ ) compared with the high EPA/AA group [47]. Nishio et al. showed that the EPA and statin group had a greater increase in fibrous-cap thickness, with a greater decrease in lipid arc and lipid length compared with the statin alone group [48].

## 7. Conclusion

OCT is a high-resolution imaging technology that can provide detailed observation of vulnerable coronary atherosclerotic plaques in clinical settings. Since only OCT imaging of coronary artery is not able to accurately predict the future adverse events in patients with coronary artery disease (CAD), bringing together clinical data obtained by OCT with clinical data will improve future outcome of patients with CAD. Further developments in imaging technology could enable cardiologists to precisely detect vulnerable plaques in coronary artery and to improve more optimal treatments for vulnerable patients.

## Author details

Takao Hasegawa and Kenei Shimada\*

\*Address all correspondence to: shimadak@med.osaka-cu.ac.jp

Department of Internal Medicine and Cardiology, Osaka City University Graduate School of Medicine, Abeno-ku, Osaka, Japan

## References

- [1] Bourantas CV, Garcia-Garcia HM, Serruys PW. Letter by Bourantas et al. regarding article, "Nonculprit plaques in patients with acute coronary syndromes have more vulnerable features compared with those with non-acute coronary syndromes: a 3-vessel optical coherence tomography study." *Circ Cardiovasc Imaging*. 2012 Nov; 5(6):e68. 23169984.
- [2] Kato K, Yonetsu T, Kim SJ, Xing L, Lee H, McNulty I, et al. Nonculprit plaques in patients with acute coronary syndromes have more vulnerable features compared with those with non-acute coronary syndromes: a 3-vessel optical coherence tomography study. *Circ Cardiovasc Imaging*. 2012 Jul;5(4):433-40. 22679059.

- [3] Ambrose JA. In search of the "vulnerable plaque." Can it be localized and will focal regional therapy ever be an option for cardiac prevention? *J Am Coll Cardiol*. 2008 Apr 22;51(16):1539-42. 18420095.
- [4] Kume T, Akasaka T, Kawamoto T, Watanabe N, Toyota E, Neishi Y, et al. Assessment of coronary arterial plaque by optical coherence tomography. *Am J Cardiol*. 2006 Apr 15;97(8):1172-5. 16616021.
- [5] Rieber J, Meissner O, Babaryka G, Reim S, Oswald M, Koenig A, et al. Diagnostic accuracy of optical coherence tomography and intravascular ultrasound for the detection and characterization of atherosclerotic plaque composition in ex-vivo coronary specimens: a comparison with histology. *Coron Artery Dis*. 2006 Aug;17(5):425-30. 16845250.
- [6] Tearney GJ, Regar E, Akasaka T, Adriaenssens T, Barlis P, Bezerra HG, et al. Consensus standards for acquisition, measurement, and reporting of intravascular optical coherence tomography studies: a report from the International Working Group for Intravascular Optical Coherence Tomography Standardization and Validation. *J Am Coll Cardiol*. 2012 Mar 20;59(12):1058-72. 22421299.
- [7] Takano M, Jang IK, Inami S, Yamamoto M, Murakami D, Okamatsu K, et al. In vivo comparison of optical coherence tomography and angioscopy for the evaluation of coronary plaque characteristics. *Am J Cardiol*. 2008 Feb 15;101(4):471-6. 18312760.
- [8] Kubo T, Matsuo Y, Ino Y, Tanimoto T, Ishibashi K, Komukai K, et al. Optical coherence tomography analysis of attenuated plaques detected by intravascular ultrasound in patients with acute coronary syndromes. *Cardiol Res Pract*. 2011;2011:687515. 21941667. Pubmed Central PMCID: 3173965.
- [9] Sukiennik A, Radomski M, Rychter M, Kubica J. Usefulness of optical coherence tomography in the assessment of atherosclerotic culprit lesions in acute coronary syndromes. Comparison with intravascular ultrasound and virtual histology. *Cardiol J*. 2008;15(6):561-3. 19039763.
- [10] Takarada S, Imanishi T, Ishibashi K, Tanimoto T, Komukai K, Ino Y, et al. The effect of lipid and inflammatory profiles on the morphological changes of lipid-rich plaques in patients with non-ST-segment elevated acute coronary syndrome: follow-up study by optical coherence tomography and intravascular ultrasound. *JACC Cardiovasc Intervent*. 2010 Jul;3(7):766-72. 20650439.
- [11] Matsuo Y, Kubo T, Okumoto Y, Ishibashi K, Komukai K, Tanimoto T, et al. Circulating malondialdehyde-modified low-density lipoprotein levels are associated with the presence of thin-cap fibroatheromas determined by optical coherence tomography in coronary artery disease. *Eur Heart J Cardiovasc Imaging*. 2013 Jan;14(1):43-50. 22573905.
- [12] Iguchi T, Hasegawa T, Otsuka K, Matsumoto K, Yamazaki T, Nishimura S, et al. Insulin resistance is associated with coronary plaque vulnerability: insight from optical

- coherence tomography analysis. *Eur Heart J Cardiovasc Imaging*. 2014 Mar;15(3):284-91. 24022065.
- [13] Bouki KP, Katsafados MG, Chatzopoulos DN, Psychari SN, Toutouzas KP, Charalampopoulos AF, et al. Inflammatory markers and plaque morphology: an optical coherence tomography study. *Int J Cardiol*. 2012 Feb 9;154(3):287-92. 20974497.
- [14] Uemura S, Ishigami K, Soeda T, Okayama S, Sung JH, Nakagawa H, et al. Thin-cap fibroatheroma and microchannel findings in optical coherence tomography correlate with subsequent progression of coronary atheromatous plaques. *Eur Heart J*. 2012 Jan;33(1):78-85. 21831910.
- [15] Kubo T, Imanishi T, Takarada S, Kuroi A, Ueno S, Yamano T, et al. Assessment of culprit lesion morphology in acute myocardial infarction: ability of optical coherence tomography compared with intravascular ultrasound and coronary angioscopy. *J Am Coll Cardiol*. 2007 Sep 4;50(10):933-9. 17765119.
- [16] Kume T, Akasaka T, Kawamoto T, Ogasawara Y, Watanabe N, Toyota E, et al. Assessment of coronary arterial thrombus by optical coherence tomography. *Am J Cardiol*. 2006 Jun 15;97(12):1713-7. 16765119.
- [17] Sluimer JC, Kolodgie FD, Bijmens AP, Maxfield K, Pacheco E, Kutys B, et al. Thin-walled microvessels in human coronary atherosclerotic plaques show incomplete endothelial junctions relevance of compromised structural integrity for intraplaque microvascular leakage. *J Am Coll Cardiol*. 2009 Apr 28;53(17):1517-27. 19389562. Pubmed Central PMCID: 2756458.
- [18] Kolodgie FD, Gold HK, Burke AP, Fowler DR, Kruth HS, Weber DK, et al. Intraplaque hemorrhage and progression of coronary atheroma. *New Eng J Med*. 2003 Dec 11;349(24):2316-25. 14668457. Epub 2003/12/12. eng.
- [19] Kitabata H, Tanaka A, Kubo T, Takarada S, Kashiwagi M, Tsujioka H, et al. Relation of microchannel structure identified by optical coherence tomography to plaque vulnerability in patients with coronary artery disease. *Am J Cardiol*. 2010 Jun 15;105(12):1673-8. 20538113.
- [20] Beckman JA, Ganz J, Creager MA, Ganz P, Kinlay S. Relationship of clinical presentation and calcification of culprit coronary artery stenoses. *Arterioscler Thromb Vasc Biol*. 2001 Oct;21(10):1618-22. 11597935. Epub 2001/10/13. eng.
- [21] Burke AP, Weber DK, Kolodgie FD, Farb A, Taylor AJ, Virmani R. Pathophysiology of calcium deposition in coronary arteries. *Herz*. 2001 Jun;26(4):239-44. 11479935. Epub 2001/08/02. eng.
- [22] Fujii K, Carlier SG, Mintz GS, Takebayashi H, Yasuda T, Costa RA, et al. Intravascular ultrasound study of patterns of calcium in ruptured coronary plaques. *Am J Cardiol*. 2005 Aug 1;96(3):352-7. 16054456. Epub 2005/08/02. eng.
- [23] Kataoka Y, Puri R, Hammadah M, Duggal B, Uno K, Kapadia SR, et al. Spotty calcification and plaque vulnerability in vivo: frequency-domain optical coherence tomog-

raphy analysis. *Cardiovasc Diagn Ther.* 2014 Dec;4(6):460-9. 25610803. Pubmed Central PMCID: 4278040.

- [24] Mizukoshi M, Kubo T, Takarada S, Kitabata H, Ino Y, Tanimoto T, et al. Coronary superficial and spotty calcium deposits in culprit coronary lesions of acute coronary syndrome as determined by optical coherence tomography. *Am J Cardiol.* 2013 Jul 1;112(1):34-40. 23540654.
- [25] Moreno PR, Falk E, Palacios IF, Newell JB, Fuster V, Fallon JT. Macrophage infiltration in acute coronary syndromes. Implications for plaque rupture. *Circulation.* 1994 Aug;90(2):775-8. 8044947. Epub 1994/08/01. eng.
- [26] Tearney GJ, Yabushita H, Houser SL, Aretz HT, Jang IK, Schlendorf KH, et al. Quantification of macrophage content in atherosclerotic plaques by optical coherence tomography. *Circulation.* 2003 Jan 7;107(1):113-9. 12515752. Epub 2003/01/08. eng.
- [27] Hoffmann R, Mintz GS, Dussaillant GR, Popma JJ, Pichard AD, Satler LF, et al. Patterns and mechanisms of in-stent restenosis. A serial intravascular ultrasound study. *Circulation.* 1996 Sep 15;94(6):1247-54. 8822976. Epub 1996/09/15. eng.
- [28] Abela GS, Aziz K, Vedre A, Pathak DR, Talbott JD, Dejong J. Effect of cholesterol crystals on plaques and intima in arteries of patients with acute coronary and cerebrovascular syndromes. *Am J Cardiol.* 2009 Apr 1;103(7):959-68. 19327423. Epub 2009/03/31. eng.
- [29] Kellner-Weibel G, Yancey PG, Jerome WG, Walser T, Mason RP, Phillips MC, et al. Crystallization of free cholesterol in model macrophage foam cells. *Arterioscler Thromb Vasc Biol.* 1999 Aug;19(8):1891-8. 10446067. Epub 1999/08/14. eng.
- [30] Rajamaki K, Lappalainen J, Oorni K, Valimaki E, Matikainen S, Kovanen PT, et al. Cholesterol crystals activate the NLRP3 inflammasome in human macrophages: a novel link between cholesterol metabolism and inflammation. *PloS One.* 2010;5(7):e11765. 20668705. Pubmed Central PMCID: PMC2909263. Epub 2010/07/30. eng.
- [31] Duewell P, Kono H, Rayner KJ, Sirois CM, Vladimer G, Bauernfeind FG, et al. NLRP3 inflammasomes are required for atherogenesis and activated by cholesterol crystals. *Nature.* 2010 Apr 29;464(7293):1357-61. 20428172. Pubmed Central PMCID: PMC2946640. Epub 2010/04/30. eng.
- [32] Nakamura S, Inami S, Murai K, Takano M, Takano H, Asai K, et al. Relationship between cholesterol crystals and culprit lesion characteristics in patients with stable coronary artery disease: an optical coherence tomography study. *Clin Res Cardiol: Official Journal of the German Cardiac Society.* 2014 Dec;103(12):1015-21. 25086962.
- [33] Nakazawa G, Otsuka F, Nakano M, Vorpahl M, Yazdani SK, Ladich E, et al. The pathology of neoatherosclerosis in human coronary implants bare-metal and drug-

- eluting stents. *J Am Coll Cardiol*. 2011 Mar 15;57(11):1314-22. 21376502. Pubmed Central PMCID: 3093310.
- [34] Park SJ, Kang SJ, Virmani R, Nakano M, Ueda Y. In-stent neoatherosclerosis: a final common pathway of late stent failure. *J Am Coll Cardiol*. 2012 Jun 5;59(23):2051-7. 22651862.
- [35] Takano M, Yamamoto M, Inami S, Murakami D, Ohba T, Seino Y, et al. Appearance of lipid-laden intima and neovascularization after implantation of bare-metal stents extended late-phase observation by intracoronary optical coherence tomography. *J Am Coll Cardiol*. 2009 Dec 29;55(1):26-32. 20117359.
- [36] Kang SJ, Mintz GS, Akasaka T, Park DW, Lee JY, Kim WJ, et al. Optical coherence tomographic analysis of in-stent neoatherosclerosis after drug-eluting stent implantation. *Circulation*. 2011 Jun 28;123(25):2954-63. 21646494.
- [37] Yonetsu T, Kato K, Kim SJ, Xing L, Jia H, McNulty I, et al. Predictors for neoatherosclerosis: a retrospective observational study from the optical coherence tomography registry. *Circ Cardiovasc Imaging*. 2012 Sep 1;5(5):660-6. 22798521.
- [38] Morishima I, Sone T, Okumura K, Tsuboi H, Kondo J, Mukawa H, et al. Angiographic no-reflow phenomenon as a predictor of adverse long-term outcome in patients treated with percutaneous transluminal coronary angioplasty for first acute myocardial infarction. *J Am Coll Cardiol*. 2000 Oct;36(4):1202-9. 11028471.
- [39] Lee T, Yonetsu T, Koura K, Hishikari K, Murai T, Iwai T, et al. Impact of coronary plaque morphology assessed by optical coherence tomography on cardiac troponin elevation in patients with elective stent implantation. *Circ Cardiovasc Intervent*. 2011 Aug;4(4):378-86. 21791670.
- [40] Ikenaga H, Ishihara M, Inoue I, Kawagoe T, Shimatani Y, Miura F, et al. Longitudinal extent of lipid pool assessed by optical coherence tomography predicts microvascular no-reflow after primary percutaneous coronary intervention for ST-segment elevation myocardial infarction. *J Cardiol*. 2013 Aug;62(2):71-6. 23680004.
- [41] Tanaka A, Imanishi T, Kitabata H, Kubo T, Takarada S, Tanimoto T, et al. Lipid-rich plaque and myocardial perfusion after successful stenting in patients with non-ST-segment elevation acute coronary syndrome: an optical coherence tomography study. *Eur Heart J*. 2009 Jun;30(11):1348-55. 19383736.
- [42] Ueda T, Uemura S, Watanabe M, Sugawara Y, Soeda T, Okayama S, et al. Colocalization of thin-cap fibroatheroma and spotty calcification is a powerful predictor of procedure-related myocardial injury after elective coronary stent implantation. *Coron Artery Dis*. 2014 Aug;25(5):384-91. 24681754.
- [43] LaRosa JC, Grundy SM, Waters DD, Shear C, Barter P, Fruchart JC, et al. Intensive lipid lowering with atorvastatin in patients with stable coronary disease. *New Eng J Med*. 2005 Apr 7;352(14):1425-35. 15755765.



- [44] Takarada S, Imanishi T, Kubo T, Tanimoto T, Kitabata H, Nakamura N, et al. Effect of statin therapy on coronary fibrous-cap thickness in patients with acute coronary syndrome: assessment by optical coherence tomography study. *Atherosclerosis*. 2009 Feb;202(2):491-7. 18572175.
- [45] Habara M, Nasu K, Terashima M, Ko E, Yokota D, Ito T, et al. Impact on optical coherence tomographic coronary findings of fluvastatin alone versus fluvastatin + ezetimibe. *Am J Cardiol*. 2014 Feb 15;113(4):580-7. 24388622.
- [46] Yokoyama M, Origasa H, Matsuzaki M, Matsuzawa Y, Saito Y, Ishikawa Y, et al. Effects of eicosapentaenoic acid on major coronary events in hypercholesterolaemic patients (JELIS): a randomised open-label, blinded endpoint analysis. *Lancet*. 2007 Mar 31;369(9567):1090-8. 17398308.
- [47] Hasegawa T, Otsuka K, Iguchi T, Matsumoto K, Ehara S, Nakata S, et al. Serum n-3 to n-6 polyunsaturated fatty acids ratio correlates with coronary plaque vulnerability: an optical coherence tomography study. *Heart Vess*. 2014 Sep;29(5):596-602. 24005765.
- [48] Nishio R, Shinke T, Otake H, Nakagawa M, Nagoshi R, Inoue T, et al. Stabilizing effect of combined eicosapentaenoic acid and statin therapy on coronary thin-cap fibroatheroma. *Atherosclerosis*. 2014 May;234(1):114-9. 24637411.

