

We are IntechOpen, the world's leading publisher of Open Access books Built by scientists, for scientists

6,900

Open access books available

186,000

International authors and editors

200M

Downloads

Our authors are among the

154

Countries delivered to

TOP 1%

most cited scientists

12.2%

Contributors from top 500 universities



WEB OF SCIENCE™

Selection of our books indexed in the Book Citation Index
in Web of Science™ Core Collection (BKCI)

Interested in publishing with us?
Contact book.department@intechopen.com

Numbers displayed above are based on latest data collected.
For more information visit www.intechopen.com



Skull Base Endoscopic-Assisted Surgery

Joachim M.K. Oertel and
Guilherme Ramina Montibeller

Additional information is available at the end of the chapter

<http://dx.doi.org/10.5772/60588>

Abstract

Endoscopic-assisted surgery is becoming a more and more important tool in the neurosurgical armamentarium. This chapter provides a broad overview of the role of this technique in various skull base procedures. It starts with a historical perspective followed by a thorough exploration of the various principles and techniques for different indications. Additionally, the topics of “minimally invasive” techniques using “key hole” approaches are explained. At the end of this chapter, advantages and pitfalls with endoscopic assisted techniques are discussed.

Keywords: Endoscopic assisted skull base surgery, aneurysm clipping, vestibular schwannoma, key hole surgery

1. Introduction

The neuroendoscopic technique has its roots in the early 20th century, applied at the beginning to treat hydrocephalus with cauterization or removal of the choroid plexus [1, 2]. Pure endonasal endoscopic resection of pituitary tumors became more popular in the 1990s, and skull base endoscopy has made timid advances since then. Increased development in skull base endoscopy occurred just before 2005 [3]. The new generation of neuroendoscopes allowed neurosurgeons to use them in the subarachnoid space and to use their excellent light quality and optical resolution in the depth during microsurgical procedures [1, 4].

Nowadays the neuroendoscope is used in different intracranial procedures as the main visualization tool or as an additional device. In modern skull base surgery, it has a significant

supplementary value and has been used more and more frequently for different pathologies and in diverse occasions. Some advantages of the neuroendoscope for the skull base surgery are as follows:

- a. Very good illumination
- b. The possibility to demonstrate structures from a different angle (“look around the corner”)
- c. Less invasiveness by reduction of approach size and retraction of structures

Different from intraventricular endoscopy, there are no preformed cavities in skull base surgery, and the need of retraction of structures is not infrequent. Vestibular schwannomas, cerebellopontine angle meningiomas, trigeminal neuralgia, epidermoid tumors, hemifacial spasms, and aneurysms are some of the skull base pathologies in which the endoscope can be helpful giving additional information on the target. The possibility of introduction of the tip of the endoscope into deep areas and the use of different angle scopes widening the field of view permit the reduction of surgical trauma during the approach, by reduced retraction of structures.

The endoscopic-assisted technique is becoming a very powerful method to be added to the armamentarium of neurosurgical technologies in skull base surgeries. This chapter provides a broad overview of the role of this technique in a wide spectrum of skull base diseases, starting with a historical perspective of the evolution of the use of the endoscope in skull base surgery and followed by the exploration in depth of the principles and techniques of the different surgical methods. In addition, the topic of “minimally invasive” skull base surgery using “keyhole” approaches and finally the learning curve and complications associated with the application of these new techniques is discussed.

2. Evolution of neuroendoscopy

The name endoscope comes from two Greek words — endon that means within and skopein that means to view [5]. Along the years, this visualization instrument has been used to look inside every natural opening and cavity in the human body.

At the beginning, the direct visualization inside of the bladder, female genital organs, or the digestive tract using a speculum was restricted to a few centimeters. The view into deeper cavities was restricted by the difficulty of illumination and poor visual quality. The son of Italian immigrants and born in Mainz, Germany, in 1773, physician Philipp Bozzini constructed at the beginning of the 19th century what may be considered as a rudimental endoscope. This equipment consisted of a speculum with two chambers — one for the transmission of light and the other one for the visualization. Bozzini called this instrument “Lichtleiter” what in German means “light conductor” [2].

After several improvements and developments of this equipment in Germany and Austria, the serial production of cystoscopes began in the United States at the beginning of the 20th century. The initial use of this technique in neurosurgery has its roots in the early 20th century.

The urologist Victor Darwin L'Esspinasse and the neurosurgeon Allen Buckner Kanavel used for the first time an endoscope to perform the cauterization of the choroid plexus in two children with hydrocephalus in 1910 [1, 2].

Guiot et al. in Paris documented the first case of a pure transsphenoidal endoscopic resection of a pituitary tumor in 1962. This surgical technique became more popular, however, in the mid-1990s. After a short break, increased development of the endoscopy of the skull base could be observed again at the beginning of the 21st century. These advances were fruit of two important elements present at this time: technology and creativity [3]. Endoscopes with better light quality and capable of exceptional image reproduction allowed an excellent exposition of the deep surgical field in the skull base. New ideas and attempts to solve old problems as the restricted straight-line view of the microscope were responsible for additional discoveries in this field [1, 4].

Endoscopic skull base surgery techniques as the minimally invasive approaches, endoscopic-assisted surgery and full-endoscopic surgery are today in continuous development.

Advances of the neuroendoscopic equipment like the endoscope-integrated near-infrared indocyanine green video angiography for aneurysm surgery and the continuously variable-view rigid endoscope with possibility to alternate the view angle without the necessity of changing the scope just as well contribute to the rapid progress of skull base endoscopy [6-8]. In the same way, the combination with other known methods as robot-assisted neuroendoscopy and neuro-navigated endoscopy propel the progress of this technique.

3. Skull base surgery

Skull base surgery comprises the treatment of several pathologies that are located or have their source in the most inferior part of the cranial cavity. Because of the complex anatomy and important structures, approaches and operations in this region have always been challenging. Tumors, aneurysms, and neurovascular conflicts are the most frequent pathologies treated in this area. During the last decades, important developments in the skull base surgery were responsible for substantial reductions in the morbidity and mortality. Advancements of the intraoperative neuromonitoring, microsurgical techniques, and new imaging modalities were some of these developments [9]. The use of the endoscopic technique in this region began later on and is gradually increasing.

3.1. Goals of skull base surgery

Skull base pathologies may be very complex and the decision of the right treatment is not always so evident. In some cases, there is little or no doubt about what should be done. However, in many of these patients, different therapy options or no therapy at all ("wait and see") should be considered. So that the best advice may be given to a patient, the physician must have the knowledge concerning the natural history of the disease and also be up-to-date about the current and new treatment alternatives [10].

The goal of every medical treatment is of course the well-being of the patient. To achieve that, some objectives as tumor complete resection, partial resection, or simply biopsy for eventually further radio- or chemotherapy should be considered in different situations [11]. The skull base surgery aim should be very well analyzed in every case and the expectations of the patient need to be considered for the final decision of the therapy strategy.

The main objective during the surgery of tumors in this region is the complete removal with preservation of function provoking as little physical and mental pressure as possible to the person being treated. If total resection is not possible or represents a great risk of impairment of important functions as in some cases of sphenoid wing meningiomas, large vestibular schwannomas, or petroclival meningiomas, cytoreductive surgery as preparation for radiotherapy should be considered [12, 13]. In certain cases of elderly or, for example, patients with neurofibromatosis type 2, purely decompression may be the main goal of the operation [12, 14].

In most cases, however, the final goal is to achieve a complete tumor resection, aneurysm clipping, or neurovascular decompression with total neurovascular function preservation and minimal patient stress.

4. Clinical features

The clinical presentation of skull base pathologies is very variable, depending on the nature and location of the underlying cause. Cranial nerve dysfunction, cerebellar symptoms, hydrocephalus (e.g., in tumors of the posterior cranial fossa obstructing the 4th ventricle), and thunderclap headache (in patients with subarachnoid hemorrhage after aneurysm rupture) are some of the possible presentations. Furthermore, a considerable number of patients with a skull base disease are referred to a neurosurgical department with no complains and an incidental finding. The actual patient's complains and results expectations should be considered during decision and planning of the most appropriate treatment modality.

5. Diagnosis and neuroimaging

As said before, skull base pathologies are much diversified. The ideal image method should be elected depending on the current questions for each case.

Magnetic resonance imaging (MRI) is useful in almost every case due to its magnificent ability to demonstrate soft tissues. The routine T1-, T2-, and T1 with endovenous contrast injection-weighted images should be obtained in all three planes — axial, coronal, and sagittal — so that an accurate study of each case can be carried out. The fluid-attenuated inversion recovery (FLAIR) is a pulse sequence using an inversion recovery technique that nulls fluids. It is very sensitive to edema and some parenchymal abnormalities and can be used to indirectly demonstrate lesions that are not evident in other sequences. Diffusion weighted imaging (DWI) sequences are useful in differentiating epidermoid tumors, that are hyperintense due

its solid composition), from arachnoid cysts shown hypointense, demonstrating high diffusivity. Some authors still report about the importance of this sequence during the assessment of clival tumors, particularly in differentiating chordoma from chondrosarcoma [15]. The gradient echo sequence provides information about hemoglobin breakdown products and calcifications [16].

Computed tomography (CT) scan is the image of choice for demonstrating bony structures. Before surgeries involving the internal auditory canal (IAC) or sella, for example, a thin-layer CT scan is mandatory. Also during surgery of sphenoid wing meningioma with bone involvement or when using the supraorbital approach, a CT scan may be valuable. Preoperatively, the evaluation of several aspects is important:

- a. Disposition of the bony labyrinth (vestibule, semicircular canals, and cochlea) before drilling of the IAC and avoiding injury of these structures
- b. Disposition and height of the jugular bulb in relation to the posterior wall of the IAC
- c. Extension of the pneumatization of the mastoid cells during suboccipital craniotomy and opening of the IAC's posterior wall
- d. Location of the emissary vein during suboccipital craniotomy
- e. Location of the frontal sinus when using the supraorbital approach
- f. Configuration of the sella and sphenoid sinus during surgery of intra-, para-, and suprasellar lesions
- g. Extension of bone infiltration by tumors such as sphenoid wing meningioma and others

Preoperative computed tomography angiography (CT-angiography) is useful in some cases, demonstrating tumor blood supply and patency of sinuses, veins, and arteries. Tridimensional representation of aneurysm configuration and its relationship with parent, branching, and perforating arteries is likewise helpful in selected circumstances when conceiving the surgical strategy.

Angiography is losing ground to CT-angiography and magnetic resonance angiography but is still the gold standard image method for aneurysm, arteriovenous malformation, and dural arteriovenous fistula evaluation before surgery.

Cervical spine x-ray should be performed preoperatively to rule out gross deformities depending on the patient positioning chosen. If there is necessity of extreme rotation, flexion, or extension of the head as in the semi-sitting position, for example, a cervical study prior to surgery may avoid major injuries.

Preoperative planning is a very important "part of the surgery." Previous and meticulous study of images to understand the individual anatomy of each patient should be performed. Planning of surgery should start with choosing the best craniotomy site and the optimal trajectory to the desired spot. Reachability and view angle using microscope and different angled endoscopes should be taken into consideration. Recognition of anatomical variations and the neurovascular relationship is important to achieve the surgical goal with minimal

effort and without undesirable surprises. The comprehension of aneurysm configuration or exact tumor extension when analyzing images before surgery reduces intraoperative time and fulfills surgeon and staff.

6. Underlying pathologies and current indications for endoscopic-assisted surgery

There are several situations in skull base surgery in which the use of the endoscope may supplement the traditional microscopic visualization technique. Endoscopy may, in these surgeries, commonly enhance the exposure of the operative field and frequently provide new information for the surgeon [17-22]. In the authors' experience, benefits of this visualization technique are noted especially in cases in which important neurovascular structures constitute a hindrance for the straight-line view of the microscope or in cases with a narrow surgical corridor and "keyhole" approaches (e.g., supraorbital approach, retrosigmoidal approach, etc.). Situations in which it is important to have a lateral view as in lesions invading the IAC, for example, are another interesting indication for this technique. Because of the high definition images delivered and the proximity of the endoscope tip to the region observed, superior exposition of surface texture may help in differentiating some lesions from normal tissue.

6.1. Aneurysm surgery

Surgical clipping is still the most complete treatment alternative for intracranial aneurysms [19, 23, 24]. Aneurysm complete exclusion of the circulation after clipping without occlusion of parent, branching, and perforation vessels is the main goal of the surgical therapy. Large series reported incidences of unexpected residual filling and parent artery occlusion after clipping 4–19% and 0.3–12%, respectively [19, 23]. With the continuous advances in endovascular technologies for the treatment of aneurysms, patients undergoing coiling have increased considerably [25]. Reduction of undesirable and preventable events is essential to support that the surgical technique remains as a reliable treatment alternative [19].

The gold standard examination for evaluation after aneurysm clipping is still the intraoperative digital subtraction angiography (DSA). Routine intraoperative DSA is however not available in most centers [19]. New techniques to better expose and understand the aneurysm anatomy and parent and branching vessels' configuration intraoperatively as the near-infrared indocyanine green video angiography (ICG-VA) and microvascular Doppler sonography (mDs) have been developed. A study in 2010 analyzing both techniques concluded that the methods are complementary and the drawbacks could be compensated by each other. In this report, when both techniques were simultaneously used, 90% of all aneurysms could be correctly evaluated. If only one of these techniques was used, evaluations were correct in about 80% of the cases [23]. These intraoperative techniques have also some weak points. Blood flow assessment in small perforators is not possible using the mDs and illumination deep in the surgical field may be deficient during ICG-VA when small craniotomies are performed [23]. Particularly, because of the straight-line view of the microscope, these techniques have the

limited capacity to expose areas behind vessels or the aneurysm sac. To overcome this situation, a mirror or a high-definition image endoscope may be used.

Endoscopy has several advantages (definition, magnification, etc.) in comparison with a simple micromirror during aneurysm surgery. It has been used in different stages of surgery and presented to be safe and effective diminishing unexpected findings as incomplete aneurysm occlusion or parent vessels' compromise in large series reports [19, 26, 27]. About a lower retraction of the nervous structures and reduced morbidity has also been reported [26].

The decision of whether or not to use the endoscope should be based on the preoperative imaging. If this reveals an intricate anatomy, endoscope set and tower should be prepared for possible application. Intraoperative, insufficient exposure of perforators and/or aneurysm anatomy is an indication for the endoscopic-assisted surgery.

6.2. Cerebellopontine angle

The cerebellopontine angle (CPA) is a complex region of the skull base, with elaborated neurovascular structures and little space. Tumors growing in the CPA tend to disturb cranial nerve functions, brainstem, cerebellum, and eventually cerebrospinal fluid circulation. Different tumors incurring in this location present different behaviors, infiltrating, pushing, or adhering to important structures. Some lesions "create space," pushing structures and sometimes facilitating the approach. Epidermoid tumors, for example, frequently spread around cranial nerves, arteries, and veins invading recesses and corners making complete tumor resection under the straight line view of the microscope difficult, sometimes impossible. Use of endoscopy additionally to the microscope enables a safe removal of such tumors, reduces the extra retraction of nerves and vessels, and eliminates the necessity of enlarging the craniotomy in some cases [22].

The use of the endoscopic-assisted technique during the removal of epidermoid tumors of the posterior fossa is recommended in almost all cases because of the growing behavior of these lesions.

6.2.1. Vestibular Schwannoma

Vestibular schwannomas are benign tumors that generally arise from the vestibular portion of the vestibulocochlear nerve. The region where this tumor grows (Obersteiner–Redlich zone), where the nerve covering myelin changes from central to peripheral type, is close to the opening of the internal auditory canal (IAC) [28]. Dandy considered, in 1941, that surgery of these tumors was the most difficult of all neurosurgical procedures [29]. Resection of these kinds of lesions is still nowadays frequently not easy. One reason for that is the invasion of tumor in the IAC. Visualization of the whole resection area of intrameatal tumors using the microscope is usually just possible after opening the posterior meatus wall. In several cases, the opening of the IAC is not sufficient by risk of damage to the vestibular system and cochlea. By some patients, with high jugular bulb, the complete opening of the IAC is difficult or, sometimes, nearly impossible. Because of the histological benign behavior of this tumor, complete tumor resection with preservation of neurovascular structures and their function is in most cases the aim of surgery.

The capability of the wide view angle of the endoscope associated to the superb illumination of the field enables a deeper exposure of the IAC and eventually residual tumor after resection under microscope view [18, 30-34].

Endoscopy is indicated in cases with deep intrameatal seated vestibular schwannomas, far medial placed labyrinth structures, and high jugular bulb.

6.2.2. *Neurovascular compression syndromes*

Microvascular decompression (MVD) is an important alternative in the treatment of trigeminal neuralgia and hemifacial spasm. Other neurovascular compression syndromes, such as disabling positional vertigo, tinnitus, and glossopharyngeal neuralgia may also, sometimes, be treated through this surgical option [35]. Several vessels may be responsible for the neurovascular conflict. Arteries and also veins can be compressing the nerve. The neurovascular conflict usually occurs at the root exit or entry zone, but compression of the trigeminal nerve distally in Meckel's cave has been described as well [35].

The incidence of identification of a neurovascular conflict during MVD using the microscope oscillates between 25% and 98% in large series [35-37]. The reason of the inability to recognize a neurovascular conflict could be a negative exploration, as the probability to find the site of nerve compression increases with the surgeon's experience [35, 36]. Insufficient visualization of the root exit zone in Meckel's cave or an incomplete view of the inferior and anterior aspect of the trigeminal nerve were also described as a possible reason for a negative exploration during decompression [35].

The use of endoscopy in MVD surgeries has already been described by some authors in the literature [35, 36, 38, 39]. In these cases, a recognition of 100% of the site of compression was reported [35, 36, 38, 39].

During surgeries of neurovascular compression syndromes, the use of endoscopy is specially indicated in cases with unclear or poor exposure of the neurovascular conflict.

6.3. **Intraparenchymal lesions of the brainstem and cerebellum**

The neurosurgical approach to deep seated intraparenchymal lesions of the cerebellum and particularly of the brainstem should be kept as small as possible to avoid unnecessary injuries. Because of the balloon-like shape frequently assumed by the resection cavity, the whole operative field view is not always possible using the straight-line view of the microscope. In these cases, an incomplete resection of the lesion with the microscopic vision may occur. Bertalanffy et al. described in 1991 about the increased risk of a secondary hemorrhage after incomplete resection of deep-seated brainstem cavernomas. In this series, residual cavernous hemangioma induced bleeding in two cases [40]. The use of an endoscope may be useful decreasing the deficit of the microscope during the exposure of a cavity through a small opening. This technique can help the surgeon, peculiarly in cases of cavernous hemangiomas and hemangioblastomas. The use of endoscopy should be indicated in cases of deep seated brainstem and cerebellum lesions and by the existence of a small resected cavity.

6.4. Meningioma

Surgery of skull base meningiomas is challenging. The frequently demanding approach, the close relation with important neurovascular structures, and the possible involvement of bone are some of the adversities found during the surgical treatment of this disease. Not rarely, bone, dura mater, vessels, and cranial nerves are superposed to tumor parts and restrict the straight-line view of the microscope [41]. The endoscopic-assisted microsurgery technique is an advantage for skull base meningioma surgery in the hand of experienced surgeons. Use of different angled endoscopes may reduce craniotomy size, skull base drilling, and brain retraction in selected cases [41].

Reasons for employing the endoscope during surgery of skull base meningiomas are the intricate relationship of tumor with neurovascular structures, deep seated lesions, and inadequate exposure of the anatomy because of an insufficient angle of view, small craniotomy, and preoperative images revealing possible blind corners.

7. Treatment

The first step before treatment of a skull base pathology is the individual understanding of the disease, patient's anatomy, and patient's expectations. By means of a careful imaging examination and recognition of the relationship of important anatomical structures, possible pathways and eventual pitfalls as well as the understanding of the clinical presentation and patient's expectation, the decision for the best treatment choices can be made.

Whether or not to use the endoscope initially, during or at the end of surgery for inspection may be determined by the pathology or preoperative image findings. There are different endoscopic-assisted techniques available, and the most appropriate should be chosen depending on the needs of each case. Some of these endoscopic-assisted surgical alternatives for the treatment of skull base pathologies are discussed in the following text.

7.1. Surgical clipping

The endoscopic technique during aneurysm clipping should always be used in combination with the standard microscopic visualization so that benefits of both methods may represent an advantage (Fig. 1). The endoscopic-assisted surgical technique may be used in different situations during aneurysm clipping:

- a. Inspection of the aneurysm anatomic and topographical configuration as well as of its surroundings
- b. Clipping under endoscopic view, when the approach is limited (e.g., supraorbital keyhole approach)
- c. Post-clipping evaluation, checking for complete occlusion, parent vessel, or perforating artery occlusion or restriction [19]

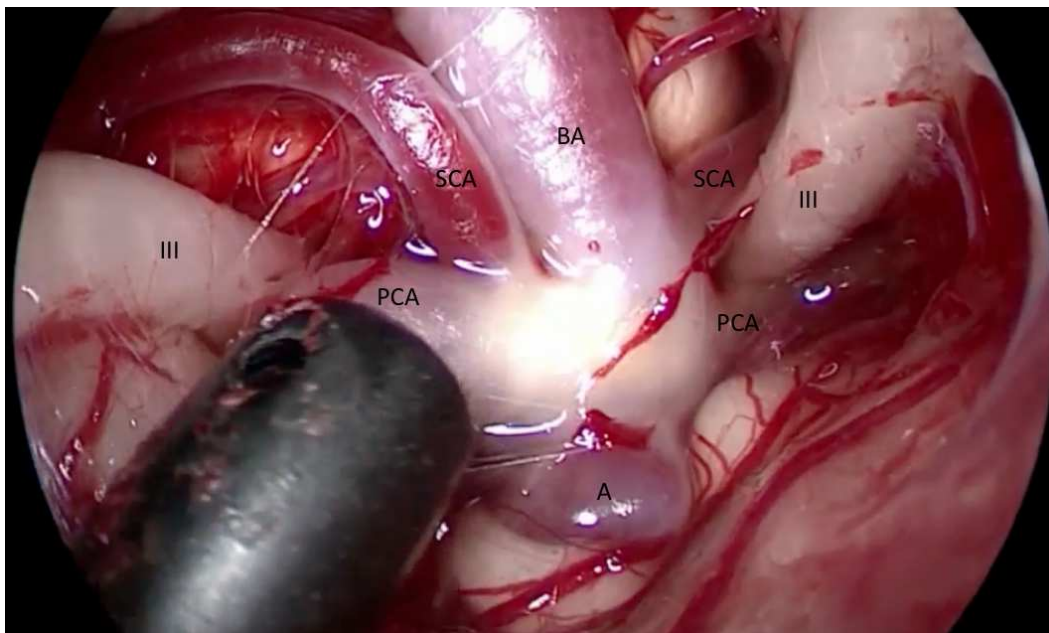


Figure 1. Endoscopic view during inspection of a basilar artery aneurysm before clipping and exposure of the surgical field through the left opto-carotid window and a pterional approach. III, oculomotor nerve; PCA, posterior cerebral artery; SCA, superior cerebellar artery; BA, basilar artery; A, aneurysm sac. (Klinik fuer Neurochirurgie—Universitaet des Saarlandes—Prof. Oertel/Dr. Montibeller)

Use of this technique showed to enhance the completeness of aneurysm occlusion and diminish compromise of involved vessels in a large study series [19].

A novel technique with the endoscopic near-infrared indocyanine green video angiography (ICG-VA) was developed. The aim of this new method is to compensate the weakness of the traditional microscope ICG-VA in the evaluation of vessels located in the depth of the surgical field particularly through small craniotomies. The first results of the comparison of both methods in 40 cases revealed that in 27.5% of cases the endoscopic ICG-VA provided better results for the evaluation of the post-clipping situation. Prevention of neck remnant or branch occlusion could be prevented in four cases, changing the surgical procedure [6].

7.2. Cerebellopontine angle tumor resection

Endoscopy may help in different situations maximizing the exposure of the surgical field during operations in the CPA. The deepness of this region and the complexity of its neurovascular anatomy represent an obstacle to the straight-line view of the microscope. Use of the endoscope in the CPA should, also because of that, be performed by experienced hands. We advocate that insertion of the endoscope in the posterior fossa should always be performed under microscopic view. After initial orientation, the surgeon's sight may switch to the endoscopic monitor.

Changes between angled endoscopes should be performed to offer the optimal exposition for different situations. It is very important to pay attention to the direction of the insertion of the endoscope, especially when using angled optics. With the angled view, the direction of

movement is not the same of sight. Depending on the angle of the optic used and the angle of view, the trajectory of positioning may eventually not be seen with the endoscope.

Because of the narrowness of this region, lens blurring is a frequent problem encountered during inspection. To prevent this issue, the suction tip can be held close to the endoscope tip. This reduces the moisture and keeps the lenses dry. Cleaning of lenses with warmed-up water also helps to minimize this undesirable situation.

7.2.1. Intrameatal tumor resection

Endoscopy may be useful during surgery of tumors invading the IAC (Fig. 2). Especially those with a deep extension inside the canal. The endoscope revealed to be helpful finding residual tumor in 11.1–48.1% of selected cases after microscopic resection during vestibular schwannoma surgery [18, 21, 31–34, 42]. An advantage could also be seen during surgery of other tumors invading the IAC [17]. The capability to look further inside the IAC even before opening it in comparison with the microscope has been proven in cadaveric studies [30].

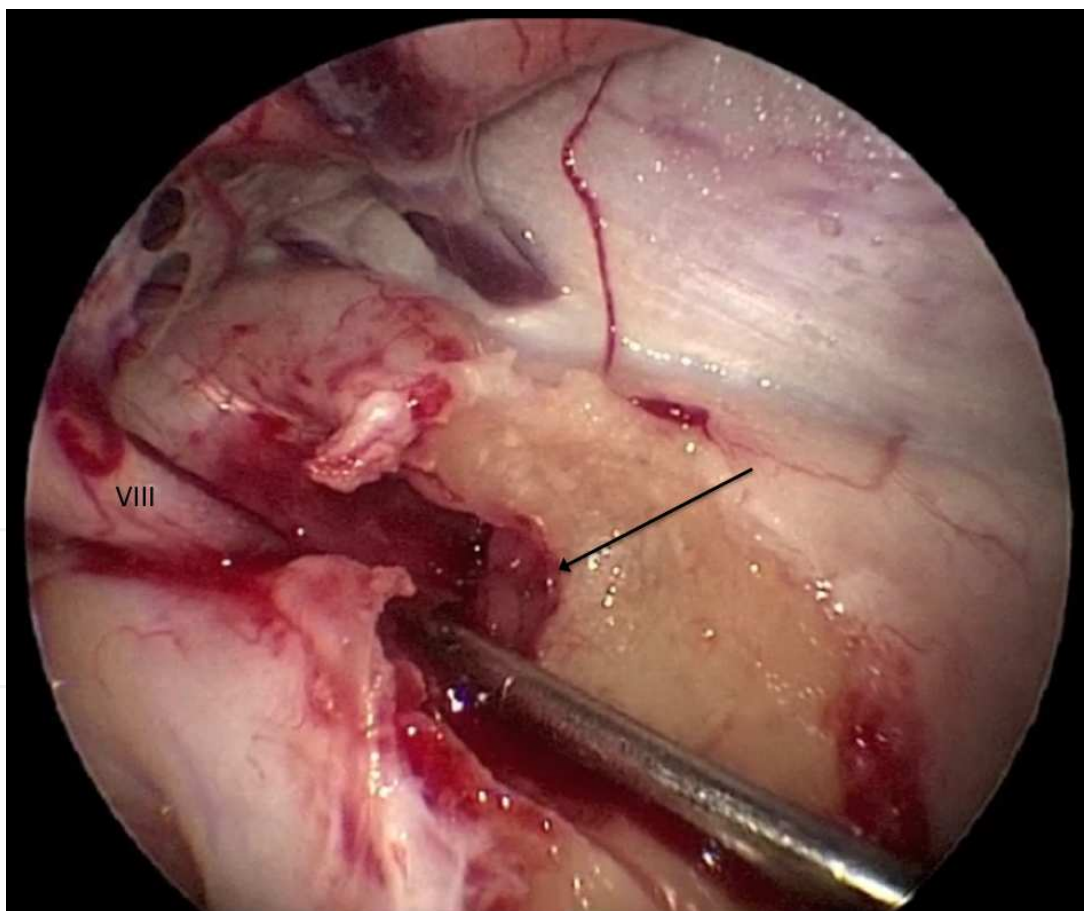


Figure 2. Endoscopic view of the opened internal auditory canal after microscopic resection of a small intrameatal vestibular schwannoma at the right side in semi-sitting position. Detection of intrameatal residual tumor (arrow) due the angled view of the 30° endoscope. VIII, vestibulocochlear nerve. (Klinik fuer Neurochirurgie—Universitaet des Saarlandes—Prof. Oertel/Dr. Montibeller)

The recognition of the facial nerve was facilitated and it could be identified in the early stages of the dissection of vestibular schwannomas using the “look around the corner” technique [32].

Identification of opened air cells minimizing the chance for postoperative cerebrospinal fluid fistula may be another advantage of the endoscopic-assisted technique [31, 43].

Because of the extended view delivered through endoscopy, drilling of the posterior wall of the IAC in cases of a medially placed labyrinth or high jugular bulb may be reduced [30, 44].

7.3. Microvascular decompression

The advantages of the endoscopic-assisted technique during MVD have been described by many authors [17, 35, 36, 38, 39]. The endoscope may be used to inspect the trigeminal and facial nerve root as well as Meckel’s cave. This technique may help to identify the compression site, find multiple spots of neurovascular contact, and confirm decompression at the end of surgery [17].

Fully endoscopic MVD has also been described with good results [45].

7.4. Anterior fossa tumor resection

By surgery of tumors of the anterior cranial fossa, the endoscope may also be useful during inspection before and after microscopic resection. Especially in cases of olfactory groove meningiomas, endoscopy may play a role accessing the integrity of the olfactory nerve.

7.5. Intraparenchymal lesions of the brainstem and cerebellum

Introduction of the endoscope inside small resection cavities of brainstem or cerebellum may provide an advantage for the inspection of the whole wall of the cavity and rule out bleeding spots or residual tumor after microscopic resection.

8. Endoscopic setting

Special microsurgical instruments and technique are necessary as well as microsurgical experience. Changing the views between microscope and endoscope requires attention of the surgeon and his assistant. Several modalities of observing the endoscopic and microscopic images at the same time have been described [4]. Alternating between oculars of microscope and the video screen of the endoscopy, numerous variations may be possible. We use the oculars of the microscope for the microscopic image and a video screen placed in front of the surgeon to display the endoscopic image (Fig. 3). The position of equipment and staff in the operating room is very important so that the surgeon is able to move in an ergonomic or user-friendly way maximizing his coordination. An example with a possible distribution is seen in Fig. 4.

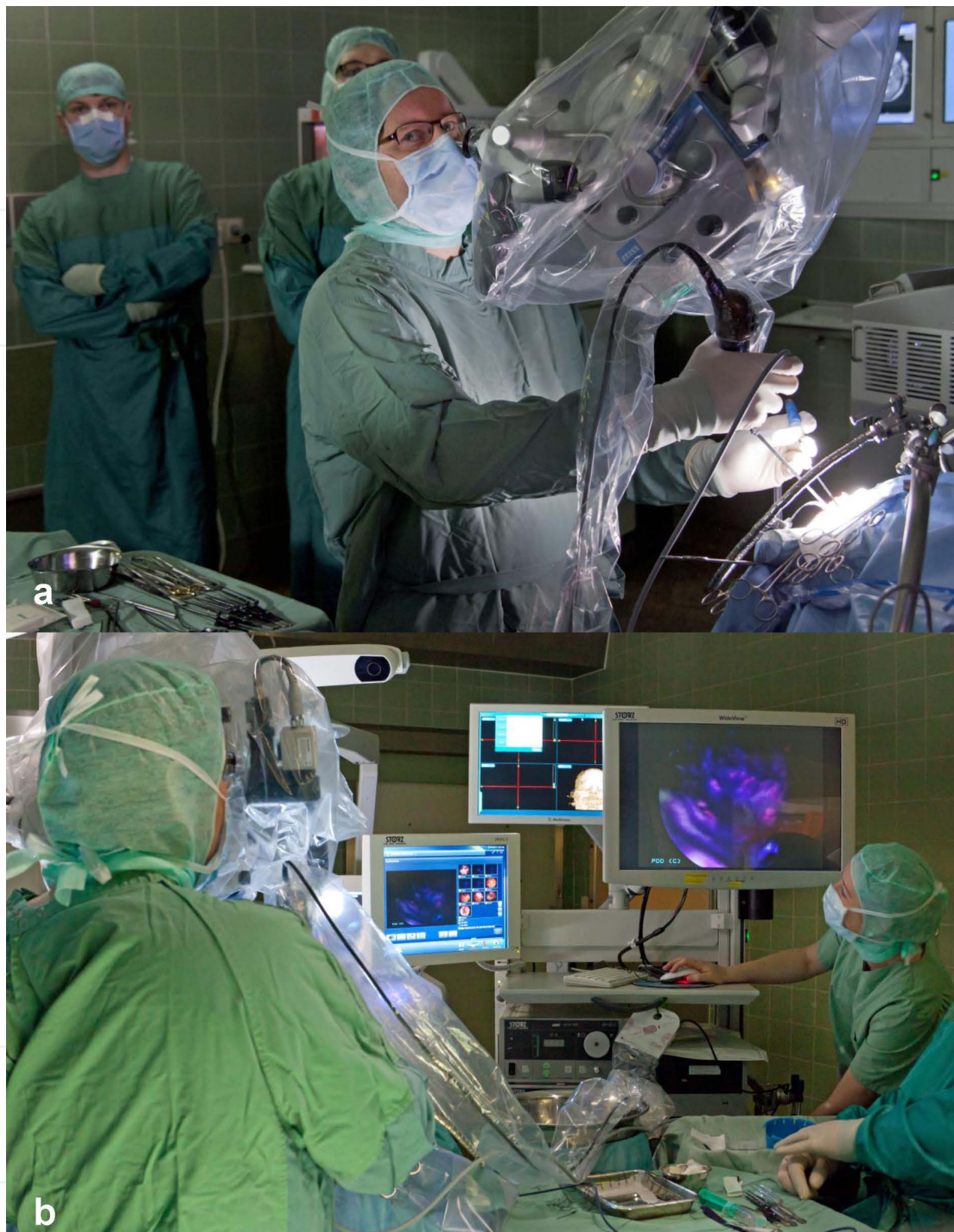


Figure 3. Endoscopic-assisted technique showing the introduction of the endoscope in the surgical field by the surgeon under microscopic view (a) and the position of the endoscope screen (b). (Klinik fuer Neurochirurgie—Universitaet des Saarlandes—photograph of the department: Ruediger Koop)

9. Advantages of endoscopic-assisted surgery

Neuroendoscopy may offer several advantages in selected cases of skull base surgery in comparison with the microscope. The better illumination of the field due to the proximity of

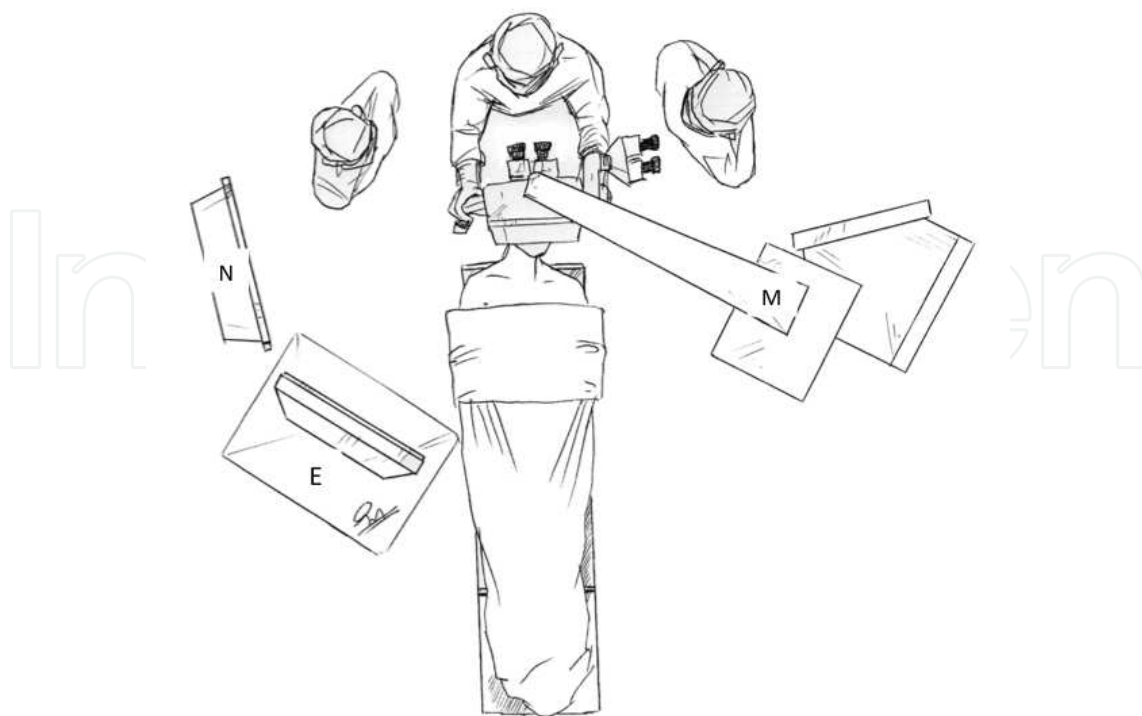


Figure 4. Possible distribution of equipment in the operation theatre providing a user-friendly movement of the surgeon. M: microscope, E: endoscope screen, N: neuronavigation screen. (Dr. Erasmo Barros da Silva Junior)

the endoscope tip to the tissue and the high definition images delivered by the new generation equipment offer an excellent visualization of the surgical field. Also, the different perception of tissue texture is observed when both techniques are compared. The expanded view angle and different possible “looks” using a movable instrument is of course also a benefit in some skull base surgeries with a complex anatomy. Reduced tissue mobilization and the necessity of retraction of important structures as well as reduced trauma are a consequence of the different view angle capability of the neuroendoscope when compared with the microscope. Finding additional information at target in some skull base surgeries is obviously a great benefit of the endoscopy. In the authors’ experience, most of this technique during skull base surgery in the actual days may be achieved when using both techniques, microscope and neuroendoscope, together as supplementary and additive devices.

10. Disadvantages of endoscopic-assisted surgery

Some disadvantages of the endoscope when compared with the image delivered by the microscope are as follows:

- a. Inferior 3D-perception of the images. Compensated with surgeon’s experience time but cannot be set side by side with the microscope, at least not with the current technology. New 3D-endoscopes are in development and trying to improve this issue.

- b. Distortion of images is another issue that should be considered a disadvantage of the endoscopic images. Especially in deep areas, images get deformed in size. Angled endoscopes also distort the images that are distant from the tip [30].
- c. Time consuming — Gerganov et al. analyzed the additional time for the use of this technique during the removal of vestibular schwannomas and concluded that 15–20 minutes extra time was needed in the operating theater applying the endoscope [13]. We believe it is very difficult to exactly calculate the additional time needed for the use of this technique. Some information given through endoscopy may even shorten the operative time. Particularly, only one case with complete tumor removal instead of leaving remnant tumor behind will justify any additional surgical time. If the endoscopic equipment is prepared and set in standby in every skull base surgery, undesirable waste of time may be avoided.

11. Complications and risks

Some authors also reported about the complications and limitations of this technique [22, 34, 41, 46, 47]. The use of endoscopy during skull surgery may correlate with iatrogenic damage of nerves and vessels [46]. Hori et al. reported about the injury of the facial nerve during inspection with the endoscope in one case of a series [34].

The risk of using this instrument, especially with the 30°, 45°, and 70° angulated optics should be kept in mind. With angulated scopes, it is not always easy to know where the tip of the instrument is and the introduction of this tool in the operative field should be performed under microscopic view.

12. Conclusions

Vestibular schwannomas, trigeminal schwannomas, epidermoid tumors, hemifacial spasms, cerebellopontine angle meningiomas, anterior fossa meningiomas, and aneurysms between others are some of the skull base pathologies with which the endoscope can be helpful giving some additional information on the target. The neuroendoscope is usually used for inspection of the situs and not as the main source for imaging. In a few selected circumstances, endoscopic-assisted surgery present a benefit in comparison with the microscope and can be used during the preparation of structures, resection of tumors (e.g., intrameatal vestibular schwannoma or epidermoid tumor), or clipping intricate aneurysms.

Endoscopy in microsurgical removal of vestibular schwannomas may be useful, especially in cases with small deep intrameatal tumors and of high-positioned jugular bulb. Inspection of the fundus of the internal auditory canal may permit the identification of eventual remnant tumor.

In epidermoid tumors, endoscopic inspection, and endoscopic-assisted tumor resection are of great value, particularly in the posterior fossa, finding remnant tumor and reaching difficult

and delicate areas. In epidermoid tumor surgery of the cerebellopontine angle, when remnants are not visible in a straight line, the endoscope-assisted technique can contribute to safe tumor removal. It also allows the resection of tumor extensions without retracting neurovascular structures or enlarging the craniotomy.

In trigeminal neuralgia, the endoscope may help when the neurovascular conflict cannot be identified using the straight-line view of the microscope.

In aneurysm surgery, endoscopy is especially useful in deep-seated lesions and in aneurysms with suspicion of perforators on their backside. In some cases, additional information on aneurysm occlusion and on the patency of parent, branching, and perforating arteries can be gained.

The possibility of introduction of the tip of the endoscope into deep areas and the use of different angle scopes widening the field of view permit the reduction of surgical trauma during the approach, by reduced retraction of structures. Discovery of additional information at target, however, is certainly the principal advantage of this tool. Novel indications for endoscopy in the skull base surgery are growing fast and different uses of this device are being tested.

Acknowledgements

The authors thank Mr. Ruediger Koop for the nice pictures exposing the real surgical situations using the endoscopic-assisted technique and Dr. Erasmo Barros da Silva Junior for his attractive illustration of the ergonomic equipment distribution in the operating room.

Joachim Oertel acts as consultant for Karl Storz Company. Thank you for your cooperation!

Author details

Joachim M.K. Oertel* and Guilherme Ramina Montibeller

*Address all correspondence to: oertelj@freenet.de

Saarland University Medical Center, Homburg, Germany

References

- [1] Grunert P, Gaab MR, Hellwig D, Oertel JM. German neuroendoscopy above the skull base. *Neurosurgical focus*. 2009;27(3):E7.

- [2] Grunert P, Oertel J. Technical and clinical evolution of modern neuroendoscopy. In: Iancu C, editor. *Advances in Endoscopic Surgery: InTech*; 2011. p. 175-90.
- [3] Morcos JJ. Editorial: endoscopy and skull base. *Journal of neurosurgery*. 2012;117(4): 687-9.
- [4] Perneczky A, Fries G. Endoscope-assisted brain surgery: part 1--evolution, basic concept, and current technique. *Neurosurgery*. 1998;42(2):219-24; discussion 24-5.
- [5] Epstein M. Endoscopy: developments in optical instrumentation. *Science*. 1980;210(4467):280-5.
- [6] Rediker J, Fischer G, Oertel J. Endoscope- vs. microscope-integrated near-infrared indocyanine green videoangiography (ICG-VA) in aneurysm surgery. Abstractband 65 Jahrestagung der Deutschen Gesellschaft für Neurochirurgie (DGNC); 13-16.06.20122014.
- [7] Ebner FH, Marquardt JS, Hirt B, Tatagiba M, Schuhmann MU. Visualization of the anterior cerebral artery complex with a continuously variable-view rigid endoscope: new options in aneurysm surgery. *Neurosurgery*. 2010;67(2 Suppl Operative):321-4.
- [8] Ebner FH, Marquardt JS, Hirt B, Feigl GC, Tatagiba M, Schuhmann MU. Broadening horizons of neuroendoscopy with a variable-view rigid endoscope: an anatomical study. *European Journal of Surgical Oncology : the journal of the European Society of Surgical Oncology and the British Association of Surgical Oncology*. 2010;36(2): 195-200.
- [9] Donald PJ. History of skull base surgery. *Skull Base Surgery*. 1991;1(1):1-3.
- [10] Ojemann RG. Skull-base surgery: a perspective. *Journal of Neurosurgery*. 1992;76(4): 569-70.
- [11] Ramina R, Aguiar PHPd, Tatagiba M. *Samii's Essentials in Neurosurgery*. Berlin Heidelberg, Germany: Springer-Verlag; 2014.
- [12] Tatagiba M, Acioly MA. Vestibular Schwannoma: Current State of the Art. In: Ramina R, Aguiar PHPd, Tatagiba M, editors. *Samii's Essentials in Neurosurgery*. Berlin Heidelberg, Germany: Springer-Verlag; 2014. p. 265-83.
- [13] Roser F, Ebner F. Sphenoid Wing Meningiomas. In: Ramina R, Aguiar PHPd, Tatagiba M, editors. *Samii's Essentials in Neurosurgery*. Berlin Heidelberg, Germany: Springer-Verlag; 2014. p. 173-83.
- [14] Matthies C. Functional Microsurgery of Vestibular Schwannomas. In: Ramina R, Aguiar PHPd, Tatagiba M, editors. *Samii's Essentials in Neurosurgery*. Berlin Heidelberg, Germany: Springer-Verlag; 2014. p. 285-300.
- [15] Yeom KW, Lober RM, Mobley BC, Harsh G, Vogel H, Allagio R, et al. Diffusion-weighted MRI: distinction of skull base chordoma from chondrosarcoma. *AJNR American Journal of Neuroradiology*. 2013;34(5):1056-61, S1.

- [16] Parizel PM, Hauwe LVD, Belder FD, Goethem JV, Venstermans C, Salgado R, et al. Magnetic Resonance Imaging of the Brain. In: Reimer P, Parizel PM, Meaney JFM, Stichnoth F-A, editors. *Clinical MR Imaging, A Practical Approach*; 2010.
- [17] Montibeller GR, Oertel J. Endoskopisch assistierte Operationen der hinteren Schädelgrube. Abstractband "Hintere Schädelgrube und kraniozervikaler Übergang - innovative Techniken" 30-30-21 Jahrestagung der Gesellschaft für Schädelbasischirurgie e V (GSB); Tübingen, Germany; 2013.
- [18] Montibeller GR, Gaab MR, Oertel J. What is the role of the endoscope during microsurgical removal of vestibular schwannomas? Abstractband 63 Jahrestagung der Deutschen Gesellschaft für Neurochirurgie (DGNC); 13-16.06.2012/2012.
- [19] Fischer G, Oertel J, Perneczky A. Endoscopy in aneurysm surgery. *Neurosurgery*. 2012;70(2 Suppl Operative):184-90; discussion 90-1.
- [20] Tuchman A, Platt A, Winer J, Pham M, Giannotta S, Zada G. Endoscopic-assisted resection of intracranial epidermoid tumors. *World neurosurgery*. 2013.
- [21] Kumon Y, Kohno S, Ohue S, Watanabe H, Inoue A, Iwata S, et al. Usefulness of endoscope-assisted microsurgery for removal of vestibular schwannomas. *Journal of Neurological Surgery Part B, Skull Base*. 2012;73(1):42-7.
- [22] Schroeder HW, Oertel J, Gaab MR. Endoscope-assisted microsurgical resection of epidermoid tumors of the cerebellopontine angle. *Journal of Neurosurgery*. 2004;101(2):227-32.
- [23] Fischer G, Stadie A, Oertel JM. Near-infrared indocyanine green videoangiography versus microvascular Doppler sonography in aneurysm surgery. *Acta Neurochirurgica*. 2010;152(9):1519-25.
- [24] David CA, Vishteh AG, Spetzler RF, Lemole M, Lawton MT, Partovi S. Late angiographic follow-up review of surgically treated aneurysms. *Journal of Neurosurgery*. 1999;91(3):396-401.
- [25] Nakamura M, Montibeller GR, Gotz F, Krauss JK. Microsurgical clipping of previously coiled intracranial aneurysms. *Clinical Neurology and Neurosurgery*. 2013;115(8):1343-9.
- [26] Perneczky A, Boecher-Schwarz HG. Endoscope-assisted microsurgery for cerebral aneurysms. *Neurologia Medico-Chirurgica*. 1998;38 Suppl:33-4.
- [27] Kalavakonda C, Sekhar LN, Ramachandran P, Hechl P. Endoscope-assisted microsurgery for intracranial aneurysms. *Neurosurgery*. 2002;51(5):1119-26; discussion 26-7.
- [28] Betka J, Chovanec M, Zverina E, Profant O, Lukes P, Skrivan J, et al. Minimally Invasive Endoscopic and Endoscopy-Assisted Microsurgery of Vestibular Schwannoma. In: Iancu C, editor. *Advances in Endoscopic Surgery: InTech*; 2011.

- [29] Ramina R, Aguiar PH, Tatagiba M. Samii's Essentials in Neurosurgery: Springer; 2007.
- [30] Montibeller GR, Fries F, Petrakakis I, Becker KW, Oertel J. Comparison of microscopic and endoscopic view of the internal auditory canal - A cadaveric study. Abstract-band 65 Jahrestagung der Deutschen Gesellschaft für Neurochirurgie (DGNC); 13-16.06.20122014.
- [31] Wackym PA, King WA, Poe DS, Meyer GA, Ojemann RG, Barker FG, et al. Adjunctive use of endoscopy during acoustic neuroma surgery. *The Laryngoscope*. 1999;109(8):1193-201.
- [32] Gerganov VM, Romansky KV, Bussarsky VA, Noutchev LT, Iliev IN. Endoscope-assisted microsurgery of large vestibular schwannomas. *Minimally Invasive Neurosurgery : MIN*. 2005;48(1):39-43.
- [33] Chovanec M, Zverina E, Profant O, Skrivan J, Cakrt O, Lisy J, et al. Impact of video-endoscopy on the results of retrosigmoid-transmeatal microsurgery of vestibular schwannoma: prospective study. *European Archives of Oto-Rhino-Laryngology : Official Journal of the European Federation of Oto-Rhino-Laryngological Societies*. 2013;270(4):1277-84.
- [34] Hori T, Okada Y, Maruyama T, Chernov M, Attia W. Endoscope-controlled removal of intrameatal vestibular schwannomas. *Minimally Invasive Neurosurgery : MIN*. 2006;49(1):25-9.
- [35] Rak R, Sekhar LN, Stimac D, Hechl P. Endoscope-assisted microsurgery for microvascular compression syndromes. *Neurosurgery*. 2004;54(4):876-81; discussion 81-3.
- [36] Badr-El-Dine M, El-Garem HF, Talaat AM, Magnan J. Endoscopically assisted minimally invasive microvascular decompression of hemifacial spasm. *Otology & Neurotology : Official Publication of the American Otological Society, American Neurotology Society [and] European Academy of Otology and Neurotology*. 2002;23(2):122-8.
- [37] Papanagiotou P, Grunwald IQ, Politi M, Struffert T, Ahlhelm F, Reith W. [Vascular anomalies of the cerebellopontine angle]. *Der Radiologe*. 2006;46(3):216-22.
- [38] King WA, Wackym PA, Sen C, Meyer GA, Shiau J, Deutsch H. Adjunctive use of endoscopy during posterior fossa surgery to treat cranial neuropathies. *Neurosurgery*. 2001;49(1):108-15; discussion 15-6.
- [39] Charalampaki P, Kafadar AM, Grunert P, Ayyad A, Perneczky A. Vascular decompression of trigeminal and facial nerves in the posterior fossa under endoscope-assisted keyhole conditions. *Skull base : Official Journal of North American Skull Base Society [et al]*. 2008;18(2):117-28.
- [40] Bertalanffy H, Gilsbach JM, Eggert HR, Seeger W. Microsurgery of deep-seated cavernous angiomas: report of 26 cases. *Acta Neurochirurgica*. 1991;108(3-4):91-9.

- [41] Schroeder HW, Hickmann AK, Baldauf J. Endoscope-assisted microsurgical resection of skull base meningiomas. *Neurosurgical Review*. 2011;34(4):441-55.
- [42] King WA, Wackym PA. Endoscope-assisted surgery for acoustic neuromas (vestibular schwannomas): early experience using the rigid Hopkins telescope. *Neurosurgery*. 1999;44(5):1095-100; discussion 100-2.
- [43] Valtonen HJ, Poe DS, Heilman CB, Tarlov EC. Endoscopically assisted prevention of cerebrospinal fluid leak in suboccipital acoustic neuroma surgery. *The American Journal of Otology*. 1997;18(3):381-5.
- [44] Pillai P, Sammet S, Ammirati M. Image-guided, endoscopic-assisted drilling and exposure of the whole length of the internal auditory canal and its fundus with preservation of the integrity of the labyrinth using a retrosigmoid approach: a laboratory investigation. *Neurosurgery*. 2009;65(6 Suppl):53-9; discussion 9.
- [45] Lang SS, Chen HI, Lee JY. Endoscopic microvascular decompression: a stepwise operative technique. *ORL; Journal for Oto-Rhino-Laryngology and Its Related Specialties*. 2012;74(6):293-8.
- [46] Gerganov VM, Giordano M, Herold C, Samii A, Samii M. An electrophysiological study on the safety of the endoscope-assisted microsurgical removal of vestibular schwannomas. *European Journal of Surgical Oncology: The Journal of the European Society of Surgical Oncology and the British Association of Surgical Oncology*. 2010;36(4):422-7.
- [47] Tatagiba M, Matthies C, Samii M. Microendoscopy of the internal auditory canal in vestibular schwannoma surgery. *Neurosurgery*. 1996;38(4):737-40.