

# We are IntechOpen, the world's leading publisher of Open Access books Built by scientists, for scientists

6,900

Open access books available

186,000

International authors and editors

200M

Downloads

Our authors are among the

154

Countries delivered to

TOP 1%

most cited scientists

12.2%

Contributors from top 500 universities



WEB OF SCIENCE™

Selection of our books indexed in the Book Citation Index  
in Web of Science™ Core Collection (BKCI)

Interested in publishing with us?  
Contact [book.department@intechopen.com](mailto:book.department@intechopen.com)

Numbers displayed above are based on latest data collected.  
For more information visit [www.intechopen.com](http://www.intechopen.com)



---

## **Echinococcosis in Mexico — A Story Worth Sharing**

---

Ana Flisser, Pablo Maravilla, Pilar Mata-Miranda and  
Fernando Martinez-Hernandez

Additional information is available at the end of the chapter

<http://dx.doi.org/10.5772/60868>

---

### **Abstract**

At the beginning of the XXI millennium, while working at a general hospital in Mexico City, a young lady arrived with a previous diagnosis of liver amebiasis given six years earlier. Different treatments in various clinical settings were provided. In the hospital, the first approach was an ultrasound study and unexpectedly an *Echinococcus granulosus* cyst was clearly identified. The patient received adequate treatment and accepted to participate as the index case in an epidemiological survey performed in her community. Inhabitants, dogs, cattle, pigs, and sheep were studied; cysts in humans, pigs, and sheep were searched by ultrasound and dogs by coproantigens, livestock, and dogs were negative for larval or adult stages respectively. The use of ultrasound allowed the detection of two cases (overall prevalence 0.95). DNA of the patient's cyst recovered by surgery was purified, amplified, sequenced, and multiple alignments were performed and analyzed, identifying to *Echinococcus ortleppi*. Subsequently, in a population genetics study focused to evaluate the presence and genetic variability of the intestinal tapeworm in dogs and of cystic echinococcosis in livestock in central areas from Mexico, *Echinococcus canadensis* G7 was identified and was found only in pigs. Based on a genetic network analysis, the following deductions were made: 1) *E. canadensis* G7 in Mexico is very diverse and was probably introduced from abroad several times from different sources and from different countries; 2) G7 haplotypes grouped in the North American wildlife cluster are placed far from Mexican isolates, thus they might be ruled out as sources of introduction to Mexico; and 3) the species status for G7, formally named *E. canadensis*, is still controversial, because biologically different strains (G6 to G10) are currently unified, though ecological and genetic data appear to indicate otherwise.

**Keywords:** Cystic echinococcosis, *Echinococcus canadensis*, *Echinococcus granulosus*, hydatid cyst, Mexico

## 1. Introduction

Echinococcosis, a well-known helminthic disease [1, 2] is practically absent in Mexico since there were only 10 clinical cases of this disease reported in PubMed since 1962. Between 1990 and 1998, only 33 hospitalized cases with postoperative diagnosis of echinococcosis were reported in the yearbook statistics of the Mexican Ministry of Health. Except for two, all cases were in adult men: 10 were reported in 1993 and 21 in 1996. Furthermore, cases might have been in immigrants or travelers but there is no information available [3].

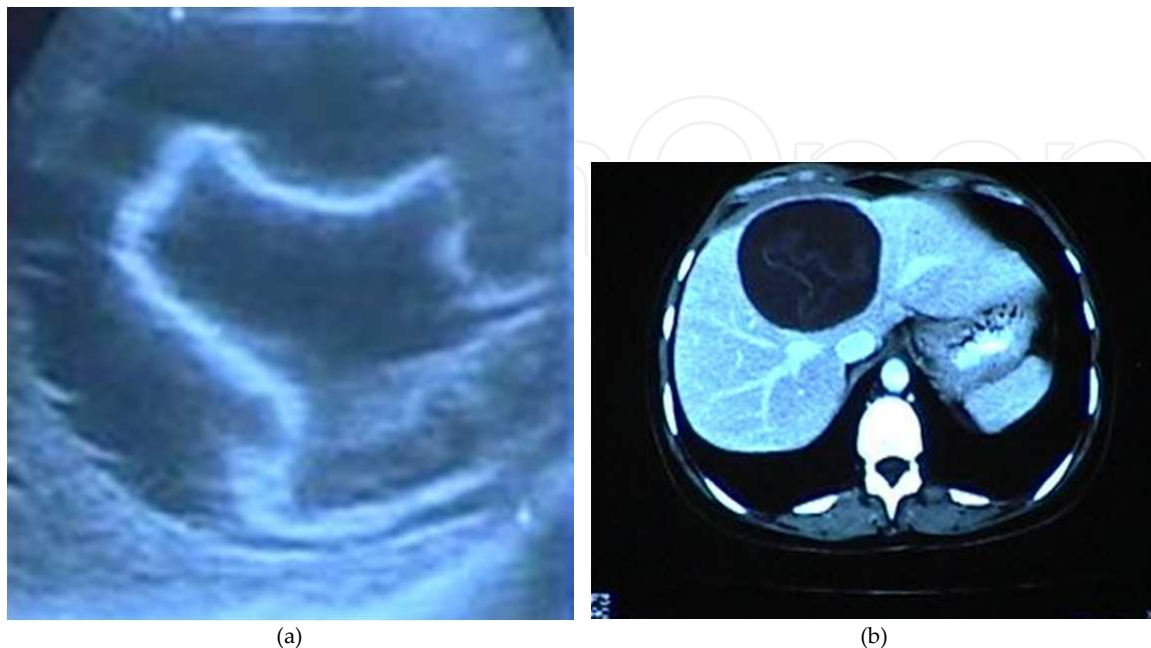
On the other hand, taxonomy of the genus *Echinococcus* has been a matter of controversy and some confusion, particularly for *E. canadensis*, since ecological and geographical strains have been unified into a single species [4-8]. In Mexico, the pig-dog cycle is mainly present and maintains the pig strain of *E. granulosus* sensu lato (s.l.) or genotype (G)7. Some epidemiological studies performed from northern Mexico indicate the presence of the larval stage or cystic echinococcosis (CE) in livestock [9-11]. In addition, *E. oligarthra* has been recorded in a wildcat (*Lynx rufus texensis*) [12], *E. granulosus* sensu stricto (s.s.) in a rural pig [13], and *E. ortleppi* (*E. granulosus* s.l., G5) in a patient [14]. However, there is no evidence that these species are being maintained in Mexico, because only isolated cases have been documented [15, 16]. Here we review and discuss those studies conducted on *Echinococcus granulosus* s.l. in Mexico.

## 2. The clinical case

In the year 2000, a 38-year-old female from a community in the State of Mexico, two hours NW from Mexico City, attended the General Hospital “Dr. Manuel Gea Gonzalez”. She had never lived or visited outside her community. She was treated six years before for cholecystectomy; the surgical finding was a normal bile vesicle, as commented by the patient. Her main complaint was pain in the right hypochondrium without migration that started two months before admission to the hospital, fever, malaise, fatigue, moderate pain with spontaneous exacerbation, and partial remission. Her family history had no importance for the present disease. Previous medical treatment included various antibiotics and metronidazole for the treatment of a hepatic amebic abscess. These drugs were provided simultaneously with painkillers, thus the patient partially improved. A private clinician performed an ultrasonography study (US) and found an undefined cyst with an internal calcification and referred her to the General Hospital “Dr. Manuel Gea Gonzalez”.

One of the hospital clinicians undertook physical examination. No cardiopulmonary abnormalities were seen and peristalsis was normal. On palpation, muscular resistance in the right hypochondria, hepatomegaly, and no signs of acute abdomen were found. Laboratory tests were normal. US showed a solitary cyst that measured around 6 cm and contained undulating hyperechogenic membranes floating inside the cyst fluid (Figure 1a). Computed tomography (CT) image showed a similar pattern (Figure 1b). Since both images resembled a hydatid cyst, an intradermal Casoni test was performed. A thickening of 4 cm at 15 minutes and at 24 hours was detected. Since this test cross-reacts with other helminthes [17], coproparasitological tests

were performed for larva and eggs and the results were negative. Albendazole at 800 mg daily was given for two weeks.

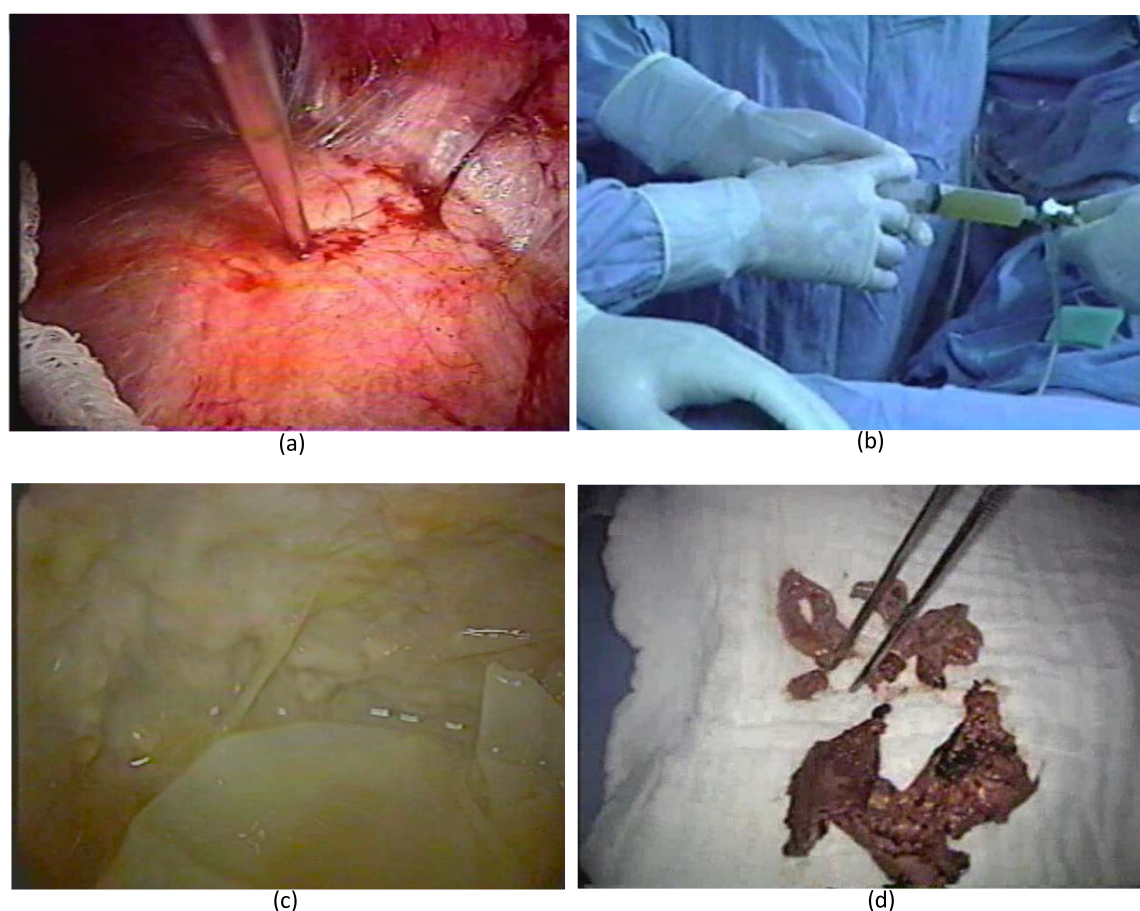


**Figure 1.** Hepatic hydatid cyst of the patient; the ultrasonographic image shows a solitary cyst that measured around 6 cm and contained undulating hyper-echogenic membranes floating inside the cyst fluid (a); the CT shows a similar hyperdense pattern (b).

A colangio-pancreatographic retrograde endoscopy (CPRE) was performed to eliminate the possibility of communicating biliary ducts. The result of this procedure was negative but the patient developed severe post-CPRE pancreatitis, thus enteral feeding was started and albendazole was stopped after one week. Laparoscopic surgery was performed two weeks later by the surgical team of the hospital, using percutaneous aspiration-instillation-reaspiration (PAIR) [18-21]. The cyst was punctured to extract the intracystic fluid (Figure 2a) and instill 100 cc of hypertonic saline solution (17.7% NaCl) as a scolicidal agent (Figure 2b) that was left for 10 minutes. The upper part of the cyst was also irrigated and opened; exploration within the cyst clearly showed the germinal membrane (Figure 2c) that was totally extracted (Figure 2d). No complications arose during the surgical procedure. Seven days later, the patient was sent home without any symptoms. A CT performed 60 days after surgery showed a fluid filled cavity with 50% size reduction. In spite of our lack of experience in the treatment of liver cystic echinococcosis, the decision to perform laparoscopy was taken since the cyst was free in the right liver lobule and the patient could have a surgical procedure of minimal invasion as a definitive treatment for the parasitic disease, which came out successful, without complications or recurrence according to the TC performed 14 and 60 days later.

At the Center for Disease Control and Prevention in Atlanta (CDC), USA, ELISA and western blot were done with the serum samples taken before, 2, 3, and 11 weeks after surgery. All were positive to echinococcosis, and the western blot showed the 8 kDa diagnostic band [22]. At

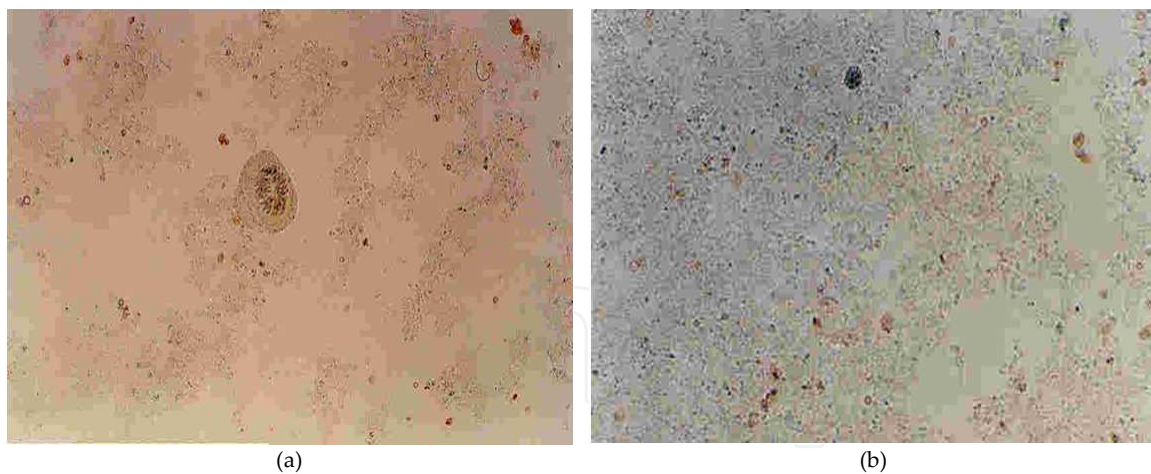




**Figure 2.** The hydatid cyst was punctured to extract the cyst fluid (a) and instill hypertonic saline solution (b); the germinal membrane could be seen from the inner surface of the cyst capsule, in the lower part of the figure the parasite's membrane is smooth, while the host's capsule, seen in the upper side of the figure (c) is rough, probably due to the inflammatory reaction; the germinal membrane was fully extracted (d).

laparoscopy, 90 ml hydatid fluid was collected, immediately low-speed centrifuged, and the pellet was analyzed. Light microscopy showed many protoscolices, mostly damaged (Figure 3a), while the sample obtained after PAIR treatment contained only debris (Figure 3b). These images are probably due to the effect of albendazole and the hypertonic solution, respectively. We tried to confirm and pursue the infection by orally introducing around 500 protoscolices into a young dog, but coproparasitoscopic studies were negative after two months and no parasites were detected at necropsy. Worthwhile mentioning is that for several years the patient received treatments without definitive diagnosis, since bacterial infections, amebic liver abscess, and vesicular problems were presumed. CE is a well-known parasitic disease, its diagnosis, medical treatment, and epidemiology have been exhaustively published [1, 2], imaging techniques are available, and cysts are specific. Nevertheless, differential diagnosis of CE in gastrointestinal malaise is not considered in Mexico [23, 24].

DNA from the germinal layer of the cyst obtained during laparoscopic surgery was obtained and analyzed by RAPD, 18s rRNA PCR-RFLP, and *coI* PCR-sequencing techniques. Banding profiles and sequence analysis matched 100% to *Echinococcus ortleppi* (*E. granulosus* s.l. G5,



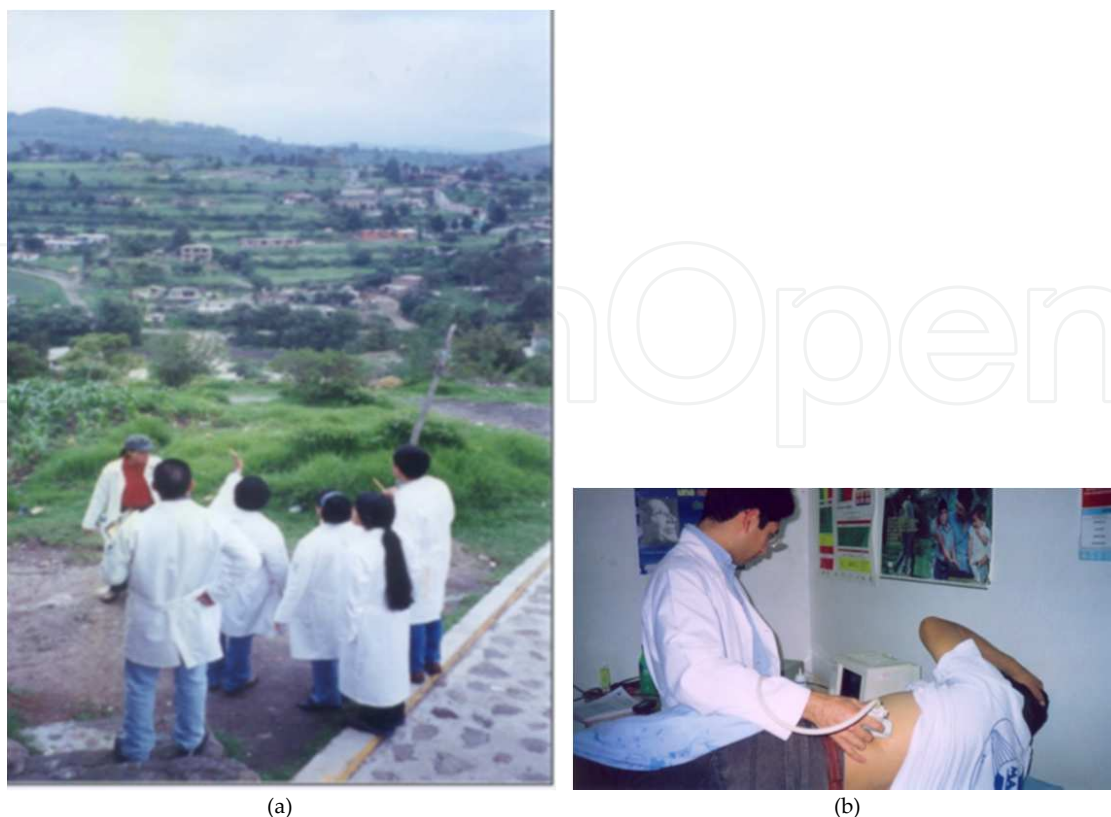**Figure 3.** Micrograph of the pellet obtained after centrifugation of the cyst fluid before instilling the hypertonic solution (a) and after this process (b). An *Echinococcus* protoscolex can be seen in (a) but only detritus in (b).

cattle strain). Interestingly, there are few human cases documented for CE in humans by *E. ortleppi* in the world. DNA analysis of partly calcified cyst recovered from an infected Dutch boy suggested that this *Echinococcus* species can be infective to humans [25] since in regions such as the Netherlands and Switzerland where the cattle strain occurs, cattle may act as a source of human infection. In addition, a first case of cattle strain (G5) in humans in South America was also reported in a rural community of Argentina [26].

### 3. Epidemiologic study

Between September and November 2002, a cross-sectional study was undertaken in the area of the index case, Santa Cruz, Tepozotlan, State of Mexico [3]. The objective of this work was to determine the prevalence and distribution of human echinococcosis and its probable risk factors. This US-based study was a pilot to search for autochthonous human echinococcosis in Mexico. Initially, authorization to perform the study was obtained from the jurisdiction, local authorities, and the clinician in charge of the Health Center. Ethics and Research Commissions of the Hospital General "Dr. Manuel Gea González" approved the research protocol. Household census was used to randomly select houses, visits were done in order to obtain cartography from the community and to identify street names and house numbers. Demographic, household characteristics, and animals were registered. The community, Santa Cruz, is located in the municipality of Tepozotlan, State of Mexico at 19°42'50" N and 99°13'24" W at 2300 masl. The municipality belongs to a warm zone bordered by 4 mountain ranges: Sierra Madre Occidental, Eje Neovolcanico, Sierra Madre Oriental y Sierra Madre del Sur (Figure 4a).

An initial field exercise was performed in the community Cañadas de Cisneros, close to Santa Cruz, in order to train the field workers, to evaluate if the content of the family questionnaire was clearly understood and to register the average time that each worker needed to fill one family questionnaire. One hundred people were interviewed during the exercise and the



**Figure 4.** Scenery of the community of Santa Cruz (a), an ultrasound participant of the community (b).

average time for answering one questionnaire was 10 minutes. Most questions were clearly understood, except when asked if inhabitants had animals, 60% answered no but many had dogs, so another question specific on having dogs was added. This questionnaire was used for the investigation of risk factors in a larger population.

Santa Cruz had then 405 houses (11 were uninhabited), 98% of the streets were paved, electric power, telephone, and drinking water were available, the latter by a chlorine facility. There was no drainage thus latrines were used. Of the 375 houses that were submitted to a census 1,911 inhabitants were found, with an average of 5 (from 1 to 17) per house. Women constituted 63%, average age was 27; 20% of men and women were between 3 and 24 years and 30% were between 25 and 44 years; 48% were single, 41% married, the remaining were widows, couples separated or living together; 39% studied primary school, 24% middle school, 17% high school, 5% kindergarten, 3% bachelor, and 7% illiterate. Male workers made almost half of the population; students (30%) and house workers (23%) constituted the other half. Most houses were built of brick, sand, and had latrines, although 3% used the field. Drinking water was available in 86% of the houses, half of which boil the water before drinking, those lacking drink water from a well. Dogs were present in 83% of houses, 79% were vaccinated for rabies, most slept outside, although half of the dogs were kept tied. Of the 426 dogs in the community, feces were collected from 414 to examine for cestode eggs. After treatment and purge, 3 dogs had *Taenia pisiformis* but none had *Echinococcus*. Also, 83% of people had livestock, 77% were kept close to the house.



Sample size was defined for prevalence, each house was considered a unit; 94 houses were randomly selected and the index case and her family were also included. Families were visited to inform them about the study and invite them to participate; a written informed consent was requested. All members of the selected families were also invited to attend the Health Center for a free US; those units that did not accept, the house to the right replaced them. Cysts were searched in liver, spleen, and kidneys and cyst characteristics were recorded. Blood was drawn from people with images suggestive of CE, serum samples were sent to CDC for diagnosis confirmation, and an in-depth questionnaire was applied to them.

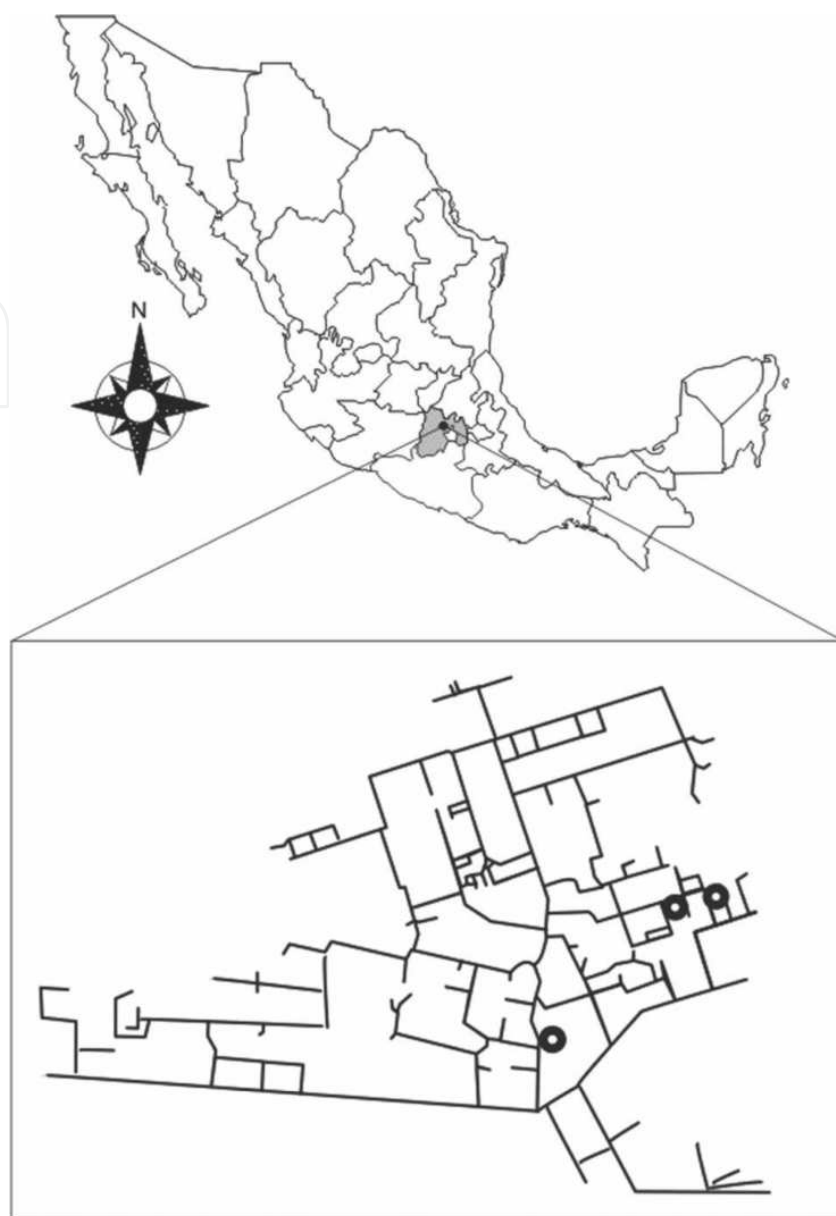
Only 331 people out of the 543 that were invited to have a US attended (Figure 4b). To avoid bias, families that attended and those that did not attend were compared for differences in demographic data. A high proportion of students and house workers were observed; the opposite was found with male workers who were less in the group that undertook a US; this was to be expected because workers could not lose a working day. Regarding knowledge of the disease, 8% of participants older than 18 years said they heard of hydatid cysts or "sand (arenilla)" and 15% referred having seen cysts in livestock viscera. Concerning interaction with dogs, 37% said dogs were guardians, 34% said they were friends or pets, 20% were companions or toys, and 9% said that dogs transmit diseases. How do people show kindness to dogs? 32% pet them, 25% talk to them, and 9% hug and kiss their dogs. While 26% of dogs lick their owners, 22% play or jump, 15% touch their legs, 12% bark, and 25% did not answer. Out of 331 US performed, 2 people had images suggestive of hydatid cysts; added to the index case give a prevalence of 0.9%. Cases were distributed in the same sector of the community (Figure 5). The close distribution of cases suggests the same exposure source.

The index case has been described at the beginning of this chapter in all clinical aspects. Epidemiologic data showed that the husband was a veterinarian. They lived with 12 other family members; all were submitted to diagnostic assays; Casoni test was positive in 3 people at 15 minutes but negative at 48 hours, all 12 were negative in ELISA, and in coproparasitoscopic studies. The house had a cement floor and walls, they had a small farm with 4 sheep, 3 cows, 2 horses, and 1 pig; they also grew vegetables and had 4 dogs that are fed with fresh viscera from livestock slaughtered in the backyard. Dogs were held in the same place for 3 days in order to collect feces to look for the adult parasite, and the results were negative.

The second case detected during the US survey was an 89-year-old married male, without digestive or abdominal symptomatology. The US showed one irregular 76 x 72 mm lesion with a defined wall in the right hepatic lobule, having two densities, one anechoic and internal echoes like snowflakes (Figure 6a). The serum sample was negative. He lived with 6 people in a brick house with a cement floor; he grew vegetables, fresh water was kept in a cistern, drinking water in flasks and had a latrine. He had 2 dogs that were held at the entrance of the house, slept outside, and were fed with leftovers, never with fresh viscera.

The third case, also detected during the US screening survey, was a 46-year-old married female. The US showed one 55 x 48 mm lesion in the left hepatic lobule with a wall slightly limited by a hyperechoic round ring (Figure 6b). The serum sample was negative. There were 4 households, she finished primary school, lived in a brick house with a cement floor, had a latrine,

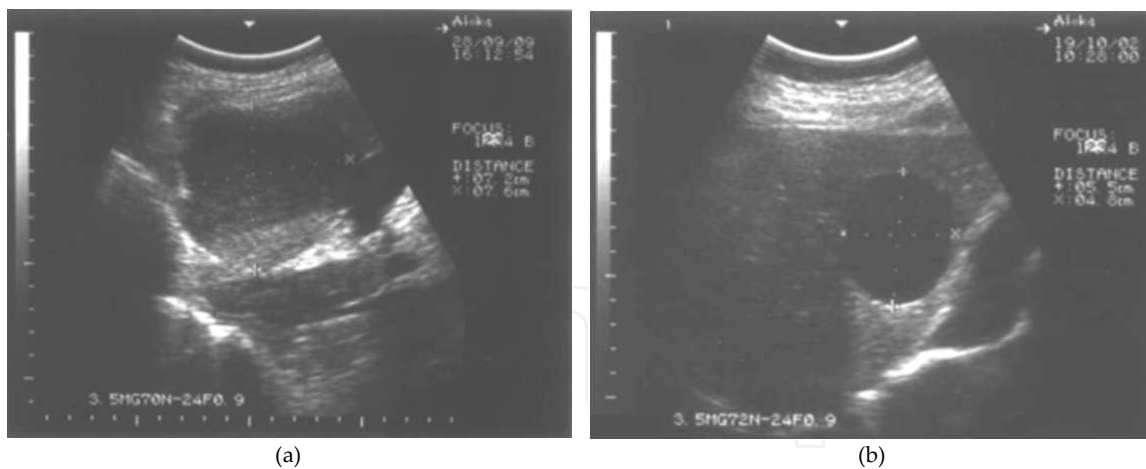




**Figure 5.** Location of the community of Santa Cruz in Mexico and of the cases in the community. Kindly reproduced with permission of the American Society of Tropical Medicine.

fresh water was kept in a small cistern, they boiled drinking water and kept it in flasks. They did not grow vegetables and did not have dogs.

These 2 cases were not confirmed by molecular techniques since, being asymptomatic, they were not offered any treatment at that time. Nevertheless, interestingly, in addition to the fact that the cases lived more or less close by, is the finding that the hydatid cysts of both cases detected in the community had similar sizes (between 5 cm and 7 cm). It is known that hydatid cysts grow approximately 1 cm per year [1, 2], suggesting that exposure occurred around 6 years earlier, and also that possibly one dog harboring *E. granulosus* s.l. adult parasites, living at that time in close contact with their houses, could have infected both patients.



**Figure 6.** US of the second (a) and third probable (b) cases. Kindly reproduced with permission of the American Society of Tropical Medicine.

#### 4. Population genetics study for *Echinococcus*

Due to scarce source of genetic information and as an attempt to clarify the status of *Echinococcus granulosus* s.l. and genetic variability in Mexico, the presence of the intestinal tapeworms in dogs and of CE in livestock of north and central areas from Mexico with informal reports of this parasite was conducted [16].

#### 5. CE in slaughterhouses

Several sanitary inspections to the municipal slaughterhouse of Calera, Zacatecas took place between December 2005 and June 2006 to identify CE in visceral organs, as well as to obtain data regarding the infected animals, place of origin, owner information, and number and size of cysts. In this slaughterhouse, formal farm and backyard livestock animals are accepted, coming from Zacatecas and nearby states (Aguascalientes, Morelos, and San Luis Potosi), thus offal from 387 pigs, 243 bovines, and 32 sheep were inspected for the larval stage of *Echinococcus*. Of the more than 660 animal viscera inspected in the Calera slaughterhouse, 18 pigs showed CE (7 males and 11 females,  $P < 0.05$ ), with a mean of 8 hepatic cysts per animal with average size of  $3.7 \pm 1.7$  cm. Interestingly, a similar tendency about gender in infected animals was observed in the experimental model of CE in mice, where female have a higher number of cysts in liver than male [27]. The global frequency of 5% of CE in pigs seen in the municipal slaughterhouse of Calera and the community studied are similar to previous data of Mexico [9, 13], but lower than those from other Latin American countries that can be as high as 12% for livestock [28]. Samples of fluid cysts from 9 pigs (6 from Zacatecas, 2 from Aguascalientes, and 1 from Morelos) were recovered and stored in 70% ethanol and processed for molecular analysis. PCR for amplifying a partial sequence of mitochondrial cytochrome oxidase I (*coI*) of size  $\approx 450$  bp [29], were performed to fluid cysts and amplicons were purified, sequenced, and compared with several *coI* sequences from the GenBank.

### 5.1. Epidemiological study for CE in livestock

Based on the presence of the parasite in the municipal slaughterhouse of Calera, Zacatecas, a rural community, was selected to identify the adult and larval stages. The community is located in the northern state of Zacatecas, in the central area at 22°55'N, 102°48'W; it has a semi-arid-dry weather, mild temperature (mean 15.4°C), with average rainfall of 448 mm H<sub>2</sub>O.

In 2006, an initial census showed that the community was organized in 39 blocks with 155 houses, 140 were inhabited with 526 peoples, showing a mean of 4±2 people/house, a range from 1 to 11 and a mode of 2. Also, 266 were women and 260 were men, 174 (33%) were younger than 18 years old. On the other hand, 26% were economically active population (136/526) and 74% of households derive their income from a single person; the main activity was agriculture (83%) followed by crafts (10%) and trade (7%). The community had electricity, chlorinated drinking water, and telephone services; 45% of the streets are paved. Of the 140 housing, 49 (35%) had 60 dogs, while in 79 (56%) several livestock were recorded, such as sheep (586 animals/18 houses), cattle (441 animals/58 houses), pigs (124 animals/44 houses), and horses (31 animals/ 24 houses).

### 5.2. Identification of Echinococcus and treatment of dogs

With the owners' verbal consent, feces obtained by rectal spoon of all 60 dogs in the community were recovered and analyzed by Faust technique [3, 30] and by Coproantigen ELISA (CpAg ELISA) [31, 32]. Coprological study showed that 5 dogs were infected with *Toxocara canis* (8.3%), 2 with teniids (3.4%) and 1 with *Ancylostoma caninum* (1.6%), while 11 samples positive for *E. granulosus* antigens (18.3%) were detected. Fecal samples were obtained after treatment and used for egg and antigen detection; none was positive.

For Copro-PCR, only in those 11 positive samples by CpAg ELISA were analyzed; JB3 and JB4 primers [29] only 3 samples yielded one amplicon of ≈450 bp and those were purified and sequenced, showing a high identity with *E. canadensis* G7 genotype.

Positive dogs for taeniid eggs or coproantigens were purged and treated; for this they were isolated in cages with fecal collection facilities, which were maintained in the backyards of their homes, and were treated orally with praziquantel and with arecoline bromide. Dogs were kept in the cage and after collection of feces the dogs were released. However, no tapeworms were recovered after treatment, probably because it was administered 3 months after diagnosis, since arecoline bromide is rarely available in Mexico. Fecal samples were obtained after treatment and used for egg and antigen detection; none was positive.

In addition, a questionnaire was applied to search for possible risk factors in the population, and showed that having fed pig and/or sheep raw offal to dogs was significantly associated with *Echinococcus* antigen positivity (odds ratio=5.9, 95% confidence interval=1.11-31.3, P=0.023).

### 5.3. Identification of CE in pigs and sheep

From July 2006 to January 2007, 586 sheep and 55 adult pigs were examined using US for hydatid cysts in the community. For this, standing sheep were immobilized and US was performed with a transducer between the 4<sup>th</sup> and the 7<sup>th</sup> intercostal ribs of the shaved right side, no sedation was required for the sheep. Pigs were intramuscularly sedated and positioned for the transducing process. All sheep in the community were submitted to US, except: piglets, pregnant or nursing females, as well as stallions or pigs destined for early human consumption. In the community, sheep and pigs are confined in small flocks inside semi-closed backyard areas where they had access to open feeding, and that were accessible to dogs, cats, and other small wilds animals.

Three local abattoirs in the community were identified; regular visits were undertaken, mainly during pig and sheep sacrifice in order to recover potential infected viscera. Before sacrifice, animals were submitted to US and afterwards, during viscera inspection, spleen, liver, and lungs were meticulously checked. Only 3 female pigs had CE during necropsy, but only in 1 case was the diagnosis previously established using US. However, it was not possible to recover any fluid cysts for DNA analysis.

### 5.4. Phylogenetic and population genetics analyses

All sequences obtained of 9 hydatid cysts and 3 by Copro-PCR, were subjected to BLAST search in the GenBank database; multiple alignments were performed with the CLUSTAL W [33] and MUSCLE [34] programs, with manual adjusted in MEGA program v5 [35]. The multiple alignments were used to determine the appropriate model of molecular evolution in the Modeltest 3.7 program [36]. The *coI* sequences for *E. granulosus* s.l. were analyzed with the General Time Reverse model, using gamma distribution (GTR+G). The phylogenetic reconstruction using Bayesian inference was performed with Mr Bayes 3.2.1 program [37-39]. Analysis was executed for 10 million generations; trees were sampled every 100 generations. Trees with scores lower than those at the stationary phase were discarded from the analysis, while those that reached the stationary phase were collected and used to build consensus trees. In addition, unrooted haplotype networks were created using NETWORK 4.611 software. These networks were nested according to the rules in Median-Joining networks [40], in which interior/tip status was considered a clade/haplotype and the ancestral haplotype had priority over missing haplotypes. An analysis of genetic diversity within and between populations was performed using DnaSPv4 [41] and included nucleotide diversity ( $\pi$ ), haplotype polymorphism ( $\theta$ ), expected heterozygosity ( $H_s$ ), genetic differentiation index ( $F_{ST}$ ), and Tajima's D test.

Up to 335 sequences for *coI* of *E. granulosus*, *E. canadensis*, *E. equinus*, *E. ortleppi*, *E. shiquicus* and *E. multilocularis* were analyzed, 68 haplotypes were found. GenBank has many more sequences of *E. granulosus* (232) than of other species,  $H_s$  and  $\pi$  values were lower than *E. canadensis* (Table 1). Also,  $\theta$  values were very small ( $\sim 0.3$  for *E. granulosus* and *E. canadensis* and  $< 0.01$  for other species), whilst Tajima's D test exhibited negative values. When we matched different *Echinococcus* species, the  $F_{ST}$  value was close to 1, suggesting a very high differentiation between species and corroborating the taxonomic status among these species (Table 2).



Species	N <sup>1</sup>	Haplotypes	$\pi^2$	$\theta^3$	Tajima's D
<i>E. granulosus</i> s.s.	232	31	0.0085	0.0423	-2.3523
<i>E. canadensis</i>	70	18	0.0118	0.0336	-2.1235
<i>E. shiquicus</i>	16	9	0.0054	0.0076	-1.0886
<i>E. equines</i>	10	6	0.0061	0.0075	-0.7831
<i>E. ortleppi</i>	3	2	0.0023	0.0022	ND <sup>4</sup>
<i>E. multilocularis</i>	4	2	0.0019	0.0015	ND

<sup>1</sup>N, number of sequences analyzed

<sup>2</sup> $\pi$ , nucleotide diversity

<sup>3</sup> $\theta$ , haplotype polymorphism

<sup>4</sup>ND, not determined

**Table 1.** Genetic polymorphism indexes among *Echinococcus* species obtained with the use of *col* GenBank sequences.

Population A (Species A)	Population B (Species B)	F <sub>ST</sub>
<i>E. canadensis</i>	<i>E. equinus</i>	0.8498
<i>E. canadensis</i>	<i>E. granulosus</i> s.s.	0.8243
<i>E. canadensis</i>	<i>E. ortleppi</i>	0.7023
<i>E. canadensis</i>	<i>E. shiquicus</i>	0.8578
<i>E. canadensis</i>	<i>E. multilocularis</i>	0.8840
<i>E. equinus</i>	<i>E. granulosus</i> s.s.	0.9156
<i>E. equinus</i>	<i>E. ortleppi</i>	0.9390
<i>E. equinus</i>	<i>E. shiquicus</i>	0.9198
<i>E. equinus</i>	<i>E. multilocularis</i>	0.9517
<i>E. granulosus</i> s.s.	<i>E. ortleppi</i>	0.9068
<i>E. granulosus</i> s.s.	<i>E. shiquicus</i>	0.9269
<i>E. granulosus</i> s.s.	<i>E. multilocularis</i>	0.9429
<i>E. ortleppi</i>	<i>E. shiquicus</i>	0.9455
<i>E. ortleppi</i>	<i>E. multilocularis</i>	0.9540
<i>E. shiquicus</i>	<i>E. multilocularis</i>	0.9557

F<sub>ST</sub>, genetic differentiation index

**Table 2.** Genetic differentiation index values between different paired sequences of *Echinococcus* species.

Sequences for *coI* of *E. canadensis* from Africa, Asia, Europe, and Latin and North America deposited in the GenBank databases (58), as well as our 12 sequences were analyzed (from KF734649 to KF734660, GenBank accession numbers). High identity (>98%) between Mexican, Peruvian, and Polish pig sequences was found. Globally, G6 was compared to G7 and to G8 and showed lower value of  $H_s$  (~0.26) and the pair between G6 and G7 exhibited the lowest value of  $F_{ST}$  (~0.10); the other genotypes had  $F_{ST} \geq 0.6$ . When G6 and G7 were separated by geographic area, the main pairs had  $F_{ST} \leq 0.1$ , except Europe vs. Africa. We did not find available sequences of G7 in humans, however, there are some sequences for G6 in humans from Africa (Mauritania) and Asia (China, Iran, Mongolia) that presented similar  $H_s$  and  $F_{ST}$  values as those sequences for G6 and G7 obtained from livestock (Table 3).

Population A	Population B	$H_s$ <sup>1</sup>	$F_{ST}$ <sup>2</sup>
G6	G7	0.2712	0.1018
G6	G8	0.2618	0.9169
G6	G10	0.3836	0.6339
G7	G8	0.5306	0.9198
G7	G10	0.5981	0.6484
G8	G10	0.6447	0.9030
Mexico (G7)	Europe <sup>3</sup> (G7)	0.8017	0.0988
Latin America <sup>4</sup> (G7)	Europe (G7)	0.7815	0.0938
Latin America (G7)	Africa <sup>5</sup> (G6)	0.5993	0.0773
Latin America (G7)	Asia <sup>6</sup> (G6)	0.6393	0.0773
Latin America (G7)	Africa-Asia <sup>7</sup> (G6)	0.8146	0.0542
Europe (G7)	Africa (G6)	0.2370	0.2
Europe (G7)	Asia (G6)	0.2666	0.2
Europe (G7)	Africa-Asia (G6)	0.5222	0.1142

<sup>1</sup> $H_s$ , expected heterozygosity within each population

<sup>2</sup> $F_{ST}$ , genetic differentiation index

<sup>3</sup>include sequences from Italy, Poland, and Rumania

<sup>4</sup>include sequences from Mexico and Peru

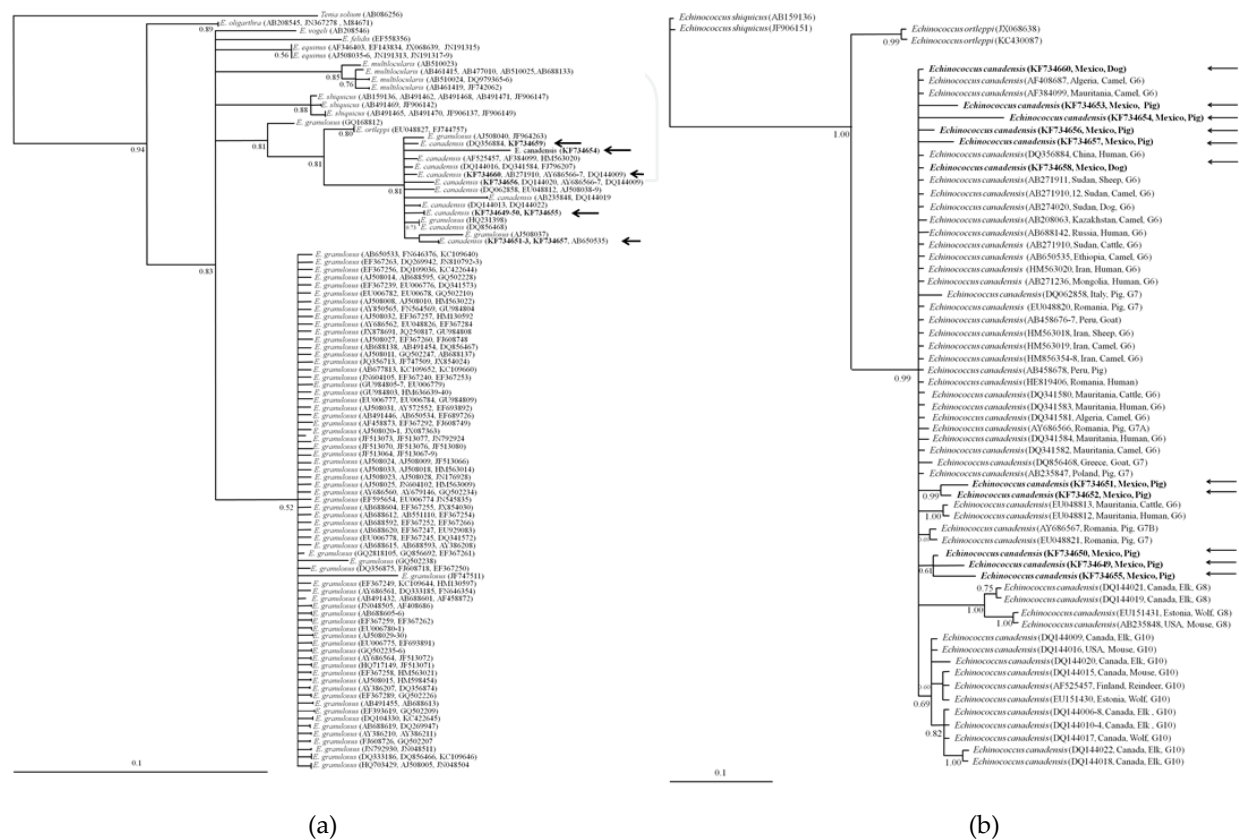
<sup>5</sup>include sequences from Algeria, Ethiopia, Mauritania, and Sudan

<sup>6</sup>include sequences from Iran and Kazakhstan

<sup>7</sup>include sequences of patients from China, Iran, Mauritania, Mongolia, and Russia

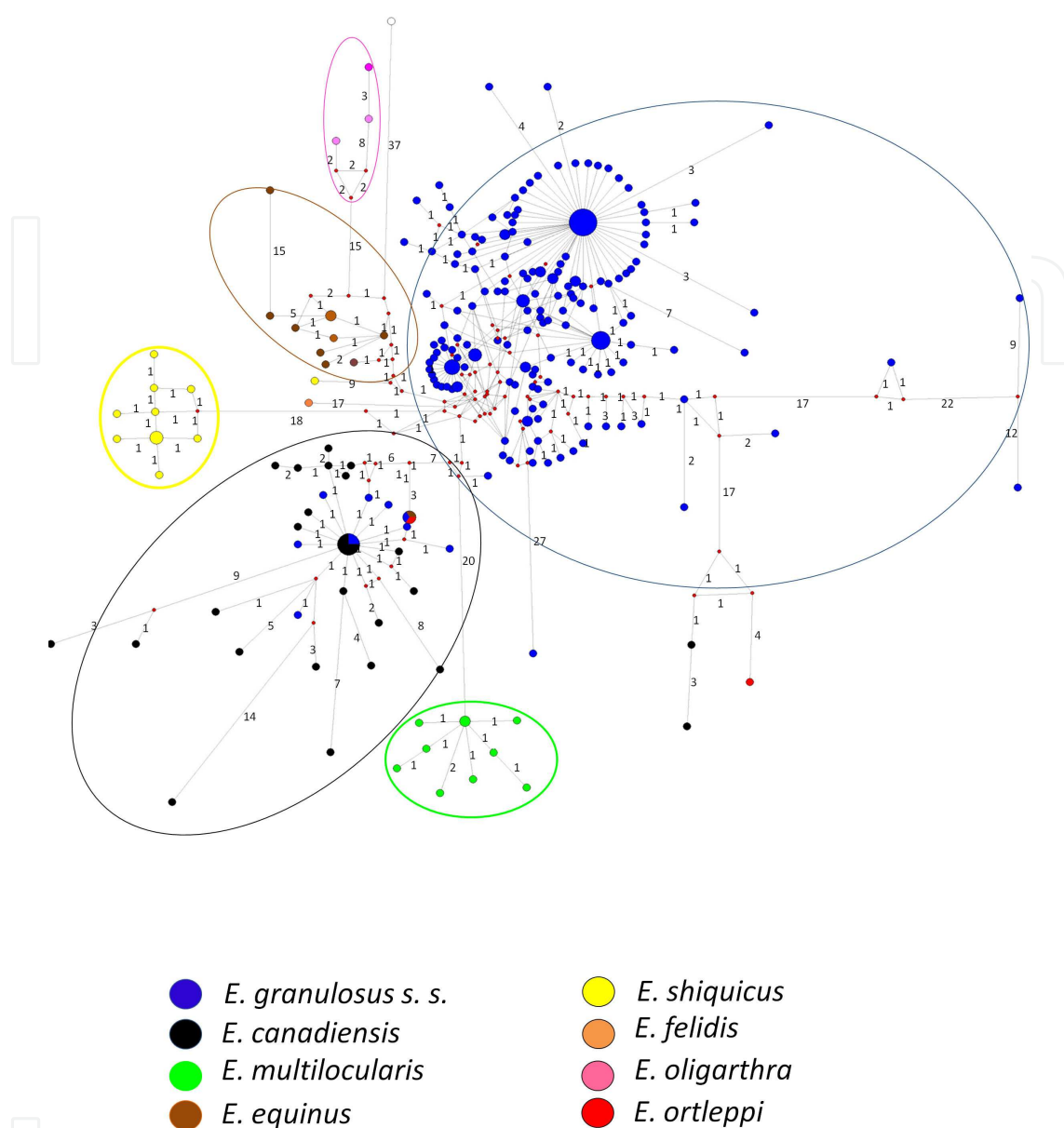
**Table 3.** Expected heterozygosity and genetic differentiation indexes between different paired sequences of *Echinococcus canadensis* genotypes obtained from animals.

Regarding the phylogenetic analyses, a Bayesian tree showed that all Mexican sequences obtained were grouped in the *E. canadensis* cluster with a value of 0.80 of posterior probability (Figure 7a), while a second Bayesian inference performed with only *E. canadensis* grouped to Mexican sequences with a G6 and G7 cluster from different reservoirs and different countries (Figure 7b).



**Figure 7.** Bayesian phylogenetic trees of *Echinococcus* species (a) and *Echinococcus canadensis* (b) using *col* sequences; Bayesian analysis with the *col* data; Values at nodes indicate the posterior percentage probabilities using 10 million generations. The Mexican sequences are identified by arrows.

The haplotype network inferences showed consistent results with the values of genetic differentiation previously obtained (Figure 8); some sequences of *E. granulosus* were placed in the *E. canadensis* clade, probably because at the time they were submitted to GenBank, their taxonomic status had not been fully established. However, clearly 6 clades can be identified that correspond to *E. granulosus*s.s., *E. multilocularis*, *E. canadensis*, *E. equinus*, *E. oligarthra*, and *E. shiquicus*. Other network trees, which were built only with sequences of *E. canadensis*, exhibited a similar distribution profile according to their host (Figure 9a) and origin country (Figure 9b). Thus, 3 clusters were identified: one for Canada, USA, Finland, Estonia, Mongolia, Kazakhstan with elk, wolf, and moose; the 2nd, for African, Asian, Latin-American, and European countries with camel, cattle, sheep, dog, pig, goat, and human and interestingly, the Mexican G7 haplotypes were placed around core dispersion center; finally, the 3rd cluster grouped other haplotypes G7 from Romania, Mauritania, and Peru and identified in pigs, humans, camels, and cattle.

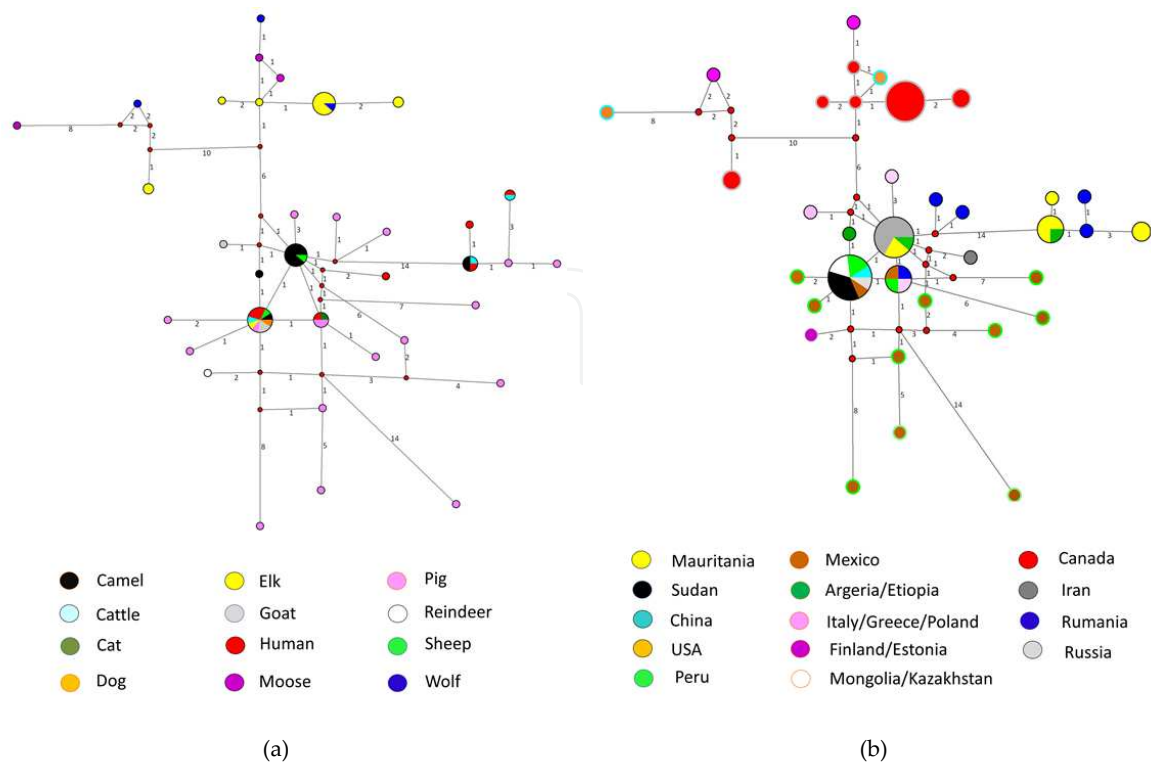


**Figure 8.** Median joining network of *Echinococcus* species using *col* sequences. Bigger sizes of circles represent higher frequency of each haplotype in each species. Numbers in branches refer to mutational changes.

### 5.5. What can we interpret about the population genetics study about *Echinococcus* in Mexico?

Current revisions accept 9 *Echinococcus* species based on clinical, molecular, epidemiological, and biological data, as well as characteristics of their host-parasite relationship: *E. granulosus* s.s., *E. felidis*, *E. multilocularis*, *E. shiquicus*, *E. equinus*, *E. oligarthra*, *E. vogeli*, *E. orteppi* and *E. canadensis* [5-7, 10]. Field and laboratory findings have revealed a significant phenotypic and genetic variability among isolates of *Echinococcus*, mainly for *E. granulosus* s.l. from different intermediate hosts. Recent phylogenetic studies based on both mitochondrial and nuclear DNA genes have showed that *E. granulosus* s.l. consists of 10 strains or genotypes (G1 to G10)





**Figure 9.** Median joining network trees of *Echinococcus canadensis* from different reservoirs (a) and countries (b), built using *col* sequences. Numbers in branches refer to mutational changes; sizes of circles are proportional to haplotype frequencies, thus, bigger circles represent ancestral haplotypes, small red circles represent missing haplotypes.

with at least 4 valid species: *E. granulosus* s.s. (G1-G3; sheep strains [G1 and G2] and buffalo strain [G3]), *Echinococcus equinus* (G4; horse strain), *Echinococcus ortleppi* (G5; cattle strain), and *Echinococcus canadensis* (G6-G10: camel strain [G6], pig strain [G7], cervid strains [G8 and G10] and human strain [G9, under a controversial status]) [4, 5, 42, 43]. Nonetheless, the species status of *E. canadensis* is still controversial [4-8, 11, 44], because few biological differences have been identified among all strains (from G6 to G10) proposing them as a single species. However, ecological and geographical differences between camel and pig strains to cervid strains show clear differences, suggesting a diversification process. In this way, some authors have suggested that G6 and G7 should be treated as a single species designated as *E. intermedius* [4, 8, 11], and even G8 as *E. borealis* and G10 as *E. canadensis* have also been proposed [8]. In contrast, Nakao et al. [6, 7, 45], advise that G6 to G10 should be retained by the specific name *E. canadensis*, pending further population genetic studies, using particularly nuclear DNA markers to clarify the status of the taxon.

A contrasting phenomenon is observed for CE by *E. canadensis* (G7) in humans, because the pig strain is the main genotype identified in patients from Eastern and Southeastern European countries [46, 47]. There are few human cases of CE reported in Mexican patients, although none by G7 has been identified by molecular techniques. There are only 2 genetic studies performed in samples of CE from Mexico; Cruz-Reyes et al. [11] documented that G7 parasites of Mexican and Polish pig isolates showed similar patterns by RFLP of rDNA ITS1 and RAPD techniques, although PCR-sequencing analysis of mitochondrial *col* gen fragment was

performed, no polymorphism data were reported. Saarma et al. [48] identified 2 variants (A, B) inside of G6/G7 group consisting of samples from Mexico and Argentina, using 5 nuclear markers (elongation factor 1 alpha, transforming growth factor beta receptor kinase, thioredoxin peroxidase, calreticulin, and ezrin-radixin-moesin-like protein).

In general, the genetic population parameters reported by Rodriguez-Prado et al. [16] were similar to those reported by Haag et al. [49], who using mitochondrial (*nad*) and nuclear (*ActII*, *Hbx2*, *AgB*) sequences of *Echinococcus*, found  $\pi=0.0005$  for *E. multilocularis*, and  $\pi=0.0090$  for *E. granulosus*. In addition, a study focused in the genetic diversity of *Echinococcus granulosus* s.s. hydatid cysts from 4 European countries (Bulgaria, Hungary, Romania, and Italy) evaluated by DNA sequence analysis of the *coI*, showed  $F_{ST}$  values that ranged from 0.018 to 0.187 with higher negative values for Tajima's D that ranged from -0.515 to -1.066 [50]. Analyzing Mexican and other sequences, it was observed that among *E. canadensis* populations, they have a moderate differentiation ( $F_{ST} \sim 0.1$ ), while the other genotypes of *E. canadensis* exhibited a high differentiation among them ( $F_{ST} > 0.6$ ). When G6 and G7 were divided in geographic areas, similar genetic differentiation was observed with  $F_{ST} < 0.1$ , except when Europe (G7) was matched with Africa or Asia ( $F_{ST}=0.2$ ). However, in both cases, this phenomenon could be interpreted as a moderate genetic differentiation within these populations. Also, we found negative values for Tajima's D, similarly to Casulli et al. [50] data, indicating that a size expansion due to a bottleneck event might have occurred in the past.

Based in the network analyses and according to Rodriguez-Prado et al. [16], the following inferences can be done: 1) *E. canadensis* in Mexico is very diverse and has probably been introduced from abroad several times from different sources because 6 Mexican isolates have from 4 to 14 mutational changes between the isolate and the main haplotype; 2) haplotypes grouped in the North American wildlife cluster (G10) are closer within them, with 1 or 2 mutational changes and they are placed far of the Mexican isolates, thus they might be ruled out as sources of introduction to Mexico; 3) differentiation between G6 and G7 would not make any sense based on the differentiation of genetic indexes found for both genotypes ( $F_{ST}$  close to 0.1), besides one of the main ancestral dispersion centers in the network analysis, clustered identical haplotypes of G6 and G7 from China, Mexico, Peru, Sudan, and Russia.

## 6. Final remarks

The first human CE case identified by molecular techniques was reported in 2006 in the United Kingdom (UK) in a male with clinical and CT scan images consistent with CE that was surgically treated for the removal of a hydatid cyst, which was subsequently confirmed as *E. granulosus* G1 [51]. This case was similar to the Mexican one: it was unexpected and wrongly diagnosed for a long time. Also in the UK, recent *Echinococcus* isolates from intermediate and definitive animal hosts, as well as from human CE cases were analyzed to determine species and genotypes within these hosts. *E. equinus* was identified from horse hydatid isolates, while *E. granulosus* s.s. was identified from hydatid cysts of sheep and cattle, as well as in DNA extracted from a farm dog, foxhound fecal samples, and from human cystic echinococcosis isolates. Low genetic variability for *E. equinus* using *coI* sequences ( $\pi=0.000666\pm0.000620$ ) indicates the presence of a dominant haplotype; in contrast, greater haplotypic variation was

observed for *E. granulosus* s.s. ( $\pi=0.000955\pm0.000790$ ). Furthermore, a haplotype phylogenetic inference showed a star-shaped network with a centrally placed main haplotype that was reported from other world regions [52].

Four new cases of CE in Mexican patients were reported since 2009, a 38-year-old female from the State of Mexico, who was submitted to surgery to remove a liver cyst [53]; 2 cases referred to a tertiary-care oncology hospital with an initial diagnosis of liver and lung cancer, respectively. The liver cyst case was resolved with percutaneous drainage and administration of albendazole for 2 months, while the lung cyst was resolved solely with 2 months of albendazole [54]. The last case was a 16-year-old female from the state of Puebla, Mexico with a liver cyst that was surgically removed [55]. Unfortunately, in all cases, molecular assays were not performed so identification of *Echinococcus* strains was not possible.

## 7. Conclusion

We wish to finalize this chapter by pointing out that the correct diagnosis and adequate management of the initial case, the subsequent epidemiological follow-up of human echinococcosis at a community level in Mexico and the in-depth genetic study of the parasite, integrate a comprehensive and unique study of *Echinococcus granulosus*, s.l. and support the very low frequency of this disease in Mexico.

Although no data on cystic echinococcosis caused by *E. canadensis* G7 have previously been documented in Mexican patients, the high number of infected patients in central Europe by the G7 genotype, points to the potential public health importance of this strain or species, as well as the necessity to perform molecular and epidemiological studies focused to clarify this contrasting situation and the controversial taxonomic status of *E. canadensis* species.

## Author details

Ana Flisser<sup>1\*</sup>, Pablo Maravilla<sup>2</sup>, Pilar Mata-Miranda<sup>3</sup> and Fernando Martinez-Hernandez<sup>2</sup>

\*Address all correspondence to: flisser@unam.mx

1 Departamento de Microbiología y Parasitología, Facultad de Medicina, Universidad Nacional Autónoma de México, DF, México

2 Departamento de Ecología de Agentes Patógenos, Hospital General "Dr. Manuel Gea González", Secretaría de Salud, DF, México

3 Coordinación Auxiliar de Investigación en Salud, Delegación Veracruz Norte, Xalapa, Veracruz, México

## References

- [1] Eckert J, Gemmell MA, Meslin FX, Pawlowski ZS, editors. WHO/OIE Manual on echinococcosis in humans and animals: A public health problem of global concern. World Organization for Animal Health and World Health Organization. Paris, France. 2001;265.
- [2] Flisser A, Craig PS. Larval cestodes. In: Cox FEG, Wakelin D, Gillespie SH, Despommier DD, editors. Topley & Wilson's microbiology and microbial infections. 10th ed. Arnold, London. 2005;5:677-712.
- [3] Mata-Miranda P, Osnaya-Palma I, Rodríguez-Prado U, Gutiérrez-Marín A, Tawil M, Hernández-González S, Solano-Ceh M, Villalvaso L, Martínez-Maya JJ, Maravilla P, García-de-la-Torre, G, Flisser A. Epidemiologic and ultrasonographic study of echinococcosis in a community in the State of Mexico. *Am J Trop Med Hyg.* 2007;77:500-555.
- [4] Thompson RC. The taxonomy, phylogeny and transmission of *Echinococcus*. *Exp Parasitol.* 2008;119:439-446.
- [5] McManus DP. Current status of the genetics and molecular taxonomy of *Echinococcus* species. *Parasitology.* 2013;11:1-7.
- [6] Nakao M, Yanagida T, Konyaev S, Lavikainen A, Odnokurtsev VA, et al. Mitochondrial phylogeny of the genus *Echinococcus* (Cestoda: Taeniidae) with emphasis on relationships among *Echinococcus canadensis* genotypes. *Parasitology.* 2013;140:1595-1601.
- [7] Nakao M, Lavikainen A, Yanagida T, Ito A. Phylogenetic systematics of the genus *Echinococcus* (Cestoda: Taeniidae). *Int J Parasitol.* 2013;43:1017-1029.
- [8] Lymbery AJ, Jenkins EJ, Schurer JM, Thompson RC. *Echinococcus canadensis*, *E. borealis*, and *E. intermedius*. What's in a name?. *Trends Parasitol.* 2015;31:23-29.
- [9] Martínez-Maya JJ, Zuñiga A, Jaramillo A, Cardenas L, Navarro F. Caracterización epidemiológica de la equinococosis/hidatidosis en Zacatecas, Mexico. *Vet Mex.* 1994;25:231-237.
- [10] Schantz PM, Chai J, Craig PS, Eckert J, Jenkins DJ, et al. Epidemiology and control of hydatid disease. In: Thompson RCA, Lymbery AJ editors. *Echinococcus* and hydatid disease. Wallingford, Oxon, UK: CAB International. 1995:233-331.
- [11] Cruz-Reyes A, Constantine CC, Boxell AC, Hobbs RP, Thompson RC. *Echinococcus granulosus* from Mexican pigs is the same strain as that in Polish pigs. *J Helminthol.* 2007;81:287-292.



- [12] Salinas-Lopez N, Jimenez-Guzman F, Cruz-Reyes A: Presence of *Echinococcus oligarthrus* (Diesing, 1863) Lühe, 1910 in *Lynx rufus texensis* Allen, 1895 from San Fernando, Tamaulipas state, in North-east Mexico. *Int J Parasitol.* 1996;26:793-796.
- [13] Villalobos N, González LM, Morales J, de Aluja AS, Jiménez MI, et al. Molecular identification of *Echinococcus granulosus* genotypes (G1 and G7) isolated from pigs in Mexico. *Vet Parasitol.* 2007;147:185-189.
- [14] Maravilla P, Thompson RCA, Palacios-Ruiz JA, Estcourt A, Ramirez-Solis E, et al. *Echinococcus granulosus* cattle strain identification in an autochthonous case of cystic echinococcosis in central Mexico. *Acta Trop.* 2004;92:231-236.
- [15] Rodriguez-Prado U, Gutiérrez-Marín A, Martínez-Ocaña J, Romero-Valdovinos M, Olivo-Díaz A, Hernández-Castro R, Flisser A, Maravilla P, Martínez-Maya JJ. Estudio coprológico y ultrasonográfico en perros y borregos de una comunidad suburbana en el Estado de México para la búsqueda de *Echinococcus spp.* *Vet Mex.* 2014;Supp:53-58.
- [16] Rodriguez-Prado U, Jimenez-Gonzalez DE, Avila G, Gonzalez AE, Martinez-Flores WA, Mondragon de la Peña C, Hernandez-Castro R, Romero-Valdovinos M, Flisser A, Martinez-Hernandez F, Maravilla P, Martinez-Maya JJ: Genetic variation of *Echinococcus canadensis* (G7) in Mexico. *Am J Trop Med Hyg.* 2014;91:1149-1153. doi: 10.4269/ajtmh.14-0317.
- [17] Ceruzzi O, Osimani JJ, Botto C, Rodríguez N, Cabrera R. Algunos factores a considerar en la evaluación de la intradermorreacción de Casoni para hidatidosis. *Bol Chile Parasitol.* 1976;31:50.
- [18] Alper A, Emre A, Hazar H, Özden I, Bilge O, Acarli K, Ariogul O. Laparoscopic surgery of hepatic hydatid disease: Initial results and early follow-up of 16 patients. *World J Surg* 1995;19:725.
- [19] Khoury G, Jabbour-Khoury S, Bikhazi K. Results of laparoscopic treatment of hydatid cyst of the liver. *Surg Endosc.* 1996;10:57.
- [20] Saglam A. Laparoscopic treatment of liver hydatid cysts. *Surg Laparosc Endosc.* 1996;6:16.
- [21] Sayek I, Onat D. Diagnosis and treatment of uncomplicated hydatid cyst of the liver. *World J Surg.* 2001;25:21.
- [22] Maddison SE, Slemenda SB, Schantz PM, Fried JA, Wilson M, Tsang VCW. A specific diagnostic antigen of *Echinococcus granulosus* with an apparent molecular weight of 8 KDa. *Am J Trp Med Hyg.* 1989;40:377-383.
- [23] Palacios JA, Ramírez-Solis ME, Cárdenas-Mejía A, Maravilla P, Flisser A. Hypertonic saline in hydatid disease. *World J Surg.* 2002;26:1398.

- [24] Palacios-Ruíz JA, Ramírez-Solís E, Moreno-Moller M, Cárdenas-Mejía A, Mata-Miranda P, Maravilla P, Flisser A. Identificación y manejo integral de un caso autóctono de hidatidosis en México. *Rev Mex Gastroenterol.* 2003;68:41-45.
- [25] Bowles J, Van Knapen F, McManus DP. Cattle strain of *Echinococcus granulosus* and human infection. *Lancet.*1992;39:1358.
- [26] Scott, JC, McManus, DP. The random amplification of polymorphic DNA can discriminate species and strains of *Echinococcus*. *Trop. Med. Parasitol.* 1994;45.
- [27] Blancas Mosqueda M, Herrera Esparza R, Rodríguez Padilla C, Tavizón García JP, Mercado Reyes M, et al. Gender as a factor of susceptibility to infection in experimental hydatidosis. *Rev Latinoam Microbiol.* 2007;49:31-37.
- [28] Moro P, Schantz PM. Echinococcosis: A review. *Int J Infect Dis.* 2009;13:125-133.
- [29] Bowles J, McManus DP. Genetic characterization of the Asian *Taenia*, a newly described taeniid cestode of humans. *Am J Trop Med Hyg.* 1994;50:33-44.
- [30] Faust EC, Sawitz W, Tobie J, Odom V, Peres C, Lincicome DR. Comparative efficiency of various techniques for the diagnosis of protozoa and helminth in feces. *J Parasitol.* 1939;25:241-261.
- [31] Allan JC, Craig PS, Garcia Noval J, Mencos F, Liu D, et al. Coproantigen detection for immunodiagnosis of echinococcosis and taeniasis in dogs and humans. *Parasitology.* 1992;104:347-356.
- [32] Moro PL, Lopera L, Bonifacio N, Gonzales A, Gilman RH, et al. Risk factors for canine echinococcosis in an endemic area of Peru. *Vet Parasitol.* 2005;130:99-104.
- [33] Thompson JD, Higgins DG, Gibson TJ, Clustal W. Improving the sensitivity and progressive multiple sequence alignment through sequence weighting, positions-specific gap penalties and weight matrix choice. *Nucleic Acids Res.* 1994;22:4673-4680.
- [34] Edgar RC. MUSCLE: multiple sequence alignment with high accuracy and high throughput. *Nucleic Acids Res.* 2004;32:1792-1797.
- [35] Tamura K, Peterson D, Peterson N, Stecher G, Nei M, et al. MEGA5: Molecular Evolutionary Genetics Analysis using maximum likelihood, evolutionary distance, and maximum parsimony methods. *Mol Biol Evol.* 2011;28:2731-2739.
- [36] Posada D, Crandall KA. Modeltest: testing the model of DNA substitution. *Bioinformatics.*1998;14:817-818.
- [37] Huelsenbeck JP, Ronquist F, Nielsen R, Bollback JP. Bayesian inference of phylogeny and its impact on evolutionary biology. *Science.* 2001;14:2310-2314.
- [38] Holder M, Lewis PO. Phylogeny estimation: traditional and Bayesian approaches. *Nat Rev Genet.* 2003;4:275-284.

- [39] Ronquis F, Huelsenbeck JP. MrBayes 3: Bayesian phylogenetic inference under mixed models. *Bioinformatics*. 2003;19:1572-1574.
- [40] Bandelt HJ, Forster P, Röhl A. Median-joining networks for inferring intraspecific phylogenies. *Mol Biol Evol*. 1999;16:37-48.
- [41] Rozas J, Sanchez-Del Barrio JC, Messeguer X, Rozas R. DNA sequence Polymorphism (DNAsp) ver. 4.10.9. Departamento de Genetica, Universidad de Barcelona. 2006.
- [42] Thompson RC, McManus DP. Towards a taxonomic revision of the genus *Echinococcus*. *Trends Parasitol*. 2002;18:452-457.
- [43] Alvarez Rojas CA, Romig T, Lightowlers MW. *Echinococcus granulosus* sensu lato genotypes infecting humans—Review of current knowledge. *Int J Parasitol*. 2014;44:9-18.
- [44] Yanagida T, Mohammadzadeh T, Kamhawi S, Nakao M, Sadjjadi SM, et al. Genetic polymorphisms of *Echinococcus granulosus* sensu stricto in the Middle East. *Parasitol Int*. 2012;61:599-603.
- [45] Nakao M, McManus DP, Schantz PM, Craig PS, Ito A. A molecular phylogeny of the genus *Echinococcus* inferred from complete mitochondrial genomes. *Parasitology*. 2007;134(Pt 5):713-722.
- [46] Schneider R, Gollackner B, Schindl M, Tucek G, Auer H. *Echinococcus canadensis* G7 (pig strain): An underestimated cause of cystic echinococcosis in Austria. *Am J Trop Med Hyg*. 2010;82:871-874.
- [47] Dybicz M, Gierczak A, Dąbrowska J, Rdzanek Ł, Michałowicz B. Molecular diagnosis of cystic echinococcosis in humans from central Poland. *Parasitol Int*. 2013;62:364-367.
- [48] Saarma U, Jõgisalu I, Moks E, Varcasia A, Lavikainen A, Oksanen A, Simsek S, Andresiuk V, Denegri G, González LM, Ferrer E, Gárate T, Rinaldi L, Maravilla P. A novel phylogeny for the genus *Echinococcus*, based on nuclear data, challenges relationships based on mitochondrial evidence. *Parasitology*. 2009;136:317-28.
- [49] Haag KL, Zaha A, Araújo AM, Gottstein B. Reduced genetic variability within coding and non-coding regions of the *Echinococcus multilocularis* genome. *Parasitology*. 1997;115:521-529.
- [50] Casulli A, Interisano M, Sreter T, Chitimia L, Kirkova Z, La Rosa G, Pozio E. Genetic variability of *Echinococcus granulosus* sensu stricto in Europe inferred by mitochondrial DNA sequences. *Infect Genet Evol*. 2012;12:377-383.
- [51] Craig PS, Woods ML, Boufana B, O'Loughlin B, Gimpel J, San Lett W, Mcmanus DP. Cystic echinococcosis in a fox-hound hunt worker, UK. *Pathogens and Global Health*. 2012;106:373-375.
- [52] Boufana B, Lett WS, Lahmar S, Buishi I, Bodell AJ, Varcasia A, Casulli A, Beeching NJ, Campbell F, Terlizzo M, McManus DP, Craig PS. *Echinococcus equinus* and *Echino-*

*coccus granulosus* sensu stricto from the United Kingdom: Genetic diversity and haplotypic variation. Int J Parasitol. 2015;45:161-6. doi: 10.1016/j.ijpara.2014.10.005.

- [53] Steta J, Torre A. Mexican-native human echinococcosis: Case report of an underestimated disease. Ann Hepatol. 2009;8:251-254.
- [54] Cornejo-Juárez P, Espinosa-Altamirano A, Ibarra-del-Río M, Pacheco-Bravo I, Volkow-Fernández P. Cystic echinococcosis: A disease mimicking cancer in a non-endemic country report of two cases. West Indian Med J. 2013;62:266-269.
- [55] Orea-Martínez JG, Pérez-Corro MA, Contreras-Vera RA, Bretón-Márquez JH. A case of hydatid cyst caused by *Echinococcus granulosus* in Puebla, Mexico, that resulted in successful surgical treatment. Rev Gastroenterol Mex. 2013;78:116-119. doi: 10.1016/j.rgmx.2012.10.007.



