

We are IntechOpen, the world's leading publisher of Open Access books Built by scientists, for scientists

6,900

Open access books available

185,000

International authors and editors

200M

Downloads

Our authors are among the

154

Countries delivered to

TOP 1%

most cited scientists

12.2%

Contributors from top 500 universities



WEB OF SCIENCE™

Selection of our books indexed in the Book Citation Index
in Web of Science™ Core Collection (BKCI)

Interested in publishing with us?
Contact book.department@intechopen.com

Numbers displayed above are based on latest data collected.
For more information visit www.intechopen.com



Artery Embolization of Uterine Fibroids as Alternative to Hysterectomy

Chrisostomos Sofoudis

Additional information is available at the end of the chapter

<http://dx.doi.org/10.5772/60473>

Abstract

Uterine artery embolization (UAE) was presented as a treatment for symptomatic uterine fibroids in the early of 1990s, after initially being used as a temporary surgical procedure before the performance of hysterectomy or myomectomy. Although the existence of intraoperative complications is associated with overall survival, plenty of these complications can be prevented. Until recently, surgical management represents the treatment of choice regarding the uterine fibroids. With the arrival of UAE, the percentage of major complications such as intraoperative bleeding, adhesions and ureteral injury is decreasing. The ultimate scope of the problem remains the proper management accompanied by knowledge and experience.

Keywords: Uterine embolization, fibroids, hysterectomy

1. Introduction

1.1. Uterine fibroids

Uterine fibroids are very common, non-cancerous (benign) growths that develop in the muscular wall of the uterus. Other names for fibroids include Leiomyoma, Leiomyomata, Fibromyomas, Fibromas, Myofibromas, and Myomas. They are composed of smooth muscle and connective tissue developing and enhancing the uterus wall. They can present in a very wide range of sizes, from small to enlarged myomas. Africans, in comparison with Caucasians, are three times more prone to uterine fibroids formation. They account for one third of all hysterectomies performed in the United States —approximately 100,000 procedures every

year. Due to their enlarged size, fibroids deform the abdominal cavity. In most cases, more than one are detected inside the peritoneal wall.

Due to their location, uterine fibroids can be classified into the following categories:

- a. **Submucosal fibroids.** Fibroids that grow into the inner cavity of the uterus (submucosal fibroids) are more likely to cause prolonged, heavy menstrual bleeding and infertility problems for women trying to achieve a pregnancy.
- b. **Subserosal fibroids.** Fibroids that project to the outside of the uterus (subserosal fibroids) can sometimes press on the bladder, causing urinary symptoms. If fibroids bulge from the back of the uterus, they occasionally can press into either the rectum, causing a pressure sensation, or the spinal nerves, causing backache.
- c. **Intramural fibroids.** Some fibroids grow within the muscular uterine wall (intramural fibroids). If they are large enough, they can distort the shape of the uterus and cause prolonged, heavy menstrual cycles, as well as pain and pressure.

According to the size, the symptomatology can vary from pressure to abdominal pain and signs of peritoneal obstruction. Vaginal bleeding accompanied with episodes of metrorrhagia, especially in premenopausal women could disturb their daily activities and their quality of life. Other symptoms comprise heavy, prolonged menstrual periods and unusual monthly bleeding, sometimes with clots; this medical situation could lead to anaemia. Fibroids' existence may also be detected via pain in the back and legs, pain during sexual intercourse, bladder pressure leading to a frequent urge to urinate, and pressure on the bowel, leading to constipation and bloating.

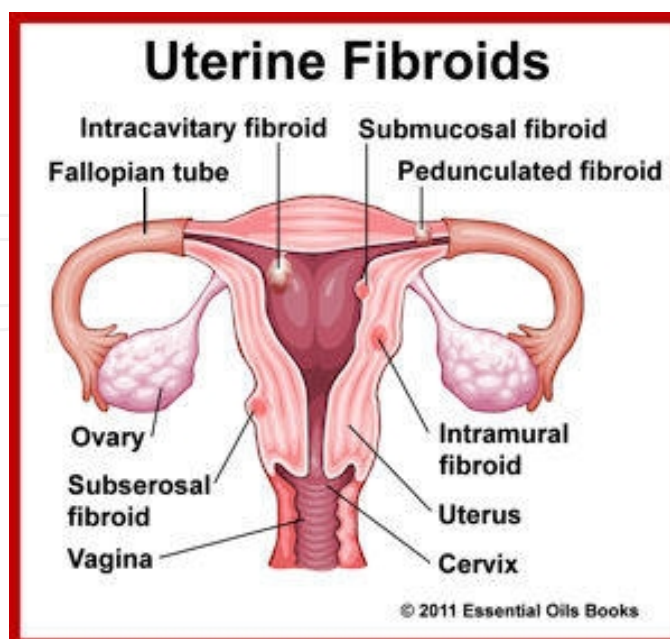


Figure 1. Classification of uterine fibroids (2011 Essential Oils Books.)

2. Diagnostic procedures

The diagnosis of uterine fibroids could be made via the taking of a detailed medical history, an assiduous physical examination, and proper imaging techniques. The anamnesis history may also include details such as the age of the patient, possible anomalies of the menstrual cycle, episodes of abdominal pain, and urgent pressure resulting from incontinence. Information on factors such as episodes of metrorrhagia and diffuse vaginal bleeding could produce a successful diagnosis. The role of transvaginal ultrasonography in diagnosis is unquestionable.

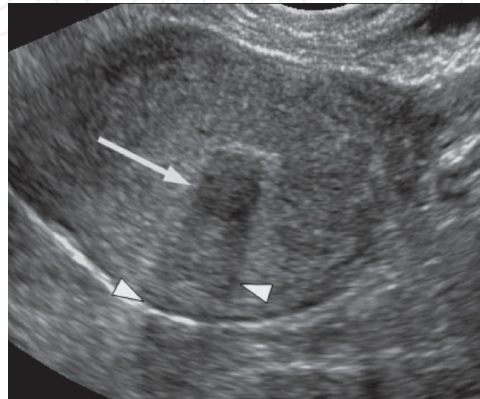


Figure 2. Ultrasonographic depiction of uterine fibroid.(Arrow). Wilde Sue and Scott-Barrett Sarah. Radiological appearances of uterine fibroids. Indian J Radiol Imaging. Aug 2009; 19(3): 222–231.

Uterine fibroids appear as well-defined solid masses with a similar echogenicity to the myometrium. They can deform the uterus' contour, resulting in a bulky formation. Submucous fibroids could be easily differentiated from the endometrium layer but not so easily from endometrial polyps. CT examination might not prefer to choose imaging regarding the diagnosis of pelvic masses. In many cases, uterine myomas reflect a bulky, deformed uterus or a mass in continuity with the uterus.

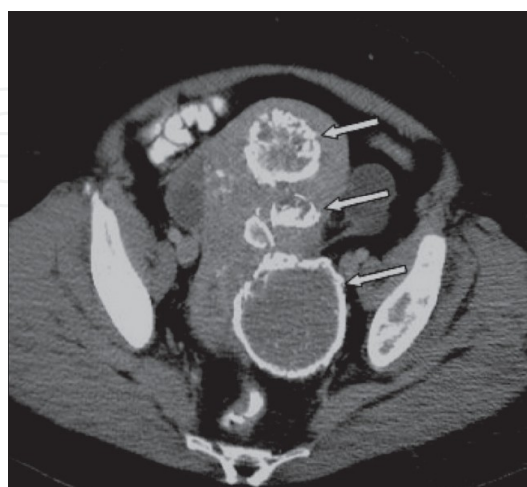


Figure 3. CT scan showing multiple uterine fibroids.(Arrows). Wilde Sue and Scott-Barrett Sarah. Radiological appearances of uterine fibroids. Indian J Radiol Imaging. Aug 2009; 19(3): 222–231.

The sensitivity and specificity of the MRI reflect on the accurate preoperative diagnosis of uterine myomas. The imaging findings consist of an excellent delineation of both internal and external uterine contours, measurement accuracy of intercornual diameter, visualization improvement of the endometrial architecture, and identification of uterine horns.

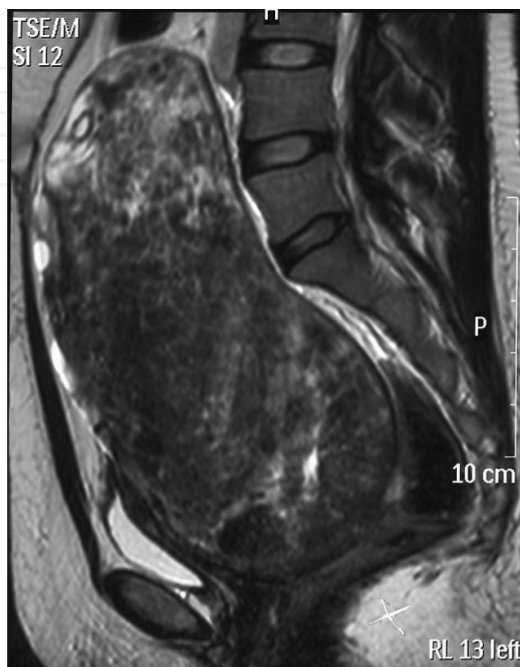

Figure 4. Sagittal T2 weighted MR image showing a large fibroid mass extending to upper endplate of lumbar spine. Madhuri TK, Kamran W, Walker W, Butler-Manuel S. Synchronous *uterine* artery embolization and laparoscopic myomectomy for massive *uterine* leiomyomas. JSLS.2010 Jan-Mar;14(1):120- 2.

3. Management options

Leiomyomas may develop in the myometrium cavity, occasionally in the cervix, broad ligament, and ovaries. Most frequently, they develop in the myometrial wall and could lead to uterine distortion. The treatment of choice consists of surgical or laparoscopic myomectomy avoiding all the intra- or postoperative complications. The advantages regarding laparoscopic myomectomy involve less blood loss, shorter hospital stays, and fewer intraoperative complications. The technical skill required for the excision of myoma and a lack of surgical experience are considered significant limiting factors to the wide acceptance of this technique.

Factors such as diffuse abdominal bleeding, adhesions, and multiple and enlarged myomas contraindicate the use of laparoscopic management. In cases of episodes of vaginal bleeding accompanied with abdominal pain, constipation, and ureter obstruction, the choice of a hysterectomy seems mandatory. Among all the intraoperative complications, the necessity of the treatment of the fibroid bleeding appears to be paramount. Specific research takes place

continuously regarding the development of an ideal, minimally invasive method, trying to reach the goals of a treatment that is safe and tolerated well. Plenty of surgical or non-surgical methods have been performed, such as laparoscopic uterine ligation, myomectomy, and high-intensity, focused ultrasound. The arrival of uterine artery embolization (UAE) has changed all the therapeutical options. No limitations appear regarding the fibroids' size and number that can be treated with UAE.

4. Uterine arteries embolization

4.1. Basic principles

The embolization of uterine fibroids arteries represents a minimally invasive procedure as far as the treatment of uterine fibroids is concerned. Indications of uterine artery embolization are the following:

- Trauma
- Malignant gynaecological tumours
- Post-labour bleeding
- Bleeding following gynaecological surgery

This specific technique manages to be extended during the last two years enhancing the management of arterial venous malformations of the genital tract and gestational trophoblastic disease. The limitations of uterine fibroid embolization (UFE) are many, and subsume women with no symptomatology regarding their condition, existence of cancer, or pelvic infection. Women with a known allergy to contrast materials should undergo preoperative treatment or follow a different treatment option. The gold standard is based on fibroid reduction by obstructing its vessels with embolic elements during the catheterization of uterine arteries. Through this procedure, a successful devascularization and prolonged quality of life can be achieved. The fibroid shrinkage may cause a significant decrease of all intra- or postoperative complications.

4.2. Equipment

Before the performance of the procedure, it is mandatory to perform a preoperative depiction of the uterine cavity, certifying that uterine fibroids are the main cause of the uterine bleeding, and the number, the size, and the location of uterine myomas. The appropriate information should consist of many details, such as gestational status, known allergies, reception of medications such as NSAIDs, and known medical status. The necessary equipment is the following:

- X-ray equipment
- Catheter

- Embolic material

The presence of fluoroscopy for the transformation of the X-rays into video depictions is obligatory. The catheter encloses a long plastic tube approximately 1/8 of the catheter in diameter. The necessary embolic agents are the following:

- Calibrated microspheres of 500, 700, and 900 μm , alone or in combination
- Gelfoam, a gelatine sponge material

All the mentioned substances certify the safety and effectiveness of the procedure regarding the uterine fibroid embolization. In conclusion, the necessity of an intravenous line and the monitoring of heartbeat and blood pressure should always be stressed. During the procedure, all the security instructions should be followed, achieving the prevention of all possible intraoperative complications.

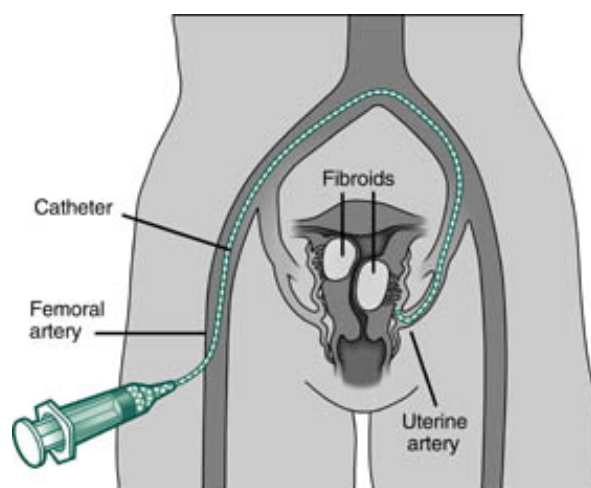


Figure 5. Procedure of uterine fibroid embolization (Medscape)

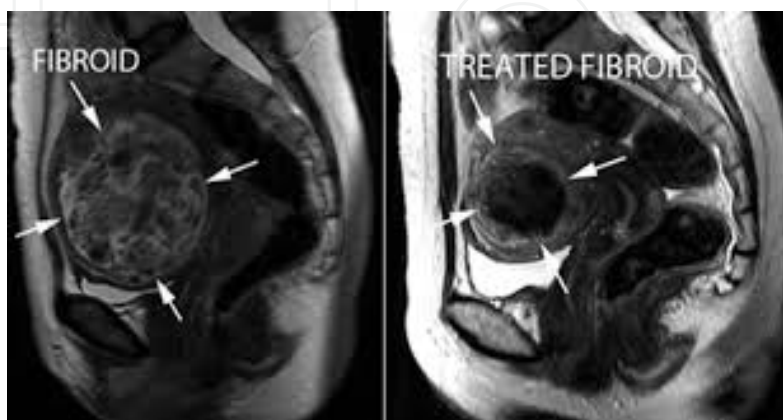
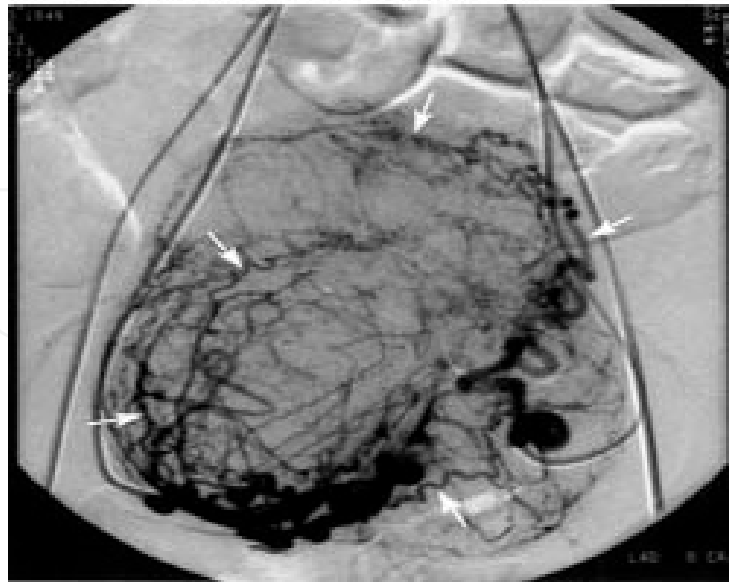


Figure 6. Left: A large fibroid is seen in the uterus (arrows). Right: Four months following uterine fibroid embolization, the fibroid has substantially decreased. (Fibroid.png)

Pre-embolization angiogram



Post-embolization angiogram

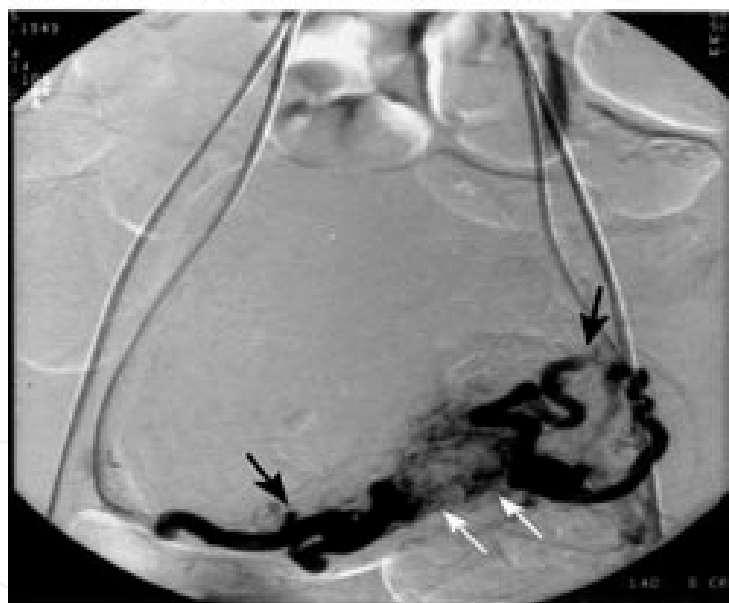

Figure 7. Uterine arteries embolization. Pre- and Post-embolization angiogram.(Georgetown University Hospital-Division of Vascular and International Radiology)

4.3. Procedure

Transcatheter arterial embolization represents an alternative type of hysterectomy regarding the treatment of symptomatic uterine myomas. By the time the embolic agents are injected inside the uterine arteries, they can reach the entire arterial central branch, including the arterial in- and outflow. The successful collateral blood supply provides arterial flow, prohib-

iting the ischemic establishment of the area. The impact of the embolic agents could produce conditions of shrinkage throughout the uterine fibroids. This ischemic devascularization prohibits intraoperative bleeding and the following hysterectomy. The success rate depends on the skills and the expertise of the surgeon.

Additionally, blood pressure monitoring, oxygen flow, and available sedatives in case of pain during the injection appear necessary. The next step reflects the transformation of the X-ray guidance into video depiction. At the end of the procedure, the transarterial catheter is removed and a haemostasis of the area is achieved by applying local pressure. The majority of the women on whom this procedure was performed declared that they were satisfied: an average of 50%. The ultimate goal depends on the fertility rate regarding nulliparous premenopausal women. For women who are interested in future fertility, a myomectomy seem to be a suitable choice. In general, uterine fibroid embolization seems to be a safe procedure in correlation with all intraoperative instructions, minimizing all intra- or postoperative complications.

4.4. Complications

During the procedure of uterine arteries embolization concerning the treatment of uterine fibroids, many intra- or postoperative complications could emerge. The complication rate depends, as mentioned, on the skill and expertise of the surgeon. Infection, local bleeding, or local hematoma represent the earliest postoperative complications.

Allergic reactions or spasms of the uterine arteries with the after-effect of pain, due to contrast medium and local ischemia, can be treated with vasodilator agents or micro-catheter techniques. The intraoperative abdominal pain in terms of the local ischemia responds to NSAIDs. Postoperative infection followed in many cases, as local or diffuse sepsis caused by endometritis or tubo-ovarian abscess, which can be treated preoperatively with broad spectrum antibiotic agents according to established guidelines. In many cases, episodes of pain persistence over two weeks after the procedure have been reported. In these conditions, and in the case of an absence of infection, surgical intervention seems mandatory. The possibility of hysterectomy due to chronic abdominal pain is estimated in 2% of the women who underwent uterine embolization.

The procedure of uterine arteries embolization can lead to postembolization ovarian failure in women over 45. The pathophysiologic mechanisms remain unknown. The whole procedure is significant, mostly in cases of fertility preservation. The postoperative impact of uterine arteries embolization reflects the improvement of menstrual disorders. Improvement during episodes of menorrhagia and metrorrhagia has been reported. In many cases, the generated embolization can lead to amenorrhea due to ovarian failure. Uterine wall defects, episodes of uterine fistula or uterine necrosis represent neglected cases of uterine arteries embolization. Due to treatment failure, the possibility of hysterectomy performance after uterine arteries embolization appears as a reality. The main causes reflect the existence of persistent bleeding, abdominal pain, fibroid prolapse, and episodes of uterine malignancies.

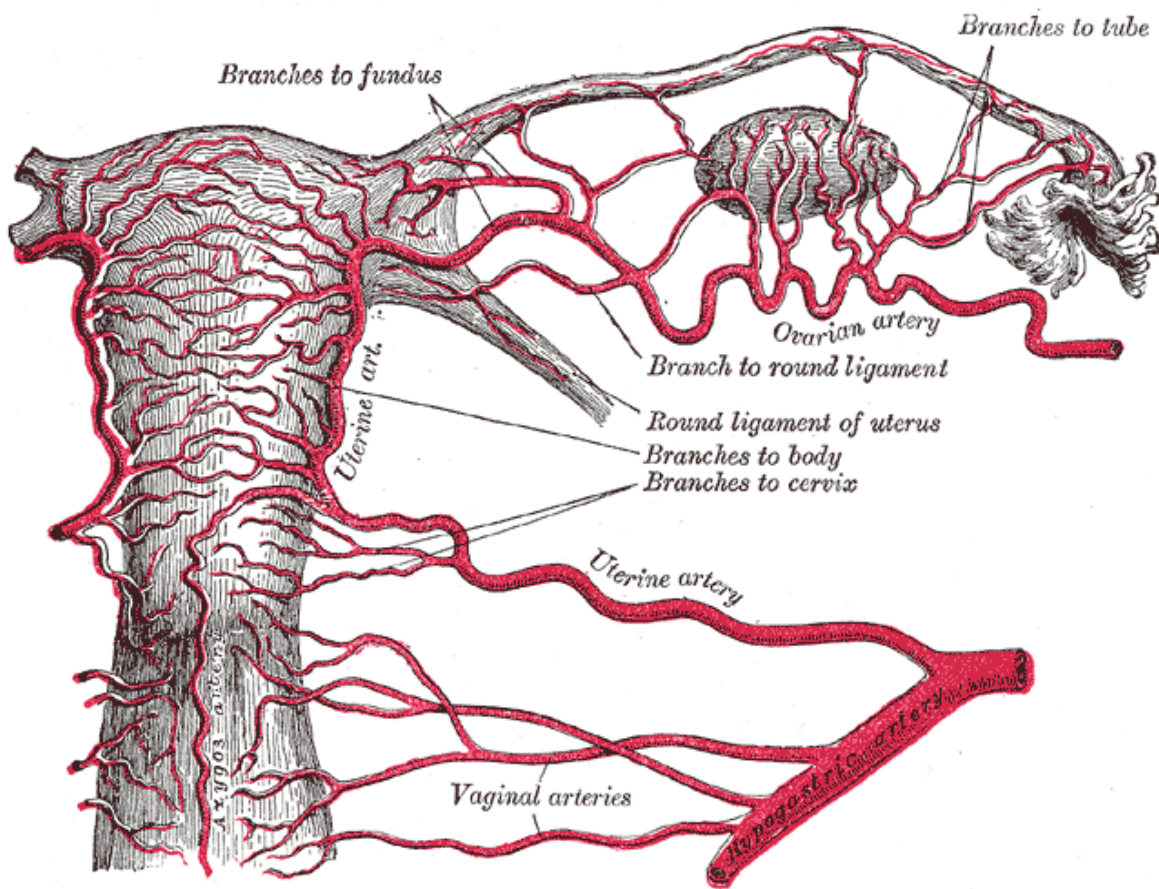


Figure 8. Arteries of the female reproductive tract (posterior view): uterine artery, ovarian artery and vaginal arteries. (Wikipedia)

4.5. Other techniques

The uterine arteries embolization regarding episodes of symptomatic uterine fibroids represents the treatment of choice in cases of diffuse intraoperative abdominal bleeding. Apart from this skilled and expertised procedure, alternative techniques such as ligation of uterine arteries or providing pharmaceutical agents such GnRH agonists with the ultimate scope being the increase of apoptosis among symptomatic fibroid muscle cells may emanate.

In cases of symptomatic uterine fibroids, focusing on fertility preservation via a laparoscopic ligation of uterine arteries seems to be a logical option. It reflects an effective procedure and stands as a worthy alternative to hysterectomy or myomectomy. Necessary conditions required for this procedure may be laparoscopic skills and the precise location of the uterine vessels. The collateral blood supply could lead to shrinkage due to ischaemia and infraction. The procedure can be performed laparoscopically or abdominally, though the laparoscopic procedure is superior. Every procedure has specific indications and contraindications. The crucial condition concerning the success rate increase remains the performance in centres with appropriate expertise in laparoscopic surgery. If these conditions cannot be fulfilled, massive abdominal bleeding could occur with the final result being the performance of a hysterectomy.

The existence of vaginal spotting after uterine ligation is considered to be a prohibitive factor. The second alternative procedure represents the supply of GnRH agonists with the principle example being the use of triptorelin. The pharmaceutical impact of GnRH agonists reflects the cell death, cell necrosis, and finally apoptosis. As result, all the apoptotic cells could lead to vessel obstruction and decrease of uterine flow. This procedure deputizes as its ultimate goal the fibroid shrinkage and the management of possible intraoperative bleeding. New strategies have been conducted in order to minimize the operative complications. The hysteroscopic endometrial ablation represents an alternative option. All these non-surgical procedures increase the fertility preservation in women of reproductive age.

Many studies must be further conducted, in order for precise and detailed results to emerge. The research steps must follow all the current guidelines focusing on the minimization of all intra- or postoperative complications. The ultimate goal remains the increase of survival rates and improvement of the surgical procedure. In comparison with all mentioned techniques, the B-Lynch technique represents an alternative procedure with remarkable results regarding fertility preservation and the management of operative bleeding after resection of uterine fibroids. The special advantage of this innovative technique is that it presents an alternative to major surgical procedures for controlling pelvic arterial pulse pressure, or hysterectomy. To date, this suturing technique, when applied correctly, has been successful with no problems and no apparent complications.

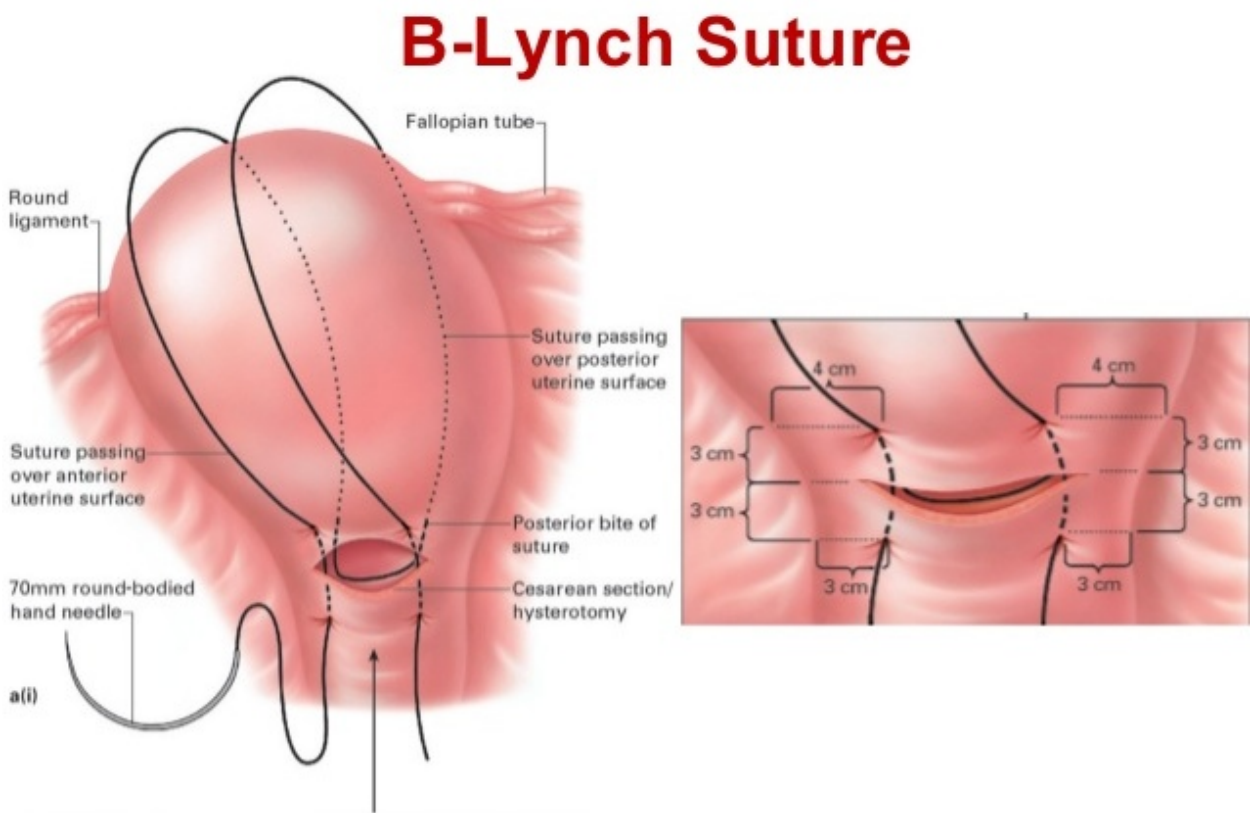


Figure 9. Schematic depiction of B-Lynch technique. (B-Lynch & Shah, A Comprehensive Text Book of PPH 2nd Ed. 2012)

5. Fertility preservation

The fibroid shrinkage due to uterine artery embolization in young nulliparous women, and especially the management of extensive metrorrhagia, involves important issues regarding fertility preservation. Due to the arrival of reports describing gestation and labour after uterine artery embolization (UAE), many alternative procedures have been performed.

Many studies reported individually with respect to postoperative complications. Many cases reported episodes of miscarriage, preterm deliveries, pre-eclampsia, and intrauterine growth restriction, as well as a high incidence of caesarean sections. Finally, several cases of intrauterine adhesions, endometrial atrophy, and fistula creation between the uterine cavity and the embolized intramural myoma have been reported in the current literature. Despite all the intra- or postoperative complications, uterine artery embolization prevents hysterectomies. This procedure must be properly planned depending on the haemorrhagic conditions of the disease and the surgical expertise of the surgeon.

Uterine artery embolization (UAE) has gained a great impact due to its uterus preservation, a necessary condition regarding female psychological and reproductive status. Uterus preservation is related to female psychosocial integrity and decreases anxiety and depression in correlation with women who have undergone hysterectomies. Many studies have reported the correlation between the performance of hysterectomy, and psychological and bodily disorders. In our period, in a world characterized by anxiety, economical, and physical stress, and difficulties within human relationships, fertility preservation has a high value. Nulliparous women feel mutilated after the performance of a hysterectomy, unable to achieve the ultimate aim of childbirth. All these reports try to demystify concepts such as uterine artery embolization and fertility preservation. Multidisciplinary cooperation is mandatory for ultimate procedure management.

6. Patient counselling

The most significant factor for uterine artery embolization involves patient counselling. The patient must be informed regarding the procedure, all intra- or postoperative complications, as well as conditions which are related to fertility preservation and the increase of life expectancy. Prior to any management procedure, all patients need evaluation through their medical history and physical examination. Daily habits, reception of medicament agents, and menstrual disorders must be mentioned in order to make clear the correlation with the management options.

The next step will be the evaluation of the severity of the lesion. Imaging findings and laboratory examination could confirm the results from the physical examination. A basic principle will be the constant updating regarding all the predisposing factors, which could influence the management selection. The patient must understand all the possible management options, the mechanisms procedure, and decide on the ultimate management option.

The physician's duty will be analysis and understanding the condition's status. The final decision depends on the patient. A well-informed patient together with the medical staff will map the proper procedure, taking into consideration not only the marital and reproductive status, but also the individual family planning of the patient.

All studies derived from the current bibliography agree that patient counselling could produce fewer intra- or postoperative complications and increase the life expectancy rate. Besides the preoperative patient counselling, an important role could be played by the well-trained psychologists and health professionals concerning the postoperative course. They should inform the patient regarding the postoperative options in order to prevent the possible stress and depression that could emerge. The postoperative mapping after uterine artery embolization as an alternative to a hysterectomy consists of future pregnancy. Many studies must be conducted in order to ensure future results.

7. Conclusion

Embolization of uterine arteries in cases of symptomatic fibroids introduces a vital and precise procedure in order to minimize all the intra- or postoperative complications, as well as to increase life expectancy and survival rates. Surgical skills, patient counselling, and properly trained medical staff should be taken into consideration as the proper indicators of the uterine arteries embolization. Multidisciplinary cooperation is mandatory with a view to proper and uneventful management.

Author details

Chrisostomos Sofoudis

Address all correspondence to: chrisostomos.sofoudis@gmail.com

2nd Department of Obstetrics and Gynaecology, University of Athens, Aretaieio Hospital, Greece

The author declares no financial interest regarding this manuscript.

References

- [1] Chabbert-Buffet N, Esber N, Bouchard P. Fibroid growth and medical options for treatment. *Fertil Steril*. 2014 Sep; 102(3):630–9.

- [2] Doherty L, Mutlu L, Sinclair D, Taylor H. Uterine fibroids: clinical manifestations and contemporary management. *Reprod Sci.* 2014 Sep; 21(9):1067–92.
- [3] Bulun SE. Uterine fibroids. *N Engl J Med.* 2013 Oct 3; 369(14):1344–55.
- [4] Lefebvre G, Vilos G, Allaire C, Jeffrey J. The management of uterine leiomyomas. SOgc clinical practice guideline, no.128, May 2003. *J Obstet Gynecol Can* 2003; 25(5): 396–405.
- [5] Burbank F, Hutchings FL. Uterine artery occlusion by embolization or surgery for treatment of fibroids: a unifying hypothesis-transient uterine ischemia. *J Am Assoc Gynecol Laparosc* 2000; 7:S1–49.
- [6] Walker WJ, Pelage JP. Uterine artery embolization for symptomatic fibroids: clinical results in 400 women with imaging follow-up. *Br J Obstet Gynecol* 2002; 109:1262–72.
- [7] Spies JB, Spector A, Roth AR, Baker CM, Mauro L, Murphy-Skrynarz K. Complications after uterine artery embolization for leiomyomas. *Obstet Gynecol* 2002; 100(5): 873–80.
- [8] Edwards RD, Moss JG, Lumdsen MA, et al. Uterine-artery embolization versus surgery for symptomatic uterine fibroids. *N Engl J Med* 2007; 356(4):360–70.
- [9] Henenkamp WJ, Volkers NA, Birnie E, et al. Symptomatic uterine fibroids: treatment with uterine artery embolization or hysterectomy — results from the randomized clinical embolization versus hysterectomy (EMMY) Trial. *Radiology.* 2008; 246(3): 823–32.
- [10] Pinto I, Chimeno P, Romo A, et al. Uterine fibroids: uterine artery embolization versus abdominal hysterectomy for treatment. A prospective, randomized and controlled clinical trial. *Radiology.* 2003; 226(2):425–31.
- [11] Wilde S, Scott S. Radiological appearances of uterine fibroids. *Indian J Radiol Imaging.* Aug 2009; 19(3): 222–231.
- [12] Madhuri TK, Kamran W, Walker W, Butler-Manuel S. Synchronous uterine artery embolization and laparoscopic myomectomy for massive uterine leiomyomas. *JSLS.* 2010 Jan–Mar; 14(1):120–2.
- [13] Pelage JP, Le Dref O, Soyer P, et al. Fibroid-related menorrhagia: treatment with superselective embolization of the uterine arteries and midterm follow-up. *Radiology.* 2000; 215(2):428–31.
- [14] Pron G, Mocarski E, Cohen M, et al. Hysterectomy for complications after uterine artery embolization for leiomyoma: results of a Canadian multicenter clinical trial. *J Am Assoc Gynecol Laparosc* 2003; 10(1):99–106.
- [15] Spies JB, Bradley LD, Guido R, Maxwell GL, Levine BA, Coyne K. Outcomes from leiomyoma therapies: comparison with normal controls. *Obstet Gynecol* 2010; 116(3): 641–652.

- [16] Brunereau L, Herbreteau D, Gallas S, et al. Uterine artery embolization in the primary treatment of uterine leiomyomas: technical features and prospective follow-up with clinical and sonographic examinations in 58 patients. *AJR Am J Roentgenol* 2000; 175(5):1267–1272.
- [17] Siskin GP, Shlansky-Goldberg RD, Goodwin SC, et al. UAE versus Myomectomy Study Group. A prospective multicenter comparative study between myomectomy and uterine artery embolization with polyvinyl alcohol microspheres: long-term clinical outcomes in patients with symptomatic uterine fibroids. *J Vasc Interv Radiol* 2006; 17(8):1287–1295.
- [18] Ananthakrishnan G, Murray L, Ritchie M, et al. Randomized comparison of uterine artery embolization (UAE) with surgical treatment in patients with symptomatic uterine fibroids (REST trial): subanalysis of 5-year MRI findings. *Cardiovasc Intervent Radiol* 2013; 36(3):676–681.
- [19] Ruuskanen A, Hippeläinen M, Sipola P, Manninen H. Uterine artery embolisation versus hysterectomy for leiomyomas: primary and 2-year follow-up results of a randomised prospective clinical trial. *Eur Radiol* 2010; 20(10):2524–2532.
- [20] Jun F, Yamin L, Xinli X, et al. Uterine artery embolization versus surgery for symptomatic uterine fibroids: a randomized controlled trial and a meta-analysis of the literature. *Arch Gynecol Obstet* 2012; 285(5):1407–1413.
- [21] van der Kooij SM, Bipat S, Hehenkamp WJ, Ankum WM, Reekers JA. Uterine artery embolization versus surgery in the treatment of symptomatic fibroids: a systematic review and metaanalysis. *Am J Obstet Gynecol* 2011; 205(4):e1–e18.
- [22] Gupta JK, Sinha A, Lumsden MA, Hickey M. Uterine artery embolization for symptomatic uterine fibroids. *Cochrane Database Syst Rev* 2012; 5:CD005073.
- [23] Poulsen B, Munk T, Ravn P. Long-term follow up after uterine artery embolization for symptomatic uterine leiomyomas. *Acta Obstet Gynecol Scand* 2011; 90(11):1281–1283.
- [24] Popovic M, Berzaczy D, Puchner S, Zadina A, Lammer J, Bucek RA. Long-term quality of life assessment among patients undergoing uterine fibroid embolization. *AJR Am J Roentgenol* 2009; 193(1):267–27.
- [25] Cardozo ER, Clark AD, Banks NK, Henne MB, Stegmann BJ, Segars JH. The estimated annual cost of uterine leiomyomata in the United States. *Am J Obstet Gynecol*. 2012; 206(3):211–e1–9.
- [26] Yoon SW, Kim KA, Cha SH, Kim YM, Lee C, Na YJ, et al. Successful use of magnetic resonance-guided focused ultrasound surgery to relieve symptoms in a patient with symptomatic focal adenomyosis. *Fertil Steril*. 2008; 90(5):2018. e13–5.
- [27] Behera MA, Leong M, Johnson L, Brown H. Eligibility and accessibility of magnetic resonance-guided focused ultrasound (MRgFUS) for the treatment of uterine leiomyomas. *Fertil Steril*. 2010; 94(5):1864–8.

- [28] O'Sullivan AK, Thompson D, Chu P, Lee DW, Stewart EA, Weinstein MC. Cost-effectiveness of magnetic resonance guided focused ultrasound for the treatment of uterine fibroids. *Int J Technol Assess Health Care*. 2009; 25(1):14–25.
- [29] Zowall H, Cairns JA, Brewer C, Lamping DL, Gedroyc WM, Regan L. Cost-effectiveness of magnetic resonance-guided focused ultrasound surgery for treatment of uterine fibroids. *Bjog*. 2008; 115(5):653–62.
- [30] Tropeano G, Amoroso S, Scambia G. Non-surgical management of uterine fibroids. *Hum Reprod Update*. 2008; 14(3):259–74.
- [31] Hald K, Langebrekke A, Klow NE, Noreng HJ, Berge AB, Istre O. Laparoscopic occlusion of uterine vessels for the treatment of symptomatic fibroids: initial experience and comparison to uterine artery embolization. *Am J Obstet Gynecol*. 2004; 190: 37–43.
- [32] Watkinson A, Nicholson A. Uterine artery embolization to treat symptomatic uterine fibroids. *BMJ*. 2007; 335(7622):720–722.
- [33] Marshburn PB, Matthews ML, Hurst BS. Uterine artery embolization as a treatment option for uterine myomas. *Obstet Gynecol Clin North Am*. 2006; 33(1):125–144.
- [34] Smith WJ, Upton E, Shuster EJ, Klein AJ, Schawrz ML. Patient satisfactory and disease specific quality of life after uterine artery embolization *Am J Obstet Gynecol* 2004; 190(6):1697–1703.
- [35] Pritts EA. Fibroids and infertility: a systematic review of the evidence. *Obstetrical and Gynecological Survey*, 2001, vol.56, no.8, pp. 483-491.
- [36] Poncelet C, Benifla JL, Batallan A, Darai E, Mandelenat P. Myoma and infertility :analysis of the literature. *Gynecol Obset Fertil*, 2001, vol.29, no.6, pp. 413–421.
- [37] Fletcher H, Wharfe G, Williams N, Gordon-strachan G, Pedican M, Brooks A. Venous thromboembolism as a complication of uterine fibroids: a retrospective descriptive study. *Journal of Obstetrics and Gynecology*, 2009, vol.29, no.8, pp.732–736.
- [38] Fletcher HM, Wharfe G. Intestinal obstruction and thromboembolism in a postmenopausal woman with large calcified fibroids. *Journal of Obstetrics and Gynecology*, 2008, vol.28, no.7, pp.754–755.
- [39] Olive DL, Pritts EA. Fibroids and reproduction. *Seminars in Reproductive Medicine*, 2010, vol.28, no.3, pp. 218–227.
- [40] Olive DL. The surgical treatment of fibroids and infertility. *Seminars in Reproductive Medicine*, 2011, vol.29, no.2, pp.113–123.
- [41] Duhan N. Current and emerging treatments for uterine myoma — an update. *International Journal of Women's Health*, 2011, vol.3, pp.231–241.
- [42] Lupattelli T, Clerissi J, Basile A, et al. Treatment of uterine fibromyom with bilateral uterine artery embolization: state of the art. *Minerva Ginecol*. 2007; 59(4):427–439.

- [43] van der Kooij SM, Bipat S, Hehenkamp WJ, Ankum WM, Reekers JA. Uterine artery embolization versus surgery in the treatment of symptomatic fibroids: a systematic review and metaanalysis. *Am J Obstet Gynecol*. 2011; 205(4):317.
- [44] Moss JG, Cooper KG, Khaund A, et al. Randomised comparison of uterine artery embolisation (UAE) with surgical treatment in patients with symptomatic uterine fibroids (REST trial): 5-year results. *BJOG*. 2011; 118(8):936–944.
- [45] Al-Badr A, Faught W. Uterine artery embolization in an undiagnosed uterine sarcoma. *Obstet Gynecol*. 2001; 97(5):836–837.
- [46] Tulandi T, Sammour A, Valenti D, Child TJ, Seti L, Tan SL. Ovarian reserve after uterine artery embolization for leiomyomata. *Ferti Steril*. 2002; 178(1):197–198.
- [47] Kaump GR, Spies JB. The impact of uterine artery embolization on ovarian function. *J Vasc Interv Radiol*. 2013; 24(4):459–467.
- [48] Vercellini P, Oldani S, DeGiorgi O, Cortesi IL, Moschetta M, Crosignani PG. Endometrial ablation with a vaporizing electrode in women with regular uterine cavity or submucous leiomyomas. *J Am Assoc Gynecol Laparosc*. 1996; 3(4):S52.
- [49] Froeling V, Meckelburg K, Schreiter NF, et al. Outcome of uterine artery embolization versus MR-guided high-intensity focused ultrasound treatment for uterine fibroids: long-term results. *Eur J Radiol*. 2013; 82(12):2265–2269.
- [50] Mara M, Horak P, Kubinova K, Dundr P, Belsan T, Kuzel D. Hysteroscopy after uterine fibroid embolization: evaluation of intrauterine findings in 127 patients. *J Obstet Gynaecol Res*. 2012; 38(5):823–831.