

We are IntechOpen, the world's leading publisher of Open Access books Built by scientists, for scientists

6,900

Open access books available

186,000

International authors and editors

200M

Downloads

Our authors are among the

154

Countries delivered to

TOP 1%

most cited scientists

12.2%

Contributors from top 500 universities



WEB OF SCIENCE™

Selection of our books indexed in the Book Citation Index
in Web of Science™ Core Collection (BKCI)

Interested in publishing with us?
Contact book.department@intechopen.com

Numbers displayed above are based on latest data collected.
For more information visit www.intechopen.com



A Review on Amiodarone as an Antiarrhythmic Drug

Fereshteh Mehraein

Additional information is available at the end of the chapter

<http://dx.doi.org/10.5772/60418>

Abstract

Antiarrhythmic drugs are used to suppress abnormal heart rhythms by different mechanisms. Amiodarone as an iodinated benzofuran derivative is a potent antiarrhythmic drug that is being used for the treatment of a wide variety of cardiac arrhythmias. Amiodarone has been reported to cause frequent and potentially serious toxicity. It was estimated that the prevalence of side effects was 15 % in the first year and increased to 50% with long-term therapy. Thyroid, lung, liver, ophthalmologic and neurologic systems can be affected by Amiodarone. Most of the adverse effects of the drug are related to its dosage and duration of administration. Therefore the effectiveness of Amiodarone in long-term treatment of patients with heart arrhythmia is limited because of the development of its adverse side effects.

Keywords: Antiarrhythmic drugs, Amiodarone, Side effects

1. Introduction

Antiarrhythmic drugs are used to suppress abnormal heart rhythms and have been differentiated by their antiarrhythmic action according to the classification system developed by Vaughn-Williams in 1970 [1]. The classification includes five major groups of antiarrhythmic drugs, classes I, II, III, IV and V (Table 1). Class I agents are sodium channel blockers, class II are beta blockers, class III are potassium channel blockers, class IV are calcium channel blockers and class V agents work by unknown mechanisms. The class I agents are classified into class Ia, Ib and Ic. Ia class includes Quinidine, Procainamide and Disopyramide. They slow the rate of rise of phase 0, lengthen the refractory period and the width of the monophasic action potential. Quinidine is one of the oldest antiarrhythmic agents derived from the cinchona tree

bark and has anti malarial, antipyretic and antiarrhythmic effects. Procainamide and its main metabolite, N-acetyl Procainamide are effective for treating supraventricular and ventricular arrhythmias. Disopyramide has three important side effects. It is vagolytic causing urinary retention, constipation and dry mouth. The class 1b agents are pure sodium channel blockers. This class includes Lidocaine, Phenytoin Mexiletine and Tocainide. Class Ib antiarrhythmic agents used only for the management of ventricular tachyarrhythmia. The class Ic agents are strong sodium channel blockers. This class comprises of Flecainide, Encainide, Propafenone and Moricizine. They are being used to treat ventricular and supraventricular tachyarrhythmia. They are contraindicated in patients with structural heart disease due to the risk of precipitating life-threatening ventricular arrhythmias. Class II drugs include Metoprolol, Carvedilol, Atenolol, Propranolol and Bisoprolol. They antagonize beta-receptors inhibiting the effect of the sympathetic nervous system resulting in decreased heart rate, contractility and conductivity. The class III agents are drugs that block the potassium channel as their main anti arrhythmic effect. This class includes Sotalol, Dofetilide, Ibutilide, and Amiodarone. They exert their effect by prolonging the refractory period. Sotalol is a nonspecific beta adrenergic receptor blocker with potassium channel blocking properties that is used in managing ventricular arrhythmias and atrial fibrillation. Dofetilide is a potassium channel blocker and excreted by the kidneys. Ibutilide is a short-acting intravenous potassium channel blocker that is used only for the acute termination of atrial fibrillation or flutter. Class IV drugs are Verapamil and Diltiazem. These drugs are known as nondihydropyridine and act by blocking cardiac calcium uptake. They are used to slow AV nodal conduction by decreasing heart rate. Class V agents include Adenosine, Digoxin, magnesium and sulphate are used in supraventricular arrhythmias, especially heart failure with atrial fibrillation, contraindicated in patients with ventricular arrhythmias [1–3]. Amiodarone is considered one of the most effective antiarrhythmic drugs which is widely prescribed. Here, its clinical uses as well as its side effects are reviewed.

Mechanism	Examples	Class
These drugs block cardiac sodium channels and depress phase 0 of the action potential. Class Ia drugs treat atrial fibrillation and ventricular arrhythmia.	Quinidine, Procainamide, Disopyramide	Ia
These drugs are cardiac sodium channel blockers and shorten the action potential. They are used for ventricular tachycardia.	Lidocaine, Phenytoin, Mexiletine and Tocainide	Ib
These drugs are cardiac sodium channel blockers. The class Ic drugs are commonly used to treat ventricular and supraventricular tachyarrhythmia.	Flecainide, Encainide, Propafenone and Moricizine	Ic
These drugs are known as beta-blockers and decrease heart rate, contractility and conductivity.	Metoprolol, Carvedilol, Atenolol, Ppropranolol, Bisoprolol	II
These drugs act by blocking cardiac potassium channels. They are effective to treat atrial fibrillation and ventricular tachycardia.	Amiodarone, Sotalol, Dofetilide, Ibutilide,	III
These are cardiac calcium channel blockers. They are used to slow AV nodal conduction decreasing heart rate.	Verapamil, Diltiazem	IV
unknown mechanisms	Adenosine, Digoxin, magnesium and sulfate	V

Table 1. Classification of antiarrhythmic drugs (based on mechanism of action)

2. History and main uses

Cardiac dysrhythmia also known as arrhythmia or irregular heartbeats is a group of conditions in which the electrical activity of the heart is irregular [4]. Arrhythmias may occur in the atria or ventricles [5] and is one of the most common signs of anomaly in heart function. Amiodarone as an iodinated benzofuran derivative (Figure 1) is a potent antiarrhythmic drug that is being used for the treatment of a wide variety of cardiac arrhythmias [6]. For the first time, the Russian physiologist, Gleb Von Anrep discovered the original precursor molecule of Amiodarone that was called Khellin. Khellin is the extract of an African plant named Khella. Anrep noticed that one of his technicians' angina symptom was cured after he took Khellin [7, 8]. In 1960, European pharmaceutical industries were working on the preparations of extracts derived from Khellin and finally they purified and developed Amiodarone in 1961 [7]. Oral Amiodarone that suppresses life-threatening ventricular arrhythmias and also chronic atrial fibrillation is available in tablets of 200 mg and 400 mg in generic forms as Cardarone and Pacerone, respectively. In addition to the tablet forms, it is also available in solution for intravenous administration. Intravenous administration of Amiodarone is effective in suppressing serious arrhythmias which reduces the need for atrial fibrillation cardiac surgeries. The intravenous administration of Amiodarone requires following a restrict dosing schedule. Amiodarone is typically given in high doses of 800-1600 mg daily, either intravenously or orally until the arrhythmia is under control, although for long-term oral administration of the drug 200 - 600 mg daily is recommended [8-10].

3. Mechanism of action

Amiodarone is a Class III antiarrhythmic agent [7, 8] that prolongs the duration of action potential and hence increases the refractory period of atrial, nodal and ventricular tissues, thereby has a very broad spectrum of activity. An increase in the refractory period of the atrial cells is a major contributing factor for controlling the atrial tachyarrhythmia [5-7]. A reduction in the permeability of the A-V node, both anterograde and retrograde, explains the efficacy of the medicine in nodal tachycardia caused by reentry through the A-V node [11-13]. Its action on ventricular arrhythmias is explained by a number of mechanisms, e.g. its effect on the atrium and A-V node results in a reduction in the frequency of stimuli reaching the ventricle, thus giving the ventricular cell mass enough time to repolarize in cases where there have been nonsynchronous refractory periods. Furthermore, prolonging the refractory period of the His-Purkinje system and ventricular contractile fibers reduces or prevents micro reentry [5-7]. Amiodarone increases coronary blood flow, decreases cardiac oxygen requirements without producing negative inotropic effects and also suppresses ectopic pacemakers, and this is particularly valuable in arrhythmias associated with ischemic damage or angina pectoris [10-17].

3.1. Metabolism

Amiodarone is incompletely and erratically absorbed following oral administration. Absolute bioavailability ranges from 22 to 86% but there is extensive inter-subject variations [6, 7]. Its metabolism occurs in the gut wall and in the liver that could determine the availability of the

medicine. The half-life of Amiodarone is long and with chronic oral dosing can be from 14 to 110 days but is usually in the range of 14–59 days. The principal metabolite of Amiodarone, which has been detected in the plasma and other tissues, is Desethylamiodarone [16, 18]. This metabolite has been reported to have a longer half-life than Amiodarone, i.e. 10 hours after a single dose of Amiodarone and 60–90 days after chronic dosing with Amiodarone. The mechanism of action of this metabolite is not yet known. Amiodarone is highly protein bound and is thought to bind strongly to proteins at concentrations of 10 µg/mL. It is believed that most of the medicine is excreted via the liver and gastrointestinal tract by biliary excretion [16, 8]. There may be some hepatic recirculation too. The apparent volume of distribution after oral administration (200–400mg) of Amiodarone is 6.31 ± 4.93 L/kg. Amiodarone is highly lipid soluble and tends to accumulate in adipose tissues as well as in highly perfused organs, e.g. lung, bone marrow, adrenals, liver, pancreas, heart, spleen and kidney. The concentration of Amiodarone in packed red blood cells is approximately 60% of that in plasma [8, 9]. Amiodarone and its metabolite Desethylamiodarone (DEA) can cross the placenta and therefore it may be toxic to embryo [8, 9]. Amiodarone is metabolized in the liver by cytochrome P450 enzyme system [8] and excreted through biliary route with almost no elimination via renal route [11, 12].

3.2. Chemistry

Amiodarone is a benzofuran derivative with two atoms of iodine per molecule (Figure 1), with a molecular weight of 645.32 g/mol, It is highly lipophilic and is not water soluble [9, 12, 13].

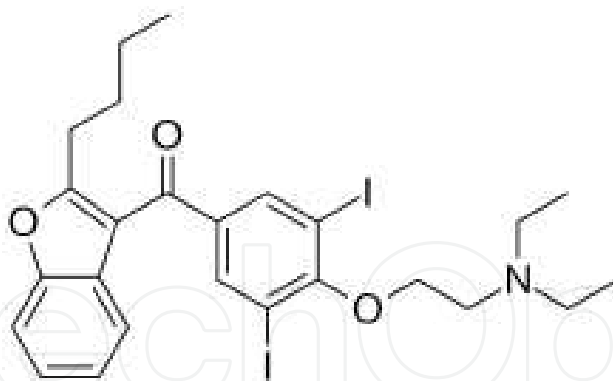


Figure 1. Chemical structure of Amiodarone

3.3. Interactions

Amiodarone is subject to multiple interactions with oral anticoagulants (e.g. Warfarin) and any drugs that cause bradycardia, e.g. beta blockers and calcium channel blockers. Amiodarone increases Digoxin level [8, 9]. Drugs that deplete potassium from the body (e.g. diuretics) should be avoided in the time of treatment with this drug. Amiodarone may increase Phenytoin levels [8, 11].

4. Side effects

Amiodarone has been reported to cause frequent and potentially serious toxicity [13, 15, 16, 18]. Most of the adverse effects of the drug are related to its dosage and duration of administration, e.g. concurrent use of other antiarrhythmic agents, severity of underlying disease state, and individual variation in pharmacokinetic profile of the medicine in each individual [11, 18]. In most patients who have been administered Amiodarone for a long period of time experienced one of the side effects [16, 18]. Even low doses of the drug are associated with significant adverse effects [18]. It was estimated that the prevalence of side effects was 15 % in the first year and increased to 50% with long-term therapy [19–21]. Thyroid, lung, gastrointestinal organs, ophthalmologic and neurologic systems can be affected by Amiodarone [16, 18].

4.1. Thyroid dysfunction

As Amiodarone may induce thyroid disorders, particularly in patients with personal history of thyroid disorders, clinical and biological monitoring recommended before starting the treatment, during the treatment and for several months after the treatment ends [21–23]. Serum TSH levels should be measured when thyroid dysfunction is suspected. Amiodarone contains two atoms of iodine per molecule (Figure 1). This amounts to 37.5% of organic iodine by molecular weight, of which 10% is deiodinated to yield free iodine. It has the potential to cause thyroid dysfunction because of the two iodine atoms [22, 23]. It often causes an increase of T4 and rT3 and a decrease of T3 in serum that mainly related to the inhibition of 5'-deiodinase activity, resulting in a decrease in the production of T3 from T4 and a decrease in the clearance of rT3 [19–21]. In 14–18% of Amiodarone-treated patients, a thyroid dysfunction was observed that either related to Amiodarone-Induced Thyrotoxicosis (AIT) or Amiodarone -Induced Hypothyroidism (AIH) [24, 25]. Amiodarone also inhibits the peripheral conversion of thyroxine (T4) to triiodothyronine (T3) [21, 25]. At the extrathyroidal level, Amiodarone has the specific ability to inhibit 5'-monodeiodination of T4 [23]. Amiodarone causes changes in serum thyroxine (T4), triiodothyronine (T3), reverse triiodothyronine (rT3) and thyroid-stimulating hormone (TSH) concentrations. These changes are similar to those produced by iodinated radiographic contrast agents. The magnitude of these changes is dose dependent [24]. Amiodarone strongly inhibits type I, 5'-monodeiodinase enzyme activity that leads to changes in the rate of conversion of T4 to T3 [23, 24]. A decrease of 5'-deiodination of T4 to T3 is observed in many tissues but is most pronounced in the thyroid and the liver, the latter being the main extrathyroidal T3 production site [21]. This inhibitory action persists during and for several months after Amiodarone treatment, explaining the decreased plasma and tissue T3 concentrations [20, 21]. A decrease in T3 concentration affects the biological activity ensued by T3 hormone as T3 binds to its nuclear receptor that regulates many other cell biological activities [24–26]. The inhibition of type I 5'-deiodinase activity also results in the reduced clearance and a consequent rise in serum rT3 concentrations [23, 24]. Conversely, the

inhibition of type II 5'-deiodinase activity by Amiodarone may lead to reduced intrapituitary T3 concentrations and this may in part account for the increase in serum TSH levels that was observed in patients treated with the drug [19–21]. AIH is believed to be the result of inability of the thyroid gland to escape from the Wolff-Chaikoff effect (according to Wolff-Chaikoff effect, the large amount of iodide that is released during the metabolism of Amiodarone leads to an adaptive blockage of further thyroidal iodide uptake and thyroid hormone biosynthesis). Furthermore, Amiodarone indirectly affects the thyroid hormone metabolism by inhibiting cellular thyroid hormone uptake. Results from kinetic studies suggested a decrease in the transfer of T4 from the plasma pool to rapidly exchangeable tissue pools, such as in the liver [21, 23], that leads to decreased availability of the substrate T4 intracellularly and hence reduced T3 production. A selective decrease in hepatic T4 transport was also demonstrated in hepatocytes and perfused rat liver as well as an impaired T3 uptake was observed in an anterior pituitary cell line [24, 25]. The risk of developing hypothyroidism is independent of the daily dose of Amiodarone. However, the risk is greater in the elderly and in female patients, probably as a result of a higher prevalence of underlying thyroid abnormality in this population [23, 25]. For example, it was shown that relative risk of developing AIH was 13-fold higher in female patients with positive thyroid thyroglobulin antibodies, as compared with men without thyroid antibodies [22, 23]. Another side effect of the drug is thyrotoxicosis which may occur anytime during therapy or even after the discontinuation of therapy. Hypothyroidism is usually an early event and it is uncommon after the first 18 months of Amiodarone treatment [22, 23]. AIH can be managed by either discontinuation of Amiodarone therapy or thyroid hormone replacement [19]. Although in some cases discontinuation of Amiodarone may not be feasible especially in the treatment of difficult ventricular tachyarrhythmia. In these cases, safer and more reliable option is thyroid hormone replacement therapy [23]. The following symptoms usually indicate the development of thyroid hypothyroidism which are associated with Amiodarone treatment, e.g. weight gain, cold intolerance, reduced physical activity and excessive bradycardia. The diagnosis is supported by a clear increase of TSH (thyroid stimulating hormone) in serum [21, 23]. Euthyroidism (normal level of thyroid hormone in serum) is usually should be obtained within 1–3 months following the discontinuation of treatment. AIT (Amiodarone-induced thyrotoxicosis) may occur during Amiodarone treatment or up to several months after discontinuation [26, 27]. AIT occurs in 2–12% of patients on chronic Amiodarone treatment. Clinical features in patients developing AIT such as weight loss, onset of arrhythmia, angina and congestive heart failure should alert the physician. The diagnosis is confirmed by a clear decrease in serum TSH level in which case Amiodarone should be withdrawn [23, 27]. Recovery from AIT usually occurs within a few months following drug withdrawal. There are two types of AIT. Type I is primarily related to excess iodine-induced thyroid hormone synthesis in an abnormal thyroid gland and Type II AIT which is developed by Amiodarone treatment is a destructive thyroiditis [28, 29]. In patients with preexisting thyroid abnormalities, thyrotoxicosis is believed to result from iodine-induced excessive thyroid hormone synthesis which is caused by drug treatment (Type I AIT) [29]. In this type of AIT, the pathogenesis is related to the

effects of iodine overload by the drug on already abnormal thyroid glands, such as nodular goitre, autonomous nodule or latent Graves' disease [26, 27, 29]. However, in patients with an apparently normal thyroid gland, thyrotoxicosis results from the damage of thyroid gland by the drug that ensues the release of thyroid hormones into the circulation (Type II AIT) [27–29]. In vitro studies had shown Amiodarone to be cytotoxic to the thyroid cells; similarly, moderate to severe follicular damage and destruction were demonstrated in histopathological studies on thyroid gland tissues obtained from patients who were treated with the drug and showed symptoms of Type II AIT [26]. Clinical manifestations of AIT include palpitations, supraventricular tachycardia, weight loss, sweating and muscle weakness. By physical examination and ultra sonography of the thyroid the two types can be diagnosed and differentiated [22, 23, 30].

4.2. Pulmonary toxicity

There are numerous reports describing pulmonary toxicity associated with Amiodarone. Amiodarone-induced pulmonary toxicity (AIPT) occurs in 1–17% of patients. Acute pneumonitis and chronic fibrosis may be increased with higher circulating concentration of the drug [31, 32]. AIPT is more frequent in men and increases with age. Individuals with preexisting lung disease appear to be more susceptible to the drug [33, 34]. Pulmonary toxicity can be observed from the time of initiation of the treatment or after several years of treatment [32]. Regular x-ray of chest is recommended to be performed routinely in patients who are undergoing long-term therapy or when diagnosis is suspected. Once AIPT is diagnosed, treatment with corticosteroid and reduction or withdrawal of Amiodarone therapy should be carried out. Onset of dyspnoea or non-productive cough may be related to pulmonary toxicity such as interstitial pneumonitis [33–36]. In very rare cases when intravenous Amiodarone was administered, interstitial pneumonitis has been reported [35, 36]. Some of the symptoms of dyspnoea are fatigue, weight loss, and fever. Whether or not these symptoms are present in the patients, chest x-ray should be performed [34, 36]. In cases of development of interstitial pneumonitis in patients which is caused by Amiodarone therapy, early withdrawal of the drug is recommended. Symptoms usually resolve within 3–4 weeks followed by slow improvement in pulmonary function within several months after withdrawal. Corticosteroid therapy expedites the recovery in these cases [32, 34]. In very rare cases severe respiratory complications sometimes fatal have been observed usually after surgery (Adult acute respiratory distress) [33, 35]. Amiodarone and its metabolite can cause lung damage by producing oxygen radicals and accumulation of phospholipids in the cells or by causing an immunological reaction [34, 35, 37]. The latter is supported by the finding of cytotoxic T cells in bronchoalveolar lavage fluid from patients who were diagnosed with AIPT [35]

A variety of recent studies suggest a critical role for alveolar cell apoptosis and lung fibrosis caused by the drug [34, 36]. We previously showed acute pathological changes including alveolar capillary congestion and infiltration of red blood cells into the lumen of alveoli in rabbits that were treated with the Amiodarone for two weeks [38]. Card also showed that

the drug induces acute pulmonary inflammation following intratracheal administration of Amiodarone after 24 hours in a hamster model [39]. Electron microscopy of the lung tissues in Amiodarone treated rats showed pathological changes after three weeks [40]. These researchers showed the appearance of inclusion bodies inside the pneumocytes [40, 41]. One possible mechanism of lung damage by the drug is the accumulation of phospholipids in the lung cells. The accumulation of inclusion bodies in the cytoplasm of the cells is thought to be due to decreased degradation of phospholipids because Amiodarone is a powerful inhibitor of degradation of phospholipids by lysosomes [38, 40, 41]. These inclusion bodies have also been detected in other tissues exposed to Amiodarone. Pitsiavas [40] found that Amiodarone induces specific ultrastructural changes in thyroid cells in rats. The specific changes included evidence of inclusion bodies and was also mentioned that Amiodarone is directly cytotoxic to the thyroid. There has also been debate in the past as to whether these inclusion bodies in cells in Amiodarone treated animals only reflect the ongoing cytotoxic process or whether these bodies are directly toxic to the cell in their own right. As mentioned earlier, Amiodarone causes the formation of inclusion bodies in many cell types. These changes are the result of inhibition of degradation of phospholipids by Amiodarone [40–42]. It has been shown that Amiodarone causes vacuolization in type II pneumocytes which are known as reactive type II pneumocytes [43]. The highest prevalence of reactive type II pneumocytes were noted in patients with systemic inflammatory response and alveolar hemorrhage [44–46]. In addition, reactive type II pneumocytes tended to occur more frequently in ventilator associated drug induced pulmonary disorders and they were associated mainly with the condition of acute lung injury [39, 44]. Microscopic observations showed diffused interstitial pneumonitis with widening of alveolar septa and interstitial fibrosis in lung tissues from patients [47, 48]. Organizing pneumonia, acute respiratory distress syndrome (ARDS), diffused alveolar hemorrhage (DAH) are the other adverse effects from Amiodarone administration [44, 47]. Interstitial pneumonitis is the most common adverse effect of Amiodarone which presents after two months of therapy with 400 mg per day [35]. The symptoms are fever, cough, pleuritic pain and weight loss. Accumulated phospholipids in lung cells because of drug treatment, interfere with metabolism of cells which results cell injury and death [35, 44]. Alteration of the phospholipids of cellular and organelle membrane by Amiodarone leads to change in their functions [35, 41, 42]. Angiotensin enzyme increases Amiodarone-induced lung toxicity [36, 45, 47]. Other pulmonary side effects from Amiodarone treatment include fibrosis that is the result of chronic inflammation which in turn is due to cellular damage, reduced forced vital capacity, total lung capacity and reduced diffusing capacity. Other Amiodarone side effect on lung is organizing pneumonia which is accompanied with the proliferation of granulation tissue which consists of fibroblasts, myofibroblast and collagen fibers [35, 45, 48]. Acute respiratory distress syndrome (ARDS) is characterized by diffuse alveolar hemorrhage which includes pulmonary edema, systemic lupus vasculitis and hemorrhage [35]. The more common form AIPT is associated with doses of 400 mg daily or more. AIPT is reversible if diagnosed early [31, 49].

4.3. Cardiac toxicity

Amiodarone by blocking the calcium channel activity can cause sinus bradycardia and AV nodal block in 5% of patients. Hypotension may occur when concentrated Amiodarone hydrochloride injection is given by the intravenous route. In some cases, hypotension may be refractory, resulting in fatal outcomes [8, 18].

4.4. Hepatotoxicity

Hepatotoxicity is common with higher doses of Amiodarone. Elevation of serum enzymes are reported in 15–50% of patients in long-term therapy. Regular monitoring of liver function tests (measuring of serum aspartate aminotransaminases, serum alanine aminotransferase glutamyl transepeptidase levels) is recommended as soon as Amiodarone treatment is started and during the treatment. The elevation of these enzymes is usually asymptomatic. These changes are dependent on the dose of the drug. Acute liver disorders including severe hepatocellular insufficiency or hepatic failure, sometimes fatal and chronic liver disorders may occur with oral and intravenous forms within the first 24 hours of i.v. Amiodarone [50, 51]. Therefore, Amiodarone dose should be reduced or the treatment discontinued if the transaminases increase exceeds three times the normal range [51, 52]. Because of the potential risk of hepatotoxicity and/or accumulation, Amiodarone should be used with extreme caution in patients with hepatic disease [50, 51]. Histologic examination of biopsy samples from Amiodarone-induced cirrhotic patients showed that drug-induced cirrhosis is similar to alcoholic cirrhosis. Close examination of liver tissues from the patients showed leukocytic infiltrate and strikingly high Mallory's hyaline along with other usual pathologic findings of cirrhosis are noted [53–55]. Mallory's hyaline is an eosinophilic inclusion made up of intermediate keratin filaments. Mallory's hyaline can be seen in primary biliary cirrhosis, alcoholic cirrhosis or hepatitis, nonalcoholic cirrhosis and some other conditions [50, 52]. Other histological evidences revealed accumulation of granules in macrophages, intralobular inflammatory infiltrates, fibrosis and phospholipidosis. Electron microscopy observation shows abnormal mitochondria and phospholipid laden lysosomes [53, 54]. Amiodarone causes direct damage to membrane lipid bilayer and changes in mitochondrial function. Amiodarone as a potent inhibitor of phospholipase A that promotes the accumulation of lipid rich materials in lysosomes. The studies showed that mitochondrial dysfunction leads to fibrosis. Patients with hepatotoxicity from Amiodarone have symptoms such as fatigue, nausea, weight loss, hepatomegaly, elevation of serum aminotransferase and alkaline phosphate levels [55, 56].

4.5. The effects of Amiodarone on ocular tissue

Corneal deposits develop in almost all patients and regular ophthalmological monitoring (e.g. slit lamp biomicroscopy, visual acuity, ophthalmoscopy, etc.) is recommended. If blurred or decreased vision occurs, ophthalmological examination including fundoscopy should be promptly performed. Appearance of optic neuropathy and/or optic neuritis requires Amiodarone withdrawal due to the potential progression to blindness [57, 58]. Electron microscopic observation revealed the presence of lysosomal-like intracytoplasmic

membranous lamellar bodies in extraocular muscle fibers, corneal epithelium, stromal and endothelial cells, conjunctival epithelium, scleral cells, lens epithelium, iris, ciliary body, choroid, retinal pigment epithelium, ganglion cells, large diameter axons of the optic nerve, the endothelium of ocular blood vessels and basal cells of corneal epithelium. Lamellar bodies in these cells contained iodine [53, 59]. Deposits were observed in the corneal epithelium of Amiodarone treated patients [59] about one week after the initiation of treatment with Amiodarone [59], keratopathy, unilateral and bilateral anterior ischemic optic neuropathy are also occurred [60, 61]. The corneal deposits are caused by secretion of Amiodarone from lacrimal gland on corneal surface. These deposits are brown and have been described as resembling cat's whiskers [57, 58]. Amiodarone-induced ocular side effects are time and dose-dependent. The changes are reversible after stopping Amiodarone treatment. Amiodarone-related optic neuropathy has been reported after 4 month duration of treatment with unilateral or bilateral visual loss that can progress to blindness [62, 63]. Microscopic studies showed the accumulation of lamellar inclusions in the axons of the optic nerve because of drug induced lipidoses [57, 63].

5. Other side effects of Amiodarone

Dermatologic, gastrointestinal, neurologic and genitourinary changes are the other side effects of chronic use of Amiodarone. Photosensitivity and less frequently phototoxicity are important dermatological side effects. Photosensitivity is quite common and there is a wide spectrum of skin reactions, ranging from an increased propensity to suntan to intense burning and erythema and swelling of the exposed area [64, 65]. Phototoxicity induces blue-gray skin hyperpigmentation of predominantly sun exposed areas. It develops in <10% of patients, preferentially affecting men. It was mainly observed after an average of 20 months of continuous Amiodarone treatment and a minimal cumulative dose of 160 g [64, 66]. Histopathologically, Amiodarone-induced phototoxicity has been related to lysosomal dermal lipofuscin deposits. The only treatment is reduction or cessation of therapy, upon which skin changes may slowly abate [64, 66]. However, skin discoloration is likely to persist for years. The intensity of these reactions could be alleviated by a reduction in dosage or by application of a protective sunscreen. Patients should be instructed to avoid exposure to the sun or use protective measures during therapy [64–66].

Peripheral neuropathy has been observed in 3–30% of patients on long-term high dosage (generally over 400mg/day) regimen which include tremor, ataxia and sleep disturbances. Histologically, inclusion bodies and segmental demyelination of the nerve fibers have been demonstrated in peripheral nerve fibers. After discontinuation of the medicine, the neurological complication is slowly and incompletely resolved [65, 67].

A significant association was found between the development of epididymitis and high-dose Amiodarone treatment for a long time. Genitourinary effects include sterile epididymitis with pain and swelling in the scrotum [68].

6. Conclusion

Side effects occur more frequently with long-term administration of the drug, e.g. more than 6 months and is related to total dose of the drug administered; therefore the effectiveness of Amiodarone in long-term treatment of patients with heart arrhythmia is limited because of the development of its adverse side effects.

Author details

Fereshteh Mehraein^{1,2}

Address all correspondence to: femehra@yahoo.com

1 Anatomy Department, Faculty of Medicine, Iran University of Medical Sciences, Tehran, Iran

2 Minimally Invasive Surgery Research Center, Iran University of Medical Sciences, Tehran, Iran

References

- [1] Vaughan Williams EM. Classification of anti-arrhythmic drugs: In: Sandoe E, Flensted-Jensen E, Olesen KII, eds. Symposium on Cardiac Arrhythmias, Stockholm, Sweden, Astra. 1970;449–472.
- [2] Siddoway LA. Pharmacologic principals of antiarrhythmic drugs. In: Podrid PJ, Kowey PR: eds. Cardiac arrhythmia: Mechanisms, diagnosis, and management. Baltimore, Md: Williams & Wilkins; 1995.
- [3] Bigger JT Jr. Antiarrhythmic treatment: an overview. Am J Cardiol. :1984;5:8B–16B.
- [4] Chung S, Reinier K, Teodorescu C, Evanado A, Kehr E, Al Samara M, et al. Epidemiology of sudden cardiac death: clinical and research progress in cardiovascular disease. Prog Cardiovasc Dis. 2008;51(3):213–28.
- [5] Wiener N, Rosenblueth A. The mathematical formulation of the problem of conduction of impulses in a network of connected excitable elements, specifically in cardiac muscle. Archives del instituto de cardiologia de Mexico. 1946;16(3):205–65.
- [6] Plomp TA. Analytical profiles of Amiodarone in analytical profiles of drug substances. San Diego. K Florey ed. Academic Press Inc., 1991.

- [7] Deltour G, Binon F, Tondeur R, Goldenberg C, Henaux F, Sion R, et al. Studies in the benzofuran series.VI. Coronary – dilating activity of alkylated and aminoalkylated derivatives of 3-benzoylbenzofuran. *Arch Int Pharmacodyn Ther*:1962;139:247–54.
- [8] Goldschlager N, Epstein AE, Naccarelli G, Olshansky B, Singh B. Practical guidelines for clinicians who treat patients with Amiodarone. Practice Guidelines Subcommittee, North American Society of Pacing and Electrophysiology. *Arch Intern Med*. 2000;160:1741–8.
- [9] Vassalo P, Trhman RG. Prescribing Amiodarone. *JAMA*:2007;298:1312–22.
- [10] Scheinman MM, Levine JH, Cannom DS, Friehling T, Kopelman HA, Chilson DA, et al. Dose-ranging study of intravenous Amiodarone in patients with life-threatening ventricular tachyarrhythmias. The Intravenous Amiodarone Multicenter Investigators Group. *Circulation*. 1995;92(11):3264.
- [11] Siddoway L. Amiodarone: Guidelines for use and monitoring. *Am Fam Physician*. 2003;68:2189–96.
- [12] Podrid PJ. Amiodarone: Reevaluation of an old drug. *Ann Intern Med*.1995;122:689–700.
- [13] Primeau R, Agh A, Giorgi C. Long term efficacy and toxicity of Amiodarone in the treatment of refractory cardiac arrhythmias. *Can J Cardiol*:1989;5:98–104.
- [14] Zimetbaum P. Amiodarone for atrial fibrillation. *N Eng J Med*. 2007;356:935–41.
- [15] Rosenbaum MB, Chiale PA, Halpern MS, Nau GT, Przybylski J, Levi RJ, et al: Clinical efficacy of Amiodarone as an anti-arrhythmic agent. *Am J Cardiol*.1976; 38: 934.
- [16] Connolly SJ. Evidence-based analysis of Amiodarone efficacy and safety. *Circulation*. 1999;100(19):2025.
- [17] Desai AD, Chun S, Sung RJ. The role of intravenous Amiodarone in the management of cardiac arrhythmias. *Ann Intern Med*.1997;127(4):294.
- [18] Vorperian VR, Havighurst TC, Miller S, January CT. Adverse effects of low dose Amiodarone: a meta-analysis. *J Am Coll Cardiol*:1997;30(3):791.
- [19] Harjai KJ, Licata AA. Effects of Amiodarone on thyroid function. *Ann Intern Med*. 1997;126:63–73.
- [20] Lambert MJ, Burger G, Galeazzi RL, Engler D. Are selective increases in serum thyroxine (T4) due to iodinated inhibitor for T4 monodeiodination indicative of hyperthyroidism? *J Clin Endocrinol Metab*.1982;55:1058–65.
- [21] Kennedy RL, Griffiths H, Gray TA. Amiodarone and the thyroid. *Clin Chem*. 1989;35:1882–7.

- [22] Newman CM, Price A, Davis DW, Gray TA, Weetman AP. Amiodarone and the thyroid: a practice guide to the management of thyroid dysfunction induced by Amiodarone therapy. *Heart*.1998;79:121–7.
- [23] Figge HL, Figge J. The effects of Amiodarone on thyroid hormone function: a review of physiology and clinical manifestations. *J Clin Pharmacol*.1990;30:588–95.
- [24] Martino E, Bartalena L, Mariotti S, Aghini-Lombardi F, Ceccarelli C, Lippi F, et al. Radioactive iodine thyroid uptake in patients with Amiodarone-iodine-induced thyroid dysfunction. *Acta Endocrinol* 1988;119:167–73.
- [25] Harjai KJ, Licata AA. Effects of Amiodarone on thyroid function. *Ann Intern Med* 1997;126:63– 73.
- [26] Brennan MD, Erickson DZ, Carney JA, Bahn, RS. Nongoitrous Amiodarone-associated thyrotoxicosis: evidence of follicular disruption in vitro and in vivo. *Thyroid*. 1995;5:177–83.
- [27] Bartalena L, Brogioni S, Grasso L, Bogazzi F, Burelli A, Martino E. Treatment of Amiodarone-induced thyrotoxicosis, a difficult challenge: results of a prospective study. *J Clin Endocrinol Metab*. 1996;81:2930–3.
- [28] Cappiello E, Boldorini R, Tosoni A, Piraneo S, Bernasconi R, Raggi U. Ultrastructural evidence of thyroid damage in Amiodarone-induced thyrotoxicosis. *J Endocrinol Invest*.1995;18:862–8.
- [29] Tsang W, Houlden RL. Amiodarone induced thyrotoxicosis:A review. *Can J Cardiol*: 2009;25(7):421–4.
- [30] Rormensch HH, Belhassen B, Swanson BN, Shoshani D, Spielman SR, Greenspon AJ, et al. Steady-state serum Amiodarone concentrations: Relationship with antiarrhythmic efficacy and toxicity. *Ann Intern Med*.1984;101:462–9.
- [31] Ernawati DF, Stafford L, Hughes FD. Amiodarone Induced pulmonary toxicity. *BR J Clin Pharmacol*.2008;66:82–7.
- [32] Kudenchuk PJ, Pierson DJ, Greene HL, Graham EL, Sears GK, Troubaugh GB: prospective evaluation of Amiodarone pulmonary toxicity. *Chest*.1984;86:541–548.
- [33] Camus P, Martin WJ, II, Rosenow EC, III. Amiodarone pulmonary toxicity. *Clin Chest Med*.2004;25:65–75.
- [34] Martin WJ, Rosenow EC. Amiodarone pulmonary toxicity: Recognition and pathogenesis (part:2). *Chest*.1988;93:1242–8.
- [35] Wolkove N, Baltzan M. Amiodarone pulmonary toxicity. *Can respir J*: 2009;16(2):43–48.

- [36] Uhal BD, Wang R, Laukka J, et al. Inhibition of Amiodarone induced lung fibrosis but not alveolitis by angiotensin system antagonists. *Basic Clin Pharmacol Toxicol*. Feb 2003;92(2):81–87.
- [37] Verchei A, Blazovics A, Gyorgy I, Feher E, Toth M, Szenasi G, et al. The role of free radicals in the pathogenesis of Amiodarone toxicity. *J Cardiovasc Electrophysiol*: 1993;4:161–177.
- [38] Mehraein F, Shams A. Amiodarone induced morphological changes in rabbit pneumocytes. *Yakhteh Medical Journal*:2009, 11(1):13–16.
- [39] Card JW, Raz WJ, Brien JF, Margolin SB, Massey TE. Differential effects of pirferri-done on acute pulmonary injury and ensuing fibrosis in the hamster model of Amiodarone induced pulmonary toxicity. *Toxicol Sci*:2003, 75:169–180.
- [40] Pitsiavas V, Smerdely P, Li M, Boyages SC. Amiodarone induces a different pattern of ultrastructural changes in the thyroid to iodine excess alone in both the BB/W rat and the Wistar rat. *Eur J Endocrinol*:1997;137:89–98.
- [41] Bartussio A, Marzini S, Agostini M, Alberti A, Cimenti C, Bruttomesso D, et al. Amiodarone inhibits lung degradation of SPA and perturbs the distribution of lysosomal enzymes. *AM J Physiol Lung Cell Mol Physiol*:2001;281:1189–99.
- [42] Hruban Z. Pulmonary and generalized lysosomal storage induced by amphiphilic drugs. *Environ Health Prospect*. 1984;33:53–76.
- [43] Linsson K, Jacobe J, Poletti VE, van Mook W, Cornelissen EL. Reactive type II pneumocytes in bronchoalveolar lavage fluid. *Acta Cytol*:2004;48:497–504.
- [44] Marchlinski FE, Gansler TS, Waxman HL, Josephson ME. Amiodarone pulmonary toxicity. *Ann Int Med*.1982;97:839–45.
- [45] Ashrafian H, Davey P. Is Amiodarone an underrecognized cause of acute respiratory failure in the ICU. *Chest*. 2001;120:275–82.
- [46] Iskandar SB, Abi-saleh B, Keith RL, Byrd RP Jr, Roy TM. Amiodarone-induced alveolar hemorrhage. *South Med J*. 2006;99:329–30.
- [47] Ott MC, Khoor A, Leventhal JP, Paterick TE, Burger CD. Pulmonary toxicity in patients receiving low-dose Amiodarone. *Chest*. 2006;123:646–51.
- [48] Seki S, Itagaki S, Kobayashi M, Hirano T, Iseki K. Amiodarone increases the accumulation of DEA in a human alveolar epithelium derived cell line. *Biol Pharm Bull*. 2008;31:1449.
- [49] Larsen BT, Vaszar LT, Colby TV, Tazelaar HD. Lymphoid hyperplasia and eosinophilic pneumonia as histologic manifestations of amiodarone induced lung toxicity. *Am J Surg Pathol*.2012;36:509.

- [50] Lewis JH, Mullick F, Ishak KG, Ranard RC, Raqsdale B, Perse RM. et al. Histopathologic analysis of suspected amiodarone hepatotoxicity. *Hum Pathol*:1990; 21: 59–67.
- [51] Ioannou GN, Boyko EJ, Lee SP. The prevalence and predictors of elevated serum aminotransferase activity in the United States in 1999–2002. *Am J Gastroenterol*. 2006; 101: 76–82.
- [52] Lewis H, Ranard RC, Caruso A, Jackson LK, Mullick F, Ishak KG. et al., Amiodarone hepatotoxicity: prevalence and clinicopathologic correlations among 104 patients. *Hepatology*. 1989 ;9(5):679–685.
- [53] Puli SR, Fraley MA, Puli V, Kuperman AB, Poucell S, Ireton J, et al. Amiodarone-associated phospholipidosis and fibrosis of the liver: light immunohistochemical and electron microscopic studies. *Gastroenterology*. 1984;86(5 Pt 1):926.
- [54] Alpert MA. Hepatic cirrhosis caused by low-dose oral Amiodarone therapy. *Am J Med Sci*. 2005;330(5):257–261.
- [55] Simon JB, Manley PN, Brien JF, Armstrong PW. Amiodarone hepatotoxicity simulating alcoholic liver disease. *N Engl J Med*. 1984; 311: 167–172.
- [56] Pollak PT, Shafer SL. Use of population modeling to define rational monitoring of Amiodarone hepatic effects. *Clin Pharmacol Ther*. 2004; 75: 342–351.
- [57] 57:Mäntyjärvi M, Tuppurainen K, Ikäheimo K. Ocular side effects of Amiodarone. *Surv Ophthalmol*: 1998;42(4):360.
- [58] Ingram DV. Ocular effects in long-term Amiodarone therapy. *Am Heart J*. 1983;106(4 Pt 2):902.
- [59] Haug SJ, Friedman AH: Identification of Amiodarone in corneal deposits. *Am J Ophthalmol*: 1991;111:518–19.
- [60] Kaplan LJ, Cappaert WE: Amiodarone keratopathy. correlation to dosage and duration. *Arch Ophthalmol*.1982; 100:601–2.
- [61] Flach AJ, Dolan BJ. Progression of Amiodarone induced cataracts. *Doc Ophthalmol*: 1993;83:323.
- [62] Thystrup JD, Fledelius HC: Retinal maculopathy possibly associated with Amiodarone medication. *Acta Ophthalmol*:1994; 72:639–641.
- [63] Macaluso DC, Shults WT, Fraunfelder FT. Features of Amiodarone- induced optic neuropathy. *Am J Ophtalmol*:1999;127:610.
- [64] Enseleit F, Wyss CA, Duru F, Noll G, Ruschitzka F. Images in cardiovascular medicine. The blue man: Amiodarone-induced skin discoloration. *Circulation*. 2006;113(5):e63.

- [65] Vrobel TR, Miller PE, Mostow ND, Rakita L: A general overview of Amiodarone toxicity: its prevention, detection, and management. *Prog Cardiovasc Dis.* 1989;31:393–426.
- [66] Kounis NG, Frangides C, Papadaki PJ, Zavras GM, Goudevenos J. Dose-dependent appearance and disappearance of Amiodarone-induced skin pigmentation. *Clin Cardiol.* 1996;19(7):592.
- [67] Orr CF, Ahlskog JE. Frequency, characteristics, and risk factors for Amiodarone neurotoxicity. *Arch Neurol.* 2009;66(7):865.
- [68] Ibsen HHW, Frandsen F, Brandrup F, Moller M. Epididymitis caused by treatment with Amiodarone. *Genitourin Med.* 1989;65:257–258.