

We are IntechOpen, the world's leading publisher of Open Access books Built by scientists, for scientists

6,900

Open access books available

185,000

International authors and editors

200M

Downloads

Our authors are among the

154

Countries delivered to

TOP 1%

most cited scientists

12.2%

Contributors from top 500 universities



WEB OF SCIENCE™

Selection of our books indexed in the Book Citation Index
in Web of Science™ Core Collection (BKCI)

Interested in publishing with us?
Contact book.department@intechopen.com

Numbers displayed above are based on latest data collected.
For more information visit www.intechopen.com



Reconstruction of the Face Following Cancer Ablation

Ata Garajei, Ali Arabkheradmand,
Mohammad Hosein Kalantar Motamed,
Alex E. Pazoki and Ashkan Rashad

Additional information is available at the end of the chapter

<http://dx.doi.org/10.5772/59746>

1. Introduction

Following ablation of a tumor that is the primary lesion or metastatic tissue, facial reconstruction is needed to restore and replace both hard and soft tissue losses. Ideally, reconstruction should strive to restore the maxillofacial form, quality of tissues, oral competence, and oral cavity functions, allowing the patient to return and adapt to society. Each area to be reconstructed must be considered individually to define the characteristics needed to provide the structural bed for total functional return. To focus on the reconstructive approaches and goals, an anatomic list should be compiled that includes:

1. Structures that are missing and their function,
2. Structures that are present but with compromised blood supply and/or function, and
3. Structures that are present and working well [1].

In general, goals of the reconstructive surgeon revolve around the restoration of functions, including normal deglutition with tongue and pharyngeal components; adequate oral competence; adequate mandibular mobility for functional mastication, with complete dental rehabilitation; airway support and patency after a tracheotomy to allow decannulation; fluent speech function paralleling deglutition; protective sensory function, especially sensations of the tongue, corneal blink reflexes, and trigeminal facial sensory nerves; and overall movement of the head and neck region, including shoulder lift and the muscles of the face [2]. As with all aspects of life, form usually follows function. Special attention must be paid to the preoperative facial aesthetic units that can be redefined, such as the mandibular symphysis, angle of the jaw, malar regions, nose, and teeth. The end result is a patient who is able to return to a normal lifestyle, engaging in routine activities of family life, work, and society. Reconstructive

principles have been formulated to increase the predictability of successful surgery. They include the use of a team approach to decrease operative time by synchronous resection and flap preparation; avoidance of multiple flaps and vein grafts whenever possible; minimizing of flap ischemia by shaping the flap while still vascularized; and slight overcorrection of the soft tissue deficiency with well-vascularized soft tissues [3]. The ideal technique must be fast, reliable, and cost efficient, imposing minimal morbidity on the patient [4]. Considerable debate involving immediate versus delayed reconstruction continues. The reconstructive process may involve multiple staged surgical procedures, for which the patient will require extensive preoperative counseling.

Advocates of delayed treatment wait months to years after the original surgical resection [5]. Factors that disfavor an immediate approach include the covering of the primary site and therefore the inability to detect a recurrence, a longer surgical time, the possibility of seeding cancer cells in newly dissected tissue planes, and an increased risk of graft infection from the contaminated salivary environment [6]. In contrast, Markowitz and colleagues [7] were not able to demonstrate any advantage for delayed reconstruction. In fact, secondary surgery, or two-stage reconstruction, is associated with higher overall complication rate, longer hospital stay, and greater cost [8]. Heller and associates [9] studied the long-term benefits in 47 patients who underwent immediate reconstruction of the mandible and found acceptable functional and long-term survival results. Leaving the patient unreconstructed was advocated by those who felt that an adequate follow-up period to detect recurrence was required before complete reconstruction. Since the advent of extensive noninvasive imaging systems such as computed tomography (CT), magnetic resonance imaging (MRI), and single photon emission CT (SPECT) technology, physicians are better able to identify an early recurrence. Over the past decade, one-stage reconstructive efforts using musculocutaneous flaps and microvascular free tissue transfers have significantly improved the quality of life of such patients. When such a reconstruction is performed during the primary surgery, it allows postoperative radiation treatment to be administered in a timely fashion. Delaying postoperative radiation can result in increased morbidity and increase the risk of recurrence [10]. Furthermore, delayed reconstruction is preceded by considerable fibrosis and soft tissue contraction, increasing the difficulty of subsequent reconstruction and compromising functional and cosmetic restoration.

The advantages of immediate or early reconstruction in summary are as follows: reduction in the total number of surgical procedures, less time that the patient must endure deformity and morbidity, protection and preservation of vital structures, reduced economic cost of treatment, and rapid oral rehabilitation and return to normal social lifestyle [4]. The surgical result after cancer resection of the oral cavity and oropharynx is a significant functional and cosmetic defect. For example, a partial glossectomy leaves a patient with varying degrees of articulation and swallowing difficulties, depending on the amount of tongue tissue removed. Bony resection of the involved mandible produces masticatory problems, as well as alteration of facial contour.

A multidisciplinary team is often involved in the assessment and treatment of cancer patients. This team consists of head and neck surgeons, plastic surgeons, oral and maxillofacial surgeons, maxillofacial prosthodontists, radiation oncologists, medical oncologists, radiolog-

ists, pathologists, speech and occupational therapists, internists, and psychologists. Preoperative evaluation of the patient must include a full assessment of the patient's overall health, ability to tolerate prolonged general anesthesia and blood loss, emotional and intellectual abilities, motivation, and expectations. In addition, the status of the patient's airway and nutritional needs must be addressed. Preoperative physical examinations, endoscopies or panendoscopy, and radiologic evaluation (CT scans, MRI) must outline the tumor size, location, and tissue type (biopsy) and rule out other concomitant lesions. The choice of which reconstructive modality is used depends on the extent of the defect preoperatively. The stage of the disease, the type of node dissection, and the availability of neck vessels are determined by the surgeon. Transverse CT scan and a lateral cephalogram provide the model of the mandible in two dimensions. Enhanced three-dimensional reconstructive CT scans further outline the preoperative mandibular contours and provide a more complete model. Before surgery, it is equally important that the patient be evaluated by a prosthodontist to aid in the achievement of proper bimaxillary arch alignment for postsurgical dental rehabilitation. Angiograms or noninvasive Doppler studies of the recipient and donor vessels are obtained if their adequacy is in doubt, providing information regarding their vascular status. Successful outcome can be ensured when the overall medical condition of the patient, the extent of the disease and prognosis, and the potential donor sites are thoroughly evaluated in the preoperative setting. [11]

Reconstruction in head and neck cancer patients requires a thorough understanding of function and tissue defects needs to be restored. Anatomically, a classification system for maxillofacial rehabilitation has been described.

Maxillary defects encompass minor defects of the hard and soft palate to extensive hard and soft tissue losses from resections of the maxilla, soft palate, sinuses, and adjacent structures (i.e., orbit and cheek).

Mandibular defects include alveolar segments with associated soft tissues, as well as portions of the tongue and floor of the mouth.

Facial defects include structures of the orbit, nose, ear, and/ or cheek. Defects of the oral cavity and oropharynx of small to moderate size can be successfully closed primarily, as long as tongue mobility and the gingival sulcus are not compromised. The goal of reconstructive surgery is to achieve coverage of the soft tissue defect, providing a definitive separation between the oral cavity and the neck. This can be accomplished by use of either split-thickness or full-thickness skin grafts or local, regional flaps. Functional and aesthetic outcomes become less favorable as the extent of resection increases. Large defects, depending on the location, require vascularized skin, soft tissue, and muscle. The advantages of myocutaneous flaps are abundant blood supply, greater reliability, better effectiveness and predictability. These pedicled osteomyocutaneous flaps facilitate resistance to infection and resorption, which is directly related to the osseous vascular supply. Flap geometry, bone availability, and muscle bulk restrict the degree to which the pedicled flap will adapt to the defect [12]. The use of free microvascular flaps is another option for reconstruction in this region. The free microflaps provide vascularized skin and bone to regions formerly considered impossible to reconstruct owing to limitations of the donor site tissue. The most widely used free microvascular flaps

are radial forearm flaps for the floor of the mouth defects involving segments of the mandible. Flap selection is based on the quantity and contour of bone required, as well as the volume of soft tissue necessary to accommodate the patient's needs. Whenever possible, it is best to use adjacent soft tissue. If this is not feasible, then a regional flap (e.g., pectoralis major myocutaneous flap or deltopectoral flap) may be required. Reconstruction of mandibular defects requires the use of myocutaneous and microvascular free flaps, in conjunction with osseointegrated dental implants, to provide satisfactory masticatory function. The goal of reconstructing a tooth-bearing mandible with adequate strength, with appropriate vestibular sulci, and without excessive soft tissue bulk continues to invite surgeons to develop new treatment options. Once the mandibular segments are properly aligned to restore a normal relationship with the maxilla, oral rehabilitation is easily accomplished by a maxillofacial prosthodontist. One area of oromandibular reconstruction that has challenged reconstructive surgeons is the restoration of preoperative sensory and motor functions. Both pedicled and free tissue flaps are large, insensitive tissue blocks that are used to replace oral tissues, thus compromising swallowing and speech mechanisms. It has been difficult to reproduce the complex neurosensory and muscular activities of the oral and pharyngeal viscera. There is a need for thin, pliable, sensate tissue to facilitate oral rehabilitation. Radial forearm, dorsalis pedis, lateral thigh, lateral arm, and fibular osteocutaneous flaps all possess thin, pliable tissue and identifiable sensory nerves that may be integrated into the reconstructive plan. [4] Urken and Moscoso [13] reported 80% sensory recovery in 40 cases of mandibular reconstruction with radial forearm flaps. Reconstruction of other bony defects typically requires bone grafting (cortical versus cancellous), bone containing vascularized pedicled or free flaps, and free nonvascularized bone grafts. With the advent of rigid fixation, bone grafting techniques have been enhanced, allowing broader applications. Alloplastic materials such as silicone and hydroxyapatite have been used to "fill in" bony defects and not to replace functional and structural tissue loss. The success of bone grafting is completely dependent on adequate stabilization, immobilization, and healthy soft tissue coverage. Once tissue has been irradiated, its repair capacity is compromised. In bone, hypovascularity, damage to osteoprogenitor cells and hypoxic tissue are responsible.

When a patient has received doses greater than 5000 rads (50 Gy) after ablative tumor surgery, significant reconstructive difficulties are encountered. Grafts placed into irradiated tissue beds have high rates of complications.

Hyperbaric oxygen (HBO) has been reported to help poorly perfused tissues by allowing hyperoxygenation [14], providing antimicrobial activity (cidal to anaerobes and static to microaerophilic organisms) [15], increasing fibroblastic proliferative activity [16], improving neovascularization and angiogenesis [17], increasing bone matrix formation [18], increasing mineralization [19], promoting osteoclastic activity to remove necrotic bone [20]; and enhancing the transport capacity of erythrocytes by increasing their deformability [21]. Ganstrom [22] suggested a protocol for HBO delivery: The patient is seated in a pressurized closed chamber that is above one atmospheric pressure. The patient breathes 100% oxygen, with oxygen toxicity avoided by regulating time and dose limits. Routinely, a single treatment (dive) varies from 90 to 120 minutes once or twice a day. Another protocol developed by Marx¹ is as follows:

20 sessions of HBO at 2.4 atmospheres (ATA) for 90 minutes of oxygen breathing, once daily for 5 or 6 days per week. This is followed by the surgical procedure. Postoperatively, the patient undergoes 10 sessions of HBO, following the same preoperative regimen. The disadvantage of HBO is time consumption without improvement in the quantity of tissue; only the quality is enhanced. Also, HBO is expensive, ranging up to \$50,000 for a treatment sequence. There are some contraindications to receiving hyperbaric oxygen, including optic neuritis, immune deficiency states, and end-stage chronic obstructive pulmonary disease. It is therefore very important to make a thorough assessment of the patient's medical history, pulmonary status, and chest radiograph. Occasionally, pulmonary function testing and ophthalmologic evaluation are required.

2. Grafts

2.1. Free skin grafting

Healthy skin grafts usually retain the same color as the donor area and retain the texture and appearance of normal skin (Figure. 1). Skin grafting to the oral cavity has been indicated for the correction of periodontal defects, minor and major preprosthetic defects, and implant surgery, as well as for the reconstruction of traumatic, congenital cleft, and tumor ablative surgery.

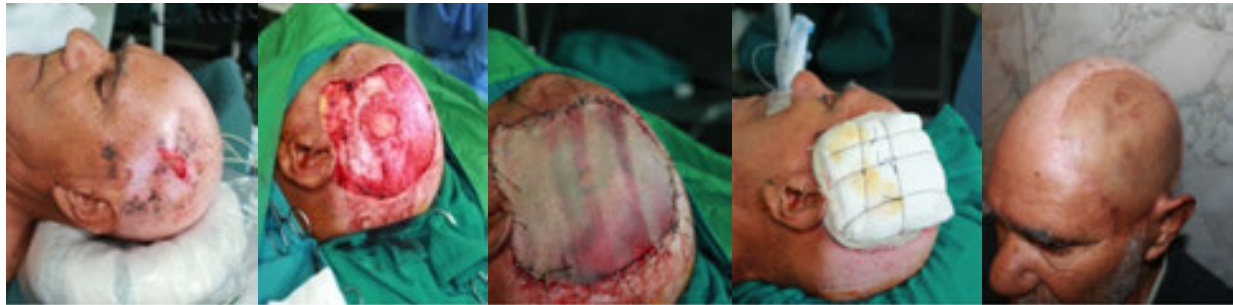


Figure 1. Free skin graft of the scalp.

Free grafting of the oral mucosa was first described by Propper [23] and was later refined by Fusing grafting on forehead and expanded mesh graft techniques. Skin grafts [24] are taken from a variety of donor sites. The anterior and lateral aspects of the thigh are frequently used because they can provide a sufficient quantity of graft material using a relatively simple procedure. The buttocks are also used as a donor site when cosmesis is a concern. Full-thickness skin grafts from a retroauricular location are chosen when a good color match is desired for facial reconstruction. For mucosal grafting, the cheek and palate are the two sites most widely used for oral transplantation. Theoretically, the tissue that is intended for reconstruction must closely match the nature of that which was removed. For example, lost periodontal tissues would best be replaced by partial-thickness skin grafts. Theoretically, the tissue that is intended for reconstruction must be of the same thickness as the tissue that was removed. Full-thickness skin grafts may be harvested by adjusting the dermatome to control the thickness of the graft and to confine the amount of donor tissue being removed. The desired thickness of the graft is generally dependent on the correct adjustment on the dermatome; manual dexterity, pressure, advancement of the dermatome, and experience. A similar harvest can be obtained using a scalpel and sharp dissection of the epidermis and dermis from the underlying connective tissues. Oral mucosal grafts from the palate are taken free handed with a scalpel. A Mormann mucotome with a 6-mm blade is also suited for instrumentation. Skin grafts are preferably outlined before injection with a local anesthetic solution. In this way, the tissues are not distorted with the infused solution. If using a dermatome, a donor site with evident capillary bleeding from the dermal layer can be dressed with a Telfa cover sponge impregnated with 1:100,000 epinephrine solution and placed over the site for approximately 10 minutes for hemostasis.

the dermatome to control the thickness of the graft and to confine the amount of donor tissue being removed. The desired thickness of the graft is generally dependent on the correct adjustment on the dermatome, manual dexterity, pressure, advancement of the dermatome, and experience. A similar harvest can be obtained using a scalpel and sharp dissection of the epidermis and dermis from the underlying connective tissues. Oral mucosal grafts from the palate are taken free handed with a scalpel. A Mormann mucotome with a 6-mm blade is also suited for instrumentation. Skin grafts are preferably outlined before injection with a local anesthetic solution. In this way, the tissues are not distorted with the infused solution. If using a dermatome, a donor site with evident capillary bleeding from the dermal layer can be dressed with a Telfa cover sponge impregnated with 1:100,000 epinephrine solution and placed over the site for approximately 10 minutes for hemostatic control. A dressing is then placed to prevent infection and to promote rapid healing. Traditionally, a dressing with petroleum jelly gauze over the donor site works well. There is no need for antibiotics unless there is clinical evidence of infection. When using the free-hand technique for skin graft acquisition, the donor site must be closed primarily, which is relatively easy in the lateral thigh, buttocks, and inguinal regions. The subcutaneous tissues are undermined widely to allow for a tension-free closure. Sutures are placed in the subcutaneous layer, as well as in the skin. There is no need for a drain, provided that dead space has been eliminated using the layered closure. The graft is then placed on a wet gauze towel, which helps prevent folding of the graft edges. A "mesher" can be used to cut multiple slits in the graft to transform it into a lattice, which increases its area two to three times its original size. A meshed graft also has greater pliability to follow irregular contours. The use of slits also creates sites where blood and wound exudate can escape, providing optimal healing conditions. In order for skin grafting to be successful, graft immobility is of primary importance, especially during the early healing phase of revascularization. There have been various methods to achieve this goal: sutures, splints, wires, bone screws, and fibrin adhesive. Stents can be produced in advance using conventional dental impression materials and techniques. Ideally, graft immobility should be maintained for 5 to 7 days. Essentially, a graft that is not protected has a greater likelihood of failure. The use of freeze-dried allergenic grafts has been shown in studies to be comparable to skin grafts for maintaining vestibular depth. Lyophilized dura as a wound dressing after periodontal surgery was reported to delay healing time, with subsequent hematoma formation. There have been many similar studies comparing the effectiveness of allografts and xenografts with that of traditional fresh autogenous skin grafts. At present, there are no benefits in using such materials for oral and maxillofacial reconstruction.

2.2. Bone grafting

When faced with a patient who requires reconstruction of significant hard tissue losses of the mandible, bone grafting is the most viable treatment option. The continuity defect must be prepared with a graft that provides several functions. The principles of bone induction and conduction have been studied extensively over the years. The graft must be able to provide a source of viable osteogenic cells, such that it maintains sufficient osseous bulk and resists resorption for subsequent prosthetic rehabilitation. It must also act as a precursor for bone

production and maturation by the bone induction principle. The graft must physically correct any facial form deficiencies resulting from underlying hard tissue losses.

2.2.1. *Autogenous bone grafts*

Autogenous bone is a viable treatment option. It can be particulate cancellous bone marrow, cortical blocks, or a combination of corticocancellous blocks. Particulate bone and cancellous marrow grafts contain numerous osteoprogenitor cells and allow a rapid revascularization. However, owing to their particulate nature, they require some form of containment via either soft tissue envelope-type pockets or rigid mandibular trays. The nonvascular corticocancellous blocks provide structure and bulk. The most common sites for acquisition are the anterior and posterior ilium, rib, and cranial bone. These types of grafts transplant more mineral content rather than osteocompetent cells. When grafting autogenous bone for reconstruction, one must pay close attention to the anatomic detail of the donor site as well as the amount, quality, and contour of bone to be used.

The iliac crest is widely accepted because it provides the greatest absolute amount of cancellous bone volume, as well as providing a cortical plate with significant structure and contour. When approaching the anterior ilium, the position and course of sensory cutaneous innervation must be considered. The nerve most often affected in this dissection is the iliohypogastric nerve, which courses over the area of the tubercle. The subcostal nerve traverses over the tip of the anterior superior iliac spine. The lateral femoral cutaneous nerve provides cutaneous sensory innervation to the lateral thigh region. It is located medially between the iliacus and psoas major muscles and then dives deep to the inguinal ligament, piercing the tensor fascia lata muscle. The incisions are therefore made lateral to the crest, avoiding the lateral femoral cutaneous nerve, extending from 2 cm posterior to the iliac tubercle, away from the subcostal nerve, to 1 cm posterior to the anterior superior spine. This places the incision away from the belt and waistband area, preventing excessive impingement. The blood supply to the anterior ilium is from terminal branches of the deep circumflex iliac artery. This lies medially and is avoided in the dissection. A roll is placed under the supinepositioned patient to elevate the iliac crest by lateral rotation at the hip. The patient is then prepped with povidone-iodine (Betadine) soap and paint and draped in a standard sterile fashion. Before sharp dissection, local infiltration of 1 % lidocaine with 1:100,000 epinephrine is used at the planned incision site for its local anesthetic and vasoconstrictive properties. A No. 15 blade is used to make the skin incision, extending to the subcutaneous tissues. Electrocautery is used to gain hemostatic control. The incision can then be manipulated to be centered over the crest. A sharp dissection is completed through the external and internal oblique musculature and periosteal layers to gain access to the bony crest. A subperiosteal reflection of the iliac crest in the medial direction is preferred, to avoid dissection of the tensor fascia lata muscles laterally, creating gait disturbances. Elevation of the iliacus muscle on the medial aspect of the ilium allows adequate access and visualization of the crest for retrieval of the desired bone graft. One must take care in this medial dissection to avoid accidental perforation of the peritoneum and/or bowel. Several osteotomy approaches, with either conventional mallet and osteotomes or air or electrical-driven saw blades, have been described to gain access to the cancellous bone. For

small quantities of particulate cancellous bone marrow (PCBM), the "clamshell" approach requires an osteotomy in the midcrestal position to a depth just through the cortical plates. The medial and lateral cortices can be "split" and greensticked apart to allow a route of entry to the cancellous graft. The "trap-door" technique allows access by creating a midline osteotomy and reflecting either medial or lateral cortices, pedicled on adjacent muscles. The "hollowed crest" approach osteotomizes the crest in a horizontal fashion by "de-capping" the crest and reflecting the crest cap laterally to gain access to the central marrow (e.g., Tschapp approach). Finally, Tessier's approach attempts to maintain the contour of the crest by performing oblique osteotomies off the lateral and medial aspects and retrieving the bone deep to the crest itself. If a corticocancellous block is desired, full-thickness osteotomies are completed on the medial aspect, detaching the block at the most medial aspect. Once cancellous marrow has been found, bone can be harvested using a 3/8- or 1/2 inch bone gouge and series of curettes. Upon maximal retrieval, closure of the donor sites begins. Any sharp edges are smoothed with bone files. Hemostasis can be achieved with electrocautery of small perforating vessels, placement of bone wax, or microfibrillar bovine collagen (Avitene) to tamponade bleeding. A drain is usually required, exiting at a site away from the incision and suctioned at a low intermittent strength to avoid continuous aspiration of marrow blood. Closure is achieved primarily, first reapproximating periosteal layers with 2-0 Vicryl suture, muscular layers with 4-0 Vicryl suture, subcutaneous tissues with 3-0 chromic gut suture, subcuticular with running, pull-out, and skin with 4-0 nylon/praline suture. A pressure dressing is helpful in the immediate postoperative setting and can be accomplished with cover sponges and foam tape [24].

Rib harvesting provides an alternative source of autogenous bone (Figure 2).

At the present time, its primary indication is to reconstruct the mandibular articulation with good adaptation to the temporal fossa and reestablishment of ramus height, and also to augment an atrophic mandible. Depending on size and contour, fourth, fifth, and sixth ribs are best. The sixth rib is most widely used because it can be accessed through an inframammary crease incision. At this level, minimal muscle is transected, as the dissection is between the pectoralis major and rectus abdominis muscles, thus preserving these for future muscle flaps. With the patient in the supine position, an inframammary incision is made through the skin and subcutaneous tissues until fibers from the pectoralis major muscle (from above) and rectus abdominis muscle (from below) are seen attaching on the sixth rib. A periosteal incision is placed at the greatest convexity on the lateral aspect of the rib, and with the use of periosteal elevators, the rib is exposed from its costochondral junction anteriorly to a posterior length as much as 18 cm. The length is limited posterolaterally by the latissimus dorsi muscle. Careful elevation of the periosteum with Molt and Freer elevators is most effective in preventing small tears in the pleura, as small projections of the pleural cortex may tear with the use of large elevators. Once reflection is completed, the resection is begun at the cartilage site, taking only 3 mm of cartilage medially in both adults and children. Including more than 3 mm increases the chance for cartilage separation from bone, especially in children. Once the anterior end is separated from the sternum, the rib can be elevated by placing an instrument on the undersurface of the rib, protecting the parietal pleura as the posterior extent is reached. The posterior end is then

cut, and the host end is smoothed with files. At this time, it is prudent to evaluate the pleura for tears. This can be done either visually or with the use of saline irrigation; the latter produces air bubbles if an air leak is present. Closure begins with periosteal approximation, followed by a muscle layer, subcutaneous tissue layer, and skin. Drains are usually not indicated. In children, a full morphologically normal rib will regenerate within 1 year, whereas in adults, an incomplete bone ossicle resembling a rib slowly forms over 1 to 3 years. [25]

Calvarial bone grafting for oral and maxillofacial surgery has progressed since its described use by Harsha and colleagues [26]. It has been widely used for vertical augmentation of maxilla and reconstruction of orbital wall and floor defects. It has a unique characteristic of early revascularization, which is directly related to the numerous vascular systems. As a result, the graft survives with little dimensional change. The paramedian portion of the parietal bone is the most likely area for harvest because it is the thickest, it is away from any vital structures (e.g., the superior sagittal sinus), and there is less chance that the scar will be visible in patients with male pattern baldness. The approach to this area requires a hemicoronal or bicoronal incision, posterior to the ear, and is carried through the five scalp layers (skin, subcutaneous tissues, galea-aponeurotic layer, loose connective tissue, and periosteum). Bleeding skin vessels are hemostatically controlled with Raney clips. The use of electrocoagulation may destroy hair follicles and result in patchy alopecia. A bur is used to create the shape of the desired graft in the outer cortex to the level of the cancellous marrow. Then, with the use of curved osteotomes, the outer table can be cleaved from the inner table in the plane of the interposed cancellous marrow. The incision is closed primarily in layers. Pressure dressings with "crani-caps" are placed to allow adaptation of the elevated tissues to bony scalp.

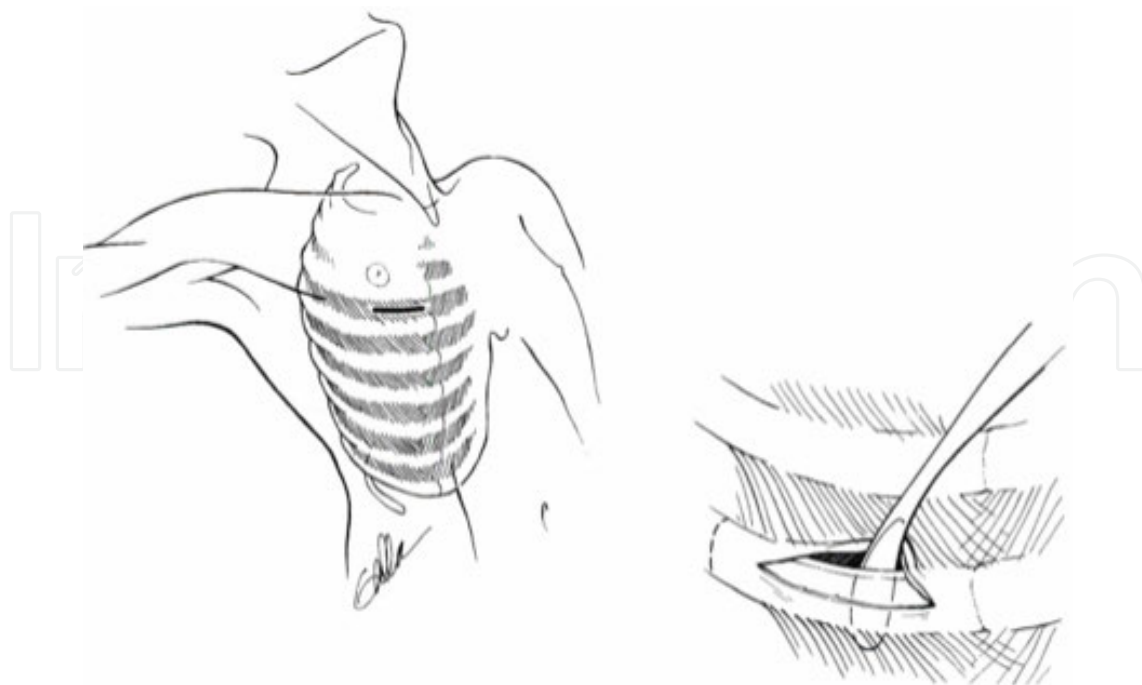


Figure 2. Rib harvesting

Rigid plate fixation [27] has resolved the problems with nonunion, but resorption continues to occur due to the stress shielding. Branemark and colleagues [28] in 1975 first reported the successful use of a block bone graft stabilized by a titanium plate in traumatic cases. Rigid plates have been well adapted to the preselected mandible to achieve the functional contours necessary for reconstruction. Li and associates [29] established a technique to maintain mandibular position with respect to the temporomandibular joint. Before resection, the mandible is placed in maximal intercuspation, with condyles seated firmly in the fossa.

Miniplates and screws are spanned bilaterally from the maxillary zygomatic processes to the mandibular ascending ramus. The plate is then adapted to the contour of the existing mandible, and the resection takes place. In this technique, the posterior facial height is maintained, as well as accurate adaptation of the condyle to the fossa. Ardary [30] also commented on the importance of adequately stabilizing the free bone graft with the use of a mandibular reconstruction plate in a report of nine consecutive cases with successful results. Absolute stability promotes neovascularization of the graft by permitting vascular ingrowth while simultaneously allowing for immediate postsurgical jaw function. Boyne [31] compared segmental defects in dogs that were bridged together with block bone or stabilized with a plate or with particulate bone and marrow within a Vitallium tray. He found significant resorption with the block bone, whereas complete bony regeneration and union were evident when the PCBM and tray were used. Dacron urethane mandibular trays were used with autogenous iliac crest bone in one study that showed retention of 80% of bony height over a 3-year period, with little alteration in the complication rate compared with standard reconstructive techniques [32]. The Dacron tray is a lightweight, biologically inert structure that is easy to adapt to the mandible, requiring a more limited access. Its radiolucency allows one to appreciate the radiographic monitoring of the bone graft. And, finally, reconstruction of the bone graft with fixation plates and metallic trays requires a second surgical procedure before endosseous dental implant placement, whereas the Dacron tray does not require removal. Mandibular reconstruction with reimplantation of resected mandibles that are hollowed out and function like a tray has been studied by Jisander and coworkers [33]. The prepared segments act as a matrix for new bone formation and as a carrier for transplanted cancellous bone. [34].

2.2.2. *Allogenic bone grafts*

Allogenic grafts are those taken from the same species but transplanted into a different individual. [35]. The major disadvantage of FFB is the small risk of disease transmission. [36] Bone substitutes, or alloplastic materials, have been used to recontour alveolar defects and as extenders in bone graft systems for reconstruction of major continuity defects. One such substitute is hydroxyapatite. It does not have the mechanical properties necessary for reconstructing major defects but provides a temporary matrix for future bone growth because of its osteoconductive nature.

Xenografts of bone and cartilage such as bovine bone mineral have been used as fillers or spacers in orthognathic and preprosthetic surgeries, as well as sinus grafting procedures (Figure 3) and alloplastic trays are commonly used to bridge the gap and to carry PCBM to fill mandibular defects. Its drawback is the risk of disease transmission. The Dacron-coated

polyurethane crib is flexible, lightweight, biologically inert, easy to trim and adapt to the mandible, and radiolucent, which allows assessment of postoperative bone graft healing. Its disadvantages include its reliability in long-span mandibular defects, where intermaxillary fixation or internal reinforced metal rods are used for added rigidity.

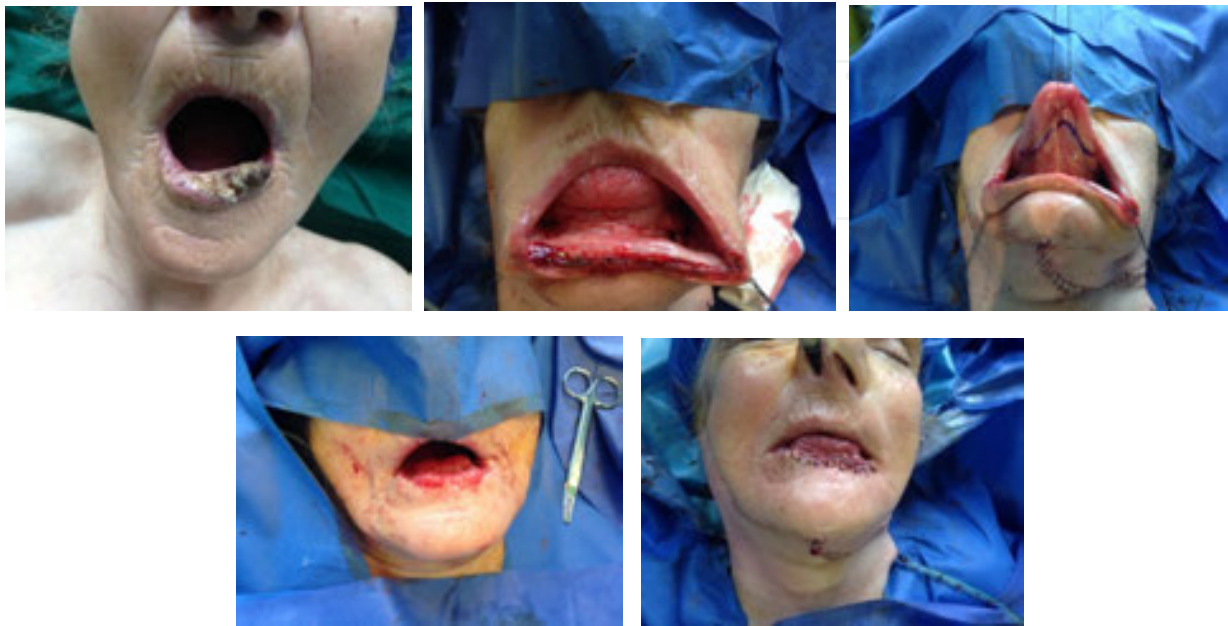

Figure 3. Polyurethane crib (left), alveolar bone grafting (right)

Metallic alloplastic trays have the ability to maintain the normal relationship of the residual mandibular segment without additional fixation, so the patient resumes normal functions earlier. The titanium tray is harder than the Dacron tray but softer than cobalt-chromium and stainless steel trays. The disadvantages of metallic cribs are that they have very high flanges in order to carry an adequate volume of bone, thus interfering with preprosthetic procedures and dental prostheses. This leads to tray removal. A simple technique was recently reported by Tayapongsak and coworkers [37] in designing a custom-made inferior border titanium crib (IBTC). The disadvantages of the custom-made IBTC are the use of intermaxillary fixation and its nonresorptive ability.

3. Flaps

Soft tissue flaps can be classified according to the method of movement (i.e., local or distant); according to blood supply, such as axial or random pattern; and according to the composition of the flap, such as cutaneous, myocutaneous, osteomyocutaneous, or fasciocutaneous. Random flaps consist of skin with the underlying subcutaneous tissues and frequently muscle. Their blood supply is provided by the plexuses from the dermal and subdermal regions. Axial patterned flaps have their perfusion from dominant vessels present with the flap. They may also contain secondary vessels to increase the flap's viability.

3.1. Local flaps

3.1.1. Lingual tongue flap

The use of tongue flaps was described as early as 1909 by Lexer, for the repair of cheek defects. Since then, tongue flaps have been described for facial and labial reconstruction [38]. Flaps from the dorsum of the tongue are designed lengthwise, usually paramedian, with a posterior or anterior base. Transverse flaps do not cross the midline of the body of the tongue, because its blood flow would be compromised. The posteriorly based dorsal tongue flap relies on the dorsal lingual artery for its survival. It usually runs the entire length of the tongue, from the circumvallate line to its anterior tip. The thickness of the flap is approximately 8 mm and is uniform, to avoid a wedge-shaped cross section. The flap includes mucosa and the adherent stratum of the superior lingual musculature. The flap, once elevated, can be rotated laterally and backward to repair the defect in the retromolar trigone or tonsillar region on the ipsilateral side, or to repair a cheek defect. This donor region is closed by direct suture, with meticulous attention to hemostasis. Dead space is eliminated by interrupted buried sutures, thus preventing hematoma formation and airway compromise. This closure does not affect the tongue's lingual function.

The anteriorly based dorsal tongue flap offers greater mobility, because the pedicle is on the free end of the tongue, and is thus more versatile. The tip of the tongue is supplied by the anastomotic ranine arch, which is the terminal branch from the forward continuation of the lingual artery. This vessel gives off numerous branches as it ascends to the tip. Thus the flap, which appears delicate and friable, is more robust than imagined. This type of flap is indicated mainly to repair anterior cheek and commissural defects. With outward rotation, it can be used to replace the lining and vermilion of the lips. With downward rotation, it is able to repair floor of the mouth defects in the anterior region, as well as anterior lateral defects when rotated through a window in the median raphe of the tongue. And by forward reflection, it can cover oronasal defects in cleft patients and excisional defects of the hard palate. As opposed to the posterior-based flap, the anterior one requires second-stage surgery to divide the tongue at its pedicle in order to maintain speech and swallow function.

The transverse dorsal tongue flap is usually created in bipedicle form, such that the flap is transferred anteriorly from the tongue to the floor of the mouth or to the lip, and the donor defect is closed primarily by approximation. The disadvantage is that tongue length is diminished and blunting of the free end occurs. This type of flap is recommended in cases in which length is not a factor.

The perimeter flap is developed by a vertical incision just inside and parallel to the border of the tongue. These flaps are narrow and may be uni- or bipedicle in design. Their use is indicated mainly for repair of lip vermilion defects, and variations in flap design are possible. Because of the anastomotic ranine arch, there is no compromise of vascular supply.

Dorsoventral flaps are derived from the lingual tip by a horizontal incision, inside and parallel to the edge, and are wider than they are long. They can be reflected dorsally on a posterior base to reconstruct the lining of the upper lip. The flap can also be reflected ventrally on an

anterior base for lower lip reconstruction. A combination of both types of flaps can be incorporated to reconstruct vermilion and lining. The only drawback in creating these flaps is the resultant shortening of the tongue, which may affect speech and swallow mechanisms.

Ventral-based flaps have been described for repairs of anterior floor of the mouth defects, where two parallel lengthwise posterior-based flaps are reflected and rotated to the anterior defect. The resultant donor site cannot be closed primarily because of obvious contraction of the tongue. In this case, a skin graft can be placed to cover the donor site and is in fact well tolerated, with minimal effect on tongue mobility. This flap also has good results for vermilion reconstruction [38] (Figure 4)




Figure 4. Reconstruction of the lower lip with a pedicled tongue flap.

3.1.2. Nasolabial flap

Nasolabial flaps are more useful for intraoral reconstruction when they are based inferiorly. With this design, floor of the mouth, tongue, and anterior mandibular defects can be reconstructed (Figure 5). In the dissection, it is important to include a thick portion of the underlying subcutaneous tissues to provide adequate blood supply to the flap. Its primary supply is from the branches of the facial artery. The flap can be based superiorly for upper alveolar or palatal

Figure 4. Reconstruction of the lower lip with a pedicled tongue flap.

Nasolabial Flap

Nasolabial flaps are more useful for intraoral reconstruction when they are based inferiorly. With this design, floor of the mouth, tongue, and anterior mandibular defects can be reconstructed (Figure 5). In the dissection, it is important to include a thick portion of the underlying subcutaneous tissues to provide adequate blood supply to the flap. Its primary supply is from the resurfacing. A long, tapered flap is designed on the hairless skin edge along the nasolabial fold. The epithelium is removed at the base and tunneled through the cheek. It is then sutured into the oral cavity at the desired site and to its contralateral counterpart as the flaps lie side by side to provide wide coverage of the deficiencies.

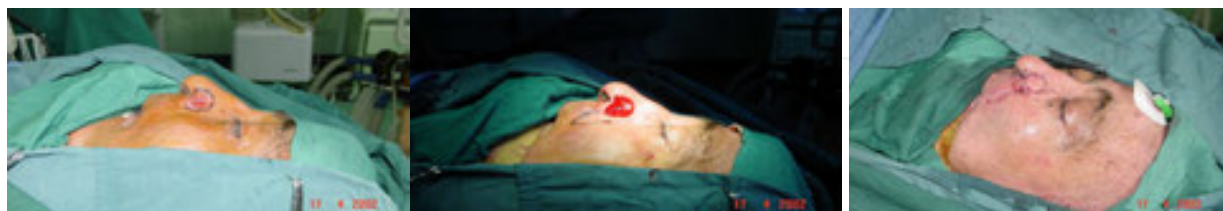

Figure 5. Nasolabial flap.

Cervical Island Skin Flap

3.1.3. Cervical island skin flap

For defects that include the oral mucosa, gingiva, and part of the mandible after excision of gingival carcinomas, a cervical island skin flap has been described for reconstruction, alongside a bone graft for the hard tissue mandibular bony defect [39]. The cervical island flap was first described by Farr and colleagues [40]. The size of the skin island depends on the extent of the resected oral mucosa and gingiva, which in most cases is 2 to 2.5 cm in width and 4 to 5 cm in length. A skin margin of 3 mm is elevated to suture the skin of the flap to the oral mucosa (Figure 6).

11

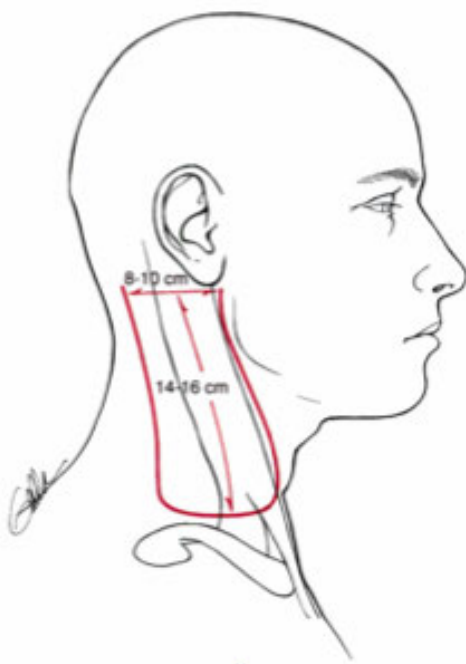


Figure 6. Cervical Island Skin Flap

mandible and introduced medial to the mucosal defect. The margin of the denuded distal part of the flap is sutured to the lingual edge of the cut surface of the remaining mandible. The border of the skin island is sutured to the mucosa of the floor of the mouth and the anteroposterior adjoining gingiva, thus forming a partition. The lateral

Figure 6. Cervical Island Skin Flap

flap. The pocket can then be filled with autologous PCBM or hydroxyapatite granules. The flap is passed under the mandible and introduced medial to the mucosal defect. The margin of the denuded distal part of the flap is sutured to the lingual edge of the cut surface of the remaining mandible. The border of the skin island is sutured to the mucosa of the floor of the mouth and the anteroposterior adjoining gingiva, thus forming a partition. The lateral margin of the skin island is sutured to the buccal mucosa. This creates a pocket from the cervical flap. The pocket can then be filled with autologous PCBM or hydroxyapatite granules. The study by Tashiro and associate [39] showed successful reconstruction using this technique. Reconstructed mandibles lost approximately 8% to 22% of their bone height, with patients wearing their prostheses comfortably. Minimal necrosis of the flaps was noted.

3.1.4. Bilobe skin flap. Bilobe flaps are double transposition flaps that share a single base (Figure 7). Similar to single transposition flaps, bilobe flaps move around pivotal points located at their base and develop independent pivotal points as they pivot. Since each flap or lobe moves around an independent pivotal point, each lobe develops and individual standing cutaneous deformity. The greater is the arc of movement about their pivotal points, the larger are the standing cutaneous deformities.

Bilobe Skin Flap Bilobe flaps are double transposition flaps that share a single base (Figure 7). Similar to single transposition flaps, bilobe flaps move around pivotal points located at their base and develop independent pivotal points as they pivot. Since each flap or lobe moves around an independent pivotal point, each lobe develops and individual standing cutaneous deformity. The greater is the arc of movement about their pivotal points, the larger are the standing cutaneous deformities.

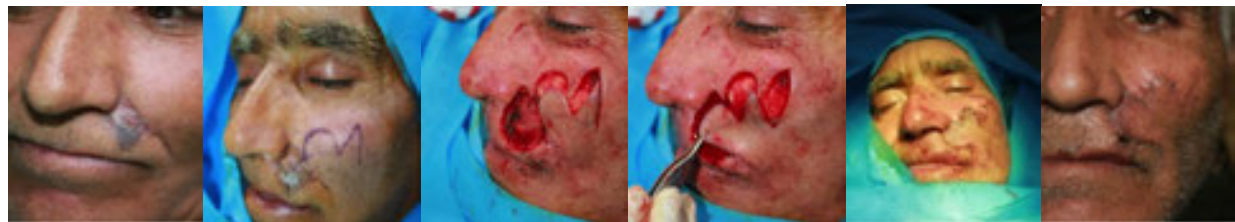

Figure 7, Bilobed skin flap

Regional Flaps

PEDICLED FACIOCUTANEOUS/MYOCUTANEOUS/MUSCLE FLAPS

The pectoralis major myocutaneous flap was first introduced by Ariyan [41] in 1979, and along with the forehead flap, it was the most commonly used flap for head and neck reconstruction in the early 1980s. However, these flaps consisted of only epithelium and some subcutaneous tissue

and therefore were not appropriate for defects in which bulk had to be restored. The total scheme of soft tissue reconstructive management is dependent on the type of pathology being treated. For example, the management of oral cancer requires immediate soft tissue reconstruction. Also, in areas where reconstructive bone plates are used, it is usually paramount to have the plate covered with a muscle flap when postoperative adjuvant radiotherapy will be used, which helps prevent skin dehiscence overlying the bone plate.

Sternocleidomastoid Myocutaneous Muscle Flap

The sternocleidomastoid (SCM) myocutaneous flap was first described by Owen [42] in 1955. This type of flap has been reported in the literature for a variety of indications [43]. These include aiding in mucosal reconstruction by providing an epithelial lining; creating a facial cover to close mouth to have the plate covered with a muscle flap when postoperative adjuvant radiotherapy will be used, which helps prevent skin dehiscence overlying the bone plate.

3.2.2. *Sternocleidomastoid myocutaneous/ muscle flap*

The sternocleidomastoid (SCM) myocutaneous flap was first described by Owen [42] in 1955. This type of flap has been reported in the literature for a variety of indications[43]. These include aiding in mucosal reconstruction by providing an epithelial lining; creating a facial cover to close orocutaneous fistula; releasing scar contractures, especially around the angle and submandibular regions; providing additional tissue to allow for a passive, tension free closure; and, when used as a muscle flap, obliterating dead space around a bone graft. It is also a very vascular flap that, when used in an irradiated tissue bed, provides additional perfusion to the bone graft material. This strap muscle originates at the medial third of the clavicle (muscular) and near the manubrium (tendon). The SCM is innervated by a branch of the spinal accessory nerve, which is found between the internal carotid artery and the internal jugular vein, outside the carotid sheath, and enters the deep surface of the muscle. The dominant blood supply is from branches of the occipital artery and corresponding vein. The muscle also receives blood supply from the superior thyroid artery and vein, and the entire muscle and overlying skin remain viable (Figure 8). The inferior third aspect of the muscle is supplied by a branch of the inferior thyroid artery and a branch of the thyrocervical trunk, which may be sacrificed if not contained in the desired flap design. The dissection begins by outlining the skin paddle at the anterior and posterior borders with a scalpel and dissecting through skin, subcutaneous tissues, and platysmal muscle until the SCM is reached. The myocutaneous flap is then separated from the clavicular and sternal origins and deeply dissected to the level of the carotid sheath. This dissection is carried superiorly, always taking care to avoid trauma to the contents of the carotid sheath. At the level of the carotid bifurcation and anterior to the muscle, the branches of the superior thyroid artery are found. Just below the level of the bifurcation, the spinal accessory nerve enters the posterior dorsal surface of the muscle. It is important that this nerve be preserved, to maintain the function of the trapezius muscle. Thus, neuromuscular blocking agents are not recommended. The flap is developed until adequate length to reach the recipient site without tension is achieved. One of the drawbacks of this flap is the limited size and arc of rotation. For this reason, these flaps are not used for defects involving the anterior floor of the mouth. Functionally, use of the SCM muscle for reconstructive purposes does not lead to the inability to rotate the head to the contralateral side, as this function is maintained by other muscles (splenius capitis, trapezius, and suprahyoid muscles of the contralateral neck).

3.2.3. *Temporalis muscle flap*

Temporalis flap can provide abundant tissue for soft tissue reconstruction of the upper two thirds of the face, as well as reconstruction of the oropharynx (Figure 9). Use of this flap has been studied extensively. It was first described by Golovine, who used the flap for the obliteration of dead space after orbital exenteration as cited by Huttenbrink [44]. It is used to reconstruct composite defects of the maxilla, as well as areas of scar contracture and soft tissue deficiencies. Cheung [45] described the use of the temporalis flap for intraoral defects after maxillectomies in cats and the healing mechanisms of the flap in the oral cavity. He found a biologic response similar to that of humans, with regeneration of smooth palatal mucosa,

this flap is the size and arc of rotation. For this reason, these flaps are not used for defects involving the anterior floor of the mouth. Functionally, use of the SCM muscle for reconstruction purposes does not lead to the inability to rotate the head to the contralateral side, as this function is maintained by other muscles (splenius capitis, trapezius, and supahyoid muscles of contralateral neck).

Research Article
 Reconstruction of the Face Following Cancer Ablation
 658
<http://dx.doi.org/10.5772/59746>

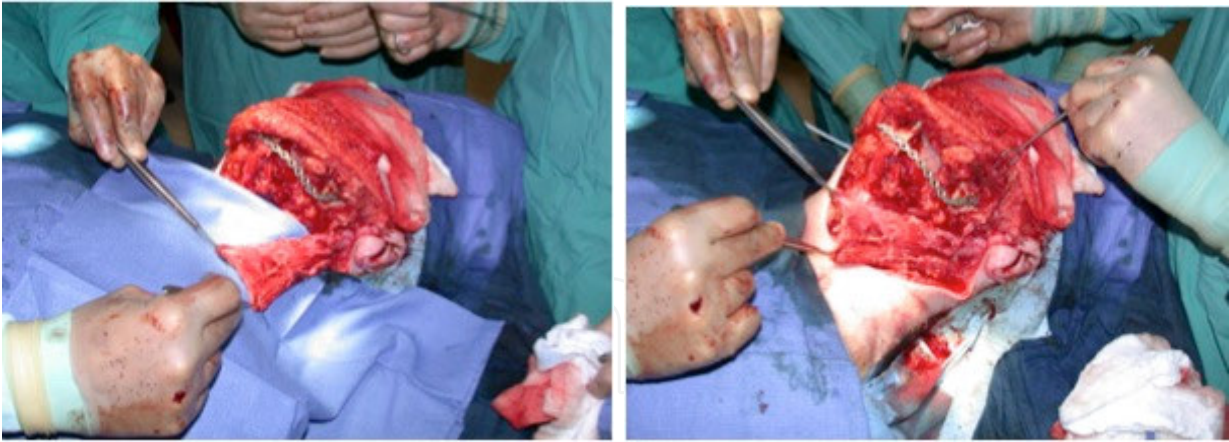

Figure 8. Sternocleidomastoid Myocutaneous/ Muscle Flap

Temporalis Muscle Flap Anatomically, the fan-shaped, bipennate temporalis muscle is based on the temporal artery and vein. The anterior division of the maxillary artery (which arises from the second division of the maxillary artery) The anterior deep temporal artery enters the muscle approximately 1 cm anterior to the coronoid process, whereas the posterior branch is 1.7 cm posterior to the bony landmark. Thus, the mobilized flap, consisting of the fascia, muscle, and pericranium, can be split into anterior and posterior flaps. It is used to reconstruct dead space after orbital exenteration as cited by Huttenbrink [44]. It is used to reconstruct composite defects of the maxilla, as well as areas of scar contracture and soft tissue deficiency. Cheung [45] described the use of the temporalis flap for intraoral defects after maxillectomy in cats and the healing mechanisms of the flap in the oral cavity. He found a biologic response similar to that of humans, with regeneration of smooth palatal mucosa, without ruga formation.

13

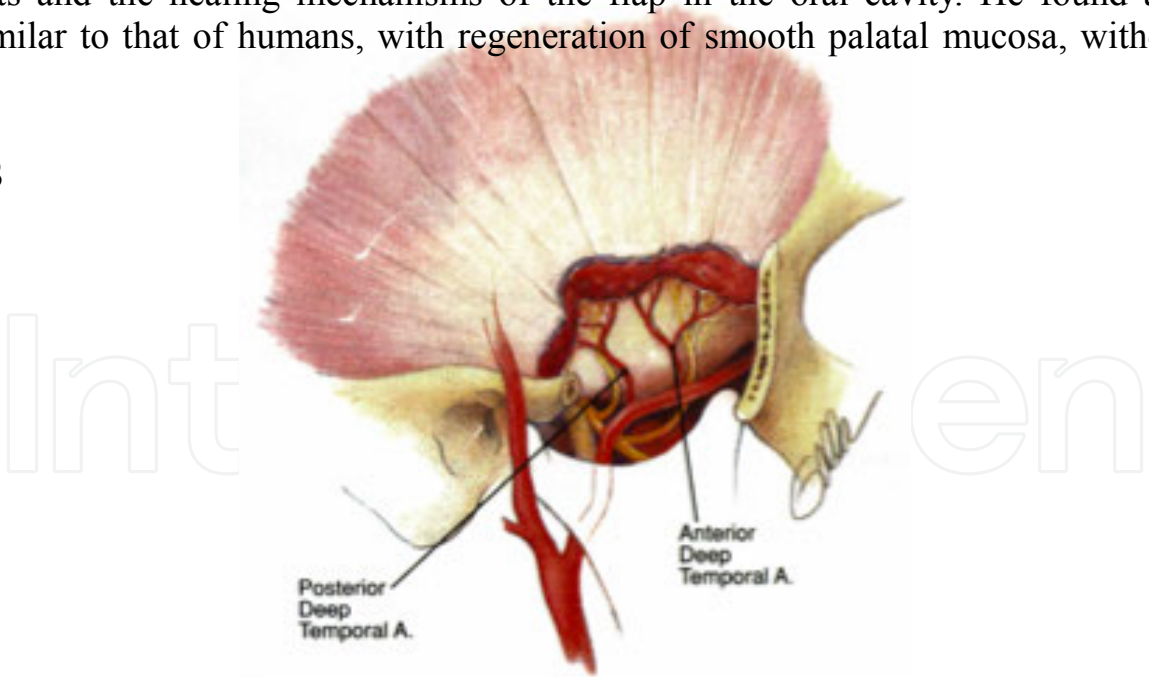


Figure 9. Temporalis muscle

An additional flap can be pedicled from the middle temporal artery, which arises from the superficial temporal artery immediately superior to the zygomatic arch. Located immediately

deep to the subdermal layer is the superficial temporal fascia, which is a thin, highly vascular layer of moderately dense connective tissue. On its deep aspect, a very loose areolar tissue separates it from the deep temporal fascia. A temporoparietal fasciocutaneous flap described by Upton and colleagues [46] can be raised, as it is based on the superficial temporal artery. It is a prefabricated flap, in that a full-thickness skin graft is placed on the temporoparietal fascia 2 weeks before reconstruction. Access to the temporal flap is via a bicoronal incision and flap. It has the advantage of being very thin and quite sturdy and is suitable for the maxillofacial region. The dissection extends to the deep temporal fascia until the entire muscle is exposed. In this way, the temporal branch of the facial nerve (cranial nerve VII) is protected. In a subperiosteal plane, the muscle is then stripped of the temporal bone. When used for reconstructing the oral cavity, passage to enter the mouth requires fracturing the zygomatic arch as far posteriorly and anteriorly as possible and displacing it laterally, providing a tunnel into the mouth. The flap can then be rotated by dividing the coronoid process carefully, so as not to sever the vascular pedicle. Its ability to provide a large amount of tissue for reconstructing facial defects results in a mild cosmetic deformity at the donor site (i.e., hollowing of the temporalis fossa). However, with time, the depression may be hidden either by scar tissue or by hairstyle. If only an anterior flap is being used, the posterior flap can be rotated to fill in the prominent depression. Alloplastic materials, such as acrylic, have been used to fill in the defect. If used, the posterior flap can be rotated to fill in the prominent depression. Alloplastic materials, such as acrylic, have been used to fill in the defect.

3.2.4. Forehead myocutaneous flap

The forehead flap is a powerful tool in nasal and surrounding area reconstruction and is currently the method of choice for resurfacing large nasal defects [47]. It has evolved from the forehead flap is a powerful tool in nasal and surrounding area reconstruction and is currently the method of choice for resurfacing large nasal defects [47]. It has evolved from its origins as a forehead-based flap with significant donor site morbidity and excessive bulk to an elegant (procedure) using a narrow pedicle with adequate length and appropriate thickness to achieve an esthetically pleasing result for both the patient and surgeon [48] (Figure 10).

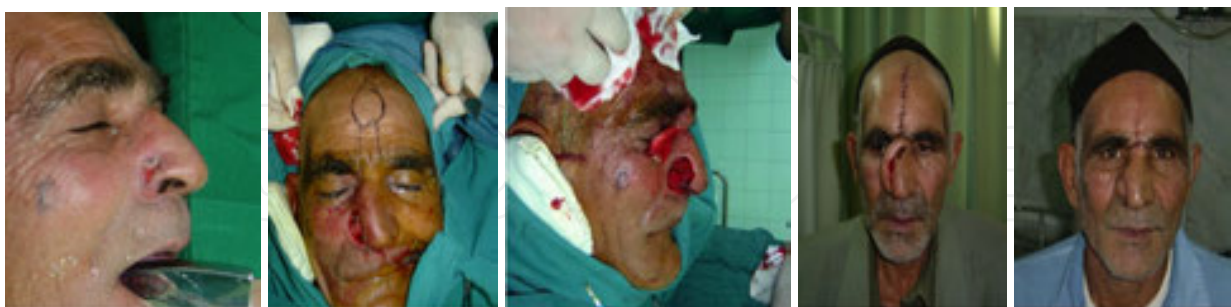

Figure 10. Forehead Myocutaneous Flap

Advances in understanding of the anatomic basis for forehead flaps have allowed surgeons to expand the versatility of the pedicle without compromising viability. The midline skin paddle has advantages, which include a favorable donor site scar [49]. The forehead flap is multilamellar, consisting of skin, subcutaneous tissue, frontalis muscle, and a thin, areolar layer. Elevated as a full thickness flap based on a paramedian pedicle, its supratrochlear vessels pass deeply over the periosteum at the supraorbital rim and travel vertically upward through the muscle to lie at an almost subdermal position under the skin at the hairline. It is both a myofascial and axial flap, and highly vascular [50] (Figure 11).

deeply over the periosteum at the supraorbital rim and travel vertically upward through the muscle to lie at an almost subdermal position under the skin at the hairline. It is both a myofascial and axial flap, and highly vascular [50] (Figure 11).

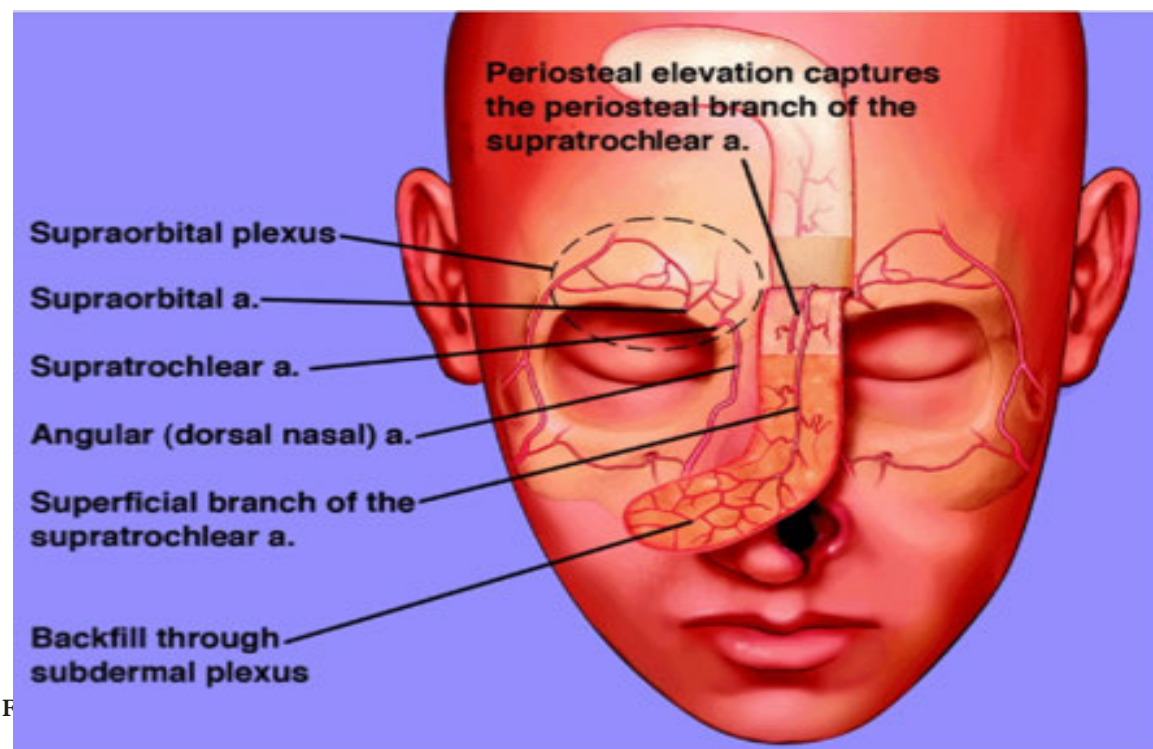


Figure 11. Forehead Myocutaneous Flap with this flap has been an important, managing factor for these problems (Figure 12). [51]

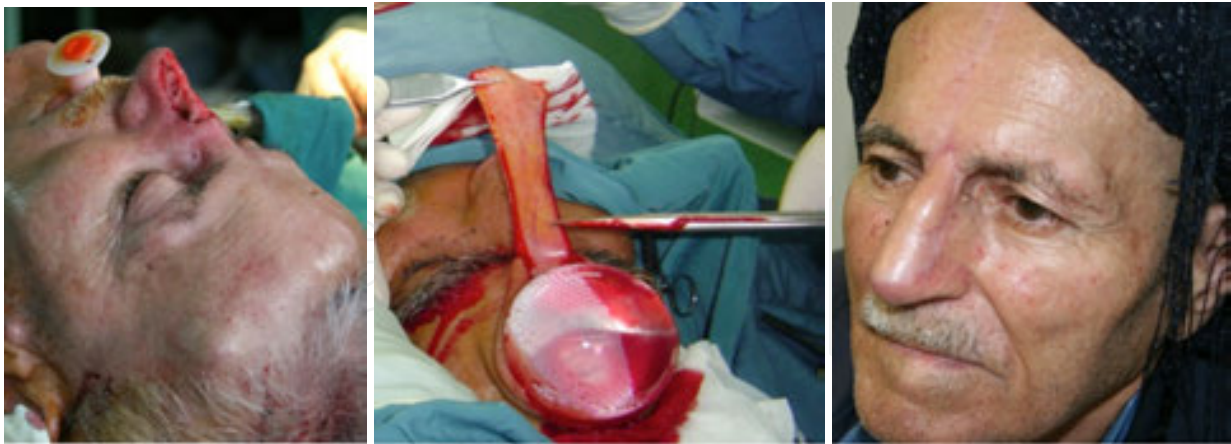

Figure 12. Forehead Myocutaneous Flap

Temporoparietal Fasciocutaneous Flap
Over the years, many uses have been found for the well-vascularized and long-reaching pedicled temporoparietal fascial (TPF) flap (Figure 13).

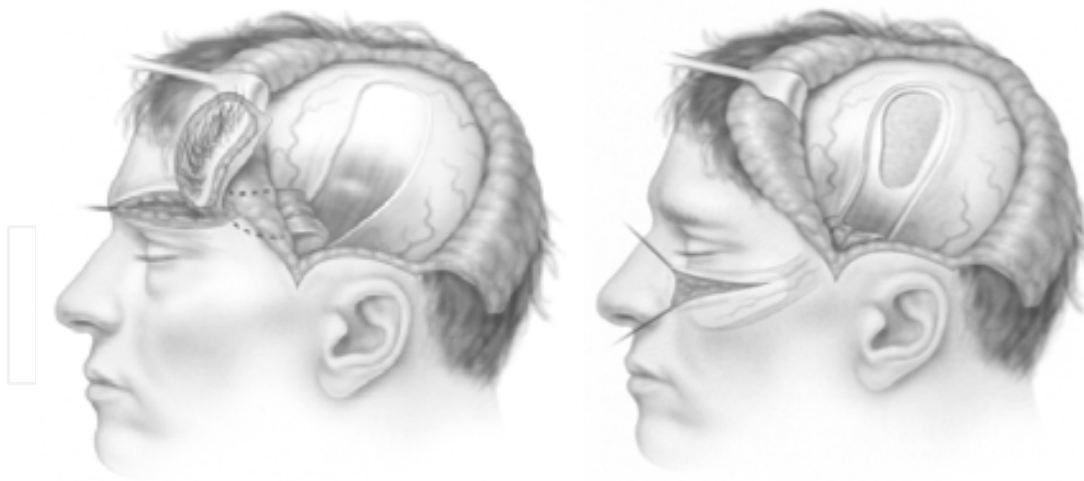

Figure 13. Temporaloparietal Fasciocutaneous Flap

Figure 13. Temporaloparietal Fasciocutaneous Flap

It has been used for several reconstructive situations, including functional and esthetic restoration of the extended maxillectomy; mandibulectomy; anterior skull base; oral cavity;

base of tongue, and pharyngeal, orbital, auricular, mastoid, scalp, dura, cheek, lip, eyelid, and brow deficits. It also provides excellent vascular inflow for cases of infection such as with osteoradionecrosis of the facial or mandibular bones, or coverage for carotid protection [51]. When confronted with a head and neck defect following tumor resection or trauma, especially in a chemoradiated field, one must call upon a hardy, reliable and flexible flap for reconstruction, such as the TPF flap. Additionally, the TPF flap avoids the relatively awkward positioning of free flaps and musculocutaneous flaps and still is richly vascular. There are several variations of the TPF flap, including the superficial temporal vessels-pedicled pericranial-galea flap, which can be used in combination with an iliac bone graft to reconstruct the orbital floor, and palate in total maxillectomy defects with globe preservation [51]. The TPF flap can be used in composite with outer-table or full-thickness calvarial for maxillectomy/ orbital floor or mandibular deficits. This modification was originally described by Conley [51] but with the entire temporalis muscle. This tissue also has been used as a free microvascular flap. This tissue also has been used as a free microvascular flap.

3.2.6. Scalp myocutaneous flap

Scalp Myocutaneous Flap

The scalp consists of five layers: skin, subcutaneous tissue, galea aponeurotica, sub-

aponeurotic areolar tissue and pericranium. The three outer layers are closely joined, and function as a single entity. Skin thickness in this region ranges from 3 to 8 mm, making it the thickest in the body. The adnexal tissues, nerves, lymphatics, and principal scalp vessels are located in a dense layer of subcutaneous tissue underlying the skin. The paired occipitalis and frontalis muscles are connected at the vertex by the galea aponeurotica which is an elastic musculofascial layer supported by the areolar tissue in the sub-aponeurotic space. This is by far the strongest and most important layer. The primary function of the subaponeurotic layer is to enable scalp mobility. It is comprised of loose, thin, connective tissue facilitating this movement. The pericranium is the innermost layer of the scalp. Generally, scalp flaps are elevated superficial to this layer. There are many different types of rotation flap techniques that may be used for reconstruction of scalp defects. The reconstructive surgeon has used rotation, sliding, and direct advancement bipedicle flaps since the mid-twentieth century. Rotation flaps are used primarily for small defects. Transposition flaps are used for larger defects (Figure 14).

of rotation flap techniques that may be used for reconstruction of scalp defects. The reconstructive surgeon has used rotation, sliding, and direct advancement bipedicled flaps since the mid-twentieth century. Rotation flaps are used primarily for small defects.

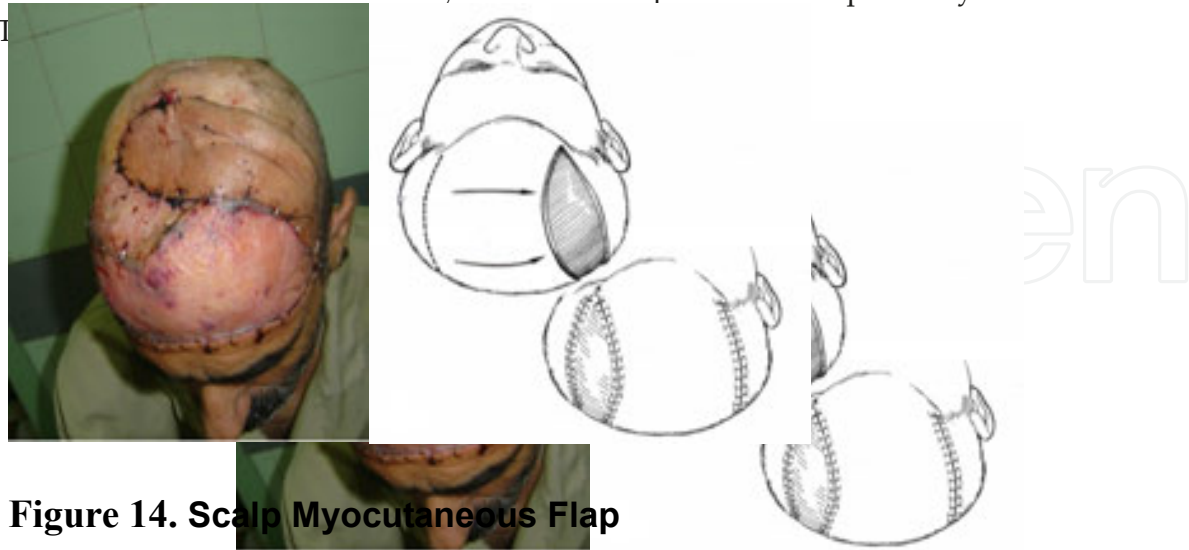


Figure 14. Scalp Myocutaneous Flap

The use of tissue expansion in scalp reconstruction has been an important in managing these problems (Figure 15).

The use of tissue expansion in scalp reconstruction has been an important in managing these problems (Figure 15).



Figure 15. Scalp Myocutaneous Flap

Platysmal Myocutaneous Flap

The platysmal myocutaneous flap is an axial flap used for soft tissue reconstruction and maxillofacial surgery. It has significant advantages in reconstruction of the buccal and maxillary defects after excision of lesions such as squamous cell carcinoma, the flap is close to the

3.2.7. *Platysmal myocutaneous flap*

The platysmal flap has been described as an axial flap used for soft tissue reconstruction in oral and maxillofacial surgery. It has significant advantages in reconstruction of the buccal mucosa after excision of lesions such as squamous cell carcinoma; the flap is close to the site of reconstruction, as well as being a thin and generally hairless tissue surface that is adequate to line the buccal mucosa. Also, carcinomas of the buccal mucosa rarely require neck dissections. In situations in which neck dissection is performed, the major vascular branch to this flap, the submental branch of the facial artery, is likely to be sacrificed, therefore obviating the use of this type of flap. The flap is not indicated in patients with previous irradiation, because the small perforators supplying blood to the subdermal plexus may provide inadequate perfusion to the flap. This type of flap is indicated for stage I and II gingival squamous cell carcinomas that require oral lining. It can cover an exposed area of mandible where other types of coverage, such as skin grafts, would not survive. It can be used as a bipedicle neck flap for closure of a tight neck during bone graft reconstruction and as a random pattern flap for closure of bone graft dehiscence. This muscle of facial expression originates from the skin just inferior to the clavicle and inserts into the skin of the face superior to the body of the mandible. Its motor function is supplied by cranial nerve VII (the facial nerve), and sensory innervation of the overlying skin is by the cutaneous nerves of the cervical plexus (C2 and C3). Again, the major artery for the pedicle is the submental branch of the facial artery. It also has a minor pedicle that is supplied by the superficial branch of the transverse cervical artery. The overlying skin is supplied by small perforators from these two main vessels. This is a technically easy flap that can be harvested in the same operative field, providing a thin and pliable flap for resurfacing deficiencies. The skin paddle is outlined by determining the size of the recipient defect. The skin paddle is placed in the supraclavicular fossa when the site to be reconstructed is located in the upper neck or oral cavity. Skin incisions are made over the anterior and posterior aspects of the muscle or parallel to the midline and are carried down to the midline, taking care to avoid cutting through the muscle. The deep aspect of the muscle is dissected down to the investing layer of the deep cervical fascia. The flap is then undermined superficially to the investing fascia and mobilized superiorly, where the submental branch of the facial artery is coursing in a horizontal fashion over the submandibular gland. The dissection is continued until adequate mobility of the flap is achieved to cover the defect [43]. Esclamado and coworkers [52] described 12 consecutive patients undergoing reconstruction for T2 and small T3 lesions of the oral cavity and oropharynx. They reported a flap survival rate of 92%, whereas earlier studies had reported 80% to 85%. Their complications were related to skin paddle loss, pharyngocutaneous fistula, and intraoral wound dehiscence, related to excessive tension on the muscle pedicle as it was rotated to the recipient site. The apron flap is a musculocutaneous flap incorporating the platysmal muscle. It can provide an adequate amount of thin tissue to resurface defects involving the floor of the mouth. It is usually outlined in the lower part of the neck. The base is frequently de-epithelialized in order to turn the flap under the mandible and into the floor of the mouth in a one-step procedure. The donor site can be closed primarily by undermining skin edges to achieve advancement of the adjacent tissues of the cervical skin. This reconstruction provides a thin lining to the remaining mandible and reconstructed floor of the mouth.

3.3. Pedicled osteomyocutaneous flaps

In the development of mandibular reconstruction techniques, it was evident that nonvascular bone grafting was a less reliable technique, because there was a high rate of infection secondary to salivary contamination, and vascularity to the graft was limited by the vascularity of the recipient bed in cases of previous irradiation. As a result, a poor success rate was obtained. [53-60] Using vascularized bone implies the maintenance of an intact blood supply to the bone during transplantation. This enables the donor bone to retain its original volume when incorporated for mandibular defects. The additional blood supply also aids in resisting infection and extrusion of the graft. The bone remains viable and does not need to be replaced by "creeping substitution." The healing time is therefore shortened, and function is regained earlier. An early study compared vascularized bone grafts with nonvascularized types and concluded that free grafts undergo resorption but pedicled bone grafts have greater survival [61-63]. Pedicled osteomyocutaneous flaps have the advantages of ease of flap harvest, relatively short operative time, decreased resorption, improved healing, and decreased infection rate. Their disadvantages include limited amount of bone for grafting, a variable vascular supply, and limited maneuverability of the bone. These factors contribute to an overall lower success rate compared with that of composite free tissue transfers, which is about 95%. However, the latter flap designs require increased sophistication and expertise and prolonged operative time. The following pedicled osteomyocutaneous flaps are clinically useful techniques for head and neck skeletal reconstruction.

3.3.1. Sternocleidomastoid osteomyocutaneous flap

Conley and Gullane [64] first described the SCM flap with a bone component for head and neck repairs. It was further described by Siemssen and colleagues [65] in 1978 for reconstruction of traumatic mandibular fractures, osteoradionecrosis, and mandibular defects following cancer resection. Barnes and associates [66] in 1981 made further technical modifications and cited a 3- year follow-up with no bone resorption. The SCM osteomyocutaneous flap was recently used by Friedman and Mayer [67] for tracheal reconstruction using clavicular periosteum with an SCM pedicle in cases of long-standing subglottic or tracheal stenosis. They were able to conform the clavicular periosteum to that of the trachea, with resulting bone formation to provide stability to the airway. The technique for raising an SCM osteomyocutaneous flap is to use the contralateral muscle and bone for reconstruction. After tumor resection, the clavicle is measured to obtain the desired segment to fill the mandibular defect. The clavicle that is harvested must include its medial portion and at least two thirds of the lateral clavicular body. Once the SCM muscle is dissected, preserving the clavicular attachments, the thyrocervical trunk, its blood supply, is identified and transected. The superior thyroid trunk is preserved superiorly, as is the spinal accessory nerve. Once the clavicle is released from all its attachments except for the SCM, it is rotated on the muscular pedicle across the midline into the defect and fixated with conventional bone fixation systems. The intraoral defect is closed primarily, the external skin flap is repositioned, and the neck is closed in a standard layered closure. The primary problem with this type of flap is the tripartite blood supply to the SCM muscle. The flap as described is a superior based one, which has the occipital artery as the major supply to the superior aspect of the muscle only. Thus the skin component

of the flap is unreliable. Other disadvantages include the exposure of the great vessels of the neck after mobilization and a resulting contour deformity of the neck. However, the flap is a rapid, technically easy flap to elevate for one-stage immediate reconstruction of oromandibular defects.

3.3.2. *Pectoralis major-rib osteomyocutaneous flap*

In 1979, the pectoralis myocutaneous flap was first introduced, and it has been modified over the years. Cuono and Ariyan [68] first reported a case in which they used a rib graft for mandibular reconstruction and proved its viability 3 months postoperatively. Multiple studies have reported on the inconsistencies of this flap, with the primary limitations involving the tenuous blood supply, which hinders manipulation and contouring of the transferred bone. The size of the skin island is also limited, and it cannot be manipulated on the pedicle to achieve the desired closure. Additional graft resorption occurs, as well as pectoralis muscle atrophy, loss of cartilage, and separation of the graft from the mandible. Therefore, several other modifications have been designed to overcome these limitations. The pectoralis osteomyocutaneous flap has its dominant vascular pedicle based on the pectoral branch of the thoracoacromial artery, which is located beneath the clavicle at the midsuperior edge of the muscle. Other vascular pedicles include that which contains the lateral thoracic artery and other perforating arterial branches at the first through sixth intercostal spaces off the internal mammary artery. The skin island is chosen to lie in a transverse axis over the fifth rib between the nipple and sternum. Placement in the inframammary crease is an alternative site, especially in female patients. The elliptic skin island is incised through skin and subcutaneous tissues to the level of the pectoralis major muscle. The muscle is dissected from the inferior sixth, seventh, and eighth ribs, and the dissection proceeds in a cephalad direction toward the fifth and sixth intercostal spaces. Laterally, the pectoralis muscle is bluntly dissected off pectoralis minor muscle to expose the vascular pedicle while maintaining the attachments to the fifth rib. The intercostal muscles between the fifth and sixth ribs are divided, with reflection of the pleura from the undersurface of the rib performed carefully. The rib is then sectioned at its lateral and medial desired extent with rib cutters. This rib segment, along with its muscle attachments, is released from the anterior chest wall, with increased mobilization of the flap gained by dividing the humeral, sternal, and clavicular attachments. A segment of the clavicle may also be excised to increase mobility. The flap is then transferred under the deltopectoral skin bridge. The rib segment harvested with the skin pedicle is secured to the remaining mandibular segment. The skin island can then be secured to the intraoral mucosa. The donor site is closed primarily by undermining the adjacent wound margins. Advantages of this reconstructive design include the technical ease of harvest and a versatile and durable flap that contains a long pedicle. However, the rib segment does not provide adequate bone stock for reconstruction, there is an increased risk of pneumothorax, and the limited vascular supply to the bone segment may lead to long-term bone resorption and muscular atrophy.

3.3.3. *Temporalis osteomuscular/ osteomusculofascial Flap*

The temporalis osteomuscular flap is an option for reconstruction of maxillary and mandibular deficiencies. Its advantageous location permits the arc of rotation of the flap to facilitate

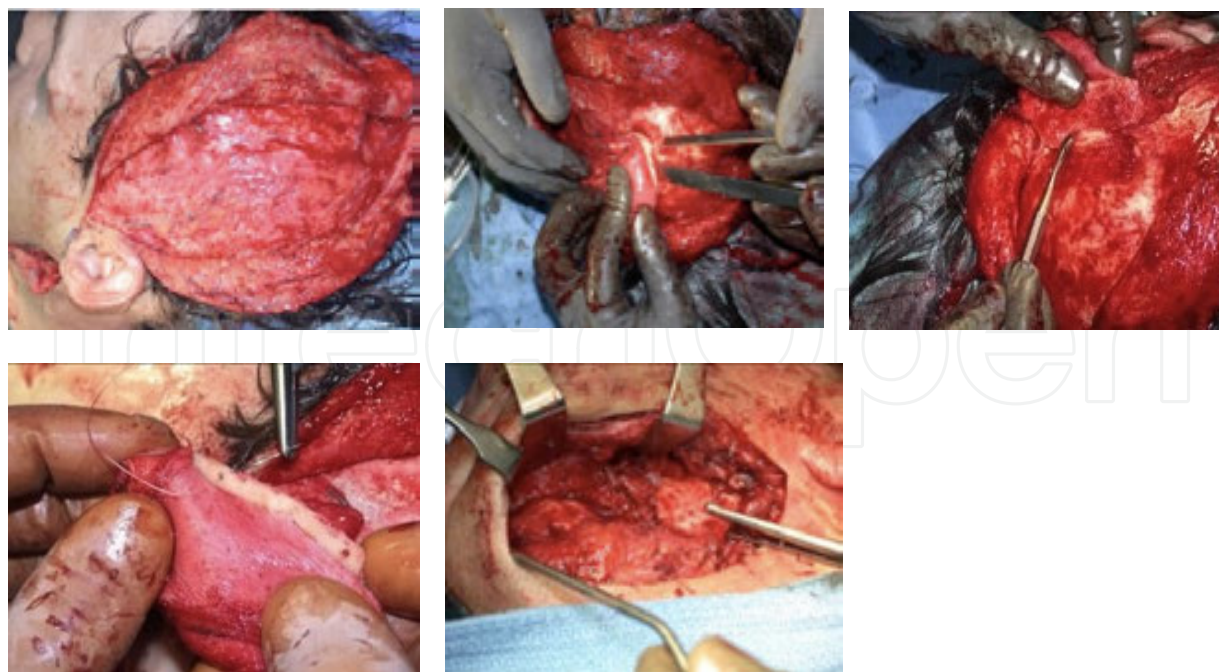


Figure 16. Temporalis Osteomuscular/ Osteomusculofascial Flap

Figure 16. Temporalis Osteomuscular/ Osteomusculofascial Flap

Free Flaps

Free Fasciocutaneous Flaps

at all anatomic levels. [69] Conleys [70] designed an incorporating the temporalis muscle and the underlying bone, using the designed a composite flap for orbital and frontal reconstructions but encountered limited mobility due to an anatomic obstruction by the intact zygoma and lateral orbital rim. The dissection was modified to include division of the arch and removal of the coronoid process, which allowed maximal mobility of the muscle flap by basing the pedicle on the deep temporal artery. The involvement of the membranous calvarial bone provides further advantages, anastomosed with the transected branches of the greater auricular nerve. This was a major breakthrough in the restoration of sensory function in the oral cavity. The radial forearm flap with or without incorporation of radial bone stock has many attributes that make it ideal for the reconstruction of intraoral defects. It is composed of a hairless surface that is relatively thin and pliable and allows easy three-dimensional restoration of the oral cavity. There is flexibility in skin paddle design, allowing for the creation of independent skin islands to resurface intraoral defects. The vascular pedicle that can be obtained has a generous length and caliber, which facilitates revascularization, especially if recipient vessels are at a distance. The rich vascularity of the flap promotes rapid healing and minimizes wound-healing complications, and there is a potential for simultaneous use of cranial bone. They found a low incidence of temporal volume loss and adverse effects on jaw movements. Finally, the flap can be harvested at the same time as tumor ablation is performed. Anatomically, the major blood supply to the flap is from the branches of the radial artery that course along the lateral intramuscular septum of the forearm, between the brachioradialis and flexor carpi radialis muscles. There are 9 to 17 septal perforators that supply the deep forearm fascia, superficial long muscle and the overlying skin. The septal perforators and the direct branches of the radial artery supply the tendons of the brachioradialis, flexor carpi radialis and palmaris longus muscles. Vascularized segments of the lateral wrist tendons and radius can be included in the flap based on a periosteal circulation supplied by the osteonemes, producing full or partial thickness bone grafts. The muscle is anchored to the

zygomatic arch by the deep temporal fascia. Dividing these attachments allows anterior mobilization of the flap. Again, the zygomatic arch may be divided, and the coronoid process may be transected to provide maximal transposition of the flap. The muscle's arc of rotation is thus increased, as it is isolated on its neurovascular pedicle. The flap can be used for external reconstruction of maxillary and mandibular defects but can also be tunneled intraorally to reach the ipsilateral canine region. The bone segment is fixed to the surrounding bone by standard fixation materials, such as wires or plates. The wound is then closed in a two-layered fashion with the appropriate use of drains (Figure 16).

4. Free flaps

4.1. Free fasciocutaneous flaps

4.1.1. Radial forearm flap

Originally developed in China [73], the radial forearm flap has developed into one of the most utilized techniques for reconstruction. Initially, it was used for the correction of cervical skin contracture in burn patients. It was then applied for reconstruction of total thumb defects using a portion of the radial bone. In 1983, Soutar [74] introduced this technique to oromandibular reconstruction. Urken [75] followed in 1989 by re-innervating the oral cavity with modifications of the flap design, using medial and lateral antebrachial cutaneous nerves of the forearm anastomosed with the transected branches of the greater auricular nerve. This was a major breakthrough in the restoration of sensory function in the oral cavity. The radial forearm flap with or without incorporation of radial bone stock has many attributes that make it ideal for the reconstruction of intraoral defects. It is composed of a hairless surface that is relatively thin and pliable and allows easy three-dimensional restoration of the oral cavity. There is flexibility in skin paddle design, allowing for the creation of independent skin islands to resurface intraoral defects. The vascular pedicle that can be obtained has a generous length and caliber, which facilitates revascularization, especially if recipient vessels are at a distance. The rich vascularity of the flap promotes rapid healing and minimizes wound-healing complications, and there is a potential for sensory reinnervation. Finally, the flap can be harvested at the same time as tumor ablation is performed. Anatomically, the major blood supply to the flap is from the branches of the radial artery that course along the lateral intramuscular septum of the forearm, between the brachioradialis and flexor carpi radialis muscles. There are 9 to 17 septal perforators that supply the deep forearm fascia superficial to muscle and the overlying skin. The septal perforators and the direct branches of the radial artery supply the tendons of the brachioradialis, flexor carpi radialis, and palmaris longus muscles. Vascularized segments of the lateral cortex of the distal radius can be included in the flap, based on a periosteal circulation supplied by direct fascioperiosteal branches of the radial artery and musculoperiosteal vessels. The maximal length that can be harvested is 12 cm, based on the pronator teres muscle insertion proximally and the brachioradialis insertion distally. The sensory nerves, the medial and lateral antebrachial cutaneous nerves, run in close proximity to the superficial veins of the

forearm and can be incorporated by dissecting proximally to obtain adequate length to anastomose to recipient vessels (Figure 17).

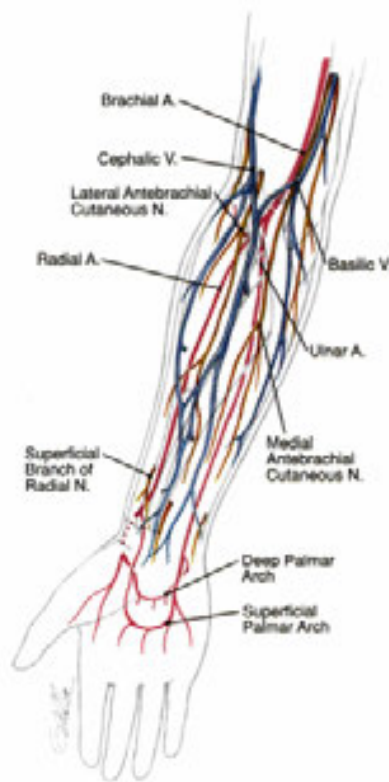

Figure 17. Forearm anatomy

The nondominant arm is usually selected for flap harvest, after documentation of adequate palmar circulation by Allen's test. Under sterile conditions, the extremity is exsanguinated, followed by application of a tourniquet. The skin paddle is then outlined, with its configuration dependent on the size and shape of the defect. It is usually projected over the course of the radial artery and one of the subcutaneous veins. The paddle is frequently outlined over the distal radius to obtain a vascular pedicle of greatest length. A flap may also be designed to provide a second, proximal skin island that is exteriorized in the lower neck to serve as an external monitor of flap viability. Intervening tissue is often used to provide coverage to the carotid vessels and augment soft tissue defects in radical neck cases. Once the distal incision is made, the radial vessels are identified and ligated just lateral to the flexor carpi radialis tendon. The incisions are carried through the deep muscular fascia, and flap elevation proceeds deep to this plane and extends proximally toward the intramuscular septum of the forearm. As the septum is approached, the septal perforators are encountered. The flap is then elevated for the flexor muscles of the wrist, where care is taken to preserve the paratendon, as this provides the vascularized bed for the healing of skin grafts. Once the intramuscular septum is widely exposed, the radial vessels are elevated sharply from the groove between the flexor carpi radialis and the brachioradialis muscles. The dissection continues proximally until the

bifurcation of the brachial artery, which requires careful separation of the muscle bellies. At this proximal aspect, the antebrachial cutaneous nerves are identified next to the cephalic vein. The tourniquet is then released while the flap is still attached to its vascular pedicle, so the flap is reperfused until ready for transfer to the donor site. If radial bone is to be used, a cuff of muscle and periosteum is preserved along the anterior radial border in continuity with the lateral intramuscular septum. The periosteum and muscle are carefully incised along the ulnar border of the radius. Holes are drilled into the bone, which are subsequently joined by a fissure bur, and the osteotomy is completed with a reciprocating saw. Only 40% of the anterior radius can be harvested in full thickness. The bone is then lifted and segmentalized by greenstick fractures in order to be adapted to the bony defect. Each segment is attached by a screw to a precontoured titanium reconstruction plate [76]. The harvested fascia is then adapted to the bony contours and sutured to provide a watertight seal. Following tissue transfer, the wound is closed and bolstered with split-thickness skin grafts. Full-thickness skin grafts that are defatted and taken from the abdomen provide an excellent alternative to the traditional split thickness grafts, which are associated with complications [77]. An ulnar transposition flap may be used to close a small residual donor defect. An ulnar immobilizing splint is then applied for approximately 1 week. The wrist is in slight extension to eliminate dead space between the brachioradialis and flexor carpi radialis muscles, where a hematoma may form. Radial forearm flaps have been applied mostly to reconstruction of the oral cavity and pharyngeal defects. They provide tissue with an independent blood supply capable of healing in a contaminated and irradiated wound. It has been shown in many studies that an improved level of oral cavity function occurs after skin graft reconstruction as opposed to using tongue or myocutaneous flaps alone [78]. The radial forearm flap, without its bony counterpart, is well suited for the reconstruction of tongue and floor of the mouth defects. A bilobed design has been used by Urken and Biller [79] to restore shape and volume of the tongue with one lobe and to resurface the floor of the mouth and gingiva with the second lobe. They reported that mobility, oral alimentation, articulation, and sensory reinnervation occurred in the majority of their patients (Figure 18).

In those cases in which tumor ablation involves segmental mandibulectomy, the radial forearm flap with its radial bone, or in conjunction with bone stock from other sites such as iliac crest free flap or scapular bone, achieves functional mandibular reconstruction with a sensate soft tissue component. Nakatsuka and colleagues [80] described their experience using dual free flap transfers combining the radial forearm flap with an osteocutaneous free bone flap. Despite a high complication rate of 41 %, the technique is useful for obtaining good alveolar ridge height. Circumferential defects of the hypopharynx or cervical esophagus can be restored with the use of tubed radial forearm free flaps, allowing rehabilitation of the swallowing mechanism. Soft palatal defects can be reconstructed by using this flap design, folded over on itself to provide lining for the oro- and nasopharynx. Utilizing the tendons, as incorporated in flap design, allows total lip and chin reconstruction, with the palmaris longus tendon acting as a sling to assist in maintaining the vertical height and support of the lip [81]. Complications of using the radial forearm flap include those encountered with other designs, such as flap necrosis, delayed wound healing due to failure of the skin graft to take over the exposed flexor tendons of the wrist, radial bone fracture, lack of sensation over the grafted donor site, vascular

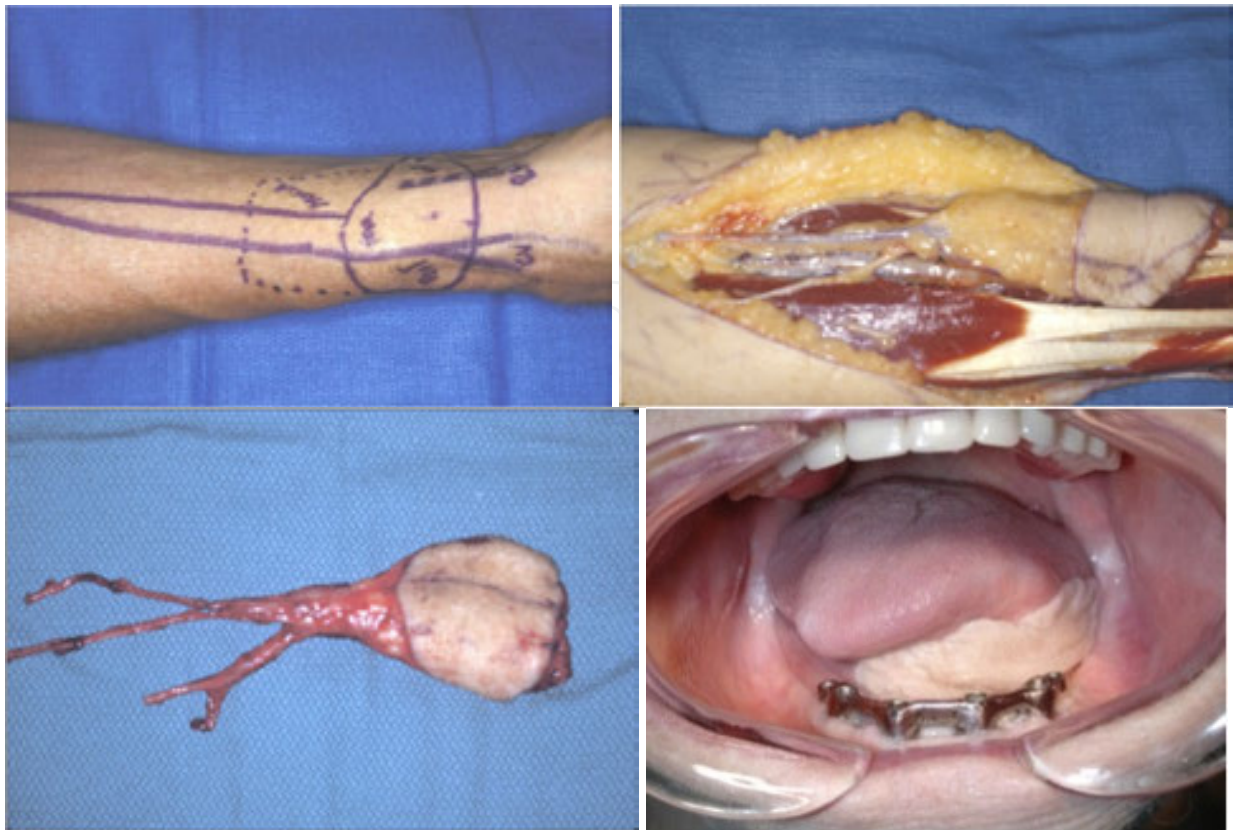


Figure 18. Radial Forearm Flap

Figure 18. Radial Forearm Flap

In those cases in which tumor ablation involves segmental mandibulectomy, the radial forearm flap with its radial bone, or in conjunction with bone stock from other sites such as iliac crest free flap at the stapedial anastomosis. This is a functional mandibular reconstruction with a sensitive soft tissue component. Nakatsuka and colleagues [80] described their experience using dual free flap transfers combining the radial forearm flap with an osteocutaneous free bone flap. Despite a high complication rate of 41 %, the technique is useful for obtaining good alveolar ridge height.

4.1.2. Lateral thigh flap
Circumferential defects of the hypopharynx or cervical esophagus can be restored with the use of tubed radial forearm free flaps, allowing rehabilitation of the swallowing mechanism. Soft palatal defects can be reconstructed by using this flap design, folded over on itself to provide lining for the oro- and nasopharynx. Utilizing the tendons, as incorporated in flap design, allows total lip contractures in the anterior neck. It has been described as a fasciocutaneous flap from the lower limb used primarily for pharyngoesophageal defects [84]. This flap provides a more abundant surface area than any other skin flap. The overlying skin in women is frequently thin, pliable, and hairless. The more proximal aspect of the flap is used to provide bulk, whereas the thinner distal aspect can be used to reconstruct the thin oral and pharyngeal mucous membranes. This is useful in those cases in which tumor ablation involves segmental mandibulectomy, the radial forearm flap with its radial bone, or in conjunction with bone stock from other sites such as iliac crest free flap at the stapedial anastomosis. This is a functional mandibular reconstruction with a sensitive soft tissue component. Nakatsuka and colleagues [80] described their experience using dual free flap transfers combining the radial forearm flap with an osteocutaneous free bone flap. Despite a high complication rate of 41 %, the technique is useful for obtaining good alveolar ridge height.

Lateral Thigh Flap
This type of flap was first described by Baek [83] in 1983, when it was used for reconstruction of subtotal and total glossectomies, the flap can serve as a sensate fasciocutaneous flap, with the lateral femoral cutaneous nerve anastomosed with the glossopharyngeal or lingual nerves. This flap also has a long vascular pedicle, which may lend itself to the repair of cranial base defects by anastomosis to the carotid artery. The overlying skin in women is frequently thin, pliable, and hairless. The more proximal aspect of the flap is used to provide bulk, whereas the thinner distal aspect can be used to reconstruct the thin oral and pharyngeal mucous membranes. This is useful

postoncologic mandibulectomy defect is unique, in that oral contamination, radiation changes, and decreased blood supply hinder the use of nonvascularized tissues. Furthermore, rehabilitation of the dental arch is possible with the simultaneous use of vascularized osteocutaneous flaps and osseointegrated implants, which results in improved postoperative masticatory function. A variety of donor sites exist for oromandibular reconstruction, including the iliac crest, fibula, scapula, radius, metatarsus, and rib [90]

Iliac Crest Osteocutaneous Free Flap

Free microvascular flaps in oromandibular reconstruction have proved to be reliable in the face of adverse environmental conditions [91]. Of the sites that have been described, the iliac crest composite free flap has distinguished itself as being the most efficacious and has become the principal reconstructive option (Figure 20).

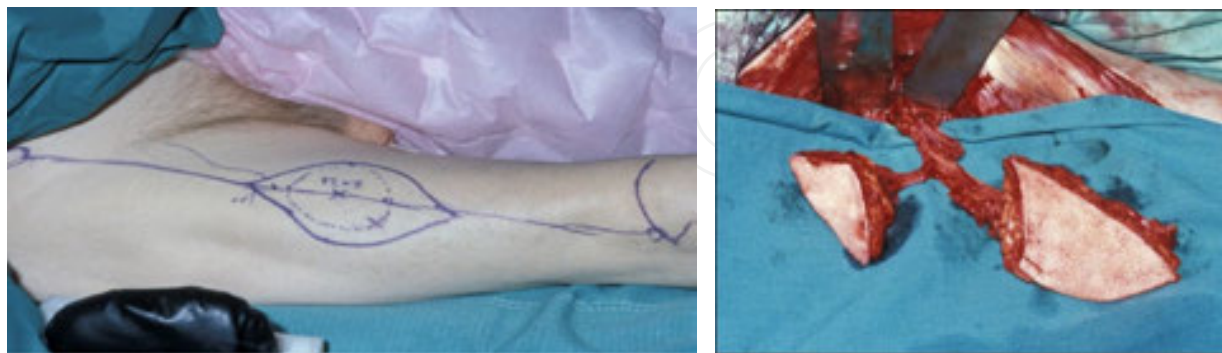


Figure 19. The lateral thigh flap

This flap has not gained popularity largely owing to technical difficulties. However, for large laryngopharyngectomies, it should be a first-line reconstructive choice.

4.2. Free osteomyocutaneous flaps

Primary mandibular reconstruction in patients treated with preoperative radiation therapy is often unsuccessful, failing because of ineffective healing, lack of neovascularization, or infection from salivary contamination. The use of vascularized free flaps has decreased the morbidity and mortality, as well as the length of hospital stay, for patients who have undergone oral cavity reconstruction. The use of myocutaneous vascularized flaps has been criticized, because they result in bulky tissues in the oral cavity, which has a major adverse affect on deglutition and articulation, and dental appliances often fail in these settings. Free vascularized bone flap transfers from distant sites have revolutionized mandibular reconstruction. [85-89] The postoncologic mandibulectomy defect is unique, in that oral contamination, radiation changes, and decreased blood supply hinder the use of nonvascularized tissues. Furthermore, rehabilitation of the dental arch is possible with the simultaneous use of vascularized osteocutaneous flaps and osseointegrated implants, which results in improved postoperative masticatory function. A variety of donor sites exist for oromandibular reconstruction, including the iliac crest, fibula, scapula, radius, metatarsus, and rib [90]

4.2.1. Iliac crest osteocutaneous free flap

Free microvascular flaps in oromandibular reconstruction have proved to be reliable in the face of adverse environmental conditions [91]. Of the sites that have been described, the iliac crest composite free flap has distinguished itself as being the most efficacious and has become the principal reconstructive option (Figure 20).

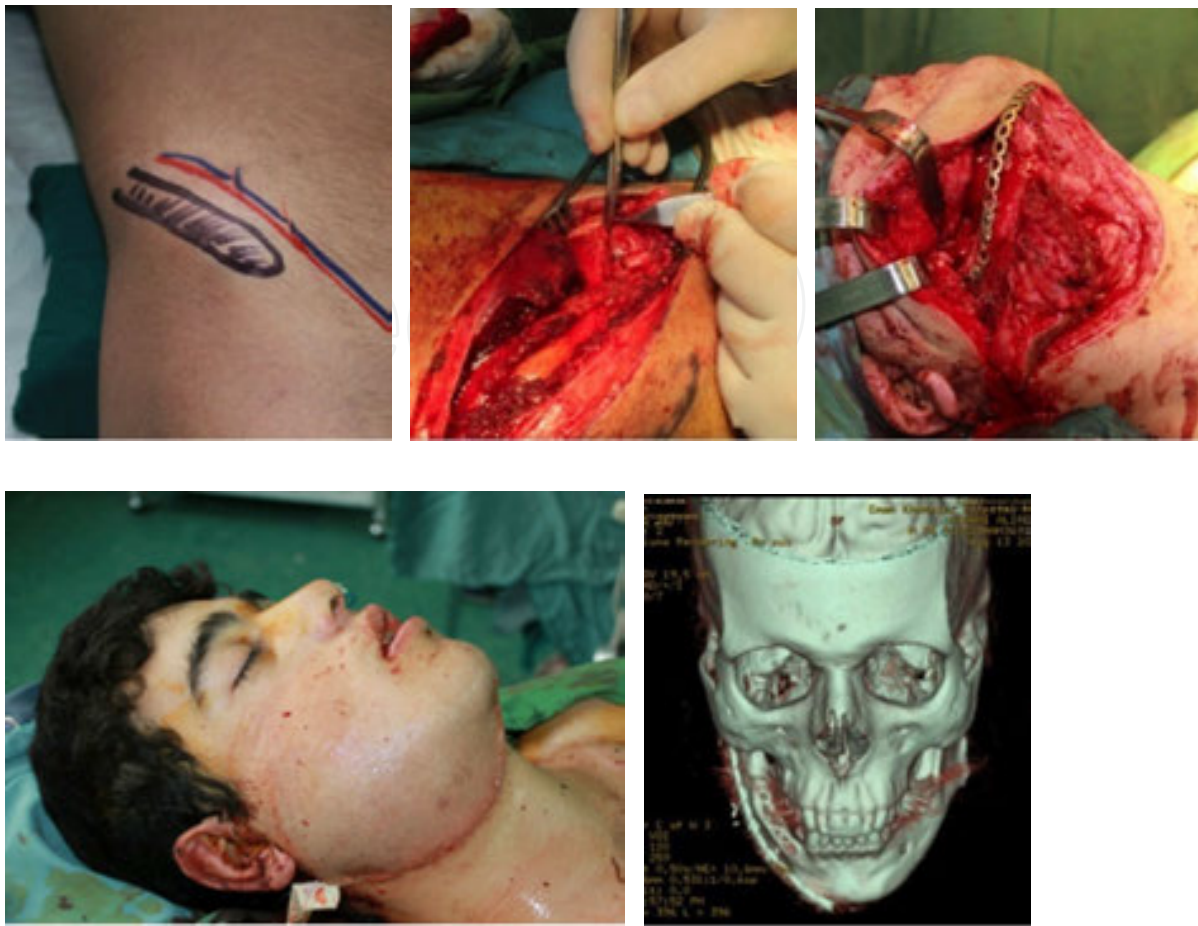

Figure 20. Iliac Crest Osteocutaneous Free Flap

The corticocancellous iliac crest yields sufficient bone for reconstruction, as well as providing the appropriate contour to parallel the mandible. The cancellous portion promotes rapid healing, while the dense cortex maintains strength and contour and allows the use of rigid fixation and restoration with osseointegrated implants. The soft tissue free flap provides extensive soft tissue coverage. With the incorporation of the internal oblique muscle, the oral cavity can be lined, and articulation can be improved following glossectomy. Use of the iliac crest free flap allows for immediate reconstruction, thus preventing distortions in contour. This is accomplished by the use of fixation stabilization achieved before initial resection. This approach is also amenable to use of a dual surgical team, improving the efficiency of harvest. The flap can be raised as an osteocutaneous, myo-osseous, or osteomyocutaneous flap. Review of Ulken's report suggests a success rate of 96% [29]. This type of reconstructive option also has limitations; for example, this technique of reconstruction also has limitations; for example, technically difficult in obese patients. Removal of a bicortical block produces significant site deformity and asymmetry. Enlargement on the abdomen may occur, producing weakness and hernia development. The associated skin paddle may be difficult to mobilize and thus difficult to orient and position. The bulky bony mass often requires secondary revision to improve or correct ideal contours. Postoperative sequelae include injury to the lateral femoral cutaneous ilioinguinal nerves, which can produce unpleasant dysesthesia and/or anesthesia. A number of refinements have taken place over the years to prevent some of these adverse postoperative sequelae. The split inner cortex iliac crest microsurgical free flap preserves the outer cortex to anchor the abdominal wall musculature and fascia and produces a firm, dependable closure, preventing abdominal wall weakness and subsequent hernia formation. The advantages of liberating a single cortex are that it is technically easier, takes less time to harvest, reduces blood loss, and decreases the incidence of hematoma or seroma formation. Of course, the amount

unpleasant dysesthesia and/or anesthesia. A number of refinements have taken place over the years to prevent some of these adverse postoperative sequelae. The split inner cortex iliac crest microsurgical free flap preserves the outer cortex to anchor the abdominal wall musculature and fascia and produces a firm, dependable closure, preventing abdominal wall weakness and subsequent hernia formation. The advantages of liberating a single cortex are that it is technically easier, takes less time to harvest, reduces blood loss, and decreases the incidence of hematoma or seroma formation. Of course, the amount of harvested bone is limited and less reliable for contouring osteotomies, internal fixation, and osseointegration. However, the breadth of the single cortex is comparable to that of the intact mandible. The iliac bone is perfused by a number of vessels, including the deep, lateral, and superficial circumflex iliac arteries; the superficial inferior epigastric artery; and the superior deep branch of the superior gluteal artery. The osteomyocutaneous flap is based on the deep iliac artery as the principal blood supply, with accompanying perforators to augment perfusion to the overlying skin.

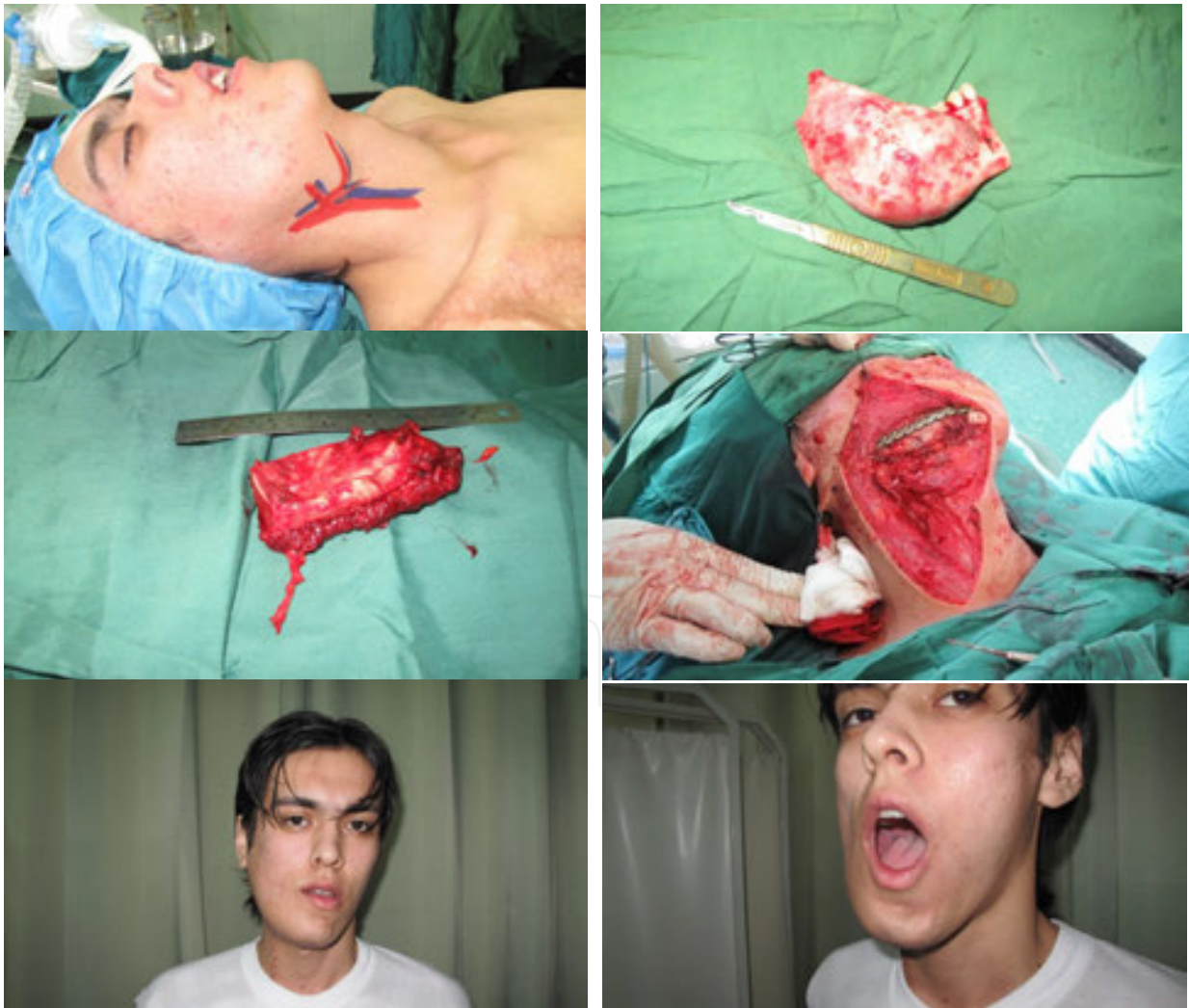

Figure 21. Iliac Crest Osteocutaneous Free Flap
Figure 21. Iliac Crest Osteocutaneous Free Flap

Incorporation of the internal oblique muscle flap provides a source of oral lining to aid in the reconstruction of compound deficiencies. Durable internal fixation of free vascularized bone grafts is accomplished with reconstructive plating systems (e.g., THORP, AO). Placement of the plates before initial resection maintains contour and eliminates the need for intermaxillary or external fixation (**Figure 22**).



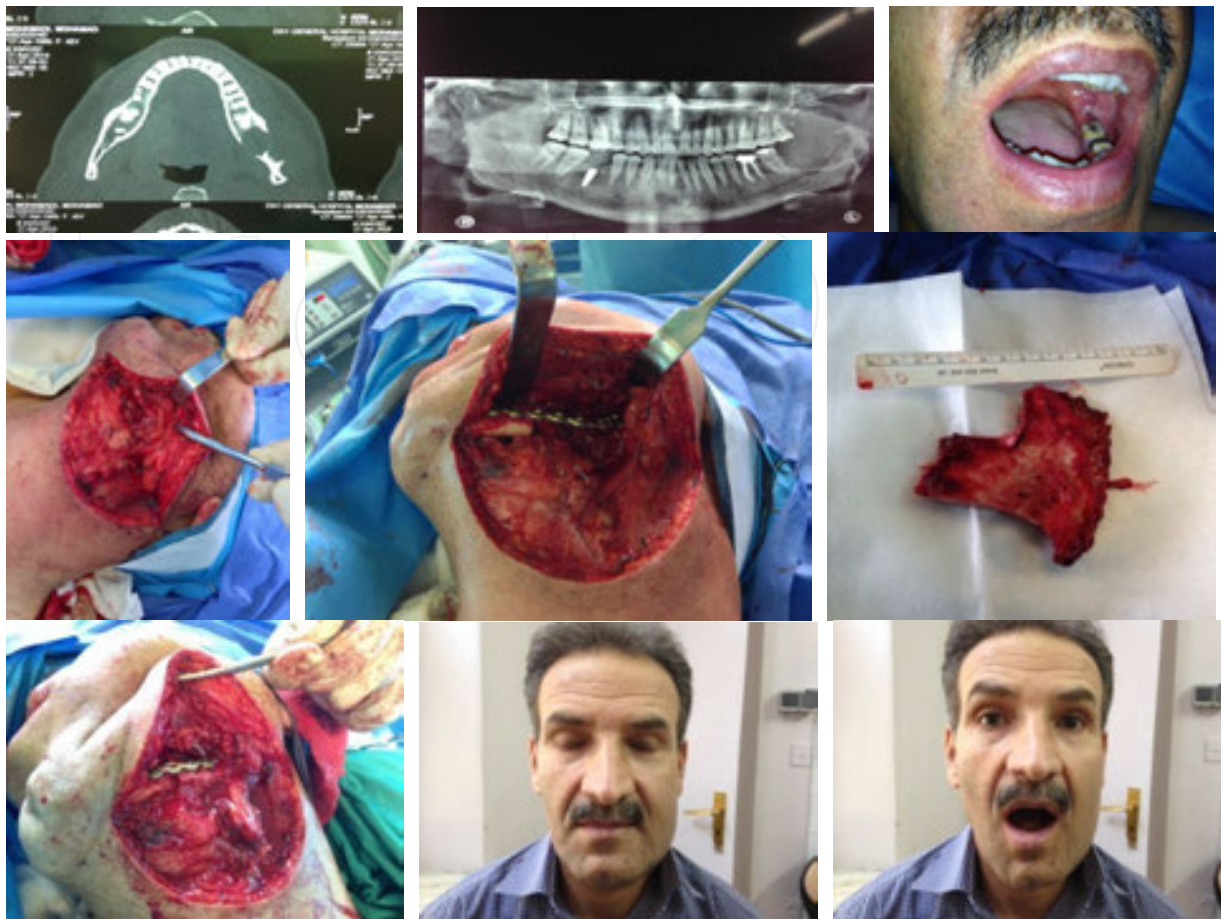

Figure 22. Iliac Crest Osteocutaneous Free Flap

The deep circumflex iliac artery originates from the external iliac just proximal to the inguinal ligament and courses toward the iliac spine in a plane deep to the transverse fascia and parallel to the inguinal ligament. In this path, it is crossed by the ilioinguinal and lateral femoral cutaneous nerves. The dissection begins with a skin incision parallel to the inguinal ligament in the direction of the anterior superior iliac spine. A vertical incision over the major femoral vessels is made approximately 5 cm in length, forming a final inverted-L--shaped incision. The deep circumflex vessels are identified and dissected to their origin. Care is taken to identify the ascending branch of the deep circumflex artery, which takes off from the parent artery 1 cm before the anterior iliac spine. It is important to preserve this vasculature, as it is the major supplier to the internal oblique muscle. If required, a skin paddle can be excised over the crest. The skin, subcutaneous tissues, and fascia are elevated as one unit, with an adjoining 2.5- cm protective cuff of muscle. The skin flap is then undermined to the superior border of the crest, where the periosteum is divided in the midline of the crest. With adequate elevation of the periosteum in the medial and lateral dimensions, the two cortices can be osteotomized with a sagittal saw. The internal oblique muscle flap can then be fashioned, with the iliocostalis muscle divided and dissected to a level below the deep circumflex artery. The medial cortical plate can then be accessed for the osteotomy. The shape of the reconstructed mandible is dependent on the sites of the osteotomy. The vascular pedicle follows behind the newly designed

mandibular angle with a length sufficient to reach the external carotid system, where anastomoses of the donor vessels will take place. The donor site is closed in layers, where the residual internal oblique muscle is reapproximated with the residual periosteum, and the external oblique muscle is anchored to the outer cortex of the iliac crest. Drains are frequently used in the wound site and covered with fascia and skin. This donor site provides a long vascular pedicle that can be fashioned to fit the defect precisely (Figure 21).

Incorporation of the internal oblique muscle flap provides a source of oral lining to aid in the reconstruction of compound deficiencies. Durable internal fixation of free vascularized bone grafts is accomplished with reconstructive plating systems (e.g., THORP, AO). Placement of the plates before initial resection maintains contour and eliminates the need for intermaxillary or external fixation (Figure 22).

4.2.2. Fibula free flap

Among the free flap donor sites used for mandibular reconstruction, the fibula is becoming a popular choice (Figures 23). [92]

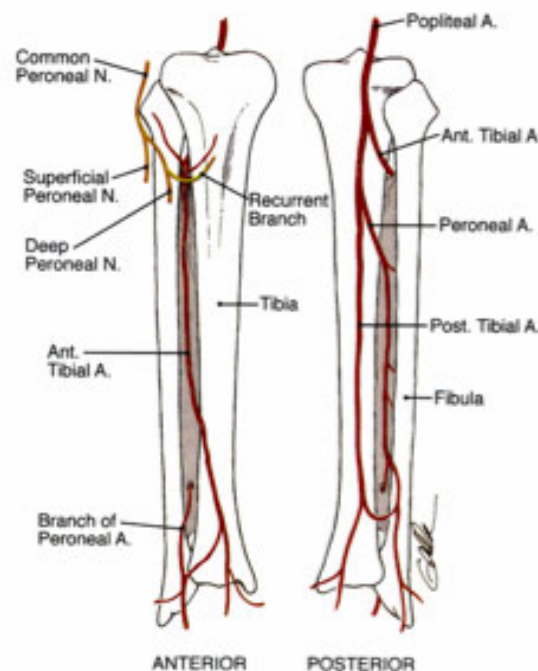


Figure 23. Fibula anatomy

It provides enough bone stock, with up to 25 cm of bone, and can maintain a consistent shape throughout its length for shaping a mandibular defect. Its blood supply courses along with it, in parallel, guaranteeing adequate vascularity to the osteotomized segments. The muscle segment also parallels the bony segment, enabling the soft tissue defect to be filled in ade-

quately. It provides a rigid, strong, tubular-shaped cortical bone similar to the anatomic structure of the mandible, and it is easily contoured without compromising vascularity [93]. Simultaneous reconstruction, both internally and externally, can be reliably performed with an associated skin island based on the septocutaneous blood supply. Finally, the graft site is located distally enough so that two teams can work simultaneously. Most anterior mandibular reconstructions, where defects can exceed 12 cm and where external skin or floor of the mouth defects mandate replacement, are accomplished primarily with fibula free flaps. Other indications include hemimandibular defects with adjacent lateral floor of the mouth or buccal mucosa loss. Carroll and Esclamado recently suggested the use of preoperative angiography in all patients undergoing reconstructions using fibular osteocutaneous flaps [94]. They found that subclinical and marked atherosclerotic disease may be detected in patients with clinically benign lower extremity examinations, and that aberrant arterial anatomy exists in 5% to 7% of the population. However, a dominant peroneal artery occurs in a very small number of patients in a population, and an angiogram is not justified. Moreover, a diseased peroneal artery can be safely used for microvascular anastomoses. But if the peroneal artery must be used in the free flap transfer, adequate foot runoffs must be present. Primary reconstruction provides the optimal setting for obtaining the best surgical result. Graft shaping is easily accomplished when the resected segment is directly visualized. In secondary reconstruction, distortion of the anatomy, secondary to soft tissue contracture, makes the reconstruction a "mystery." Before tumor ablation, miniplates are easily contoured to the existing mandible. They provide a high degree of precision, without the bulk of AO reconstruction plates. When planning on which donor leg to use, the ipsilateral fibula is generally used [95]. When the same side is used, the flexor hallucis longus muscle lies under the fibula to aid in filling in the soft tissue defect. The skin island can then be easily rotated up and over the fibula to reach the oral cavity and reconstruct a mucosal defect. The skin island is designed to run along the length of the fibula to preserve all its septal blood supply. The long axis is centered over the fibula's posterior border, such that the septal blood supply is captured. The width of the island is approximately 4 cm on average, which usually allows primary closure of the donor site (Figure 24).

A larger skin island requires some type of skin graft closure. Dissection begins from a lateral approach, with the skin incised anteriorly. The lateral compartment, separated from the anterior by the intramuscular septum, is divided, and muscles from both groups are divided, with the use of electrocautery to gain hemostasis. A cleft posteriorly between the soleus and flexor hallucis muscles is created by blunt dissection, and the soleus is separated with electrocautery from the fibula (Figure 25).

Osteotomies are performed at the proximal neck of the fibula and at a distal site 4 to 6 cm proximal to the lateral malleolus. The peroneal vessels and the flexor hallucis longus muscle are divided distally. At the distal site, traction on the bone outward exposes the posterior tibialis muscle and its median raphe; the former is then divided along the latter in a distal to proximal direction. The peroneal and tibial vessels are usually safe as long as the muscle is divided along the raphe. The recipient vessels are dissected in preparation for a microvascular transfer. The facial artery and external carotid artery are used most frequently, and the superior thyroid artery is used as an alternative. However, the external jugular vein is generally

and over the fibula to reach the oral cavity and reconstruct a mucosal defect. The skin is designed to run along the length of the fibula to preserve all its septal blood supply. The flap is centered over the fibula's posterior border, such that the septal blood supply is captured. The width of the island is approximately 4 cm on average, which usually allows primary closure of the donor site (**Figure 24**).

678

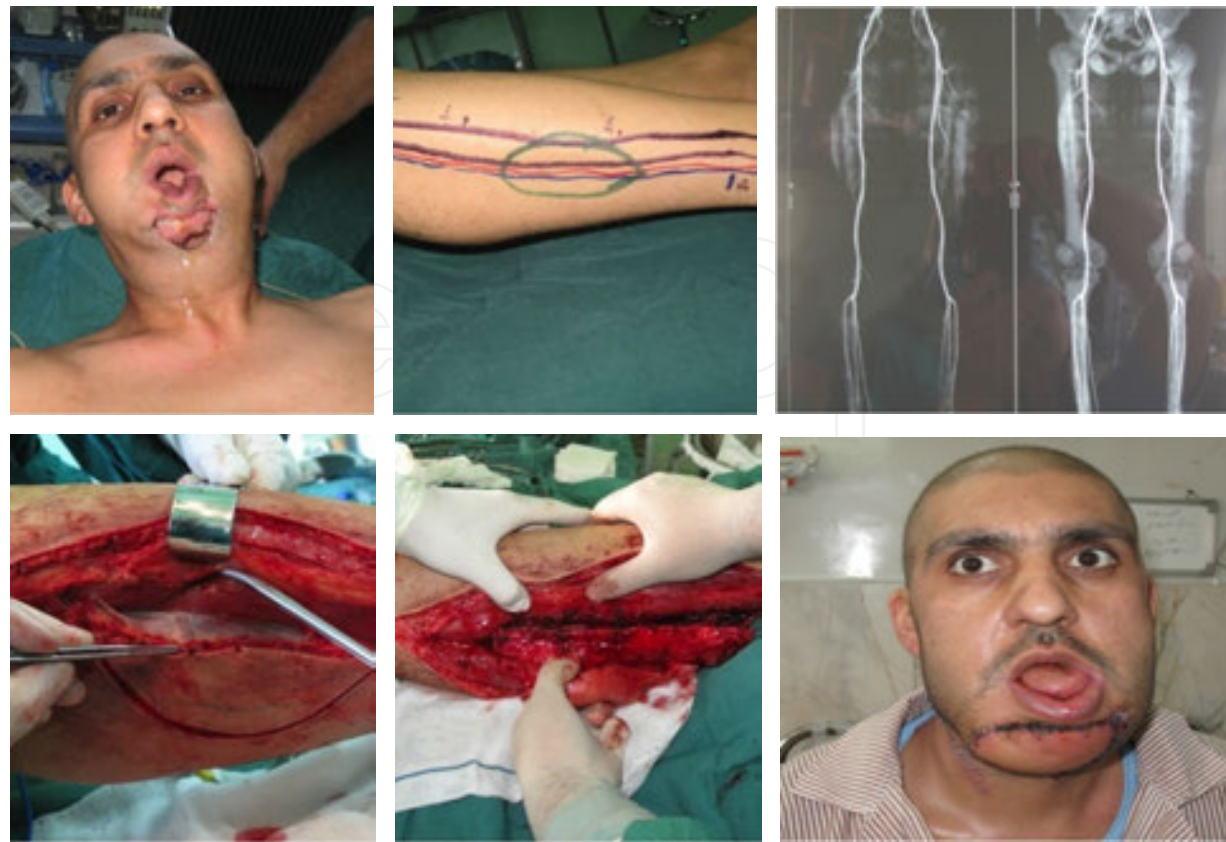
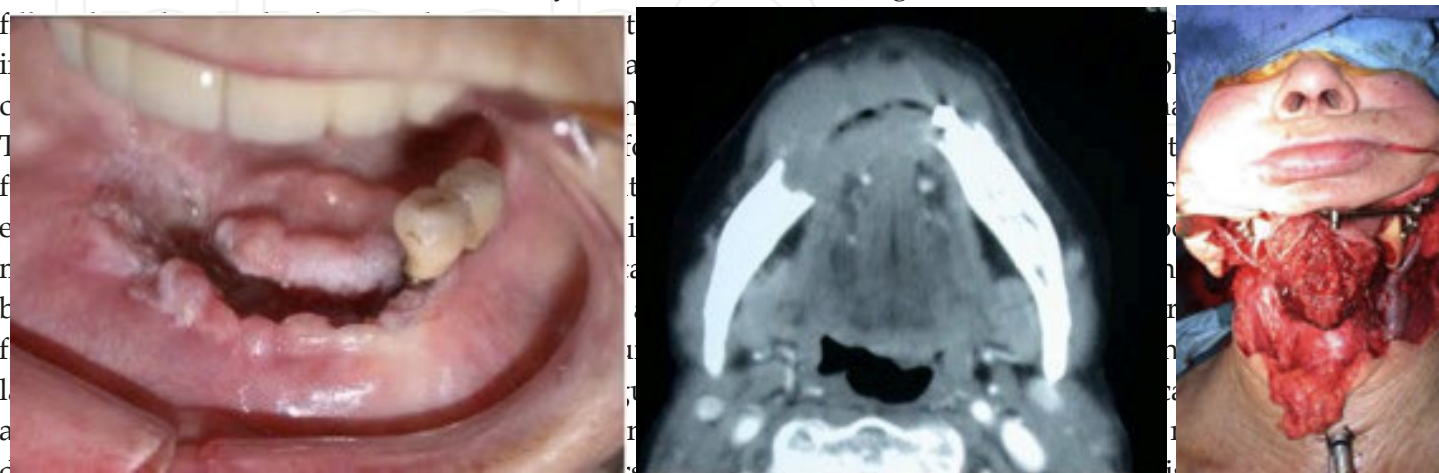
Figure 24. Free fibula flap

A larger skin island requires some type of skin graft closure. Dissection begins from a preferred approach, because it is more superficial and has an ideal diameter for anastomosis. In general, to prevent lengthy ischemia times, the fibula is shaped as much as possible before the pedicle is divided. The graft is completely shaped, and then the final osteotomies that determine the overall length are performed before the inset process. The process of shaping is facilitated by prefabricated templates. Osteotomies in the desired positions are created and stabilized with multiple pins. Once microvascular anastomosis is complete, the skin island is rotated up and over the mandible into the oral cavity. The flexus hallucis longus muscle can be used to



defect [77]. There has been ongoing controversy regarding the reliability of the skin island associated with the fibular osteocutaneous flap in mandibular reconstruction. Jones and

coworkers [98] recently addressed this topic by studying a new flap design in 60 cadavers. They found that a major perforator through the soleus muscle or flexor hallucis muscle can provide perfusion to the skin flap, without the need to incorporate portions of the muscle. The reliability of the skin island is based on the design's more distal location (that is, it is placed more distally over the distal third of the lower leg); preoperative identification of the perforators with Doppler mapping so as not to sacrifice them during dissection; and protection of the septocutaneous perforators that traverse the posterior periosteum when performing wedge osteotomies of the fibula. Violations of this design may be responsible for the poor outcomes previously reported regarding the reliability of the fibular osteocutaneous flap for mandibular reconstruction (Figure 26).

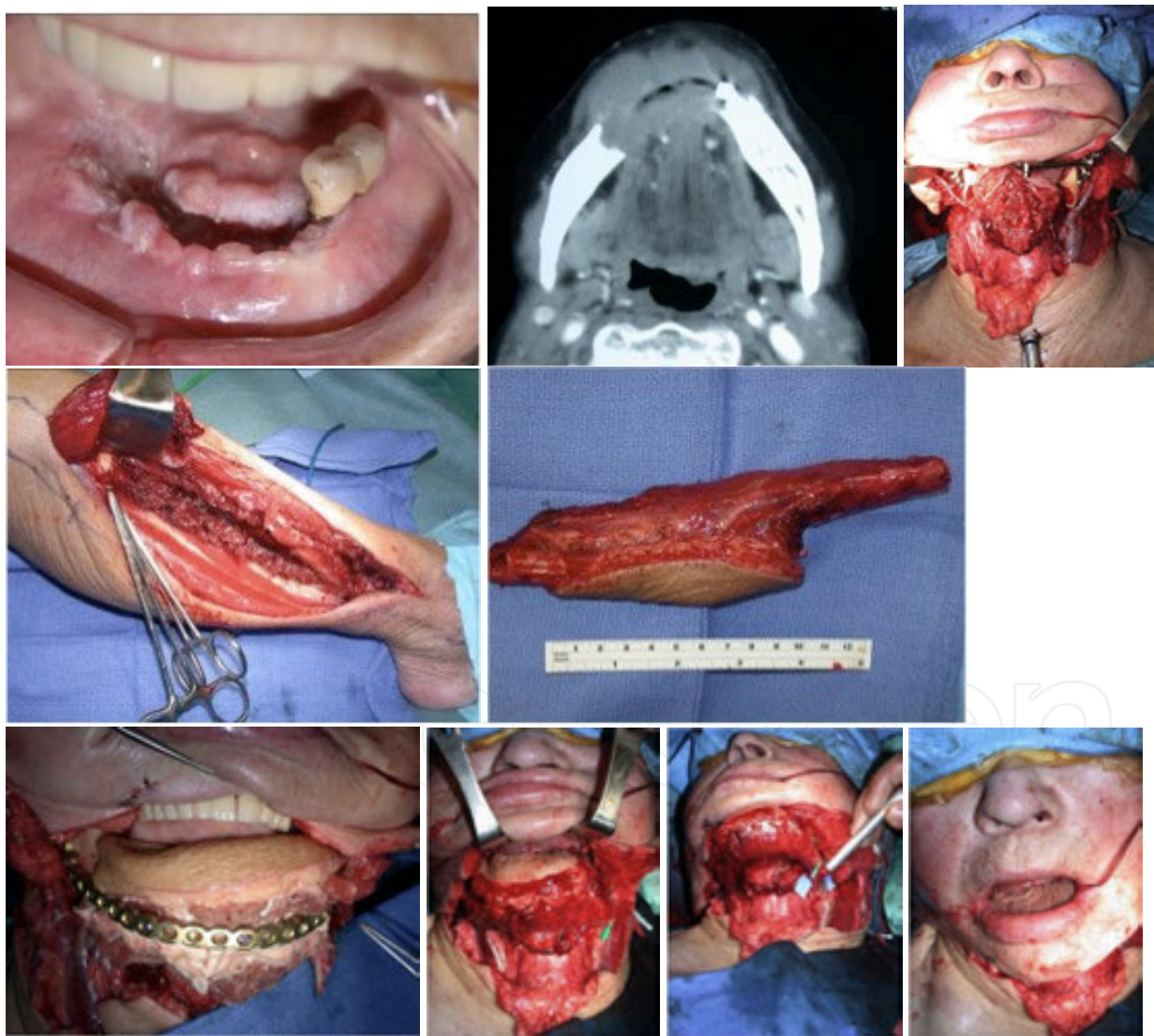


Figure 25. Free fibula flap

Figure 25. Free fibula flap
 Osteotomies are performed at the proximal neck of the fibula and at a distal site 4 to 6 cm proximal to the lateral malleolus. The peroneal vessels and the flexor hallucis longus muscle are divided distally. At the distal site, traction on the bone outward exposes the posterior tibialis muscle and its median raphae; the former is then divided along the latter in a distal to proximal direction. The peroneal and tibial vessels are usually safe as long as the muscle is divided along the raphae. The recipient vessels are dissected in preparation for a microvascular transfer. The facial artery and external carotid artery are used most frequently, and the superior thyroid artery is used as an alternative. However, the external jugular vein is generally preferred, because it is more superficial and has an ideal diameter for anastomosis. In general to prevent lengthy

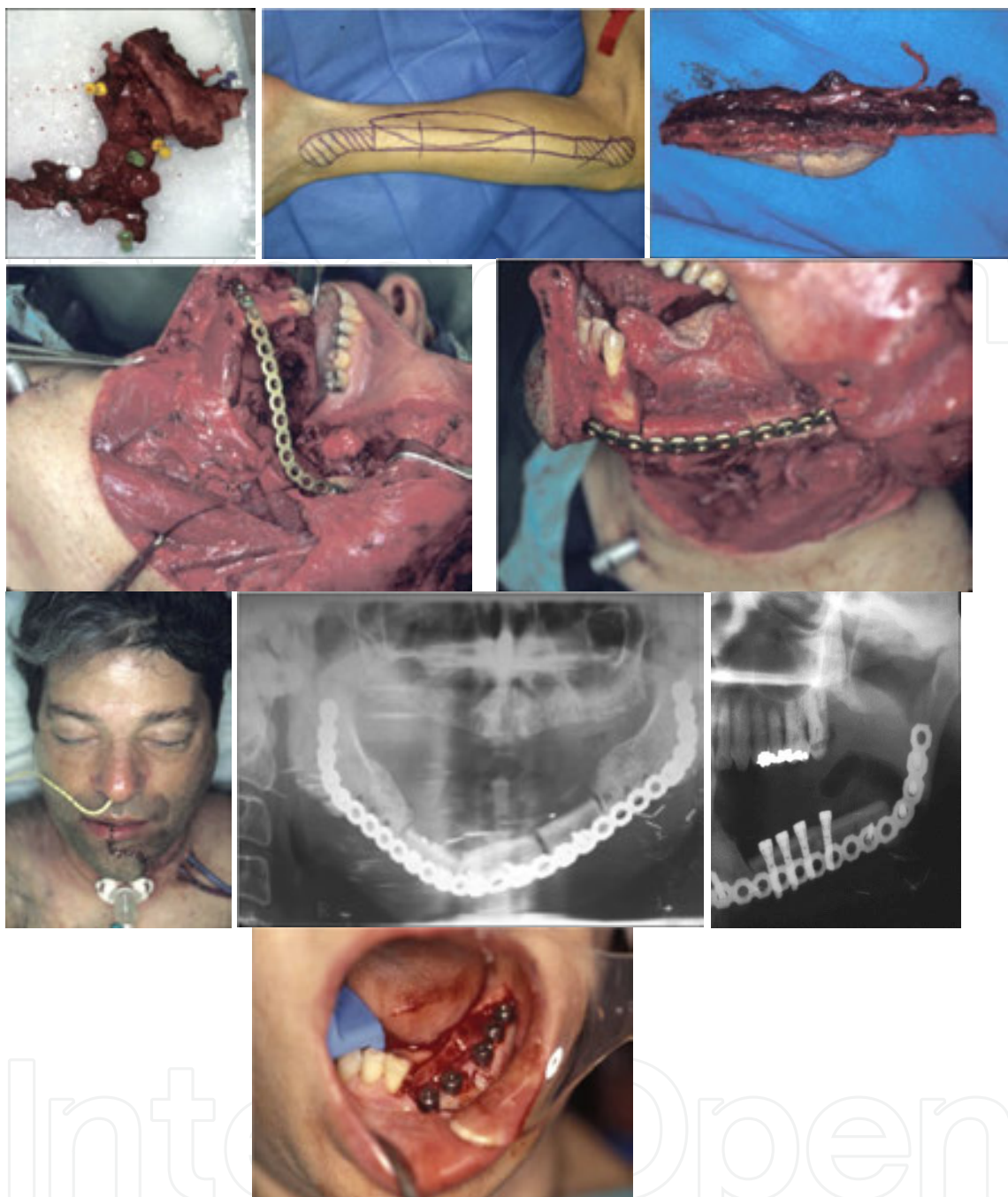

Figure 26. Free fibula flap reconstruction

Other Free Flaps in Head and Neck Reconstruction

4.3. Linked Free Flaps

The goal of reconstructive surgery is to replace bone and soft tissue in a manner such that functional and aesthetic problems are minimized. For this reason, a large number of pedicled myo-osteocutaneous flaps and free tissue transfers have been developed. Patients who have undergone previous surgery and radiation develop poor recipient beds. In these cases, vascularized bone has become a viable treatment option. In cases in which complex soft tissue and bony defects have resulted from tumor extirpation, multiple head and neck surgical myo-osteocutaneous flaps and free tissue transfers have been developed. Patients who have

undergone previous surgery and radiation develop poor recipient beds. In these cases, vascularized bone has become a viable treatment option. In cases in which complex soft tissue and bony defects have resulted from tumor extirpation, multiple head and neck surgical operations, and past irradiation, limited recipient vascularity requires reconstructive modalities other than a single osteocutaneous flap. Because of their limitations, linking of free flaps has become a preferred method of reconstruction for complex composite head and neck defects. The use of sequentially linked free flaps is best suited to cases of composite defects that cannot be adequately restored by a single flap, large through-and-through head and neck defects, limited native vasculature from either previous surgical excisions or preoperative radiation, lack of availability of local or regional flaps, and defects that require both adequate bony stock and a thin mucosal lining for intraoral coverage. [99-117]

Wells and coworkers [118] described their technique for using the radial forearm flap in conjunction with a free fibular transfer. Similar experiences were shared by Camilleri and associates [119] reporting survival rates of 98%. Elevation of the flaps occurred simultaneously and independently of each other, as described earlier. The peroneal vessels and vein from the contoured fibular flap and the radial artery vessels and cephalic vein were anastomosed in an end-to-end fashion, respectively. The long pedicle of the forearm flap allowed for primary anastomosis of the linked flaps without the use of intervening vein grafts. The radial artery was then anastomosed end to end to a branch of the external carotid artery, and the cephalic vein was anastomosed to the external or internal jugular vein in an end-to-end configuration. This technique is advantageous because there is no ideal osteocutaneous free flap that provides both an unlimited amount of bone and a reliable cutaneous component. The fibula provides ample bone stock to reconstruct the entire mandible, and the forearm furnishes a thin, reliable, hairless sensate flap for intraoral lining. The potential disadvantage is the risk of proximal thrombosis, which results in the loss of two free tissue transfers. Also, extra operative time is involved in the microvascular reconstruction. However, if the two donor sites are appropriately spaced, the use of two surgical teams may reduce operative time. Penfold and colleagues [120] described the combination serratus anterior-rib flap with the latissimus dorsi myocutaneous flap for mandibular reconstruction. Their technique accesses both flaps through a single skin incision placed along the anterior border of the latissimus muscle. After elevating this muscle, the lower part of the serratus anterior muscle is exposed. A segment of rib (either sixth or seventh in this location) with its associated periosteum and a cuff of muscle above and below is elevated on the serratus muscle pedicle. The superior part of the latissimus dorsi muscle is then divided, and the combined flap is transferred on a common pedicle of the thoracodorsal vessels. The donor site is closed primarily. The vascular anastomosis can then be performed in an end-to-side fashion to the external carotid artery and vein, or to the facial artery and vein. The amount of tissue provided by the latissimus dorsi muscle flap for transfer is ideal for reconstructing large mandibular defects, which are often associated with extensive soft tissue losses involving the floor of the mouth. The disadvantages of using such a combined flap include those associated with serratus-rib composite flaps, such as insufficient bony stock to allow for placement of osseointegrated implants. Even though bulky tissue is required for reconstructing extensive soft tissue defects, the combined flap may provide excessive tissue bulk in the neck, resulting in poor cosmesis. Another variation in flap design is the combined

V-shaped scapular osteocutaneous and latissimus dorsi myocutaneous flap, used for primary or secondary reconstruction of the mandible, intraoral mucosa, and external skin. The design, reported by Yamamoto and coworkers [121], is based on the vascular network including the angular branch from the thoracodorsal artery, the dorsal scapular artery, the circumflex scapular artery arising from the subscapular artery, and the suprascapular artery. They reported seven cases in which this reconstructive option was employed, citing six successful cases. The fact that this combined flap is nourished by the angular branch allows the graft to have an independent long arc of rotation. The V shape of the grafted bone has a reliable blood supply from the vascular network. Combining this bone graft with a myocutaneous component, the latissimus dorsi flap, allows the reconstruction of large soft tissue losses in the oral floor or submandibular region. The latissimus dorsi muscle may also restore tongue volume when large tongue defects coexist. As already mentioned, the main disadvantage of using the latissimus dorsi flap in conjunction with a scapular bone flap is the necessity of patient repositioning for flap harvest. Thus, the operation is usually prolonged. Also, the quality of bone retrieved from the scapula is not adequate to accept dental reconstructive implants, unless the lateral border or inferior angle of the scapula is obtained.

5. Site specific reconstruction problems

5.1. Mandibular reconstruction

Mandibular reconstructive procedures have conventionally consisted of bone graft replacing the resected defect. Historically, Macewen [122] discussed the reconstruction of defects using a tibia harvested graft. Blocker and Stout [123] described the use of iliac crest in the mandible. Development of other donor sites was sought, with disappointing results. Metallic cribs and mesh trays to contain the grafts were designed but were suboptimal for primary reconstruction. Furthermore, in patients who had been irradiated or who presented with extensive soft tissue defects, successful reconstruction was difficult to achieve, as there was a greater chance of postoperative infection due to diminished blood circulation, ingress of oral flora, and an absent blood supply to the grafted bone. One technique that would provide increased resistance to infection was to use pedicled grafts. Conley [124] and Snyder [125] published the first case reports using osteomyocutaneous flaps in the immediate reconstructive setting. Numerous other flaps followed, with minimal reliability and poor success rates. They were subsequently considered unacceptable for primary mandibular reconstruction. Because the defect site is plagued with soft tissue loss, oral contamination, and compromised irradiated tissues, free vascularized grafts were thought to be the ideal choice. McKee [126] and Daniel [127] were the first to report the outcomes of free vascularized composite rib flaps in a large series of patients. Success rates have increased for microvascular free tissue transfers using iliac crest and scapular free flaps, reaching 96% [128]. With the recent development of rigid fixation systems, reconstruction of the mandible with a combination of metallic plate and pedicled osteomyocutaneous flap or microvascular free tissue transfer has been advocated. Essentially, reconstruction of the mandible with bone grafting must be dimensionally and

structurally stable, capable of withstanding the functional demands of prosthesis. The graft must be able to maintain a correct arch form and continuity, with significant bone height and osseous bulk for full prosthetic rehabilitation and an acceptable facial form. The primary goals of mandibular reconstruction are to achieve primary wound closure and to achieve adequate range of motion with a stabilized, repetitive occlusion, dependent on the maintenance of physiologic condylar position. Bony reconstruction is of importance when acceptable facial aesthetics are required. If a defect in the anterior symphysis or chin region were not addressed, an "Andy Gump" deformity would result, with posterior and inferior collapse. Lateral defects stabilize jaw symmetry and contour. Functionally, masticatory difficulties result from poor bony reconstructive efforts. Inadequately repaired regions result in jaw deviation and inability to fabricate an acceptable prosthesis. Soft tissue attachments to the mandible are also affected (i.e., lip, floor of the mouth, tongue, hyoid musculature). Thus, poor restoration of a mandibular defect results in oral incompetence and difficulties with speech, mastication, and swallowing functions. Bony mandibular defects are classified by the amount of hard tissue loss specific to an anatomic region. For example, class I mandibular defects involve the alveolus, but with preservation of mandibular continuity; class II defects involve loss of continuity distal to the canine; class III involves loss up to the mandibular midline region; class IV deficiencies involve the lateral aspect of the mandible but are augmented to maintain pseudoarticulation of bone and soft tissue in the region of the ascending ramus; class V involves the symphysis and parasymphyseal regions only, augmented to preserve bilateral temporomandibular articulations; class VI is similar to class V, except that mandibular continuity is not restored. Similar functional deficits can occur with inadequate soft tissue reconstruction. For example, inadequate mucosal replacement can create restricted tongue mobility and insufficient space for dental reconstruction.

5.2. Reconstruction of symphysis, condyle, and ramus

Symphyseal mandibular defects resulting from cancer ablation continue to be a surgical problem. Many techniques using autologous bone grafts, osteomyocutaneous regional and free flaps, and alloplastic and allogeneic materials have been described in the literature, with variable results. As in all reconstructive surgical cases, the primary goals are restoration of function and cosmesis. Recently, distraction osteogenesis has been used in mandibular reconstruction. In essence, a vascularized bony segment is stretched, or distracted, across a defect, inducing new bone formation from the native bone. This process has been well described in the orthopedic surgical literature for the reconstruction of long bones in lower extremities. Bony defects of the symphysis create a great cosmetic and functional problem. Annino and associates [129] created iatrogenic mandibular symphyseal defects in the canine model and reported great success with the use of a trifocal distraction osteogenetic appliance. Mandibular body segmental defects were also reconstructed by distraction osteogenesis, and biomechanical testing revealed the newly generated bone to have approximately 77% the strength of the native bone. Owing to the complexity of applying this device, it is not recommended for the reconstruction of mandibular condylar or ramus regions.

5.3. Reconstruction plates

The AO stainless steel plate has been available for many years as an effective means of mandibular replacement. Mignogna and colleagues [130] commented on their experiences using the AO reconstruction plate with a sternal osteomyocutaneous flap in primary mandibular reconstruction. They replicated the mandible with a malleable pattern before excision and transferred its shape to an AO reconstruction plate, which was then positioned to the unresected portions of the mandible with drilled pilot holes. Once resection takes place, the pectoralis myocutaneous flap is harvested, and the sternum is split to the size of the defect. The osteocutaneous flap is placed at the defect site, and the AO plate is rigidly fixed into position using noncompression screws. Closure of the myocutaneous portion of the flap is carried out meticulously to prevent oral contamination. Mignogna and colleagues believe that the increased operative time, high failure rate, frequent need for operative rescue, and need for specialized training, care, and facilities make reconstruction with vascularized free flaps an impractical option for reconstructive surgeons. In the titanium hollow screw system (THORP), hollow screws integrate at the surface level and permit ingrowth of bone that locks each screw in place. Before resection, the plate is bent and shaped to the existing contours of the mandible [131]. The resected mandible may also serve as a template for plate bending and hole drilling. The plate is generally contoured to the inferior border of the mandible to avoid tooth roots, maintain facial contour, leave space for osseointegration, and keep it well away from the oral mucosa to lessen the chance of intraoral exposure. Metallic fatigue and plate exposure are some of the complications that require removal and replacement. Intraoral exposures are frequently associated with granulation tissue that heals in the immediate postoperative period. Nonetheless, it remains an excellent method of fixing a vascularized bone graft.[132] The plates, in general, provided better cosmetic results than autogenous bone grafting, because there is greater flexibility in contouring a metal plate as opposed to a linear bone strut. Alloplastic metallic plates provided a more rapid postoperative oral rehabilitation and have become a viable reconstructive option. Cordeiro and Hidalgo [133] studied the effects of soft tissue coverage for titanium reconstructive plating systems. They compared patients who received pectoralis major flaps with those who received soft tissue-free flaps. Forty-four percent of the patients with pectoralis flaps had extrusion of the hardware, requiring its subsequent removal. They commented that the excessive tension placed on the flap, from the shoulder-based pedicle; create this high risk of failure. Moreover, despite the increased operative time to acquire free tissue for transfer, as well as the complexity of its harvest; free flap patients had shorter hospital stays, higher overall success rates, and fewer additional procedures. Their data suggest that a free flap provides more reliable soft tissue coverage of reconstruction plates than does a pectoralis flap.

Recently, Blackwell and colleagues [134] looked at the outcomes of using various soft tissue free flaps in conjunction with mandibular reconstruction plates. Even though the added morbidity associated with harvesting free vascularized bone grafts is higher than that for harvesting soft tissue alone, they found a high rate of delayed failure (40%) using metallic reconstruction plates and soft tissue. Thus, they advocate the practice of using vascularized bone-containing free flaps or a combination of free flaps for patients who are undergoing

primary reconstruction of lateral mandibulectomy defects. Kudo and associates [135] evaluated the use of various mandibular reconstructive techniques. They commented on the excellent long-term results when using AO-type reconstruction plates, citing successful reconstruction lasting over 10 years, provided sufficient soft tissues exist. When there is a lack of soft tissue, avoidance of plate exposure is best handled by using a myocutaneous flap. Immediate reconstruction of the posterior region of the mandible was most appropriately treated with a metallic plate or a myocutaneous flap and bone graft. Anterior mandibular regions that were immediately reconstructed with autogenous bone grafts resulted in post-operative infection. The authors recommended delayed bone grafting after immediate fixation using a metallic plate to bridge the mandibular defect. An extensive defect of the anterior region requires immediate reconstruction with a myocutaneous flap and bone graft.

5.4. Reconstruction of maxillary and midfacial defects

Tumors of the midface account for a small subset of head and neck cancers. Malignancies of the paranasal sinuses make up 0.2% of the total number of malignancies and 3% of all cancers in the aerodigestive tract. Tumors of the palate are uncommon, representing 8% of all oral cancers and 5% of all aerodigestive carcinomas. The goal in treatment and reconstruction of these cancers is extirpation in toto and cure of the patient with restoration of aesthetic form and function [136]. In many situations, the surgical resection results in a significant functional loss, causing feeding and speech developmental problems with oral-antral communication and velopharyngeal incompetence. Loss of the orbital floor and Lockwood's ligament may result in the loss of orbital support, with ensuing exophthalmoses and orbital dystopia. Reconstructive options are determined primarily by the extent of the midfacial skin deficit, the extent of maxillary buttress resection, the size of the palatal defect, and the loss of orbital support (Figure 27).

Type I defects are those with loss of midfacial skin of the cheeks and lips only. The underlying bony skeleton is not affected. These cutaneous defects can be restored with standard soft tissue reconstructive techniques, from simple primary closure in areas of lax surrounding soft tissue to skin grafts and use of cervicofacial flaps. Larger tissue deficits require regional or distant flaps, such as, latissimus dorsi, temporalis, or forehead flaps. Larger aesthetic units may require resurfacing with free tissue transfers.

Type II and III defects result from partial maxillectomy procedures in which the palate is complete or a portion of the palate is lost, respectively. Traditionally, these midfacial defects are satisfactorily restored by fabrication of a maxillofacial prosthesis in which the denture and palatal obturator close the oral antral fistula and provide projection of the midface. The only requirement for success is that there is an adequate residual palatal arch with enough surrounding soft tissues to support the prosthesis. The impression is taken of the defect well after swelling has subsided, approximately 3 to 4 weeks. The silicone prosthesis constructed from the impression is custom made and attached by previously inserted integrated fixtures and abutments. Other patients may benefit from reconstruction with autogenous tissues, with the use of ipsilateral or bilateral temporal muscle flaps or facial artery musculomucosal flaps, which are often used to reconstruct small oroantral fistulae and palatal defects.

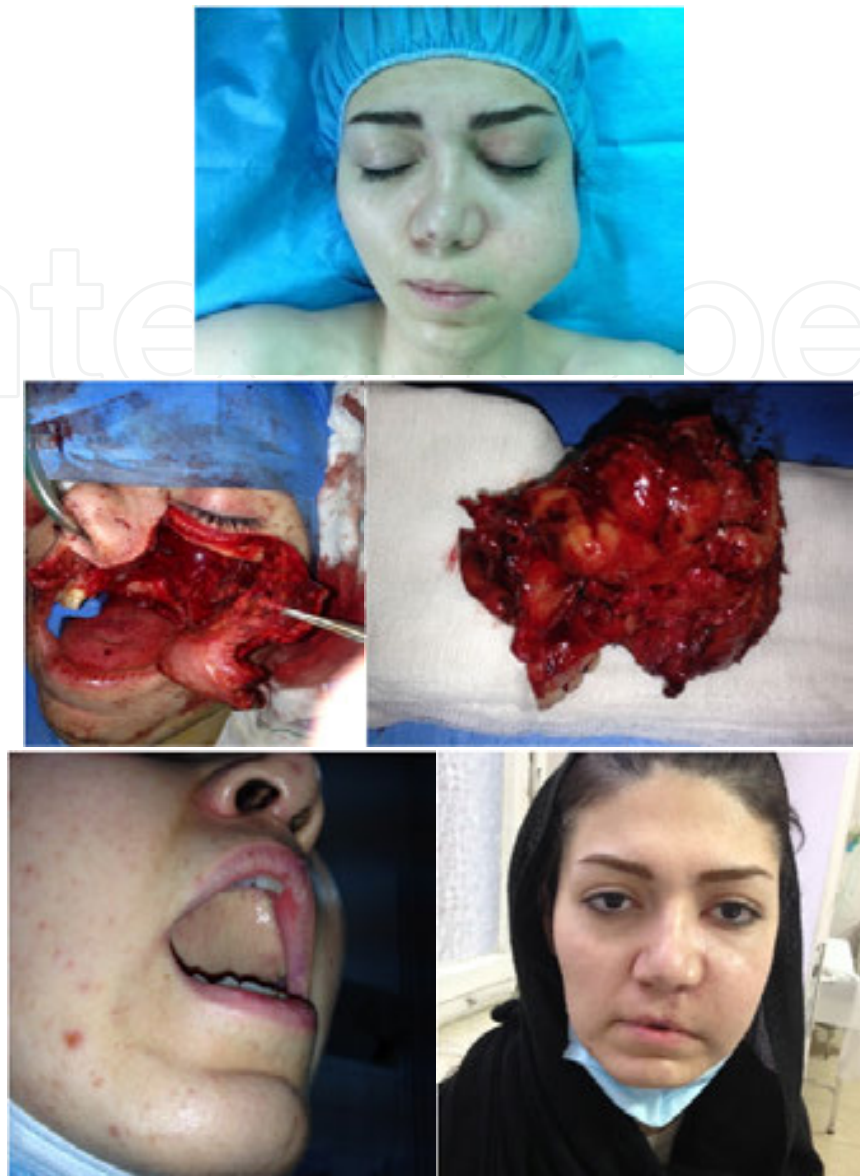

Figure 27. Maxillary tumor reconstruction

Type IV defects that result after total maxillectomy with a concomitant palatotomy are best served by reconstruction with autogenous tissue via regional or distant flaps. The aforementioned pedicled flaps and free tissue transfers are all indicated to redrape defects in the middle third of the face. The bony component is addressed with vascularized bone with its cutaneous counterparts, or bone combined with separate free soft tissue flaps used as linked flaps. For example, by combining the bony reconstruction with scapular and parascapular paddles, massive defects of the midface can be reconstructed with primary closure of the donor site. In this case, the muscular portion of the transfer can be used to obliterate the dead space of the maxillary sinus defect, and the cutaneous aspect can be used to resurface the face and palate.

Type V defects are type IV defects that extend into the orbital floor. Tumors that require exenteration of the orbit should be followed by reconstructive procedures that obliterate the

orbital cavity and restore facial contour. Orbital support procedures, described by Ilankovan and Jackson [137], include split-thickness vascularized calvarial bone pedicled on either the temporalis or the superficial temporalis muscle to reconstruct the orbital floor. A temporo-parietal facial flap has been used for orbital and eyelid reconstruction. Free transfer flaps are advocated for this reconstructive challenge, as there are no limitations with

rotation and the goals of maintaining facial structural stability and contour are upheld. Sadove and Powell [138] described a one-stage reconstruction of the subtotal maxillectomy and hemimandibulectomy with a free fibular osteocutaneous flap. After harvesting a vascularized fibular bone flap, multiple osteotomies allow the surgeon to shape the bone and simultaneously apply the segments to the maxilla and mandible. The technique applied was taken from Jones and colleagues [139]. In their "double-barreled" bone graft, transverse osteotomies produce two vascularized bone struts that can be folded parallel to each other and connected by the periosteum and muscle cuff pedicle. Here, three bone struts were employed; the distal end of the fibula was rigidly fixed to the small remaining portion of the maxilla, and a transverse osteotomy allowed a 90-degree turn of the segment. A second osteotomy was then performed to allow fixation to the remaining zygomatic fragment, and all osteotomies were rigidly fixated with miniplates and screws. A third osteotomy in the remaining third portion of the harvested fibula allowed removal of a 3- cm segment, which would account for the distance between the maxilla and mandible. The remaining vascularized bony segment was then rotated and used to bridge the mandibular bony defect, and rigid fixation was similarly applied. The accompanying peroneal vessels were anastomosed end to side with a radial artery, from a radial artery forearm flap. The combination of radial forearm and fibular fasciocutaneous flaps offers excellent versatility to meet the extreme three-dimensional demands of reconstruction of massive injuries to the face.

5.5. Lip reconstruction

The overall survival rate for carcinomas involving the lip has increased over the past 30 years to 85% to 90%. Because regional spread is uncommon in the behavior of lip cancers, reconstruction after tumor ablation becomes paramount in these patients. Most neoplastic processes occur in the lower lip, and almost all lesions are epidermoid or squamous cell carcinomas. Upper lip malignancies are almost exclusively basal cell cancers. The primary function of the lip is oral competence, along with its role in speech, deglutition, and beauty. The competence is provided by the sphincter muscles, the orbicularis oris muscle, and a number of elevator and depressor muscles. Its primary blood supply is from the superior and inferior labial arteries, which are direct branches of the facial artery. When performing lip reconstruction, one must attempt to retain the sphincter muscle function, obtain a watertight oral seal, and allow sufficient opening for daily dietary habits. In defects of 30% to 65%, upper lip tissue may be transferred by a pedicle flap based on the labial artery [140]. The oral commissure is preserved when using this in conjunction with the Abbe technique or when the flap is rotated around the commissure using the Eastlander method. The flap on the upper lip is designed with the medial incision on the philtrum ridge to allow closure of the donor site on this natural landmark. The largest flap that can be designed is approximately 2 cm, and one fourth of the

upper lip can be excised and closed primarily. The Karapandzic technique also uses lip tissue by advancing and rotating segments of skin, orbicularis muscle, and mucosa. However, the principal disadvantage is the creation of microstomia. Local flaps are preferable to regional flaps for closing defects of less than two thirds of the lip width because of their skin color and texture match and the availability of mucous membrane for internal lining. Defects greater than two thirds of the entire lip are best reconstructed using adjacent cheek flaps. Large defects of the upper lip may be reconstructed by excising crescent-shaped peri-alar cheek tissue and advancing the flaps medially. For larger defects, between 65% and 80%, the cheek tissue can be advanced as in the Webster-Bernard approach. This technique, however, has led to the development of chronic tension, resulting in a poorly functioning lower lip. Karapandzic lip rotation has been used, without inevitable microstomia. This approach requires dissection of the remaining lower lip segment, the modiolus bilaterally, and the lateral upper lip tissue, and then advancement of these components to reconstruct the lower lip deficiency. Defects greater than 80% to 85% have been reconstructed with inferiorly based nasolabial flaps. Massive defects of the lip, chin, and mandible are reconstructed with the use of distant flaps, transferring composite flaps of skin and bone revascularized by microvascular techniques. The radial forearm flap, incorporating the plantaris tendon, provides excellent support to the circumoral structures (Figure 28).

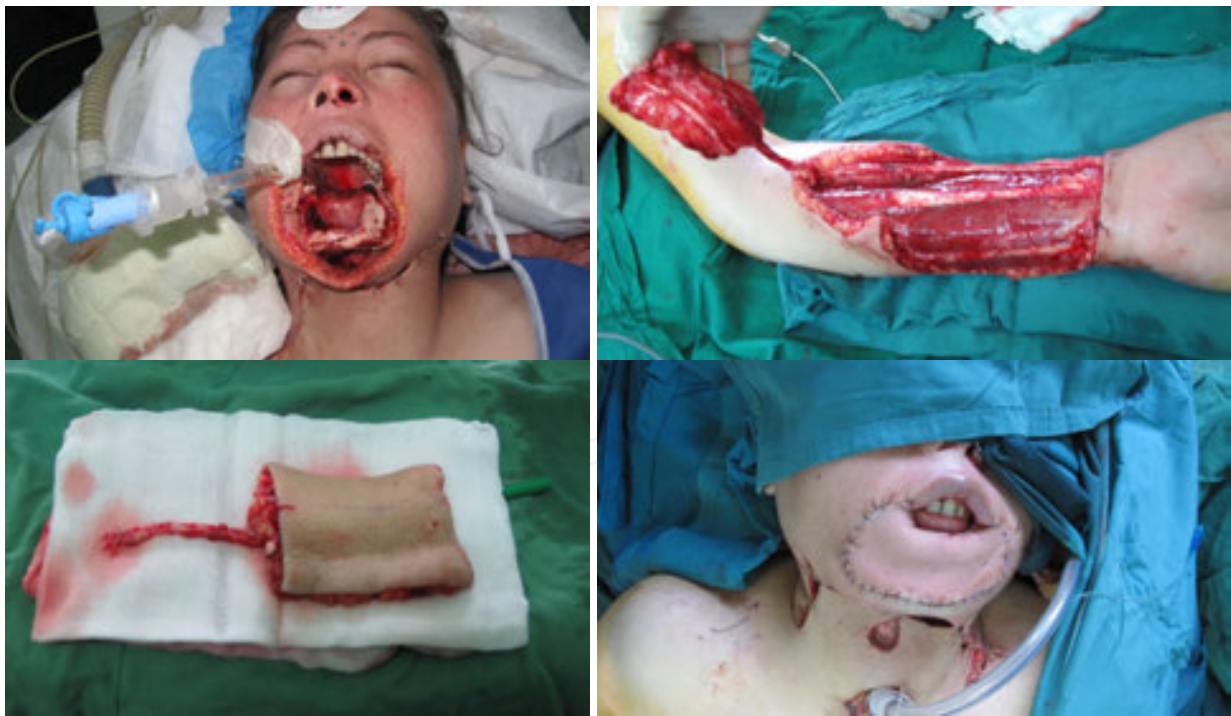

Figure 28. Total reconstruction of the lower lip

Figure 28. Total reconstruction of the lower lip

Sensation can be restored by suturing the antebachial cutaneous nerve of the flap to the stump of mental neural tissue. To effectively reconstruct the lower lip, the skin, mucosa, and functioning muscle must be replaced. Dissection of the platysma myocutaneous flap with an extended muscle pedicle including the cervical branch of the facial nerve would greatly improve its motor function. This has yet to be demonstrated clinically. The temporal forehead flap can be used for total upper lip reconstruction, but a secondary cosmetic deformity precludes its common use. More recently, the pectoralis major myocutaneous flap has been used for lip reconstruction; it has the advantage of being an axial myocutaneous flap that may be elevated as a strip of muscle, and a portion of the flap may be turned on itself to provide tissue for the inner aspect of the lips or anterior floor of the mouth [141]. The development of microvascular techniques has allowed reconstruction of concomitant defects of the lip, chin, and anterior mandible by transferring free composite osteomyocutaneous flaps, providing vascularized bone grafts for mandibular reconstruction.

extended muscle pedicle including the cervical branch of the facial nerve would greatly improve its motor function. This has yet to be demonstrated clinically. The temporal forehead flap can be used for total upper lip reconstruction, but a secondary cosmetic deformity precludes its common use. More recently, the pectoralis major myocutaneous flap has been used for lip reconstruction; it has the advantage of being an axial myocutaneous flap that may be elevated as a strip of muscle, and a portion of the flap may be turned on itself to provide tissue for the inner aspect of the lips or anterior floor of the mouth [141]. The development of microvascular techniques has allowed reconstruction of concomitant defects of the lip, chin, and anterior mandible by transferring free composite osteomyocutaneous flaps, providing vascularized bone grafts for mandibular reconstruction.

5.6. Tongue reconstruction

Reconstruction of hemiglossectomy requires a thin-tissue flap. Many flaps have been advocated for this purpose. The forearm flap is easily retrieved, but the donor site must receive skin grafting coverage. Because this is an area of daily exposure, its appearance may not be well tolerated by patients. The forehead flap is also easy to harvest, but one of the complications is facial nerve palsy from damage to the temporal branch of the facial nerve. In order to restore the tongue's sensation, a neurovascular radial forearm flap and lateral arm flap could potentially fulfill a sensory function if anastomosed to the lingual or inferior alveolar nerve (Figure 29).

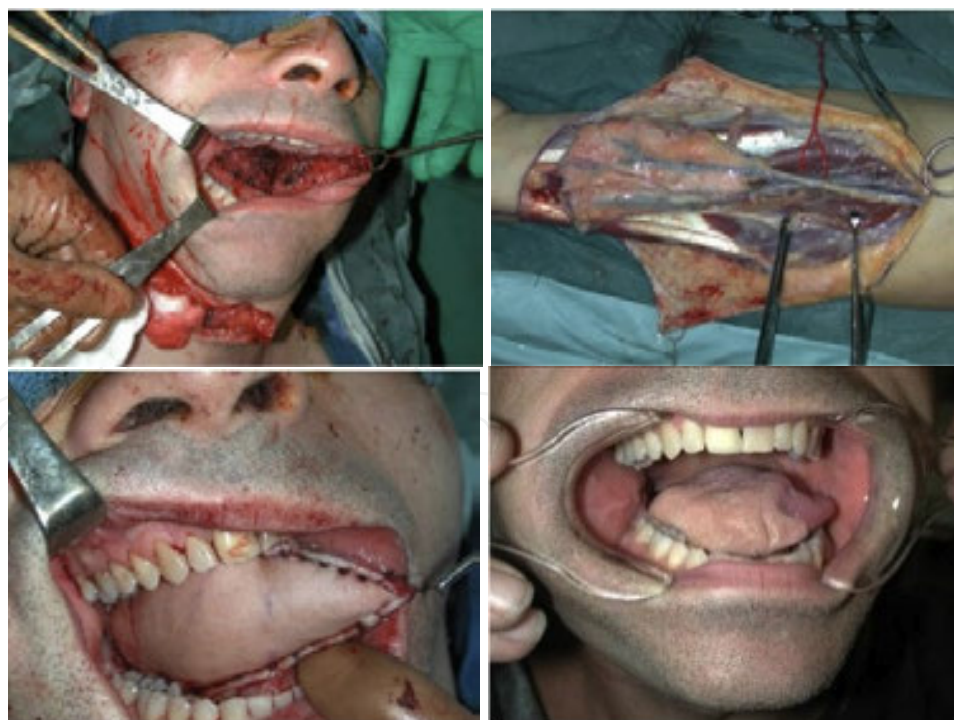

Figure 29. Tongue reconstruction

The dorsalis pedis flap has recently received attention, as it is thinner than the lateral forearm flap. The donor site is well covered, and its distal location allows simultaneous harvest and closure. The only functional disturbances are related to slight sensory alterations, which have to improve over time. No motor deficits or impairments have been reported. Initially, angiography was recommended, but a Doppler flowmeter is able to detect dorsalis pedis patency. The largest skin island that can be obtained is approximately 9 by 8 cm, designed to include the dorsalis pedis artery and the first metatarsal dorsal artery. Dissection is elevated and the dorsalis pedis artery is located laterally to medially. The exten-

ablation. The only functional disturbances are related to slight sensory alterations, which have been shown to improve over time. No motor deficits or impairments have been reported. Initially, preoperative angiography was recommended, but a Doppler flowmeter is able to detect dorsalis pedis artery patency. The largest skin island that can be obtained is approximately 9 by 8 cm. The flap is designed to include the dorsalis pedis artery and the first metatarsal dorsal artery. Distally, the flap is elevated and the dorsalis pedis artery is located laterally to medially. The extensor hallucis brevis tendon should be cut because it crosses the first metatarsal artery. If a long pedicle is desired, the inferior extensor retinaculum is incised to elevate the tibialis anterior artery and dorsalis pedis artery. The donor site is then covered by a split-thickness skin graft [142].

5.7. Nasal reconstruction

The most common causes of nasal defects are wide surgical excisions of nasal tumors, followed by trauma and infection. Most nasal skin tumors are basal cell carcinomas, with squamous cell carcinomas accounting for up to 50% of all aggressive tumors. Frequently, treatment of these neoplastic processes requires hemirhinectomy or total rhinectomy to achieve cure. Historically, the use of a nasal prosthesis attached to spectacles was cosmetically acceptable but could be troublesome and lead to patient noncompliance. In fact, more patients have opted for immediate reconstruction [143]. The principles of nasal reconstruction are to replace the lost mucosal lining, reconstruct the skeletal framework, and achieve adequate external skin coverage. The mucosal lining is best replaced by folding full thickness adjacent nasal skin or by using nasolabial flaps or a fold-down median forehead flap (the Kazanjian flap) (Figure 30). [144]

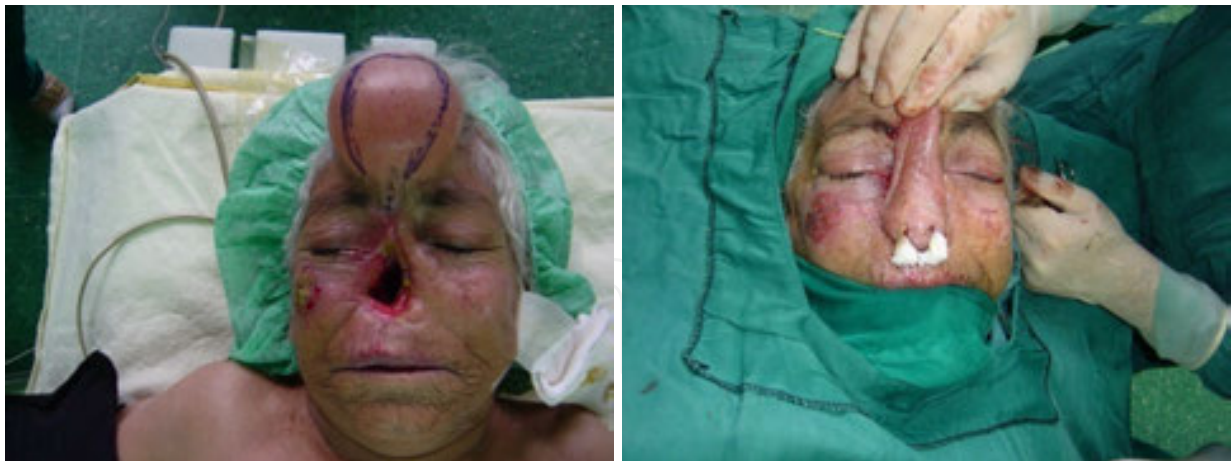

Figure 30: Nasal reconstruction using tissue expansion

The skeletal framework provides support to prevent sagging of overlying tissues, which can lead to nasal stenosis and a poor cosmetic result. The framework can be made by advancing the remaining septal cartilage or using a composite conchal graft, cartilage xenograft, Silastic prosthesis, or cantilever bone graft, which is usually a strut of rib bone graft fixed at its base to the nasal or frontal bones by osteosynthesis wires or plates. The problem arises when trying to match color and texture to replace the external skin covering. This has led to the development of many types of flap designs, including median forehead flaps, based on the supraorbital and supratrochlear vessels, and the scalping forehead flap, which resembles the nasal skin in color and texture and is based on the superficial temporal artery. Primary closure of these forehead flaps can be accomplished with the use of tissue expanders. This, however, requires multiple staged procedures, which may affect patient willingness. The retroauriculotemporal flap, or Washio flap [145], is based on the anastomosis between the posterior branches of the superficial temporal and

to match color and texture to replace the external skin covering. This has led to the development of many types of flap designs, including median forehead flaps, based on the supraorbital and supratrochlear vessels, and the scalping forehead flap, which resembles the nasal skin in color and texture and is based on the superficial temporal artery. Primary closure of these forehead flaps can be accomplished with the use of tissue expanders. This, however, requires multiple staged procedures, which may affect patient willingness. The retroauriculotemporal flap, or Washio flap [145], is based on the anastomosis between the posterior branches of the superficial temporal and retroauricular vessels. Its advantage is that the donor site is hidden and composite skin and conchal cartilage are available. Distant pedicled flaps from the arm or neck have been used but require prolonged periods of immobilization and often have poor cosmetic results. Free microvascular tissue transfer can also provide tissue coverage, as well as bony support (Figure 31).

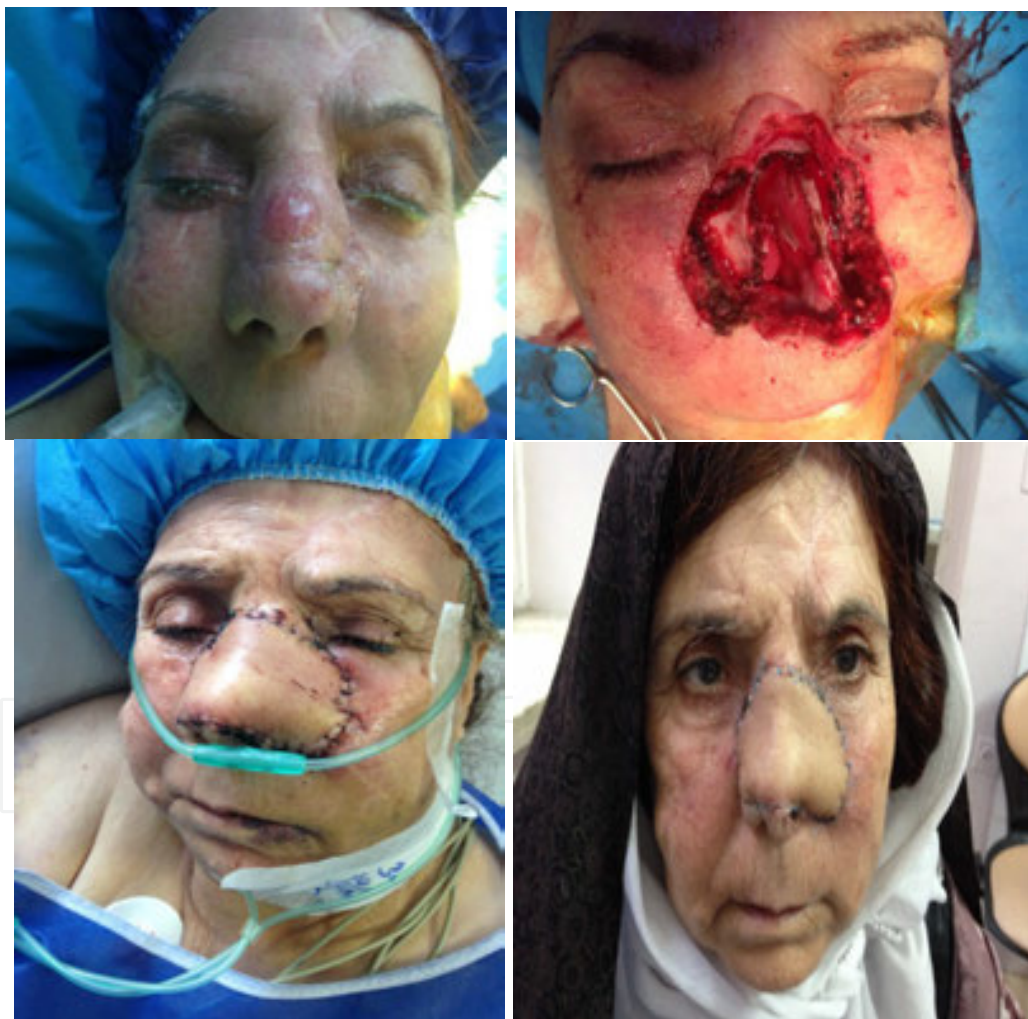

Figure 31. Free flap nasal reconstruction

For example, in the dorsalis pedis osteocutaneous flap, skin is taken from the dorsum of the foot, associated with a vascularized bone graft from the second metatarsal bone.

Reconstruction of the Buccal Mucosa

Cancers occurring in the buccal mucosa account for only 10% of all oral cavity carcinomas. There is a higher distribution in the southeastern United States, where "snuff dipping" is a common practice. These lesions tend to occur along the occlusal plane or just below it, and involve the mandible more than the maxilla. These types of lesions are readily treated with surgical

5.8. Reconstruction of the buccal mucosa

Cancers occurring in the buccal mucosa account for only 10% of all oral cavity carcinomas. There is a higher distribution in the southeastern United States, where "snuff dipping" is a common practice. These lesions tend to occur along the occlusal plane or just below it, and affect the mandible more than the maxilla. These types of lesions are readily treated with surgical ablative surgery, followed by reconstructive efforts to restore the defect. Smaller lesions can be successfully treated with local and buccal flaps. When larger defects are left from surgical excision of larger tumors, more substantial flap designs are required. The buccal cavity allows for expansion of the oral cavity during opening and chewing. Limitation in this region affects jaw function and vestibular loss. Because the buccal mucosa requires a thin, soft, pliable flap for its reconstruction [146], a deltopectoral flap is an ideal choice. It is, however, a two-stage procedure that gives a significantly better result than simple myocutaneous flaps. A thin flap reconstruction can also be achieved with a microvascular free tissue transfer of jejunum used as a patch graft, or with a radial forearm flap. Large full-thickness defects have historically been reconstructed using forehead flaps, temporalis muscle flaps, or pectoralis, latissimus, or trapezius muscle flaps [147]. The operative combination of lower lip splitting incisions and composite anterior oromandibular reconstruction creates a pre-disposition to increased lip and labial sulcus deformities related to abnormal wound healing, which is commonly caused by extensive anterior floor of the mouth and oral lining defects combined with partial skin paddle necrosis, inadequate intraoral lining replacement, closure under excess tension, over projection of mandible reconstruction, and improper draping of the soft tissues of the chin to the reconstructed mandible. The lower lip deformity is called a reverse whistling deformity [148]. It is a vertically short lip with central notching associated with oral incontinence and an inadequate lower labial sulcus. To repair this cosmetically displeasing complication, the scar contractures are released with excisions, and vertical musculomucosal turnover flaps are combined with bilateral lip advancement to improve the deficient lip height and labial sulcus. The blood supply to these flaps is based on inferior labial artery and submental artery distributions, which are branches of the facial artery.

5.9. Craniofacial reconstruction

Large resections during cranial surgery produce severe disfigurement and emotional anguish, with significant functional impairment for the patient. After surgical management of skull-based malignancies, the reconstructive surgeon is faced with the extensive task of not only restoring the anatomic defects but also preventing potentially life-threatening complications, such as ascending meningitis from the close proximity of the paranasal sinuses and nasopharynx to the dura. Reconstructions may be immediate or delayed. Although immediate reconstruction after extensive resection of aggressive or recurrent tumors has been recommended, it is not routinely practiced, because extensive immediate reconstruction may lead to delayed detection of early recurrence. Also, the ideal reconstructive option, which is usually the first major reconstruction, would be sacrificed. The two indications for immediate reconstruction are to prevent ascending infection from an open nasopharynx or to close the frontal sinus, and to prevent exposure of brain and/or bone. Historically, many cranial base defects were treated

with the use of local flaps through a "patch" design. Myocutaneous flaps were then developed, with the pectoralis major and latissimus dorsi flaps becoming the most widely employed. Finally came the advent of free tissue transfer for larger defects requiring well-vascularized tissue with bulk, not restricted by pedicles. As experience with free flap harvest has been gained, complication rates have dropped. The correct selection and application of these reconstructive methods require that the surgeon appreciate the capabilities of each technique. Often a combination of techniques is required for optimal reconstruction. The most common combination is an internal fixation device and a bone graft. In the reconstruction of cranio-orbital defects, the following goals are addressed: achieve a tight dural seal to isolate the intracranial contents from the aerodigestive tract, obliterate dead spaces in the sinuses to remove potential sources of infection, suspend and support neural structures, provide bone and soft tissue coverage, maintain function, and achieve optimal cosmetic result [149]. The likelihood of recurrence of the disease and its concealment by the reconstruction has been a major deterrent to midface reconstruction. Calvarial grafts, having a membranous bony quality with delayed resorption, are excellent replacements for the orbital floor and nasal dorsum. Stability is maintained with rigid fixation. When combined with the temporoparietal fascia, a calvarial graft provides an excellent source of vascularized tissue for enhancing soft tissue reconstruction to the orbit and maxilla. However, because it is based on a pedicle, its arc of rotation limits its flexibility. Free tissue transfer using microvascular anastomosis has alleviated this problem. The scapula, radial forearm, and dorsalis pedis osteocutaneous flaps all have fairly long pedicles and can carry both skin and bone reliably. The deep circumflex iliac artery flap has a short pedicle, thick skin, and little mobility, making it more difficult to maneuver. A modification of the scapular flap using the angular artery, which supplies the entire lateral border of the scapula, can increase the pedicle from 4 to 9 cm to 13 to 18 cm; this allows the skin and bone to have much longer, independent arcs of rotation, so that they can be used in different parts of the reconstruction, such as skin for the palate and lateral nasal wall and bone for the infraorbital rim, with the two segments supplied by the same subscapular pedicle [150]. Preoperative planning for osseous reconstruction begins with a careful and thorough history and physical examination. Radiographic imaging with standard cephalometric radiographs and CT with three dimensional reconstructive images are very useful. Reconstructions of the cranial base are divided by their anatomic designs. Classifications by Jones and Jacksons have been widely used to integrate the anatomic boundaries with tumor growth patterns in different regions. Region I corresponds to defects extending from the anterior midline to the posterior wall of the orbital cavity, but including an extension down the clivus to the foramen magnum. This region houses tumors from the maxilla, maxillary antrum, parotid gland, and midfacial skin. Initially, reconstruction was aimed at covering the exposed dura with the use of nonvascularized split-thickness skin grafts, such as tensor fascia lata grafts. Failures would occur in 50% of the cases in which dural leaks of cerebrospinal fluid occurred [151]. Thus, covering the defect with a vascularized tissue seemed appropriate. Forehead flaps, glabella flaps, pericranial flaps, and galea flaps have all been advocated. Defects of the anterior cranial fossa can be covered by using a laterally positioned temporalis muscle flap. Myocutaneous flaps have also been used and provide a number of distinct advantages. They are well vascularized, provide additional bulk that aids in eliminating dead

space, and provide acceptable soft tissue contouring and aesthetic results. The pectoralis major flap is used to reach the orbital region, but it must be exteriorized to reach this site, thus adding a second operation. The latissimus dorsi muscle flap can access the orbit without a subsequent exteriorization procedure, but the patient must be repositioned for its harvest. A trapezius flap is also available, but its use must be carefully assessed in a previously irradiated patient or one in whom a radical neck dissection was performed. Again, this technique requires repositioning of the patient. In larger defects, free tissue transfer provides a well-vascularized, bulky tissue, without the restrictions of a pedicle. The most frequently used is the rectus abdominis free flap; simultaneous ablation of the tumor and flap harvest by two surgical teams reduces operative time and patient mortality. Region II defects essentially include the boundaries of the middle cranial fossa. It comprises the infratemporal and pterygomaxillary fossae and the overlying segment of the skull base. Tumors of this area include basal and squamous cell carcinoma of the external ear and scalp, invasive parotid tumors, and tumors of the middle ear. Access to the middle cranial vault is primarily through an infratemporal approach but may also be combined with a mandibulotomy, lateral mandibulotomy, anterior mandibulotomy with swing, or anterior displacement of the mandible. Also, via a hemicoronal incision, a transtemporal approach can provide access to the tumor. The location and the size of the defect dictate which reconstructive option is used. Historically, large scalp rotation flaps [152] and deltopectoral flaps have provided adequate restoration. Smaller defects can be repaired with temporalis muscle flaps. However, when larger defects may be inadequately treated with these local flaps—that is, when communications between the nasopharynx and dura persists—free flaps become the procedure of choice, specifically, the rectus abdominis free flap.

Region III includes the posterior segment of the middle cranial fossa, as well as the entire posterior section. The most common tumors encountered here are glomus tumors and schwannomas. Through a transtemporal approach, tumors are readily excised, and small defects can be closed with local flaps such as temporalis, deltoid, and sternocleidomastoid. Larger defects are more definitively reconstructed with latissimus dorsi flaps or the rectus abdominis free flap. Eye socket reconstruction requires not only a mucosal lining but also supportive tissue to mimic the tarsus. Traditionally, full- or split-thickness skin grafts without any supportive tissue failed owing to severe contracture formation. Millard [153] in 1962 used a composite nasal cartilage-mucosa graft. In 1985, Siegel [154] discussed the use of the palatal mucosa for reconstruction of the eyelid. The palatal mucosa is thick and rigid tissue that has been used for the reconstruction of the lip, gingiva, nasal vestibular lining, and tracheal wall defects. The "socket plasty" described by Yoshimura and coworkers [155] uses a palatal mucosa graft to maintain the dimensions of the socket to accept an orbital prosthesis. The palatal mucosa is sutured to deepen the fornix and keep the maximal dimensions of the graft for at least 10 to 14 days. An artificial eye or Silastic rubber ball is inserted to maintain the newly formed socket during the initial healing period. The donor site usually heals unremarkably, with little patient discomfort. Orbital floor defects have been treated with many materials, including autografts, allografts, xenografts, and alloplasts. The ideal material is fresh autogenous bone, but this requires a second surgical procedure. Harvested auricular cartilage provides an excellent source of autogenous tissue for repairing orbital floor defects. This fresh cartilage maintains adequate structure and volume many years after transplantation [156] In

fact, less resorption occurs if the perichondrium is left intact. Two approaches to auricular harvesting have been described: patients susceptible to keloid formation benefit from a posterior approach, and others undergo the anterior approach. The anterior approach involves a semicircular incision made through skin and perichondrium within the edge of the concha bowl to hide the scar. The skin-perichondrial flap is elevated anteriorly with blunt dissection to expose the graft conchal cartilage. Once the desired amount is excised with its associated perichondrium, the donor site can be closed with single-layer closure. The graft can then be sculpted to its desired shape, thus allowing it to be custom fitted. The posterior approach uses a posterior auricular incision to expose the posteromedial aspect of the concha. Using blunt dissection with a Freer elevator, the cartilage is accessed and excised from its native site. The auricular wound is closed in a similar fashion as that described for the anterior approach. Both techniques require a pressure dressing to prevent hematoma formation. This procedure is quick, is in the same location as the recipient site, and has minimal associated morbidity [157]. Shestak [158] described the reconstruction of combined midfacial and palatal defects with the use of a latissimus dorsi musculocutaneous free flap with separate skin paddles to reconstruct multiple tissue surfaces. After tumor excision, the recipient vessels of free flap are selected in the ipsilateral neck. The latissimus dorsi flap is harvested in a standard fashion, with the proximal end of the inscribed skin paddle designed at least 5 cm below the tip of the scapula to allow an ample length of the thoracodorsal artery and vein. The palatal inset is performed first using everting horizontal mattress sutures to obtain a watertight seal. An area of the skin is then de-epithelialized to accept remnants of facial skin and lip segments. The vascular pedicle is passed through a tunnel to the recipient vessels in the neck. Revascularization occurs by microvascular anastomosis. Because of the latissimus dorsi's accessibility, pedicle length, reliability of skin paddles, and ample available tissue, this flap is a viable treatment option for soft tissue reconstruction of complex craniofacial defects. Shestak reported 12 reconstructions using the same technique with satisfactory functional and aesthetic outcomes.

6. Implants in reconstruction

After extensive ablation of maxillofacial tumors, reconstruction of the head and neck region is attempted to restore the external cosmetic and functional deficits. However, masticatory function continues to be a problem in the rehabilitation of these patients. Without dental implants, the area of reconstruction does not allow placement of a dental prosthesis. Implants eliminate the requirement for adjacent natural soft tissue support for the prosthesis. Endosseous implants placed in bone grafts have been shown to stimulate bone growth and minimize its resorption. Therefore, when one reconstructive option is chosen over another, not only the quantity but also the quality of the bone that will ultimately receive endosseous implants should be a consideration [20]. Implants can be placed after a reconstruction has been performed or at the time of immediate reconstruction [159] Stoler and Hill [160] were the first to report a case in which oromandibular reconstruction was performed for a patient who had undergone ablative surgery for fibrous dysplasia using a combination of both free cranial and microvascular iliac crest grafts, as well as osseointegrated implants placed in vitro and then

grafted onto the reconstructed mandible. The advantages of immediate placement are the ease of access and ability to avoid any adjacent alloplastic materials, such as bone plates and screws. One possible problem associated with immediate placement is improper position of the implant. A delayed placement has the advantage of providing better control for placement in the correct position. However, disadvantages of the delayed technique are the necessity for a secondary surgical procedure, the need to deal with abnormal intraoral soft tissues, and the need to be aware of the position of the vascular pedicle as it relates to the reconstructed mandible [161]. Moscoso and associates [162] analyzed the effect of osseointegration in various donor sites for vascularized bone used for oromandibular reconstruction. The results of the study confirmed that the iliac crest is the most uniform implantable source of vascularized bone for the reception of osseointegrated implants. This was followed by scapula, fibula, and radius. They also pointed out some gender differences. Male fibulas were statistically equivalent to the iliac crest in terms of implantability. In females, however, only one third of proximal scapulas and 50% of proximal to midfibulas would allow implant placement. The long-term stability of a successfully osseointegrated implant is dependent on implant dimension, the structural integrity of the bone to withstand functional loading, and allowances for loss of marginal bone height [163]. In cases in which the iliac crest is not accessible owing to previous bone grafting attempts or disruption of vascular anatomy from previous groin vascular surgery, or when the excessive tissue bulk associated with the osteomyocutaneous iliac flap is not desired, an alternative is to use osseointegrated implants in free vascularized radial bone grafts. The radial bone graft provides the ideal mucosal replacement tissue from the associated forearm skin paddle. Radial bone was previously reported as being too thin to accept implants. Mounsey and Boyd [164] reported their experiences using implants placed in vascularized radial bone flaps.

They showed that for small, straight, bony defects, the radius is a good alternative. In larger defects, the contoured iliac crest is a better option. However, the radial bone may be osteotomized to attempt to create the desired mandibular contour. They reported excellent results following implant placement in small- to moderate-size lateral defects, as well as small anterior or anterolateral defects. Further reports using radial bone and dental implants were made by Martin and colleagues [165], with similar success. They do not advocate one-stage reconstruction and primary implant placement because of the possibility of jeopardizing its periosteal blood supply. The microvascular free fibular transfer is an excellent option for reconstruction of large mandibular defects. Its bicortical nature mimics that of the native mandible and seems to be ideal for inserting implants as primary stabilization is achieved [166]. However, dental restoration with traditional removable oral appliances has failed owing to diminished denture-bearing regions as tongue dysfunction. Zlotolow and associates [167] studied the use of the fibular free flap with osseointegrated implants. They reported seven successful cases and concluded that with microvascular bony reconstruction with osseointegrated implants, the quality of life is greatly enhanced by bringing the patient closer to the predisease state.

In 1994, Donovan and coworkers [168] described a new technique combining calvarial onlay bone grafts with osseointegrated implants—more specifically, the Branemark system. The use of such membranous grafts stemmed from previous reports stating that less resorption is seen

with membranous bone grafts, compared with endochondral onlay grafts [169]. After harvesting the outer cortical table of calvarial-parietal bone in strips, two grafting techniques are used. The vertical technique is used primarily in the atrophic maxilla, and the graft is secured to the lateral aspect of the remaining maxillary bone or alveolar processes with a rigid screw system. This is followed by a period of healing, approximately 6 to 8 months, before definitive placement of dental implants. They reported an 86% success rate with this onlay procedure, attributing possible failures to varying degrees of soft tissue ingrowth, as well as the cortical strip of bone being further away from its source of blood supply. The horizontal technique, which enjoyed a 98% success rate, places the calvarial bony strips in a horizontal fashion in the anterior maxillary region, where the nasal spine is separated from its most inferior bony attachment. The cortical struts are then placed in a horizontal fashion superiorly at the level of the nasal floor as well as inferiorly, augmenting the height of the maxillary ridge. The "sandwiched" maxilla is then stabilized with its grafts with the placement of osseointegrated implants from one canine eminence to the other. These implants, in contrast to those used in the vertical technique, have bicortical stabilization and are placed close together to aid in stress load distribution. These success rates are comparable to those seen when reconstructing the anterior mandible. All patients were restored with implant-supported prostheses, resulting in good function, a stable prosthesis, lack of donor site morbidity, early ambulation, and a short hospital stay.

6.1. Maxillofacial prosthodontics

The demand for maxillofacial prosthodontic devices for the rehabilitation of patients with postsurgical defects has intensified in recent years. The extensive surgical procedures necessary to eradicate cancer of the head and neck often leave extremely large physical defects that may not be amenable to surgical reconstruction. The prosthodontist can provide surgical stents, radiation carriers and shields, intraoral cone stents, palatal augmentation prostheses for glossectomy patients, and immediate transitional and definitive prostheses, as well as extraoral prostheses to replace ears, nose, and facial defects. Thus, the maxillofacial prosthodontist must have knowledge of the disease, etiology, diagnosis, treatment, and rehabilitation in order to be a member of the team that is responsible for enhancing the patient's quality of life [170]. Prosthetic and prosthodontic appliances are required for realignment and fixation of mandibular fragments in adequate dental occlusal relationships with the teeth of the opposing jaw; as obturators for the occlusion of defects of the palatal region; for the maintenance of facial form and contour so as to prevent contracture of the tissues during the healing period; as a temporary or transitional modality before or during surgical treatment; and for the restoration of facial features, such as the nose, auricle, or orbital region [171]. The maxillary defects that result from ablative cancer surgery vary in complexity, but prosthetic rehabilitation may provide a functional and aesthetic result. The purpose of the obturator prosthesis is to re-establish the normal contour of the oral cavity to allow normal speech and swallowing. The size of the defect determines the size of the obturator, or bulb portion that closes the surgical defect. The loss of this supporting tissue can be offset by gaining retention from the peripheral tissues. The maturity of the defect also determines how the obturator is tolerated. The more mature the defect, the more readily it is tolerated. A skin graft can provide a firm

tissue base that resists abrasion and reduces mucus secretion, minimizing poor hygienic environments. The opposing mandibular ridge is important to the stability of the obturator. Prosthetic rehabilitation of the maxillectomy patient is performed in three phases. Stage one starts with the placement of the surgical packing and surgical obturator, which is retained for 5 to 7 days by screw or wire fixation. This helps re-establish oral contours and allows the patient to start a liquid diet almost immediately postoperatively, bypassing the need for nasogastric feeding. In the second stage, the surgical obturator is removed and modified with a tissue conditioner. As the obturator is modified, the patient learns how to swallow less forcefully, and leakage around the prosthesis decreases. The third stage can be anywhere from 3 months to over a year after maxillectomy, when the definitive obturator prosthesis is fabricated [172]. In maxillectomy patients, osseointegrated implants may be placed in the residual alveolar ridge or horizontal palate. An edentulous maxillectomy defect has the poorest prognosis for accepting an obturator. It is impossible to achieve retention of a complete maxillary denture. Thus, endosseous implants may aid in retention, stability, and support of the obturator prosthesis; a bar and clip, magnet, and ball-0-ring gasket-type keeper are widely used in these situations. The bar and clip assembly provides the obturator prosthesis with improved stability and retention. For patients with significant extraoral tissue loss, the facial prosthesis also has limitations related to retention and stability. The extraoral application of implants has been a significant advance in maxillofacial prosthetics (Figure 32).

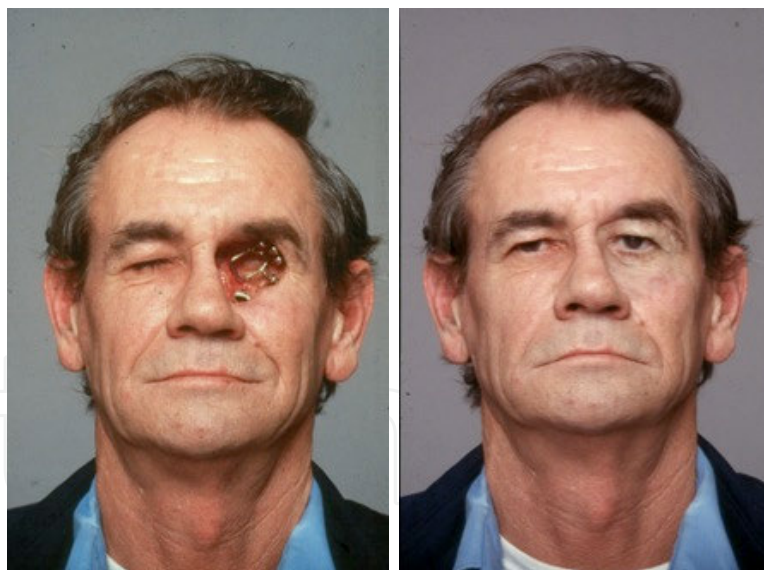

Figure 32. Orbit prosthesis

For example, implants placed in the mastoid bone or the temporal bone can be used for orbital prosthesis. A nasal prosthesis can use a similar retention technique. A nasal prosthesis can use a similar retention technique and have its fixtures placed in the floor of the nose. And in situations in which Amorbation included the orbit, implants can be placed in the supraorbital rim region [173]. As with intraoral dental implants, extraoral sites require proper hygiene practices to ensure tissue health.

Pediatric Reconstruction

Mandibular reconstruction and rehabilitation in a 7-year-old with osteosarcoma reported by Richardson and Cawood [174]. They made every effort to maintain the bone matrix so as not to disturb the normal growth processes of the face. After tumor resection and partial mandibulectomy, immediate reconstruction with a titanium mesh tr

7. Pediatric reconstruction

Mandibular reconstruction and rehabilitation in a 7-year-old with osteosarcoma were recently reported by Richardson and Cawood [174]. They made every effort to maintain the functional matrix so as not to disturb the normal growth processes of the face. After tumor ablation with a partial mandibulectomy, immediate reconstruction with a titanium mesh tray was performed without bone graft. This technique allowed the tray to function as a space maintainer. When the patient approached the onset of puberty, the tray was removed and a composite circumflex iliac crest free flap was used to restore the continuity and soft tissue deficiencies. Microvascular anastomosis of the donor and recipient sites was used. Two years later, osseointegrated implants were placed, with a subsequent vestibuloplasty with a split-thickness skin graft. They concluded that the multidisciplinary approach to the care of this patient, along with the introduction of revascularized free tissue transfer with osseointegrated implants, revolutionized the reconstruction of pediatric orofacial defects following extensive tissue losses.

8. Postoperative evaluation

The postoperative care and management of complications require an understanding of osseous wound healing and the potential causes of failure. Loss of skeletal stability as a result of loss of fixation allows for motion at the wound interface, with secondary impairment of vascularization. Early recognition of flap compromise is associated with improved chances of flap salvage. The ideal flap monitoring technique should be reliable, reproducible, easily interpretable, inexpensive, noninvasive, rapidly responsive to changes in microcirculation, and able to provide continuous monitoring in the immediate postreconstructive period. The clinical examination should focus on capillary refill time (>3 seconds is the cutoff), which provides information on the adequacy of the arterial supply. Early venous outflow obstruction results in capillary refill that is too brisk. The color of a flap can also provide information about arterial insufficiency. A pale flap signifies poor flap perfusion, whereas one with outflow obstruction is congested and hyperemic. Skin temperature can assess the adequacy of circulation in digits but is of little use when applied to flaps for reconstruction, as changes in ambient temperature affect the measured surface temperature readings. The most invasive monitoring method is blood flow from the flap. Flow of oxygenated blood, from a needle puncture, indicates good perfusion, whereas dark red blood or sluggish flow is a prognostic indicator.

Buried flaps, or flaps used for pharyngoesophageal reconstruction, require some other form of monitoring technique, because direct visualization is not possible. Flexible fiberoptic telescopes have been used, but this method cannot be performed on a continual basis. To visualize a segment of jejunum used for pharyngeal reconstruction, a sheet of silicone rubber (Silastic) is placed over the segment of jejunum and the skin is left open to provide a "window" to allow a direct view of the jejunum. A flap can be designed with a segment externalized so that the surgeon can readily visualize it. The cutaneous part can often be partially externalized and incorporated in the wound closure to serve as an indicator of graft survival; this also

decreases wound tension. Tissue that is unnecessary for reconstruction and is supplied by the vascular pedicle can be externalized and observed for impairment of blood supply.

There are a number of adjunctive monitoring devices that can be used to assess the adequacy of tissue perfusion. An electromagnetic flowmeter determines the absolute blood flow in a vessel by electromagnetic induction and allows immediate and continuous readings to see slow or rapid changes. The ultrasonic Doppler flowmeter has been in clinical use for more than 30 years and is useful if one is certain that the flow signal heard is from the vascular pedicle. Arterial thermometry is a system that measures temperature difference across a vascular anastomosis with implanted thermocouple probes. Fluorescein has been used to identify flaps with inadequate perfusion; when injected intravenously, it diffuses out to the capillaries into the interstitial fluid. The staining can then be visualized under ultraviolet illumination. The more intense the staining, the better the perfusion, and vice versa. The dermofluorometer enables the clinician to quantify minute degrees of fluorescence and uses smaller doses of the drug to prevent allergic reactions. Radioisotope washout of xenon 133, sodium pertechnetate Tc99m, iodine 131, and sodium 24 has been used to indicate the adequacy of perfusion; after administration of an isotope, clearance from the flap is monitored and correlated with flap perfusion (i.e., greater clearance equals greater flap perfusion). Pulse oximetry can detect pulsatile blood flow until the artery is 95% occluded. Laser-Doppler velocimetry is currently the best tool for objective monitoring of flaps. It must be in place when the flap is known to have good perfusion, because changes in this initial value are the important parameter. The laser-Doppler velocimeter can provide an accurate, easily interpretable readout of tissue perfusion that is rapidly responsive to changes in perfusion. Duplex Doppler ultrasonography is capable of identifying and characterizing blood flow from small, superficially located vessels, similar to those involved with microvascular surgery. Different shades of gray are assigned to stationary areas, whereas color is assigned to areas of motion such as blood flowing within a vessel. Vessels as small as 1 mm in diameter can be identified. Transcutaneous oxygen monitoring is also an option, where PO_2 is measured directly to assess the state of microcirculation. Finally, changes in interstitial fluid hydrostatic pressures can reflect changes in blood flow [175]. Radiologic literature on bone graft evaluation is sparse. Follow-up assessment of skeletal reconstruction with plain radiographs and cephalometric studies in the immediate postoperative period is needed to document the position of bone segments and the location of hardware. However, data on the evaluation of primary bone tumors and bone allografts stress the role of plain film radiography. In 1992, Soderholm and colleague [176] studied the effectiveness of using plain film radiography in the follow-up and prognosis of non-vascular bone grafting used in mandibular reconstruction. They concluded that narrow-beam radiography and spiral tomography are excellent tools for the evaluation of bone resorption and bony healing of mandibular grafts. Panoramic radiographs are able to visualize the whole mandibular bone and are used for a general assessment; tomography is used for specified, selected diagnostic tasks, such as to visualize bone resorption within the graft and under the plate. After reconstruction of large defects in the oral cavity or the oropharynx with myocutaneous or free microvascular flaps, physical rehabilitation by a therapist trained in speech and swallowing is of paramount importance, as these reconstructive procedures cannot fully restore the patient's ability to masticate, swallow, or speak. The major aims of physical therapy

are to decrease the amount of facial deformity and to limit the loss of oral opening. Oral opening exercises are initiated as soon as the patient can tolerate them. Stretching exercises three to four times a day are adequate home regimens. A specialized therapist may use the Therabite mouth opener (Therabite Co., Bryn Mawr, PA) to improve maximal opening. Also, those patients who have had neck dissections require physical therapy for shoulder pain and trapezius weakness. Range-of-motion exercises are necessary to prevent frozen shoulder and worsening pain.

Author details

Ata Garajei^{1,2,3*}, Ali Arabkheradmand², Mohammad Hosein Kalantar Motamed^{4,5}, Alex E. Pazoki⁶ and Ashkan Rashad⁷

*Address all correspondence to: atagarajei@tums.ac.ir

1 Department of Oral and Maxillofacial Surgery, School of Dentistry, The Cancer Institute, Tehran

2 Department of Head and Neck Surgical Oncology and Reconstructive Surgery, The Cancer Institute, Tehran, Iran

3 Craniomaxillofacial Research Center, Tehran University of Medical Sciences, Tehran, Iran

4 Trauma Research Center, Baqiyatallah University of Medical Sciences, Tehran, Iran

5 Department of Oral and Maxillofacial Surgery, Azad University of Medical Sciences, Dental College, Tehran, Iran

6 Department of Oral and Maxillofacial Surgery, Johns Hopkins University, Baltimore, USA

7 Department of Oral and Maxillofacial Surgery, Bremerhaven Hospital (Reinkenheide); Bremerhaven, Germany

References

- [1] Marx RE, Schiff WM, and Saunders TR: Reconstruction and rehabilitation of cancer patients. In Fonseca RJ, Davis WH (eds): Reconstructive Preprosthetic Oral and Maxillofacial Surgery, ed 2. Philadelphia, WB Saunders, 1995, p 1057.
- [2] Ferraro NF, August M: Reconstruction following resection for maxillofacial tumors. Oral Maxillo fac Surg Clin North Am 1993;5:355.

- [3] Markowitz BL, Calcaterra TC: Preoperative assessment and surgical planning for patients undergoing immediate composite reconstruction of oromandibular defects. *Clin Plast Surg* 1994; 21:9.
- [4] Martin PJ, O'Leary MJ, Hayden RE: Free tissue transfer in oromandibular reconstruction: Necessity or extravagance? *Otolaryngol Clin North Am* 1994; 27:1141.
- [5] Lowlicht RA, Delacure MD, and Sasaki CT: Allogeneic (homograft) reconstruction of the mandible. *Laryngoscope* 1990; 100:837.
- [6] Lawson W, Biller H: Reconstruction of the Mandible. In McCarthy JG (ed): *Plastic Surgery*, Ed 2. Philadelphia, WB Saunders, 1990, p 2069.
- [7] Markowitz B, Taleisnik A, and Calcaterra T, et al: Achieving mandibular continuity with vascular bone flaps. *J Oral Maxillofac Surg* 1994; 52:114.
- [8] Kroll SS, Schusterman MA, and Reece GP: Costs and complications in mandibular reconstruction. *Ann Plast Surg* 1992; 29:341.
- [9] Heller KS, Dubner S, Keller A: Long-term evaluation of patients undergoing immediate mandibular reconstruction. *Am J Surg* 1995; 170:517.
- [10] Shockley WW, Weissler MC: Reconstructive alternatives following segmental mandibulectomy. *Am J Otolaryngol* 1992; 13:156.
- [11] Cordeiro PG, Hidalgo DA: Conceptual considerations in mandibular reconstruction. *Clin Plast Surg* 1995; 22:61.
- [12] Kuriloff DB, Sullivan MJ: Mandibular reconstruction using vascularized bone grafts. *Otolaryngol Clin North Am* 1991; 24:1391.
- [13] Urken ML, Moscoso JF: Sensate cutaneous flaps in oral cavity and pharyngeal reconstruction. *Oper Tech Otolaryngol Head Neck Surg* 1993; 4:141-144.
- [14] Strauss MB: Chronic refractory osteomyelitis: Review the role of hyperbaric oxygen. *Hyperbaric Oxygen Review* 1980; 1:231.
- [15] Hyperbaric Oxygen Therapy: A Committee Report: Mechanisms of Action. Bethesda, MD, Undersea Medical Society, 1986, pp 5-9.
- [16] Hunt K, Pai MP: The effect of varying ambient oxygen tensions on wound metabolism. and collagen synthesis. *Surg Gynecol Obstet* 1972; 12:77.
- [17] Nemiroff PM, Lungu AP: The influence of hyperbaric oxygen and irradiation on vascularity in skin flaps: A controlled study. *Surg Forum* 1987; 37:565.
- [18] Nilsson LP, Albrektsson T, Granstrom G, et al: The effect of hyperbaric oxygen treatment on bone regeneration: An experimental study in the rabbit using the bone harvest chamber (BHC). *J Oral Maxillofac Implants* 1988; 3:43.

- [19] Granstrom G, Nilsson LP, Magnusson BC, et al: Experimental mandibular practice: Effect on bone healing after treatment with hyperbaric oxygen. Proceedings of the 25th EUBS Scientific Meeting, Eilat, Israel, 1989, pp 290-297.
- [20] Marx RE, Johnson RP, Kline SN: Prevention of osteoradionecrosis: A randomized prospective clinical trial of hyperbaric oxygen versus penicillin. *J Am Dent Assoc* 1985; 14:49.
- [21] Mathiew D, Coget J, Vinckier F, et al: Red blood cell deformability and hyperbaric oxygen therapy. *Med Subaquat Hyperbar* 1984; 3:100.
- [22] Granstrom G: The use of hyperbaric oxygen to prevent implant loss in the irradiated patient. In Worthington P, Branemark PI (eds): *Advanced Osseointegration Surgery*. Chicago, Quintessence, 1989, p 336.
- [23] Propper RH: Simplified ridge extension using free mucosal grafts. *J Oral Surg* 1964;22:469-474.
- [24] Marx RE: Philosophy and particulars of autogenous bone grafting. *Oral Maxillofac Clin North Am* 1993;5:599.
- [25] Shirota T, Ohno K, Motohashi M, et al: Histologic and microradiologic comparison of block and particulate cancellous bone and marrow grafts in reconstructed mandibles being considered for dental implant placement. *J Oral Maxillofac Surg* 1996; 54:15.
- [26] Harsha BC, Turvey TA, Powers SK: Use of autogenous cranial bone grafts in the maxillofacial surgery: A preliminary report. *J Oral Maxillofac Surg* 1986; 44:11.
- [27] Kudo K, Shoji M, Yokota M, et al: Evaluation of mandibular reconstruction techniques following resection of malignant tumors in the oral region. *J Oral Maxillofac Surg* 1992; 50:14.
- [28] Branemark PI, Lindstrom J, Hallen O, et al: Reconstruction of the defective mandible. *Scand J Plast Surg* 1975; 9:116.
- [29] Li KK, Cheney ML, and Teknos TN: The importance of mandibular position in microvascular mandibular reconstruction. *Laryngoscope* 1996; 106:903.
- [30] Ardary WC: Reconstruction of mandibular discontinuity defects using autogenous grafting and a mandibular reconstruction plate: A prospective evaluation of nine consecutive cases. *J Oral Maxillofac Surg* 1993; 51:125.
- [31] Boyne PJ: Autogenous cancellous bone and marrow transplants. *Clin Orthop* 1992; 73:253.
- [32] Gheung LK, Samman N, Tong ACK, et al: Mandibular reconstruction with the Dacron urethane tray: A radiologic assessment of bone remodeling. *J Oral Maxillofac Surg* 1994; 52:373.

- [33] Jisander S, Aspenberg P, Salemark L, et al: Mandibular reconstruction by secondary reimplantation of resected segments: A preliminary report. *Int J Oral Maxillofac Surg* 1995; 24:288.
- [34] Tayapongsak P, O'Brien DA, Monteiro CB, et al: Autologous fibrin adhesive in mandibular reconstruction with particulate cancellous bone and marrow. *J Oral Maxillofac Surg* 1994; 52:161.
- [35] Perrott DH, Smith RA, and Kahan LB: The use of fresh frozen allogeneic bone for maxillary and mandibular reconstruction. *Int J Oral Maxillofac Surg* 1992; 21:260.
- [36] Dong Y, Zhang G, Wang S, et al: The use of immediate frozen autogenous mandible, for benign tumor mandibular reconstruction. *Br J Oral Maxillofac Surg* 1996;34:58.
- [37] Tayapongsak P, Pijut J, and Scheffer RB: Inferior border titanium cribs in mandibular reconstruction. *Oral Surg Oral Med Oral Pathol* 1995; 79:30.
- [38] Bakamjian VY, Calame PM: Oropharyngeoesophageal reconstructive surgery. In Converse JM (ed): *Reconstructive Plastic Surgery*, vol 5, Ed 2. Philadelphia, WB Saunders, 1977, p 2700.
- [39] Kheradmand AA, Garajei A: Ventral tongue myomucosal flap: a suitable choice for shaved lower vermilion border reconstruction. *Journal of Craniofacial Surgery* 2013; 24 (2), e114-e116.
- [40] Tashiro H, Sasaguri M, Ozeki S, et al: Mandibular reconstruction using hydroxyapatite granules, autogenous bone, and a cervical island skin flap. *J Oral Maxillofac Surg* 1993; 51:1327.
- [41] Farr HW, Jean-Gilles B, Die A: Cervical island skin flap repair of oral and pharyngeal defects in the composite operation for cancer. *Am J Surg* 1969; 118:759.
- [42] Ariyan S: The pectoralis major myocutaneous flap: A versatile flap for reconstruction in the head and neck. *Plast Reconstr Surg* 1979; 63:73.
- [43] Owen N: Compound neck pedicle designed for repair of massive facial defects. *Plast Reconstr Surg* 1955; 15:369.
- [44] Carlson ER: Regional flaps in maxillofacial reconstruction. *Oral Maxillofac Clin North Am* 1993; 5:667.
- [45] Huttenbrink K: Temporalis muscle flap: An alternative in oropharyngeal reconstruction. *Laryngoscope* 1986; 96:1034.
- [46] Cheung LK: An animal model of maxillary reconstruction using a temporalis muscle flap. *J Oral Maxillofac Surg* 1996; 54:1439.
- [47] Upton J, Ferraro N, Healy G, et al: The use of prefabricated facial flaps for lining the oral and nasal cavities. *Plast Reconstr Surg* 1994; 94(5): 573.

- [48] Roopenian A, Kazanjian V: Median forehead flaps in the repair of defects of the nose and surrounding areas. *Tr Am Acad Oahth and Oto* 1956; 60:557.
- [49] Shumrick KA, Smith TL: The anatomic basis for the design of forehead flaps. *Arch Otolaryngol Head Neck Surg* 1992; 118:373.
- [50] Burget GC, Menick FJ: *Aesthetic Reconstruction of the Nose*. St. Louis, Mosby, 1994, p 123
- [51] Millard, DR: Reconstructive rhinoplasty for the lower half of a nose. *Plast. Reconstr. Surg* 1974; 53:133.
- [52] Kheradmand AA, Garajei A, Motamedi MH: Nasal reconstruction: Experience using tissue expansion and forehead flap. *J Oral Maxillofac Surg* 69:1478-1484, 2011
- [53] Panje WR, Morris MR: The temporoparietal fascia flap in head and neck reconstruction. *Ear Nose Throat J* 70:311-317,1991
- [54] Ladrach K, Raveh J, Lizuka T: Reconstruction of the midface and fronto-orbital region following tumor resection and trauma, in Maniglia AJ, Stucker FJ, Stepnick DW (eds): *Surgical Reconstruction of the Face and Anterior Skull Base*. Philadelphia, PA, Saunders, 1999, pp 113-140
- [55] Conley J: Use of composite flaps containing bone for major repairs on the head and neck. *Plast Reconstr Surg* 49:522-527, 1972
- [56] Esclamado RM, Burkey BB, Carroll WR, et al: The platysma myocutaneous flap: Indications and caveats. *Arch Otolaryngol Head Neck Surg* 1994; 120:32.
- [57] Bakamjian VY: A two-stage method for pharyngoesophageal reconstruction with a primary pectoral skin flap. *Plast Reconstr Surg* 1965; 36:173.
- [58] Murphy JB, Weisman RA, and Kent K: The use of stabilization plates in the immediate repair of defects following mandibular resection. *Oral Surg Oral Med Oral Pathol* 1989; 68:380.
- [59] Marx RE, Smith BR: An improved technique for development of the pectoralis major myocutaneous flap. *J Oral Maxillofac Surg* 1990; 48:1168.
- [60] Kingdom TT, Singer MI: Enhanced reliability and renewed applications of the deltopectoral flap in head and neck reconstruction. *Laryngoscope* 1996; 106:1230.
- [61] Ijsselstein CB, Hovius SER, ten Have BLEF, et al: Is the pectoralis myocutaneous flap in intraoral and oropharyngeal reconstruction outdated? *Am J Surg* 1996; 172:259.
- [62] Lehtimaki K, Pukander J: Primary mandibular reconstruction after ablative cancer surgery. *Acta Otolaryngol Suppl* 1992; 492:160.
- [63] Ord RA: The pectoralis major myocutaneous flap in oral and maxillofacial reconstruction: A retrospective analysis of 50 cases. *J Oral Maxillofac Surg* 1996; 54:1292.

- [64] Haers PE, Gratz KW, Sailer HF: The bilobed myocutaneous pectoralis major flap in closure of combined intra- and extraoral defects. *Int J Oral Maxillofac Surg* 1994; 23:214.
- [65] Baadsgaard K, Medgysi S: Muscle pedicle bone grafts. *Acta Orthop Scand* 1965; 35:279.
- [66] Panje W: Mandible reconstruction with the trapezius osteomusculocutaneous flap. *Arch Otolaryngol* 1985; 111:223-229.
- [67] Kimura Y, Nakamura T, Tojima H, et al: Trapezius osteomyocutaneous flap in reconstructive surgery for mandibular and oral defects. *Acta Otolaryngol Suppl* 1994; 511:179.
- [68] Conley J, Gullane PJ: The sternocleidomastoid muscle flap. *Head Neck Surg* 1980; 2:30F.
- [69] Siemsen SO, Kirkby B, and O'Connor TP: Immediate reconstruction of a resected segment of the lower jaw, using a compound flap of clavicle and sternocleidomastoid muscles. *Plast Reconstr Surg* 1978; 61:724.
- [70] Barnes DR, Ossof RH, Pecano B, et al: Immediate reconstruction of mandibular defects with composite sternocleidomastoid musculoclavicular graft. *Arch Otolaryngol* 1981;107:711.
- [71] Friedman M, Mayer AD: Laryngotracheal reconstruction in adults with the sternocleidomastoid myoperiosteal flap. *Ann Otol Rhinol Laryngol* 1992; 101:897.
- [72] Cuono CB, Aryan S: Immediate reconstruction of a composite mandibular defect with a regional osteomusculocutaneous flap. *Plast Reconstr Surg* 1980; 65(4): 4 77.
- [73] Gratz KW, Siler HF, Haers PE, et al: Mandibular reconstruction with full thickness calvarial bone and temporal muscle flap. *Br J Oral Maxillofac Surg* 1996; 34:379.
- [74] Conley JE: Cancer of the head and neck. New York, Appleton-Century-Crofts, 1967, p 274.
- [75] McCarthy JG: Side bar. The spectrum for calvarial bone grafting: Introduction of the vascularized calvarial flap. *Plast Reconstr Surg* 1984;74(1):10.
- [76] Choung PH, Nam IW, Kim KS: Vascularized cranial bone grafts for mandibular and maxillary reconstruction: The parietal osteofascial flap. *J Craniomaxillofac Surg* 1991;19(6):325.
- [77] Moscoso JF, Urken ML: Radial forearm flaps. *Otolaryngol Clin North Am* 1994; 27:1119-1140.
- [78] Soutar DS, Scheker LR, Tanner NS, et al: The radial forearm flap: A versatile method for in traoral reconstruction. *Br J Plast Surg* 1983; 36(1): 1.

- [79] Urken ML, Weinberg H, Vickery C, et al: The neurofasciocutaneous radial forearm flap in head and neck reconstruction: A preliminary report. *Laryngoscope* 1990; 100(2): 161.
- [80] Vaughan ED: The radial forearm free flap in orofacial reconstruction. *J Craniomaxillofac Surg* 1990; 18:2.
- [81] Gaukroger MC, Langdon JD, Whear NM, et al: Repair of the radial forearm flap donor site with a full-thickness graft. *Int J Oral Maxillofac Surg* 1994; 23:205-208.
- [82] Teichgraeber J, Bowman J, and Geopfert H: New test series for the functional evaluation of oral cavity cancer. *Head Neck Surg* 1985; 8:9.
- [83] Urken ML, Biller HF: A new bilobed design for the sensate radial forearm flap to preserve tongue mobility following significant glossectomy. *Arch Otolaryngol Head Neck Surg* 1994; 120:26.
- [84] Nakatsuka T, Harii K, Yamada A, et al: Dual free flap transfer using forearm flap for mandibular reconstruction. *Head Neck* 1992; 14:452.
- [85] Sadove RC, Luce EA, and McGrath PC: Reconstruction of the lower lip and chin with composite radial forearm-palmaris longus free flap. *Plast Reconstr Surg* 1991; 88:209.
- [86] Fenton OM, Roberts JO: Improving the donor site of the radial forearm flap. *Br J Plast Surg* 1985; 38:504.
- [87] Baek SM: Two new cutaneous free flaps: The medial and lateral thigh flaps. *Plast Reconstr Surg* 1983; 71:354.
- [88] Hayden RE: Lateral thigh flap. *Otolaryngol Clin North Am* 1994; 27:1171.
- [89] Schliephake H, Schmelzeisen R, Neukam FW: The free revascularized rectus abdominis myocutaneous flap for the repair of tumor related defects in the head and neck area. *Br J Oral Maxillofac Surg* 1996; 34:18.
- [90] Schusterman MA, Kroll SS: Reconstruction strategy for temporal bone and lateral facial defects. *Ann Plast Surg* 1991; 26:233.
- [91] Kroll SS, Baldwin BJ: Head and neck reconstruction with the rectus abdominis free flap. *Clin Plast Surg* 1994; 1:97.
- [92] Kroll SS, Reece GP: Reconstruction of the face for cancer therapy. *Adv Plast Surg* 1993; 9:127.
- [93] Arons JA, Guyuron B: Use of rectus abdominis osteomyocutaneous double island flap based on internal mammary vessels. *Br J Oral Maxillofac Surg* 1995; 48:145.
- [94] Moscoso JF, Urken ML: The iliac crest composite flap for oromandibular reconstruction. *Otolaryngol Clin North Am* 1994; 27:1097.

- [95] Shenaq SM, Klebuc MJA: The iliac crest microsurgical free flap in mandibular reconstruction. *Clin Plast Surg* 1994; 21:37.
- [96] Reyhler H, Ortabe JI: Mandibular reconstruction with the free fibula osteocutaneous flap. *Int J Oral Maxillofac Surg* 1994; 23:209.
- [97] Lee JH, Kim MJ, Kim JW: Mandibular reconstruction with free vascularized fibular flap. *J Craniomaxillofac Surg* 1995; 23:20.
- [98] Carroll WR, Esclamado R: Preoperative vascular imaging for fibular osteocutaneous flap. *Arch Otolaryngol Head Neck Surg* 1996; 122:708.
- [99] Hidalgo DA: Fibula free flap mandibular reconstruction. *Clin Plast Surg* 1994; 21:25.
- [100] Wells MD: Part I. Mandibular reconstruction using vascularized bone grafts. *J Oral Maxillofac Surg* 1996;54(7):883.
- [101] O'Leary MJ, Martin PJ, Hayden RE: The neurocutaneous free fibula flap in mandibular reconstruction. *Otolaryngol Clin North Am* 1994; 27:1081.
- [102] Jones NF, Monstrey S, Gambier BA: Reliability of the fibular osteocutaneous flap for mandibular reconstruction. Anatomical and surgical confirmation. *Plast Reconstr Surg* 1996;97:707.
- [103] Saijo M: The vascular territories of the dorsal trunk: A reappraisal for potential flap donor sites. *Br J Plast Surg* 1978;31(3):200.
- [104] Ostrup LT, Fredrichson JM: Distant transfer of a free, living bone graft by microvascular anastomoses. An experimental study. *Plast Reconstr Surg* 1974;54(3):274.
- [105] McKee D: Microvascular bone transplantation. *Clin Plast Surg North Am* 1978;5:283.
- [106] Genden E, Haughey BH: Mandibular reconstruction by vascularized free tissue transfer. *Am J Otolaryngol* 1996;17:219.
- [107] Turk JB, Vuillemin T: Revascularized bone grafts for craniofacial reconstruction. *Otolaryngol Clin North Am* 1994;27:955.
- [108] Carrel A: The surgery of blood vessels. *Johns Hopkins Hosp Bull* 1907;19:15.
- [109] Jacobson JH II, Suarez EL: Microsurgery in anastomosis of small vessels. *Surg Forum* 1960; 11:247.
- [110] Haughey BH: The jejuna! free flap in oral cavity and pharyngeal reconstruction. *Otolaryngol Clin North Am* 1994;27:1159.
- [111] Yamamoto Y, Kunihiro N, Yoshihisa S, et al: Mes Enteric flap in free jejuna! transfers: A versatile technique for head and neck reconstruction. *Head Neck* 1995;17:213.
- [112] Hayden RE: Free flap transfer for restoration of sensation and lubrication to the reconstructed oral cavity and pharynx. *Otolaryngol Clin North Am* 1994; 27:1185.

- [113] David D: Use of an innervated deltopectoral flap for intraoral reconstruction. *Plast Reconstr Surg* 1977; 60:377.
- [114] Franklin J, Withers E, Madden J, et al: Use of the free dorsalis pedis flap in head and neck repairs. *Plast Reconstr Surg* 1979; 63:195.
- [115] Hermanson A, Dalsgaard C, Arnander D, et al: Sensibility and cutaneous reinnervation in free flaps. *Plast Reconstr Surg* 1987; 79:422.
- [116] Hayden RE: Sensate flaps for oral and pharyngeal reconstruction: The next frontier. COSM, Triologic Society, Palm Beach, FL, 1990.
- [117] Urken ML, Weinberg H, Vickery C, et al: The combined sensate radical forearm and iliac crest flaps for reconstruction of significant glossectomy-mandibulectomy defects. *Laryngoscope* 1992; 102(5): 543.
- [118] Urken ML, Weinberg H, Vickery C, et al: Oromandibular reconstruction using microvascular composite free flaps: Report of 71 cases and a new classification scheme for bony, soft tissue and neurologic defects. *Arch Otolaryngol Head Neck Surg* 1991; 117:733.
- [119] Hayden RE, O'Leary M: Osseointegrated neuroasciocutaneous fibula flap for complete oromandibular reconstruction. COSM, American Academy of Facial Plastic and Reconstructive Surgery, Waikoloa, HI, 1991.
- [120] Papachristou DN, Trichilis E, Fortner JG: Experimental use of free gastric flaps for repair of pharyngoesophageal defects. *Plast Reconstr Surg* 1979; 64:336.
- [121] Mah SM, Durham JS, Anderson DW, et al: Functional results in oral cavity reconstruction using reinnervated versus nonreinnervated free fasciocutaneous grafts. *J Otolaryngol* 1996; 25:75.
- [122] Wells MD, Luce EA, Edwards AL, et al: Sequentially linked free flaps in head and neck reconstruction. *Clin Plast Surg* 1994; 21:59.
- [123] Camilleri I, Wilson GR, McLean NR: Mandibular reconstruction using a "parasitic" flap. *Br J Oral Maxillofac Surg* 1994; 32:373.
- [124] Penfold CN, Davies HT, Cole RP, et al: Combined latissimus dorsi-serratus anterior/rib composite free flap in mandibular reconstruction. *Int J Oral Maxillofac Surg* 1992; 21:92.
- [125] Yamamoto Y, Nohira K, Yamashita T, et al: Combined V figure-shaped scapular osteocutaneous and latissimus dorsi myocutaneous flap for composite mandibular reconstruction. *Head Neck* 1995; 17:219.
- [126] Macewen W: *The Growth of Bone*. Glasgow, J Mackhose, 1912.
- [127] Blocker TG, Stout RA: Mandibular reconstruction in World War II. *Plast Reconstr Surg* 1949;4:153.

- [128] Conley J: Use of composite flaps containing bone for major repairs in the head and neck. *Plast Reconstr Surg* 1972;49:522.
- [129] Snyder C: Mandibulofacial restoration with live osteocutaneous flaps. *Plast Reconstr Surg* 1979;64:14.
- [130] McKee K: Microvascular bone transplantation. *Clin Plast Surg* 1978;5:283.
- [131] Daniel R: Mandibular reconstruction with free tissue transfers. *Ann Plast Surg* 1978;2:346.
- [132] Urken ML: Composite free flaps in oromandibular reconstruction: Review of the literature. *Arch Otolaryngol Head Neck Surg* 1991;117:724.
- [133] Annino DJ, Goguen LA, Karmody CS: Distraction osteogenesis for reconstruction of mandibular symphyseal defects. *Arch Otolaryngol Head Neck Surg* 1994;120:911.
- [134] Mignogna FV, Rankow R, Garay KF: A-0 reconstruction plate and sternal osteomyocutaneous flap in primary mandibular reconstruction. *Am J Surg* 1993;166:416.
- [135] Boyd JB: Use of reconstruction plates in conjunction with soft-tissue free flaps for oromandibular reconstruction. *Clin Plast Surg* 1994;21:69.
- [136] Irish JC, Gullane PJ, Gilber RW, et al: Primary mandibular reconstruction with the titanium hollow screw reconstruction plate: Evaluation of 51 cases. *Plast Reconstr Surg* 1995;96:93.
- [137] Cordeiro PG, Hidalgo DA: Soft tissue coverage of mandibular reconstruction plates. *Head Neck Surg* 1994; 16:112.
- [138] Blackwell KE, Buchbinder D, Urken ML: Lateral mandibular reconstruction using soft-tissue free flaps and plates. *Arch Otolaryngol Head Neck Surg* 1996;122:672.
- [139] Kudo K, Shoji M, Yokota, et al: Evaluation of mandibular reconstruction techniques following resection of malignant tumors of the oral region. *J Oral Maxillofac Surg* 1992;50:14.
- [140] Wells MD, Luce EA: Reconstruction of midfacial defects after surgical resection of malignancies. *Clin Plast Surg* 1995;22:79.
- [141] Ilankovan V, Jackson IT: Experience in the use of calvarial bone grafts in orbital reconstruction. *J Oral Maxillofac Surg* 1992;30:92.
- [142] Sadove RC, Powell LA: Simultaneous maxillary and mandibular reconstruction with one free osteocutaneous flap. *Plast Reconstr Surg* 1993; 92:141.
- [143] Jones NF, Swartz WM, Mears DC, et al: The "double-barrel" free vascularized fibular bone graft. *Plast Reconstr Surg* 1988;81:378.
- [144] Luce EA: Reconstruction of the lower lip. *Clin Plast Surg* 1995;22:109.

- [145] Baker SR, Krause CJ: Pedicle flaps in reconstruction of the lip. *Fae Plast Surg* 1983;1:61.
- [146] Takeichi Y, Kamei S, Oyama S, et al: Mobile tongue reconstruction with the free dorsal pedis flap. *Acta Otolaryngol Suppl* 1996;525:30.
- [147] Stanley RJ, Olsen KD: Rhinectomy for malignant disease: A 20-year experience. *Arch Otolaryngol Head Neck Surg* 1988;114:1307.
- [148] Kazanjian VH: The repair of nasal defects with median forehead flap lining. *Surg Gynecol Obstet* 1946;83:37.
- [149] Washio H: Further experiences with the retroauricular-temporal flap. *Plast Reconstr Surg* 1972;50:160.
- [150] Yousif NJ, Matloub HS, Sanger JR, et al: Softtissue reconstruction of the oral cavity. *Clin Plast Surg* 1994;21:15.
- [151] Wells MD, Edwards AL, Luce EA: Intraoral reconstructive techniques. *Clin Plast Surg* 1995;22:91.
- [152] Wagner JD, Ress A, Coleman JJ: Repair of midline vertical lower lip deficiency after mandible reconstruction. *Am J Surg* 1996;172:625.
- [153] Neligan PC, Boyd JB: Reconstruction of the cranial base defect. *Clin Plast Surg* 1995;22:71.
- [154] Coleman JJ: Osseous reconstruction of the midface and orbits. *Clin Plast Surg* 1994;21:113.
- [155] Ketcham AS, Hoyer RC, Van Buren JM, et al: Complications of intracranial facial resections for tumors of the paranasal sinuses. *Am J Surg* 1966;112:591.
- [156] Westbury G, Wilson JSP, Richardson A: Combined craniofacial resection for malignant disease. *Am J Surg* 1975;130:463.
- [157] Millard DR Jr: Congenital nasal tip retrusion and three little composite ear grafts. Case report. *Plast Reconstr Surg* 1971;40(5):501.
- [158] Siegel RF: Palatal grafts for eyelid reconstruction. *Plast Reconstr Surg* 1985;26(3):411.
- [159] Yoshimura Y, Nakajima T, Yoneda K: Use of palatal mucosal graft for reconstruction of the eye socket. *J Craniomaxillofac Surg* 1995;23:27.
- [160] Motoki DS, Mulliken JB: The healing of bone and cartilage. *Clin Plast Surg* 1990;17:527.
- [161] Hendler BH, Gateno J, Smith BM: Use of auricular cartilage in the repair of orbital floor defects. *Oral Surg Oral Med Oral Pathol* 1992;74:719.11.
- [162] Shestak KC: Soft-tissue reconstruction of craniofacial defects. *Clin Plast Surg* 1994;21:107.

- [163] Sclaroff A, Haughey B, Gay WD, et al: Immediate mandibular reconstruction and placement of dental implants: At the time of ablative surgery. *Oral Surg Oral Med Oral Pathol* 1994;78:711.
- [164] Stoler A, Hill T: Parts I, II. Mandibular reconstruction: Combined intra-oral and in vitro placement of osseointegrated implants into a free and vascularized bone graft. *J Oral Implantol* 1992;18(1):38.
- [165] Taylor TD, Rieger WP: Alloplastic implants: Their role in reconstruction of the mandible. *Clin Plast Surg* 1994;21:79.
- [166] Moscoso JF, Keller J, Genden E, et al: Vascularized bone flaps in oromandibular reconstruction. *Arch Otolaryngol Head Neck Surg* 1994; 120:36.
- [167] Albrektsson T: A multicenter report on osseointegrated oral implants. *J Prosthet Dent* 1988; 60:76.
- [168] Mounsey RA, Boyd JB: Mandibular reconstruction with osseointegrated implants into free vascularized radius. *Plast Reconstr Surg* 1994; 94:457.
- [169] Martin IC, Cawood JI, Vaughan ED, et al: Endosseous implants in the irradiated composite radial forearm free flap. *Int J Oral Maxillofac Surg* 1992;21:266.
- [170] Reyhler R, Ortabe JI, Pecher A, et al: Mandibular reconstruction with a free vascularized fibula flap and osseointegrated implants: A report of four cases. *J Oral Maxillofac Surg* 1996;54:1464.
- [171] Zlotolow IM, Huryn JM, Piro JD, et al: Osseointegrated implants and functional prosthetic rehabilitation in microvascular fibula free flap reconstructed mandibles. *Am J Surg* 1992;165:677.
- [172] Donovan MG, Dickerson NG, Hanson LJ, et al: Maxillary and mandibular reconstruction using calvarial bone grafts and Branemark implants: A preliminary report. *J Oral Maxillofac Surg* 1994;52:588.
- [173] Peer L: Transplantation of Tissues, vol 1. Baltimore, Williams & Wilkins, 1955.
- [174] Skinner FA: Maxillofacial prosthodontics: An aid to the oncology patient. *J Med Assoc Ga* 1992;81:331.
- [175] Valauri AJ: Maxillofacial Prosthetics. In McCarthy JG (ed): *McCarthy's Plastic Surgery*, ed 2. Philadelphia, WB Saunders, 1990.
- [176] King GE, Martin JW: Complete dentures for the obturator patient. *Dent Clin North Am* 1996; 40:217.
- [177] Sharma AB: Case studies in maxillofacial reconstruction using osseointegrated implants. *Oral Maxillofac Surg Clin North Am* 1993;5:395.
- [178] Richardson D, Cawood JI: Mandibular reconstruction and rehabilitation in childhood. *Br Dent J* 1995;179:141.

- [179] Stepnick DW, Hayden RE: Postoperative monitoring and salvage of microvascular free flaps. *Otolaryngol Clin North Am* 1994;27:1201-1217.
- [180] Soderholm AL, Hallikainen D, Lindqvist C: Radiologic follow-up of bone transplants to bridge mandibular continuity defects. *Oral Surg Oral Med Oral Pathol* 1992;73:253

IntechOpen

IntechOpen

