

We are IntechOpen, the world's leading publisher of Open Access books Built by scientists, for scientists

6,900

Open access books available

186,000

International authors and editors

200M

Downloads

Our authors are among the

154

Countries delivered to

TOP 1%

most cited scientists

12.2%

Contributors from top 500 universities



WEB OF SCIENCE™

Selection of our books indexed in the Book Citation Index
in Web of Science™ Core Collection (BKCI)

Interested in publishing with us?
Contact book.department@intechopen.com

Numbers displayed above are based on latest data collected.
For more information visit www.intechopen.com



Regenerative Techniques in Oral and Maxillofacial Bone Grafting

Arash Khojasteh, Mohammad Esmaeelinejad and
Farzad Aghdashi

Additional information is available at the end of the chapter

<http://dx.doi.org/10.5772/59236>

1. Introduction

The art and science of reconstruction of maxillofacial bony defects is a field of interest for most of maxillofacial surgeons due to its importance and prerequisite role for other surgical procedures. Despite significant improvements during last decades in this field, challenge still exists to determine which type of reconstruction techniques and materials is the treatment of choice. Although dental implants are considered as a standard and effective treatment to restore dental defects nowadays, lack of adequate bone quantity is a pitfall for dental implant reconstruction procedures. Grafting techniques have a long history in the literature with different donor sources and technical innovations and improvements. These methods are the most common techniques in bone reconstruction yet, but in the era of bioengineering, new alternative horizons lie ahead.

Regenerative techniques for maxillofacial hard tissue reconstruction like other tissue engineering procedures is based on three principle elements; stem cells, scaffolds, and growth factors. The balanced scenario of bone induction and conduction is a critical issue in every bone regeneration procedure [1].

Current approaches used in clinical circumstances to reconstruct bony defects include different bone grafting methods, such as autologous bone grafts, allografts, bone-graft substitutes, distraction osteogenesis, and guided bone regeneration.

Bone-graft substitutes have been developed to be used as scaffolds to promote cell migration, proliferation and differentiation for bone regeneration without need to violate other tissue from a donor site [2.]

Distraction osteogenesis and guided bone regeneration are brilliant concepts which work basically by modifying normal bone healing process. Soft callous enlarging guidance is the key element in distraction osteogenesis and space maintaining for relatively slow growing hard tissue is the fundamental of guided bone regeneration techniques. This chapter introduces methods of bone reconstruction and regeneration in oral and maxillofacial surgery. Indeed the knowledge of exact indications and advantages of each method is invaluable for the surgeon.

2. Anatomy of the skeleton

The fundamental bony skeleton of the jaws consist of a mandible and two maxillary bones. Because of the functional aspect of these structures and their atrophic changes during aging, anatomical features have specific importance to distinguish defects and determine the proper treatment plan. The quantity and quality of bone in the alveolar process and adjacent structures are the key elements of this issue. The anatomical knowledge of these structures is also a determinant factor when using them as donor sites for reconstruction.

The alveolar bone of mandible and maxilla is a functional bony process which harbors teeth in a dentate human. After tooth loss, this bony structure loses its dimensions both vertically and horizontally [3]. After atrophic sequences, the maxillary alveolar arch diameter decreases, despite the fact that the mandibular alveolar arch enlarges in diameter and a pseudo-class III relation may appear in severe atrophic alveolar ridges (Figure 1).

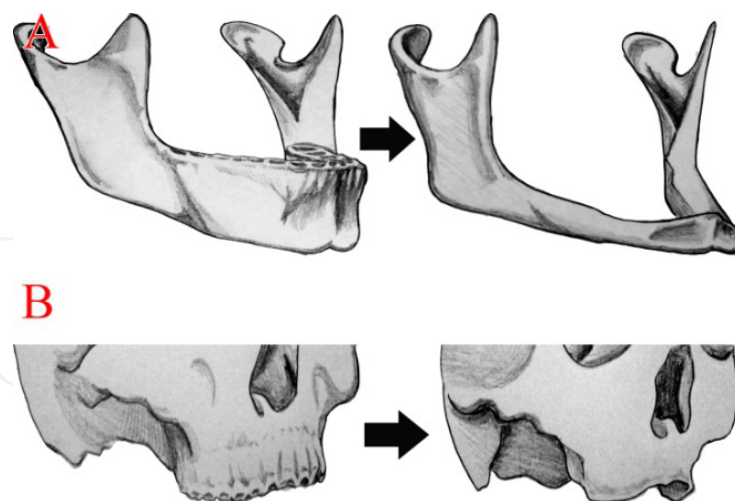


Figure 1. A, The atrophic changes of mandible. B, The atrophic changes of maxilla.

The quality of edentulous alveolar bone is classified to D1, D2, D3 and D4 based on cortical bone thickness and density of trabecular bone respectively.

D1 demonstrates the thickest cortical bone and the most dense trabecular part and is usually located in anterior mandible;

D4 demonstrates a large volume of low density trabecular bone and thin cortices and is located mainly in posterior maxilla.

D2 and D3 with intermediate characteristics are located in posterior mandible and anterior maxilla respectively [4].

The maxillary tuberosity is located in the posterior maxillary bone on each side and contains low density D4 bone and attached to the pterygoid plates at the pterygomaxillary junction. It is located next to important anatomical structures- the pterygomaxillary fissure and pterygo-palatine fossa.

The maxillary sinus is a pyramidal cavity in each maxilla with a broad base medially and an apex laterally. Its size varies depending on the patient's age and presence of teeth. During the lifetime the sinus enlarges continuously and at the age about 12, the floor of the sinus is almost at the level of the nasal floor. Maxillary posterior teeth loss and sinus pneumatization are responsible for decreasing bone volume in this area.

The mandible is the largest bone of the face and generally consists of thicker cortical bone compared to the maxilla. The anterior border of ramus as runs toward the mandibular body creates external oblique ridges bilaterally. The mandibular canal begins from the mandibular foramen at the middle medial surface of ramus horizontally and vertically and ends at the mental foramen on the buccal surface of the mandibular body near the apices of the premolar teeth on both sides. The least distance from the mandibular canal to the buccal cortex is in the distal part of the mandibular first molars. The canal course through the mandible usually makes a loop near the mental foramen with about a 3 mm diameter. The neurovascular bundle travels through this canal to supply sensation and blood to the mandibular teeth and some part of the chin.

The buccal fat pads or Bichat's fat are located lateral to the buccinator muscles bilaterally and consist of four parts; body, temporal, buccal, and pterygoid extensions. Buccal fat pads are supplied by the temporal and transverse facial arteries. The buccal fat pads are very useful structures in reconstruction of oral defects [5, 6].

3. Recipient site classification and defect analysis

The importance of alveolar bone defect analysis and classification is to determine the best regenerative treatment for each specific defect. This is more obvious when an evidence-based decision is made according to all data presented in the literature. Parameters which can describe alveolar bony defects are:

- Anatomic position of defect in the jaws (mandible/maxilla, anterior/posterior)
- Dimensions of the defect
- Morphology of the defect
- Type of reconstruction (vertical/horizontal)

- Relation of augmentation and defect region (internal; inside the contour and external, outside the ridge contour)
- Defect base width and number of residual bony walls surrounding the defect

Anterior and posterior parts of the mandible and maxilla have different bone qualities; hence they have different regenerative capacities [7]. The length of the defect affects the degree of vascularization. In vertical defects with no sufficient width to accept implants, the augmentation procedure becomes complicated because both dimensions require restoration [8]. It has been suggested that a wide bony defect base has greater capacity for bone regeneration compared to a narrow base defect [7]. The number of surrounding bony walls around the defect is mentioned in the literature as stabilization for the initial blood clot [8].

Different classifications to describe alveolar ridge defects have been documented [9-11]. Seibert et al. classified the defects of the alveolar ridge based on dimension in which the resorption had occurred: horizontal defects (class I, 33%), vertical defects (class II, 3%) and the most common variant mixed horizontal and vertical defects (class III, 56%) [10].

Some similar classifications were suggested by other investigators according to the morphology of the alveolar bone defects. A classification published by Wang and Al-Shammari, the defects were subdivided in: horizontal, vertical, and combined [12]. Each group was further classified based on the amount of the deficiency. Studer (1996) documented the first quantitative classification of alveolar defects based on predicting need to reconstruct deficiencies, with classes defined as < 3 mm, 3–6 mm and > 6 mm [8].

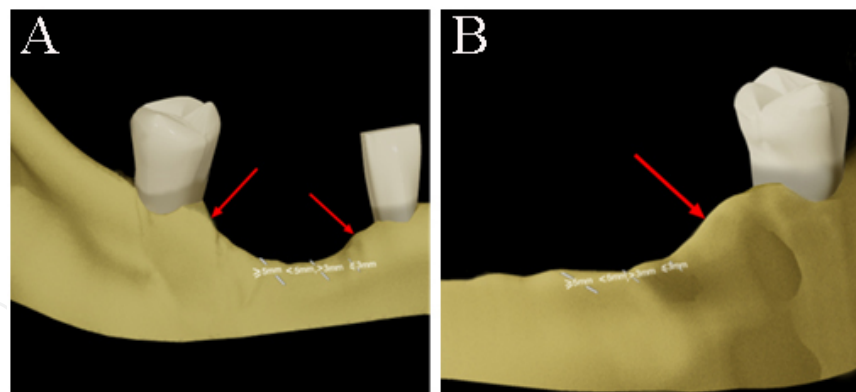


Figure 2. A, Interdental partial edentulism. Class A: two-wall defect. The arrows show the defect walls. B, Free end partial edentulism. Class B: one-wall defect (arrow).

The Cologne classification of alveolar ridge defects uses orientation of the defect (horizontal, vertical, combined and sinus area) reconstruction needs associated with the defect (small: < 4 mm, medium: 4-8 mm large: > 8 mm) [8]. Khojasteh et al. in 2013 in a literature review stressed the clinical importance of recipient site characteristics for vertical ridge augmentation concluded that information regarding the characteristics of the initial vertical defect is not comprehensively incorporated in most of the studies [8]. They proposed a classification with regard to the number of surrounding bony walls (A: Two-wall defects, B: One-wall defects, C:

A defect with no surrounding walls) and width of defect base (I: A bony defect with a base width of 5 mm or more, II: A bony defect with a base width of 3 mm or more, but less than 5 mm, III: A bony defect with a base width less than 3 mm, (Figure 2).

4. Donor sites in oral and maxillofacial surgery

Various donor sites to harvest free bone grafts are used in oral and maxillofacial surgeries. Each site has its own indications, advantages and disadvantages. Ideally, the surgeons prefer to harvest bone from a site that is close to the recipient site to operate in one surgical site and avoid making more skin scars. In reality, the quality and quantity of bone sometimes necessitates grafting from other sites.

5. Bone harvesting from intraoral donor sites

5.1. The chin

Cortical or corticocancellous block graft in sizes up to 4 cm can be harvested from the mandibular symphysis area intraorally (Figure 3). The mandibular symphysis as a donor site has been documented to provide sufficient bone to reconstruct alveolar ridge defects 4-6 mm in horizontal and up to 4 mm in vertical dimensions and can cover a span up to 3 teeth in length [13]. The available block graft may be harvested from this site is 10 mm (height) 15 mm (width), 6 mm (thickness), with an average volume of 860 cc [14]. The symphysis can provide over 50% larger graft volume in comparison to the lateral ramus region [15]. The typical symphysis corticocancellous bone graft consists of 65% cortical bone and 36% cancellous bone [14]. Because of slow resorption rate of chin grafts, it can also be used as an onlay graft for facial defects.

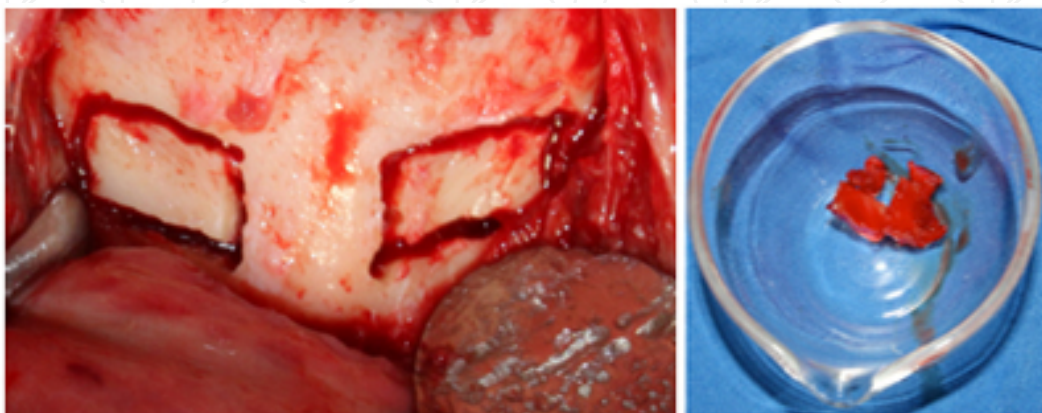


Figure 3. Block bone graft harvested from the mandibular symphysis

5.2. Lateral ramus

The mandibular lateral ramus or retro-molar region is advocated for corticocancellous bone harvesting with approximately 100% cortical composition (Figure 4).

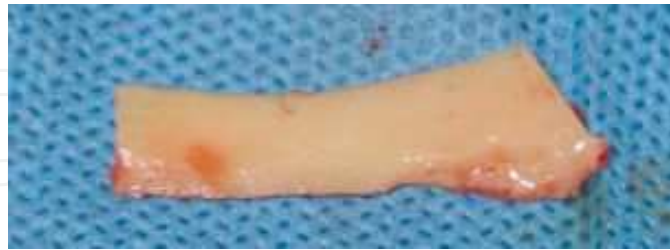

Figure 4. Block bone graft harvested from mandibular lateral ramus area.

A buccal shelf block graft can provide sufficient bone to reconstruct alveolar defects 2-3 teeth in length. Horizontal and vertical defects up to 3 to 4 mm can be augmented from this donor site [16, 17]. The maximum dimensions of ramus cortical bone blocks are 4mm (thickness) 15 mm width and 35 mm in length depending on the regional anatomy. The clinical access, position of the inferior alveolar canal, molar teeth, and width of the posterior mandible are factors limiting the amount of possible graft that may be harvested [16, 17]. The morbidity of this region has been reported lower than the mandibular symphysis region [15].

5.3. Maxillary tuberosity

Among intra-oral donor sites, the maxillary tuberosity typically provides a smaller amount of bone (Figure 5).

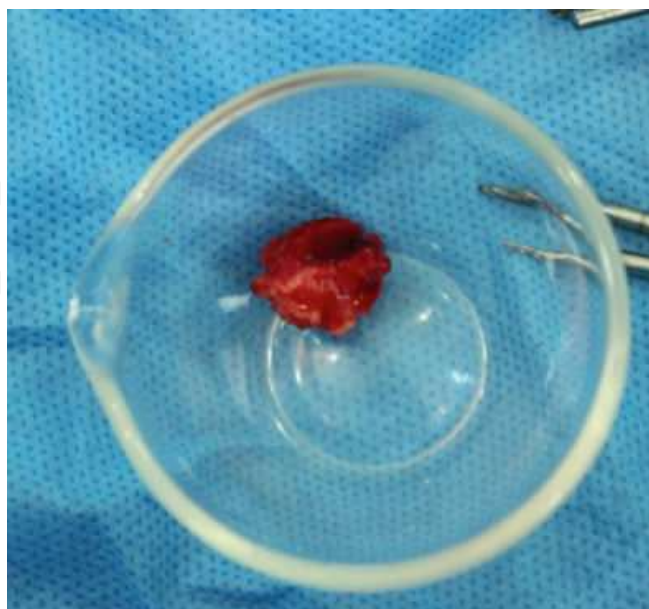


Figure 5. Block bone graft harvested from the maxillary tuberosity.

This region is usually used for harvesting cancellous bone to fill defects and for sinus lifting procedures. Existence of the 3rd molar in this site decreases the available bone for harvesting. Other anatomical limitations for using this site include: the maxillary sinus, pterygoid plates and the greater palatine canal.

5.4. Anterior palate

This area is used as a donor site usually for anterior maxillary reconstruction, especially when an impacted canine is imbedded in this region (Figure 6).

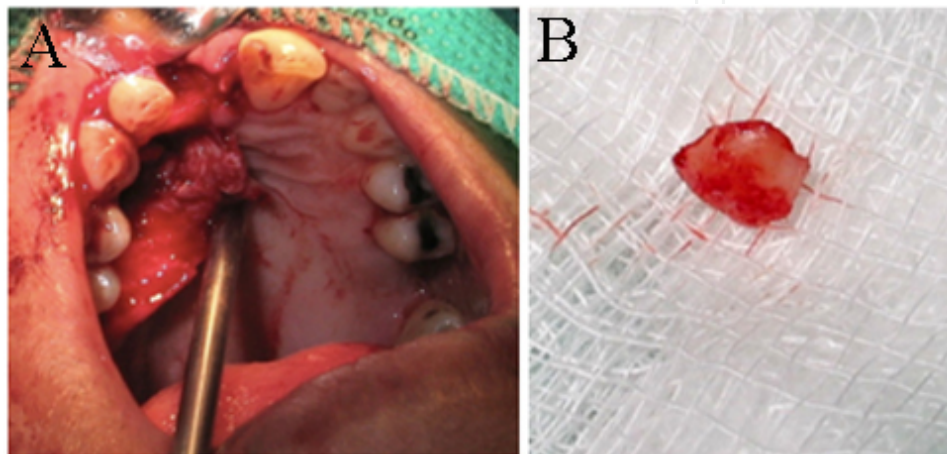


Figure 6. A, palatal flap is retracted and the donor site for harvesting palatal bone graft is exposed. B, block bone graft harvested from the anterior palate.

The corticocancellous block, cancellous or crescent-shaped grafts can be harvested from this site. The average amount of bone in this area in dentate patients is 2 cc and 2.4 in edentulous patients [18].

6. Other intraoral sources

Maxilla buttress or zygomatic processes of maxilla, anterior nasal spine and bone exostosis also have been documented as donor sites. These areas provide little bone and are preferred choices for adjacent recipient sites or in combination with other bone substitutes.

7. Bone grafting with extra oral donor sites

7.1. Iliac crest

The iliac crest bone is the most common extra-oral donor site for bone grafts. It may be harvested vascularized, non-vascularized, cortical, cancellous or corticocancellous in different shapes and in large sizes (Figure 7).

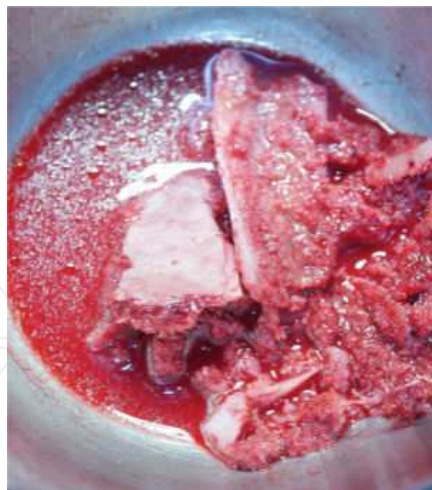

Figure 7. Iliac bone graft harvested to reconstruct the mandible.

The location of the iliac crest permits the surgeons to harvest bone graft and operate simultaneously to save operating time. A full-thickness iliac crest bone graft consists of two thick cortices with sufficient amount of cancellous bone in between and can restore the thickness and height of mandibular bone efficiently. The graft shows a good success rate, and dental implant insertion is possible in this type of bone graft [19, 20]. Mandibular continuity defects treated with free iliac bone grafting are documented with about a 70% success rate [21]. The rate of successful union is decreased significantly where the defect is longer than 6 cm [21, 22]. The posterior iliac crest also can be used as a donor site. Morbidity rate for anterior iliac crest bone grafts is more than posterior iliac site (23% and 2% respectively) [23].

Complications. Postoperative pain, iliac fractures, gate disturbances, hematoma, herniation of abdominal contents, vascular injury, nerve injury, unsightly contour defects along the iliac crest and growth disturbances in young ages [24].

7.2. Calvarial graft

The calvarium is a popular cortical bone grafting site basically for its mechanical features and very slow resorption rate [24]. It is suggested for facial augmentation, orbital roof and floor reconstruction, and covering midface defects rather than alveolar defects. Typically, the outer cortex is used as a cortical plate graft (Figure 8), although a full-thickness or inner cortex graft may be used.

The skull growth continues to the age of 8 and become thicker until the age of 20 years. The thickest portion is located at the parietal region. This donor site can provide 8 by 10 cm of bone [25]. Thickness of the calvarial bone is highly variable so preoperative radiographs help the surgeon to harvest bone safely [25]. It should keep in mind that dura is tightly adherent to the inner cortex and can easily be injured if the inner cortex is aimed to be harvested. Also various vascular structures are located just under the bone at different sites, like the superior sagittal sinus in the midline. The inner and outer cortices may merge together in inferior and lateral portions. Other anatomic structures, such as transcortical emissary veins, subcortical vessels,

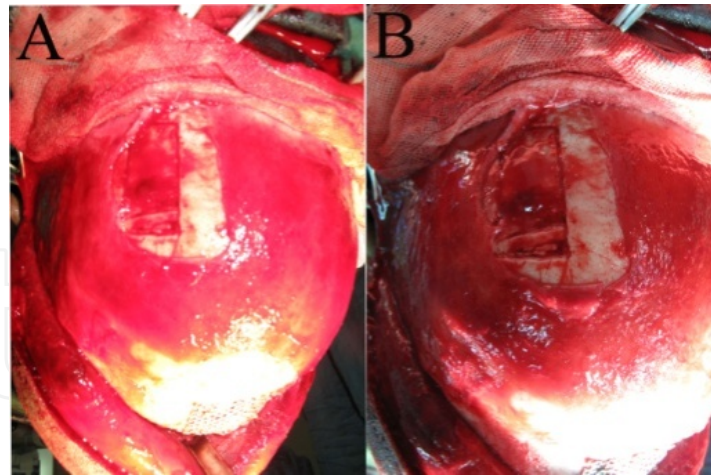


Figure 8. Calvarial bone graft harvesting approach. A, The scalp is retracted and calvarium is exposed. B, The osteotomy site is visible.

and aberrant arachnoid plexuses are also at risk and should be considered in the surgical procedures [25]. Temporalparietal regions can be used to harvest more curved grafts and straight grafts can be harvested from occipital or frontal regions.

Complications. Contour deformity at the donor site and grafting bone fracture in harvesting are the most common complications. Dural exposure or rupture is another complication but is not common. Intracranial hemorrhage due to this type of graft harvesting has been reported.

7.3. Tibial graft

The anterior surface of the tibial plateau is mentioned as a donor site for cortical or cortico-cancellous bone grafts. Proper mechanical features of the tibial cortex seem to be useful in augmentation of atrophic alveolar ridges for implant insertion or facial bone defect reconstruction. Up to 40 cc cancellous bone can be harvested from the tibia (Figure 9).

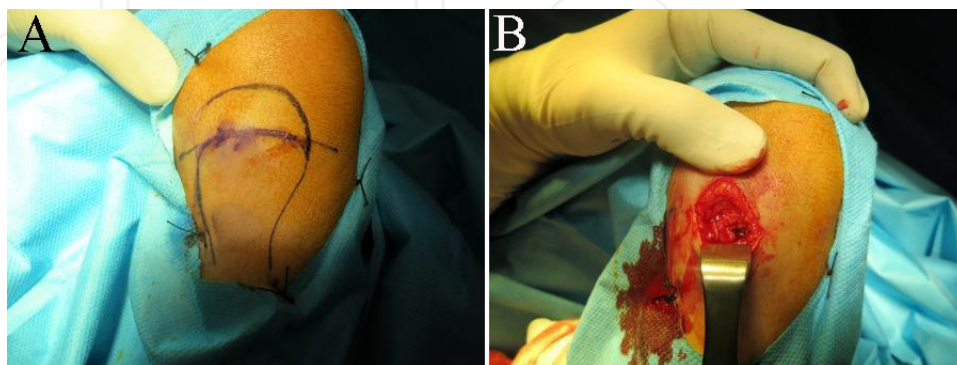


Figure 9. Tibial bone graft harvesting approach. A, the donor site is indicated before making the incision. B, the flap is retracted and bone graft is harvested using a curette.

The most common approach for this purpose is laterally at Gerdy's tubercle [26].

7.4. Rib graft

Free rib bone was one of the first autogenous bone grafts used for reconstruction of mandibular defects. Osseous or osseochondral grafts can be harvested from fifth to seventh ribs. Although costochondral grafts remain popular for the treatment of mandibular ramus and condylar defects, the quality and quantity of rib bone make it less popular for jaw defect reconstruction nowadays [27].

Complications. Postoperative chest wall pain, pleural injury leading to pneumothorax, and overgrowth of the graft [27, 28].

8. Reconstruction techniques

Different reconstruction techniques have been known and well documented for bony defects in the oral and maxillofacial area. Distraction osteogenesis and guided bone regeneration techniques, grafting procedures and especially autogenous bone grafting still are the treatments of choice in most alveolar bony defects. Soft tissue consideration and management should be borne in mind for successful stable results.

8.1. Bone grafting

"Any implanted material that promotes bone healing" is defined as a bone graft [24]. Ideally it must be: osteoconductive, osteoinductive and osteogenic.

An osteoconductive capacity means allowing or directing the new bone to form within the material structure.

An osteoinductive capacity describes supplying recruitment and/or differentiation factors for bone-forming cells by the grafting material.

An osteogenic graft material provides induced or inducible bone-forming cells.

Bone grafts are used not only for a defect facilitating healing but also for contour augmentations. For this purpose more attention is directed towards the amount and rate of graft resorption. Graft incorporation is proportional to amount of graft resistance to resorption [24].

Bone grafts can be classified as:

Autografts (transferring bone in one human),

Allografts (transferring inter-humans), and

Xenografts (transferring from other species, synthetic materials and any combination of them).

Autografts can be cancellous, cortical, corticocancellous, vascularized bone or aspirated bone marrow. The main advantage of autogenous bone is retention of at least some osteogenic cells without triggering the immune system. On the other hand donor site morbidity and limited amount are basic disadvantages. Ideally, the bone graft should be incorporated into the

recipient bed; the space that the bone graft occupies should finally become viable bone with physiological remodeling mechanisms. Many factors are involved in the incorporation process namely the graft type, graft bed (recipient site), and interface in between. Graft related factors including the type of graft, porosity and mechanism of incorporation. Recipient site viability and vascularity are very important in any autogenous grafting procedures. Graft incorporation has been summarized by Bauer and Muschler in five steps [24]

1. Hematoma formation, release of bone inducing factors and cellular recruitment
2. Inflammation and development of fibrovascular tissue, connecting the graft to the adjacent bone
3. Vascular invasion of the graft
4. Focal resorption of the graft by recruited osteoclasts
5. New bone formation, union between the graft and the surrounding bone, and graft remodeling

Graft stabilization is other critical issue in bone graft incorporation and vascularization. Instability leads to bone resorption and infection. Cancellous bone grafts can be packed in defect cavities. In these cases more graft material transfer, leads to more vital cells and increase in osteogenesis. Cortical or corticocancellous block grafts should be stabilized using fixation devices.

8.2. Bone Grafting with intra oral donor sites (localized bone augmentation)

8.2.1. Symphysis block harvesting

There are three basic approaches to access the mandibular symphysis for bone graft harvesting: 1) sulcular, 2) attached gingiva, or 3) vestibular. The advantages of sulcular and attached gingiva approaches are reductions in wound dehiscence and bleeding compared to the vestibular approach. Use of the sulcular approach is not advocated in pre-existing periodontal diseases or crowns. The vestibular approach is done through the mucosa 5 to 10 mm below the mucogingival junction; first by partial thickness dissection apically for 3mm to maintain 3mm of periosteum and mentalis muscle fibers on the bone side, which will be used to reattach the muscle fiber [29]. Below this level a full thickness incision is made and full thickness flap reflection is used. Careful attention must be paid to prevent trans-section of the mental nerve at the distal extent of the incision bilaterally (Figure 10).

It is suggested that at least 5 mm bone is maintain below the teeth apices, inferior border and bilaterally anterior to mental foramina. When a large bone block is needed, the anterior most portion of the symphysis the mental protuberance must be retained. If it is necessary to harvest two graft blocks from each side, leaving a 3mm midline connection to maintain support for the chin profile is necessary [30]. The block graft can be osteotomized by a rotary bur, reciprocating saw, or piezo instrument. Using rotary burs has disadvantages of losing some amount of bone in comparison to two other methods. Osteotomies should enter the inter-cortical layer, giving close attention not violate the lingual cortex. A fine osteotome or chisel can be used to

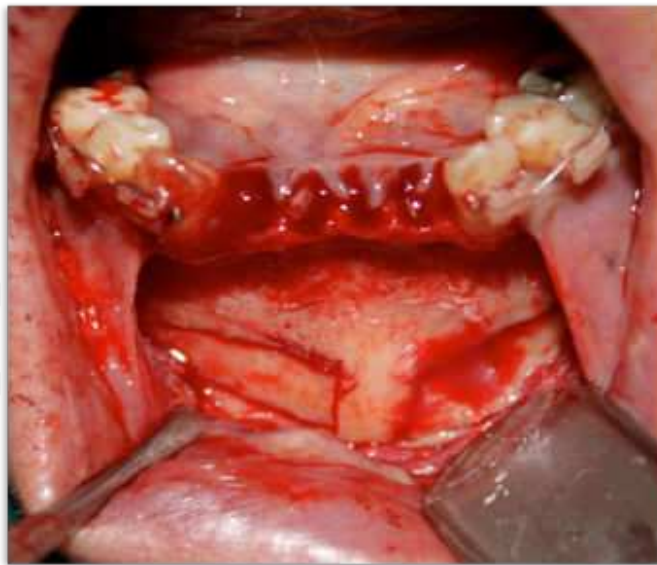


Figure 10. Full mucoperiosteal flap retracted to expose the donor site for harvesting symphyseal bone. Two osteotomy sites are determined on both sides and 3mm bone is maintained in between to support the chin profile.

reflect block bone graft from its bed. After block removal a hemostatic agent can be used in the donor site. Some clinicians prefer to fill the donor site with Freeze Dried Bone Allograft (FDBA), especially when a large block has been harvested. In the vestibular approach, when closing, a resorbable suture is first used to attach the mentalis muscle to the 3mm periosteal muscle layer left on the bone side.

8.2.2. Lateral ramus block harvesting

The approach to harvest bone graft from the lateral ramus can proceed two different ways: 1) Vestibular or 2) Sulcular. The vestibular approach has access through the area through vestibular incision on external oblique ridge. Advantage of this approach is lack of disturbing the periodontium of the adjacent teeth. The indication of sulcular approach is when recipient site is located nearby. The distal extent of the incision should not be more than occlusal plane to minimize the risk of facial nerve damage, bleeding and exposing buccal fat. Osteotomy is suggested to be performed in a defined sequence; superior cut, then anterior, then posterior and finally inferior cut (Figure 11).

The superior cut length and thickness is important. This cut is usually made approximately 4 mm medial to the external oblique ridge but can be performed up to 6 mm depending on the regional anatomy. It may be extended anteriorly to the distal area of the first molar, depending on the anatomy. The anterior and posterior vertical cuts are made in parallel to the predicted length and width of the bone graft block, and are limited by anatomic position of the mandibular canal, which determines the harvesting block width. Complete cortical penetration of inferior osteotomy cut is avoided due to its proximity to the mandibular canal in many cases. An osteotome or a chisel can be used to remove the bone graft from its bed avoiding penetrating excessively to damage mandibular canal. Closing the incision usually is done without applying any graft or hemostatic agent.

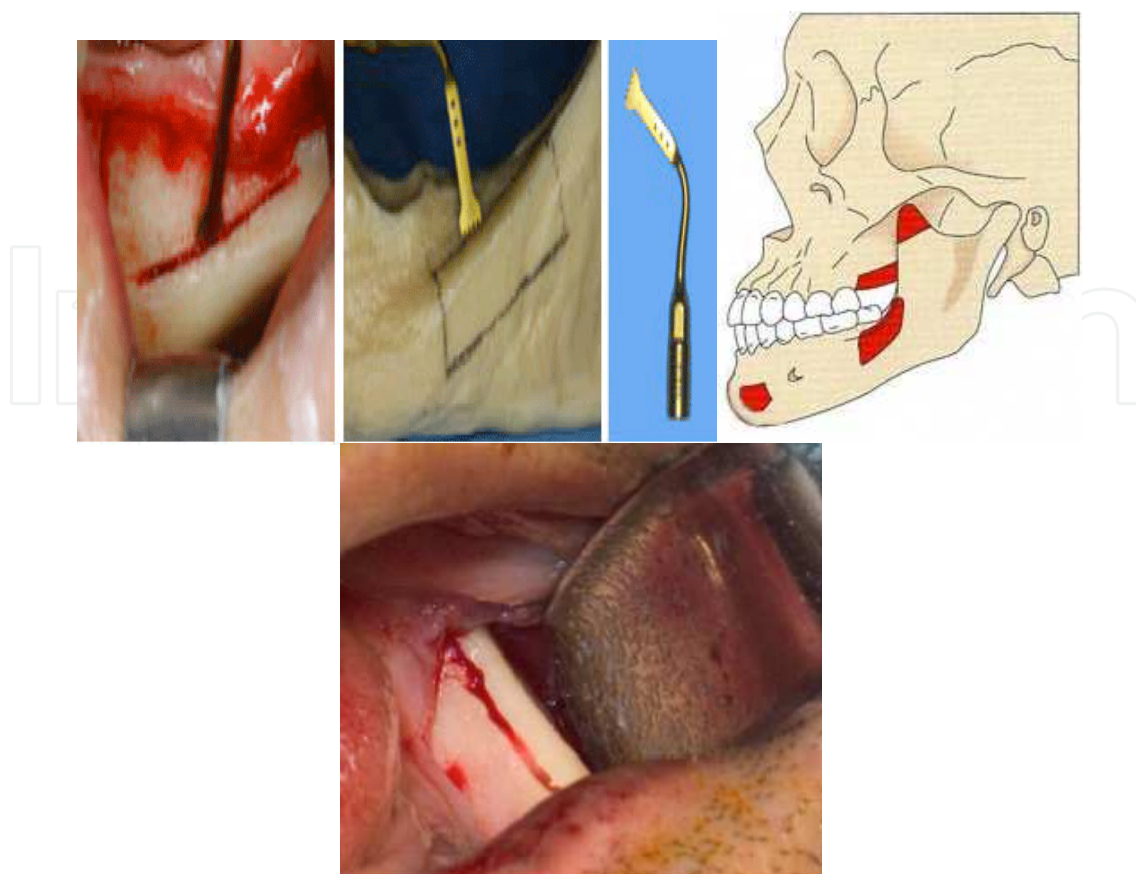


Figure 11. Intraoral approach to harvest the lateral ramus bone block. The osteotomy line of the superior cut is seen.

8.3. Anterior iliac crest bone grafting

Anterior iliac crest bone grafts are common used grafts not only in maxillofacial surgery but also in orthopedic surgery. The iliac crest is almost subcutaneous and cortical or corticocancellous grafts in different shapes and size can be taken from this region simply and safety. The *anterior superior iliac spine (ASIS)*, is easily palpable which is located in the most anterior and superior portion of the crest. Posteriorly along the crest of the ilium in the widest portion is the iliac tubercle. The incision starts 2 cm posterior to ASIS and continues up to 8 cm along the crest. The neural branches, which are in risk of damage, are iliohypogastric, subcostal branches and lateral femoral cutaneous nerves. Retracting the skin medially and avoiding extending the incision posteriorly are suggested to decrease this risk. Dissecting laterally and violating iliotibial fascia is not recommended. Harvesting bone from iliac crest can be performed via different approaches including using a trephine device, monocortically and bicortically with different techniques (Figure 12).

Usually monocortical bone blocks are harvested from the medial surface with osteotomes or a saw. In young ages, the border portion of the iliac crest consists of chondral structure which should be bypassed in the harvesting procedure. Closing the donor site is done in three layers, and a vacuum drain usually is placed. Minor complications of this bone graft harvesting included superficial infections, superficial seromas, and minor hemato-

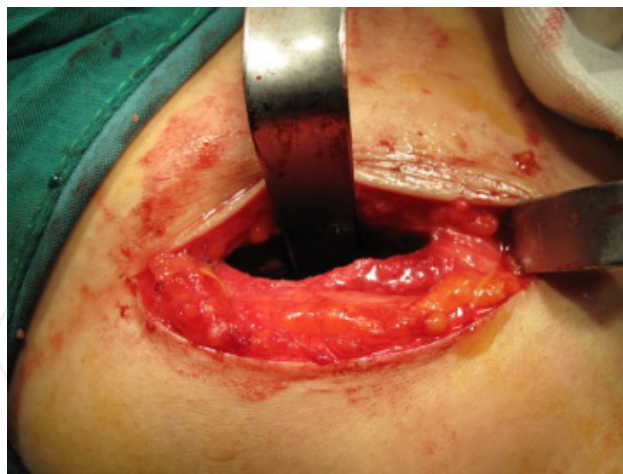

Figure 12. Iliac bone graft harvesting procedure.

mas. Major complications are herniation of abdominal contents, vascular injuries, deep infections at the donor site, neurologic injuries, deep hematoma formation requiring surgical drainage, and iliac fractures [31].

8.4. Placing the bone graft into the recipient site

A moist environment with saline is suggested as a reservoir for the autogenous bone graft. Cortical or corticocancellous block grafts can be adjusted for recipient site with burs, saws or discs. The block should be prepared so that when placed in the recipient site it does not rock and fits snugly and is in intimate contact with the underlying host bone bed. Fixation of the block graft is a principle issue. Screws and plates are devices, which can be used to achieve sufficient stability. Applying two screws is recommended and using the lag screw technique is suggested. The recipient bed and block graft may be penetrated to facilitate vascular ingrowths. Applying particulate bone graft around the bone block is usually advocated to maintain space for more osteogenesis. The graft structure is then covered with a barrier membrane to prevent soft tissue ingrowth into the integrating new bone especially when particulate materials are added. Tension free closure of the grafted site is critical to success.

8.5. Anatomic repositioning

8.5.1. Distraction osteogenesis

Distraction osteogenesis (DO) is a contemporary method that has been used in oral and maxillofacial defects. DO is a method to generate new bone by gradual separation of bone segments. In this procedure a distractor device is placed on two sides of an osteotomy site (Figure 13).

After a latency period the device is gradually activated and makes a gap between two bone segments. The new immature bone is generated between these two segments in the created gap. Then the device will not be activated for a period to give the new bone a time to mineralize

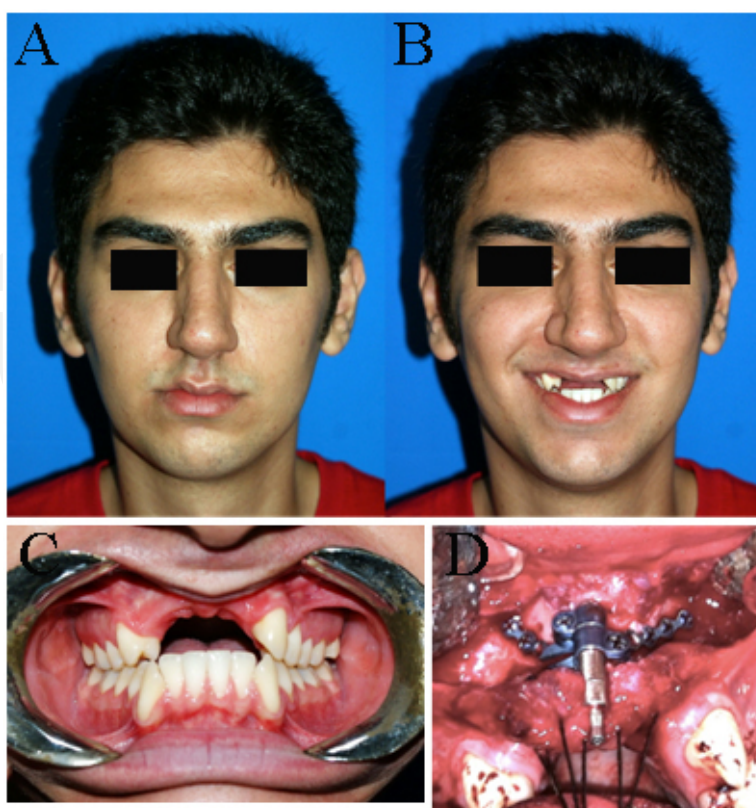


Figure 13. A. Patient with premaxillary deficiency. B. The patient has lost his anterior incisal teeth due to an anterior maxillary defect. C. Intra-oral view of the premaxilla defect. D. DO device is inserted in the surgery phase.

and turn into mature bone. This is called the consolidation phase and is usually twice the activation period. After the consolidation period the device is removed. During the activation period the surrounding soft tissue grows simultaneously with the bone formation (Figure 14). This is why the DO is also called distraction histogenesis. DO devices are divided into two groups of intraoral and extraoral types each of which have certain indications.

Indications. DO was generally used in orthopedics years before being used in maxillofacial surgery. The most popular indication of DO is in hemifacial or hemimandibular microsomia. Actually DO was used in a case of hemicraniofacial microsomia successfully for the first time by McCarthy et al. in 1992 [32]. The most important indication of DO is in syndromes associated with congenital anomalies like cerebral palsy, hemifacial microsomia, Treacher–Collins syndrome, Pierre–Robin sequence, Nager syndrome and others. Investigations have shown the successful results of DO in such cases [33].

DO in vertical dimension is another important indication. Although new methods of bone grafting like fibular microvascular graft have been broadly used in these defects sometimes their use is restricted by the large size of the defect. In these large defects DO is a better technique to regenerate new bone and reconstruct the defect [34]. Sometimes the combination of microvascularized grafts with DO procedure is an ideal technique to reconstruct large defects especially defects caused by resection of pathologic lesions [7].

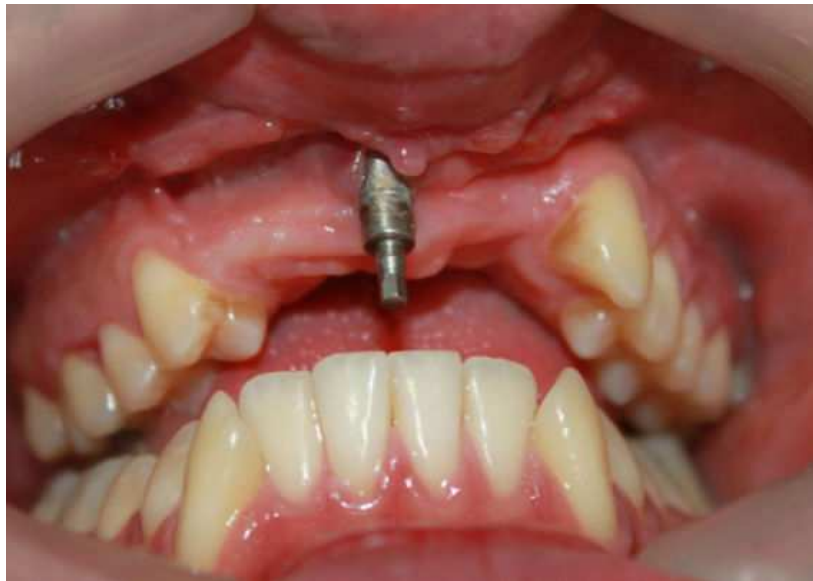

Figure 14. Inserted DO device is shown to generate new bone for reconstruction of the maxilla. The distractor device has been activated for months. The alveolar bone height has increased.

DO in transverse dimension is an interesting method being used in patients with arch constriction or an alveolar cleft. Reviews of the clinical studies about the use of DO in maxillary hypoplasia in patients with cleft lip and palate have shown the benefits of this technique as an alternative to orthognathic surgeries [35]. The important advantage of DO in these patients is unchanged or better velopharyngeal function. This method can be used in the mixed dentition period which is an advantage of this procedure comparing to orthognathic surgery procedures.

DO has been recently used in patients with midface hypoplasia in craniosynostosis like Crouzon, Apert, and Pfeiffer syndromes. Several investigations have evaluated this technique and compared it to LeFort III osteotomy [36, 37]. Although LeFort III osteotomy has been widely used to correct the maxillary retrusion, it is not possible to advance the midface a large amount. Lefort III-DO technique has been suggested in patients with great discrepancy; however trials have shown higher relapse of this method compared to the usual LeFort III osteotomy procedure. The advantage of LeFort III-DO technique is the lower risk for severe complications like cerebrospinal fluid leakage, meningitis, and infection.

Advantages. Simultaneous distraction of the soft tissue is a great advantage of this technique. The quality or quantity of the soft tissue bed makes the results of bone grafting unpredictable and reduces the success of the bone graft. In most cases DO obviates the need for bone grafting in the future. Morbidity of a donor site is also eliminated. The process of inserting and removing the device is less extensive as well.

Disadvantages. DO is a technique sensitive procedure and should be performed by an expert surgeon. The quality of the device is an important factor in success rate of the DO results. Loosening of the screws and displacement of the device may occur in some cases. DO procedures consist of two operations: one for insertion of the device and a second surgery to remove it. Sometimes a third surgery is needed in the future to achieve the perfect outcome especially

when DO has been performed in a young patient. Unpredictable outcomes or malocclusion are inadvertent results. Motor and sensory nerve dysfunction is an untoward complication of DO. This complication is especially seen in DO of the mandible which may lead to permanent or transient weakness of marginal branch of facial nerve or hypoesthesia of inferior alveolar nerve. Scar formation and infection should be considered a more usual complication of DO.

8.6. Nerve repositioning

Rehabilitation of edentulous patients is often complicated and requires special consideration. In edentulous patients with atrophic bone above the mandibular canal is insufficient; repositioning the inferior alveolar nerve (IAN) is a treatment option. This treatment is done if the overall bone height is enough to place implant fixtures, but the IAN interferes with this procedure. Repositioning of IAN is done to move the nerve from the canal placing it in a new position (outside the bone).

Nerve lateralization is a procedure in which the IAN is exposed and retracted laterally while the surgeon is inserting the fixtures. Then the nerve is left to fall back against the inserted fixtures or the lateral cortex. In nerve transposition technique the IAN, mental nerve and incisive nerve are exposed by corticotomy of the bone surrounding the mental foramen. Then the IAN is transected from its junction with the incisive nerve. In this way the nerve is freed and its retraction is much easier. The IAN is replaced posteriorly after cutting the incisive nerve. The surgeon is able to install the implant fixture after distalization of the IAN (Figure 15).

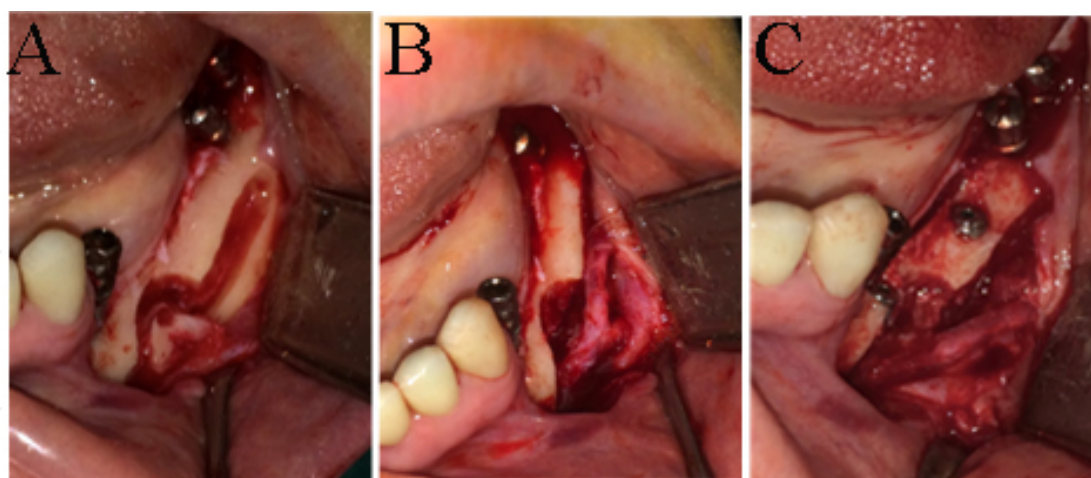


Figure 15. A, Nerve lateralization in an atrophic mandible to eliminate the nerve interfering with implant surgery. B, The IAN is transposed from the mandibular canal to make space for installation the implants. C, Simultaneous implant installation is also possible in this technique.

Indications. The actual indication of IAN transposition or lateralization is in atrophic posterior mandible where remaining bone above the mandibular canal is less than 10 mm [38,39]. There is no actual contraindication of IAN transposition reported in the literature.

Advantages. The risk of damage to IAN during the installation of fixtures is reduced by retracting and repositioning the nerve. The surgeon is able to use a longer fixture which may engage the inferior cortex of the mandible. The fixtures have more stability due to their bicortical insertion. This procedure is performed simultaneously with implant fixture installation with or without bone grafting.

Disadvantages. The risk of damage to the IAN is a prominent disadvantage of nerve transpositioning; Traction on the nerve usually causes temporary sensory loss [40]. Mandibular fracture, implant loss, hemorrhage, and osteomyelitis are other possible complications in long implant installation, associated with the transposition and lateralization of the IAN [38, 41, 42].

9. Guided bone regeneration (GBR)

The treatment and rehabilitation of edentulism with dental implants has become a routine treatment modality in contemporary dental practice. Nevertheless, tooth loss is frequently associated with subsequent bone loss, often resulting in inadequate bone dimensions for ideal dental implant placement. Alveolar ridge resorption in partially and totally edentulous patients may interfere with the safe and correct positioning and placement of implants. When ridge resorption occurs, bone augmentation is essential to guarantee adequate bone volume, to provide patients with proper inter-arch dimensions, and to insure a satisfactory aesthetic result.

9.1. Classic GBR

Guided bone regeneration (GBR) is an important concept concerning restoration of deficient alveolar sites (e.g., an extraction site or deficient alveolar ridge) for implant placement. GBR uses an occlusive membrane interface between gingiva and the alveolar bone tissue to promote osteogenic tissue regeneration. The occlusive membrane acts as a barrier when placed into the surgical site, preventing connective and epithelial tissue migration into the defect. Progenitor cells located in the adjacent alveolar bone or blood are then able to recolonize the root area and differentiate into a new osteogenic tissue with the formation of new bone.

The strategy to isolate the bone defect with a material that will function as a physical barrier to avoid gingival cell invasion led to the development of GBR membranes. These membranes need to exhibit: (1) biocompatibility to allow integration with the host tissues without eliciting inflammatory responses, (2) proper degradation profile to match those of new tissue formation, (3) adequate mechanical and physical properties to allow its placement in vivo, and (4) sufficient sustained strength to avoid the membrane collapse and perform their barrier function. GBR membranes are divided into two groups, nonresorbable and resorbable, according to their degradation characteristics.

Indications. The most popular application of GBR is in dehiscence and fenestration type defects with simultaneous implant placement (Figure 16).

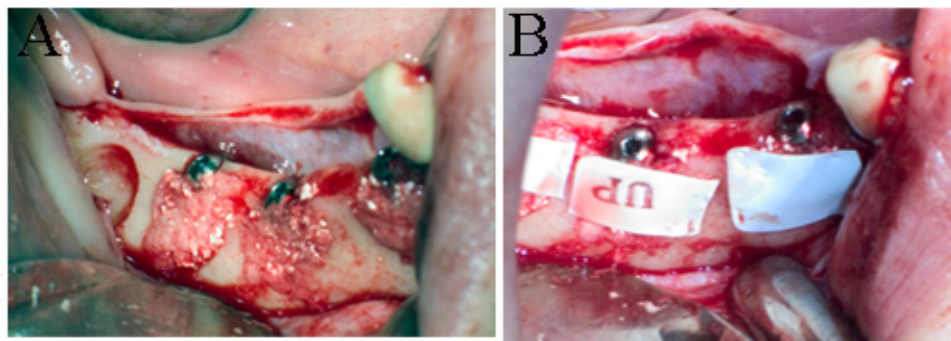


Figure 16. A, GBR is an efficient technique in correcting the dehiscence bone defects around implants. B, Exposed threads of the fixtures are covered by bone materials and a membrane to promote the osteogenic cells to generate new bone according to the guided regeneration concept.

The exposed threads of implants may be covered by bone materials and a membrane to prevent migration of the epithelial and connective tissue cells to the surgical site. So the osteogenic cells have the opportunity to migrate into the defect site and promote new bone formation. The bony dehiscence after installation of fixtures can be treated successfully by using GBR technique [43].

The other indication for GBR is an atrophic ridge either before or during implant surgery. The important consideration in reconstruction of ridge atrophy is appropriate case selection. Based on a general guide it is suggested to perform GBR procedure in A1, A2 or B1 defects of Khojasteh et al. classification. Application of GBR technique in these defects is associated with high implant survival rates [8]. Studies on installation of implants simultaneously with GBR showed a survival rate of 92.2% in horizontal defects. Others have reported the success rate of implants after the GBR procedure (non-simultaneous implant placement) reported 100% success in horizontal defects. The mean bone augmentation in these defects was 3.31 mm [43].

Advantages. GBR allows for the re-growth of the bone and the tissue. GBR is a relatively easy and predictable method which can be used under local anesthesia for small defects. In large defects due to trauma or resection of tumors the combination of this technique with bone grafting is an appropriate procedure for bone augmentation [43].

Disadvantages. As the procedure takes approximately six months to heal completely, the likelihood of failure is higher if the patient does not take appropriate care. Apart from this, the success is also defect specific as the chances of success may be smaller if the condition is severe [44].

The patient can contribute to the success of the procedure by maintaining good plaque control, nonsmoking, anti-infective therapy, and systemic health maintenance.

9.2. Cortical tenting (Osteogenic GBR)

A usual limitation in reconstruction of the oral and maxillofacial region is the resorption of bone grafts due to contraction of overlying soft tissue. Excessive bone grafting is not always the ideal technique to compensate for resorption. We are not able to harvest a large amount of

graft in all cases. Sometimes the defect size is larger than the harvested bone graft. In some cases we prefer to harvest the bone graft from an intra-oral recipient site rather than an extra-oral site because of its morbidity. The *cortical tenting technique* has been suggested as an alternative method.

Cortical tenting is a reconstruction method in which a block bone graft together with bone substitutes are used to augment the horizontal and vertical deficiencies [45]. The first step in this method is to harvest an appropriate block graft for the recipient site. There are several intraoral sites to harvest a block graft; however the ideal graft should be prepared after weighing the advantages and disadvantages. The lateral ramus of the mandible is a popular donor site and is used in most studies [46-48]. The cortical nature of this bone graft is the reason for its high resistance to resorption, although prolong neovascularization and the risk of damage to IAN are important disadvantages of this block graft [46, 49]. The other useful donor sites are maxillary tuberosity and chin. A retrospective study by Khojasteh et al. showed that the greatest vertical bone gain was in the defects where tuberosity was used as a block graft [46]. The simplicity of bone harvest and lower risk for nerve damage are other advantages of this donor site.

After preparing a block graft it must be adapted to the recipient site and fixed properly with a gap from the surface of the defect (Figure 17A). Then bone materials are used to fill the gaps (Figure 17B).

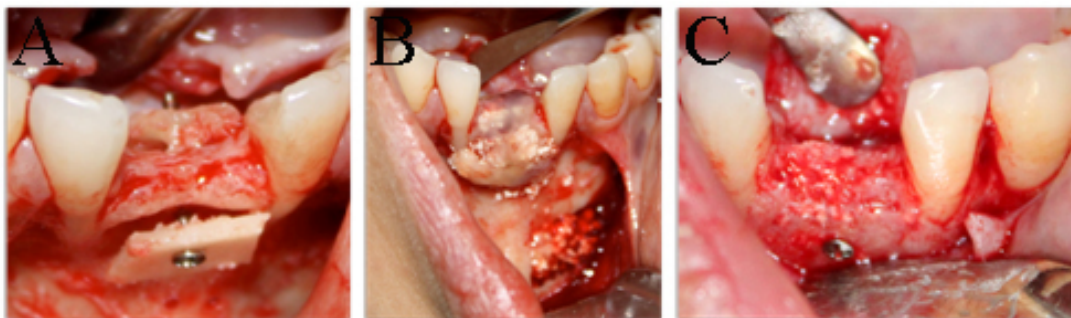


Figure 17. A, An anterior mandible defect after retracting the soft tissue flap. Lateral ramus bone block is harvested as a block graft and fixed with micro-screws with a gap from the buccal surface. B, The gap between the bone graft and alveolar bone is filled with bone materials. C, The defect has filled with new generated bone after 20 weeks.

The bone substitute could also be used to cover the bone block. With this technique we anticipate the bone resorption and prevent this complication by tenting the periosteum [50]. Then a membrane is used to cover the site. The soft tissue flap is sutured last (Figure 18).

Indications. This technique is most useful in horizontal defects of the anterior maxilla. After extracting the maxillary incisors a saucer-shaped defect may present in the premaxilla. This kind of defect could be properly corrected with the tenting technique [46, 50]. This method is also applicable in atrophic posterior mandibles [45]. Three-dimensional reconstruction with this technique is possible in atrophic ridges [51].

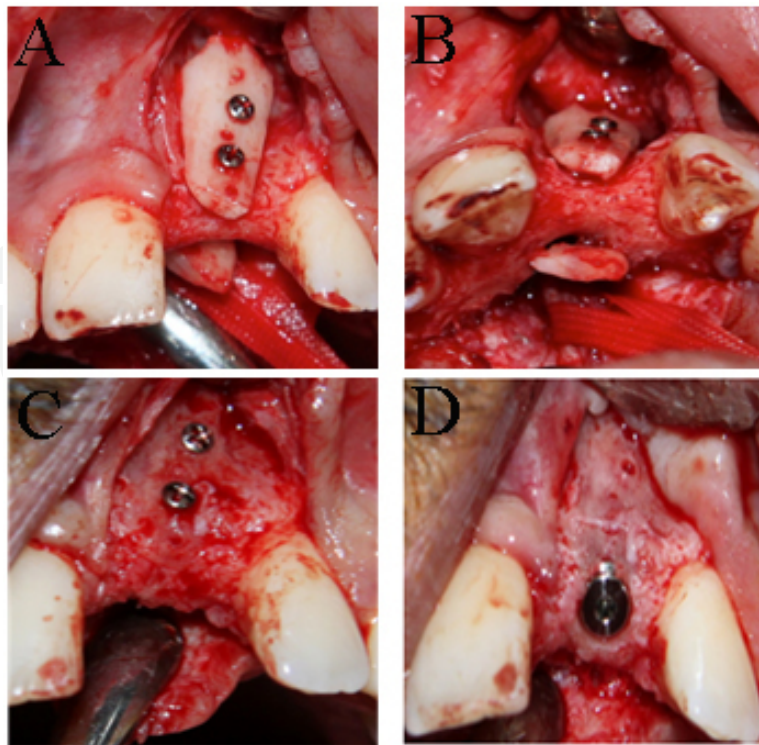


Figure 18. A, The defect of anterior maxilla is obvious after retracting the soft tissue flap. B, Lateral ramus bone block is harvested as a block graft and fixed with micro-screws. C, The surgical site is ready for implant surgery after 20 weeks. D, The deficiency is corrected and installation of the implant was performed without any problems.

Advantages. This technique decreases the patient's morbidity and is relatively simpler than other procedures. This procedure can be performed under local anesthesia. The bone particulates in the tenting technique promote the vascularization in the graft and improve bone regeneration and remodeling [52].

Disadvantages. The tenting technique is not suitable in most combined horizontal and vertical defects. This method is not suitable for large defects resulting from severe trauma or resection of pathologic lesions. Complications including hematoma and nerve damage due to bone harvesting from chin and lateral of mandibular ramus respectively are some other disadvantages of this procedure. Inflammation, infection, graft exposure, and graft failure are other complications mentioned in the literature [46].

9.3. GBR in combination with onlay bone graft (OBG)

Reconstruction of combined defects with representation of both horizontal and vertical bone deficiencies requires specific consideration. Decision-making in rehabilitation of these kinds of defects involves the patient's preferences, defect size, and cost considerations [53]. Combination of GBR and OBG is an appropriate technique in reconstruction of small combined defects before implant surgery. By applying this procedure the surgeon is able to use longer and wider implants, increasing the surface area resulting in a higher survival rate. In this technique a block bone graft is harvested and fixed in the defect area usually for vertical

augmentation followed by using classic GBR procedure to restore the remaining defects (Figure 19).

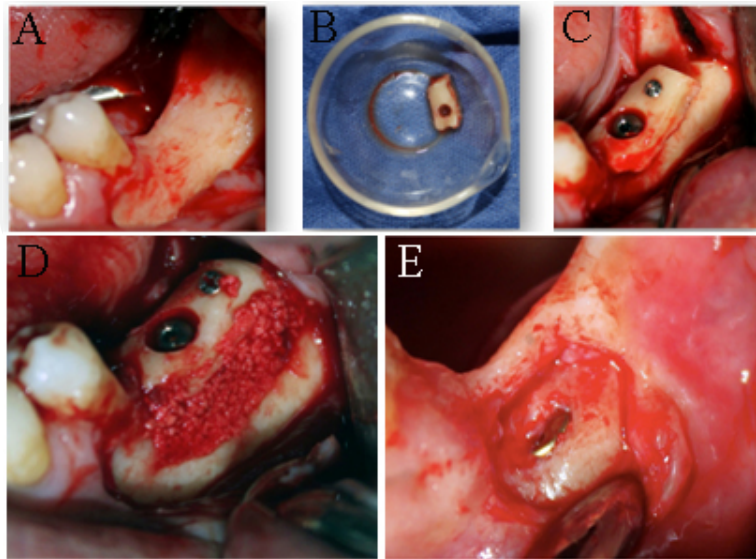


Figure 19. A, The atrophic ridge of posterior mandible is selected as the recipient site. B, Lateral ramus bone graft is harvested as an OBG. C, The OBG is fixed to augment the defect vertically. D, Bone materials are used to reconstruct the horizontal defect by GBR procedure. E, The surgical site is ready for insertion of implant fixtures.

Approximately after 6 months the surgical site is ready to install the implant fixtures. The average bone gain presented in the literature is 4.3 mm after performing this procedure [43].

Indications. This procedure is suitable for small to moderate defects in partial edentulous patients. This technique is usually indicated in combined defects to reconstruct horizontal and vertical defects. The common indication of this technique is in the anterior maxilla.

Advantages. This procedure can be performed under local anesthesia. This technique removes the need for harvesting extraoral bone grafts and reduces discomfort of the patient.

Disadvantages. This technique is not for large defects. The high failure rate of this technique in posterior of mandible is one of the major drawbacks of this technique [54].

10. Regenerative cell therapy

Although the autograft is accepted as the gold standard for the treatment of bone defects, some drawbacks of autogenous bone grafts such as limited graft accessibility, prolonged operation time and donor site morbidity as well as high costs, continue to drive the quest for development of alternative methods for bone regeneration and repair. Three new strategies are recently undergoing investigation:

Stem cell therapy; the transplantation of cultured osteogenic cells from host tissues like bone marrow.

Protein therapy; the application of osteoinductive growth factors in various reconstruction techniques.

Gene therapy; the transduction of genes encoding cytokines with osteogenic capacity into cells at the repair sites.

Bone engineering techniques consist of three main components: cell, growth factor, and carrier. Osteogenic cells are responsible for the generation of new bone. Without existing cells with osteogenic potential no new bone would be produced and no defect would be reconstructed. The proteins with osteoinductive potential known as growth factors are the second factor needed for reconstruction of defects. These growth factors are responsible for enhancement of new bone formation by affecting the cells which play a role in bone healing. The application of cultured cells or growth factors without any scaffold is almost impossible. Choosing the right scaffold for delivery of the cells and growth factors and acting as mesh for new bone formation is a significant issue in bone engineering.

11. Growth factors in bone regeneration

Protein therapy has demonstrated the most practical promise, mainly incorporating osteoinductive morphogens. Several osteoinductive cytokines have been suggested and investigated in the literature including bone morphogenetic proteins (BMPs), vascular endothelial growth factor (VEGF), platelet derived growth factor (PDGF), and transforming growth factor beta (TGF- β). Bone morphogenetic proteins have the most experimental and practical potential. Some studies however have shown the efficacy of other growth factors on bone reconstruction[55]. Synergic effects of two or more growth factors have been evaluated in some studies [56, 57].

Bone morphogenic proteins (BMPs). BMP is a large family of growth factors released naturally from different human tissues and acts in regenerating bone and cartilage tissue. The efficacy of BMP has been evaluated in several investigations [58-60]. After producing recombinant human BMP (rhBMP) the use of this cytokine became more popular in clinical studies. BMP can be applied in the surgical site by a carrier namely absorbable collagen sponge (ACS) or poly lactic glycolic acid (PLGA). The positive influence of BMP on bone regeneration in defects of the oral and maxillofacial area has been shown in most studies [55].

Platelet-derived growth factor (PDGF). PDGF promotes new bone formation. This facilitating bone regeneration factor is suggested to be used in maxillofacial defects where bone grafting is needed [61, 62]. PDGF improves the new bone formation by three main methods including mitogenesis, angiogenesis macrophage activation. The major role of PDGF is in differentiation of pre-osteoblasts to osteoblasts and proliferation of mesenchymal stem cells (MSCs). The usual carrier for PDGF has a mineral part in most investigations [55].

Vascular endothelial growth factor (VEGF). VEGF is an angiogenic factor which usually is released in response to hypoxia or tissue damage. VEGF has been used in different studies with both polymeric scaffolds and ceramic carriers [63, 64]. This growth factor is sometimes

applied in combination with other promoting factors like BMP and PDGF to improve its regenerative features [65-67]. Despite all the important roles of VEGF investigated and presented in the literature most studies showed that this growth factor is less inductive than BMP in bone regeneration [55].

Basic fibroblast growth factor (bFGF). bFGF is an important growth factor in wound healing, formation of granulation tissue and remodeling [68]. Several studies evaluated the effect of bFGF in bone regeneration; however its role is not as important as other factors like BMP [55].

Transforming growth factor beta (TGF- β). TGF- β is a group of proteins released from several tissues including macrophages and plays an important role in healing. The bone regenerative features of rhTGF- β 1, rhTGF- β 2, and TGF- β 3 have been evaluated in different investigations. The usual carrier for the delivery of this growth factor in these studies is a gelatinous matrix. Some of these researches have shown the positive influence of this growth factor in bone regeneration [55].

Indications. The most common usage of growth factors is in implant surgery. The defects created during the procedure or post-operative bone dehiscences may be corrected with the application of growth factors. **Advantages.** Growth factors are presented as an alternative for bone grafts in reconstruction of maxillofacial defects. These proteins reduce the morbidity of the patients by removing the need of harvesting bone grafts. These factors are responsible for the major events in regeneration including angiogenesis, cell differentiation, mitogenesis, and bone formation [69]. Furthermore the combination of these proteins with bone grafts promotes the generation of new bone and facilitates healing of the defects.

Disadvantages. The high costs of producing growth factors are the major limitations for using these materials in humans. Production of recombinant growth factors as rhBMP and rhPDGF requires a period of time and high costs [70]. Application of growth factors is very technique sensitive and the clinician should be an expert in this procedure. Choosing a slow releasing scaffold is still a challenge among surgeons to use with the growth factor as a carrier. The appropriate dosage and useful concentration of these proteins in bone regeneration is another controversial issue which should be resolved. The excess amount of growth factor or wrong application of them may lead to ectopic bone formation and result in insufficient correction of the deficiencies.

12. Carriers in bone regeneration

Biomaterial carriers are needed for delivery and sustained release of growth factors. The application of growth factors without a proper carrier is very hard and their handling is almost impossible. There is no universal carrier for this purpose. Several biomaterial carriers have been suggested to be effective in delivery of certain growth factors and accelerate bone formation. The osteoconductive ability of the scaffold should be considered in choosing the right carrier for the purpose. The advantages and disadvantages of usual growth factor carriers are presented in Table 1.

Biomaterial carrier	Preparation technique	Advantages	Disadvantages
PLGA	solvent casting/ particulate leaching	Control over porosity, pore sizes and Crystallinity; high porosity	Residual solvents; limited mechanical properties
ACS	Freeze drying method	Facilitates surgical implantation and retention of the growth factor at the treatment site; hemostasis	Low porosity and low mechanical strength
HA	Particle aggregated scaffold	High mechanical strength	Brittleness, low fracture strength, and high density
NBM	Production methods of cadavers' bone	High porosity and interconnectivity	Potential host reaction, limited supply, excessive resorption, and potential disease transmission
DBM	demineralization process on allogenic bone	High porosity	Limited particle sizes range
β -TCP	Ceramic-based injectable scaffold	Facilitate early revascularization And accelerate bone regeneration; serves as a rich source for calcium and phosphorus	Brittleness, low fracture strength, and high density

PLGA, Polylactic co-glycolic acid; ACS, Absorbable collagen sponge; HA, Hydroxyapatite; NBM, Natural bone matrix; DBM, Demineralized bone matrix; β -TCP, Beta tri-calcium phosphate.

Table 1. The pros and cons of most common scaffolds

13. Cell therapy

13.1. MSCs harvesting sources

Cell therapy is a new technique in reconstruction of bone deficiencies presented as an alternative for bone grafting. The self-renewal ability and the capability of differentiating to osteogenic cells have made the stem cells a popular source in regeneration of bone defects. Several tissues have been suggested as the source of stem cells including fat, umbilical cord blood, lung, liver, skin, periosteum, and skeletal muscle [71]. Recently dental pulp was used as a new origin for extracting stem cells for regenerative purposes [72]. The usual source of MSCs in each study and various models is different. According to the literature the most common origin to harvest the MSCs in rat models is human bone marrow-derived mesenchymal stem cells (hBMSCs) usually extracted from femur or tibia [73-75]. The most common source in harvesting MSCs to regenerate the bone defects in rabbit and dog models as well as human studies is the iliac bone [71]. By considering the reduced differentiation potential of MSCs harvested from bone marrow investigators have attempted to find new sources of MSCs. Birth associated tissues like umbilical cord and dental pulp as well as adipose tissue are new sources that have been found to contain MSCs [76].

13.2. MSCs culture and differentiation protocol

MSCs as a compartment of various cell populations are aspirated from the selected origin like the iliac crest or buccal fat pad. The aspirated cells are cultured in a medium with Dulbecco's modified Eagle's medium (DMEM) and fetal bovine serum (FBS) for 3 h in a 37 degrees 5% CO₂ incubator. Then the non-adherent cells are discarded after three hours and adherent cells are washed with phosphate-buffered saline (PBS) and fresh medium is replaced. The culture is treated with 0.5 ml of 0.25% trypsin containing 0.02% ethylene-diamine-tetra-acetic acid (EDTA) for 2 min at room temperature when the primary culture is confluent. A purified population of MSCs can be obtained 3 weeks after the initiation of culture [77]. The third generation of the cells is usually used in the studies (Figure 20) [78, 79]

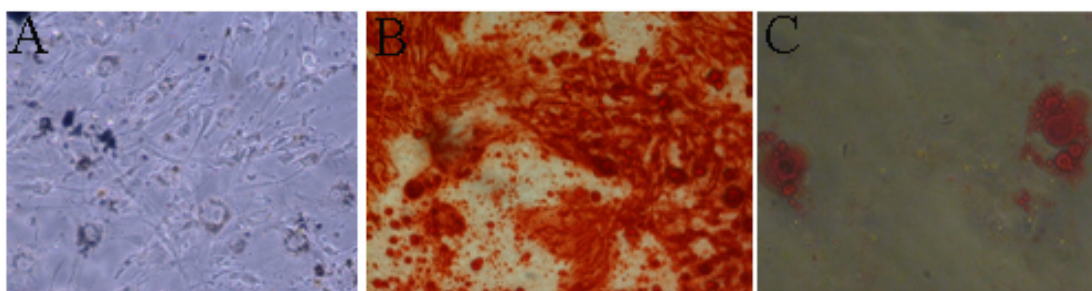


Figure 20. A, Proliferation of MSCs under light microscopy. B, Alizarin red staining for evaluating differentiation of MSCs to osteoprogenitor cells. Mineralization of the extracellular matrix is visualized by this staining technique. C, Oil red staining of MSCs, depicted adipogenic differentiation.

13.3. MSCs culture on scaffolds

Several investigations have evaluated the efficacy of stem cell regenerative ability on animals [78-82]. The stem cells should be implanted on an appropriate scaffold before delivery to the surgical site. According to the literature TCP is an efficient carrier for the stem cells to be loaded on and transplanted to the surgical site [71, 80, 81]. After preparation the choice carrier for reconstruction purpose it should be immersed into the medium impregnated with the MSCs. The MSCs should be implanted on the scaffold after 2 hours in 37°C. Scanning electron microscope (SEM) is a useful assay to evaluate the presence of MSCs on the scaffold (Figure 21). Tripoding adherence of MSCs on the scaffold can be assessed under SEM [78].

13.4. Current trends in MSCs application in bone regeneration

Presentation MSCs as a novel regenerative technique in reconstructing bone defects provoked lots of investigators to evaluate the efficacy of MSCs application in oral and maxillofacial areas. Omitting the need for bone harvesting from a donor site and reducing the patient morbidity by application of MSCs in bone reconstruction promises a bright future for researchers around the world. Comparing the application of MSCs in bone regeneration to the control groups which bone materials were used has shown the increase of new bone formation. Implantation of MSCs together with bone minerals improves the regeneration of bone defects by delivery

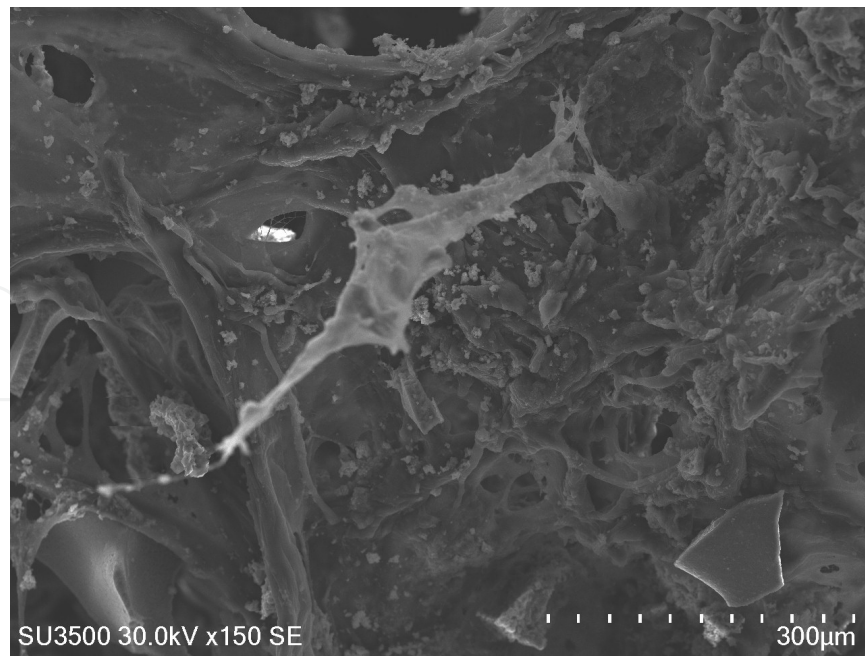

Figure 21. SEM Evaluation of MSCs (×50). SEM analysis shows lodging of the cells within the pores of the scaffold.

of the cells responsible for synthesizing new bone directly to the defect site [80]. Experimental studies on rat models have shown that the maximum bone formation was 2.53 mm in the β -TCP/MSC group 6 weeks after the surgery [79]. Histomorphometric analysis of the rabbit experiments at 6 and 12 weeks post-operation has demonstrated significantly higher bone formation in the group which MSCs were applied in combination with PRGF and nano-HA [78]. Histological analysis of rabbit models in other investigations demonstrated that the mean amount of vertical bone was higher in the MSCs group than the control group (2.09 mm versus 1.03 mm) after two months [82]. Choosing the appropriate scaffold for delivery of MSCs is important to gain the highest rate of new bone formation. The different studies on dog mandibles have indicated the importance of scaffolds on bone formation [61, 80, 81]. Jafarian et al. showed that six weeks after delivering dog BMSCs with biphasic scaffold (HA/TCP) or NBBM (Bio-Oss) in a through-and-through 10-mm mandibular defect, new bone formation was 65.78% and 50.31%, respectively [80]. Histomorphometric analysis in Khojasteh et al. study showed that after 8 weeks of the scaffold implantation (polycaprolactone-tricalcium phosphate (PCL-TCP)) higher amount of lamellar bone was generated more on the test side (48.63%) than control side (17.27%) [81]. Khojasteh et al. in another study applied MSCs with recombinant platelet derived growth factor (rh-PDGF) in mandibular defects in dogs; however the result showed only 21.52% new bone formation [61].

Nowadays the major concern about the application of MSCs in bone defect reconstruction is its effectiveness and delivery technique in human cases. Application of MSCs in sinus floor lifting in posterior atrophic maxilla has been assessed in human trials and reports. Several organic and inorganic materials have been suggested for sinus augmentation in the literature. MSCs seeded on an appropriate scaffold are new regenerative techniques advocated for this procedure. High mean percentage of new generated bone in these studies may indicate the

important inductive potential of MSCs [83]. Alveolar cleft of maxilla is another recipient site for applying MSCs instead of autografts to reduce morbidity. Some authors have shown successful results of using MSCs in alveolar clefts [84] whilst some others did not [85]. The amount of new bone formation may be insufficient for reconstruction of clefts; however it is usually enough for orthodontic tooth movements [85]. The combination of MSCs and a growth factor may increase their inductive and regenerative potential; however the results were not satisfactory yet [86].

Indications. Alveolar clefts are examples of the maxillofacial defects which cell therapy may be useful [85, 86]. Cell therapy is also indicated in augmentation of the sinus floor [83].

Advantages. It avoids the drawbacks of bone grafting like donor site morbidity. The stem cells are able to differentiate to different cell linings based on the combined growth factor. By extracting the cells from the own patient autologous transplantation is possible and no immune-suppressive therapy is necessary.

Disadvantages. Accessibility and the requirement for a large amount of cells are the main disadvantages of cell therapy as well as expenditure of time and money to provide the adequate cells for regeneration in large defects. The genetic damage occurrence of adult stem cells is a possibility in old patients. Embryonic stem cells have the risk of rejection and uncontrolled proliferation (turning into a teratoma).

14. Summary

Bone regeneration and anatomical bone reconstruction in defects of oral and maxillofacial region have been always a critical and controversial issue. There are lots of regenerative techniques suggested to be effective in oral and maxillofacial defects; however no one can absolutely choose the best efficient procedure. The quantity and quality of the regenerated bone is another aspect of defect reconstruction which should be highly considered. Although several regenerative procedures can be used in a certain defect, the regenerated bone may not be functional all the time.

Author details

Arash Khojasteh¹, Mohammad Esmaelinejad^{2*} and Farzad Aghdashi²

*Address all correspondence to: esmaelinejad@gmail.com

1 Department of Oral and Maxillofacial Surgery, Dental Faculty, Shahid Beheshti University of Medical Sciences, Tehran, Iran

2 Department of Oral and Maxillofacial Surgery, Dental Faculty, Shahid Beheshti University of Medical Sciences, Tehran, Iran

References

- [1] Jimi E, Hirata S, Osawa K, Terashita M, Kitamura C, Fukushima H. The current and future therapies of bone regeneration to repair bone defects. *Int J Dent*. 2012;2012:148261.
- [2] Dimitriou R, Jones E, McGonagle D, Giannoudis PV. Bone regeneration: current concepts and future directions. *BMC Med*. 2011;9:66.
- [3] Chen ST, Buser D. Clinical and esthetic outcomes of implants placed in postextraction sites. *Int J Oral Maxillofac Implants*. 2009;24 Suppl:186-217.
- [4] Trisi P, Rao W. Bone classification: clinical-histomorphometric comparison. *Clin Oral Implants Res*. 1999;10(1):1-7.
- [5] Hassani A, Khojasteh A, Alikhasi M. Repair of the perforated sinus membrane with buccal fat pad during sinus augmentation. *J Oral Implantol*. 2008;34(6):330-3.
- [6] Khojasteh A, Mohajerani H, Momen-Heravi F, Kazemi M, Alikhasi M. Sandwich bone graft covered with buccal fat pad in severely atrophied edentulous maxilla: a clinical report. *J Oral Implantol*. 2011;37(3):361-6.
- [7] Behnia H, Homayoun S, Qaranizade K, Morad G, Khojasteh A. Multidisciplinary reconstruction of a palatamaxillary defect with nonvascularized fibula bone graft and distraction osteogenesis. *J Craniofac Surg*. 2013;24(2):e186-90.
- [8] Khojasteh A, Morad G, Behnia H. Clinical importance of recipient site characteristics for vertical ridge augmentation: a systematic review of literature and proposal of a classification. *J Oral Implantol*. 2013;39(3):386-98.
- [9] Cawood JL, Howell RA. A classification of the edentulous jaws. *Int J Oral Maxillofac Surg*. 1988;17(4):232-6.
- [10] Seibert JS. Reconstruction of deformed, partially edentulous ridges, using full thickness onlay grafts. Part II. Prosthetic/periodontal interrelationships. *Compend Contin Educ Dent*. 1983;4(6):549-62.
- [11] Tinti C, Parma-Benfenati S, Polizzi G. Vertical ridge augmentation: what is the limit? *Int J Periodontics Restorative Dent*. 1996;16(3):220-9.
- [12] Wang HL, Al-Shammari K. HVC ridge deficiency classification: a therapeutically oriented classification. *Int J Periodontics Restorative Dent*. 2002;22(4):335-43.
- [13] Pikos MA. Mandibular block autografts for alveolar ridge augmentation. *Atlas Oral Maxillofac Surg Clin North Am*. 2005;13(2):91-107.
- [14] Neiva RF, Gapski R, Wang HL. Morphometric analysis of implant-related anatomy in Caucasian skulls. *J Periodontol*. 2004;75(8):1061-7.

- [15] Misch CM. Comparison of intraoral donor sites for onlay grafting prior to implant placement. *Int J Oral Maxillofac Implants*. 1997;12(6):767-76.
- [16] Pikos MA. Block autografts for localized ridge augmentation: Part I. The posterior maxilla. *Implant Dent*. 1999;8(3):279-85.
- [17] Pikos MA. Block autografts for localized ridge augmentation: Part II. The posterior mandible. *Implant Dent*. 2000;9(1):67-75.
- [18] Hassani A, Khojasteh A, Shamsabad AN. The anterior palate as a donor site in maxillofacial bone grafting: a quantitative anatomic study. *J Oral Maxillofac Surg*. 2005;63(8):1196-200.
- [19] Sekine J, Sano K, Ikeda H, Inokuchi T. Rehabilitation by means of osseointegrated implants in oral cancer patients with about four to six years follow-up. *J Oral Rehabil*. 2006;33(3):170-4.
- [20] Guven O. Rehabilitation of severely atrophied mandible using free iliac crest bone grafts and dental implants: report of two cases. *J Oral Implantol*. 2007;33(3):122-6.
- [21] Pogrel MA, Podlesh S, Anthony JP, Alexander J. A comparison of vascularized and nonvascularized bone grafts for reconstruction of mandibular continuity defects. *J Oral Maxillofac Surg*. 1997;55(11):1200-6.
- [22] Foster RD, Anthony JP, Sharma A, Pogrel MA. Vascularized bone flaps versus nonvascularized bone grafts for mandibular reconstruction: an outcome analysis of primary bony union and endosseous implant success. *Head Neck*. 1999;21(1):66-71.
- [23] Ahlmann E, Patzakis M, Roidis N, Shepherd L, Holtom P. Comparison of anterior and posterior iliac crest bone grafts in terms of harvest-site morbidity and functional outcomes. *J Bone Joint Surg Am*. 2002;84-a(5):716-20.
- [24] Bauer TW, Muschler GF. Bone graft materials. An overview of the basic science. *Clin Orthop Relat Res*. 2000(371):10-27.
- [25] Pensler J, McCarthy JG. The calvarial donor site: an anatomic study in cadavers. *Plast Reconstr Surg*. 1985;75(5):648-51.
- [26] Ko EC, Chang CM, Chang P, Kao CC, Chen KJ, Wu IF, et al. Tibial Cancellous Bone Grafting in Jaw Reconstruction: 10 Years of Experience in Taiwan. *Clin Implant Dent Relat Res*. 2013.
- [27] Saeed NR, van Eeden SP, Hensher R, Kent JN. Re: follow up of mandibular costochondral grafts after release of ankylosis of the temporomandibular joints. *Br J Oral Maxillofac Surg*. 2007;45(1):91.
- [28] Peltomaki T, Isotupa K. The costochondral graft: a solution or a source of facial asymmetry in growing children. A case report. *Proc Finn Dent Soc*. 1991;87(1):167-76.

- [29] Gapski R, Wang HL, Misch CE. Management of incision design in symphysis graft procedures: a review of the literature. *J Oral Implantol*. 2001;27(3):134-42.
- [30] Toscano N, Shumaker N, Holtzclaw D. The art of block grafting: a review of the surgical protocol for reconstruction of alveolar ridge deficiency. *J Implant Adv Clin Dent*. 2010;2:45-66.
- [31] Arrington ED, Smith WJ, Chambers HG, Bucknell AL, Davino NA. Complications of iliac crest bone graft harvesting. *Clin Orthop Relat Res*. 1996(329):300-9.
- [32] McCarthy JG, Schreiber J, Karp N, Thorne CH, Grayson BH. Lengthening the human mandible by gradual distraction. *Plast Reconstr Surg*. 1992;89(1):1-8; discussion 9-10.
- [33] Chopra S, Enepekides DJ. The role of distraction osteogenesis in mandibular reconstruction. *Curr Opin Otolaryngol Head Neck Surg*. 2007;15(4):197-201.
- [34] Kunkel M, Wahlmann U, Reichert TE, Wegener J, Wagner W. Reconstruction of mandibular defects following tumor ablation by vertical distraction osteogenesis using intraosseous distraction devices. *Clin Oral Implants Res*. 2005;16(1):89-97.
- [35] Scolozzi P. Distraction osteogenesis in the management of severe maxillary hypoplasia in cleft lip and palate patients. *J Craniofac Surg*. 2008;19(5):1199-214.
- [36] Nout E, Cesteley LL, van der Wal KG, van Adrichem LN, Mathijssen IM, Wolvius EB. Advancement of the midface, from conventional Le Fort III osteotomy to Le Fort III distraction: review of the literature. *Int J Oral Maxillofac Surg*. 2008;37(9):781-9.
- [37] Saltaji H, Altalibi M, Major MP, Al-Nuaimi MH, Tabbaa S, Major PW, et al. Le Fort III distraction osteogenesis versus conventional Le Fort III osteotomy in correction of syndromic midfacial hypoplasia: a systematic review. *J Oral Maxillofac Surg*. 2014;72(5):959-72.
- [38] Luna AH, Passeri LA, de Moraes M, Moreira RW. Endosseous implant placement in conjunction with inferior alveolar nerve transposition: a report of an unusual complication and surgical management. *Int J Oral Maxillofac Implants*. 2008;23(1):133-6.
- [39] Gasparini G, Boniello R, Saponaro G. Long term follow-up in inferior alveolar nerve transposition: our experience. 2014;2014:170602.
- [40] Yaghmaei M, Mashhadiabbas F, Shahabi S, Zafarbakhsh A, Yaghmaei S, Khojasteh A. Histologic evaluation of inferior alveolar lymphatics: an anatomic study. *Oral Surg Oral Med Oral Pathol Oral Radiol Endod*. 2011;112(5):564-7.
- [41] Babbush CA. Transpositioning and repositioning the inferior alveolar and mental nerves in conjunction with endosteal implant reconstruction. *Periodontology* 2000. 1998;17(1):183-90.
- [42] Misch C. *Implantes dentais contemporâneos*: Elsevier Brasil; 2011.

- [43] Milinkovic I, Cordaro L. Are there specific indications for the different alveolar bone augmentation procedures for implant placement? A systematic review. *Int J Oral Maxillofac Surg.* 2014;43(5):606-25.
- [44] Linde A, Alberius P, Dahlin C, Bjurström K, Sundin Y. Osteopromotion: a soft-tissue exclusion principle using a membrane for bone healing and bone neogenesis. *J Periodontol.* 1993;64(11 Suppl):1116-28.
- [45] Morad G, Khojasteh A. Cortical tenting technique versus onlay layered technique for vertical augmentation of atrophic posterior mandibles: a split-mouth pilot study. *Implant Dent.* 2013;22(6):566-71.
- [46] Khojasteh A, Behnia H, Shayesteh YS, Morad G, Alikhasi M. Localized bone augmentation with cortical bone blocks tented over different particulate bone substitutes: a retrospective study. *Int J Oral Maxillofac Implants.* 2012;27(6):1481-93.
- [47] Rocuzzo M, Ramieri G, Bunino M, Berrone S. Autogenous bone graft alone or associated with titanium mesh for vertical alveolar ridge augmentation: a controlled clinical trial. *Clin Oral Implants Res.* 2007;18(3):286-94.
- [48] Rocuzzo M, Ramieri G, Spada MC, Bianchi SD, Berrone S. Vertical alveolar ridge augmentation by means of a titanium mesh and autogenous bone grafts. *Clin Oral Implants Res.* 2004;15(1):73-81.
- [49] Hwang KG, Shim KS, Yang SM, Park CJ. Partial-thickness cortical bone graft from the mandibular ramus: a non-invasive harvesting technique. *J Periodontol.* 2008;79(5):941-4.
- [50] Le B, Burstein J, Sedghizadeh PP. Cortical tenting grafting technique in the severely atrophic alveolar ridge for implant site preparation. *Implant Dent.* 2008;17(1):40-50.
- [51] Khoury F, Khoury C. Mandibular bone block grafts: diagnosis, instrumentation, harvesting techniques and surgical procedures. *Bone Augmentation in Oral Implantology* New Malden, United Kingdom: Quintessence publishing Co, Ltd. 2007:169-83.
- [52] Louis PJ, Gutta R, Said-Al-Naief N, Bartolucci AA. Reconstruction of the maxilla and mandible with particulate bone graft and titanium mesh for implant placement. *J Oral Maxillofac Surg.* 2008;66(2):235-45.
- [53] Pommer B, Zechner W, Watzek G, Palmer R. To graft or not to graft? Evidence-based guide to decision making in oral bone graft surgery. *Bone Grafting.* 2012:1-25.
- [54] Nissan J, Ghelfan O, Mardinger O, Calderon S, Chaushu G. Efficacy of cancellous block allograft augmentation prior to implant placement in the posterior atrophic mandible. *Clin Implant Dent Relat Res.* 2011;13(4):279-85.
- [55] Khojasteh A, Behnia H, Naghdi N, Esmaeelinejad M, Alikhassy Z, Stevens M. Effects of different growth factors and carriers on bone regeneration: a systematic review. *Oral Surg Oral Med Oral Pathol Oral Radiol.* 2013;116(6):e405-23.

- [56] Kanczler JM, Ginty PJ, White L, Clarke NM, Howdle SM, Shakesheff KM, et al. The effect of the delivery of vascular endothelial growth factor and bone morphogenetic protein-2 to osteoprogenitor cell populations on bone formation. *Biomaterials*. 2010;31(6):1242-50.
- [57] Young S, Patel ZS, Kretlow JD, Murphy MB, Mountziaris PM, Baggett LS, et al. Dose effect of dual delivery of vascular endothelial growth factor and bone morphogenetic protein-2 on bone regeneration in a rat critical-size defect model. *Tissue Eng Part A*. 2009;15(9):2347-62.
- [58] Carstens MH, Chin M, Li XJ. In situ osteogenesis: regeneration of 10-cm mandibular defect in porcine model using recombinant human bone morphogenetic protein-2 (rhBMP-2) and Helistat absorbable collagen sponge. *J Craniofac Surg*. 2005;16(6):1033-42.
- [59] Jovanovic SA, Hunt DR, Bernard GW, Spiekermann H, Wozney JM, Wikesjo UM. Bone reconstruction following implantation of rhBMP-2 and guided bone regeneration in canine alveolar ridge defects. *Clin Oral Implants Res*. 2007;18(2):224-30.
- [60] Wikesjo UM, Qahash M, Thomson RC, Cook AD, Rohrer MD, Wozney JM, et al. rhBMP-2 significantly enhances guided bone regeneration. *Clin Oral Implants Res*. 2004;15(2):194-204.
- [61] Khojasteh A, Dashti SG, Dehghan MM, Behnia H, Abbasnia P, Morad G. The osteoregenerative effects of platelet-derived growth factor BB cotransplanted with mesenchymal stem cells, loaded on freeze-dried mineral bone block: A pilot study in dog mandible. *J Biomed Mater Res B Appl Biomater*. 2014.
- [62] Schwarz F, Ferrari D, Podolsky L, Mihatovic I, Becker J. Initial pattern of angiogenesis and bone formation following lateral ridge augmentation using rhPDGF and guided bone regeneration: an immunohistochemical study in dogs. *Clin Oral Implants Res*. 2010;21(1):90-9.
- [63] Yonamine Y, Matsuyama T, Sonomura T, Takeuchi H, Furuichi Y, Uemura M, et al. Effectable application of vascular endothelial growth factor to critical sized rat calvaria defects. *Oral Surg Oral Med Oral Pathol Oral Radiol Endod*. 2010;109(2):225-31.
- [64] Wernike E, Montjovent MO, Liu Y, Wismeijer D, Hunziker EB, Siebenrock KA, et al. VEGF incorporated into calcium phosphate ceramics promotes vascularisation and bone formation in vivo. *Eur Cell Mater*. 2010;19:30-40.
- [65] De la Riva B, Sanchez E, Hernandez A, Reyes R, Tamimi F, Lopez-Cabarcos E, et al. Local controlled release of VEGF and PDGF from a combined brushite-chitosan system enhances bone regeneration. *J Control Release*. 2010;143(1):45-52.
- [66] Luo T, Zhang W, Shi B, Cheng X, Zhang Y. Enhanced bone regeneration around dental implant with bone morphogenetic protein 2 gene and vascular endothelial growth factor protein delivery. *Clin Oral Implants Res*. 2012;23(4):467-73.

- [67] Samee M, Kasugai S, Kondo H, Ohya K, Shimokawa H, Kuroda S. Bone morphogenetic protein-2 (BMP-2) and vascular endothelial growth factor (VEGF) transfection to human periosteal cells enhances osteoblast differentiation and bone formation. *J Pharmacol Sci.* 2008;108(1):18-31.
- [68] Esmaeelinejad M, Bayat M. Effect of low-level laser therapy on the release of interleukin-6 and basic fibroblast growth factor from cultured human skin fibroblasts in normal and high glucose mediums. *J Cosmet Laser Ther.* 2013;15(6):310-7.
- [69] Lee K, Silva EA, Mooney DJ. Growth factor delivery-based tissue engineering: general approaches and a review of recent developments. *J R Soc Interface.* 2011;8(55):153-70.
- [70] Demain AL, Vaishnav P. Production of recombinant proteins by microbes and higher organisms. *Biotechnology Advances.* 2009;27(3):297-306.
- [71] Khojasteh A, Behnia H, Dashti SG, Stevens M. Current trends in mesenchymal stem cell application in bone augmentation: a review of the literature. *J Oral Maxillofac Surg.* 2012;70(4):972-82.
- [72] Morad G, Kheiri L, Khojasteh A. Dental pulp stem cells for in vivo bone regeneration: a systematic review of literature. *Arch Oral Biol.* 2013;58(12):1818-27.
- [73] Akita S, Fukui M, Nakagawa H, Fujii T, Akino K. Cranial bone defect healing is accelerated by mesenchymal stem cells induced by coadministration of bone morphogenetic protein-2 and basic fibroblast growth factor. *Wound Repair Regen.* 2004;12(2):252-9.
- [74] Kim J, Kim IS, Cho TH, Lee KB, Hwang SJ, Tae G, et al. Bone regeneration using hyaluronic acid-based hydrogel with bone morphogenic protein-2 and human mesenchymal stem cells. *Biomaterials.* 2007;28(10):1830-7.
- [75] Yoon E, Dhar S, Chun DE, Gharibjanian NA, Evans GR. In vivo osteogenic potential of human adipose-derived stem cells/poly lactide-co-glycolic acid constructs for bone regeneration in a rat critical-sized calvarial defect model. *Tissue Eng.* 2007;13(3):619-27.
- [76] Zomorodian E, Baghaban Eslaminejad M. Mesenchymal stem cells as a potent cell source for bone regeneration. *Stem Cells Int.* 2012;2012:980353.
- [77] Grassel S, Stockl S, Jenei-Lanzl Z. Isolation, culture, and osteogenic/chondrogenic differentiation of bone marrow-derived mesenchymal stem cells. *Methods Mol Biol.* 2012;879:203-67.
- [78] Behnia H, Khojasteh A, Kiani MT, Khoshzaban A, Mashhadi Abbas F, Bashtar M, et al. Bone regeneration with a combination of nanocrystalline hydroxyapatite silica gel, platelet-rich growth factor, and mesenchymal stem cells: a histologic study in rabbit calvaria. *Oral Surg Oral Med Oral Pathol Oral Radiol.* 2013;115(2):e7-15.

- [79] Khojasteh A, Eslaminejad MB, Nazarian H. Mesenchymal stem cells enhance bone regeneration in rat calvarial critical size defects more than platelet-rich plasma. *Oral Surg Oral Med Oral Pathol Oral Radiol Endod.* 2008;106(3):356-62; discussion 63.
- [80] Jafarian M, Eslaminejad MB, Khojasteh A, Mashhadi Abbas F, Dehghan MM, Hassanzadeh R, et al. Marrow-derived mesenchymal stem cells-directed bone regeneration in the dog mandible: a comparison between biphasic calcium phosphate and natural bone mineral. *Oral Surg Oral Med Oral Pathol Oral Radiol Endod.* 2008;105(5):e14-24.
- [81] Khojasteh A, Behnia H, Hosseini FS, Dehghan MM, Abbasnia P, Abbas FM. The effect of PCL-TCP scaffold loaded with mesenchymal stem cells on vertical bone augmentation in dog mandible: a preliminary report. *J Biomed Mater Res B Appl Biomater.* 2013;101(5):848-54.
- [82] Khojasteh A, Eslaminejad MB, Nazarian H, Morad G, Dashti SG, Behnia H, et al. Vertical bone augmentation with simultaneous implant placement using particulate mineralized bone and mesenchymal stem cells: a preliminary study in rabbit. *J Oral Implantol.* 2013;39(1):3-13.
- [83] Shayesteh YS, Khojasteh A, Soleimani M, Alikhasi M, Khoshzaban A, Ahmadbeigi N. Sinus augmentation using human mesenchymal stem cells loaded into a beta-tricalcium phosphate/hydroxyapatite scaffold. *Oral Surg Oral Med Oral Pathol Oral Radiol Endod.* 2008;106(2):203-9.
- [84] Pradel W, Tausche E, Gollogly J, Lauer G. Spontaneous tooth eruption after alveolar cleft osteoplasty using tissue-engineered bone: a case report. *Oral Surg Oral Med Oral Pathol Oral Radiol Endod.* 2008;105(4):440-4.
- [85] Behnia H, Khojasteh A, Soleimani M, Tehranchi A, Khoshzaban A, Keshel SH, et al. Secondary repair of alveolar clefts using human mesenchymal stem cells. *Oral Surg Oral Med Oral Pathol Oral Radiol Endod.* 2009;108(2):e1-6.
- [86] Behnia H, Khojasteh A, Soleimani M, Tehranchi A, Atashi A. Repair of alveolar cleft defect with mesenchymal stem cells and platelet derived growth factors: a preliminary report. *J Craniomaxillofac Surg.* 2012;40(1):2-7.

