

# We are IntechOpen, the world's leading publisher of Open Access books Built by scientists, for scientists

6,900

Open access books available

186,000

International authors and editors

200M

Downloads

Our authors are among the

154

Countries delivered to

TOP 1%

most cited scientists

12.2%

Contributors from top 500 universities



WEB OF SCIENCE™

Selection of our books indexed in the Book Citation Index  
in Web of Science™ Core Collection (BKCI)

Interested in publishing with us?  
Contact [book.department@intechopen.com](mailto:book.department@intechopen.com)

Numbers displayed above are based on latest data collected.  
For more information visit [www.intechopen.com](http://www.intechopen.com)



---

# Miniscrew Applications in Orthodontics

---

Fatma Deniz Uzuner and Belma Işık Aslan

Additional information is available at the end of the chapter

<http://dx.doi.org/10.5772/59879>

---

## 1. Introduction

Anchorage control during tooth movement is one of the main factors for ensuring successful orthodontic treatment. Anchorage can be defined as the resistance that a tooth or a group of teeth offer when they are subjected to a force [1]. The aim of orthodontic treatment is to maintain sufficient anchorage control to create appropriate force systems that provide the desired treatment effects.

Recently, implants have been used as skeletal anchorage devices for orthodontic purposes [2-5]. Temporary anchorage devices (TADs) [1,9,10], including miniplates, implants and miniscrews, have been used for skeletal anchorage [6-8]. TADs are inserted into the bone and aim to enhance orthodontic anchorage either by supporting the anchoring teeth or by being an independent anchorage unit eliminating the need for supporting teeth; they are removed once their function has been completed. They can be fixed into the bone either biomechanically (osseointegration) [11] or mechanically (cortical stabilization) [8]. Clinicians can better control anchorage by using TADs in orthodontic treatment, thereby achieving more satisfactory treatment results than could be achieved with conventional mechanics [6,12].

Currently, clinicians mostly prefer to use miniscrews for combined orthodontic treatment [13]. Despite the high success rate of miniplates, their invasive placement procedures require an oral surgeon and the associated high costs of such a procedure overshadow their use in terms of anchorage [1]. The use of osseointegrated mini-implants has also been limited because of the long waiting period for osseointegration, their large size and high cost [14,15]. Miniscrews, however, are available in favorable sizes, have relatively lower costs and are simple to insert and remove; therefore, they can be easily placed by an orthodontist with minimal tissue invasion [13]. Miniscrews obtain their stability mainly from mechanical retention in the bone [1,9], so they can be loaded immediately after placement [16]. In the literature, there is no general agreement about the terminology used [17,18]; this varies between 'miniscrews',

'microscrews', 'miniscrew implants' and 'mini-implants' [13,19-21]. In this chapter, we refer to them as miniscrews. Miniscrews are now accepted as a simple and effective tool in daily orthodontic practice and orthodontists commonly use them in a variety of clinical situations [20-25].

This chapter focuses on the principles of application for miniscrews including screw sizes, application sites and fundamental placement methods. Management of complications, the use of miniscrews in specific orthodontic situations and appliance design are also discussed.

## 2. General considerations

### 2.1. Location and dimensions of the miniscrew

The stability of miniscrews immediately following their placement (primary stability) and during orthodontic treatment is important for clinicians in terms of achieving their desired treatment results. The primary factors for stability are the quality and quantity of the bone [26-28], as well as the thickness, type and health of the soft tissue [29].

Cortical bone with a thickness of less than 0.5 mm is not suitable for miniscrew placement. Higher success rates have been reported with cortical bone at least 1.0 mm thick [27].

To maximize stability, it is better to place miniscrews in the attached gingiva (keratinized gingiva), which is more resistant to inflammation and less likely to develop soft-tissue hypertrophy [26, 29]. However, if the miniscrew has to be placed in non-keratinized mucosa, a 3-mm vertical stab incision should be used to prevent the soft tissue from surrounding the miniscrew, as this small incision requires no sutures [1].

Placement site is another important factor in the success of miniscrews [30]. Miniscrews can be placed in the inter-radicular space between tooth roots, either buccally or lingually; in the hard palate (midpalatal/parapalatal region); below the anterior nasal spine; and in the infrazygomatic crest, maxillary tuberosity, edentulous areas, chin and retromolar areas [8,30].

Conflicting reports exist regarding success rates for miniscrews in the mandible and maxilla. Park et al. [31], found that the maxilla had a higher success rate than the mandible, while others [16, 30] reported that placement of the miniscrews in the maxilla or mandible was not associated with the success rate. Moon et al. [30] found that the area between the first and second premolars in the maxilla and mandible of both young and adult patients had the highest success rate.

In the maxilla, the buccal and palatal aspects of the posterior region have been defined as safe areas for miniscrew placement, while the maxillary tuberosity is not suitable because of the minimal bone thickness in the area [32]. Ishii et al. [33], and Poggio [32] reported that the safest region for placement is the inter-alveolar septum between the maxillary first molar and second premolar, 6–8 mm apical to the alveolar crest on the palatal side. The inter-radicular distance is greater on the palatal side; however, the thickness of the palatal mucosa renders this region less favorable. This problem could be alleviated by using a miniscrew with a longer head.

However, the midpalatal suture region is the most favorable placement site for miniscrews in terms of both bone and soft-tissue characteristics. This region, with its high density of cortical bone and thin keratinized soft tissue ensures the biomechanical stability of the miniscrews [23,34] and has been shown to have a higher success rate (90%) than the parapatatal suture region (84%) [35]. However, the parapatatal area is the most suitable region for miniscrew placement in adolescents for preventing developmental disturbances of the midpalatal suture, as the transverse growth of the midpalatal suture continues up until the late teens [36].

In the mandible, the safest region is either between the second premolar and first molar, or between the first and second molars, owing to the adequate bone thickness [22,32]. The thinnest bone was found between the first premolar and the canine. If a miniscrew has to be implanted into this region, it should be placed 11 mm below the alveolar crest [32]. Although the area between the second premolar and the first molar has thicker cortical bone than the area between the first and second premolars in the mandible, the success rate in this area is significantly lower [30]. These results suggest that other factors beyond bone quality, such as soft-tissue thickness [37], oral hygiene [38] and root proximity [39,40] might also affect the success rate of miniscrews.

Miniscrews are available in a variety of materials, shapes, head designs, length and diameter, being 5–12 mm long and having a diameter from 1.2 to 2.3 mm [6,11,20,41–43]. In general, 1.2–1.6 mm miniscrews are used. Because of its low success rate, the 1.0-mm diameter miniscrew is not suitable for clinical use [16]. However, the 1.2-, 1.3- and 1.5-mm diameter miniscrews have had similar or higher success rates than the 1.6-mm miniscrew [16,38]. The design of the miniscrew also affects primary stability, with a conical thread design achieving superior primary stability when compared with a cylindrical design [42].

Selection of the correct diameter and length depends on the region in which the miniscrew will be placed. If it is placed in the inter-radicular region, a miniscrew with a smaller diameter will be preferred, as it will decrease the risk of root damage [30]. The recommended diameter is 1.3 mm in the maxilla, 1.4 mm in the mandible and 1.5 or 1.6 mm in the midpalatal area [12].

Determining the length of the miniscrew primarily depends on the quality of the bone, the screw angulation, the soft-tissue thickness and the adjacent anatomic structures [8,38,44]. In regions with adequate cortical density, small miniscrews are preferred, while longer miniscrews are preferred if stability is required in trabecular bone.

The screw should be embedded into the bone at least 5–6 mm [45,46], yet deeper placements have been recommended when bone quality is low [47,48]. Minimal depth of placement is at least 6 mm for the maxilla and 4 mm for the mandible [12]. In maxillary buccal alveolar bone, 7–8 mm miniscrews are recommended, while 5–6 mm long miniscrews are suitable in the mandibular buccal bone [12]. Short screws can become dislodged when they are placed in the palatal region owing to the thick palatal soft tissue [44,49]. Long miniscrews (10–12 mm) are preferred in the palatal region to compensate for the thick palatal soft tissue and to keep 6-mm miniscrews embedded in the bone [48,49]. Because the midpalatal region has dense cortical bone, a long miniscrew may not be needed for stability.

## 2.2. Placement of the miniscrew

Before placing the miniscrews, clinicians should radiographically assess their position relative to the roots. Panoramic or periapical radiographs, however, may not provide adequate information for optimizing the placement of a miniscrew. Computed tomography (CT) or cone-beam CT can allow clinicians to make an accurate and reliable evaluation of bone thickness and the adjacent anatomic structures, and therefore improves the success rate and ensures safe placement of the screws [33,50,51].

The patient is instructed to rinse with a chlorhexidine solution; then, infiltrative anesthesia is applied. Light local anesthesia is preferred so that the nerve fibers in the periodontal ligament remain sensitive [12], and the patient is aware if the miniscrew touches the root of the tooth, allowing the clinician to change the insertion direction.

There are two different placement methods: self-tapping and self-drilling.

*Self-tapping method:* Before placing the miniscrew, a hole is drilled in the cortical bone and a miniscrew is screwed through this hole with a hand driver. The diameter of the pilot drill should be slightly smaller (0.2–0.3 mm) than the inner (or core) diameter of the miniscrew [46]. Care must be taken to keep the axis of the drill stable so as not to enlarge the hole. To reduce heat generation while drilling, clinicians should not apply too much pressure and should irrigate the bone with coolants [52,53].

*Self-drilling method:* Self-drilling is a simpler method for placing the miniscrew than self-tapping. The miniscrew is inserted into the bone without drilling and screwed in with the hand driver [12] or motor driver [54]. Using a motor driver is helpful for gaining a higher placement success rate [54]. Self-drilling screws are reported to have better stability, with more bone to metal contact than self-tapping screws [55,56].

An incision may be made in the soft tissue before drilling [54,57]. Miyawaki et al. [16], reported that the flapless (non-incision) group had a higher success rate than the flap surgery (incision) group. By contrast, Moon et al. [30], found no difference between non-incision and incision groups in their study.

Generally, miniscrews are inserted in the buccal or lingual cortical plates; this is defined as monocortical placement. Occasionally, the miniscrew can be placed across the entire width of the alveolus (bicortical placement). Although bicortical placement provides superior force resistance and stability compared with monocortical placement, more care has to be taken during placement. Bicortical placement may be preferred when increased orthodontic loading is needed or in cases where there is insufficient cortical bone thickness [58–60].

It is usually recommended that miniscrews are placed perpendicular (at an angle of 90°) to the bone surface [45]. However, this might not always be clinically achievable, and an angular approach might be needed. If the buccal alveolar bone volume is sufficient relative to the long axis of the teeth, the miniscrew can be placed at an angle of 30–40° for the upper jaw and 20–60° for the lower jaw [12]. This angular placement minimizes root contact, as there is relatively more space [50] and the surface area of cortical bone in contact with the miniscrew is increased, allowing placement of longer miniscrews and improved stability [12]. When placing a



miniscrew at an angle into dense cortical bone using the self-drilling method, clinicians can damage the cortical bone; in such cases, the self-tapping method would be a better option [12].

Clinicians should apply slow and gentle force during insertion to avoid fracture of the miniscrew. The recommended insertion torque value is 5–10 N cm [61]. Insertion torque values are associated with the success of the procedure. The success rate of the miniscrew also depends on the clinician's experience and the type of the placement: whether self-tapping or self-drilling. If the self-tapping method is used, the following factors also affect the success rate: flap or flapless surgery, sterilization, pilot hole preparation depth and diameter, cooling technique, drill speed and pressure, direction of placement and placement procedure (steady or wiggling) [6,8,16,18,27,30,43,47].

The stability of the miniscrew should be checked after placement. If any mobility is detected, the implant needs to be removed. If primary stability is not achieved upon insertion, the miniscrew implant may loosen during orthodontic treatment [26].

Patients should be informed that they might have pain for 1–2 days and that they can take anti-inflammatory agents if required. Most patients do not have noticeable discomfort or inflammation. Patients need to be instructed in oral hygiene techniques [35] and should be advised that they can brush their teeth as usual. A compressed water spray such as Waterpik [12] and daily use of mouth rinses will be useful. Caution should be taken not to apply excessive force to the miniscrew while brushing and during mastication.

### **2.3. Timing of loading, force magnitude and direction**

The timing of loading depends largely on the miniscrew type [62–65]. For osseointegrated miniscrews, loading can commence 2–3 months after placement. Miyawaki et al. [16], observed no significant difference between loading at 1–2 months and at 3 months after placement. However, miniscrews that do not require osseointegration are often used, and they can be loaded immediately [61].

The maximum force-load that a miniscrew can withstand remains controversial [66]. Dalstra et al. [67], recommended 50 g of immediate loaded force for miniscrews placed into thin cortical bone and fine trabeculae. Many studies have reported miniscrew stability with loading forces of 300 g or less [68,69]. In their study, Buchter et al. [69], evaluated the transverse loading of miniscrews placed in dense mandibular bone and reported that immediate loads of up to 900 centinewtons per millimetre [cN/mm] remained clinically stable. Kim et al. [70], investigated whether the specific directions of the force vectors were associated with the stability of miniscrews. The results indicated that miniscrews were fixed evenly in three dimensions and were not more resistant to any particular direction of load. Park [12] recommends loading immediately after placement and keeping the force minimal (< 70 g) until 2 months after placement, and then increasing the force up to 150–200 g.

Cortical thickness, miniscrew characteristics, force magnitude, direction and loading period are reported to be factors related to miniscrew stability [16,64–66,71]. However, one study found that the duration of loading did not influence the success rate of the miniscrews [70]. To prevent the miniscrew from loosening, the moments created during force application that

may tend to unscrew the miniscrew have to be taken into consideration. To control these moments, clinicians have to carefully evaluate the force system applied to the miniscrew. If the application of such undesirable moments to the screw cannot be avoided, indirect anchorage is recommended [1,8].

Although the miniscrews may initially be stable, they may not remain stationary when subjected to orthodontic forces [72,73]. Liou et al. [72], placed miniscrews in the zygomatic buttress for direct anchorage and reported that when the screw was subjected to orthodontic force, extrusion and 0.4-mm tipping were observed at the level of the head of the screw. Liu et al. [73], evaluated the displacement of miniscrews placed in inter-radicular areas of the maxilla as anchorage for the en masse retraction of anterior teeth using three-dimensional CT registration evaluations. The researchers observed that both the molars and the miniscrews were displaced in the direction of force application and drifted mesially, but not by the same amount. The molars drifted mesially 0.91 mm and the miniscrews moved 0.23 mm on average. This result implied that the miniscrews might have come into contact with the roots following treatment. The different mesial-drift ratios of the molars and the miniscrews may be a critical factor in the loosening of miniscrews [74]. As a precaution, the researchers [73] advised placing the miniscrews mesially for long-term stability.

The conventional periodontal pressure–tension theory cannot explain the miniscrew displacement process. The Frost mechanostat theory instead identifies complex bone biomechanics [75,76]. The bone remodelling process at the bone–screw interface and the mechanism of screw displacement are correlated to the stress–strain field in the surrounding bone as a result of dynamic loading [77,78].

### 3. Complications

Complications may be related to factors such as the clinician, the patient and the miniscrews themselves [79].

*Clinician-related complications:* Clinicians' skills and experience are critical to the success rate of the procedure [70]. Once clinicians become accustomed to using miniscrews, their success rates increase [12]. Operators need to develop their skills to avoid damaging adjacent anatomical structures and the root of the tooth while placing the miniscrew.

*Patient-related complications:* These result from factors such as systemic diseases, periodontal disease, osteoporosis, drugs, pharmacologic prescriptions such as bisphosphonates, poor oral hygiene, smoking and cortical thickness of the bone [31,63,80–82], all of which can affect the stability of the miniscrew. It may be better not to use miniscrews for patients with adverse risk factors; however, if miniscrews have to be used, longer healing periods should be allowed and specific loading protocols should be applied [81,82]. It is notable that in their animal study, Park et al. [83], found that the presence of diabetes and variation in the placement system (self-drilling or self-tapping) did not affect the initial stability of orthodontic mini-implants.

*Miniscrew-related complications:* Anticipated complications with miniscrews include [6,72,79]:

1. Pain and discomfort, irritation to tongue or cheek
2. Inflammation around miniscrews
3. Soft-tissue impingement
4. Damage to surrounding anatomical structures
5. Root injury
6. Miniscrew mobility or failure
7. Fracture of miniscrews

1. Pain and discomfort, irritation to tongue or cheek

Generally, patients do not experience pain and discomfort following miniscrew placement [6,16,58,35]. If pain is present, it may last 1–2 days [58,47]. Kuroda et al. [38], analyzed patients' pain duration and intensity during the first 2 weeks after placement. One hour after placement, 95% of patients reported pain in the group in which miniscrews were placed after raising a mucoperiosteal flap, whereas in the group who had undergone a flapless approach, only 50% of patients reported pain. After 2 weeks, the values were 10% and 0% for the respective techniques.

Cheek irritation was generally not observed when miniscrews were placed in the buccal alveolar bone; however, when placed in the palatal area, tongue irritation primarily occurred. Bonding resin or a periodontal wound dressing can be applied to the head of the miniscrew to smooth its surface and to minimize soft-tissue irritation [1,84].

2. Inflammation around miniscrews

Peri-implantitis is the most commonly observed complication, and is considered to be the major factor in implant failure [43]. The localization of the miniscrew, its relationship with the soft tissue and the hygiene habits of the patient are the main factors that affect inflammation [30]. Takaki et al. [35], reported that inflammation frequency depended on the degree of mucosal penetration and stated that chronic inflammation mostly occurred when miniscrews were placed in the anterior alveolar region of the maxilla. When the miniscrew was placed in the attached gingiva or in the palatal mucosa, less inflammation was observed [12]. By contrast, when miniscrews were placed in the oral mucosa, deep in the vestibule or near a frenulum, persistent inflammation occurred [29,31]. If miniscrews are placed 1 mm below the mucogingival junction, they do not produce serious inflammation. To prevent inflammation, the screws need to be thoroughly cleaned. Mild infections can be controlled by using antiseptic mouthwash and by brushing [35]. Taking a different view, Kim et al. [70], emphasized that unlike inflammation from poor oral hygiene, inflammation caused by mobile miniscrews was not controlled with improved oral hygiene. Therefore, inflammation or swelling around a miniscrew might be the result of it loosening, rather than the cause. When taking this view, primary stability becomes increasingly important.



### 3. Soft-tissue impingement

In conditions where the miniscrew is placed deep in the vestibule, into the free gingiva or the retromolar area, the head of the miniscrews may become embedded in the overgrowth of surrounding soft tissue [85]. Placing miniscrews into attached gingiva can avoid soft-tissue impingement over the head of the screw. Additionally, the elastic chain, arch wire or coils may impinge on the gingiva and may cause inflammation, as well as gingival recession. Clinicians should be careful, as bending of the arch wire can eliminate impingement. Thin soft-tissue impingement overlying the miniscrew can be exposed with light finger pressure without having to apply a local anesthetic [85]. Soft-tissue impingement may be minimized by placing a wax pellet or an elastic separator over the miniscrew. Additionally, patients may be instructed to use chlorhexidine mouthwash. Rather than acting as an antibacterial agent and minimizing tissue inflammation, chlorhexidine reduces probable soft-tissue overgrowth by slowing down epithelialization [85,86].

### 4. Damage to surrounding anatomical structures

While placing the miniscrew, the clinician needs to be careful not to cause damage to adjacent structures, nerves, arteries and the roots of the teeth. In the mandible, as the inferior alveolar nerve runs lingual and inferior to the molar roots and moves buccally at the premolar area, the miniscrews will be placed far above the inferior alveolar nerve and will not cause any damage. When placing the miniscrew in the palatal alveolar bone, angular placement near the apex of the roots of the maxillary molars will reduce the risk of making contact with the greater palatine nerve and artery, which are situated higher in the palate [12].

### 5. Root injury

Iatrogenic root injury may occur while placing the miniscrew in a narrow inter-radicular space [87]. Clinicians need to evaluate the distance between the roots using periapical or panoramic radiographs to avoid root contact during placement. A safety clearance of 2 mm is recommended in interdental areas [64]. When this space is insufficient, the interdental space should be widened before placement during the alignment of the teeth.

Caution must be taken while placing the miniscrew. A small amount of local anesthesia is preferred to keep the nerve fibers in the periodontal ligament sensitive [12], so that the patients can feel it if the miniscrew touches the root. Clinicians can also sense contact with the root. During insertion of the miniscrew, cortical bone resistance may at the outset be quite strong; however, after penetrating the cortical bone, resistance remains minimal until the miniscrew is fully placed. If any strong resistance is felt, it should be used as an indicator of possible root contact [88]. Should this occur, the clinician should remove the miniscrew and change the insertion angulation. Angular placement of the miniscrew may minimize root contact. Placing the miniscrew slightly mesial to the contact point of teeth is also recommended. It has been shown that the distance from the outer bone surface to the buccal surface of the root is larger at the second premolars than that at the first molars [50].

Potential complications of root damage include root resorption, devitalization, dentoalveolar ankylosis and osteosclerosis [79, 89]. Researchers have determined that close proximity or

contact between a miniscrew and a root can be a major risk factor for failure of the procedure [39, 40, 90]. This view is supported by Lee et al. [91], who reported that the incidence of root resorption increased when the distance between the miniscrew and the root was less than 0.6 mm, and that the incidence of bone resorption and ankylosis was increased when the miniscrew came close to the root surface, even without root contact.

Asscherickx et al. [89], reported that if damage occurs, recovery time is relatively quick. If trauma to the root does not involve the pulp and is limited to the cementum or the dentin of the tooth, the prognosis will not be heavily influenced and healing will take place [85,88]. After removal of the miniscrew, the damaged root will be repaired in 12–18 weeks [85]. In their animal studies, Kim and Kim [92] observed that when a miniscrew was left touching the root, the normal healing response did not occur; the root surface was mostly resorbed and partial repair began at 8 weeks.

During orthodontic treatment, contact between the root and the miniscrew may occur as the tooth moves. The tooth will then stop moving and the miniscrew may become mobile. If further tooth movement is required, the miniscrew must be removed and placed elsewhere.

## 6. Miniscrew mobility or failure

Miniscrew dislodgement and mobility mostly occur in the first 1–2 months and more than 90% of the failures occur within the first 4 months [30]. When a miniscrew has resisted more than a 4-month period of force application, it can be considered successful and stable [30].

When mobility occurs, the clinician can tighten the miniscrew and leave it for 1–2 months with no loading, or light loading if necessary [1]. Supporting this recommendation, researchers reported that non-infected dental implants may reintegrate after tightening [93]; even when accidentally avulsed, an implant can become stable after reimplantation and immediate loading [94]. If stability cannot be regained, the miniscrew needs to be removed and replaced.

Miniscrew mobility and failure is mostly the result of low bone density owing to inadequate cortical thickness [85]. The health, thickness and type of soft tissue are other important factors in this context.

According to Moon et al. [30], sex, age, jaw (maxilla/mandible), soft-tissue management (incision/no incision) and placement side (left/right) are not related to the success rate of the miniscrew. By contrast, others have stated that miniscrews placed in the maxilla show a higher success rate than those placed in the mandible [10,31,35,43,54]. Occlusal stress and food impaction force may be factors causing mobility and failure of miniscrews in the mandible [35], while failure of miniscrews placed in the midpalatal area may be the result of tongue pressure [85].

There are conflicting reports about the relationship between success rate and the patient's age. Success rate tends to be lower in younger patients (<20 years old) compared with older patients (>20 years old) [54]. This may be because of the thinner cortical bone and poorer bone quality in younger patients. However, in another study, Park [95] reported that against expectations, the success rate was higher for the below 20 years age group compared with the over 20 years age group, which might be explained by the higher rate of metabolism in the young adult

group. Contrarily, Miyawaki et al. [16], stated that there was no significant difference in the success rates of the below 20 years age group, the 20–30 years age group and the over 30 years age group.

Excessive stress at the screw–bone interface may cause miniscrew failure. Miniscrew geometry and the placement method (self-drilling/self-tapping) can have an effect on the stress distribution of the peri-screw bone. Self-drilling miniscrews have been reported to have greater screw–bone contact (mechanical grip) and holding strength compared with self-tapping screws [96,97], although the technique causes greater stress to the peri-screw bone. Placing a pilot hole before self-drilling may reduce this stress.

## 7. Fracture of miniscrews

Miniscrew fracture is a more serious clinical complication than root contact [87]. Fractures most commonly occur during the last turn of miniscrew insertion and the first turn of the removal phase [1,98]. Lima et al. [98], stated that excessive force and the inability of the implant to resist rotational forces during insertion were the main causes of fractures. Clinicians should apply slow and gentle force to avoid fracture of the miniscrew. If the insertion resistance reaches the fracture strength of the implant, it would be better to wait 1–2 min to relieve the internal stress accumulated in the miniscrew and the surrounding bone [1].

In their in vitro study, Choa et al. [87], evaluated the effects of insertion angle and implant thread type on the fracture properties of orthodontic miniscrews during insertion. They reported that maximum insertion torque increased with an increase in insertion angle. When a miniscrew contacts the artificial root at a critical contact angle, deformation or fracture of the miniscrew can occur at a lower insertion torque value than that of penetration.

The fracture of a miniscrew may also occur during the removal phase. Miniscrews can be easily removed by turning them in the opposite direction of placement. To eliminate the possibility of fracture, clinicians should apply gentle untightening pressure or use an ultrasonic scaler on the screw's head until the interface between the miniscrew and the bone breaks. If the removal torque approaches the fracture torque range, the clinician should wait 1–2 weeks before again attempting to remove it [1]. The greater the duration of the miniscrew in the bone and the older the patient, the greater the removal torque of the miniscrew [3]. Stress concentrates in the cervical part of the miniscrew during removal.

Fracture of miniscrews primarily depends on the screw size. Miniscrews with a smaller diameter are easier to place between the roots; however, a small decrease in this dimension results in a meaningful increase in the torsional strength and, therefore, in the risk of fracture [6,8,10]. Screws with a larger diameter demonstrate minimal fracturing. The core (inner) diameter affects fracturing more than the outer diameter. Clinicians may prefer to use a miniscrew with a larger diameter to reduce the risk of fracture; however, doing so will increase the fracture torque [22,99].

The material that the miniscrews are made of is also a factor that affects the likelihood of fracture. Pure titanium implants are preferred as they are more biocompatible than titanium

alloy implants [1]; however, titanium alloys are stronger and provide more resistance to fracture [6].

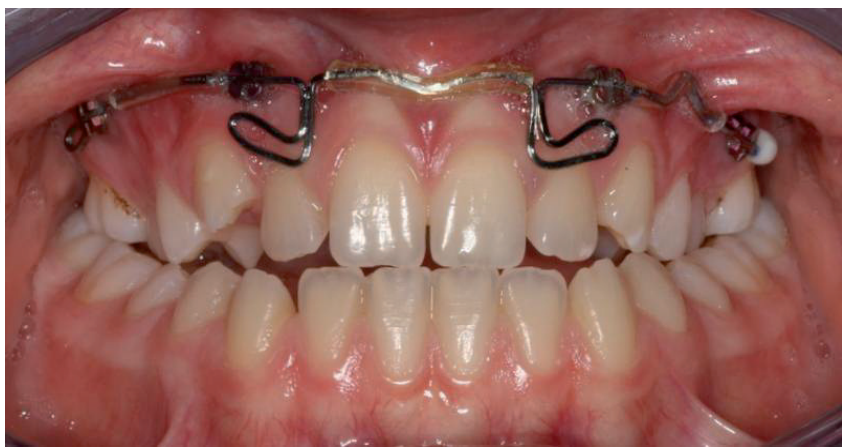#### 4. Clinical applications

Planning of orthodontic treatment should consider the desired force system to act on the teeth that need to be moved, as well as any undesired effects on the anchorage unit of teeth. This will guide ideal placement of the miniscrew for the proper appliance design.

Clinicians also should be aware of any anatomical limitations for the placement of miniscrews. The location of the miniscrew will affect the appliance design and the force system. Therefore, clinicians should plan the placement area of the miniscrews in the buccal alveolar region and/or in the palatal alveolar region or midpalatal area according to the required tooth movement. In conditions where miniscrews cannot be placed in the ideal position, the force direction should be adjusted depending on the changes in tooth movement during the treatment time.

Selection of the appropriate miniscrew design is crucial. Clinicians mostly prefer miniscrews with slotted heads, which are convenient for the attachment of different types of orthodontic wires (round, square or rectangular) and complex wire activations.

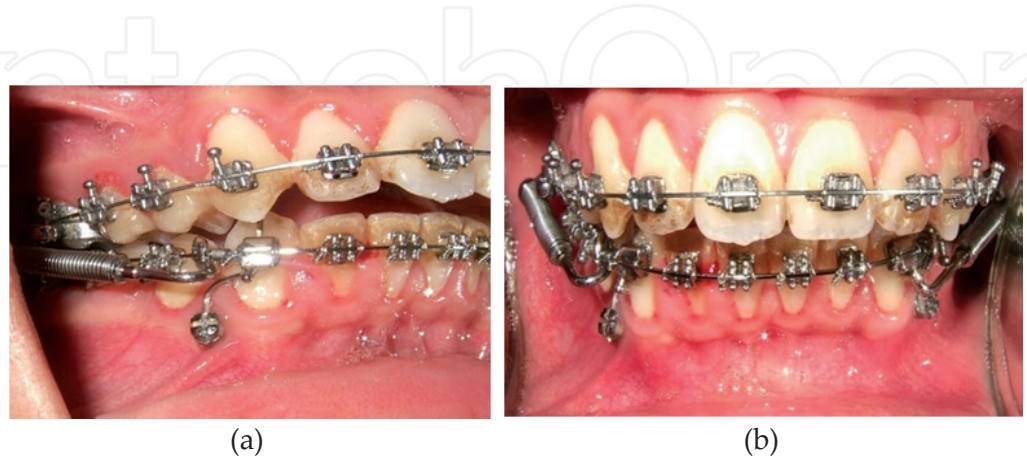Many reports describe the application of miniscrew-supported orthodontic treatment for achieving a variety of orthodontic tooth movements, including intrusion [25,49,100], extrusion, space closure (distalization, mesialization) [24, 101], uprighting, eruption of impacted teeth [102] and the correction of canted occlusal planes [103]. In addition, miniscrews can be used in the application of dentofacial orthopedics such as rapid palatal expansion and Class II and III correction (Figure 1) [12,45,104,105]. This chapter does not cover the use of miniscrews for dentoskeletal orthopedics.



**Figure 1.** Miniscrews used in the application of dentofacial orthopedics with the placement of four miniscrews between the inter-radicular areas of the maxilla. Stainless steel arch wire (0.021 × 0.025 inch) was passively connected to the miniscrews, and two hook shapes were connected to the arch wire in the lateral root region for facemask elastics.

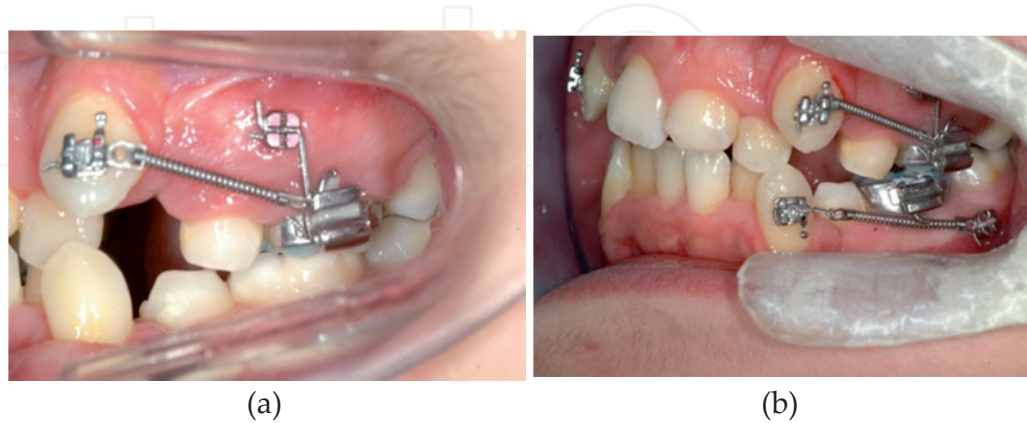


Miniscrews aim to strengthen orthodontic anchorage either by connecting to a tooth or a group of teeth to reinforce their anchorage (indirect anchorage) (Figure 2 and 3a) [105], or by acting as anchorage units themselves, eliminating the need for supporting teeth (direct anchorage) (Figures 3b and 4) [106].



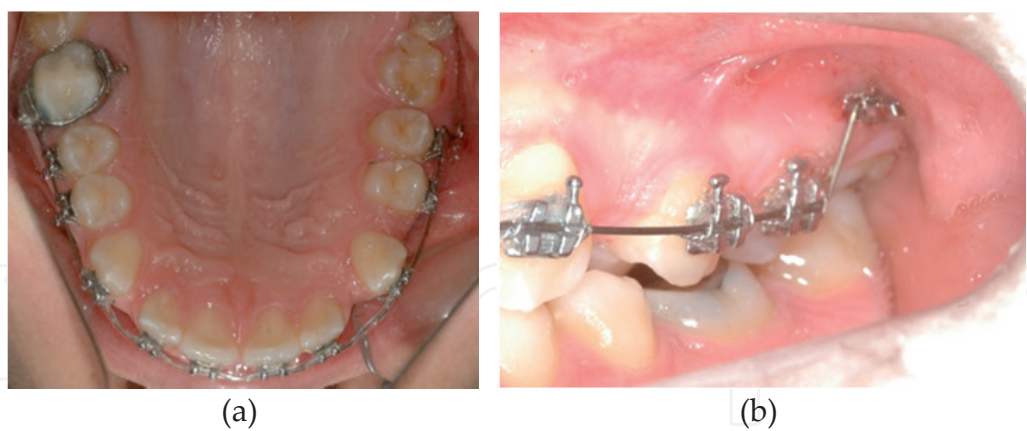
**Figure 2.** Miniscrew used as indirect anchorage to avoid buccal flaring of the anterior teeth with a forus appliance.

Miniscrews are most often used for direct anchorage. Generally, direct forces are applied between the miniscrew and the target tooth by using elastic chain, elastic thread or a coil spring to move the tooth toward the miniscrew. If a miniscrew is used as a direct anchor, it is advantageous to place the miniscrew along the line of the desired tooth movement. If force applied between the tooth and the miniscrew causes undesirable moments, then the miniscrew should be used as indirect anchorage to support the anchorage teeth, rather than acting as a direct anchor [8].



**Figure 3.** Canine distalization combined with miniscrew use as (a) indirect anchorage and (b) direct anchorage.



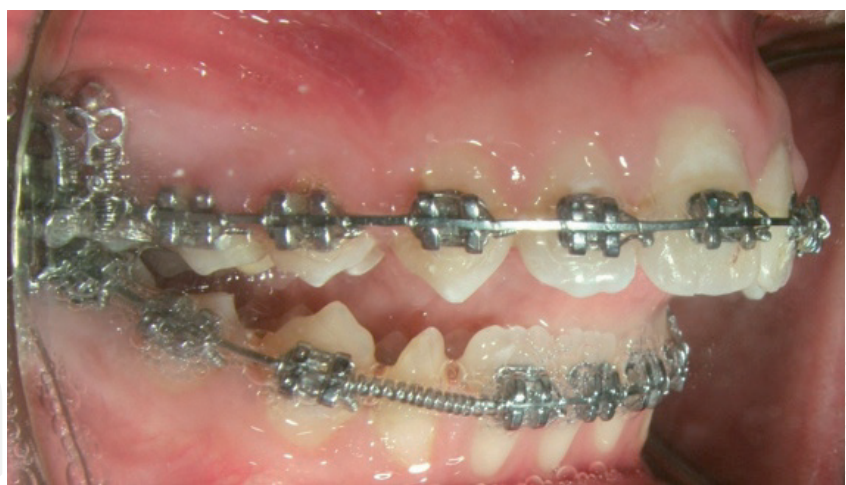

**Figure 4.** a and b: Use of a miniscrew for direct anchorage inserted between the second premolar and first molar where the molar could not be included in the arch wire because of incomplete eruption.

**4.1. Intrusion**

*4.1.1. Intrusion of posterior teeth*

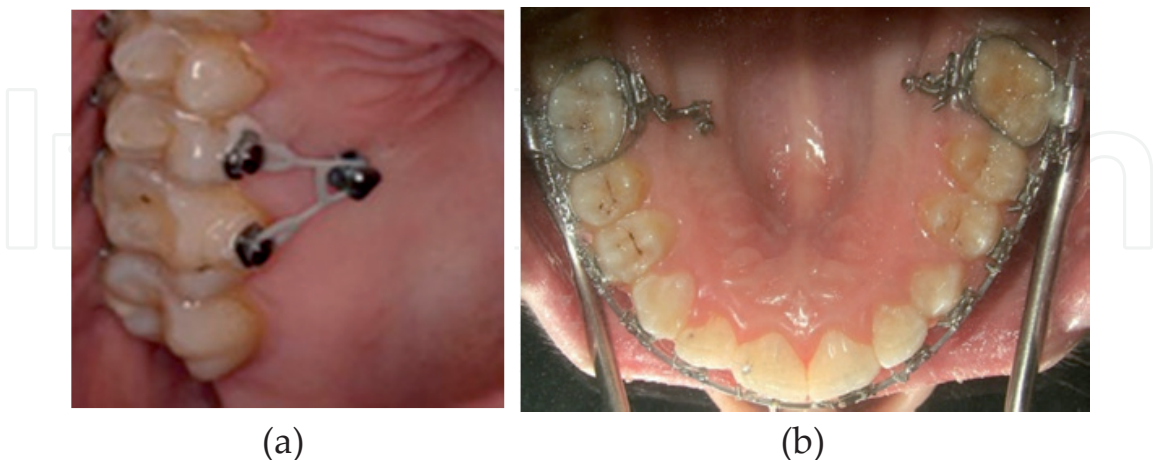
Anterior open bites can be closed successfully through the intrusion of posterior teeth using various mechanical methods incorporating miniscrews (Figure 5).



**Figure 5.** Miniscrew placed in the buccal vestibule apical to the maxillary molars, to be used for the intrusion of the posterior teeth to correct an anterior open bite.

Intrusion of posterior teeth is considered one of the most difficult types of tooth movement to achieve using conventional mechanics. A miniscrew-combined treatment may solve this problem. However, side effects such as buccal tipping have to be taken into consideration. As the intrusive force passes from the buccal to the centre of resistance, it will cause buccal tipping of the molars. When bilateral intrusion of posterior teeth is the goal, transpalatal arches can be used to avoid buccal tipping [20,21]. In unilateral intrusion, an additional miniscrew can be

placed on the palatal side to apply a palatal intrusive force for achieving intrusion of the over-erupted molar without tipping (Figure 6a and b).



**Figure 6.** a and b: Miniscrew in the palate to achieve intrusion of over-erupted posterior teeth.

#### 4.1.2. Intrusion of anterior teeth

Miniscrews may be used to stabilize the molars during the incisor intrusion process, or can be placed anteriorly and used for direct application of the intrusive force to the incisors. The miniscrews should be placed as close to the midline of the anterior arch as possible. Alternately two miniscrews may be inserted into the lateral and canine interradicular area on both left and right sides.

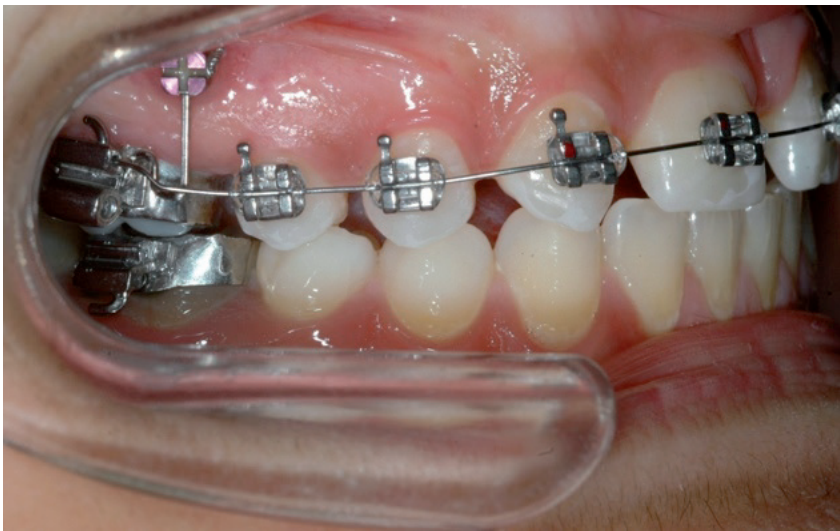#### 4.2. Extrusion

While correcting an anterior open bite, activation of an extrusion arch results in mesial tipping and an intrusive force at the molars [107]. In such cases, miniscrews can be used to avoid these side effects.

In their case report, Roth et al. [108], treated an occlusal cant with miniscrew-supported mechanics by extruding the central incisors and the canine teeth. To avoid involving the other anterior teeth, a miniscrew was placed into the alveolus of the missing upper lateral incisor and an open coil was applied perpendicularly to an orthodontic wire connecting the central incisor and the canine.

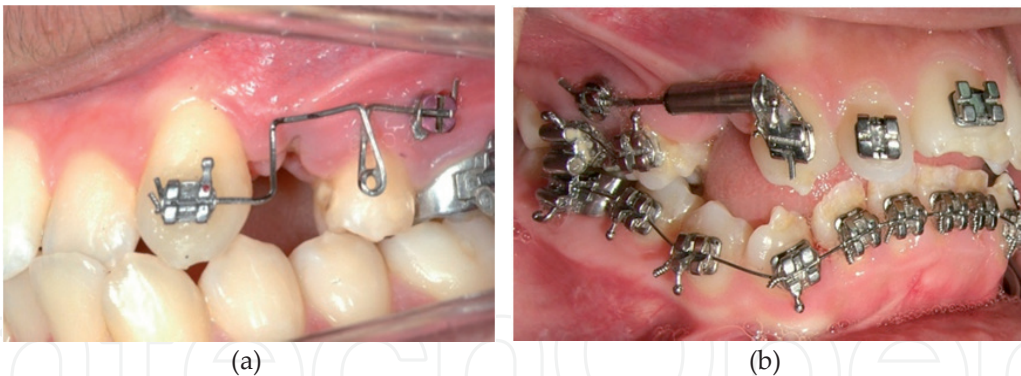#### 4.3. Space closure

Generally, miniscrews are best suited to use as indirect anchorage during retraction of the anterior teeth or protraction of the posterior teeth [20]. In this way, the miniscrew is used to avoid undesirable movement of anchorage teeth, while conventional mechanics are used to close the space created (Figures 3a and 7).



**Figure 7.** The use of a miniscrew as indirect anchorage during the distalization of the premolars and canine.

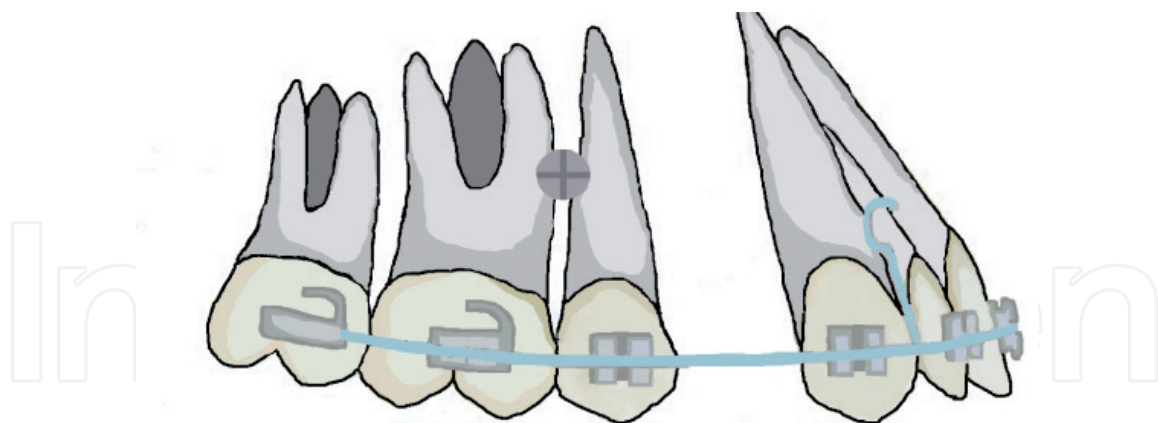
When direct anchorage is preferred for space closure, the direction and point of force application becomes crucial. Segmented arches may be preferred for canine distalization to provide a more appropriate force application point (Figure 8a and b). When the miniscrews are placed apically, a more favourable line of force direction passing closer to the centre of the resistance of the teeth can be achieved.



**Figure 8.** Miniscrews used as direct anchorage in canine distalization. Canine distalization with (a) a segmental arch and (b) a hybrid retraction arch.

Miniscrews can be used as direct anchorage when retracting the anterior teeth. Open coils/elastic chains are applied directly between the miniscrew placed between the second premolar, the first molar and the hooks on the arch wire (Figure 9). Therefore, the point of force application is close to the centre of resistance of the anterior teeth, so that the anterior segment may slide bodily with minimal tipping; 150 g of force is used for retraction [109]. In some cases, miniscrews can be placed in the palatal region. Anchorage may be indirectly reinforced by connecting a transpalatal bar to a miniscrew in the palate [110].

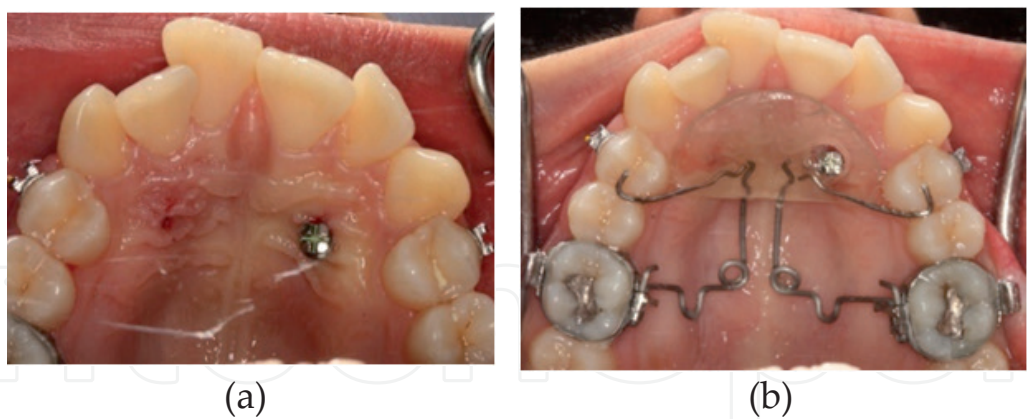



**Figure 9.** En mass retraction of the anterior teeth with miniscrew anchorage. Open coils/elastic chains can be applied directly between the miniscrew and the hooks on the arch wire.

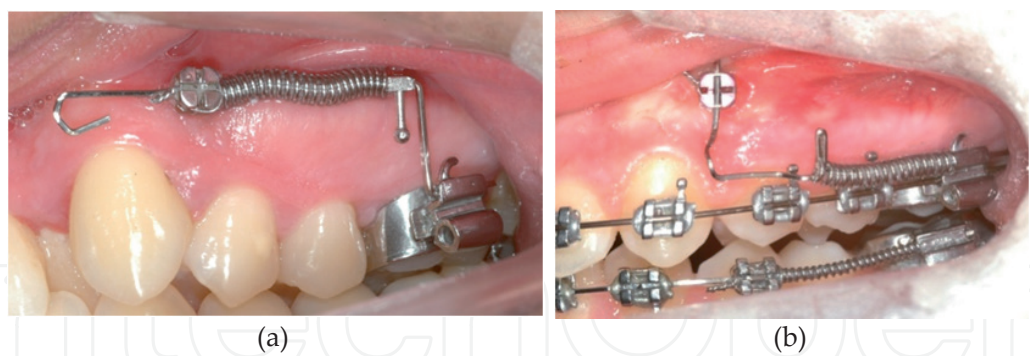
**4.4. Molar distalization**

During molar distalization with conventional intraoral appliances, tipping and extrusion can occur in conjunction with the distal movement. In addition, reactive forces on the anterior anchoring teeth occur in the form of mesialization of upper anteriors/premolars and increased overjet. Many types and designs of appliances such as the pendulum [111,116], the Keles slide appliance [112], the distal-jet [113] and the compressed coil spring [116] can be combined with a miniscrew anchorage system (Figure 10).

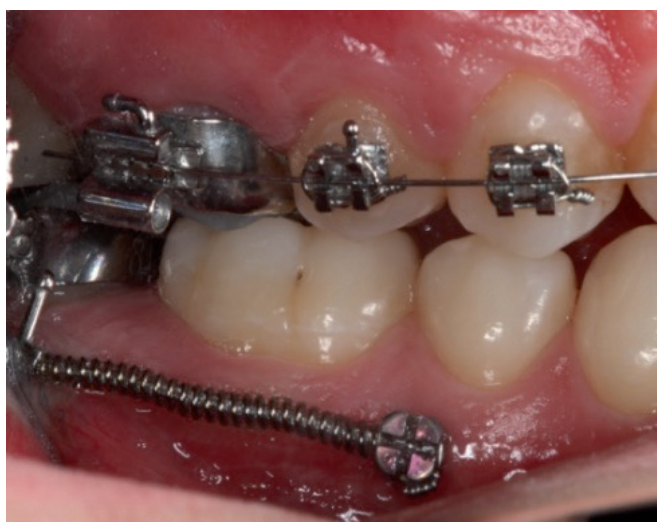

**Figure 10.** Miniscrew-supported pendulum application.

Miniscrew-supported molar distalization can only prevent undesired side effects on the anterior anchoring teeth; however, the side effects on the molars such as tipping, extrusion and rotation still remain. To avoid these undesired movements, miniscrew-supported mechanics can be designed (Figures 11 and 12). For bilateral molar distalization, rotation, tipping and extrusion can be controlled by placing the miniscrews in both the buccal and palatal region, and by using transpalatal arches [117].



**Figure 11.** Design of the retraction unit may differ because of anatomic limitations, although the miniscrew is placed in the same region; (a) the distalizing force passes through the center of resistance of the first molar, which may provide parallel distalization [118] rather than the system used in (b).



**Figure 12.** Mandibular second molar distalization with the use of direct miniscrew anchorage for the correction of mild Class III malocclusion.

#### 4.5. Uprighting

Uprighting is generally needed when second molars are impacted and the first molar tips mesially because of early premolar extraction. Uprighting vectors with intrusion are very hard to accomplish; therefore, absolute anchorage is required. Miniscrews can be used as direct anchorage to prevent reactive forces on adjacent teeth that may result in negative side effects.

For second molar uprighting, a miniscrew can be placed in the buccal inter-radicular area of the second premolar and first molar. This area is the most reliable mandibular buccal cortical site.

For first molar uprighting, the miniscrew can be placed mesially in the area between the second and first premolars; 6-to 8-mm miniscrews are preferable and 0.17 × 0.25 inch TMA wires are



preferred for preparing sectional arches with tip-back bending. Once the wire has been engaged by the miniscrew's head, intrusion and distalization forces are applied to the molar.

## 5. Conclusion

In dentistry today, it is becoming more difficult to cooperate with and satisfy patients. They have higher expectations for esthetics and comfort, yet they are impatient with longer treatment periods. Clinicians will continue to research alternative approaches to provide patients with their desired treatment outcomes over the shortest time possible. Because miniscrews provide an alternative to conventional mechanics for anchorage control, clinicians are showing increasing interest in this field. Desired treatment outcomes that are not possible with conventional mechanics may be achieved with miniscrew-supported orthodontic treatment. Miniscrews have recently become commonly accepted as a simple and effective tool in daily orthodontic practice.

With further studies and the development of new designs, appliances using miniscrews are expected to become more commonly used not only in orthodontic tooth movement, but also in the application of dentofacial orthopedics.

## Acknowledgements

We thank Dr. Eren Korunmuş and Dr. Myumyun S. Myumyun for their valuable contributions in preparing this chapter.

## Author details

Fatma Deniz Uzuner\* and Belma Işık Aslan

\*Address all correspondence to: fduzuner@yahoo.com.tr

Department of Orthodontics, Faculty of Dentistry, Gazi University, Emek Ankara, Turkey

## References

- [1] Lindauer SJ, Shroff B. Temporary anchorage devices: Biomechanical opportunities and challenges. In: R. Nanda and S. Kapila (ed.) Current therapy in orthodontics Mosby Inc. 2010; p278-290.

- [2] Gainsforth BL, Higley LB. A study of orthodontic anchorage possibilities in basal bone. *American Journal of Orthodontics* 1945;31: 406-417.
- [3] Linkow LI. Implant-orthodontics. *Journal of Clinical Orthodontics* 1970;4(12): 685-690.
- [4] Creekmore TD, Eklund MK. The possibility of skeletal anchorage. *Journal of Clinical Orthodontics* 1983;17(4): 266-269.
- [5] Costa A, Raffaini M, Melsen B. Miniscrews as orthodontic anchorage: a preliminary report. *International Journal of Adult Orthodontics and Orthognathic Surgery* 1998;13(3): 201-209.
- [6] Reynders R, Ronchi L, Bipat S. Mini-implants in orthodontics: a systematic review of the literature. *American Journal of Orthodontics and Dentofacial Orthopedics* 2009; 135(5): 564.e1-564.e19.
- [7] Huang LH, Shotwell IL, Wang HL. Dental implants for orthodontic anchorage. *American Journal of Orthodontics and Dentofacial Orthopedics* 2005; 127(6): 713-722.
- [8] Melsen B. Mini-implants: where are we? *Journal of Clinical Orthodontics* 2005;39(9) 539-547.
- [9] Mizrahi E, Mizrahi B. Mini-screw implants [temporary anchorage devices]: orthodontic and pre-prosthetic applications. *Journal of Orthodontics* 2007;34(2): 80-94.
- [10] Chen CH, Chang CS, Hsieh CH, Tseng YC, Shen YS et al. The use of microimplants in orthodontic anchorage. *Journal of Oral Maxillofacial Surgery* 2006;64(8): 1209-1213.
- [11] Roberts WE, Smith RK, Zilberman Y, Mozsary PG, Smith RS. Osseous adaptation to continuous loading of rigid endosseous implants. *American Journal of Orthodontics and Dentofacial Orthopedics* 1984; 86(2): 95-111.
- [12] Park HS. The usage of microimplants in orthodontics. In: R. Nanda and S. Kapila (ed.) *Current therapy in orthodontics* Mosby Inc. 2010; p291-300.
- [13] Papadopoulos MA, Tarawneh F. The use of miniscrew implants for temporary anchorage in orthodontics: a comprehensive review. *Oral Surg Oral Med Oral Pathol Oral Radiol Endod* 2007;103 (5): e6-15.
- [14] Higuchi KW and Slack JM. The use of titanium fixtures for intraoral anchorage to facilitate orthodontic tooth movement. *International Journal of Oral Maxillofacial Implants* 1991;6:338-344.
- [15] Odman J, Lekholm U, Jemt T, Thilander B. Osseointegrated implants as orthodontic anchorage in the treatment of partially edentulous adult patients. *European Journal of Orthodontics* 1994;16(3): 187-201.
- [16] Miyawaki S, Koyama I, Inoue M, Mishima K, Sugahara T et al. Factors associated with the stability of titanium screws placed in the posterior region for orthodontic

- anchorage. *American Journal of Orthodontics and Dentofacial Orthopedics* 2003;124(4): 373-378.
- [17] Cornelis MA, Scheffler NR, De Clerck HJ, Tulloch JF, Behets CN. Systematic review of experimental use of temporary skeletal anchorage devices in orthodontics. *American Journal of Orthodontics and Dentofacial Orthopedics* 2007;131(4): 52-58.
- [18] Mah J, Bergstrand F. Temporary anchorage devices: a status report. *Journal of Clinical Orthodontics* 2005;39(3): 132-136.
- [19] Heymann GC, Tulloch JF. Implantable devices as orthodontic anchorage: a review of current treatment modalities. *Journal of Esthetic and Restorative Dentistry* 2006;18(2): 68-80.
- [20] Maino GB, Mura P, Bednar J. Miniscrew implants: the Spider Screw Anchorage System. *Seminars in Orthodontics* 2005;11(1): 40-46.
- [21] Park HS, Kwon OW, Sung JH. Nonextraction treatment of an open bite with micro-screw implant anchorage. *American Journal of Orthodontics and Dentofacial Orthopedics* 2006; 130(3): 391-402.
- [22] Carano A, Velo S, Incorvati C, Poggio P. Clinical applications of the Mini-Screw-Anchorage-System (M.A.S.) in the maxillary alveolar bone. *Progress in Orthodontics* 2004;5:212-235.
- [23] Kim YH, Yang SM, Kim S, Lee JY, Kim KE, Gianelly AA, Kyung SH. Midpalatal miniscrews for orthodontic anchorage. *American Journal of Orthodontics and Dentofacial Orthopedics* 2010;137(1): 66-72.
- [24] Kyung SH, Hong SG, Park YC. Distalization of maxillary molars with a midpalatal miniscrews. *Journal of Clinical Orthodontics* 2003; 37(1) 22-26.
- [25] Chang YJ, Lee HS, Chun YS. Microscrew anchorage for molar intrusion. *Journal of Clinical Orthodontics* 2004;38(6) 325-330.
- [26] Wilmes B, Rademacher C, Olthoff G, Drescher D. Parameters affecting primary stability of orthodontic mini-implants. *Journal of Orofacial Orthopedics* 2006;67(3): 162-174.
- [27] Motoyoshi M, Yoshida T, Ono A, Shimizu N. Effect of cortical bone thickness and implant placement torque on stability of orthodontic mini-implants. *International Journal of Oral Maxillofacial Implants* 2007;22(5): 779-784.
- [28] Marquezana M, Mattosb CT, Sant'Annac EF, Gomes de Souza MM, Maiac LC. Does cortical thickness influence the primary stability of miniscrews? A systematic review and meta-analysis. *Angle Orthodontist* 2014 Apr 2. [Epub ahead of print] DOI: 10.2319/093013-716.1

- [29] Cheng SJ, Tseng IY, Lee JJ, Kok SH. A prospective study of the risk factors associated with failure of mini-implants used for orthodontic anchorage. *International Journal of Oral Maxillofacial Implants* 2004;19(1): 100-106.
- [30] Moon CH, Lee DG, Lee HS, Im JS, Baek SH. Factors associated with the success rate of orthodontic miniscrews placed in the upper and lower posterior buccal region. *Angle Orthodontist* 2008;78(1): 101-106.
- [31] Park HS, Jeong SH, Kwon OW. Factors affecting the clinical success of screw implants used as orthodontic anchorage. *American Journal of Orthodontics and Dentofacial Orthopedics* 2006;130(1): 18-25.
- [32] Poggio PM, Incorvati C, Velo S, Carano A. "Safe zones": a guide for miniscrew positioning in the maxillary and mandibular arch. *Angle Orthodontist* 2006;76(2): 191-197.
- [33] Ishii T, Nojima K, Nishii Y, Takaki T, Yamaguchi H. Evaluation of the implantation position of mini-screws for orthodontic treatment in the maxillary molar area by a micro CT. *The Bulletin of Tokyo Dental College* 2004; 45(3): 165-172.
- [34] Kang S, Lee SJ, Ahn SJ, Heo MS, Kim TW. Bone thickness of the palate for orthodontic mini-implant anchorage in adults. *American Journal of Orthodontics and Dentofacial Orthopedics* 2007;131(4):74-81.
- [35] Takaki T, Tamura N, Yamamoto M, Takano N, Shibahara T et al. Clinical study of temporary anchorage devices for orthodontic treatment. Stability of micro/mini-screws and mini-plates: experience with 455 cases. *Bulletin of Tokyo Dental College* 2010;51(3): 151-163.
- [36] Melsen B. Palatal growth studied on human autopsy material. A histologic microradiographic study. *American Journal of Orthodontics* 1975; 68(1): 42-54.
- [37] Kim HJ, Yun HS, Park HD, Kim DH, Park YC. Soft-tissue and cortical-bone thickness at orthodontic implant sites. *American Journal of Orthodontics and Dentofacial Orthopedics* 2006;130(2): 177-82.
- [38] Kuroda S, Sugawara Y, Deguchi T, Kyung HM, Takano-Yamamoto T. Clinical use of miniscrew implants as orthodontic anchorage: success rates and postoperative discomfort. *American Journal of Orthodontics and Dentofacial Orthopedics* 2007;131(1): 9-15.
- [39] Asscherickx K, Vande Vannet B, Wehrbein H, Sabzevar MM. Success rate of miniscrews relative to their position to adjacent roots. *European Journal of Orthodontics* 2008;30(4): 330-335.
- [40] Kuroda S, Yamada K, Deguchi T, Hashimoto T, Kyung HM, Takano-Yamamoto T. Root proximity is a major factor for screw failure in orthodontic anchorage. *American Journal of Orthodontics and Dentofacial Orthopedics* 2007;131(4): 68-73.

- [41] Melsen B, Verna C. Miniscrew implants: the Aarhus anchorage system. *Seminars in Orthodontics* 2005;11(1): 24-31.
- [42] Wilmes B, Ottenstreuer S, Su YY, Drescher D. Impact of implant design on primary stability of orthodontic mini-implants. *Journal of Orofacial Orthopedics* 2008;69(1): 42-50.
- [43] Park HS, Jeong SH, Kwon OW. Factors affecting the clinical success of screw implants used as orthodontic anchorage. *American Journal of Orthodontics and Dentofacial Orthopedics* 2006;130(1): 18-25.
- [44] Tseng YC, Hsieh CH, Chen CH, Shen YS, Huang IY, Chen CM. The application of mini-implants for orthodontic anchorage. *International Journal of Oral and Maxillofacial Surgery* 2006;35(8): 704-707.
- [45] Lee J, Kim JY, Choic YJ, Kim KH, Chung CJ. Effects of placement angle and direction of orthopedic force application on the stability of orthodontic miniscrews. *Angle Orthodontist* 2013;83(4) 667-673.
- [46] Oktenoglu BT, Ferrara LA, Andalkar N, Ozer AF, Sarioglu AC et al. Effects of hole preparation on screw pull out resistance and insertional torque: a biomechanical study. *Journal of Neurosurgery* 2001; 94(11): 91-96.
- [47] Chaddad K, Ferreira AF, Geurs N, Reddy MS. Influence of surface characteristics on survival rates of mini-implants. *Angle Orthodontist* 2008;78(1): 107-113.
- [48] Berens A, Wiechmann D, Dempf R. Mini-and micro-screws for temporary skeletal anchorage in orthodontic therapy. *Journal of Orofacial Orthopedics* 2006;67(6): 450-458.
- [49] Park YC, Lee SY, Kim DH, Jee SH. Intrusion of posterior teeth using mini-screw implants. *American Journal of Orthodontics and Dentofacial Orthopedics* 2003;123(6) 690-694.
- [50] Park HS. An anatomical study using CT images for the implantation of micro-implants. *Korean Journal of Orthodontics* 2002;32(6): 435-441.
- [51] Roze' J, Babu S, Saffazadeh A, Gayet-Delacroix M, Hoomaert A, Layrolle P. Correlating implant stability to bone structure. *Clinical Oral Implants Research* 2009;20(10): 1140-1145.
- [52] Yacker MJ, Klein M. The effect of irrigation on osteotomy depth and bur diameter. *International Journal of Oral Maxillofacial Implants* 1996;11(5): 634-638.
- [53] Matthews LS, Hirsch C. Temperatures measured in human cortical bone when drilling. *Journal of Bone and Joint Surgery Am* 1972;54(2): 297-308.
- [54] Kim JS, Choi SH, Cha SK, Kim JH, Lee HJ et al. Comparison of success rates of orthodontic mini-screws by the insertion method. *Korean Journal of Orthodontics* 2012;42(5): 242-248.



- [55] Kim JW, Ahn SJ, Chang YI. Histomorphometric and mechanical analyses of the drill-free screw as orthodontic anchorage. *American Journal of Orthodontics and Dentofacial Orthopedics* 2005;128(2): 190-194.
- [56] Kim YH, Choi JH. The study about retention of miniscrews used for intraoral anchorage. *Journal of the Korean Dental Association* 2001;39: 684-687.
- [57] Kim JW, Chang YI. Effect of drilling process in stability of micro-implants used for orthodontic anchorage. *Korean Journal of Orthodontics* 2002;32(2): 107-115.
- [58] Freudenthaler JW, Haas R, Bantleon HP. Bicortical titanium screws for critical orthodontic anchorage in the mandible: a preliminary report on clinical applications. *Clinical Oral Implants Research* 2001;12(4): 358-363.
- [59] Brettin BT, Grosland NM, Qian F, Southard KA, Stuntz TD, Morgan TA, Marshall SD, Southard TE. Bicortical vs monocortical orthodontic skeletal anchorage. *American Journal of Orthodontics and Dentofacial Orthopedics* 2008;134(5): 625-635.
- [60] Holberg C, Winterhalder P, Rudzki-Janson I, Wichelhaus A Finite element analysis of mono-and bicortical mini-implant stability. *European Journal of Orthodontics* 2014;36(5): 550-556.
- [61] Motoyoshi M, Hirabayashi M, Uemura M, Shimizu N. Recommended placement torque when tightening an orthodontic mini-implant. *Clinical Oral Implants Research*. 2006;17(1): 109-114.
- [62] Luzi C, Verna C, Melsen B. A prospective clinical investigation of the failure rate of immediately loaded mini-implants used for orthodontic anchorage. *Progress in Orthodontics* 2007;8(1): 192-201.
- [63] Gapski R, Wang HL, Mascarenhas P, Lang NP. Critical review of immediate implant loading. *Clinical Oral Implants Research* 2003;14(5): 515-527.
- [64] Wang YC, Liou EJ. Comparison of the loading behavior of selfdrilling and predrilled miniscrews throughout orthodontic loading. *American Journal of Orthodontics and Dentofacial Orthopedics* 2008;133(1): 38-43.
- [65] Yano S, Motoyoshi M, Uemura M, Ono A, Shimizu N. Tapered orthodontic miniscrews induce bone-screw cohesion following immediate loading. *European Journal of Orthodontics* 2006;28(6): 541-546.
- [66] Motoyoshi M, Inaba M, Ono A, Ueno S, Shimizu N. The effect of cortical bone thickness on the stability of orthodontic miniimplants and on the stress distribution in surrounding bone. *International Journal of Oral and Maxillofacial Surgery* 2009;38(1): 13-18.
- [67] Dalstra M, Cattaneo PM, Melsen B. Load transfer of miniscrews for orthodontic anchorage. *Orthodontics* 2004; 1: 53-62.

- [68] Kanomi R. Mini-implant for orthodontic anchorage. *Journal of Clinical Orthodontics* 1997;31(1): 763-767.
- [69] Buchter A, Wiechmann D, Koerdt S, et al: Load-related implant reaction of mini-implants used for orthodontic anchorage. *Clinical Oral Implants Research* 2005;16(4): 473-479.
- [70] Kim YH, Yang SM, Kim S, Lee JY, Kim KE, Gianelly AA, Kyung SH Midpalatal miniscrews for orthodontic anchorage: Factors affecting clinical success. *American Journal of Orthodontics and Dentofacial Orthopedics* 2010;137(1): 66-72.
- [71] Park H, Lee Y, Jeong S, Kwon T. Density of the alveolar and basal bones of the maxilla and the mandible. *American Journal of Orthodontics and Dentofacial Orthopedics* 2008;133(1): 30-37.
- [72] Liou EJ, Pai BC, Lin JC: Do miniscrews remain stationary under orthodontic forces? *American Journal of Orthodontics and Dentofacial Orthopedics* 2004;126(1): 42-47.
- [73] Liu H, Lv T, Wang N, Zhao F, Wang K, Liud D. Drift characteristics of miniscrews and molars for anchorage under orthodontic force: 3-dimensional computed tomography registration evaluation. *American Journal of Orthodontics and Dentofacial Orthopedics* 2011;139(1): e83-e89.
- [74] Park J, Cho HJ. Three-dimensional evaluation of interradicular spaces and cortical bone thickness for the placement and initial stability of microimplants in adults. *American Journal of Orthodontics and Dentofacial Orthopedics* 2009;136(3): 314.e1-12.
- [75] Frost HM. Wolff's law and bone's structural adaptations to mechanical usage: an overview for clinicians. *Angle Orthodontist* 1994; 64(3): 175-188.
- [76] Frost HM. A 2003 update of bone physiology and Wolff's law for clinicians. *Angle Orthodontist* 2004;74(1): 3-15.
- [77] Zmudzki J, Walke W, Chladek W. Stresses present in bone surrounding dental implants in FEM model experiments. *Journal of Achievements in Materials and Manufacturing Engineering* 2008;27(1): 71-74.
- [78] Lin D, Li Q, Li W, Swain M. Dental implant induced bone remodeling and associated algorithms. *Journal of Mechanical Behavior of Biomedical Materials* 2009; 2(5): 410-432.
- [79] Kravitz ND, Kusnoto B. Risks and complications of orthodontic miniscrews. *American Journal of Orthodontics and Dentofacial Orthopedics* Orthop. 2007;131(4): 43-51.
- [80] Chung KR, Kim SH, Kook YA. The C-orthodontic micro-implant. *Journal of Clinical Orthodontics* 2004;38(9): 478-486.
- [81] Piesold JU, Al-Nawas B, Grotz KA. Osteonecrosis of the jaws by long-term therapy with bisphosphonates. *Mund Kiefer und Gesichtschirurgie* 2006;10(5): 287-300.

- [82] Mengel R, Behle M, Flores-de-Jacoby L. Osseointegrated implants in subjects treated for generalized aggressive periodontitis: 10-year results of a prospective, long-term cohort study. *Journal of Periodontology* 2007;78(12): 2229-2237.
- [83] Park JB, Kim EY, Paek J, Kook YA, Jeong DM et al. Primary stability of self-drilling and self-tapping mini-implant in tibia of diabetes-induced rabbits. *International Journal of Dentistry* Epub 2014 May 11; Article ID 429359 Doi: 10.1155/2014/429359
- [84] Ludwig B, Glasl B, Lietz T, Bumann A, Bowman SJ. Techniques for attaching orthodontic wires to miniscrews. *Journal of Clinical Orthodontics* 2010;44(1): 36-40.
- [85] Yamaguchi M, Inami T, Ito K, Kasai K, Tanimoto Y. Mini-Implants in the Anchorage Armamentarium: New Paradigms in the Orthodontics. *International Journal of Biomaterials* Epub 2012;Jun 5 Article ID 394121, 8 pages. Doi: 10.1155/2012/394121
- [86] Othman S, Haugen E, Gjermo P. The effect of chlorhexidine supplementation in a periodontal dressing. *Acta Odontologica Scandinavica* 1989;47(6): 361-366.
- [87] Choa IS, Kimb TW, Ahnc SJ, Yangd IH, Baekb SH. Effects of insertion angle and implant thread type on the fracture properties of orthodontic mini-implants during insertion. *Angle Orthodontist* 2013;83(4): 698-704.
- [88] Brisceno CE, Rossouw PE, Carrillo R, Spears R, Buschang PH. Healing of the roots and surrounding structures after intentional damage with miniscrew implants. *American Journal of Orthodontics and Dentofacial Orthopedics* 2009;135(3): 292-301.
- [89] Asscherickx K, Vannet BV, Wehrbein H, Sabzevar MM: Root repair after injury from mini-screw. *Clinical Oral Implants Research* 2005;16(5): 575-578.
- [90] Chen YH, Chang HH, Chen YJ, Lee D, Chiang HH, Yao CC. Root contact during insertion of miniscrews for orthodontic anchorage increases the failure rate: an animal study. *Clinical Oral implants Research* 2008;19(1): 99-106.
- [91] Lee YK, Kim JW, Baek SH, Kim TW, Chang YI. Root and bone response to the proximity of a mini-implant under orthodontic loading. *Angle Orthodontist* 2010;80(3): 452-458.
- [92] Kim H, Kim TW. Histologic evaluation of root-surface healing after root contact or approximation during placement of miniimplants. *American Journal of Orthodontics and Dentofacial Orthopedics* 2011;139(6): 752-760.
- [93] Ivanoff CJ, Sennerby L, Lekholm U. Reintegration of mobilized titanium implants: an experimental study in rabbit tibia. *International Journal of Oral and Maxillofacial Surgery* 1997;26(4): 310-315.
- [94] Ogunsalu C. Reimplantation and immediate loading of an accidentally avulsed bead-implant: case report. *Implant Dentistry* 2004;13(1): 54-57.
- [95] Park HS. Clinical study on success rate of microscrew implants for orthodontic anchorage. *Korean Journal of Orthodontics* 2003;33(3): 151-156.

- [96] Heidemann W, Terheyden H, Gerlach KL. Analysis of the osseous/metal interface of drill free screws and self-tapping screws. *Journal of Cranio-Maxillofacial Surgery* 2001; 29(2): 69-74.
- [97] Heidemann W, Terheyden H, Gerlach KL. In vivo studies of screw-bone contact of drill-free screws and conventional self-tapping screws. *Mund-, Kiefer-und Gesichtschirurgie* 2001;5(1): 17-21.
- [98] Lima GM, Soares MS, Penha SS, Romano MM. Comparison of the fracture torque of different Brazilian miniimplants. *Brazilian Oral Research*. 2011;25(2): 116-121.
- [99] Barros SE, Janson G, Chiqueto K, Garib DG, Janson M. Effect of mini-implant diameter on fracture risk and selfdrilling efficacy. *American Journal of Orthodontics and Dentofacial Orthopedics* 2011;140(4): e181-192.
- [100] Lee JS, Kim DH, Park YC, Kyung SH, Kim TK The efficient use of midpalatal miniscrew implants. *Angle Orthodontist* 2004; 74(5): 711-714.
- [101] Park YC, Choi YJ, Choi NC, Lee JS. Esthetic segmental retraction of maxillary anterior teeth with a palatal appliance and orthodontic mini-implants. *American Journal of Orthodontics and Dentofacial Orthopedics* Orthop.2007;131(4): 537-544.
- [102] Nienkemper M, Wilmes B, Lübberink G, Ludwig B, Drescher D. Extrusion of impacted teeth using mini-implant mechanics. *Journal of Clinical Orthodontics* 2012;46(3): 150-155.
- [103] Takano-Yamamoto T, Kuroda S. Titanium screw anchorage for correction of canted occlusal plane in patients with facial asymmetry. *American Journal of Orthodontics and Dentofacial Orthopedics* 2007;132(2): 237-242.
- [104] Aslan BI, Qasem M, Dinçer M. Maxillary Protraction of a Case with Mini-screw Bone Anchorage (Case Report). *Journal of Orthodontic Research* 2013;2(1): 77-81.
- [105] Aslan BI, Kuçukkaraca E, Turkoz C, Dincer M. Treatment effects of the Forsus Fatigue Resistance Device used with miniscrew anchorage. *Angle Orthodontist* 2013;84(1): 76-87.
- [106] Celenza F. Implant-enhanced tooth movement: indirect absolute anchorage. *The International Journal of Periodontics and Restorative Dentistry* 2003;23(6): 533-541.
- [107] Isaacson RJ, Lindauer SJ. Closing anterior open bites: the extrusion arch. *Seminars in Orthodontics* 2001;7(1): 34-41.
- [108] Roth A, Yildirim M, Diedrich P. Forced eruption with microcrew anchorage for pre-prosthetic leveling of the gingival margin: case report. *Journal of Orofacial Orthopedics* 2004;65(6): 513-519.
- [109] Park HS, Kwon OW, Sung JH. Microscrew implant anchorage sliding mechanics. *World Journal of Orthodontics* 2005; 6(3): 265-274.

- [110] Wehrbein H, Feifel H, Diedrich P. Palatal implant anchorage reinforcement of posterior teeth: a prospective study. *American Journal of Orthodontics & Dentofacial Orthopedics* 1999;116(6): 678-686.
- [111] Byloff FK, Karcher H, Clar E, Stoff F. An implant to eliminate anchorage loss during molar distalization: a case report involving the Graz implant-supported pendulum. *International Journal of Adult Orthodontics and Orthognathic Surgery* 2000;15(2): 129-137.
- [112] Keles A, Erverdi N, Sezen S. Bodily distalization of molars with absolute anchorage. *Angle Orthodontist* 2003;73(4): 471-482.
- [113] Carano A, Velo S, Leone P, Siciliani G. Clinical applications of the miniscrew anchorage system. *Journal of Clinical Orthodontics* 2005; 39(1): 9-24.
- [114] Karaman AI, Başçiftçi FA, Polat O. Unilateral distal molar movement with an implant-supported distal jet appliance. *Angle Orthodontist* 2002;72(2): 167-174.
- [115] Gelgor IE, Buyukyilmaz T, Karaman AI, Dolanmaz D, Kalayci A. Intraosseous screw-supported upper molar distalization. *Angle Orthodontist* 2004;74(6): 838-850.
- [116] Kircelli BH, Pektas ZO, Kircelli C. Maxillary molar distalization with a bone-anchored pendulum appliance. *Angle Orthodontist* 2006;76(4): 650-659.
- [117] Lim SM, Hong RK. Distal Movement of Maxillary Molars Using a Lever-arm and Mini-implant System. *Angle Orthodontist* 2008;78(1): 167-175.
- [118] Bugra A. Evaluation of the dental and skeletal effects of a new designed mini-screw supported unilateral molar distalization system [thesis]. Ankara, Gazi University; 2013