

# We are IntechOpen, the world's leading publisher of Open Access books Built by scientists, for scientists

6,900

Open access books available

186,000

International authors and editors

200M

Downloads

Our authors are among the

154

Countries delivered to

TOP 1%

most cited scientists

12.2%

Contributors from top 500 universities



WEB OF SCIENCE™

Selection of our books indexed in the Book Citation Index  
in Web of Science™ Core Collection (BKCI)

Interested in publishing with us?  
Contact [book.department@intechopen.com](mailto:book.department@intechopen.com)

Numbers displayed above are based on latest data collected.  
For more information visit [www.intechopen.com](http://www.intechopen.com)



---

# Current Surgical Management of Acral Lentiginous Melanoma

---

Yasuhiro Nakamura, Yukiko Teramoto,  
Sayuri Sato and Akifumi Yamamoto

Additional information is available at the end of the chapter

<http://dx.doi.org/10.5772/59133>

---

## 1. Introduction

Malignant melanoma (MM) is the most common cause of death from skin cancer in Caucasians. The incidence of MM has considerably increased in most countries in the recent decades. However, the incidence rate of melanoma demonstrates a racial difference. The incidence rates range between 20 and 40 per 100,000 people in Australia and United States each year [1, 2]. In contrast, the incidence in Asians is clearly lower, approximately one per 100,000 [3, 4]. However, the most common clinical subtype of melanoma in Asians is acral lentiginous melanoma (ALM), which occurs at a rate of approximately 40%–65% of all cutaneous melanomas [4, 5] compared with only 2%–3% in Caucasians [6]. This subtype of melanoma, first described by Reed in 1976, is characterized by its predilection for the acral regions such as the soles, palms, and nail apparatus and by a pattern of radial lentiginous growth phase that evolves over months or years without any solar elastosis to a dermal (vertical) invasive stage. This subgroup has been designated as “plantar lentiginous melanoma,” which corresponds to ALM [7]. Thereafter, MM was classified into the following four subtypes by Clark et al. in 1986 according to histological features; nodular melanoma (NM), superficial spreading melanoma (SSM), lentigo maligna melanoma (LMM), and ALM [8].

The prognosis of ALM is generally considered to be poorer than other subtypes such as SSM and LMM. In particular, the lesions of the sole are often overlooked by patients. In addition, ALM has a likelihood of being misdiagnosed as a benign melanocytic nevus, which leads to the development of tumor and delay in treatment [9]. This problem has improved with the advent of dermoscopy, which enables the dermatologists to distinguish between the early stages of ALM and benign melanocytic nevus.

Acral sites such as the palms and soles are not sun-exposed areas, and therefore overexposure to ultraviolet light has not been shown to be a risk factor for the development of ALM [10]. On the other hand, ultraviolet light can play an important role in the development of LMM [11]. A recent study showed that 81% of non-chronic sun-damaged melanomas such as SSM had a high likelihood of BRAF or N-RAS mutations and the other subtypes, including ALM, had a low rate of mutation in either gene. In contrast, ALM had a frequent mutation or amplification of the KIT gene [12].

Because of the biological and unique anatomical specificity of ALM, there are some controversies in the treatment of ALM. In this chapter, we review the published articles regarding the surgical treatment of primary ALM lesions, including our paper and experiences, assess the current role of surgery, and discuss several major controversies of ALM surgical treatment.

## 2. Problems of excision margins in ALM

The World Health Organization Melanoma Program undertook a randomized trial and compared lateral margins of 1 and 3 cm for 612 melanoma patients with thicknesses of <2 mm [13]. Disease-free and overall survival rates did not differ between the two groups. Two subsequent trials in Europe compared the results of treating melanomas with lateral margins of 2 or 5 cm. The Scandinavian Melanoma Group Study and French Cooperative Group Trial compared lateral margins of 2 cm with 5 cm for patients with 0.8–2.0 mm-thick and <2.1 mm-thick melanomas, respectively [14, 15]. Neither study showed any evidence that lateral margins of 5 cm reduced the local recurrence rate or improved survival rates. The Intergroup Melanoma Surgical Trial also reported the results of a randomized prospective trial that compared lateral margins of 2 cm with 4 cm for 740 melanoma patients with thicknesses of 1.01–4.0 mm [16]. This trial also demonstrated that the local recurrence and survival rates were similar for the two groups. This evidence suggests that lateral margins of at least 2 cm are suitable for patients with melanoma with thicknesses of >2 mm.

Although some uncertainties remain and further trial-based evidence is required for clarification, the general consensus is that at least margins of 1 cm should be adequate for melanomas with a thickness of ≤1 mm [17]. For 1.01–2 mm-thick tumors, some evidence suggests that lateral margins > 1 cm are desirable [18]. As for *in situ* lesions, a lateral margin of 5 mm is generally recommended in some national guidelines, including Japan. However, a recent prospective, comparative study demonstrated that 86% of 1120 *in situ* lesions were successfully excised with lateral margins of 6 mm and 98.9% were successful with lateral margins of 9 mm and concluded that lateral margins of 9 mm were appropriate for *in situ* lesions [19].

The appropriate depth of excision for melanoma is also still controversial. The depth of excision has been recommended to be at least to the level of muscle fascia; deeper excisions have not been shown to improve outcomes [20, 21]. On the other hand, a recent study demonstrated that there was no advantage for a resection of the deep muscular fascia but a potential for an increased risk of intralymphatic recurrences [22].

Based on the evidence described above, current major melanoma guidelines such as the National Comprehensive Cancer Network Guideline recommends adequate lateral margins

alone, depending on the maximum thickness of the tumor. However, most of the available evidence has been obtained from clinical trials that included melanomas that were located mainly on the trunk or proximal extremities. Most studies and trials have not included melanomas in the head and neck region and on distal extremities, including ALMs. Acral sites are locations where more complex reconstructive procedures may be required if wider and deeper excision margins are applied. It is unclear whether the application of current recommended excision margins to the treatment of ALM that is biologically different from other subtypes is appropriate.

### 3. Surgical management of subungual melanoma (SUM)

SUM is a rare manifestation of MM. The incidence of SUM also has a racial difference. It represents approximately 2%–3% and 20% of all cutaneous MMs in Caucasians [23–26] and Asians [4, 27], respectively.

The anatomy of the nail apparatus is complex and is composed of the proximal nail fold, nail matrix, nail bed, and hyponychium. The proximal nail fold is continuous with the dorsal aspect of the nail matrix distally and the extensor aspect of the digital skin proximally. The cuticle separates the ventral portion of the proximal nail fold from the underlying nail plate. The nail plate is the horny end product of the nail matrix. The hyponychium is the distal portion of the nail bed, which represents the site of union between the nail bed and tip of the digits [28].

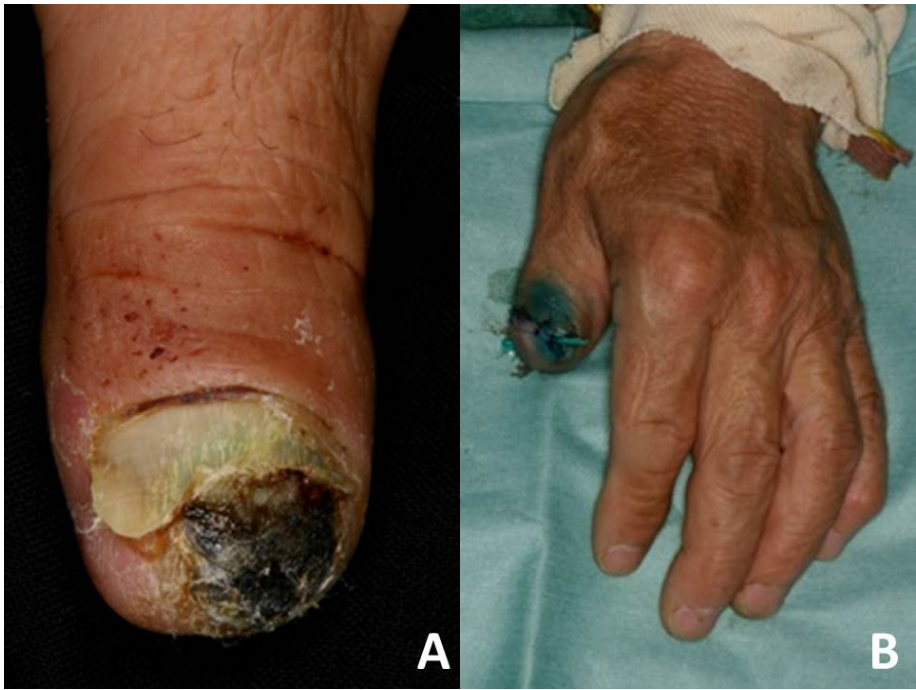#### 3.1. Invasive SUM

In the surgical treatment of SUM, amputation has been traditionally performed [29]. Comparative studies of various amputation levels have not shown any advantages for metacarpal amputations over metacarpophalangeal (MP), proximal interphalangeal (PIP), or distal interphalangeal (DIP) amputations [30]; this means that the prognosis of SUM does not depend on the amputation level but on the clinical stage [31]. Therefore, the recent trend of surgery is to utilize more distal amputations, without compromising recurrence or survival [25, 26]. In particular, in the thumb, a more distal amputation is preferable (Fig. 1). Although amputation at the interphalangeal joint of the thumb results in only a 10% loss of function of a useful hand, amputation at the MP joint of the thumb results in a 40% loss of function [32]. In contrast, from the viewpoint of the functional and cosmetic aspects, ray amputation may be more appropriate than MP, PIP, or DIP amputation for the treatment of the other fingers (Fig. 2).

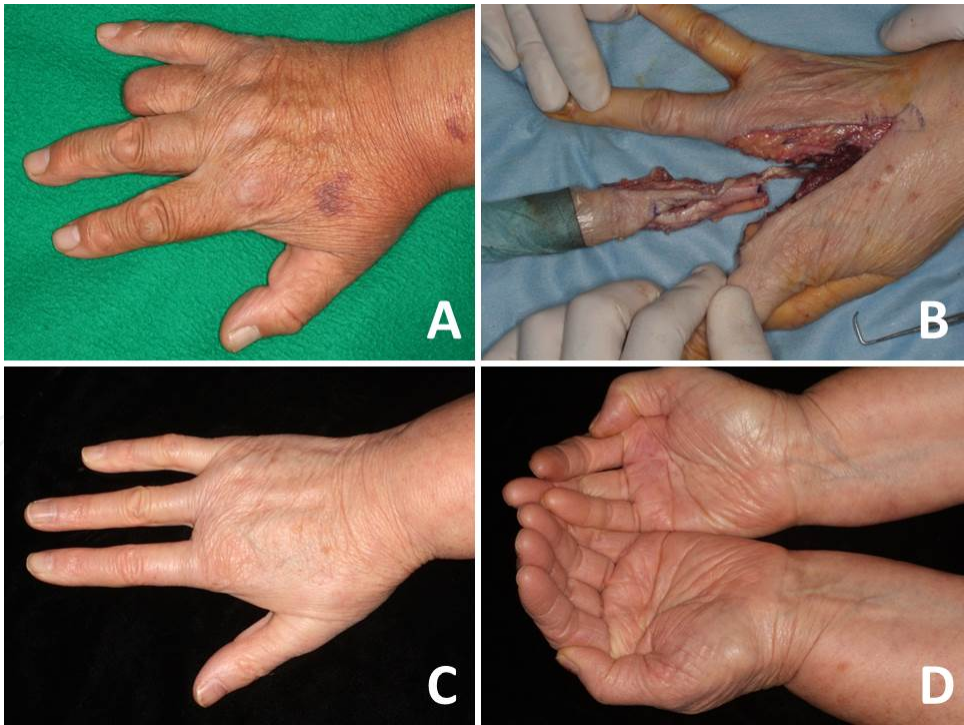
#### 3.2. *In situ* or minimally-invasive SUM

Recently, several authors have proposed conservative surgery, which involves a narrow surgical margin without amputation followed by skin grafting for *in situ* SUM and minimally-invasive SUM (Fig. 3), which is defined as a Breslow tumor thickness (TT)  $\leq 0.5$  mm [33–38]. There have also been a few case reports of two-step surgeries using artificial dermis tissue for the tentative coverage of the defect after local excision, followed by skin graft coverage after





**Figure 1.** Minimal amputation of subungual melanoma of the thumb for avoidance of functional loss. (A) Subungual melanoma on the left thumb. (B) Amputation at the interphalangeal joint.



**Figure 2.** Cosmetic and functional advantages of ray amputation for the treatment of SUM of the finger. (A) Conspicuous amputated stump of a case of subungual melanoma on the fourth finger after proximal interphalangeal amputation. (B) A case of ray amputation for melanoma of the third fingernail. (C) Inconspicuous cosmetic result with no stump after ray amputation. (D) Hand position to “scoop up water.”

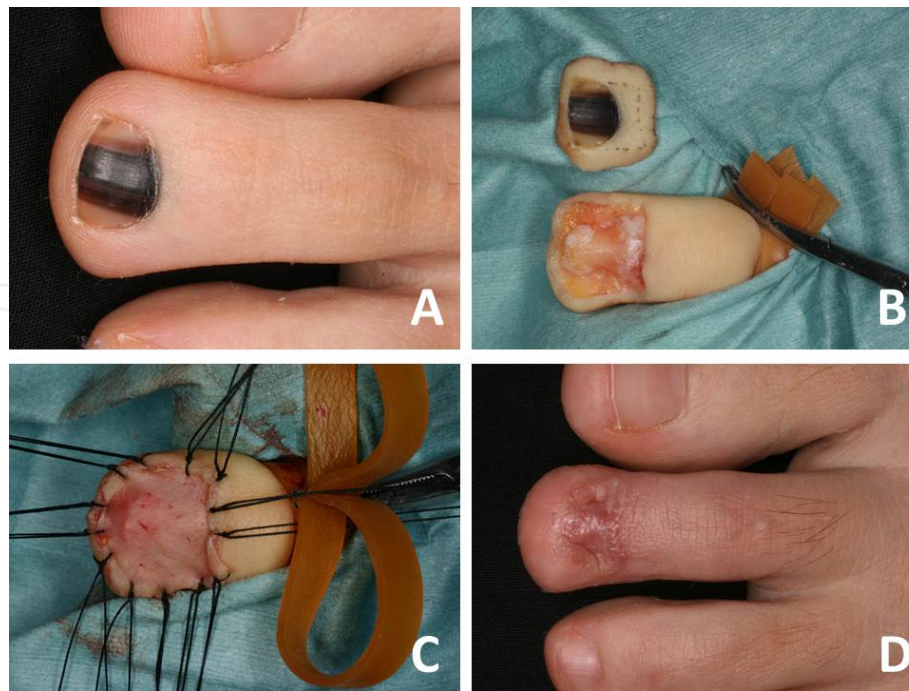
the histopathological confirmation of negative surgical margins [39, 40]. These strategies are becoming more common, although the total number of such surgeries still remains small.

### 3.3. Possibility of conservative surgery for invasive SUM

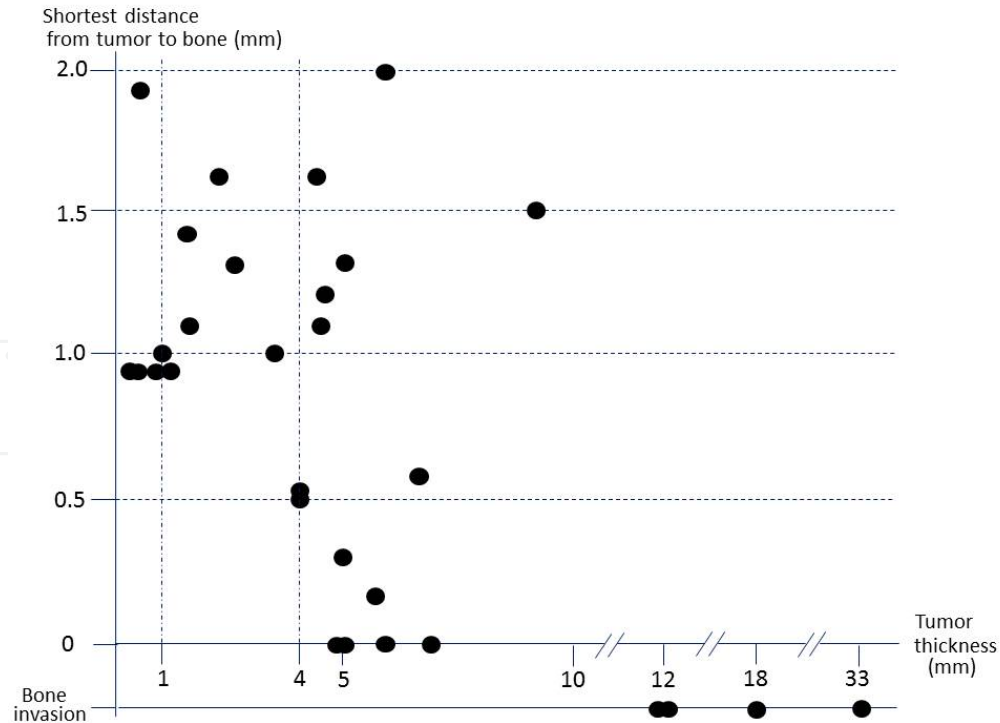
The unique anatomy of the nail apparatus described above also demonstrates that there is scant soft tissue between the nail unit and bony surface of the distal phalanx. Haneke [41] studied the distance from the tip of the nail matrix to the extensor tendon insertion of the middle finger of a young male, and the measured distance was 0.8 mm. Kim et al. [42] also studied the shortest distances between the deepest base of the nail matrix and surface of the distal phalanx in cadavers. The mean distances were 0.90 mm for thumbs, 0.72 mm for fifth fingers, 0.87 mm for first toes, and 1.09 mm for fifth toes. The mean distance of all digits was 0.90 mm. These studies have suggested that wide local excision was insufficient for the eradication of invasive SUM with a safe, deep surgical margin and appeared to be sufficient for only *in situ* or minimally-invasive SUM.

Dermatologists sometimes encounter patients with invasive SUMs that do not invade or attach to the distal phalanx. Therefore, we measured the shortest distances of 30 surgical specimens of invasive SUM between the deepest base of the tumor and the surface of the distal phalanx [43]. There were no bone invasion cases with 4 mm-thick SUMs and the shortest tumor-to-bone distances exceeded 0.9 mm in all specimens with thicknesses of <4 mm (Fig. 4). In statistical analysis, the Pearson chi-square test showed that there was a higher likelihood of bone attachment or invasion when TT exceeded 4 mm, which was statistically significant ( $P=0.009$ ). Both univariate and multivariate analyses also revealed that thick TT alone had a statistically significant effect [odds ratio 1.807 and 1.865 (95% CI 1.1085–3.008 and 1.111–3.13,  $P=0.023$  and 0.018)]. This study only focused on the histologic evaluation of deep margins and has limitations including the lack of prognostic information; however, there have also been several reports of patients with >0.5-mm-thick SUMs who underwent non-amputative surgeries and who had no local recurrence or metastasis [36, 40, 44].

These studies indicate that the patients with invasive SUMs of intermediate thicknesses may be candidates for non-amputative surgery. However, the main problem is that it is still difficult to evaluate tumor thickness by inspection or dermoscopy preoperatively. There is a possibility of the presence of an unexpectedly thicker area in the tumor than the thickness identified from an incisional biopsy, which can consequently change the surgical strategy. High-resolution ultrasound is a noninvasive examination that can evaluate tumor thickness preoperatively, and there have been several studies that reported its accuracy for the determination of tumor thickness [45–47]. However, these studies excluded SUM; therefore, its accuracy for tumor thickness evaluation in SUM remains unclear. Furthermore, an ultrasound at 20 MHz tends to overestimate thickness because of lymphocytic infiltration around the tumor or nevus remnant [48, 49]. Reflectance confocal microscopy permits the acquisition of dynamic images of the epidermis and papillary dermis with resolution to a cellular level [50] and has been experimentally used for intraoperative imaging of the nail matrix [51]. However, its limitation is the imaging depth, which cannot be deeper than 200–300  $\mu\text{m}$  [50].



**Figure 3.** Non-amputative wide local excision followed by skin grafting for *in situ* subungual melanoma. (A) *In situ* subungual melanoma on the left second toe. (B) Nail apparatus excision including the periosteum of the distal phalanx. (C) Defect coverage by skin grafting. (D) Postoperative findings 8 months after surgery.



**Figure 4.** The relationship between shortest distance from tumor to bone and tumor thickness of invasive SUM.



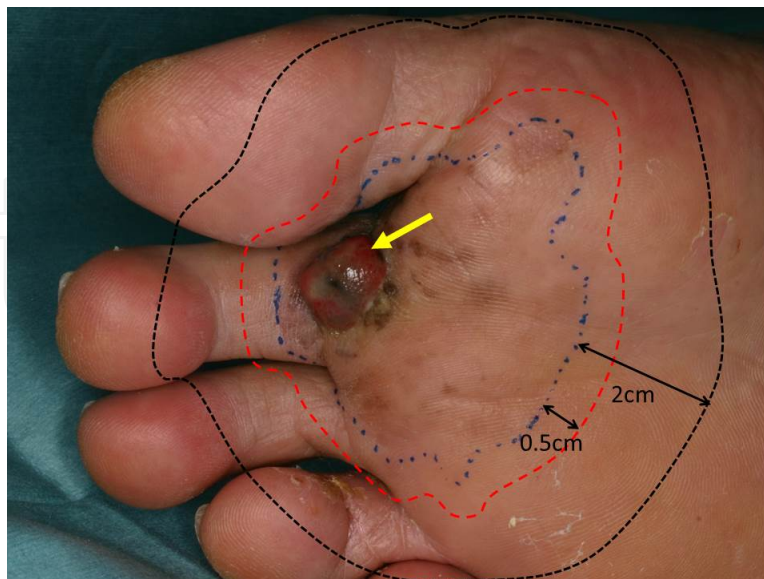
For other surgical procedures, Chow et al. has reported on wide local excision procedures involving the removal of the nail apparatus with a layer of underlying bone of 1-mm depth running parallel to the nail bed before reconstruction with skin grafting [32]. Moehrle et al. reported on the excision of SUM with the distal part of the distal phalanx (processus unguinatus), which has led to its denotation as a “functional” surgery [52].

## 4. Surgical management of ALM on the volar skin

In general, ALMs start as *in situ* lesions, with brown macules that enlarge slowly and form irregularly pigmented, asymmetric macular lesions over the years, corresponding to the radial growth phase. Thereafter, indurated nodules appear within the macular lesions and sometimes the nodules ulcerate in the so-called vertical growth phase.

### 4.1. Problems of excision margins

Because of this very slow clinical course, ALMs on the volar skin often contain *in situ* lesions at the periphery (Fig. 5). Based on the recommended lateral margins described above, the dermatological surgeons are often confused regarding the decision for lateral margins. It is still unclear whether lateral margins of 0.5–1 cm from the peripheral border of the lesion should be suitable as the peripheral lesion is considered an *in situ* lesion, or lateral margins of 2 cm from the periphery of the lesion should be selected as the entire tumor itself is regarded as an invasive lesion.

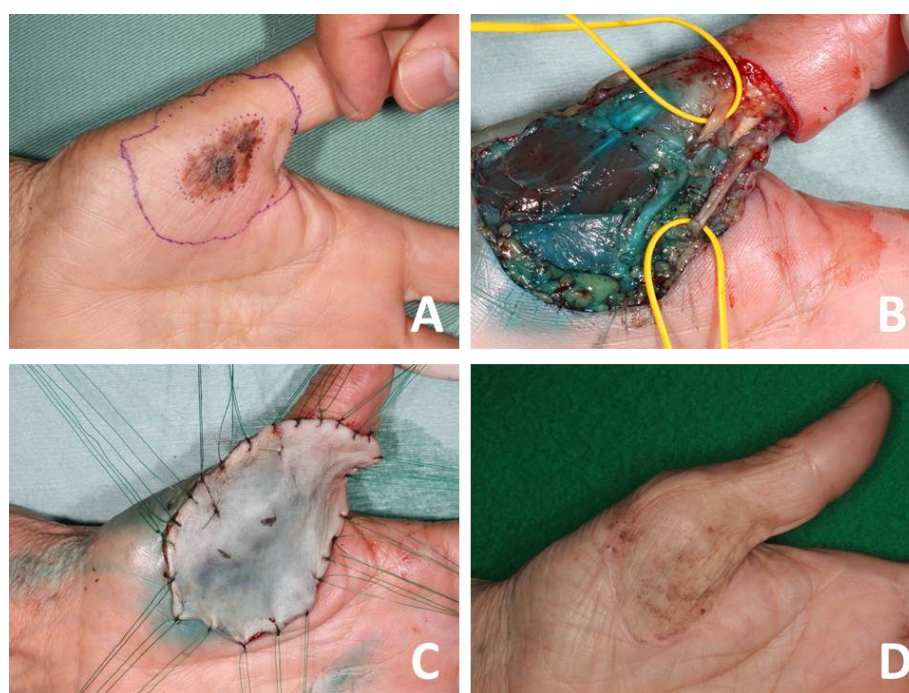


**Figure 5.** Confusion regarding excision margin for acral lentiginous melanoma which has *in situ* lesion. The arrow indicates the invasive lesion. Blue dotted line indicates the peripheral border of the *in situ* lesion. Red and black dotted lines indicate lateral margins of 0.5 cm and 2 cm from the border of the lesion, respectively.



## 4.2. ALM of the palm

In general, most ALMs on the palm are diagnosed at an early stage because the palm is the site where the patient easily notices the lesion at an earlier stage. Therefore, wide local excision is easily accomplished and the full-or split-thickness skin graft is adequate for the coverage of the surgical defect. The main point that the surgeon should pay attention to is avoiding intraoperative injuries of the palmar digital nerves, which are easily exposed during tumor excision because of the scant subcutaneous fatty tissue in some areas of the palm (Fig. 6). As for skin grafting, the skin obtained from non-weight-bearing areas of the foot is preferable because of the similarity to the quality of the palmar skin; however, the skin quality difference between the palmar skin and the skin obtained from other areas may be inconspicuous in elderly patients (Fig. 6).



**Figure 6. Surgery for the acral lentiginous melanoma on the palm.** (A) The purple line indicates a lateral margin of 1 cm from the border of the lesion. (B) After wide local excision. The palmar digital nerves are safely preserved (taped by yellow vessel loops). (C) Defect coverage by full-thickness skin grafting taken from the inguinal area. (D) Postoperative findings 24 months after surgery.

## 4.3. ALM of the sole

ALM of the sole has been traditionally difficult to find and diagnose because of its “out-of-sight” location. The lesion often precludes primary closure because of the lack of mobility of the skin on the sole and horizontal-growth of the tumor, which increases the reconstructive complexity. Therefore, after wide local excision, substantial defects have to be repaired using various methods such as skin grafting, local and distant flaps, and secondary intention healing depending on the size and site of the defect and the medical condition and lifestyle of the

patient [53]. Unlike the palm of the hands, reconstruction of the sole of the foot is difficult because of its anatomy. The sole has weight-bearing areas such as the heel. In addition, a defect on the foot may result in insufficient vascular flow [54].

#### *4.3.1. Split-thickness or full-thickness skin graft*

Although split-thickness skin grafting is considered to be adequate for non-weight-bearing areas, it has been considered to be inappropriate for the heel and distal plantar area and could lead to dismal results [55]. If the surgical defect is located on the non-weight-bearing areas such as the foot and distal plantar area, or if the patient has severe medical comorbidities or is less active, the defect may be covered by split-or full-thickness skin grafting. Although skin grafting has advantages such as being much simpler than flap reconstruction, it is considered that defects of the weight-bearing areas should be repaired using local or distant flaps in ambulatory patients.

By authors' experience, the indication for skin grafting on the heel depends on the amount of the remaining subcutaneous fat pad after tumor excision. If the primary tumor is a thinner lesion and there is no need to excise the enormous subcutaneous fat pad together with the tumor, both split-or full-thickness skin grafts may be acceptable for weight-bearing reconstruction (Fig. 7A). In contrast, neither split-nor full-thickness skin grafting is appropriate when wide local excision including the subcutaneous fat beneath the tumor is required for oncologic purposes, which may lead to exposure of the calcaneum. Insufficient cushion because of the paucity of the fat pad eventually produces an erosion or ulceration of the skin graft (Fig. 7B).

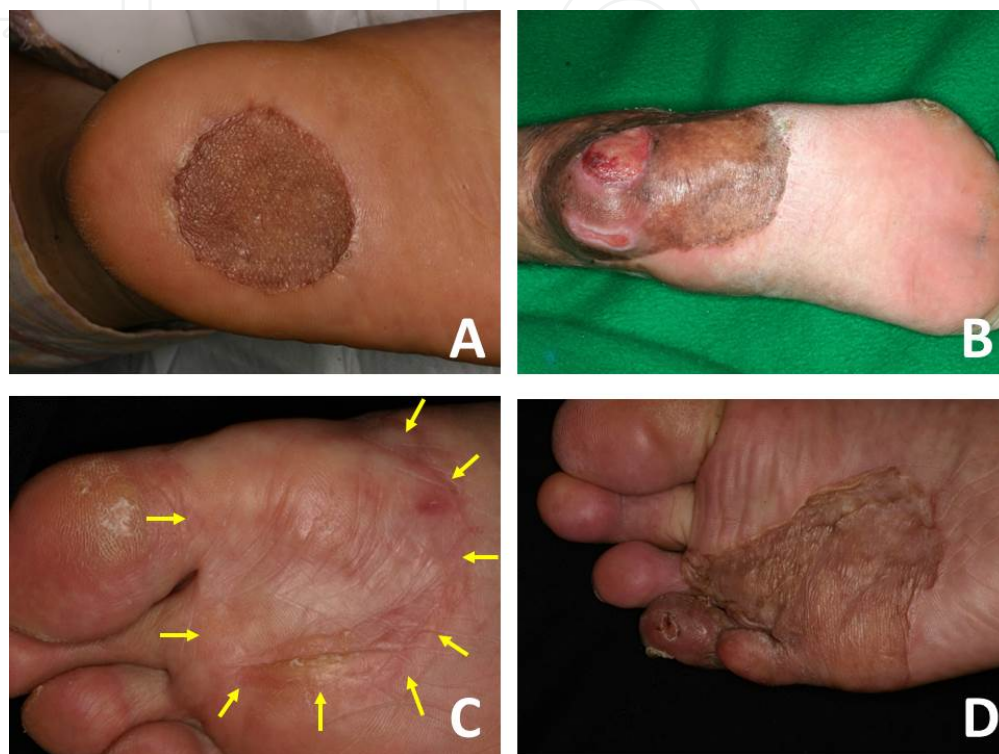
As for the distal plantar area, the weight pressure on this area is not as great as on the heel. Therefore, we think that skin grafting for this area is more acceptable than that for the heel. Even through a large amount of the subcutaneous fat may be dissected with the tumor, full-thickness skin grafting may be durable for weight pressure over a long-term postoperative course (Fig. 7C). When there is remaining subcutaneous fat, reconstruction using the split-thickness skin grafting is also acceptable (Fig. 7D).

Skin grafts are generally taken from the contralateral limb because the melanoma cells were thought to primarily metastasize via lymphatic routes [56]. In contrast, a recent study has shown that there was no difference in the rates of donor site recurrence between the ipsilateral and contralateral limbs [57].

#### *4.3.2. Local or distant flaps*

A flap reconstruction is usually recommended for the closure of weight-bearing areas of the feet. The coverage of weight-bearing areas provides well-padded tissue superior to skin grafting. Among the various flaps, the medial plantar flap is the optimal reconstructive procedure. The plantar flap can provide the same quality of skin cover for weight-bearing areas and can also provide some sensation. In particular, using heel reconstruction, the donor site is located distally and away from the lymphatics of the primary site (Fig. 8).

The distally-based sural artery neurocutaneous flap is an optional procedure for heel reconstruction. Because the donor site is the posterior aspect of the lower leg, the quality of the skin is different from that of the sole. A comparative study between the medial plantar flap and distally-based sural artery flap demonstrated that the postoperative complications were higher in patients who underwent sural artery neurocutaneous flap procedures [58].



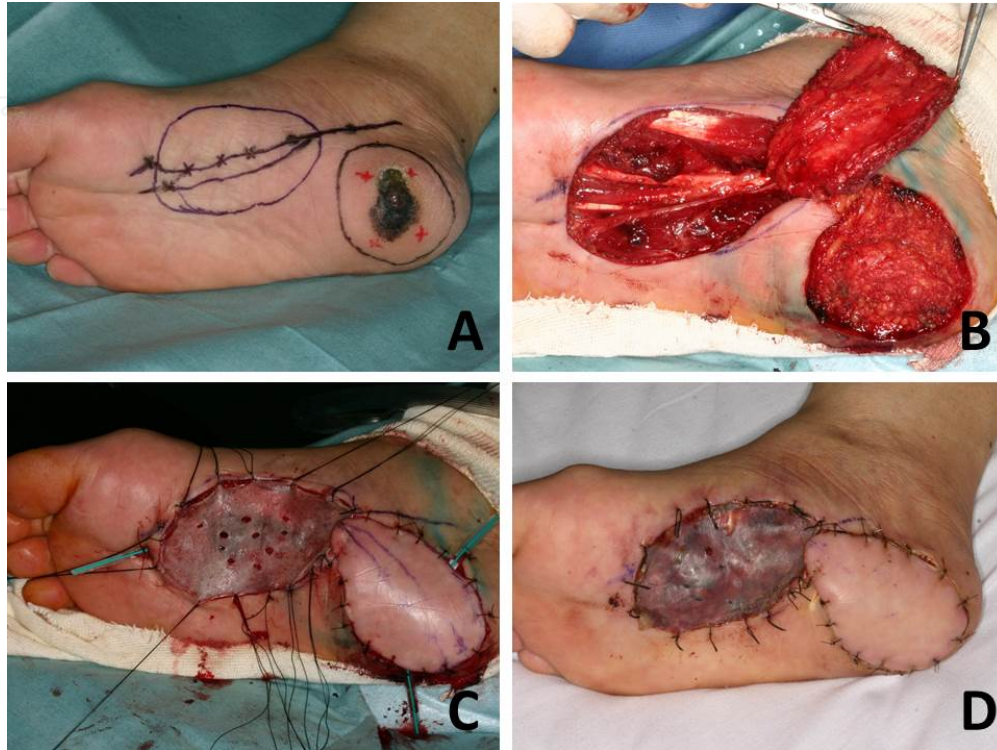
**Figure 7. Skin grafting on the weight-bearing areas after excision of acral lentiginous melanoma.** (A) Split-thickness skin grafting on the remaining subcutaneous fat pad of the heel. (B) Split-thickness skin grafting on the heel after excision of the tumor with a large amount of subcutaneous fat pad. The ulceration is visible on the skin graft. (C) Full-thickness skin grafting (arrows) on the plantar aponeurosis, 10 years after surgery. (D) Split-thickness skin grafting on the remaining subcutaneous fat, 2 years after surgery.

#### 4.3.3. Secondary intention healing

Secondary intention healing requires a long-term healing period, prolonged care such as regular and frequent dressing changes, and careful observation. According to previous reports, it took approximately 12–18 weeks to close the defects (mean defect size: 32.6–36.5 cm<sup>2</sup>) [54, 59]. Despite these drawbacks, it has the advantages of avoiding a secondary wound for tissue harvesting, a smaller scar because of the natural contraction of the wound, and granulation tissue that acts as a cushion to absorb impact while walking [54]. Recently, the effect of negative pressure wound therapy in addition to secondary intention healing has been investigated [59]. Compared with secondary intention healing alone, there was no difference in time to complete wound healing. However, the vascularity score and height of the scars was significantly better, and no wound infections during the course of treatment had occurred in the former group.



These methods clearly require a more extended period of healing time than skin grafting or flaps. Therefore, it would be appropriate to apply these methods to small-to medium-sized surgical defects.



**Figure 8. Reconstructive surgery of the acral lentiginous melanoma on the heel using medial plantar flap.** (A) The flap design and excision margin of the tumor on the heel. (B) Elevation of the medial plantar flap. (C) Defect coverage by flap and the coverage of the donor site by skin grafting. (D) Postoperative findings 9 days after surgery.

## 5. Conclusions

Increased understanding of the molecular biology and pathogenesis of melanoma may lead to the development of novel therapeutic agents and treatment plans for melanoma. However, surgery is still the mainstay of treatment as there are no proven effective adjuvant systemic treatments.

Although several reliable national guidelines for melanoma have been produced using the evidence-based method, there are still some controversies in the treatment of ALM. Because of the biological and unique anatomical specificity of ALM, It is still unclear whether the thickness of ALM and recommended lateral margins are the same as that with other subtypes. Large randomized prospective studies with long-term follow up are necessary to fully evaluate surgery for ALM in the future. The accumulation of evidence produced by such studies will lead to the development of novel ALM treatments in the melanoma guidelines.



## Acknowledgements

This work was partly supported by the National Cancer Center Research and Development Fund (26-A-4).

## Author details

Yasuhiro Nakamura\*, Yukiko Teramoto, Sayuri Sato and Akifumi Yamamoto

\*Address all correspondence to: ynakamur@saitama-med.ac.jp

Department of Skin Oncology/Dermatology, Comprehensive Cancer Center, Saitama Medical University International Medical Center, Saitama, Japan

## References

- [1] Parkin D. M., Bray F., Ferlay J. & Pisani P. (2005). Global cancer statistics, 2002. *CA Cancer J Clin*, 55, 74-108.
- [2] Sneyd M. & Cox B. (2006). The control of melanoma in New Zealand. *N Z Med J*, 119, U2169.
- [3] Makredes M., Hui S. K. & Kimball A. B. (2010). Melanoma in Hong Kong between 1983 and 2002: a decreasing trend in incidence observed in a complex socio-political and economic setting. *Melanoma Res*, 20, 427-430.
- [4] Ishihara K., Saida T., Otsuka F. & Yamazaki N. (2008). Statistical profiles of malignant melanoma and other skin cancers in Japan: 2007 update. *Int J Clin Oncol*, 13, 33-41.
- [5] Roh M. R., Kim J. & Chung K. Y. (2010). Treatment and outcomes of melanoma in acral location in Korean patients. *Yonsei Med J*, 51, 562-568.
- [6] Markovic S. N., Erickson L. A., Rao R. D., Weenig R. H., Pockaj B. A., Bardia A., Vachon C. M., Schild S. E., McWilliams R. R., Hand J. L., Laman S. D., Kottschade L. A., Maples W. J., Pittelkow M. R., Pulido J. S., Cameron J. D. & Creagan E. T. (2007). Malignant melanoma in the 21st century, part 1: epidemiology, risk factors, screening, prevention, and diagnosis. *Mayo Clin Proc*, 82, 364-380.
- [7] Arrington J. H., 3rd, Reed R. J., Ichinose H. & Krentz E. T. (1977). Plantar lentiginous melanoma: a distinctive variant of human cutaneous malignant melanoma. *Am J Surg Pathol*, 1, 131-143.

- [8] Clark W. H., Jr., Elder D. E. & Van Horn M. (1986). The biologic forms of malignant melanoma. *Hum Pathol*, 17, 443-450.
- [9] Metzger S., Ellwanger U., Stroebel W., Schiebel U., Rassner G. & Fierlbeck G. (1998). Extent and consequences of physician delay in the diagnosis of acral melanoma. *Melanoma Res*, 8, 181-186.
- [10] Phan A., Touzet S., Dalle S., Ronger-Savle S., Balme B. & Thomas L. (2006). Acral lentiginous melanoma: a clinicoprognostic study of 126 cases. *Br J Dermatol*, 155, 561-569.
- [11] Newell G. R., Sider J. G., Bergfelt L. & Kripke M. L. (1988). Incidence of cutaneous melanoma in the United States by histology with special reference to the face. *Cancer Res*, 48, 5036-5041.
- [12] Curtin J. A., Fridlyand J., Kageshita T., Patel H. N., Busam K. J., Kutzner H., Cho K. H., Aiba S., Brocker E. B., LeBoit P. E., Pinkel D. & Bastian B. C. (2005). Distinct sets of genetic alterations in melanoma. *N Engl J Med*, 353, 2135-2147.
- [13] Veronesi U., Cascinelli N., Adamus J., Balch C., Bandiera D., Barchuk A., Bufalino R., Craig P., De Marsillac J., Durand J. C. & et al. (1988). Thin stage I primary cutaneous malignant melanoma. Comparison of excision with margins of 1 or 3 cm. *N Engl J Med*, 318, 1159-1162.
- [14] Cohn-Cedermark G., Rutqvist L. E., Andersson R., Breivald M., Ingvar C., Johansson H., Jonsson P. E., Krysaner L., Lindholm C. & Ringborg U. (2000). Long term results of a randomized study by the Swedish Melanoma Study Group on 2-cm versus 5-cm resection margins for patients with cutaneous melanoma with a tumor thickness of 0.8-2.0 mm. *Cancer*, 89, 1495-1501.
- [15] Khayat D., Rixe O., Martin G., Soubrane C., Banzet M., Bazex J. A., Lauret P., Verola O., Auclerc G., Harper P. & Banzet P. (2003). Surgical margins in cutaneous melanoma (2 cm versus 5 cm for lesions measuring less than 2.1-mm thick). *Cancer*, 97, 1941-1946.
- [16] Balch C. M., Soong S. J., Smith T., Ross M. I., Urist M. M., Karakousis C. P., Temple W. J., Mihm M. C., Barnhill R. L., Jewell W. R., Wanebo H. J. & Desmond R. (2001). Long-term results of a prospective surgical trial comparing 2 cm vs. 4 cm excision margins for 740 patients with 1-4 mm melanomas. *Ann Surg Oncol*, 8, 101-108.
- [17] Karakousis C. P. (1996). Surgical treatment of malignant melanoma. *Surg Clin North Am*, 76, 1299-1312.
- [18] McKinnon J. G., Starritt E. C., Scolyer R. A., McCarthy W. H. & Thompson J. F. (2005). Histopathologic excision margin affects local recurrence rate: analysis of 2681 patients with melanomas  $\leq 2$  mm thick. *Ann Surg*, 241, 326-333.
- [19] Kunishige J. H., Brodland D. G. & Zitelli J. A. (2012). Surgical margins for melanoma in situ. *J Am Acad Dermatol*, 66, 438-444.

- [20] Kenady D. E., Brown B. W. & McBride C. M. (1982). Excision of underlying fascia with a primary malignant melanoma: effect on recurrence and survival rates. *Surgery*, 92, 615-618.
- [21] Holmstrom H. (1992). Surgical management of primary melanoma. *Semin Surg Oncol*, 8, 366-369.
- [22] Grotz T. E., Glorioso J. M., Pockaj B. A., Harmsen W. S. & Jakub J. W. (2013). Preservation of the deep muscular fascia and locoregional control in melanoma. *Surgery*, 153, 535-541.
- [23] Dawber R. P. & Colver G. B. (1991). The spectrum of malignant melanoma of the nail apparatus. *Semin Dermatol*, 10, 82-87.
- [24] Blessing K., Kernohan N. M. & Park K. G. (1991). Subungual malignant melanoma: clinicopathological features of 100 cases. *Histopathology*, 19, 425-429.
- [25] Finley R. K., 3rd, Driscoll D. L., Blumenson L. E. & Karakousis C. P. (1994). Subungual melanoma: an eighteen-year review. *Surgery*, 116, 96-100.
- [26] Banfield C. C., Redburn J. C. & Dawber R. P. (1998). The incidence and prognosis of nail apparatus melanoma. A retrospective study of 105 patients in four English regions. *Br J Dermatol*, 139, 276-279.
- [27] Takematsu H., Obata M., Tomita Y., Kato T., Takahashi M. & Abe R. (1985). Subungual melanoma. A clinicopathologic study of 16 Japanese cases. *Cancer*, 55, 2725-2731.
- [28] Tan K. B., Moncrieff M., Thompson J. F., McCarthy S. W., Shaw H. M., Quinn M. J., Li L. X., Crotty K. A., Stretch J. R. & Scolyer R. A. (2007). Subungual melanoma: a study of 124 cases highlighting features of early lesions, potential pitfalls in diagnosis, and guidelines for histologic reporting. *Am J Surg Pathol*, 31, 1902-1912.
- [29] Daly J. M., Berlin R. & Urmacher C. (1987). Subungual melanoma: a 25-year review of cases. *J Surg Oncol*, 35, 107-112.
- [30] Haneke E. (2012). Ungual melanoma-controversies in diagnosis and treatment. *Dermatol Ther*, 25, 510-524.
- [31] O'Leary J. A., Berend K. R., Johnson J. L., Levin L. S. & Seigler H. F. (2000). Subungual melanoma. A review of 93 cases with identification of prognostic variables. *Clin Orthop Relat Res*, 206-212.
- [32] Chow W. T., Bhat W., Magdub S. & Orlando A. (2013). In situ subungual melanoma: digit salvaging clearance. *J Plast Reconstr Aesthet Surg*, 66, 274-276.
- [33] Clarkson J. H., McAllister R. M., Cliff S. H. & Powell B. (2002). Subungual melanoma in situ: two independent streaks in one nail bed. *Br J Plast Surg*, 55, 165-167.
- [34] Lazar A., Abimelec P. & Dumontier C. (2005). Full thickness skin graft for nail unit reconstruction. *J Hand Surg Br*, 30, 194-198.

- [35] High W. A., Quirey R. A., Guillen D. R., Munoz G. & Taylor R. S. (2004). Presentation, histopathologic findings, and clinical outcomes in 7 cases of melanoma in situ of the nail unit. *Arch Dermatol*, 140, 1102-1106.
- [36] Cohen T., Busam K. J., Patel A. & Brady M. S. (2008). Subungual melanoma: management considerations. *Am J Surg*, 195, 244-248.
- [37] Imakado S., Sato H. & Hamada K. (2008). Two cases of subungual melanoma in situ. *J Dermatol*, 35, 754-758.
- [38] Sureda N., Phan A., Poulalhon N., Balme B., Dalle S. & Thomas L. (2011). Conservative surgical management of subungual (matrix derived) melanoma: report of seven cases and literature review. *Br J Dermatol*, 165, 852-858.
- [39] Hayashi K., Uhara H., Koga H., Okuyama R. & Saida T. (2012). Surgical treatment of nail apparatus melanoma in situ: the use of artificial dermis in reconstruction. *Dermatol Surg*, 38, 692-694.
- [40] Smock E. D., Barabas A. G. & Geh J. L. (2010). Reconstruction of a thumb defect with Integra following wide local excision of a subungual melanoma. *J Plast Reconstr Aesthet Surg*, 63, e36-37.
- [41] Haneke E. (2006). Surgical anatomy of the nail apparatus. *Dermatol Clin*, 24, 291-296.
- [42] Kim J. Y., Jung H. J., Lee W. J., Kim do W., Yoon G. S., Kim D. S., Park M. J. & Lee S. J. (2011). Is the distance enough to eradicate in situ or early invasive subungual melanoma by wide local excision? from the point of view of matrix-to-bone distance for safe inferior surgical margin in Koreans. *Dermatology*, 223, 122-123.
- [43] Nakamura Y., Fujisawa Y., Teramoto Y, Sato S, Yamada K, Sekine K, Fujimoto M, Otsuka F & Yamamoto A. (2014) Tumor-to-bone distance of invasive subungual melanoma: an analysis of 30 cases. *J Dermatol*, 41, 872-877.
- [44] Rayatt S. S., Dancey A. L. & Davison P. M. (2007). Thumb subungual melanoma: is amputation necessary? *J Plast Reconstr Aesthet Surg*, 60, 635-638.
- [45] Machet L., Belot V., Naouri M., Boka M., Mourtada Y., Giraudeau B., Laure B., Perriaud A., Machet M. C. & Vaillant L. (2009). Preoperative measurement of thickness of cutaneous melanoma using high-resolution 20 MHz ultrasound imaging: A mono-center prospective study and systematic review of the literature. *Ultrasound Med Biol*, 35, 1411-1420.
- [46] Gambichler T., Moussa G., Bahrenberg K., Vogt M., Ermert H., Weyhe D., Altmeyer P. & Hoffmann K. (2007). Preoperative ultrasonic assessment of thin melanocytic skin lesions using a 100-MHz ultrasound transducer: a comparative study. *Dermatol Surg*, 33, 818-824.



- [47] Guitera P., Li L. X., Crotty K., Fitzgerald P., Mellenbergh R., Pellacani G. & Menzies S. W. (2008). Melanoma histological Breslow thickness predicted by 75-MHz ultrasonography. *Br J Dermatol*, 159, 364-369.
- [48] Serrone L., Solivetti F. M., Thorel M. F., Eibenschutz L., Donati P. & Catricala C. (2002). High frequency ultrasound in the preoperative staging of primary melanoma: a statistical analysis. *Melanoma Res*, 12, 287-290.
- [49] Pellacani G. & Seidenari S. (2003). Preoperative melanoma thickness determination by 20-MHz sonography and digital videomicroscopy in combination. *Arch Dermatol*, 139, 293-298.
- [50] Calzavara-Pinton P., Longo C., Venturini M., Sala R. & Pellacani G. (2008). Reflectance confocal microscopy for in vivo skin imaging. *Photochem Photobiol*, 84, 1421-1430.
- [51] Debarbieux S., Hospod V., Depaepe L., Balme B., Poulalhon N. & Thomas L. (2012). Perioperative confocal microscopy of the nail matrix in the management of in situ or minimally invasive subungual melanomas. *Br J Dermatol*, 167, 828-836.
- [52] Moehrle M., Metzger S., Schippert W., Garbe C., Rassner G. & Breuninger H. (2003). "Functional" surgery in subungual melanoma. *Dermatol Surg*, 29, 366-374.
- [53] Shapiro R. L. (2002). Surgical approaches to malignant melanoma. Practical guidelines. *Dermatol Clin*, 20, 681-699, ix.
- [54] Jung J. Y., Roh H. J., Lee S. H., Nam K. & Chung K. Y. (2011). Comparison of secondary intention healing and full-thickness skin graft after excision of acral lentiginous melanoma on foot. *Dermatol Surg*, 37, 1245-1251.
- [55] Evans G. R., Friedman J., Shenaq J. & Mosser S. (1997). Plantar flap reconstruction for acral lentiginous melanoma. *Ann Surg Oncol*, 4, 575-578.
- [56] Roberts D. L., Anstey A. V., Barlow R. J., Cox N. H., Newton Bishop J. A., Corrie P. G., Evans J., Gore M. E., Hall P. N. & Kirkham N. (2002). U.K. guidelines for the management of cutaneous melanoma. *Br J Dermatol*, 146, 7-17.
- [57] Schumacher H. H., Chia H. L. & Simcock J. W. (2010). Ipsilateral skin grafts for lower limb melanoma reconstruction are safe. *Plast Reconstr Surg*, 125, 89e-91e.
- [58] Rashid M., Hussain S. S., Aslam R. & Illahi I. (2003). A comparison of two fasciocutaneous flaps in the reconstruction of defects of the weight-bearing heel. *J Coll Physicians Surg Pak*, 13, 216-218.
- [59] Oh B. H., Lee S. H., Nam K. A., Lee H. B. & Chung K. Y. (2013). Comparison of negative pressure wound therapy and secondary intention healing after excision of acral lentiginous melanoma on the foot. *Br J Dermatol*, 168, 333-338.