

We are IntechOpen, the world's leading publisher of Open Access books Built by scientists, for scientists

6,900

Open access books available

185,000

International authors and editors

200M

Downloads

Our authors are among the

154

Countries delivered to

TOP 1%

most cited scientists

12.2%

Contributors from top 500 universities



WEB OF SCIENCE™

Selection of our books indexed in the Book Citation Index
in Web of Science™ Core Collection (BKCI)

Interested in publishing with us?
Contact book.department@intechopen.com

Numbers displayed above are based on latest data collected.
For more information visit www.intechopen.com



Non-Surgical Treatment of Class III with Multiloop Edgewise Arch-Wire (MEAW) Therapy

Paulo Beltrão

Additional information is available at the end of the chapter

<http://dx.doi.org/10.5772/59257>

1. Introduction

The incidence of class III malocclusion among the western population is low, but in Japan and South Korea is high and since many patients don't accept orthognatic surgery, a conservative/camouflage treatment is often necessary. The MEAW (multiloop edgewise arch wire) was developed in 1967 by Dr. Young H. Kim to correct open bite malocclusions and was found to be extremely effective. Further development of Meaw technique extends its application to treat any type of malocclusion, especially Class III malocclusion.

The MEAWs are constructed with 0.016 x 0.022 stainless steel (bracket 0.018 inch slot) or 0.017x0.025 stainless steel (bracket 0.022– inch slot). The arches have ideal arch form with five loops on each side of the arch.

Prof. Sadao Sato developed the use of MEAW and introduced different concepts about the etiology of malocclusions. According to Sato genetics may not be the only reason to class III malocclusion, the posterior discrepancy may be the major contributing factor to class III malocclusion.

The degree of basicranial flexion differs in the various types of malocclusion. According to Hooper (1986) the spheno-basilar articulation is the most important among the cranial bones and it is where the movement of flexion-extension occurs. The cranial base angles (Na-S-Ar) comes to approximately 124,2 ° in class I patterns.

From this average value a more obtuse (extension) angle indicates skeletal Class II and a more acute (flexion) angle means skeletal Class III. The rotating movement of the cranial base (flexion/extension) occurs at the spheno-occipital articulation and it is transmitted to the maxilla through the Vomer. This dynamic mechanism has a great influence on the growth pattern of an individual during the growth period.

When the sphenoid makes flexion the rotating force of the vomer is postero-inferior and the maxilla is strongly pushed down. This causes vertical elongation of the maxillary complex, short anteroposterior dimension and posterior crowding. This is related to the development of a class III skeletal frame (Sato 2001).

The posterior discrepancy increases the probability of wisdom teeth impaction and once their impaction occurs a “squeezing-out” effect may occur, causing an over-eruption of the adjacent teeth, flatten the posterior occlusal plane and an increase in the posterior occlusal vertical dimension. The over-erupted molars produce occlusal interferences that act as a fulcrum causing a mandibular forward adaptation with subluxation of the mandibular condyles and active remodeling of the condylar cartilage. The result is a mandibular prognathism.

The skeletal Class III relationships may be due to a lack of sagittal development of maxillary or mandibular overdevelopment, or a combination of both.

Skeletal class III malocclusion is usually characterized by a steep mandibular plane angle, obtuse gonial angle, a small cranial base angle which may displace the glenoid fossa anteriorly to cause a forward positioning of the mandible, flat occlusal plane, short antero posterior diameter of the maxilla, increased vertical growth of the maxilla, labial tipping of the maxillary teeth, lingual tipping of the mandibular teeth.

In adults patients, without growing ability, orthognatic surgery is indicated for severe skeletal class III malocclusion, but moderate class III cases (borderline cases) can be treated orthodontically if the patients refuse surgery. The MEAW is often used in skeletal class III treatment without orthognatic surgery or extraction of intermediate teeth.

The objectives of the treatment are: a) to eliminate posterior discrepancy, b) to intrude the posterior teeth and to upright them, c) reconstruction the occlusal plane (steepening the occlusal plane) which induces mandibular backward adaption. The entire lower dentition is moved distally and uprighted using a MEAW with short class III elastics after extraction of the third molars. The skeletal features of the class III malocclusions are closely related to the deviation in the vertical aspect of the occlusion. According to this correcting the occlusal plane by controlling the vertical dimension is extremely important in the treatment of class III malocclusion.

To eliminate the posterior discrepancy, the upper and lower third molars should be extracted prior to the onset of treatment. The upper second molars can be extracted, if the patient is young and if the the upper third molars have quality in terms of size, shape and direction of eruption. This approach will allow steepen the occlusal plane with the elimination of the “squeezing-out effect” at the upper molars. The treatment mechanics use tip back bend activations of the MEAW and vertical or short class III elastics (3/16 inch – 6 oz) on the anterior teeth.

The steps of treatment of the class III malocclusion are: a) Levelling, b) elimination of occlusal interference,,c) establishing mandibular position d) reconstruction of the occlusal plane, e) achieving a physiological occlusion.

Sassouni and Nanda (1964) proved the vertical disproportion were, in many cases, at the origin of anteroposterior dysplasias. Therefore, treatment strategies should focus on vertical control in order to correct anteroposterior disharmony.

Angle(1899) – The class III malocclusion occurred when lower teeth occluded mesial to their normal relationship by the width of one premolar or even more in extreme cases. The class III can be defined as a skeletal facial deformity characterized by a forward mandibular position with respect to the cranial base and/or maxilla.

2. The etiology of class III malocclusion

- Genetics-an example is the famous mandibular prognathism of Habsburg family.
- Syndromes
- Crouzon syndrome
- Acromegaly
- Gorlin and Goltz syndrome Hypertrophy
- Cleido cranial dysplasia
- Achondroplasia
- Environmental factors-ex : thyroid deficiency cause large tongue, causing mandibular prognathism
- Functional factors
- Naso-respiratory diseases and enlarged tonsils
- Mental diseases-compulsive habits of protruding the mandible
- Posterior crowding – “The posterior squeezing out effect “

3. Classification of class III malocclusion

Moyers classified the class III malocclusion according the cause: osseous; muscular; dental. According to him, it was necessary to determine whether the mandible on closure was in centric relation or “convenient” anterior position.

In 1966 Charles Tweed divided class III malocclusion in pseudoclass III and skeletal class III. Tweed also divided the class III onto two distinct categories : The category A-the FMA ranges between 10° and 22°, with a large mandible ; underdeveloped maxilla and a ANB between 7° to 10° and the category B – FMA ranges between 30° to 50° with an obtuse gonial angle and a lower lip overactive.

The characteristics of Pseudoclass III are the following: normal mandible and underdeveloped maxilla, concave straight profile, skeletal pattern is class I, normal gonial angle and the retrusion of the mandible is possible.

The skeletal class III discrepancy may be the result of a large mandible, a small maxilla, a distally positioned maxilla or a combination of the three. Vertically the class III can be divided in high angle, average and low angle.

The class III subdivision is characterized by a class I molar relation on one side and a class III on the other side.

4. The differential diagnosis of skeletal class III malocclusion

The diagnostic criteria for pseudo class III according to Rabie and Yan Gu (AJODO 2000) is the following : a) 72 % showed no family history; b) molar class I in CR and class III at habitual occlusion ; c) decreased midface length ; d) forward mandibular position with normal length ; e) retroclined upper incisors with normal lower incisors; f) presence of mandibular anterior sliding into a edge-to-edge or crossbite relationship due to premature tooth contact (with CO–CR discrepancy), absence of skeletal signs of class III malocclusion. The differential diagnosis of skeletal class III malocclusion with skeletal class I include the following differences:

- In class III the SNA is lower
- The SNB is greater in class III
- The mean ANB angle in class III is negative
- The gonial angle is more open in class III
- The lower anterior facial height is increased
- Cranial base angle is smaller in class III patients

The dentoalveolar class III malocclusion present a normal ANB angle and a lingual tipping of upper incisors and labial tipping of lower incisors. The skeletal class III malocclusion show a maxillary retrusion or mandibular protrusion, or both with negative ANB, increased mandibular length, increased gonial angle, labial tipping of upper incisors and lingual tipping of lower incisors.

There are three important diagnostic principles of class III such as:

- To determine whether the mandible on closure is in centric relation or in a “convenient “ anterior position
- Identify the nature of skeletal discrepancy
- To evaluate the potential growth and development of a patient with a class III malocclusion

5. Treatment of pseudo class III malocclusion

The ideal age to treat pseudo class III is between 6 to 9 years, because treating the pseudo class III during the mixed dentition has some advantages such as : the stability of correction is better, prevent unfavourable growth of skeletal frame, prevent deleterious habits. There are many options to treat the pseudo class III malocclusion such as : equilibration of occlusion, bionator appliance, fixed appliance, acrylic crowns, acrylic inclined planes, functional appliance therapy, and orthopaedic appliances.

6. Treatment of skeletal class III malocclusion in growing patients

During the primary, mixed and permanent dentition the growth is present and the treatment is different from when the growth is finished. The first step is to distinguish if the class III is due to maxillary undergrowth, mandibular overgrowth or both or a skeletal class I with anterior cross bite. When the class III is due to mandibular overgrowth the options of treatment are : chin cap therapy, reverse class III activator (to produce retrusive force on the mandible), low or high pull head gear (HPHG) to control posterior eruption.

When class III is due to maxillary undergrowth and/or retrognathic maxillary with a orthognathic mandible, it is necessary to promote the growth and protect the maxillary using a face mask (Delaire or Petit) or a functional appliance therapy (activator or Frankel III regulator).

7. Treatment of skeletal class III malocclusion in non growing patients

The treatment of class III in adults and non growing patients can be a surgical treatment or a camouflage treatment. When a non growing patient is diagnosed as a class III malocclusion and has a strong skeletal component, the treatment of choice is usually orthodontic/orthognathic surgery. After determined that the surgery will be necessary the surgeon usually waits until the growth is finished. Maxillary growth may be completed at age 14-15 years, but mandibular growth may continue until 20 years. Then the orthodontist will decompensate the incisors and after that the surgery will be done.

8. Camouflage treatment of class III malocclusion

Beyond the adolescent growth spurt, to correct a mild skeletal class III, teeth must be displaced relative to their supporting bone to mask the underlying class III discrepancy by dental compensation. This is termed camouflage treatment. A patient with class III malocclusion, with the growth completed, a slight skeletal class III, acceptable alignment of teeth and acceptable facial proportions is a good candidate for a camouflage treatment. Since 1967 the MEAW

technique has proved to be an effective treatment camouflage and a non-surgical treatment of class III malocclusion. The extraction therapy of premolars may have limited applicability in class III treatment, for example extractions in the lower arch will increase the lingual inclination of the incisors which were already inclined. Another contraindication to extract is the cases that combine orthodontics and surgery.

9. Non-surgical treatment of class III with multiloop edgewise archwire(MEAW) therapy

Many times during the diagnosis process the etiology of the malocclusion and the mechanism of its development are depreciated. The cephalometric analysis doesn't clearly shows the cause of malocclusion, it only localizes the site of skeletal malocclusion and shows the degree of deviation. This means that current orthodontics many times identifies and treats symptoms rather than aiming the cause. Hence there is a need for the insertion of a new treatment philosophy based on the function rather than esthetic needs of the patient. It is necessary to understand the dynamic mechanism of development of malocclusion and to know the treatment technique for orthodontic occlusal reconstruction.

9.1. The dynamic mechanism of the development of class III malocclusion

During the human evolution the cranial base was modified with the bipedalism and erect posture, producing a flexion of the cranial base and a displacement of the foramen occipitale magnum from one end to the middle of the skull. The result of this displacement, is a vertical growth pattern rather than horizontal. The degree of basicranial flexion is different according to the type of malocclusion. Thus a cranial base angle (Na-S-Ar) about 124,2 degrees is characteristic of class I pattern. When the angle is closed to 130 degrees (extension of cranial base) indicates a class II malocclusion and a more acute angle closer to 120 degrees (flexion) indicates a skeletal class III. If more severe is the class III pattern, more pronounced is the flexion of the cranial base and greater is the tendency of vertical growth. Thus the vertical component of class III malocclusion is very important, contrary to be considered just a sagittal problem. According to this the use of chin cap, long class III elastics, premolar extraction, surgery are treatment approaches of skeletal class III malocclusion in the sagittal direction, neglecting the vertical component. When the angle of cranial base presents a flexion, the rotating movement occurs at the spheno-occipital synchondrosis and it is transmitted to the maxillary through the vomer. This dynamic mechanism affects the growth pattern of the growing patients. With the flexion of the sphenoid, the rotating force of the vomer is posteroinferior and the maxillary is pushed down. This produce vertical elongation, undersized sagittal dimension and posterior crowding of the maxillary. The lack of maxillary translation creates a deficit of space in the tuberosity, and a posterior crowding, that causes the "squeezing out effect ". The squeezing out effect is an over-eruption of the molars and modifies the inclination of the occlusal plane, making it flatter. Once the over-eruption of the molars occurs, then occlusal interferences appear and in order to avoid them, the mandible adapts for-

ward. This mandibular forward movement, produces a distraction of the mandibular condyles and active reformulation of the condylar cartilage, resulting in mandibular prognathism.

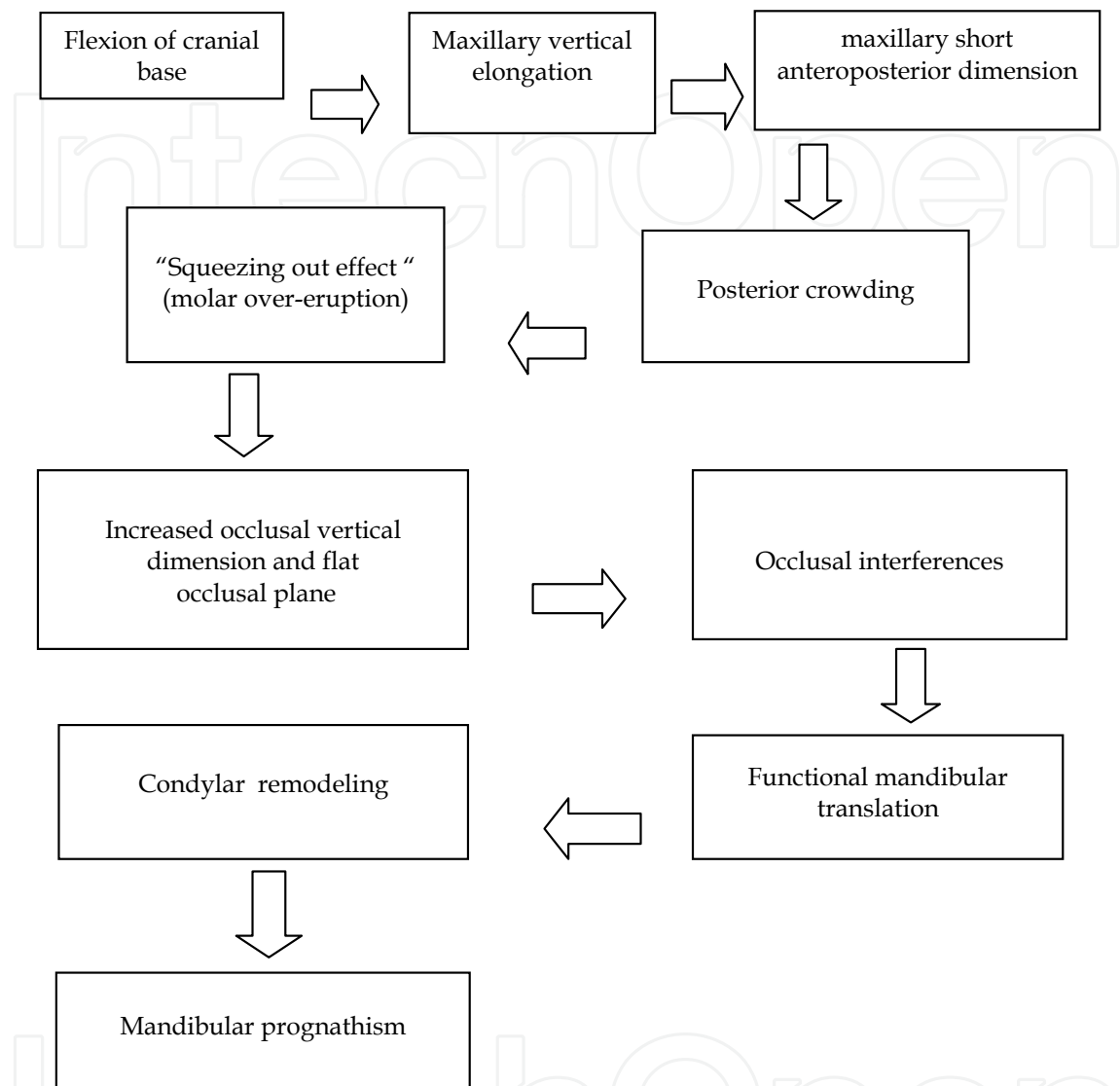


Figure 1 - The dynamic mechanism of the development of class III malocclusion

9.2. General characterization of class III malocclusion

The class III malocclusion has the following characteristics:

- Increased vertical dimension
- short maxillary length
- posterior crowding
- Increased FH-MP angle

- Labial tipping of maxillary teeth
- lower anterior teeth are inclined lingually (dento-alveolar compensation)
- ANB angle is negative
- flexion of the cranial base
- Skeletal frame is class III (APDI is more than 85)

9.3. Non-surgical treatment of class III malocclusion

It is very important to understand the dynamic mechanism of the development of class III malocclusion to establish a correct treatment plan. In the development of class III malocclusion the key point is the molar over-eruption (due to the posterior crowding) which is responsible for the flatness of the upper posterior occlusal plane. The upper posterior flat occlusal plane produces a forward mandibular adaptation. According to this there are two significant goals to attain with the treatment of class III:

- Elimination of the posterior crowding
- To Rebuild the occlusal plane (to steepen the upper posterior occlusal plane)

The posterior crowding is usually solved, by extraction of third molars prior to the onset of the treatment. The upper second molars can be extracted if the patient is young and the third molars are too high in the tuberosity. Before the decision to extract the upper second molars, the third molars should be radiographically evaluated to check if they have correct size and shape as well as appropriate position and inclination to erupt properly, replacing the extracted second molars. Another significant goal to attain with the treatment of class III is the reconstruction of the occlusal plane, because the class III malocclusion requires a steeper occlusal plane for backward adaptation of the mandible. The tip back bends of the MEAW correct the premolars and molars to an upright position 3 to 5° from the premolars teeth to molar area along with short class III elastics (6 oz) on the anterior teeth.

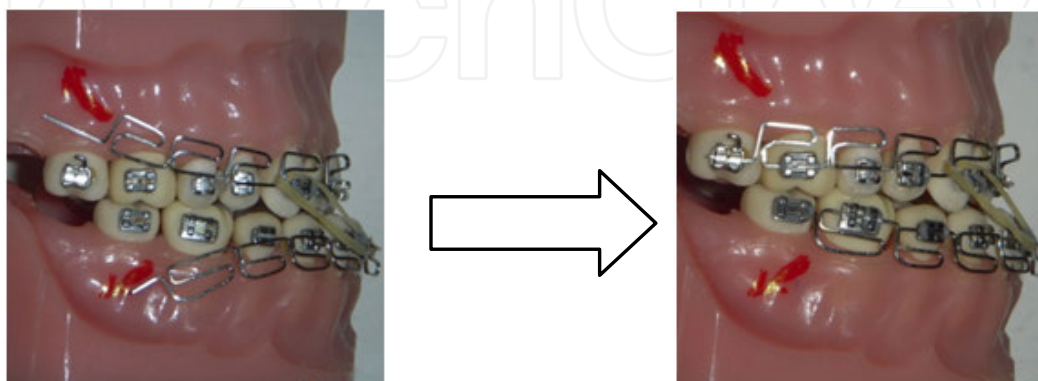

Figure 2 - The tip back bends of MEAW

9.3.1. treatment steps of class III malocclusion

* Levelling

9.3.1. treatment steps of class III malocclusion

- Levelling
- Elimination of occlusal interferences
- Establishing mandibular position
- Occlusal plane reconstruction
- Obtain a physiologic occlusion

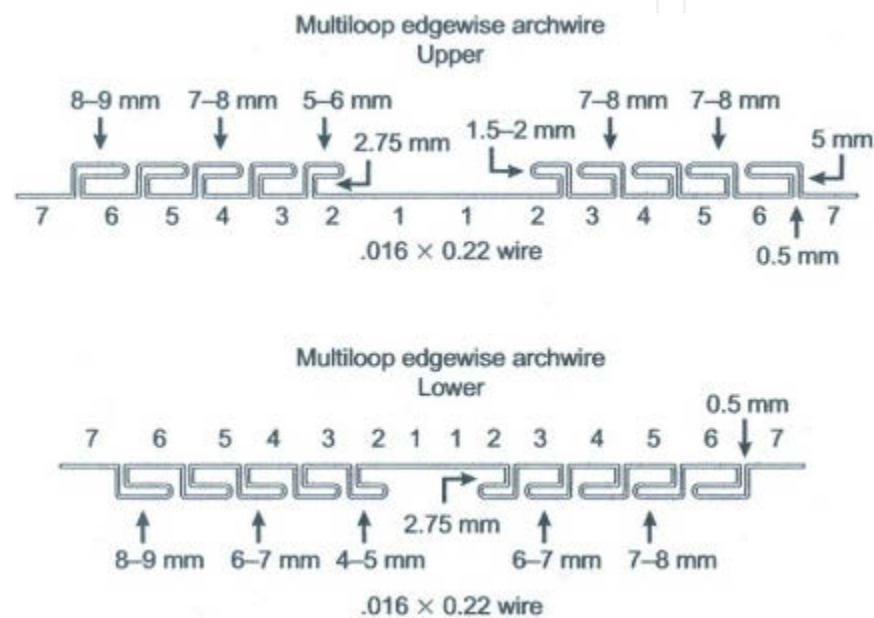


Figure 3. The MEAW's are constructed with .016x.022 stainless steel (bracket 0.018 – inch slot) or .017x.025 ss (bracket 0.022 – inch slot).

The arches have ideal arch form with five loops on each side of the arch.

10. Case report 1

Patient female 13 years old and 3 months of age, with skeletal class III and dental class III on a normodivergent face pattern, mandibular prognathism, overbite (0 mm), overjet (0 mm), flat occlusal plane in the upper molar area producing interference in the posterior area. The patient began the treatment with 13 years old and 3 months and the duration of the treatment was 18 months. The type of appliance was an edgewise multi-bracket 0.022x0.028 slot, 0° torque, 0° angulation and MEAWs arch wires. The appliance was removed in January 2013 (14Y+11M).

The purpose of the treatment for this patient with class III malocclusion was to provide a steep occlusal plane in order to achieve a posterior adaptive repositioning of the mandible, to correct the crowding and improve the occlusion by uprighting and alignment the dentition. First the

impacted upper and lower third molars should be removed, but she refused. It was explained to the patient and the parents, that without the extractions the probability of relapse was high. It was then accepted to extract the teeth later, after the end of treatment. During the last control visit (one year after the end of treatment) the patient was informed that she should extract the third molars and she agreed.

The steps of the treatment:

a-Leveling; b-Elimination of occlusal interferences ; c-Establishing mandibular position ; d-Reconstruction of the occlusal plane; e-Achieving a physiological occlusion.

Step one-Levelling – The levelling was performed using 0.016 SS wire arches.

Step two-Elimination of occlusal interferences-0,017x0,025 multiloop edgewise archs wire (MEAW) were incorporated in both dental arches. The alignment and intrusion began through progressive tipback of 3° to 5° from premolars to the molar area along with the use of short class III (3/16 inch, 6oz) elastics on both sides.

Step three-Establishing mandibular position: At the end of this phase the molar occlusion was in class one. A stable occlusion was obtained after 18 months of treatment the

retention phase was done with maxillary Hawley plate for night time use (6months) and Step four/five-Reconstruction of the occlusal plane and achieving a physiological

occlusion: In this step the tipback in molar area was removed and the occlusal plane in the molar area was steepen. A stable occlusion was obtained after 18 months of treatment the retention phase

was done with maxillary Hawley plate for night time use (6months) and bonded lingual wire for 6 months. Post-treatment results show an improved profile, occlusion and a pleasant smile. The intra-oral photos show a class I molar relationship and a correct overbite and overjet. The

mandibular superposition shows a slight mandibular posterior shift.

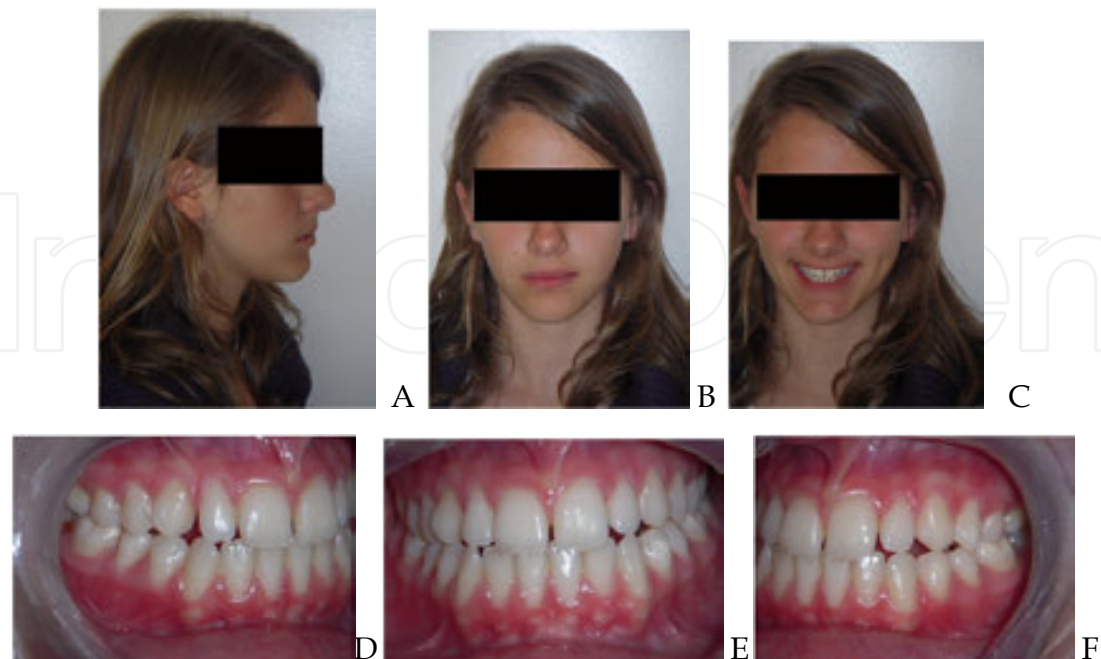

Figure 5- Pre-treatment extraoral (A - C) and intraoral (D - F) photographs

Figure 4. Pre-treatment extraoral (A-C) and intraoral (D-F) photographs

	Range	Beginning	End of treatment	End of retention
FMIA	67°+- 3	71	77	75
FMA	25°+- 3	27	28	28
IMPA	88°+- 3	82	75	77
SNA	82°+- 2	85	86	86
SNB	80°+- 2	85	84	84

Post-treatment results show an improved profile, occlusion and a pleasant smile. The intra-oral photos show a class I molar relationship and a correct overbite and overjet. The mandibular superposition shows a slight mandibular posterior shift.

	Range	Beginning	End of treatment	End of retention
FMIA	67°+ 3	71	77	75
FMA	25°+ 3	27	28	28
IMPA	88°+ 3	82	75	77
SNA	82°+ 2	85	86	86
SNB	80°+ 2	85	84	84
ANB	2°+ 2	0	2	2
Ao-Bo	2mm	-2mm	3mm	3mm
OP	10°-14°	6	5	5
Z	75°+5	91	88	88
PFH	45mm	45	46	46
AFH	65mm	62	64	66
INDEX	0,69	0,73	0,72	0,70

Table 1. Cephalometric analysis (Tweed-Merrifield)

	Beginning	End of treatment	End of retention
ODI	MP/AB 60	60	60
	FH/PP 0	0	0
	HF/FP 95	94	92
APDI	FP/AB -02	-05	-05
	HF/PP 0	-2	0
CF	ODI+APDI	153	147

Table 2. Cephalometric analysis (Kim)

	FP/AB -02		-05		-05	
	HF/PP 0		-2		0	
CF	ODI+APDI	153		147		147

Table 2 Cephalometric analysis (Kim)

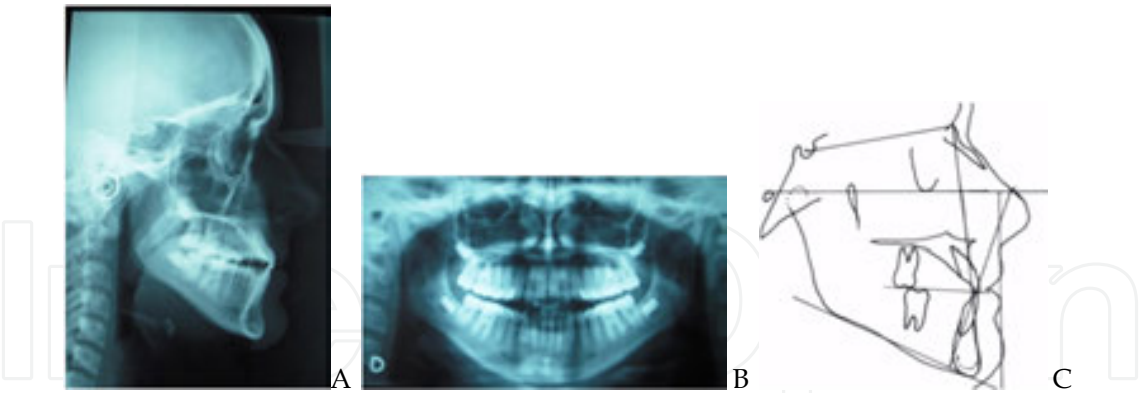


Figure 5. pre-treatment records (A-C)

Figure 6 - pre-treatment records (A-C)

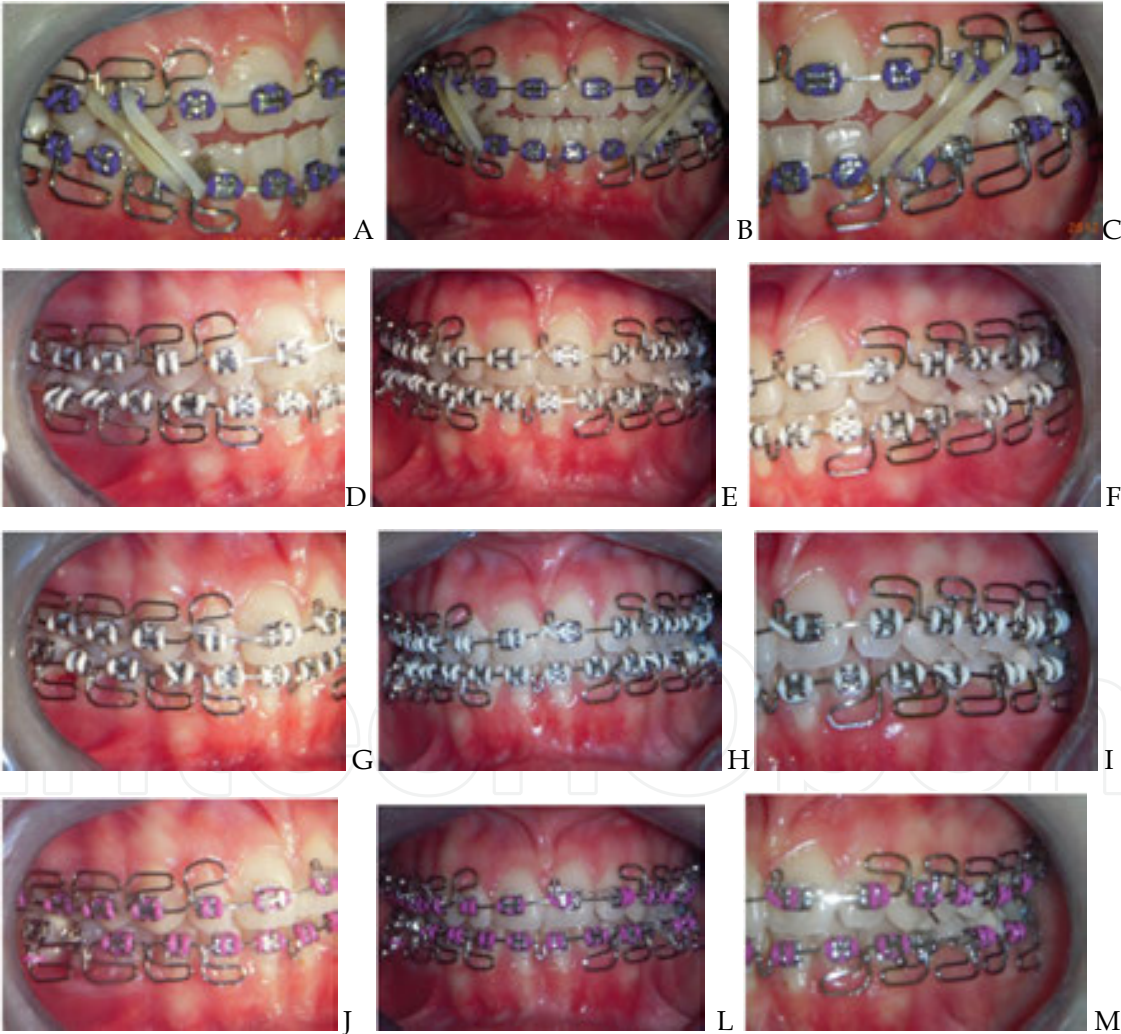

Figure 7-Photos during the treatment (A -M)
Figure 6. Photos during the treatment (A -M)

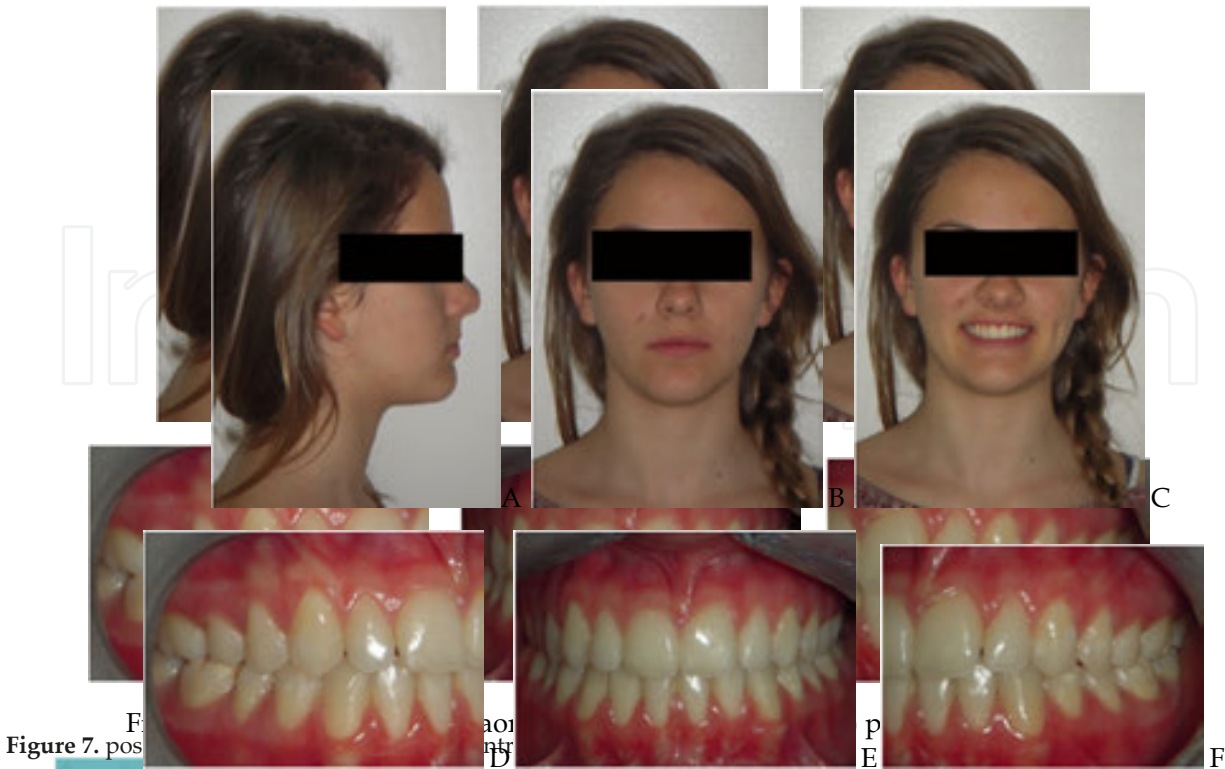


Figure 8 –post-treatment extraoral (A-C) and intraoral (D-F) photos

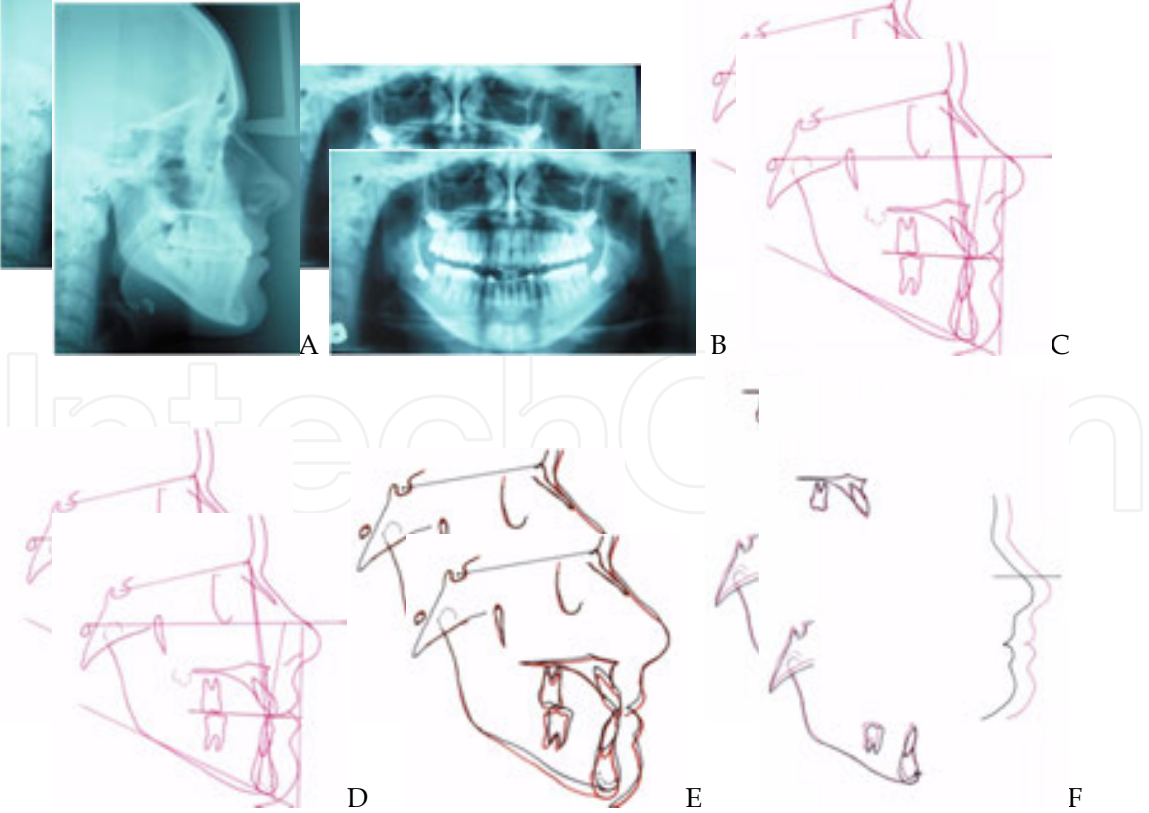


Figure 8. Post-treatment records (A-D),superimpositions (E-F)

Figure 9-Post-treatment records (A-D),superimpositions (E-F)
Figure 9-Post-treatment records (A-D),superimpositions (E-F)

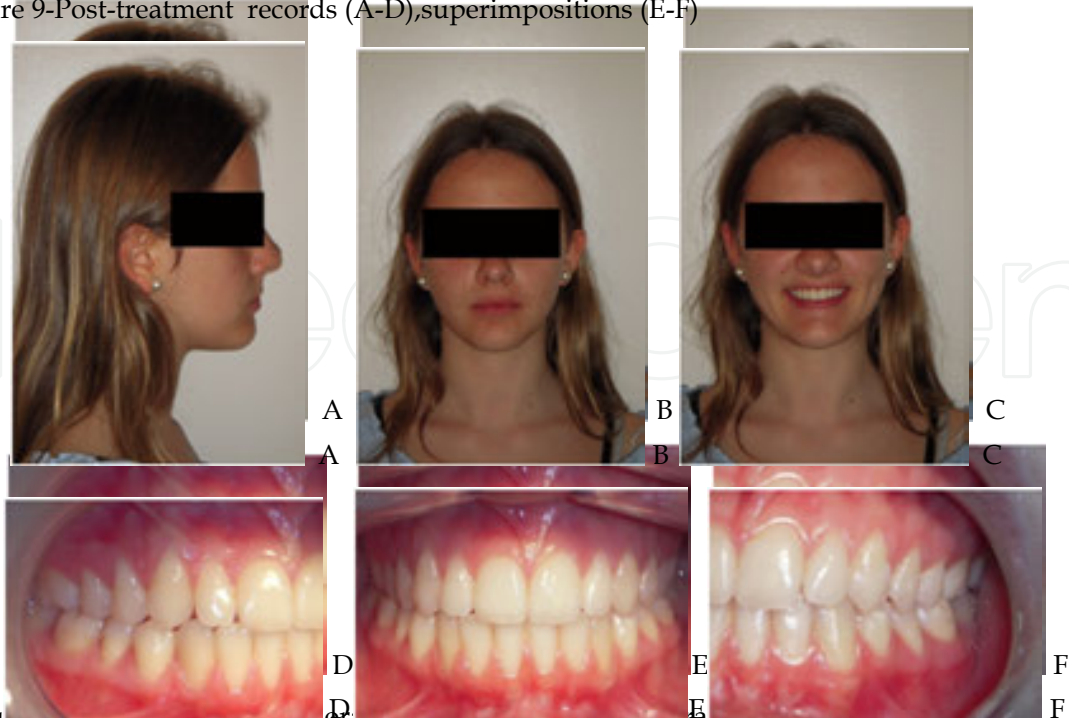

Figure 10- post-retention extra oral photos (A - C) and intraoral photos (D - F)
Figure 9. post-retention extra oral photos (A-C) and intraoral photos (D-F)
Figure 10- post-retention extra oral photos (A - C) and intraoral photos (D-F)

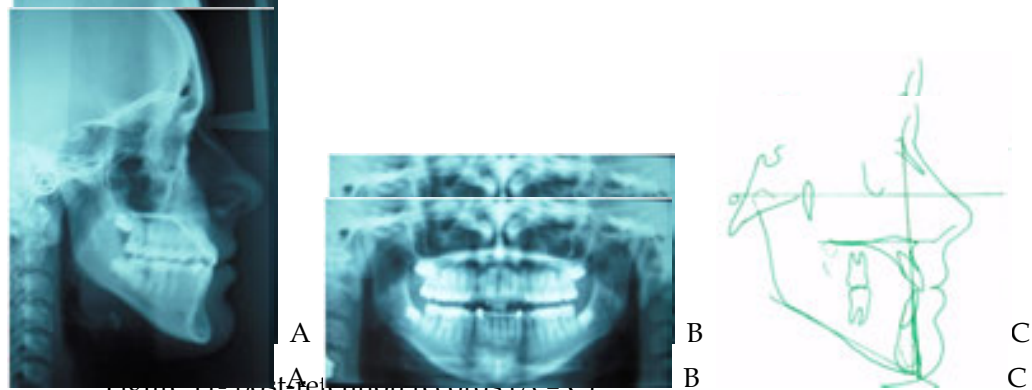


Figure 11- post-retention records (A - C)
Figure 11- post-retention records (A - C)
Figure 10. post-retention records (A - C)

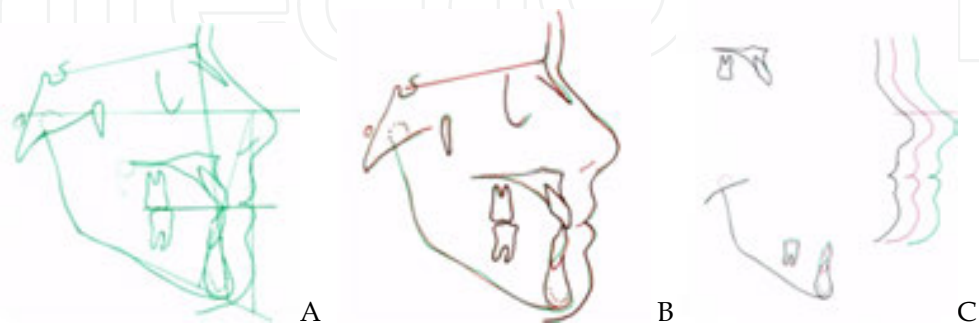

Figure 12- superimpositions (A- C)
Figure 11. superimpositions (A-C)

Case Report 2

Patient female (15 years old/10 months), with skeletal class III (ANB -2° , APDI 91)and dental class III on a hypodivergent face pattern (FMA 22°), mandibular prognathism, open bite tendency (ODI 55); overjet (0 mm), flat occlusal plane in the molar area producing interference in the posterior area.

11. Case Report 2

Patient female (15 years old/10 months), with skeletal class III (ANB-2°, APDI 91) and dental class III from the protrusion of the anterior teeth (Fig. 12), short class III elastics (3/16 inch, 6 oz) bite tendency (ODI 55); overjet (0 mm), flat occlusal plane in the molar area producing interference on the anterior teeth.

This treatment lasted 18 months. At the end of the treatment, the maxillofacial disharmony and the profile were improved. The patient displayed a pleasant smile, gnathial curve and

molar class I relationship, the overbite and overjet were corrected. According to Rym's analysis, the ODI (55°) indicates a open bite skeletal pattern. The APDI (91°) indicates a class III skeletal pattern and (MFA 85°) (combination factor) were 46° indicates a skeletal pattern requiring extraction of permanent teeth (third molars). The posterior crowding

was solved by extraction of third lower molars and upper second molars prior to the onset of the treatment. The general superimposition shows that the entire lower dental arch was moved distally and uprighted.

Before the decision to extract the upper second molars, the third molars were radiographically evaluated to check if they had space of the occlusion (open bite tendency) was appropriate position and inclination to erupt properly, replacing the second molars.

Improved. This case shows a successful orthodontic treatment of a skeletal class III

Treatment began with age (15/10), posterior crowding and reconstituting the occlusal plane alignment of both dental arches using the MEAW technique.

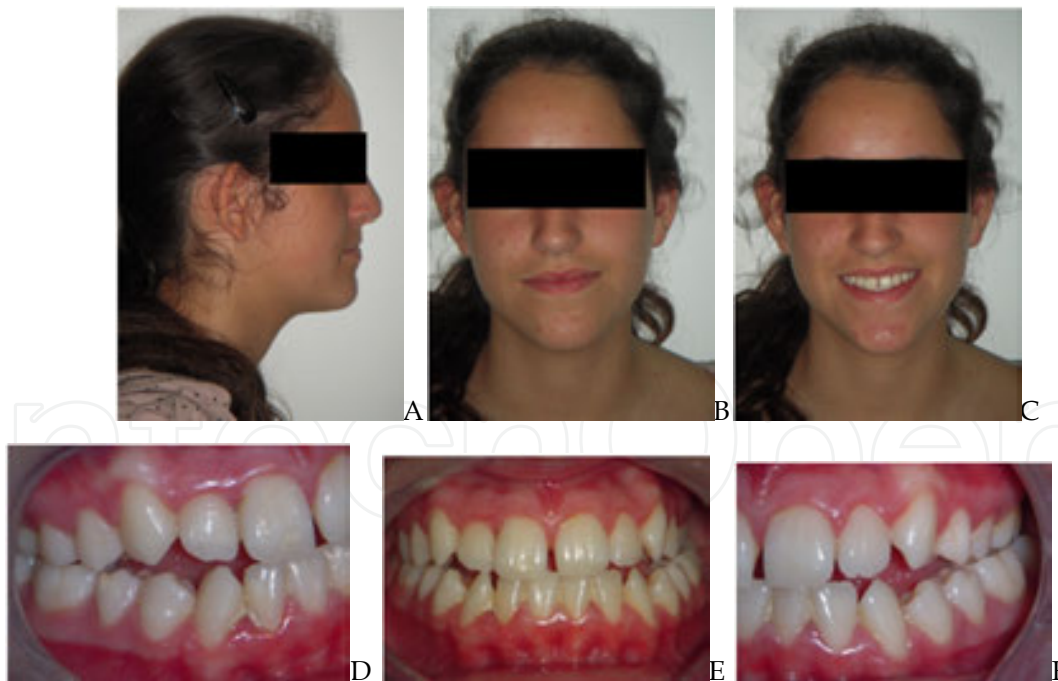

Figure 15 -Pre-treatment extraoral (A-B-C) and intraoral (D-E-F) photos
 Figure 12. Pre-treatment extraoral(A-B-C) and intraoral (D-E-F) photos

After 2 months, the use of MEAW and short class III elastics (3/16 inch, 6 oz) started. The elastics were used 24 hours per day and were removed only for brushing the teeth and to eat. The correct treatment mechanic used was progressive tip back bends activations of 3° to 5° from

the premolars teeth to molar area along with short class III elastics (3/16 inch, 6 oz) on the anterior teeth.

This treatment lasted 18 months. At the end of the treatment, the maxillofacial disharmony and the profile were improved. The patient displayed a pleasant smile, a normal canine and molar class I relationship, the overbite and overjet were corrected.

The lower incisors were lingually tipped (IMPA 85°) and the lower molars were moved distally.

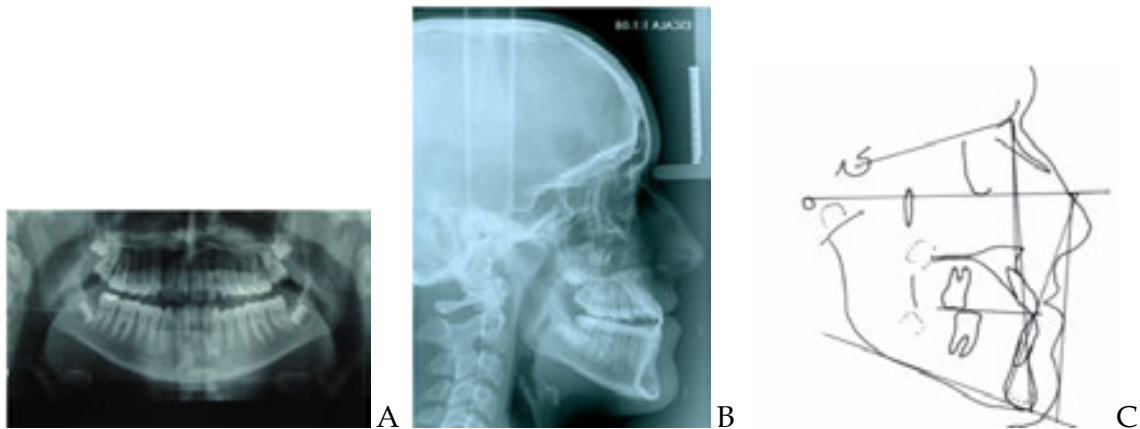
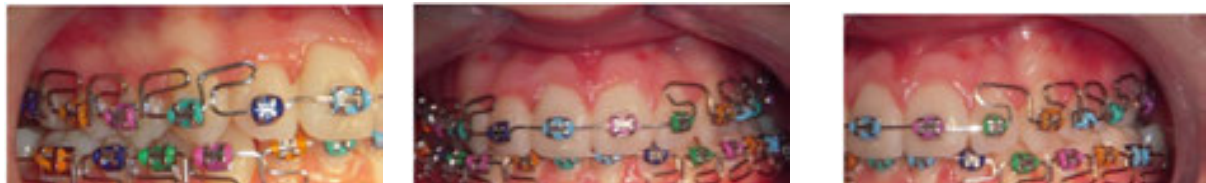

Figure 16 - Pre-treatment records (A-C)

	Range	Beginning	End of treatment	End of retention
FMIA	67°+ 3	68	74	74
FMA	25°+ 3	22	21	22
IMPA	88°+ 3	90	85	84
SNA	82°+ 2	73	75	75
SNB	80°+ 2	75	74	74
ANB	2°+ 2	-2	1	1
Ao-Bo	2mm	-7mm	-2mm	-2mm
OP	10°-14°	3	3	3
Z	75°+5	85	80	81
PFH	45mm			
AFH	65mm			
INDEX	0,69			

Table 3. Cephalometric analysis (Tweed-Merrifield)



The general superimposition shows that the entire lower dental arch was moved distally and uprighted.

The final ODI of 63° show that the vertical aspect of the occlusion (open bite tendency) was improved. This case shows a successful orthodontic treatment of a skeletal class III malocclusion, eliminating the posterior crowding and reconstructing the occlusal plane using the MEAW technique.

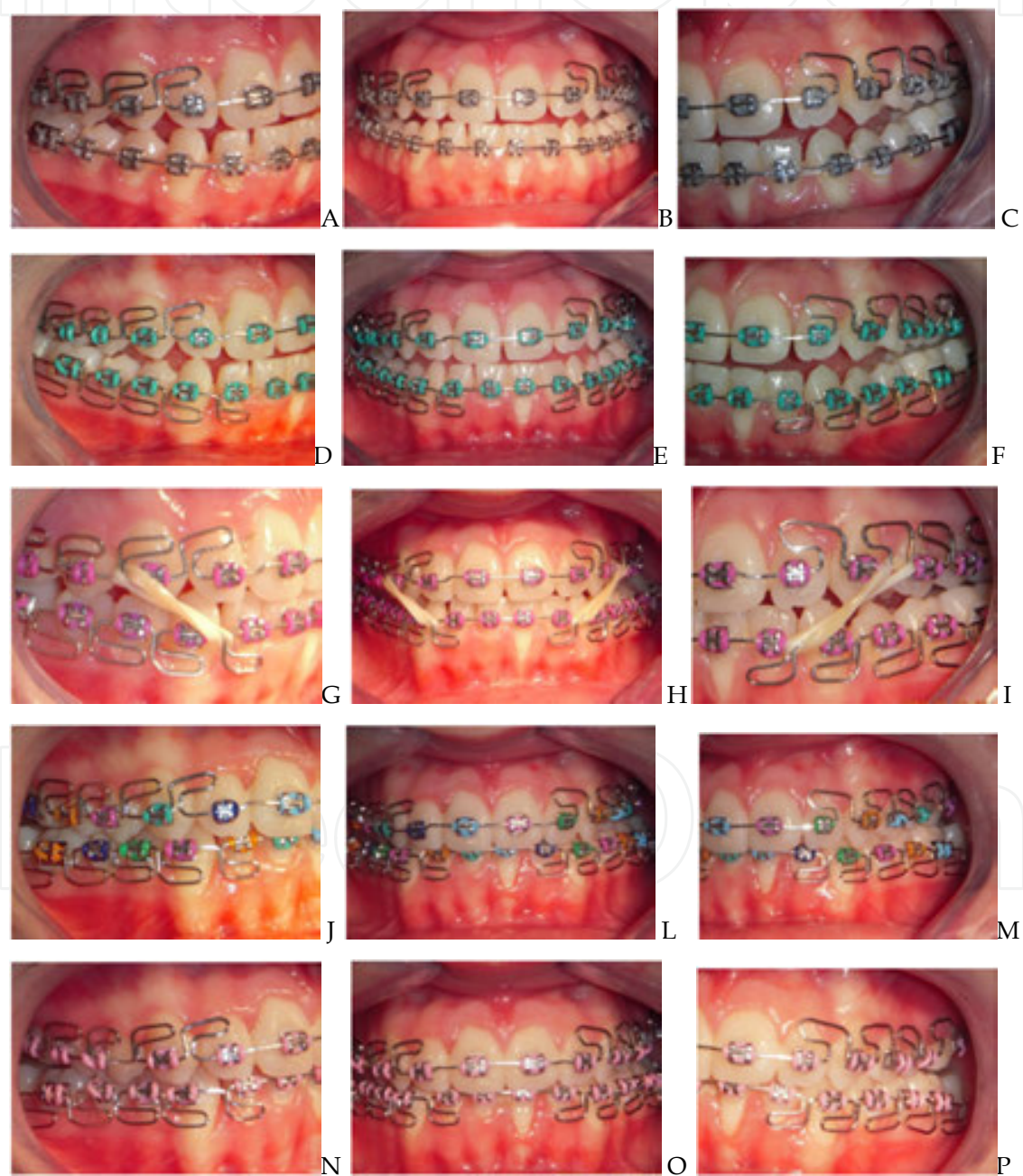

Figure 17 - Photos during the treatment.(A-P) with MEAW upper and lower and short class III elastics (6 oz, 3/16 inch).

	Range	Beginning	End of treatment	End of retention
FMIA	67°+- 3	68	74	74
FMA	25°+- 3	22	21	22

ANB	2°+ 2	-2	1	1
Ao-Bo	2mm	-7mm	-2mm	-2mm
OP	10°-14°	3	3	3
Z	75°+ 5	85	80	81
PFH	45mm			
AFH	65mm			
INDEX	0,69			

Table 3 Cephalometric analysis (Tweed-Merrifield) Beginning End of treatment End of retention

MP/AB 60		55		67		63		67		63	
ODI		55		67		63		67		63	
		Beginning		End of treatment		End of retention					
		HF/FP 92		92		92					
ODI		MP/AB 60		67		63		67		63	
APDI		FH/FP 4 -5		-4 2		90		-4 2		90	
APDI		HF/FP 92		92		90		92		90	
		FP/AB 4		2				2			
CF		ODI+APDI 5		-4		153		-4		153	
CF		ODI+APDI		146		153				153	

Table 4. cephalometric analysis (Kim) Table 4 Cephalometric analysis (Kim)

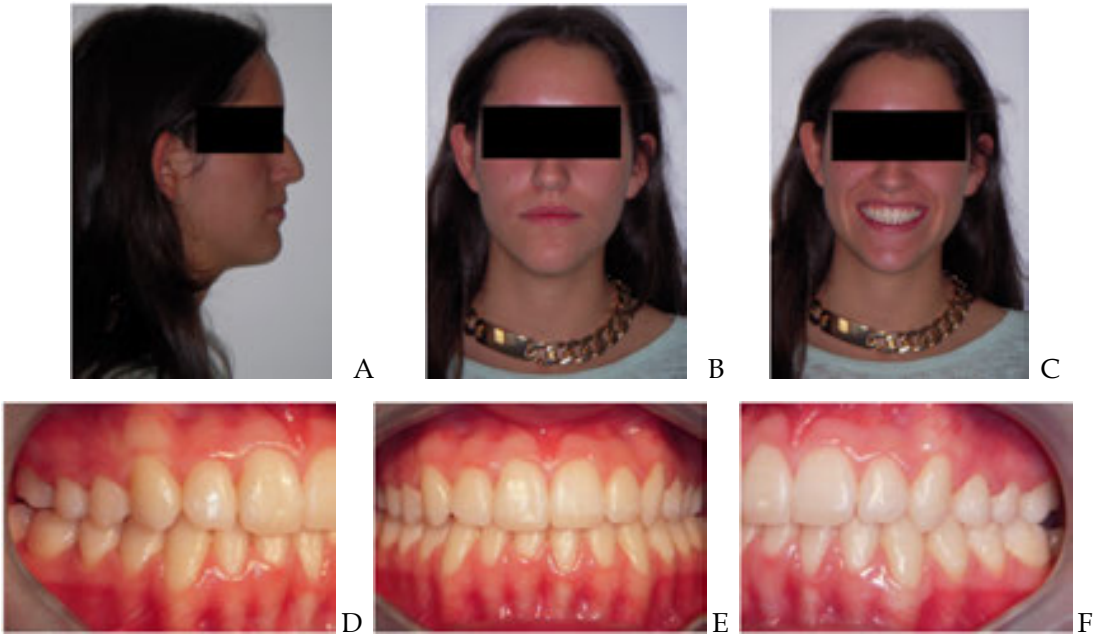


Figure 18 - Post-treatment extraoral photos (A-C) and intraoral photos (D-F)

Figure 15. Post-treatment extraoral photos (A-C) and intraoral photos (D-F)

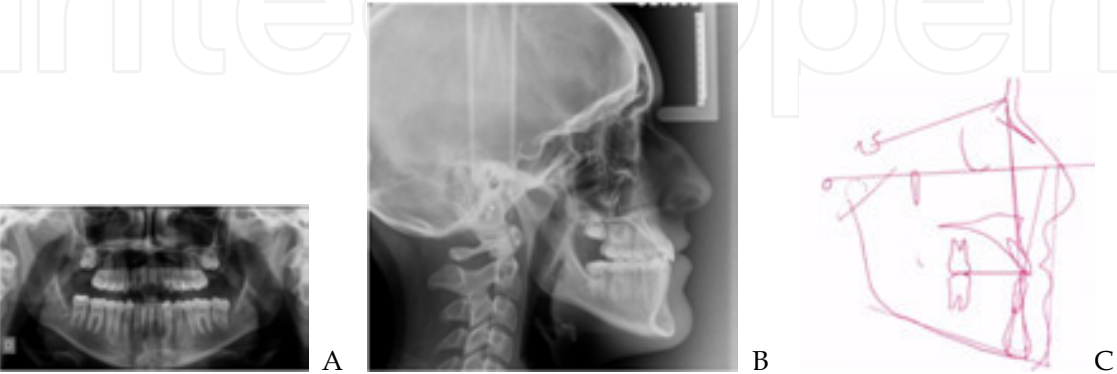
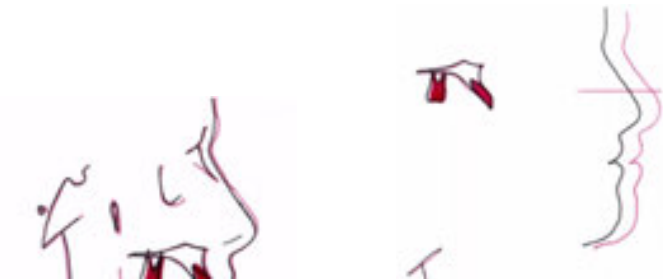
Figure 19 - Post-treatment records

Figure 16. Post-treatment records



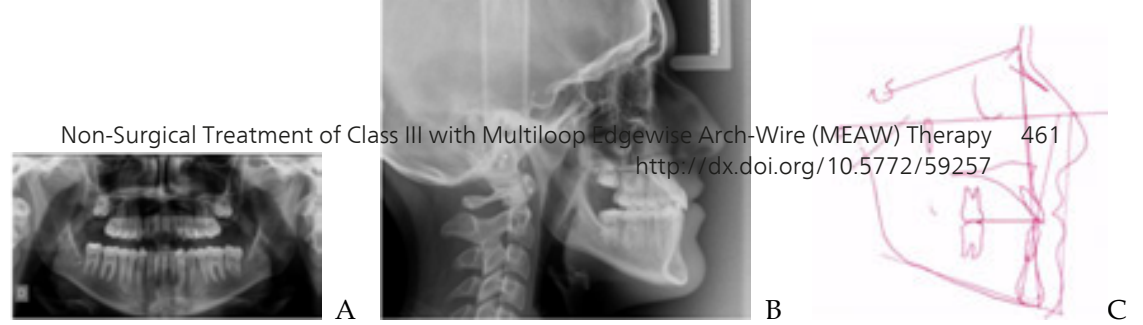

Figure 19 – Post-treatment records

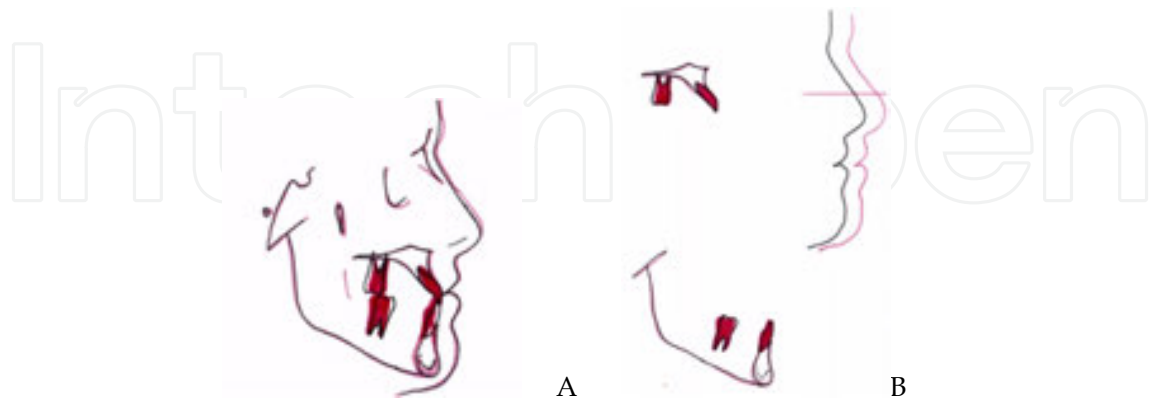


Figure 20 – superimpositions (D – E)

Figure 17. superimpositions (D – E)

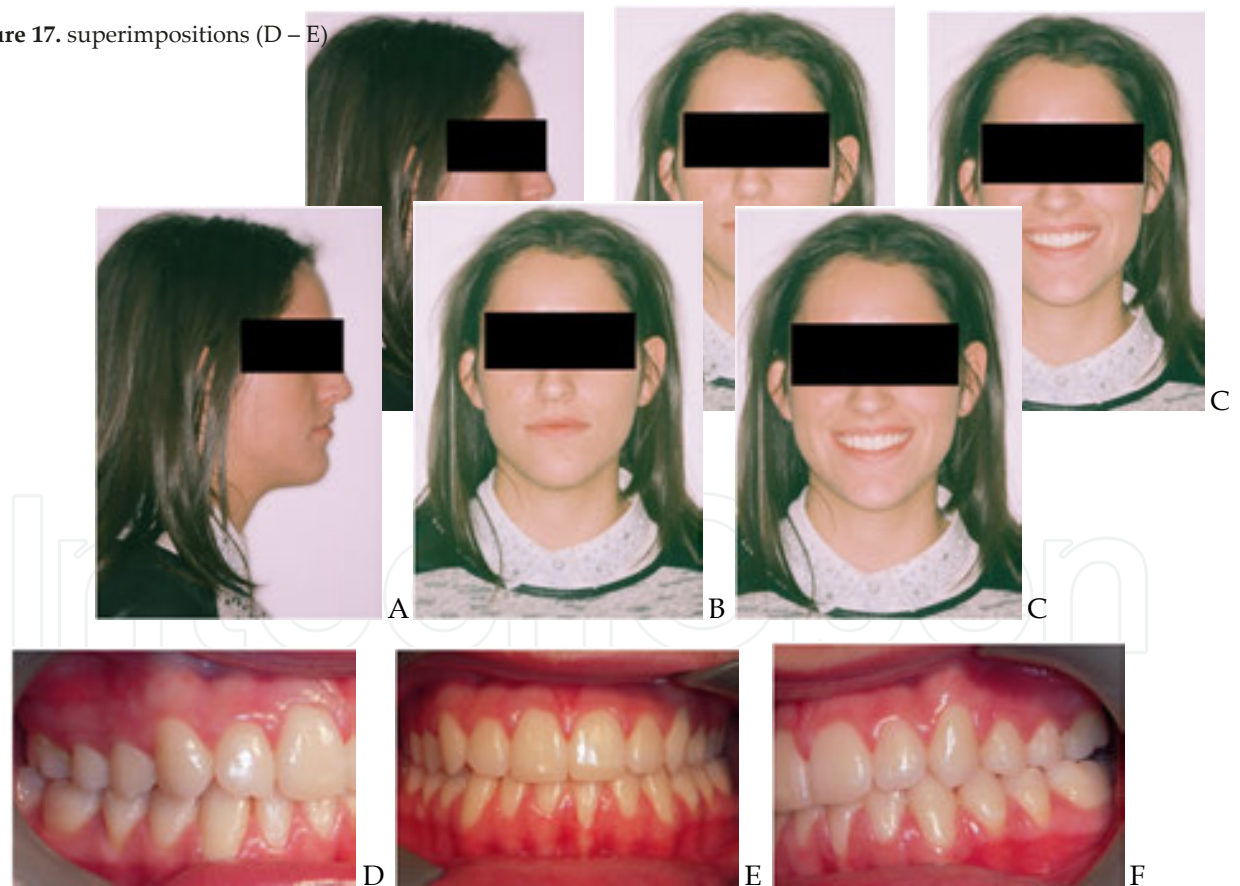

Figure 21 – Post-retention extraoral photos (A-C) and intraoral photos (D-F)

Figure 18. Post-retention extraoral photos (A-C) and intraoral photos (D-F)

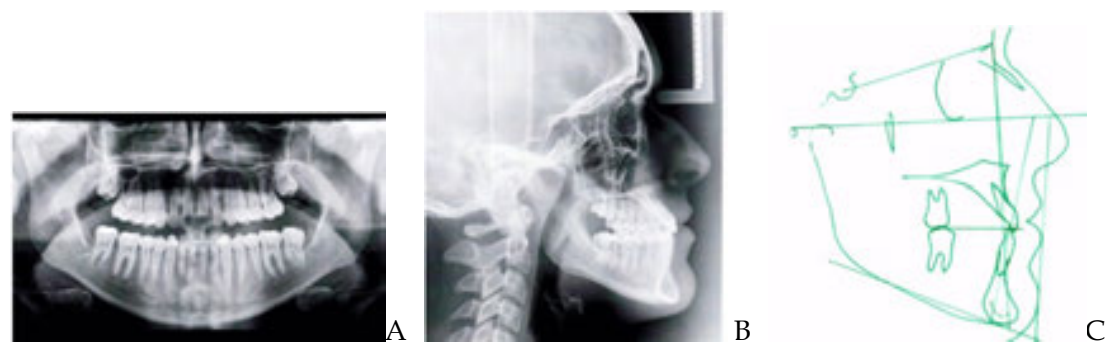

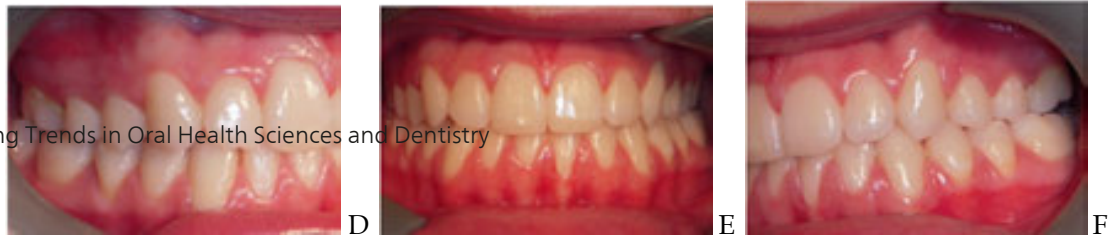


Figure 21 – Post-retention extraoral photos (A-C) and intraoral photos (D-F)

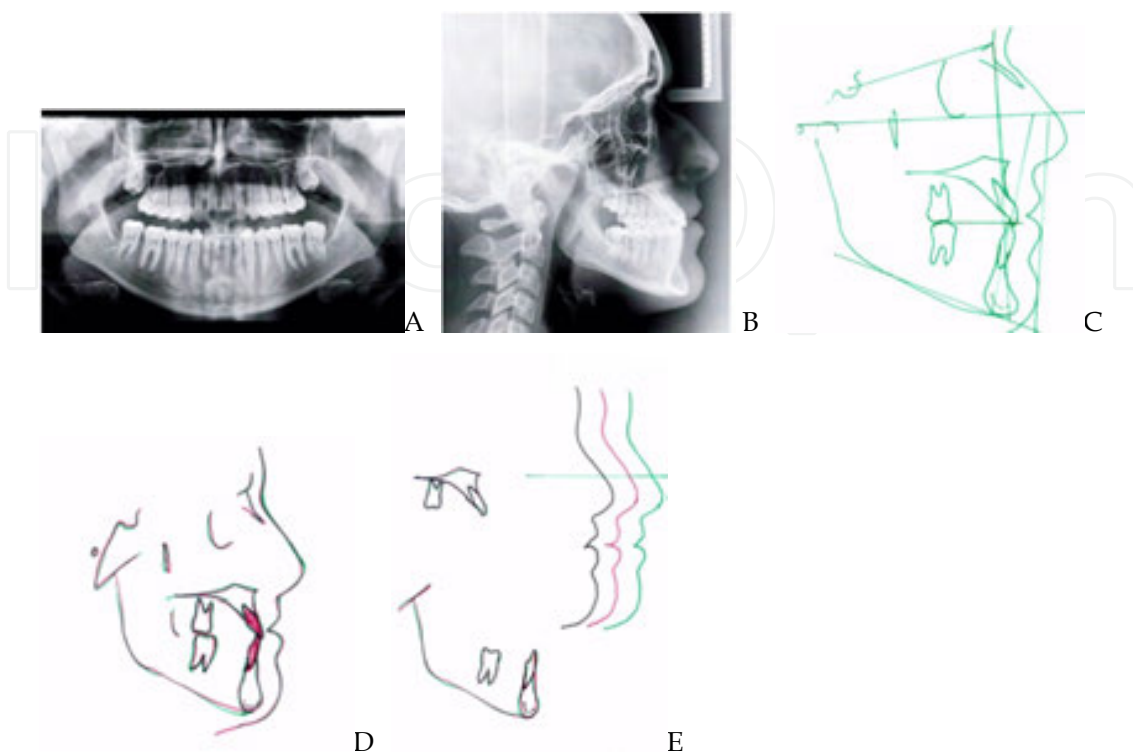


Figure 22- post-retention records (A –E)

Figure 19. post-retention records (A –E)

12. Conclusion

The MEAW technique proved to be effective in the treatment of class III malocclusion. The MEAW is a valid alternative in the treatment of class III malocclusion, when patients refuse surgery and when the disharmony of the skeletal structure is not harsh. The MEAW used correctly can properly reconstruct the occlusal plane, allowing to achieve a correct and stable occlusion, improving the profil and facial balance.

Author details

Paulo Beltrão*

Address all correspondence to: paulobeltrao@sapo.pt

French Board Of Orthodontics, Portugal

References

- [1] Beltrão, Paulo (2011) Treatment of class II deep Overbite with multiloop edgewise arch-wire(MEAW) therapy; Principles in contemporary orthodontics (Edited by Silvano Naretto),Intech
- [2] Dawson,P.E.(1989) *Evaluation, diagnosis and treatment of occlusal problems*, Dawson,P.E. (ed),The C.V. Mosby company
- [3] Fushima, K ; Kitamura,Y; Mita,H ; Sato,S; Kim,Y (1996).The significance of the cant of occlusal plane in class II/1 malocclusion. *European journal of orthodontics*, 18,27-40
- [4] Hyun-Sook Kim,Seon-Young Kim (2004).Compensatory changes of a occlusal plane angles in relation to a skeletal factors; *Korea journal of orthodontics*:34 (3) :229-40
- [5] Kim, YH,(1979),ODI/APDI combination factor, *Angle orthodontics*,49:77-84
- [6] Kim, YH;(1999);Treatment of anterior openbite and deepbite malocclusions with MEAW therapy; The enigma of vertical dimension-craniofacial growth series vol 36 Ann Arbor (edited by James McNamara Jr): center for Human growth and development-University of Michigan
- [7] Knierim, RW (1999).diagnosis of openbite and deepbite problems: a clinician`s perspective on the Kim approach; ; The enigma of vertical dimension-craniofacial growth series vol 36 Ann Arbor (edited by James McNamara Jr): center for Human growth and development-Univ.Michigan
- [8] Mc Namara,J.A. jr and Carlson,D.S. (1979)Quantitative analysis of temporomandibular joint adaptations to protrusive function; *American journal of orthodontics*, 76,593-611
- [9] Merrifield,LL.(1966)The profile line as an aid to critical evaluation of facial esthetics; *American journal of orthodontics*,804-822
- [10] Ortial,J.P(1989),Les modifications faciales par l`orthodontie, *journal de l`edgewise*, vol.20,53-86
- [11] Petrovic,A.G. and Stutzaman,J.(1975) Control process in the postnatal growth of the condylar cartilage,in McNamara J.A.jr,ed.determinants of mandibular growth,monograph 4:craniofacial growth series,Ann Arbor-Center for Human growth and development,University of Michigan
- [12] Sassouni,V,(1969)A classification of skeletal facial types,*AJODO*,55,109-123
- [13] Sato, Sadao (1994)-Case report: developmental characterization of skeletal class III malocclusion,the *Angle orthodontics*, vol.64,n°2-1994

- [14] Sato,Sadao; Akimoto (2007)-Development and orthodontic treatment of skeletal class III malocclusion without surgical intervention, The bulletin of kanagawa dental college,vol,35,n°1, March 2007
- [15] Sato, Sadao(2001) –A treatment approach to malocclusions under the consideration of craniofacial dynamics,Grace printing press, inc
- [16] Sato,Sadao (2008),orthodontic marathon course at Kanagawa dental college-Japan