

We are IntechOpen, the world's leading publisher of Open Access books Built by scientists, for scientists

6,900

Open access books available

185,000

International authors and editors

200M

Downloads

Our authors are among the

154

Countries delivered to

TOP 1%

most cited scientists

12.2%

Contributors from top 500 universities



WEB OF SCIENCE™

Selection of our books indexed in the Book Citation Index
in Web of Science™ Core Collection (BKCI)

Interested in publishing with us?
Contact book.department@intechopen.com

Numbers displayed above are based on latest data collected.
For more information visit www.intechopen.com



Surgery and Staging of Melanoma

Rolland Gyulai, Zsolt Kádár and Zsuzsanna Lengyel

Additional information is available at the end of the chapter

<http://dx.doi.org/10.5772/59471>

1. Introduction

Surgical management of melanoma encompasses primary biopsy and complete wide local excision (WLE) of the tumor, as well as the surgical treatment of metastatic melanoma, including both cutaneous and internal metastases. The management of a melanoma suspect lesion starts with the initial biopsy of the lesion. A great variety of techniques can be used for the biopsy of melanomas, and the choice of the technique is dependent on multiple factors (patient's age, strength of clinical suspicion of melanoma, thickness of the tumor, localization, etc.). Once the clinical diagnosis of melanoma is confirmed histologically, local tumor control is established by wide local excision. The margins for WLE are determined by the T stage of the tumor, and are between 0.5-2.0 cm. Certain clinical melanoma types (e.g. lentigo maligna) require special attention, as the recommended margins can differ from those generally advised for other melanoma types.

Important surgical procedures include wide local excision with safety margins, sentinel lymph node biopsy, regional lymph node dissection and reconstruction of defects after melanoma excision. A plastic surgeon of the appropriate specialty should perform the excision and reconstruction.

Performing surgery of locoregional and distant metastases depends on various factors. However, in highly selected patients, complete surgical resection of the metastases may result in prolonged survival. In addition, combination of surgery with novel immuno-, and targeted therapies, may result in an even better outcome in the future for patients with stage IV disease.

2. Primary treatment of suspicious pigmented lesion/melanoma

Early diagnosis and complete removal of the malignant cells are of paramount importance in the treatment of malignant melanoma. This usually requires a two-step approach. First, pigmented or amelanotic lesions suspicious for melanoma should be promptly biopsied and submitted to pathological evaluation, and second, the tumor should be subsequently excised with adequate surgical margins. The margins of the final excision are determined with the tumor characteristics in mind, as determined by the histopathological analysis of the biopsy specimen. Thus, removal of appropriate biopsy sample containing the fragment with the worst prognostic characteristics, is of substantial importance. As extensive loss of tissues may potentially influence the feasibility of further surgical interventions, such as the sentinel lymph node biopsy, the use of proper biopsy techniques is essential during the primary treatment of melanoma.

Recommendations regarding the width of the surgical margin of excision are nowadays clearly defined for primary melanoma, and are based on the histopathological features of the melanoma. These recommendations, however, are sometimes difficult or impossible to follow, like in the case of specially localized melanomas, or certain melanoma subtypes. This chapter summarizes the available evidence regarding different biopsy techniques and the surgical management of primary melanoma.

2.1. Biopsy of melanoma suspect lesions

The primary aim of performing biopsy in the case of a melanoma suspect lesion is to establish or exclude the diagnosis of melanoma. An additional goal is to ensure accurate pathological staging of the tumor in order to enable adequate surgical management by performing wide local excision (WLE). Excisional, incisional and shave biopsy techniques are used in the surgical treatment of melanoma.

2.1.1. Excisional biopsy

The preferred biopsy technique for most melanomas is excisional biopsy.[1,2] This means that the entire lesion is removed with an additional 1-3 mm margin of normal-appearing skin. Wider excisions, however, should be avoided, to permit subsequent lymphatic mapping for sentinel lymph node biopsy. Generally, the excised tissue sample should contain part of the subcutaneous fat as well, and should be oriented to aid subsequent histopathological evaluation. The positioning of the excision also should possibly allow for subsequent wider excisions. The excisional biopsy technique can be used in most melanomas, when primary closure of the wound is feasible. Although the lowest frequency of positive margins is reported when excisional biopsy is used, positive margins and even residual melanoma on WLE do occur.[3]

2.1.2. Incisional biopsy

The reported frequency of excisional biopsy technique used for diagnosing melanoma varies significantly with centers, countries, and individuals, and ranges between 10 and 86 percent.

[1,3-6] Thus, in a significant portion of melanoma suspect lesions, a biopsy technique other than excisional biopsy are used. Even guidelines that emphasize the importance of excisional biopsy in melanoma management state that incisional biopsy may be appropriate in certain clinical circumstances. Such clinical scenarios may include cases when excisional biopsy is not feasible due to the large size or the location (nose, ear, face, palm, and sole) of the lesion, concerns about cosmesis or low clinical suspicion of melanoma.

In the case of incisional biopsy only a portion of the lesion is removed, either by a punch biopsy or using a scalpel (Figure 1.a-c). As incisional biopsy specimens contain only part of the lesion, concerns regarding misdiagnosis, staging inaccuracy or diagnostic uncertainty may arise. Careful selection of the biopsy site is therefore crucial to ensure that the biopsy best represents the entire lesion, both in terms of the type and the T stage of the tumor. This is usually achieved by sampling the thickest, most raised area of the tumor, or the darkest part of flat lesions. Complex lesions containing multiple suspicious foci may require more than one simultaneous biopsy sampling. Both in case of punch biopsy and incisional biopsy adequate depth (reaching to the subcutaneous fat) of the sampling should be guaranteed.

The theory that incisional biopsy, by cutting through the neoplastic tissue, represents an increased risk for lymphatic or hematogenous metastatisation, and thus it should be regarded as a harmful procedure, has been refuted by several earlier studies.[3,7] Moreover, Molenkamp et al. reported slightly better survival in patients with residual tumor cells in their re-excision samples, compared to patients without residual cells in their re-excision specimen.[3] The authors speculated that immunity against residual tumor cells, triggered by biopsy induced wound healing, might be responsible for this finding.

2.1.3. Shave biopsy

In the case of shave biopsy a superficial, a few mm deep flat section of the skin is removed (Figure 1.d). Shave biopsy is ideally performed at the level of the deep dermis, however, the depth of excision is often compromised with the desire to provide a cosmetically good result. Shave biopsy of primary melanoma, as it often results in incomplete removal of the tumor and thus compromises pathological staging of the tumor, is not recommended in most of the cases for melanoma biopsy. However, if the index of melanoma suspicion is low, shave biopsy may be performed. When performing shave biopsy in pigmented lesions, deep scoop shave biopsy is the preferred technique.

2.1.4. The effect of biopsy techniques on staging, prognosis and treatment of melanoma

The biopsy of the pigmented lesion should not only establish or exclude the diagnosis of melanoma, but also provide information on the T stage of the tumor. Ideally, this initial T stage will be the same as the one achieved after the wide local excision of the tumor. This will ensure that the original treatment plan regarding the width of the surgical margin and the requirement for sentinel lymph node biopsy, does not need subsequent adjustment. As these treatment parameters are primarily determined by Breslow's depth of the tumor, achieving appropriate deep margin sampling is of paramount importance during melanoma biopsy.

Theoretically, sampling errors may stem from several scenarios (Figure 1.a-d). Tumor depth determination may be compromised by not representative tissue sampling (Figure 1a), positive deep biopsy margin (Figure 1b) or not representative tumor depth (Figure 1c). Diagnostic inaccuracy, as a consequence of inappropriate tumor depth measurement, may (Figure 1b) or may not (Figure 1c) lead to upstaging after wide local excision. In a recent study, positive deep margins were found in 12%, 32%, 17% and 24% of cases undergoing excisional, shave, punch and incisional biopsies, respectively.[4] After wide local excision, tumor depth was more than the biopsy depth in 44% of the cases with residual tumors in WLE, and resulted in T-stage reclassification in 22% of cases. Reclassification was necessary in 2%, 7%, 24% and 24% of cases when the initial diagnosis was established by excisional, shave, punch or incisional biopsy, respectively. Diagnostic inaccuracy led to subsequent treatment change in 2%, 5%, 18% and 18% of cases when excisional, shave, punch or incisional biopsy, respectively, was used for initial sampling. Although there is no data regarding the tumor thickness in the individual biopsy groups, it is likely that shave biopsy was more frequently used for thinner and incisional techniques for thicker melanomas. This may explain why initial punch and incisional biopsy so frequently required later reclassification in this study.

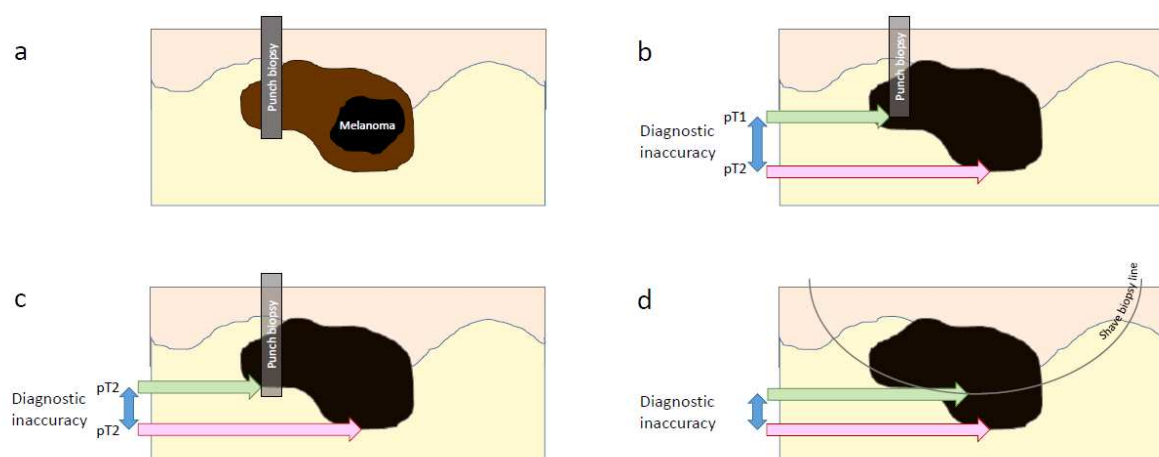


Figure 1. Diagnostic inaccuracy arising from different forms of sampling error using incisional (punch) biopsy or shave biopsy techniques. Inadequate punch biopsy sampling of pigmented lesion (a) may result in non-representative tissue sampling. Tissue sample is removed from the benign part of the pigmented lesion, while missing the malignant part leading to false negative diagnosis. Inadequate depth of punch biopsy sampling (b) results in positive deep margin on histology. Accurate T stage cannot be established, and histological reevaluation after WLE will result in the upstaging of the tumor from T1 to T2. Inadequate assessment of melanoma depth due to failure in sampling the deepest part of the tumor (c). Accurate T stage cannot be established, however, reevaluation will not result in upstaging. Positive deep margin after shave biopsy sampling of melanoma (d). Proper T stage cannot be established, and diagnostic inaccuracy may result in upstaging after WLE.

It must also be emphasized that a rather substantial part of excised melanomas are clinically not suspected to be melanoma, and vice versa, in a smaller, but significant portion of pigmented lesions, the clinical diagnosis of melanoma is not confirmed by the histopathological examination. The mean number of pigmented lesions to be excised to detect one melanoma

was 29 (range 11-83) in a study among general practitioners in Perth, Australia.[8] Thus, in cases of clinical uncertainty, shave or incisional biopsies may help to establish early melanoma diagnosis, and biopsies may also help to avoid unnecessary wide excisions in case of benign lesions.

Several studies have compared the effect of biopsy techniques on the prognosis of melanoma. [9-13] While in some studies a decreased survival rate was associated with incisional, shave or needle aspiration biopsy compared to those who had excisional biopsy, these studies included either low number of patients or significant age differences among patient groups. [12,13] Other, more recent studies, involving significantly higher numbers of patients, found no negative effect of non-radical diagnostic techniques on the survival of melanoma patients. [10,11] Moreover, Molenkamp et al. reported slightly better survival in patients with residual tumor cells in their re-excision samples,[3] and speculated that biopsy induced wound healing may theoretically trigger immunity against residual tumor cells. In summary, incisional (punch or scalpel) and shave biopsies may be used for the initial diagnosis of melanoma, although, excisional biopsy, when feasible, is recommended as the first choice.

2.1.5. Biopsy techniques in different melanoma types and special locations

Although, when feasible, excisional biopsy is the recommended technique for initial diagnosis of melanoma, there are certainly significant differences among melanoma subtypes, which, consequently, require different surgical approaches. The most critical factors when choosing the appropriate biopsy technique are clinical estimate of depth and size and localization of the lesion. Although there are no general rules regarding biopsy techniques for different clinical types of melanoma, some practical recommendations can be formulated. It must be emphasized as well that in case of lesions requiring amputation of the anatomical unit (e.g. digit or ear), histological confirmation of the diagnosis of melanoma is necessary before performing the final procedure.

- *Superficial spreading melanomas*, when primary closure of the wound is feasible, should be removed by excisional biopsy. However, these melanomas usually invade only the upper dermis, which makes them ideal candidates for shave biopsy. In case of large lesions, when complete excision of the lesion is not feasible, incisional biopsy is the preferred choice.
- *Nodular melanomas*, on the other hand, are deeply infiltrating lesions with usually smaller diameter. In most instances, therefore, nodular melanomas may and should be managed by excisional biopsy.
- *Lentigo maligna* usually presents clinically as an extensive, several centimeter large lesion on the head of elderly patients. Due to its size, location, and the frequent uncertainty in the diagnosis, as well as the advanced age of the patients, lentigo maligna often requires one or more initial incisional biopsy sampling to establish the diagnosis of melanoma, and to select subsequent management strategies.
- *Acrall-lentiginous melanomas* frequently pose a diagnostic challenge on first presentation. Moreover, their size and location commonly makes them impossible to be treated by

excisional biopsy. Therefore, especially when surgical management involves amputation, an initial incisional biopsy is essential to confirm the clinical diagnosis of melanoma.

- *Ulcerated and/or regressive melanomas* should be managed with special attention, as these clinical features are usually associated with poorer outcome. Furthermore, both ulceration and regression can interfere with histopathological evaluation, and can obscure the establishment of proper diagnosis. Therefore, excisional biopsy sampling is highly recommended in these cases to avoid false negative diagnosis or understaging.
- *Melanomas in special anatomical regions* (eyelid, ear, nose, genitoanal) usually require individual approach, as excisional biopsy sampling is often not feasible with primary wound closure. For that reason, it is recommended that an incisional biopsy is taken before final management of pigmented lesions in these locations.

2.2. Wide Local Excision (WLE) of malignant melanoma

Once the histopathological examination of the biopsy sample established the diagnosis of melanoma, the entire tumor should be surgically removed with adequate safety margins from the surrounding healthy-appearing skin. The wide local excision is intended to provide adequate surgical control of the tumor spread by removing all tumor cells from the primary tumor bed and the potential satellite lesions from the immediate vicinity of the tumor. Additionally, WLE provides tissue samples for the final T staging of melanoma.

2.2.1. General recommendations for surgical margins for wide local excision of melanoma

Current recommendations for surgical management of melanoma are based on randomized clinical trials completed several years ago.[14-20] The margin of wide local excision depends on the T stage of the melanoma, which is primarily determined by the depth of tumor invasion (see Table 1. for staging). While there has been considerable debate regarding the radicality of surgery, current guidelines recommend 0.5 – 2.0 cm surgical margins (see Table 1. for recommended surgical margins).[1]

2.2.2. Surgical margins for wide local excision in clinical types and special anatomical regions

Most melanomas on the trunk and the proximal part of the extremities may be surgically managed according to the generally recommended margins for re-excision. Certain melanoma types, however, owing to their unique localization (face, acral region of the extremities) or type (lentigo maligna), require special approach, and allow only compromised excisional margins.

2.2.2.1. Melanoma in situ (lentigo maligna and non lentigo maligna type)

In general, the NCCN guideline recommends 0.5-1.0 mm margins for in situ melanomas.[1] These recommendations, however, are based on expert consensus, as there are no randomized prospective studies that have examined the surgical margins for melanoma in situ. Recently it has been shown that almost all (99%) melanoma in situ lesions are completely removed with a 0.9 mm margin, and a margin of 0.6 mm provides negative resection margins in 86% of cases.

T classification	Thickness (mm)	Ulceration status/ mitoses	Recommended surgical margin (cm)	Remarks
Tis	in situ	NA	0.5-1.0	0.5 cm on face, neck, hands, feet 1.0 cm if significant residual pigment near the biopsy site
T1	≤1.0	a: w/o ulceration and mitosis <1/mm ² b: with ulceration or mitoses ≥1/mm ²	1.0	
T2	1.01-2.00	a: w/o ulceration b: with ulceration	1.0-2.0	
T3	2.01-4.00	a: w/o ulceration b: with ulceration	2.0	
T4	≥4.00	a: w/o ulceration b: with ulceration	2.0	

Table 1. Summary of T staging and current National Comprehensive Cancer Network (NCCN) recommended wide local excision margins for melanoma.

[21] Another recent study found that in situ melanoma lesions that were not lentigo maligna type, were unlikely to recur if completely removed, even with narrow margins (Figure 2.a).[22] On the other hand, a significantly higher incomplete excision rate was found in the lentigo maligna group (Figure 2.b), compared with the non-lentigo maligna type in situ melanomas (29.3% vs. 5.9%, respectively). Thus, the authors propose more aggressive treatment, if possible, for in situ melanomas of lentigo maligna type.

2.2.2.2. Eyelid melanoma

There is no generally accepted consensus regarding the appropriate surgical margins for eyelid melanomas. In this melanoma group, guidelines for WLE are impractical, and cannot be used in the majority of cases. In a recent retrospective study, local, nodal and distant metastases occurred in 21%, 11% and 4% of 56 cases with eyelid melanomas, respectively.[23] Pathological margins of >2 mm were associated with increased disease-free survival, compared with margins ≤2 mm. Lower eyelid melanomas were found to have significantly higher recurrence rate than upper eyelid tumors.

2.2.2.3. External ear melanoma

Although external ear melanoma had been considered to be a more aggressive type of melanoma, this hypothesis is not supported by more recent evidence. Histologically, melanomas arising on the external ear are most frequently superficial spreading melanomas (33-46%), followed almost equally by lentigo maligna (19.6%-26%) and nodular (16-22%) types. While narrower excisional margins and Mohs surgery are gaining acceptance in the treatment of ear

melanoma as well, the use of these techniques are associated with significant (30%) recurrence rates.[24] Therefore, management should follow standard melanoma treatment recommendations in external ear melanoma cases, if feasible (Figure 2.c).

2.2.2.4. Mucosal melanoma of the head and neck

Achieving melanoma-free resection margins is often difficult in this melanoma type (Figure 2.d). This may be attributed to the close proximity of critical anatomic structures, the presence of satellite formation, multifocality, angiolymphatic invasion, and submucosal spread, which are common features in oral cavity and sinonasal melanoma. The 2-year and 5-year survival rates for mucosal melanoma of the head and neck are 54% and 32%, respectively. Taking into account the high recurrence rate in this melanoma subtype, even apparently localized lesions may require radical surgery with planned reconstruction.[25,26]

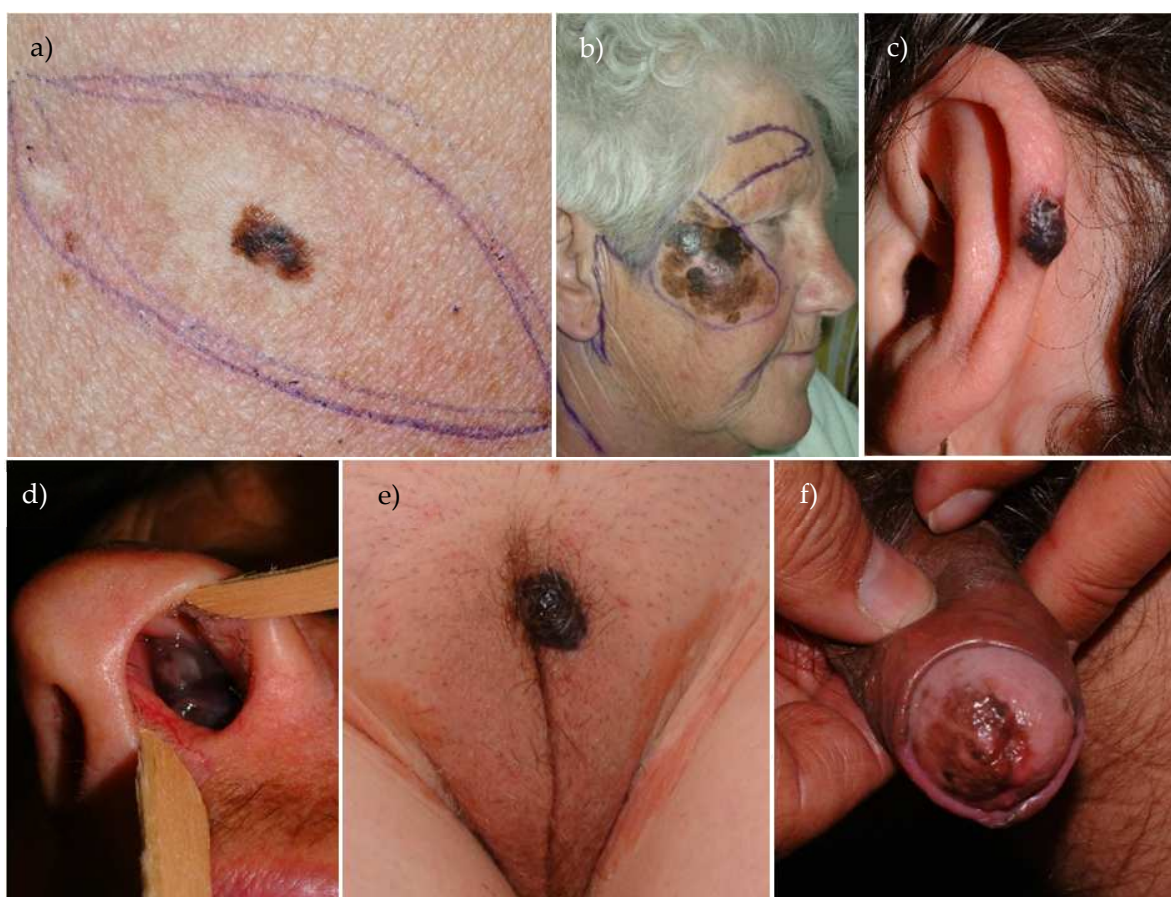

Figure 2. Melanomas in special anatomical regions require individual surgical approach. In case of in situ melanoma not lentigo maligna type (a), a 5-6 mm surgical margin is sufficient to ensure clear resection margins. In case of lentigo maligna type in situ melanomas (b), a wider, 10 mm margin is recommended, if feasible. Management of external ear melanomas (c) should follow standard melanoma treatment recommendations, if feasible. Mucosal melanomas of the head and neck region (d) require radical surgery with planned reconstruction in most cases. For mucosal melanoma of the female genitalia (e) wide excision with a 1-2 cm margin is recommended. Melanoma of the glans, preputium or urethra (f) wide local excision or penectomy provides effective local control.

2.2.2.5. *Mucosal melanoma of the female genitalia*

Although 70% of patients present with clinically localized disease, the overall prognosis of this melanoma type is poor. Surgical management of vulvar melanoma (Figure 2.e) consist of wide excision with a 1-cm margin for melanomas with a thickness of <1 mm, and a 2-cm margin for thicker lesions.[27,28]

2.2.2.6. *Mucosal melanoma of the male genitalia*

Melanoma of the glans, preputium or urethra is certainly an uncommon entity. Therefore, standard recommendations are not available for the management of this subtype of melanoma. Partial penectomy or WLE provided effective local control for low stage penile (Figure 2.f) or urethral melanomas and all scrotal lesions.[29]

2.2.2.7. *Anorectal melanoma*

Because of the rarity and the advanced stage at which most patients present, a standard surgical intervention has not been established to date for anorectal melanoma. Usually, wide local excision (with negative margin) is the preferred surgical management in most patients. Extensive disease that is not amenable to local excision, may require abdominoperineal resection.[30]

2.3. **Surgical techniques**

2.3.1. *Neck and face*

The face is an important area because it encompasses the eyes, nose, mouth and it is in proximity to the ears. The surgical radicality of extension must often be compromised to avoid injury to these structures. These structures limit the excision margins for surgical treatment of melanomas occurring on the face. In the management of cutaneous melanoma the first step is the wide local excision.

The first goal is to treat the cancer with maximal protection of function and aesthetics. We need take notice of the size and the localization of the defect, what kind of tissues are missing (bone, muscle, fat, skin, cartilage, etc.), the base of the wound, the acceptable functional impairment, the morbidity of the donor area, the moveable area around the defect, the history of the patient (previous operation or irradiation) and the expectations of the patient too. Ideally incisions should be within the relaxed skin tension lines (RSTL) or parallel to them, so the scars will be functionally and aesthetically superior. The RSTL is a complex interaction of the external and internal factors, which contains the skin as well.

If there is a melanoma on the neck, middle or lower area of the face, we can perform an elliptical excision parallel to the RSTL with a 3 to 5 mm safety border, undermining the surrounding area and closing the wound primarily.[17] If the tumor size is bigger we need to prepare local flaps to cover the defect. Local flaps' blood supply are very reliable, random pattern from the surrounding tissues or axial pattern from a named source artery. The laxity, quality and texture

of the surrounding skin is the best to prepare local flaps and it is the nearest approach to the defect's skin.

If the size of the defect is too big and there is no possibility for local flaps, skin grafting can be performed. There are split-thickness and full-thickness skin grafting. The split-thickness skin is 0.25-0.75 mm thick, the procedure is simple, fast, and not demanding. The donor area heals spontaneously and is fit to be used again as a donor area, although the graft may contract and become hypo- or hyperpigmented. The full-thickness skin is 0.8-1.1 mm thick, it rarely contracts and/or gets pigmented, it is more resistant against external cues compared to split-thickness grafts, and the subcutaneous layer may regenerate. On the other hand, this surgical technique is more demanding for the patient, and it requires a good blood supply of the recipient area, which limits the size of the graft. Lastly, the donor area needs to be sutured /closed primarily.

Recommended flaps are: rotational facial flaps, bilobed flaps, transpositional flaps, V-Y advancement flaps (Figure 3.). It is uncommon to use distant flaps on the face except for some cases, when there is not enough skin in the surrounding areas, due to irradiation or previous operations.

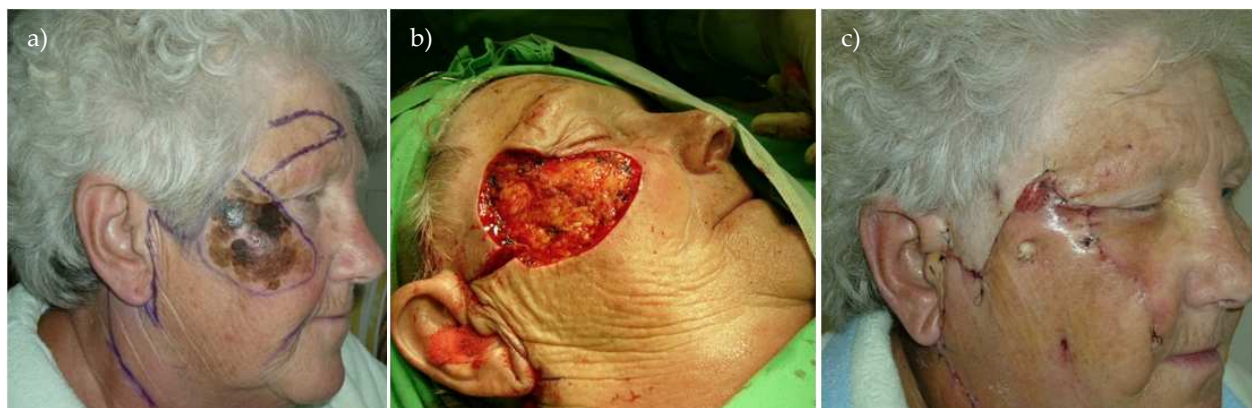


Figure 3. Removal of extensive melanoma from the face and reconstruction with combined local flaps. Melanoma (lentigo maligna type) on the face. Note markings of planned flaps (a). Extensive tissue defect after excision of melanoma with surgical margins. Reconstruction with combined local flaps (b). Good cosmetic result on 10th postoperative day (c).

2.3.2. Eye

After primary melanoma excision the choice of repair depends on the size and location of the defect, surrounding tissue mobility, degree of vascular compromise, extent of lamella loss, skin texture and color match. It is not common to excise and primarily close the wounds around the eyes.[31] In general it is done, if the size of the melanoma is very small, the melanoma is in situ, there is a sufficient skin laxity, or the patient's general health status does not permit more intensive surgical intervention. In the periocular region a 5 mm margin of excision for thin eyelid melanomas is recommended.[32,33] Care must be taken to avoid placing too much tension on the eyelid. If the defect involves one third of the eyelid margins, we can perform pentagonal wedge closure after the excision.

We have to pay attention to the canthal regions and the lower eyelid to avoid their injuries, leading to dryness and ectropium. We should also pay attention to the eyebrows and try to reconstruct them.

In this region primarily we perform local flaps and skin grafting or cartilage grafting to cover the defects after melanoma excision. The local flaps can be skin, skin-subcutaneous and skin-muscles flaps from the surrounding area, where the laxity, quality and texture are the best suited to cover these defects. Their blood supply can show random pattern from the subcutaneous layer or axial pattern from a named source artery. In these cases it is advisable to do cantopexy to prevent ectropium evolution.

Recommended flaps are: V-Y advancement flap, Tenzel and Mustarde rotation flaps, Rhomboid-Limberg transpositional flaps, Median and Paramedian forehead flaps and Glabellar flap.[31,33]

Full-thickness skin graft is used in this region to minimize scarring and pigmentation. It protects against extrinsic factors and the subcutaneous layer may regenerate. Disadvantages of full-thickness skin grafting include demanding surgery, the need for good blood supply in the recipient area and the need for suturing in the donor area. The size of this graft is also limited (Figure 4.).

If the tumor involves the tarsal plates and after the excision of the melanoma a tarsal defect develops, auricular or nasal free cartilage graft can be used to cover the defect. Generally, the cartilage graft can be covered with a local flap to reconstruct the total eyelid layers. In these cases composite grafts may be used as well, which contain skin, cartilage and, if necessary, conjunctiva.

Occasionally, if the patient's general health status is poor, it is acceptable in the medial canthal area to leave the defect open, and let it heal by second-intention. Adequate wound management and dressing should be applied to help the granulation and epithelisation. Another use of second-intention healing is to delay skin grafting. After granulation the skin graft procedure can be performed.[31,33]

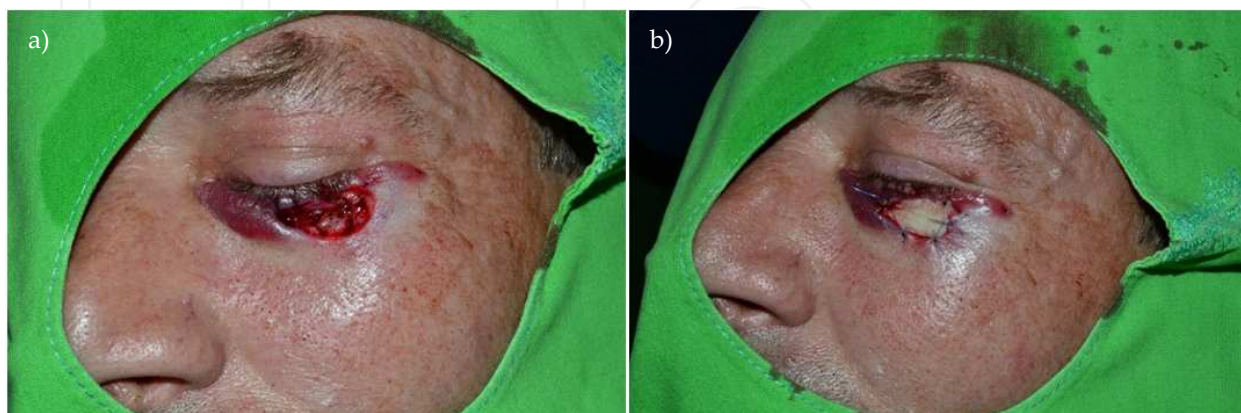


Figure 4. Full-thickness skin grafting for the reconstruction of lower eyelid defect after excision of melanoma. Lower eyelid defect (a) and full-thickness skin graft covering of the defect (b).

2.3.3. *Nose*

The nose is a three-layered structure of a skin and fibrofatty covering, a bony and cartilaginous framework and an inner lining of vestibular skin and nasal mucosa. Nasal defect may involve these layers alone or in combination.[34,35] The nose is divided into topographic subunits, as tip, dorsum, sidewalls, alar lobules, soft triangles and columella.[34,35] A wide range of techniques including defect and subunit reconstruction – using simple as well as more complex flap and multistaged procedures – must be in the surgeon's armamentarium. When a defect involves greater than 50% of a subunit, replacement of the entire subunit should be considered. We can perform primary wound closure after elliptical excision with undermining the surrounding area only on the dorsal region if the size of the tumor is not too large and the skin is loose. Second-intention healing is good only for superficial wounds on concave surfaces.[34] If the tumor size is bigger we can use local flaps from the middle face and the frontal region. (Figure 5. and 6.) The nasal tip, columella and alar regions are more difficult, and primary closure is usually not possible. Instead we use local flaps, skin grafting and composite grafting in these regions. The advantages of local flaps over skin grafts include better contour, color and texture match and less scar contracture. The most common local flap is the nasolabial flap, while the forehead flap remains the workhorse for major nasal reconstruction with numerous modifications.[34] Some others are the dorsonasal flap, glabellar flap, advancement flap from the middle face, and flaps from the upper perioral region. These local flaps are useful for defects of about 2 cm or less. If the tumor is large enough to require a tip and alar nose amputation, we can use reconstructive surgical methods or prosthetic devices. Full-thickness skin grafting is easy to perform and it is useful in the reconstruction of superficial defects in the areas of the tip and alar lobules (Figure 7.). On the other hand, it may heal with a contrasting flattened and shiny appearance.[34,35] The term composite graft means that skin and cartilage are grafted together from the conchal region, helical rim or helical root.

2.3.4. *Ear*

On the ear after wide excision, which includes skin and subcutaneous tissue removing, primary closure is usually not performed. There are many options for the reconstruction of auricular defects including direct closure, second-intention healing, full thickness skin grafts and local flaps.[36,37] The defects of the posterior wall of the ear, where the skin is more abundant and loose, can often be closed primarily. If the defect is in the central and anterior region with intact cartilage, most defects will do well by second intention healing or full thickness skin grafting.[37] If the defect involves the cartilage the most common surgical procedure is wedge excision, which means excising the skin and cartilage together in a V or W form. After these excisions we should reconstruct the cartilage and then the skin. If larger excisions are necessary, we need to use local flaps, which are from the earlobe, pre-and retroauricular regions. These flaps include direct advancement flap, rotational flaps, transposition and subcutaneous island flaps. If more than one third of the ear is involved by the tumor, we need to perform partial amputation. If the tumor is in an advanced stage, it may be necessary to amputate the whole ear. Amputation requires more complex reconstructive surgical methods to restore the ear or prosthetic devices can be used.

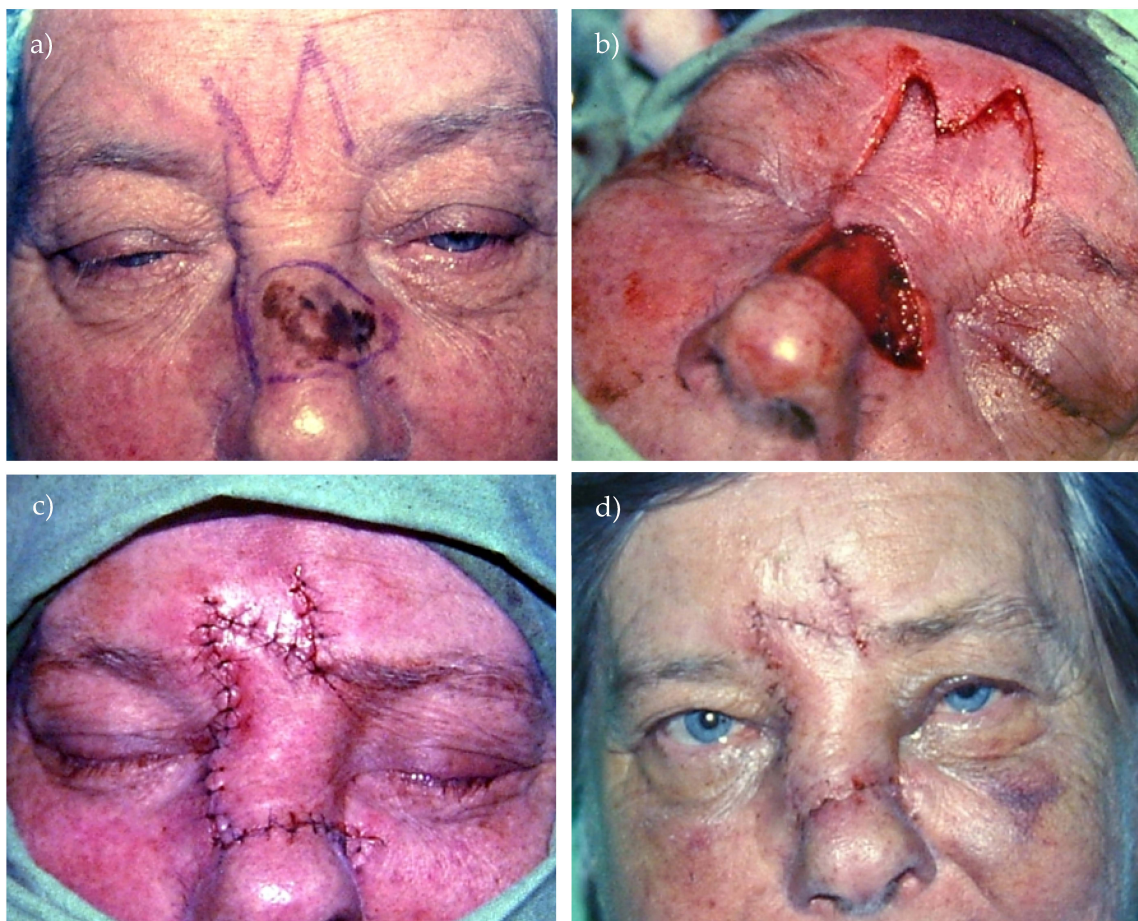


Figure 5. Glabellar flap for the reconstruction of a defect on the dorsum of the nose after wide excision of melanoma. Extensive melanoma on the dorsum of the nose (a). The defect and preparing glabellar flap (b). Suturing the flap (c) and postoperative results 3 weeks after operation (d).

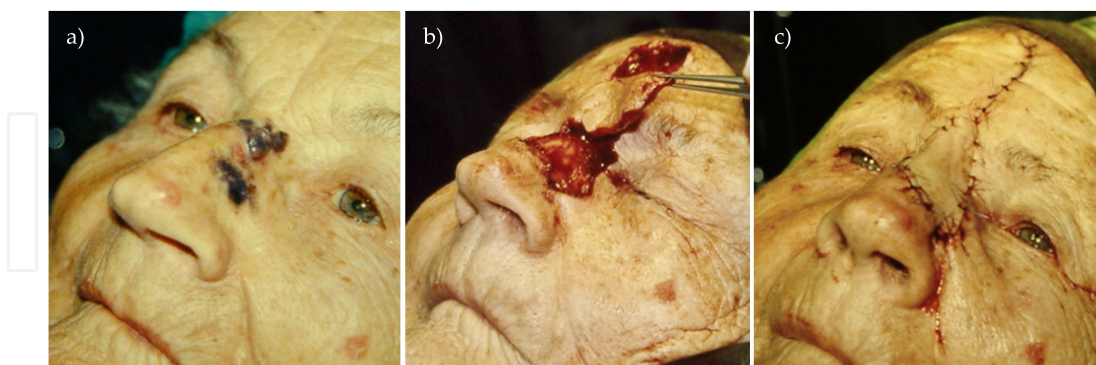


Figure 6. Forehead flap for the reconstruction of nasal and glabellar defect after melanoma excision. Melanoma on the nose and glabellar region (a). After excision and performing forehead flap (b) Suturing the flap. Good cosmetic result (c).

2.3.5. Mouth and perioral region

Melanomas in the perioral regions are not common. The tumor can involve the skin, the oral orbicular muscle and the mucosal layer alone or together.[37] In this region we should pay

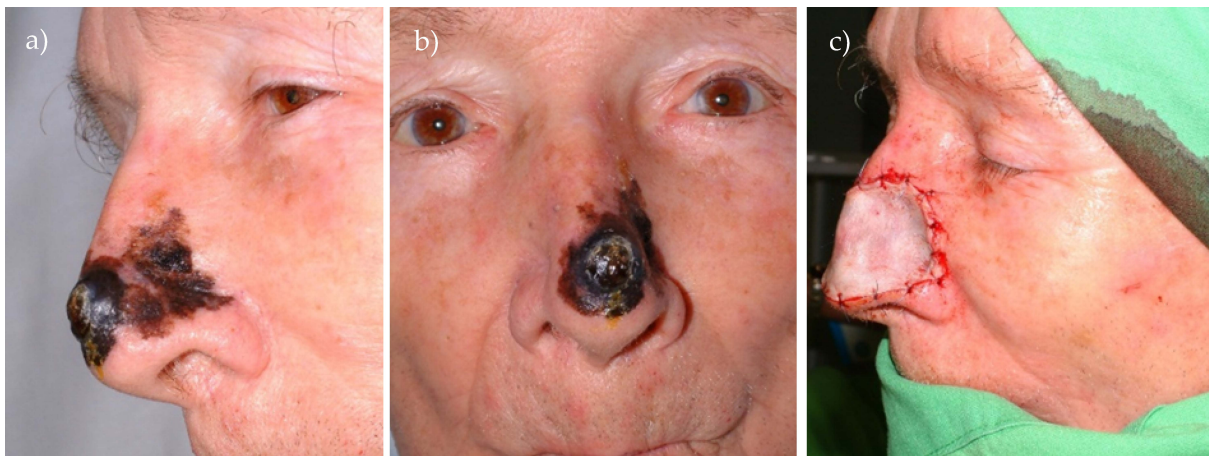

Figure 7. Split-thickness skin grafting for the reconstruction of extensive defect on the tip of the nose after excision of melanoma. Melanoma involving the tip and alar lobules of the nose (a-b) Split-thickness skin graft covering of the defect (c).

attention to protect the muscular-, sensorial-, and the closing function of the mouth, the adequate oral access for eating and to the use of dentures, to the symmetry, the upper/lower lip ratio and the quality of scars.[37] After tumor excision, if the defect is less than one half of the lip width, we can use primary wound closure after undermining the surrounding layers. Primary closure offers the best aesthetic result and should be prioritized. In the upper lip we can perform wedge excision while in the lower lip W-shape excision is used. In cases of large tumor size the defect can be covered by local skin-, and skin-mucosal flaps originating from the perioral region or from the lips and the inner surface of the mouth. The ideal donor areas for labial reconstruction are the remaining labial tissue and the opposing lip.[37] The lip is elastic and can be elongated, which is a very useful for reconstruction.

Recommended local flaps are: V-Y advancement flap, Rotational flap, Nasolabial flap, Forehead flap, Abby flap, Estlander flap, Karapandzic flap (Figure 8.).

2.3.6. Digits

The skin of the hand and toe is specialized and structurally unique, balancing the need for sensing, mobility for complex motor skills on the hand, durability to withstand wear and tear on the toe.[38] Earlier melanomas arising on the skin and/or nail bed of the digits were most frequently managed with amputation at the proximal joint from the tumor. Recently tissue- sparing excision is performed increasingly.[38] When excising melanomas on the toes, amputations should be limited to preserve as much length and function of the digit as possible without compromising the necessary safety border. It requires a more conservative surgery, wide excision and only partial resection of the affected phalanx.[38] The excision is done in the subcutaneous layer and on the fingertip, the entire nail complex needs to be removed. In these cases the defect can be covered with a local flap, like V-Y advancement flap, or we can use local flaps from the neighboring digits. If the bone is not directly involved it is not necessary to remove the total phalanx or metacarpus or metatarsus, since the removal of bone in these localisations does not have oncological benefit (Figure 9.).

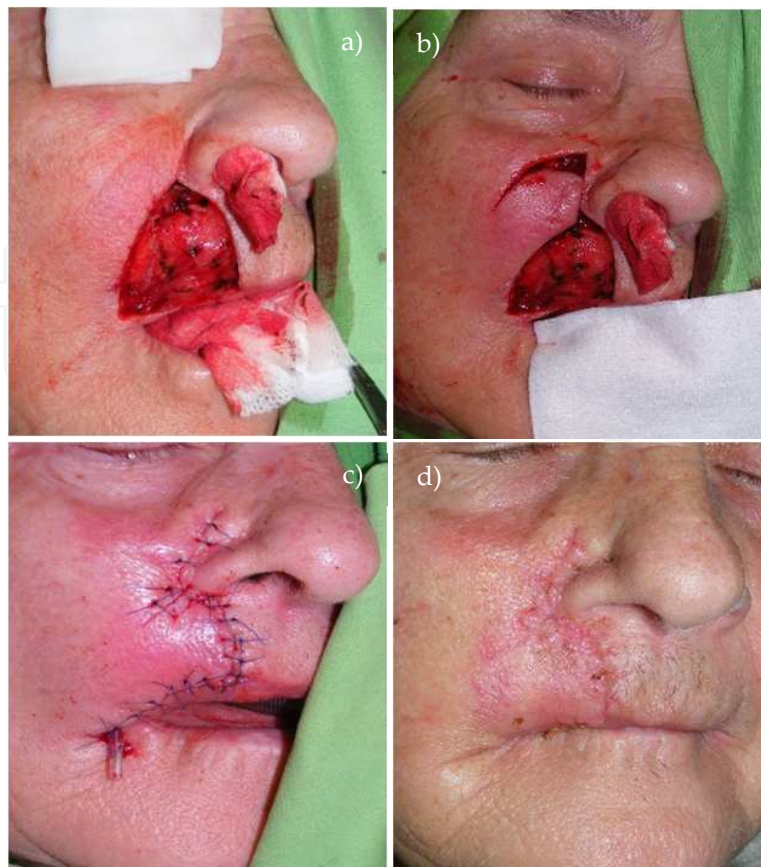


Figure 8. Reconstruction of facial defect with local flap after removal of melanoma. Large defect in the nasolabial region after melanoma excision (a). Preparing the local flap (b). Closing the wound with sutures (c). Good postoperative result 2 weeks after the operation (d).

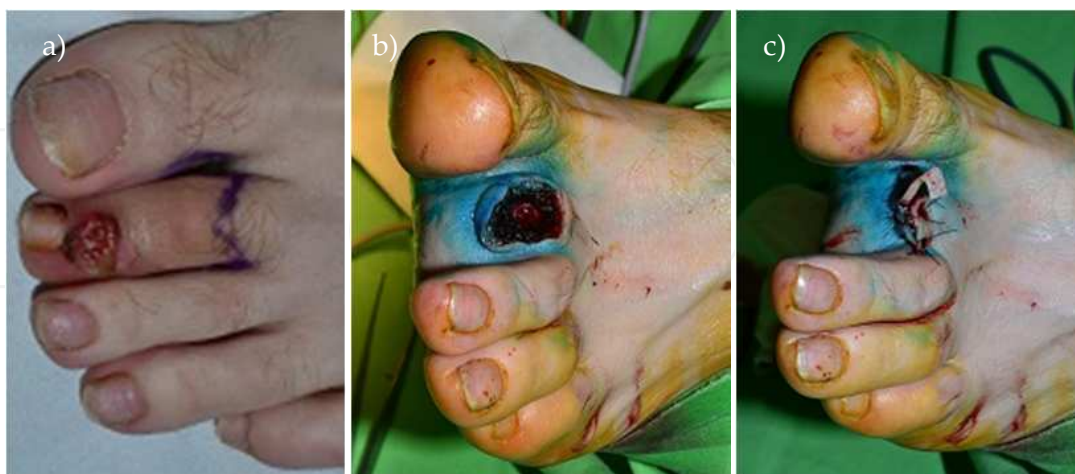

Figure 9. Surgical management of amelanotic melanoma on the toe. Melanoma present on the distal phalanx of the toe (a). Amputation at the distal phalanx (b). Suturing of the wound (c).

2.3.7. Interdigital spaces

Melanomas arising between the digits is difficult to treat. Covering to these defects can be done with full thickness skin grafts and local flaps. It may be necessary to remove the phalanx and metacarpuses and/or metatarsuses depending on the progression of the tumor.

2.3.8. Hand and foot

Acral lentiginous melanoma tends to be diagnosed at later stages due to medical diagnostic mistakes and patients' poor attention to lesions arising on extremities.[38] The reconstruction of the defects after melanoma excision on the dorsal or plantar region of the hand is challenging. Generally we can use full thickness skin grafts or local flaps and we should pay attention to retaining function. First, it is important to cover the joints, tendons and bones. If the defect is large we can perform distal flaps with microsurgical techniques. It is important to mind the weight-bearing regions of the foot, because reconstructing these defects requires a flap from the adjacent area or a free flap with microvascular anastomoses that contain adequate soft tissue to cover the defect and to supply the function too.

3. Surgery of locoregional recurrence of melanoma

Locoregional recurrence can occur as regional nodal disease or as satellite or in-transit metastases.

In-transit metastases are locoregional relapses found between the primary melanoma and the draining lymphatic basin. By definition lesions that occur more than 2 cm from the primary melanoma are termed in-transit metastases. The ones that are located closer (≤ 2 cm) are regarded as satellite lesions (Figure 10). The risk factors for the development of in-transit metastases include lymph node involvement and was confirmed as the most important prognostic factor by Weide et al.[39] Furthermore the risk of local recurrence increases significantly as the thickness of the primary melanoma increases and with the presence of ulceration.[15,39] Both satellite and in-transit metastases are regarded as stage IIIB (without regional nodal metastases) or stage IIIC (with regional nodal metastases) disease by the 2009 American Joint Committee on Cancer staging system and are associated with worse prognosis than local recurrence.[40] Patient with locoregional recurrences should undergo staging procedures (e.g. PET, CT scans) to rule out presence of distant metastatic disease. If there is no evidence of extraregional disease, the treatment strategies for in-transit metastatic disease depend on the size, number and location of the lesions.

In case of solitar lesion or limited disease surgical excision of the metastases with histologically negative margins is the adequate treatment. The precise width of surgical margin is not determined. The resection should be with generous margin depending on the anatomic site involved. Multifocal metastases within a circumscribed area may be resected en-bloc. Primary closure is preferred if possible, however skin grafting or flaps may be done for skin coverage. In patients, who have surgical resectable in-transit metastases and have not had a lymphane-

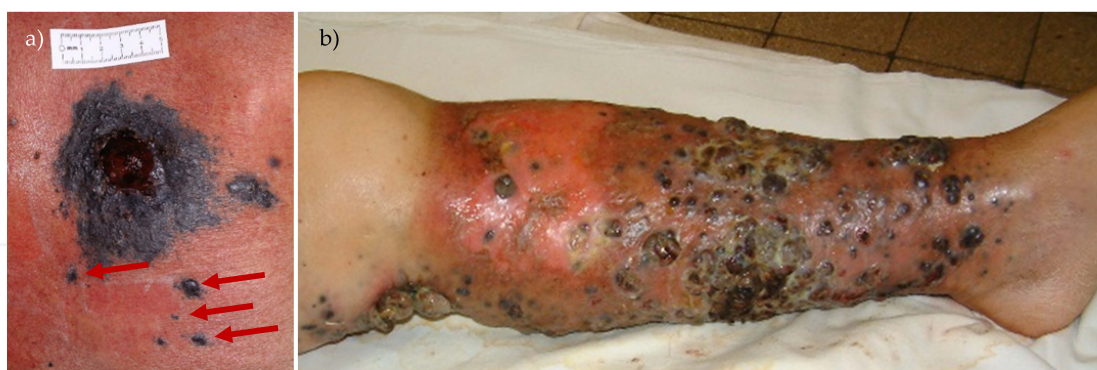

Figure 10. Satellite metastases (red arrows) around primary melanoma (a) and multiple cutaneous and subcutaneous in transit metastases on the lower leg (b).

delectomy previously a sentinel lymph node biopsy (SLNB) may be considered.[41,42] Some authors recommend performing SLNB even for patients who had undergone SLN biopsy earlier or lymph node dissection suggesting a potential benefit for proper staging and for administering the adequate therapy.[43,44]

In the presence of multiple, inoperable, locoregional cutaneous metastases on the extremity isolated limb perfusion (ILP) should be considered.[45,46] A systematic review of twenty two studies, including 2 018 patients[47] who had isolated limb perfusion concluded that the median complete response rate to ILP was of 58.20%, with a median overall response rate of 90.35%. Amputation for extensive regional recurrence is rarely indicated, as patients in such cases have a high risk of development of metastases in distant organs and no survival benefit can be achieved.

For refractory-, recurrent and for anatomically unresectable lesions intralesional (interferon, interleukin-2) or topical (imiquimod, diphencyprone) therapy, cryosurgery, electrochemotherapy, laser-, radio-, and systemic therapy may also be an effective treatment option.[48-51] Electrochemotherapy combines intravenous or intralesional cytotoxic drug, most commonly cisplatin or belomycin and intralesional electric pulses (Figure 11.). The electric pulse creates cell membrane poration resulting in a better penetration of the chemotherapeutic agent.[52,53] A study has reported a 72% objective response rate of the total of 54 lesions treated with electrochemotherapy.[53] However, superiority of one over the other has not been proven and the choice of the method depends on individual factors.

Patients suspicious for regional lymphnode recurrence should have a fine needle biopsy to confirm the diagnosis and a workup (PET CT or CT scans) to rule out distant metastases. Then lymphadenectomy should be performed in patients who did not have one or the lymphnode dissection was uncompleted. For patients who have undergone previous lymphadenectomy, excision of the recurrent tumor is still indicated, if feasible. In this case the marking of the lymphnodes by ultrasound prior the surgery makes the surgeon's job easier. In patients with recurrent disease limited to the regional lymph node basin, completion lymphadenectomy offers the best potentially curative treatment option and can provide excellent long-term survival for selected patients.[54]

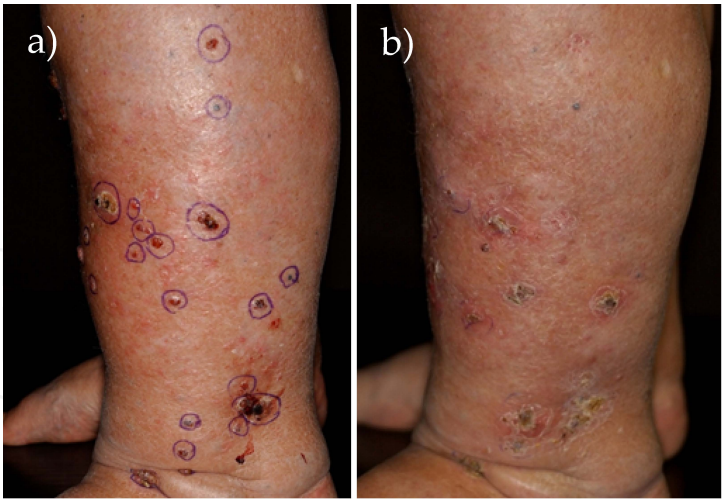


Figure 11. Electrochemotherapy (bleomycin) of multiple cutaneous and subcutaneous melanoma metastases. Before (a) and 10 days after (b) therapy. Photos courtesy of Erika Kis MD, PhD, Department of Dermatology and Allergology, University of Szeged, Hungary.

4. Surgery of stage IV disease

Metastatic melanoma has a poor prognosis and a median survival of 6-10 months depending on the site of metastasis.[40] These patients are classified as stage IV according to the American Joint Committee on Cancer (AJCC 2009) staging manual and seperated into three groups (Table 2.). Stage IV patients with M1a disease have higher survival rates than patients with lung metastases (M1b), who have a better prognosis than those with M1c disease with or without elevated lactate dehydrogenase serum levels (LDH).[55]

M classification	Site of distant metastases	LDH level
M1a	Metastases of the skin, subcutis or lymph nodes beyond regional lymph nodes	normal
M1b	Lung metastases	normal
M1c	Distant metastases at other location or Distant metastases at any location with elevated serum levels of LDH	normal elevated

Table 2. M classification of distant metastases in melanoma according to AJCC 2009.

Currently there is no gold standard care for treatment of stage IV disease. The therapeutic landscape for melanoma is rapidly changing. The first novel agent showing overall survival benefit in unresectable stage III or metastatic melanoma was an anti-CTLA4 blocking monoclonal antibody (ipilimumab) approved by the FDA in 2011.[56] Since then target therapies have been approved for the treatment of metastatic melanoma (BRAF inhibitors: dabrafenib, vemurafenib, MEK inhibitor: trametinib).[57-59] Moreover new immun (e.g. PD-1 inhibitors) and target therapies are on their way. The impact of these drugs on survival rates are clear and promising, but surgery of distant metastases could increase this rate.

Numerous studies, mainly retrospective, showed that patients in whom complete surgical excision of metastases was carried out have a 5-year survival rate of 15–28 % vs. 5–10% in patients who received systemic therapy alone.[60–64] The prospective trial of the Southwest Oncology Group showed a median overall survival of 21 months (overall survival at 3 and 4 years were 36% and 31% respectively) in 64 patients whose metastases had been completely resected. The majority of the patients had one disease site (n=50) and skin and soft tissue sites were present in more than 50% of the cases. The authors concluded that aggressive surgical therapy with follow up adjuvant therapy can be an appropriate cure for these selected patients. [65] International MMAIT-IV trial further supported the role of surgery for stage IV melanoma. In this prospective trial patients who had undergone complete resection of their metastatic disease were treated with two types of immunotherapy. The 5-year survival was 40–45%.[66] The Multicenter Selective Lymphadenectomy Trial (MSLT-I) also suggested that patients with complete resection exhibit an improved survival compared to patients receiving systemic therapy alone, regardless of site and number of metastases.[67]

Despite that these data are persuasive for surgery in patients with distant metastases, surgery is rarely used in stage IV melanoma except for palliation. Many oncologists believe that once melanoma has spread to a distant site, surgery is not helpful because patients already have occult micrometastases and circulating tumor cells. In the report of Koyanagi et al[68,69] 52% of stage IV patients had detectable circulating tumor cells. However the presence of tumor cells in the blood do not obviously generate metastatic lesions. Most of stage IV melanoma patients at first have disease progression in one organ and the number of metastases in the site can vary.

The advantage of surgical resection of metastatic melanoma is that it may delay disease progression by interrupting the metastatic cascade associated with hematogenous seeding of cells to other sites.[70,71] Surgical resection also decreases tumor burden thus reducing tumor-induced immunosuppression. Metastases greater than 2 cm are eradicated easier with surgery than with systemic treatments.[72] In addition, surgical resection has less side-effects than systemic therapeutic agents.

The recent development of imaging techniques has led to more accurate detection of metastases (size of 5–10mm), aiding surgeons in improved delineation of the extent of the disease and planning for the operation. In line with this development in surgical techniques, anesthesia and intensive supportive care have reduced operative mortality and morbidity rate even for multiple metastectomy.[71] It is evident that appropriate patient selection is essential for a good outcome.

Surgery in metastatic diseases is most effective in patients with small number of metastases and/or few metastatic organ sites.[73] Based on the MSLT-I study and Wevers et al, the percent of stage IV patients eligible for surgery can range widely from more than half to only 22%.[67, 74] In deciding about surgery, one should consider underlying co-morbidities, performance status and life expectancy. If no survival benefit and/or advantage in quality of life can be achieved with surgical metastectomy, it may be disregarded. It has been shown by numerous studies that complete (R0) resection is associated with a better survival and in all cases com-

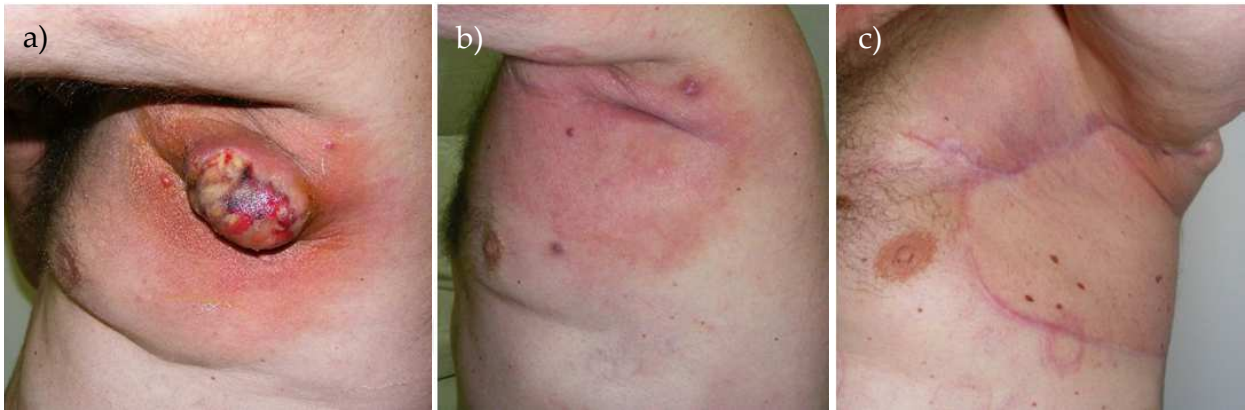


Figure 12. Neoadjuvant BRAFi in the treatment of melanoma. The 52 year-old patient with unknown primary melanoma and inoperable metastases in the left axillary region (a). BRAF inhibitor (vemurafenib) was initiated. After 3 months of BRAF inhibitor treatment the tumor almost completely regressed (b). Subsequently, the patient underwent surgery for the remnant disease (c).

pletness should be strained by the surgeon.[75-78] Further prognostic factors are prolonged disease-free survival and a tumour-volume doubling time of >60 days.[73,79,80] (Table 3.).

• Feasibility of complete surgical resection (R0)
• Number of metastases
• Site of metastases
• Tumor doubling time
• Disease free interval
• Other therapy modalities
• Acceptable functional deficit
• Co-morbidities

Table 3. Factors to consider prior to surgical resection in stage IV melanoma

Multiple disease sites are not a contraindication to surgical resection but all of the factors mentioned above should be considered before procedure. Reccurent disease can be treated with repeated metastectomy.[81-83] Ollila et al points out that prolonged disease-free interval prior to recurrence and complete surgical metastasectomy of the recurrence were the two most important prognostic factors for survival after recurrence.

In the case of large tumor masses, when surgery can not be carried out, effective systemic treatment prior to surgery is advisable in order to treat the initially unresectable disease. Neoadjuvant setting has been successfully applied in several solid tumors (e.g. breasts, head and neck cancer) but it has not been used in advanced cutaneous melanoma, because no effective systemic treatments were available for this disease. The presence of new systemic therapies (biological and target) may change this. Several case reports have shown the beneficial effects of BRAF inhibitors. Patients with unresectable bulky disease regained surgical suitabilty after taking the drug for a couple of months[84-86] (Figure 12).

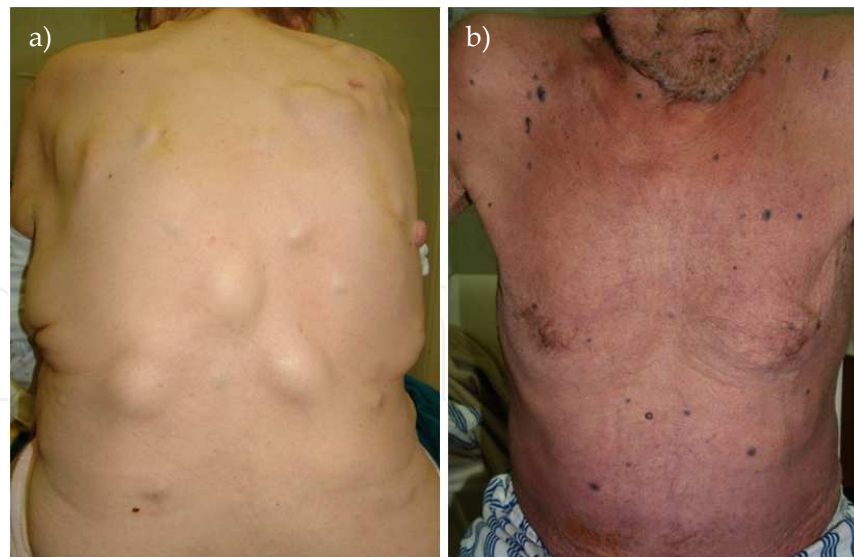

Figure 13. Multiple distant soft tissue metastases (a) and multiple distant skin metastases (b).

In contrast to BRAF inhibitors, ipilimumab seems to be a less effective agent in neoadjuvant setting because of its mechanism of action and relatively slow pattern of time response. However the surgical excision of lesions that are resistant to treatment with ipilimumab may improve outcomes for some patients. Other immunotherapies are in development (PD-1 inhibitors) which show an earlier tumor response compared to ipilimumab.[87] Overall, surgical resection of metastatic lesion in highly selected patients appears to offer a survival advantage over systemic treatment modalities alone. The decision for surgery of stage IV melanoma patients should be discussed at an interdisciplinary tumor board. After complete metastectomy, adjuvant therapy may be indicated as melanoma is likely to recur. Surgical resection should be considered more often than it is currently practiced, since the combined advances in imaging techniques and promising novel systemic agents can improve patients' quality of life and clinical outcomes.

4.1. Surgery of distant skin, soft tissue and lymphnode metastases (Stage IV M1a)

Almost 40% of patients with stage IV melanoma have M1a disease.[88] Median survival of patients in this group is 18-40 months. Skin and soft tissue metastases are usually associated with a better prognosis than distant lymph node disease (Figure 13.). Positive prognostic factors for M1a disease are fewer lesions, longer disease-free interval, and smaller size of tumors.[61] Skin and soft tissue metastases should be resected as soon as possible before the metastases becomes large and, if applicable, with wide margins (2 cm). In case of lymphnode metastases regional lymphnode dissection is performed (for details see section on lymph node dissection). Factors to consider prior to surgical resection in stage IV melanoma are summarized in Table 3. Complete surgical resection of M1a disease can promote survival up to 60 months, even after recurrence.[81] Metastases can ulcerate causing pain, bleeding, infection, and decreased quality of life. Surgical resection for palliation may be indicated in these situations.

4.2. Surgery of pulmonary metastases (Stage IV M1b)

The lung is the most typical site of visceral metastases (40%) for melanoma. Pulmonary metastases are associated with a longer survival than metastases to other visceral sites.[40] A growing number of studies have shown that pulmonary metastectomy improves survival [89-96] (Table 4). Tafra et al reported that of 984 melanoma patients with lung metastases, the 106 patients that underwent metastectomy had better 5 year survival than patients treated with non-surgical methods (27% vs. 3%, respectively).[79] Chua et al conducted a large single center study with 1737 patients.[89] 292 patients had surgery for lung metastases and the 5-year survival for this patient group was 38%.

According to the various reports, factors predictive of improved survival are: ability to achieve a complete resection, prolonged disease-free interval (>36 months), 2 or fewer pulmonary nodules,[89-91] size of the largest metastasis <2 cm, prior response to chemotherapy/immunotherapy, and male sex.[92] While the disease may recur, most of the data demonstrate that long term survival can be achieved with repeated metastectomy (in cases of extra-thoracic lesions also) in suitable patients.[91]

The presence of multiple and even bilateral pulmonary nodules is not a contraindication to surgery.[89,97] Interestingly, hilar or mediastinal lymph node involvement did not have an effect on survival.[93] In most cases pulmonary metastectomy involves wedge resection and segmentectomy with occasional indication for lobectomy.

Author	Number of patients undergoing surgery	Median OS (months)	5 year survival (%)
Andrews et al[91]	86	35	33
Chua et al[89]	292	23	34
Leo et al[93]	282	19	22
Neuman et al[94]	26	40	29
Ollila et al[61]	45	23.1	15.6
Petersen et al[90]	318	19	21
Schunan et al[92]	30	18.3	35.1
Tafra et al[79]	106	23	27
Younes et al[96]	48	32	36

OS: overall survival

Table 4. Studies of pulmonary metastectomy in patients with lung metastases from melanoma

As mentioned earlier, patient selection in Stage IV disease is very important. Tumor doubling time (TDT), an index calculated on the basis of tumour growth rate as detected on the chest radiographs, is one of the major factors predictive of survival and should be used as a consideration in the decision of whether or not to operate.[80] Patients undergoing surgical managment of lung metastases should have pulmonary function and clinical condition

suitable for the operation, controlled primary lesion, metastases that appeared technically resectable on diagnostic imaging, and preoperative biopsy consistent with melanoma.

The spread of advanced imaging techniques (CT, PET) contribute to the earlier detection of melanoma metastases and give a more precise preoperative image of the location, thus aiding the accurate selection of surgery candidates (Figure 14.).

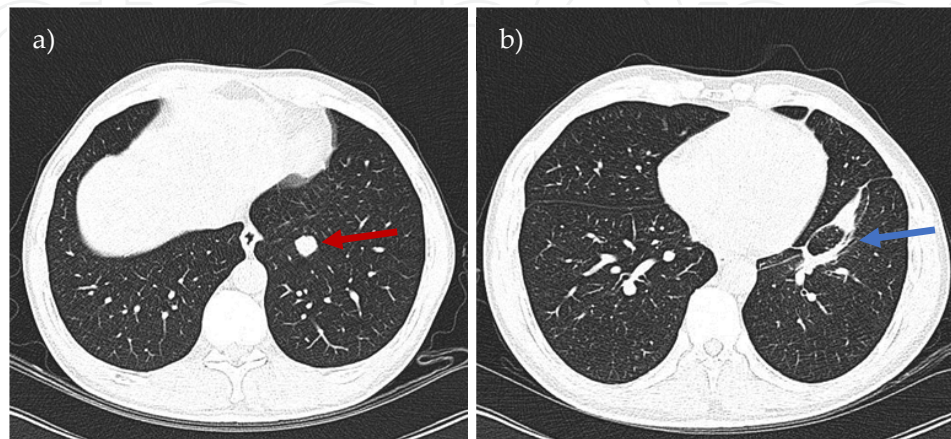


Figure 14. Solitary pulmonary metastases in a 40 year-old patient (red arrow). b. Post surgical scarring at the site of the metastases (blue arrow).

Upper aerodigestive tract metastases of melanoma are extremely rare. The patients are usually symptomatic with hemoptysis or cough. Treatments with appropriate aggressive multimodal therapies are needed in such cases (metastectomy, segmental resection, laser excision, external beam radiation).[98-100]

In conclusions, findings are suggestive that pulmonary metastectomy for carefully selected patients warrant a favourable outcome.

4.3. Surgery of visceral metastases

4.3.1. Liver metastases (Stage IV M1c)

Liver metastases can occur both in cases of cutaneous and/or ocular melanoma. It is important to distinguish them, as in metastatic ocular melanoma the liver is the predominant metastatic site (89% of cases) and often the first and only site of metastases.[100,101] In contrast, cutaneous melanoma metastases can occur in the lungs, lymph nodes, brain and soft tissue. Only few patients develop liver (15%-20%) and bowel metastases.[102,103] The difference in metastatic presentation is most likely driven by the absence of lymphatics in the uveal tract, therefore melanoma spreads hematogenously.[104]

Studies evaluating the role of surgery in the treatment of hepatic metastases from melanoma are mainly retrospective case series from single institutions. Some of these studies included non-surgical (chemotherapy, best supportive care etc) comparator arm, while others did not have a control group.[76-78,105-108] (Table 5.)

The comparative studies showed a longer median overall survival in patients who underwent hepatic resection compared to non-surgical treatment in both ocular and cutaneous melanomas. Overall survival was 2-4 months for patients with unresected hepatic metastases versus 28 months for those with completely resected liver metastases.[78] A recent metaanalysis of five studies also revealed a significant improvement in overall survival after surgery compared to non-surgical procedures.[109] The majority of noncomparative studies also reported benefit from resection of metastases.[66,75,110-114]

All studies observed that R0 resection was associated with longer overall survival than R1 or R2 surgery.[75-78]

Author	Melanoma type	Number of patients	Median OS (months)	5 year survival (%)
Adam et al[110]	Cutaneous and ocular	1452	19	21
Caralt et al[117]	Cutaneous and ocular	NR	26.3	NR
Chua et al[115]	Cutaneous and ocular	23	21	NR
de Ridder et al[75]	Ocular, cutaneous and unknown	32	29	3
Faries et al[107]	Cutaneous and ocular	1078	24.8	30
Frenkel et al[76]	Ocular	74	23	NR
Groeschl et al[111]	NR	NR	39	36
Herman et al[118]	Cutaneous and ocular	367	22	NR
Kim et al[119]	Cutaneous and GI tract	NR	9.5	4
Kodjikian et al[116]	Ocular	63	20.5	24
Mariani et al[77]	Ocular	798	23.0	NR
Marshall et al[105]	Ocular	188	24.0	NR
Pawlik et al[114]	Cutaneous and ocular	40	29.4	21 for ocular
Pilati et al[66]	Cutaneous and ocular	36	15	NR
Piperno-Neumann et al[108]	Ocular	470	21	NR
Ripley et al[112]	Cutaneous and ocular	539	36	53
Rivoire et al[106]	Ocular	63	25	NR
Rose et al[78]	Cutaneous	1750	28	29
Ryu et al[113]	Cutaneous and ocular	33	29	42

OS: overall survival; NR: not reported

Table 5. Studies of hepatic resection in patients with liver metastases from melanoma

The outcome of surgery is also influenced by the number of metastases, length of disease-free interval and limited disease distribution.[78,115,116] However, eligibility for surgery upon the extent of disease and the number of metastases varied in the studies. In the Kodjikian study[116], the cut-off number for resection liver metastases was 10 or less lesions.

Recurrence rates following hepatic resection in the studies ranged between 72% to 75%. [78,111] All in all the hepatic resection for malignant melanoma is a safe operation.

60-day mortality rates were recorded in some reviews at 1.9% and 2.3% and postoperative complications after metastectomy occurred in 15% to 20% of cases.[78,111]

In the treatment of hepatic metastases, systemic and /or non-surgical therapies can be applied in the form of adjuvant or neoadjuvant settings that supplement surgical resection. There are no clear data yet to determine the most efficacious time for the administration of systemic therapy secondary to surgery. Pawlik et al found that patients who had received adjuvant systemic therapy prior the hepatic resection had increased survival compared to patients having resection alone.[114] Adam et al reported increased survival in patients responsive to neoadjuvant chemotherapy.[110]

The data mentioned above indicate that both ocular and cutaneous metastatic melanoma patients with liver metastases benefit from surgery. To achieve this outcome, accurate patient selection is crucial. Only patients with limited disease/metastases who can be rendered surgically free of disease should be considered as candidates for hepatic resection. For patients with unresectable metastatic melanoma, systemic and /or regional (hepatic intra-arterial chemotherapy, hepatic arterial embolization, isolated/percutaneous hepatic perfusion) therapies should be taken into consideration.

4.3.2. *Gastrointestinal metastases (Stage IV M1c)*

Gastrointestinal (GI) tract is an uncommon metastatic site for melanoma malignum occurring in only 2-5% of patients. However, more than a quarter of patients with melanoma at autopsy revealed GI metastases.[120,121] Patients with metastases to the GI are often symptomatic with pain (29–64%), obstruction (27%), bleeding (27%), palpable mass (12%) or weight loss (9%). [122] In addition, the high incidence of metastases of melanoma in the small intestine has been recently assigned to the presence of functionally active chemokine CCR9 on melanoma cells that facilitate metastases to the small bowel.[123] In a large number of cases palliative surgery is needed to alleviate bleeding and /or obstruction. Looking at the survival benefit of surgery, some studies found significantly improved survival in patients who underwent surgery and had a complete resection.[121,124,125] Ollila et al. reported a 5-year survival rate of 41% after complete resection.[121]

In conclusion, metastatic melanoma of the gastrointestinal tract is very rare, but should be suspected in any patient with a history of cutaneous melanoma and new gastrointestinal symptoms. Surgical interventions for symptomatic patients with melanoma of the gastrointestinal tract significantly relieve pain and improve quality of life and may confer a survival advantage.

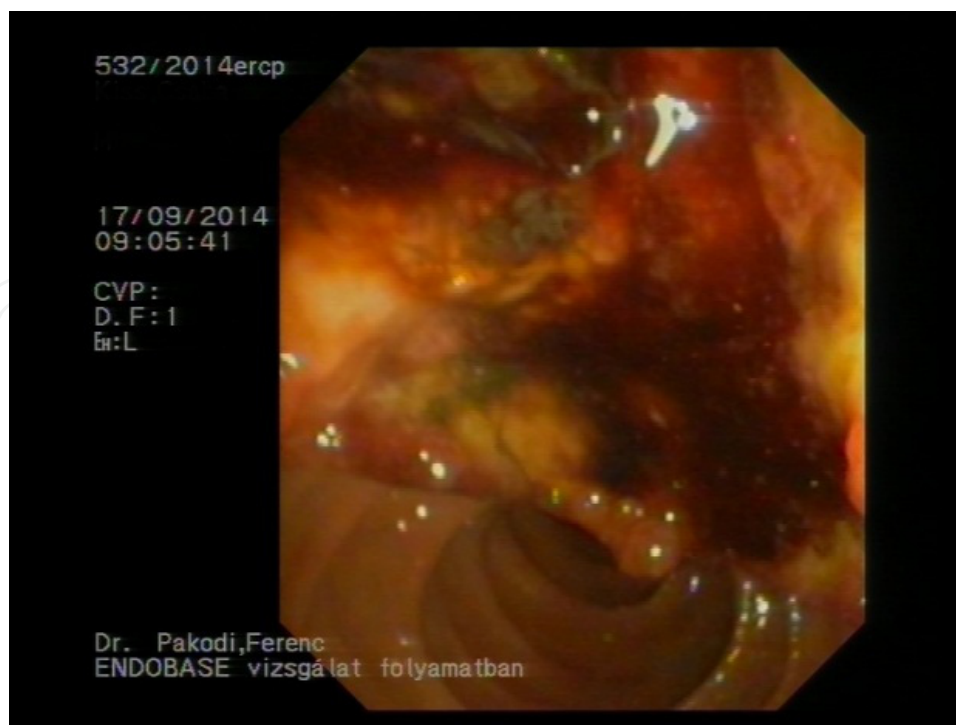


Figure 15. Duodenal melanoma metastasis.

4.3.3. Metastases to the spleen, the pancreas, or the adrenal glands (Stage IV M1c)

Isolated metastases to the spleen, pancreas or the adrenal glands are extremely rare. Few reports have demonstrated that surgical resection improves the 5-year survival.[62,126] Analysis of patients with solitary metastases to the adrenal glands yielded median survival times of 60 months.[127] In the study of Wood et al, sixty patients underwent adrenalectomy, hepatectomy, splenectomy, or pancreatectomy for melanoma metastases. The reported 5-year survival in the group after complete resection was 24%, whereas in the incomplete resection group, there were no 5-year survivors.[62,126]

4.4. Surgery of brain metastases (Stage IV M1c)

Metastatic disease to the brain is a frequent manifestation of melanoma with cerebral metastases accounting for 20-54% of deaths from melanoma.[128] It is associated with significant morbidity and mortality and poor prognosis. The median survival upon diagnosis of the cranial metastases is approximately 4 months.[129] Non-systemic treatment options are surgery, and stereotactic or palliative whole-brain radiotherapy.[130,131]

Usually patients present with symptoms such as seizures, vertigo, nausea, and vision alteration. In patients with good performance status and controlled primary disease, the surgical resection of solitary cerebral metastases is preferred. Positive prognostic factors in cases of brain metastases are younger age, good performance status, lack of neurologic symptoms, lack of extracranial disease and single focus of disease. Surgery might also be indicated for palliative

reasons. If the solitary lesion is unresectable due to localization or extracranial disease, the determination of BRAF status is essential, since the efficacy of BRAF inhibitor dabrafenib in cerebral metastatic disease has been shown.[132] If no mutation is detected in BRAF, ipilimumab might be a treatment option[133] (for details see chapter 'Treatment of Brain metastases').

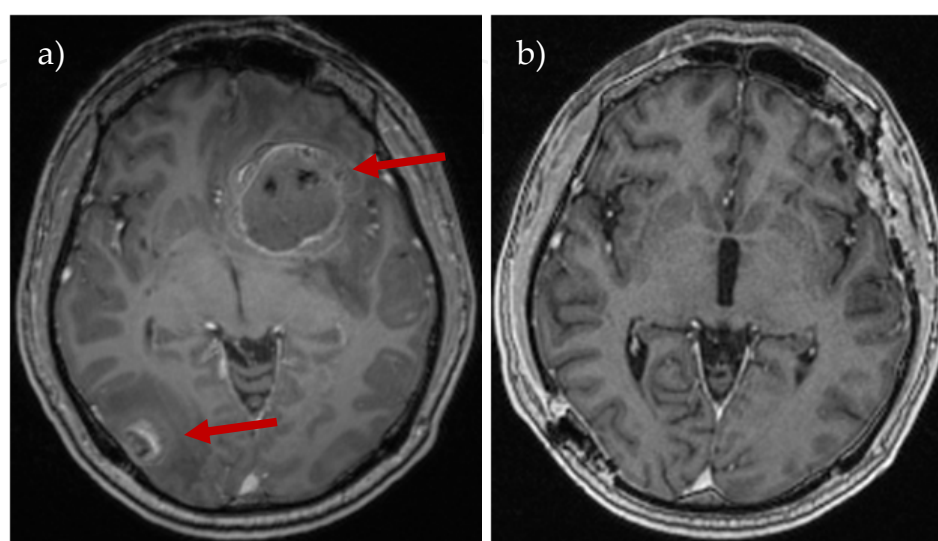


Figure 16. Pre-operative CT scan with multiple melanoma metastases. Brain metastases are indicated with red arrows (a). Post surgical CT scan (b).

4.5. Bone metastases (Stage IV M1c)

Skeletal metastases are present in 5-17% of stage IV patients and have a poor prognosis. [134] Colman et al conducted the largest retrospective analysis of melanoma patients with bone metastases.[135] The study compared the survival rate of the group of patients who underwent surgery with wide resection of metastases with the group who received other surgery or were treated without operation. The observed 1-year overall survival rate in the resection group was twice as high as that of matched historical controls (50.0 vs. 24.8%). They found that overall survival may be improved in carefully selected patients where all known macroscopic tumor can be resected.[134-137]

Author details

Rolland Gyulai*, Zsolt Kádár and Zsuzsanna Lengyel

*Address all correspondence to: gyulai.rolland@pte.hu

Department of Dermatology, Venerology and Oncodermatology, University of Pécs, Pécs, Hungary

References

- [1] Coit DG, Thompson JA, Andtbacka R, Anker CJ, Bichakjian CK, Carson WE, 3rd, et al. Melanoma, version 4.2014. *J Natl Compr Canc Netw* 2014 May;12(5):621-629.
- [2] Bishop JA, Corrie PG, Evans J, Gore ME, Hall PN, Kirkham N, et al. UK guidelines for the management of cutaneous melanoma. *Br J Plast Surg* 2002 Jan;55(1):46-54.
- [3] Molenkamp BG, Sluijter BJ, Oosterhof B, Meijer S, van Leeuwen PA. Non-radical diagnostic biopsies do not negatively influence melanoma patient survival. *Ann Surg Oncol* 2007 Apr;14(4):1424-1430.
- [4] Hieken TJ, Hernandez-Irizarry R, Boll JM, Jones Coleman JE. Accuracy of diagnostic biopsy for cutaneous melanoma: implications for surgical oncologists. *Int J Surg Oncol* 2013;2013:196493.
- [5] Yamashita Y, Hashimoto I, Abe Y, Seike T, Okawa K, Senzaki Y, et al. Effect of biopsy technique on the survival rate of malignant melanoma patients. *Arch Plast Surg* 2014 Mar;41(2):122-125.
- [6] Austin JR, Byers RM, Brown WD, Wolf P. Influence of biopsy on the prognosis of cutaneous melanoma of the head and neck. *Head Neck* 1996 Mar-Apr;18(2):107-117.
- [7] Rampen FH, van Houten WA, Jop WC. Incisional procedures and prognosis in malignant melanoma. *Clin Exp Dermatol* 1980 Sep;5(3):313-320.
- [8] English DR, Del Mar C, Burton RC. Factors influencing the number needed to excise: excision rates of pigmented lesions by general practitioners. *Med J Aust* 2004 Jan 5;180(1):16-19.
- [9] Santillan AA, Messina JL, Marzban SS, Crespo G, Sondak VK, Zager JS. Pathology review of thin melanoma and melanoma in situ in a multidisciplinary melanoma clinic: impact on treatment decisions. *J Clin Oncol* 2010 Jan 20;28(3):481-486.
- [10] Macy-Roberts E, Ackerman AB. A critique of techniques for biopsy of clinically suspected malignant melanomas. *Am J Dermatopathol* 1982 Oct;4(5):391-398.
- [11] Stell VH, Norton HJ, Smith KS, Salo JC, White RL, Jr. Method of biopsy and incidence of positive margins in primary melanoma. *Ann Surg Oncol* 2007 Feb;14(2):893-898.
- [12] Martin RC, 2nd, Scoggins CR, Ross MI, Reintgen DS, Noyes RD, Edwards MJ, et al. Is incisional biopsy of melanoma harmful? *Am J Surg* 2005 Dec;190(6):913-917.
- [13] Bong JL, Herd RM, Hunter JA. Incisional biopsy and melanoma prognosis. *J Am Acad Dermatol* 2002 May;46(5):690-694.
- [14] Veronesi U, Cascinelli N, Adamus J, Balch C, Bandiera D, Barchuk A, et al. Thin stage I primary cutaneous malignant melanoma. Comparison of excision with margins of 1 or 3 cm. *N Engl J Med* 1988 May 5;318(18):1159-1162.

- [15] Balch CM, Soong SJ, Smith T, Ross MI, Urist MM, Karakousis CP, et al. Long-term results of a prospective surgical trial comparing 2 cm vs. 4 cm excision margins for 740 patients with 1-4 mm melanomas. *Ann Surg Oncol* 2001 Mar;8(2):101-108.
- [16] Cohn-Cedermark G, Rutqvist LE, Andersson R, Breivald M, Ingvar C, Johansson H, et al. Long term results of a randomized study by the Swedish Melanoma Study Group on 2-cm versus 5-cm resection margins for patients with cutaneous melanoma with a tumor thickness of 0.8-2.0 mm. *Cancer* 2000 Oct 1;89(7):1495-1501.
- [17] Khayat D, Rixe O, Martin G, Soubrane C, Banzet M, Bazex JA, et al. Surgical margins in cutaneous melanoma (2 cm versus 5 cm for lesions measuring less than 2.1-mm thick). *Cancer* 2003 Apr 15;97(8):1941-1946.
- [18] Thomas JM, Newton-Bishop J, A'Hern R, Coombes G, Timmons M, Evans J, et al. Excision margins in high-risk malignant melanoma. *N Engl J Med* 2004 Feb 19;350(8):757-766.
- [19] Gillgren P, Drzewiecki KT, Niin M, Gullestad HP, Hellborg H, Mansson-Brahme E, et al. 2-Cm Versus 4-Cm Surgical Excision Margins for Primary Cutaneous Melanoma Thicker than 2 Mm: a Randomised, Multicentre Trial. *Lancet* 2011 Nov 5;378(9803):1635-1642.
- [20] Haigh PI, DiFronzo LA, McCready DR. Optimal excision margins for primary cutaneous melanoma: a systematic review and meta-analysis. *Can J Surg* 2003 Dec;46(6):419-426.
- [21] Kunishige JH, Brodland DG, Zitelli JA. Surgical margins for melanoma in situ. *J Am Acad Dermatol* 2012 Mar;66(3):438-444.
- [22] Akhtar S, Bhat W, Magdum A, Stanley PR. Surgical excision margins for melanoma in situ. *J Plast Reconstr Aesthet Surg* 2014 Mar;67(3):320-323.
- [23] Harish V, Bond JS, Scolyer RA, Haydu LE, Saw RP, Quinn MJ, et al. Margins of excision and prognostic factors for cutaneous eyelid melanomas. *J Plast Reconstr Aesthet Surg* 2013 Aug;66(8):1066-1073.
- [24] Jones TS, Jones EL, Gao D, Pearlman NW, Robinson WA, McCarter M. Management of external ear melanoma: the same or something different? *Am J Surg* 2013 Sep;206(3):307-313.
- [25] Patel SG, Prasad ML, Escrig M, Singh B, Shaha AR, Kraus DH, et al. Primary mucosal malignant melanoma of the head and neck. *Head Neck* 2002 Mar;24(3):247-257.
- [26] Prasad ML, Patel SG, Huvos AG, Shah JP, Busam KJ. Primary mucosal melanoma of the head and neck: a proposal for microstaging localized, Stage I (lymph node-negative) tumors. *Cancer* 2004 Apr 15;100(8):1657-1664.
- [27] Rogo KO, Andersson R, Edbom G, Stendahl U. Conservative surgery for vulvovaginal melanoma. *Eur J Gynaecol Oncol* 1991;12(2):113-119.

- [28] Ragnarsson-Olding BK, Nilsson BR, Kanter-Lewensohn LR, Lagerlof B, Ringborg UK. Malignant melanoma of the vulva in a nationwide, 25-year study of 219 Swedish females: predictors of survival. *Cancer* 1999 Oct 1;86(7):1285-1293.
- [29] Sanchez-Ortiz R, Huang SF, Tamboli P, Prieto VG, Hester G, Pettaway CA. Melanoma of the penis, scrotum and male urethra: a 40-year single institution experience. *J Urol* 2005 Jun;173(6):1958-1965.
- [30] Ballo MT, Gershenwald JE, Zagars GK, Lee JE, Mansfield PF, Strom EA, et al. Sphincter-sparing local excision and adjuvant radiation for anal-rectal melanoma. *J Clin Oncol* 2002 Dec 1;20(23):4555-4558.
- [31] Mathijssen IM, van der Meulen JC. Guidelines for reconstruction of the eyelids and canthal regions. *J Plast Reconstr Aesthet Surg* 2010 Sep;63(9):1420-1433.
- [32] Yin VT, Warneke CL, Merritt HA, Esmaeli B. Number of excisions required to obtain clear surgical margins and prognostic value of AJCC T category for patients with eyelid melanoma. *Br J Ophthalmol* 2014 Jul 22.
- [33] Harvey DT, Taylor RS, Itani KM, Loewinger RJ. Mohs micrographic surgery of the eyelid: an overview of anatomy, pathophysiology, and reconstruction options. *Dermatol Surg* 2013 May;39(5):673-697.
- [34] Thornton JF, Griffin JR, Constantine FC. Nasal reconstruction: an overview and nuances. *Semin Plast Surg* 2008 Nov;22(4):257-268.
- [35] Park SS. Nasal reconstruction in the 21st century--a contemporary review. *Clin Exp Otorhinolaryngol* 2008 Mar;1(1):1-9.
- [36] Reddy LV, Zide MF. Reconstruction of skin cancer defects of the auricle. *J Oral Maxillofac Surg* 2004 Dec;62(12):1457-1471.
- [37] Olbright S, Liegeois NJ. Closing surgical defects of the external ear. *Semin Cutan Med Surg* 2003 Dec;22(4):273-280.
- [38] Yun MJ, Park JU, Kwon ST. Surgical options for malignant skin tumors of the hand. *Arch Plast Surg* 2013 May;40(3):238-243.
- [39] Weide B, Faller C, Buttner P, Pflugfelder A, Leiter U, Eigentler TK, et al. Prognostic factors of melanoma patients with satellite or in-transit metastasis at the time of stage III diagnosis. *PLoS One* 2013 Apr 29;8(4):e63137.
- [40] Balch CM, Gershenwald JE, Soong SJ, Thompson JF, Atkins MB, Byrd DR, et al. Final version of 2009 AJCC melanoma staging and classification. *J Clin Oncol* 2009 Dec 20;27(36):6199-6206.
- [41] Yao KA, Hsueh EC, Essner R, Foshag LJ, Wanek LA, Morton DL. Is sentinel lymph node mapping indicated for isolated local and in-transit recurrent melanoma? *Ann Surg* 2003 Nov;238(5):743-747.

- [42] Gipponi M, Solari N, Giovinazzo D, Queirolo P, Bertoglio S, Villa G, et al. The role of sentinel lymph node biopsy in patients with local recurrence or in-transit metastasis of melanoma. *Anticancer Res* 2014 Jun;34(6):3197-3203.
- [43] Beasley GM, Tyler DS. Treatment of in-transit melanoma: an opportunity to discover critical knowledge. *Oncology (Williston Park)* 2011 Dec;25(14):1351-2, 1355.
- [44] Squires MH, 3rd, Delman KA. Current treatment of locoregional recurrence of melanoma. *Curr Oncol Rep* 2013 Oct;15(5):465-472.
- [45] Turley RS, Raymond AK, Tyler DS. Regional treatment strategies for in-transit melanoma metastasis. *Surg Oncol Clin N Am* 2011 Jan;20(1):79-103.
- [46] Deroose JP, Grunhagen DJ, van Geel AN, de Wilt JH, Eggermont AM, Verhoef C. Long-term outcome of isolated limb perfusion with tumour necrosis factor-alpha for patients with melanoma in-transit metastases. *Br J Surg* 2011 Nov;98(11):1573-1580.
- [47] Moreno-Ramirez D, de la Cruz-Merino L, Ferrandiz L, Villegas-Portero R, Nieto-Garcia A. Isolated limb perfusion for malignant melanoma: systematic review on effectiveness and safety. *Oncologist* 2010;15(4):416-427.
- [48] Stevens G, Thompson JF, Firth I, O'Brien CJ, McCarthy WH, Quinn MJ. Locally advanced melanoma: results of postoperative hypofractionated radiation therapy. *Cancer* 2000 Jan 1;88(1):88-94.
- [49] Damian DL, Thompson JF. Treatment of extensive cutaneous metastatic melanoma with topical diphencyprone. *J Am Acad Dermatol* 2007 May;56(5):869-871.
- [50] Berman B, Poochareon VN, Villa AM. Novel dermatologic uses of the immune response modifier imiquimod 5% cream. *Skin Therapy Lett* 2002 Nov;7(9):1-6.
- [51] Gibson SC, Byrne DS, McKay AJ. Ten-year experience of carbon dioxide laser ablation as treatment for cutaneous recurrence of malignant melanoma. *Br J Surg* 2004 Jul;91(7):893-895.
- [52] Testori A, Intelisano A, Verrecchia F, Menicanti C, Tosti G, Grassi E, et al. Alternatives for the treatment of local advanced disease: electrochemotherapy, limb perfusion, limb infusion, intralesional IL2. What is the role? *Dermatol Ther* 2012 Sep-Oct;25(5):443-451.
- [53] Byrne CM, Thompson JF, Johnston H, Hersey P, Quinn MJ, Michael Hughes T, et al. Treatment of metastatic melanoma using electroporation therapy with bleomycin (electrochemotherapy). *Melanoma Res* 2005 Feb;15(1):45-51.
- [54] Young SE, Martinez SR, Faries MB, Essner R, Wanek LA, Morton DL. Can surgical therapy alone achieve long-term cure of melanoma metastatic to regional nodes? *Cancer J* 2006 May-Jun;12(3):207-211.

- [55] Manola J, Atkins M, Ibrahim J, Kirkwood J. Prognostic factors in metastatic melanoma: a pooled analysis of Eastern Cooperative Oncology Group trials. *J Clin Oncol* 2000 Nov 15;18(22):3782-3793.
- [56] Hodi FS, O'Day SJ, McDermott DF, Weber RW, Sosman JA, Haanen JB, et al. Improved survival with ipilimumab in patients with metastatic melanoma. *N Engl J Med* 2010 Aug 19;363(8):711-723.
- [57] Chapman PB, Hauschild A, Robert C, Haanen JB, Ascierto P, Larkin J, et al. Improved survival with vemurafenib in melanoma with BRAF V600E mutation. *N Engl J Med* 2011 Jun 30;364(26):2507-2516.
- [58] Hauschild A, Grob JJ, Demidov LV, Jouary T, Gutzmer R, Millward M, et al. Dabrafenib in BRAF-mutated metastatic melanoma: a multicentre, open-label, phase 3 randomised controlled trial. *Lancet* 2012 Jul 28;380(9839):358-365.
- [59] Kim KB, Kefford R, Pavlick AC, Infante JR, Ribas A, Sosman JA, et al. Phase II study of the MEK1/MEK2 inhibitor Trametinib in patients with metastatic BRAF-mutant cutaneous melanoma previously treated with or without a BRAF inhibitor. *J Clin Oncol* 2013 Feb 1;31(4):482-489.
- [60] Martinez SR, Young SE. A rational surgical approach to the treatment of distant melanoma metastases. *Cancer Treat Rev* 2008 Nov;34(7):614-620.
- [61] Ollila DW. Complete metastasectomy in patients with stage IV metastatic melanoma. *Lancet Oncol* 2006 Nov;7(11):919-924.
- [62] Wood TF, DiFronzo LA, Rose DM, Haigh PI, Stern SL, Wanek L, et al. Does complete resection of melanoma metastatic to solid intra-abdominal organs improve survival? *Ann Surg Oncol* 2001 Sep;8(8):658-662.
- [63] Bajetta E, Del Vecchio M, Bernard-Marty C, Vitali M, Buzzoni R, Rixe O, et al. Metastatic melanoma: chemotherapy. *Semin Oncol* 2002 Oct;29(5):427-445.
- [64] Young SE, Martinez SR, Essner R. The role of surgery in treatment of stage IV melanoma. *J Surg Oncol* 2006 Sep 15;94(4):344-351.
- [65] Sosman JA, Moon J, Tuthill RJ, Warneke JA, Vetto JT, Redman BG, et al. A phase 2 trial of complete resection for stage IV melanoma: results of Southwest Oncology Group Clinical Trial S9430. *Cancer* 2011 Oct 15;117(20):4740-4706.
- [66] Morton D, Mozzillo N, Thompson J, Kelley M, Faries M, Wagner J, et al. MMAIT Clinical Trials Group. An international, randomized, phase III trial of bacillus Calmette-Guerin (BCG) plus allogeneic melanoma vaccine (MCV) or placebo after complete resection of melanoma metastatic to regional or distant sites. *Journal of Clinical Oncology* 2007;25(Suppl: 8508).
- [67] Howard JH, Thompson JF, Mozzillo N, Nieweg OE, Hoekstra HJ, Roses DF, et al. Metastasectomy for distant metastatic melanoma: analysis of data from the first Mul-

ticenter Selective Lymphadenectomy Trial (MSLT-I). *Ann Surg Oncol* 2012 Aug;19(8):2547-2555.

- [68] Koyanagi K, Kuo C, Nakagawa T, Mori T, Ueno H, Lorico AR, Jr, et al. Multimarker quantitative real-time PCR detection of circulating melanoma cells in peripheral blood: relation to disease stage in melanoma patients. *Clin Chem* 2005 Jun;51(6):981-988.
- [69] Koyanagi K, Mori T, O'Day SJ, Martinez SR, Wang HJ, Hoon DS. Association of circulating tumor cells with serum tumor-related methylated DNA in peripheral blood of melanoma patients. *Cancer Res* 2006 Jun 15;66(12):6111-6117.
- [70] Roth JA, Silverstein MJ, Morton DL. Metastatic potential of metastases. *Surgery* 1976 Jun;79(6):669-673.
- [71] Leung AM, Hari DM, Morton DL. Surgery for distant melanoma metastasis. *Cancer J* 2012 Mar-Apr;18(2):176-184.
- [72] Morton DL, Ollila DW, Hsueh EC, Essner R, Gupta RK. Cytoreductive surgery and adjuvant immunotherapy: a new management paradigm for metastatic melanoma. *CA Cancer J Clin* 1999 Mar-Apr;49(2):101-16, 65.
- [73] Meyer T, Merkel S, Goehl J, Hohenberger W. Surgical therapy for distant metastases of malignant melanoma. *Cancer* 2000 Nov 1;89(9):1983-1991.
- [74] Wevers KP, Hoekstra HJ. Stage IV melanoma: completely resectable patients are scarce. *Ann Surg Oncol* 2013 Jul;20(7):2352-2356.
- [75] de Ridder J, van Walsum M, Verhoef C, Nagtegaal I, de Wilt J, Dutch Liver Working Group. Hepatic resection for metastatic melanoma in The Netherlands: survival and prognostic factors. *Melanoma Res* 2013 Feb;23(1):27-32.
- [76] Frenkel S, Nir I, Hendler K, Lotem M, Eid A, Jurim O, et al. Long-term survival of uveal melanoma patients after surgery for liver metastases. *Br J Ophthalmol* 2009 Aug;93(8):1042-1046.
- [77] Mariani P, Piperno-Neumann S, Servois V, Berry MG, Dorval T, Plancher C, et al. Surgical management of liver metastases from uveal melanoma: 16 years' experience at the Institut Curie. *Eur J Surg Oncol* 2009 Nov;35(11):1192-1197.
- [78] Rose DM, Essner R, Hughes TM, Tang PC, Bilchik A, Wanek LA, et al. Surgical resection for metastatic melanoma to the liver: the John Wayne Cancer Institute and Sydney Melanoma Unit experience. *Arch Surg* 2001 Aug;136(8):950-955.
- [79] Tafra L, Dale PS, Wanek LA, Ramming KP, Morton DL. Resection and adjuvant immunotherapy for melanoma metastatic to the lung and thorax. *J Thorac Cardiovasc Surg* 1995 Jul;110(1):119-28; discussion 129.
- [80] Ollila DW, Stern SL, Morton DL. Tumor doubling time: a selection factor for pulmonary resection of metastatic melanoma. *J Surg Oncol* 1998 Dec;69(4):206-211.

- [81] Ollila DW, Hsueh EC, Stern SL, Morton DL. Metastasectomy for recurrent stage IV melanoma. *J Surg Oncol* 1999 Aug;71(4):209-213.
- [82] Faries MB, Morton DL. Melanoma: is immunotherapy of benefit? *Adv Surg* 2003;37:139-169.
- [83] Pflugfelder A, Kochs C, Blum A, Capellaro M, Czeschik C, Dettenborn T, et al. Malignant melanoma S3-guideline "diagnosis, therapy and follow-up of melanoma". *J Dtsch Dermatol Ges* 2013 Aug;11 Suppl 6:1-116, 1-126.
- [84] Koers K, Francken AB, Haanen JB, Woerdeman LA, van der Hage JA. Vemurafenib as neoadjuvant treatment for unresectable regional metastatic melanoma. *J Clin Oncol* 2013 Jun 1;31(16):e251-3.
- [85] Fadaki N, Cardona-Huerta S, Martineau L, Thummala S, Cheng ST, Bunker SR, et al. Inoperable bulky melanoma responds to neoadjuvant therapy with vemurafenib. *BMJ Case Rep* 2012 Oct 22;2012:10.1136/bcr-2012-007034.
- [86] La Greca M, Grasso G, Antonelli G, Russo AE, Bartolotta S, D'Angelo A, et al. Neoadjuvant therapy for locally advanced melanoma: new strategies with targeted therapies. *Onco Targets Ther* 2014 Jun 19;7:1115-1121.
- [87] Robert C, Ribas A, Wolchok JD, Hodi FS, Hamid O, Kefford R, et al. Anti-programmed-death-receptor-1 treatment with pembrolizumab in ipilimumab-refractory advanced melanoma: a randomised dose-comparison cohort of a phase 1 trial. *Lancet* 2014 Sep 20;384(9948):1109-1117.
- [88] Wong JH, Skinner KA, Kim KA, Foshag LJ, Morton DL. The role of surgery in the treatment of nonregionally recurrent melanoma. *Surgery* 1993 Apr;113(4):389-394.
- [89] Chua TC, Scolyer RA, Kennedy CW, Yan TD, McCaughan BC, Thompson JF. Surgical management of melanoma lung metastasis: an analysis of survival outcomes in 292 consecutive patients. *Ann Surg Oncol* 2012 Jun;19(6):1774-1781.
- [90] Petersen RP, Hanish SI, Haney JC, Miller CC, 3rd, Burfeind WR, Jr, Tyler DS, et al. Improved survival with pulmonary metastasectomy: an analysis of 1720 patients with pulmonary metastatic melanoma. *J Thorac Cardiovasc Surg* 2007 Jan;133(1):104-110.
- [91] Andrews S, Robinson L, Cantor A, DeConti RC. Survival after surgical resection of isolated pulmonary metastases from malignant melanoma. *Cancer Control* 2006 Jul;13(3):218-223.
- [92] Schuhan C, Muley T, Dienemann H, Pfannschmidt J. Survival after pulmonary metastasectomy in patients with malignant melanoma. *Thorac Cardiovasc Surg* 2011 Apr;59(3):158-162.
- [93] Leo F, Cagini L, Rocmans P, Cappello M, Geel AN, Maggi G, et al. Lung metastases from melanoma: when is surgical treatment warranted? *Br J Cancer* 2000 Sep;83(5):569-572.

- [94] Neuman HB, Patel A, Hanlon C, Wolchok JD, Houghton AN, Coit DG. Stage-IV melanoma and pulmonary metastases: factors predictive of survival. *Ann Surg Oncol* 2007 Oct;14(10):2847-2853.
- [95] Harpole DH, Jr, Johnson CM, Wolfe WG, George SL, Seigler HF. Analysis of 945 cases of pulmonary metastatic melanoma. *J Thorac Cardiovasc Surg* 1992 Apr;103(4):743-8; discussion 748-50.
- [96] Younes R, Abrao FC, Gross J. Pulmonary metastasectomy for malignant melanoma: prognostic factors for long-term survival. *Melanoma Res* 2013 Aug;23(4):307-311.
- [97] Pfannschmidt J, Klode J, Muley T, Dienemann H, Hoffmann H. Nodal involvement at the time of pulmonary metastasectomy: experiences in 245 patients. *Ann Thorac Surg* 2006 Feb;81(2):448-454.
- [98] Mifsud M, Padhya TA. Metastatic melanoma to the upper aerodigestive tract: a systematic review of the literature. *Laryngoscope* 2014 May;124(5):1143-1149.
- [99] Koyi H, Branden E. Intratracheal metastasis from malignant melanoma. *J Eur Acad Dermatol Venereol* 2000 Sep;14(5):407-408.
- [100] Diener-West M, Reynolds SM, Agugliaro DJ, Caldwell R, Cumming K, Earle JD, et al. Development of metastatic disease after enrollment in the COMS trials for treatment of choroidal melanoma: Collaborative Ocular Melanoma Study Group Report No. 26. *Arch Ophthalmol* 2005 Dec;123(12):1639-1643.
- [101] Kivela T, Eskelin S, Kujala E. Metastatic uveal melanoma. *Int Ophthalmol Clin* 2006 Winter;46(1):133-149.
- [102] Leiter U, Meier F, Schitteck B, Garbe C. The natural course of cutaneous melanoma. *J Surg Oncol* 2004 Jul 1;86(4):172-178.
- [103] Mourra N, Jouret-Mourin A, Lazure T, Audard V, Albiges L, Malbois M, et al. Metastatic tumors to the colon and rectum: a multi-institutional study. *Arch Pathol Lab Med* 2012 Nov;136(11):1397-1401.
- [104] Aoyama T, Mastrangelo MJ, Berd D, Nathan FE, Shields CL, Shields JA, et al. Protracted survival after resection of metastatic uveal melanoma. *Cancer* 2000 Oct 1;89(7):1561-1568.
- [105] Marshall E, Romaniuk C, Ghaneh P, Wong H, McKay M, Chopra M, et al. MRI in the detection of hepatic metastases from high-risk uveal melanoma: a prospective study in 188 patients. *Br J Ophthalmol* 2013 Feb;97(2):159-163.
- [106] Rivoire M, Kodjikian L, Baldo S, Kaemmerlen P, Negrier S, Grange JD. Treatment of liver metastases from uveal melanoma. *Ann Surg Oncol* 2005 Jun;12(6):422-428.
- [107] Faries MB, Leung A, Morton DL, Hari D, Lee JH, Sim MS, et al. A 20-year experience of hepatic resection for melanoma: is there an expanding role? *J Am Coll Surg* 2014 Jul;219(1):62-68.

- [108] Piperno-Neumann S, Chaaba H, Plancher C, Mariani P, Couturier J, Sastre-Garau X, et al. Retrospective analysis of 470 metastatic uveal melanoma (MUM) patients managed at Institut Curie between 2000 and 2008.. *Ann Oncol* 2010;21(8):(suppl 8: viii401):Abstract 3777.
- [109] Aubin JM, Rekman J, Vandenbroucke-Menu F, Lapointe R, Fairfull-Smith RJ, Mimeault R, et al. Systematic review and meta-analysis of liver resection for metastatic melanoma. *Br J Surg* 2013 Aug;100(9):1138-1147.
- [110] Adam R, Chiche L, Aloia T, Elias D, Salmon R, Rivoire M, et al. Hepatic resection for noncolorectal nonendocrine liver metastases: analysis of 1,452 patients and development of a prognostic model. *Ann Surg* 2006 Oct;244(4):524-535.
- [111] Groeschl RT, Nachmany I, Steel JL, Reddy SK, Glazer ES, de Jong MC, et al. Hepatectomy for noncolorectal non-neuroendocrine metastatic cancer: a multi-institutional analysis. *J Am Coll Surg* 2012 May;214(5):769-777.
- [112] Ripley RT, Davis JL, Klapper JA, Mathur A, Kammula U, Royal RE, et al. Liver resection for metastatic melanoma with postoperative tumor-infiltrating lymphocyte therapy. *Ann Surg Oncol* 2010 Jan;17(1):163-170.
- [113] Ryu SW, Saw R, Scolyer RA, Crawford M, Thompson JF, Sandroussi C. Liver resection for metastatic melanoma: equivalent survival for cutaneous and ocular primaries. *J Surg Oncol* 2013 Aug;108(2):129-135.
- [114] Pawlik TM, Zorzi D, Abdalla EK, Clary BM, Gershenwald JE, Ross MI, et al. Hepatic resection for metastatic melanoma: distinct patterns of recurrence and prognosis for ocular versus cutaneous disease. *Ann Surg Oncol* 2006 May;13(5):712-720.
- [115] Chua TC, Saxena A, Morris DL. Surgical metastasectomy in AJCC stage IV M1c melanoma patients with gastrointestinal and liver metastases. *Ann Acad Med Singapore* 2010 Aug;39(8):634-639.
- [116] Kodjikian L, Grange JD, Baldo S, Baillif S, Garweg JG, Rivoire M. Prognostic factors of liver metastases from uveal melanoma. *Graefes Arch Clin Exp Ophthalmol* 2005 Oct;43(10):985-993.
- [117] Caralt M, Marti J, Cortes J, Fondevila C, Bilbao I, Fuster J, et al. Outcome of patients following hepatic resection for metastatic cutaneous and ocular melanoma. *J Hepatobiliary Pancreat Sci* 2011 Mar;18(2):268-275.
- [118] Herman P, Machado MA, Montagnini AL, D'Albuquerque LA, Saad WA, Machado MC. Selected patients with metastatic melanoma may benefit from liver resection. *World J Surg* 2007 Jan;31(1):171-174.
- [119] Kim J, Mori T, Chen SL, Amersi FF, Martinez SR, Kuo C, et al. Chemokine receptor CXCR4 expression in patients with melanoma and colorectal cancer liver metastases and the association with disease outcome. *Ann Surg* 2006 Jul;244(1):113-120.

- [120] Wysocki WM, Komorowski AL, Darasz Z. Gastrointestinal metastases from malignant melanoma: report of a case. *Surg Today* 2004;34(6):542-546.
- [121] Ollila DW, Essner R, Wanek LA, Morton DL. Surgical resection for melanoma metastatic to the gastrointestinal tract. *Arch Surg* 1996 Sep;131(9):975-9; 979-80.
- [122] Tsilimparis N, Menenakos C, Rogalla P, Braumann C, Hartmann J. Malignant melanoma metastasis as a cause of small-bowel perforation. *Onkologie* 2009 Jun;32(6):356-358.
- [123] Patti R, Cacciatori M, Guercio G, Territo V, Di Vita G. Intestinal melanoma: A broad spectrum of clinical presentation. *Int J Surg Case Rep* 2012;3(8):395-398.
- [124] Branum GD, Seigler HF. Role of surgical intervention in the management of intestinal metastases from malignant melanoma. *Am J Surg* 1991 Nov;162(5):428-431.
- [125] Patel K, Ward ST, Packer T, Brown S, Marsden J, Thomson M, et al. Malignant melanoma of the gastro-intestinal tract: a case series. *Int J Surg* 2014;12(5):523-527.
- [126] Reddy S, Edil BH, Cameron JL, Pawlik TM, Herman JM, Gilson MM, et al. Pancreatic resection of isolated metastases from nonpancreatic primary cancers. *Ann Surg Oncol* 2008 Nov;15(11):3199-3206.
- [127] Branum GD, Epstein RE, Leight GS, Seigler HF. The role of resection in the management of melanoma metastatic to the adrenal gland. *Surgery* 1991 Feb;109(2):127-131.
- [128] Sampson JH, Carter JH, Jr, Friedman AH, Seigler HF. Demographics, prognosis, and therapy in 702 patients with brain metastases from malignant melanoma. *J Neurosurg* 1998 Jan;88(1):11-20.
- [129] Fife KM, Colman MH, Stevens GN, Firth IC, Moon D, Shannon KF, et al. Determinants of outcome in melanoma patients with cerebral metastases. *J Clin Oncol* 2004 Apr 1;22(7):1293-1300.
- [130] Aoyama H, Shirato H, Tago M, Nakagawa K, Toyoda T, Hatano K, et al. Stereotactic radiosurgery plus whole-brain radiation therapy vs stereotactic radiosurgery alone for treatment of brain metastases: a randomized controlled trial. *JAMA* 2006 Jun 7;295(21):2483-2491.
- [131] Skibber JM, Soong SJ, Austin L, Balch CM, Sawaya RE. Cranial irradiation after surgical excision of brain metastases in melanoma patients. *Ann Surg Oncol* 1996 Mar;3(2):118-123.
- [132] Falchook GS, Long GV, Kurzrock R, Kim KB, Arkenau TH, Brown MP, et al. Dabrafenib in patients with melanoma, untreated brain metastases, and other solid tumours: a phase 1 dose-escalation trial. *Lancet* 2012 May 19;379(9829):1893-1901.
- [133] Margolin K, Ernstoff MS, Hamid O, Lawrence D, McDermott D, Puzanov I, et al. Ipilimumab in patients with melanoma and brain metastases: an open-label, phase 2 trial. *Lancet Oncol* 2012 May;13(5):459-465.

- [134] Huang KY, Wang CR, Yang RS. Rare clinical experiences for surgical treatment of melanoma with osseous metastases in Taiwan. *BMC Musculoskelet Disord* 2007 Jul 25;8:70.
- [135] Colman MW, Kirkwood JM, Schott T, Goodman MA, McGough RL,3rd. Does metastasectomy improve survival in skeletal melanoma? *Melanoma Res* 2014 Aug;24(4): 354-359.
- [136] Stewart WR, Gelberman RH, Harrelson JM, Seigler HF. Skeletal metastases of melanoma. *J Bone Joint Surg Am* 1978 Jul;60(5):645-649.
- [137] Donaldson WF,3rd, Peppelman WC,Jr, Yaw KM. Symptomatic metastatic malignant melanoma to the spine. *J Spinal Disord* 1993 Aug;6(4):360-363.