

# We are IntechOpen, the world's leading publisher of Open Access books Built by scientists, for scientists

6,900

Open access books available

186,000

International authors and editors

200M

Downloads

Our authors are among the

154

Countries delivered to

TOP 1%

most cited scientists

12.2%

Contributors from top 500 universities



WEB OF SCIENCE™

Selection of our books indexed in the Book Citation Index  
in Web of Science™ Core Collection (BKCI)

Interested in publishing with us?  
Contact [book.department@intechopen.com](mailto:book.department@intechopen.com)

Numbers displayed above are based on latest data collected.  
For more information visit [www.intechopen.com](http://www.intechopen.com)



---

# **Minimally Invasive Implant Treatment Alternatives for the Edentulous Patient — Fast & Fixed and Implant Overdentures**

---

Elena Preoteasa, Laurentiu Iulian Florica,  
Florian Obadan, Marina Imre and  
Cristina Teodora Preoteasa

Additional information is available at the end of the chapter

<http://dx.doi.org/10.5772/59369>

---

## **1. Introduction**

Edentulism, defined as the loss of all natural teeth, is a severe chronic irreversible medical condition that associates extensive oral changes and has a negative impact on general health, psychological comfort, social functioning and on the overall quality of life. Despite the efforts made, edentulism still has a high prevalence, about 7 to 69% in the adult population worldwide, projections displaying a high rate of occurrence in the next decades, especially in the elderly population [1,2].

The most common treatment option for complete edentulism is still the conventional complete denture, an alternative which rather often does not fulfill patients' needs and is regarded as having multiple shortcomings, mainly in relation to its instability. The use of implant prostheses, fixed or removable, provides a better treatment outcome, with a significant improvement of oral function and quality of life [3].

Implant prosthesis in edentulous patients, despite their increasing use, still register low prevalence, which is most probably linked to oral, systemic and social factors. Frequently, the edentulous patients are elderly and face barriers to treatment access (e.g., limited financial means, transportation difficulties, communication problems linked to loss of hearing or visual acuity) [4,5]. They show less willingness to accept complex treatment options, with major surgical interventions, such as bone grafting, or sometimes even implant placement. Often elderly have systemic comorbidities that are sometimes risk factors for developing complica-

tions. Considering the previous, simpler treatments with high predictability and easy maintenance procedures are preferred.

Despite these factors that limit usage of implant prosthetic rehabilitations in edentulous patients, due to their better treatment outcome compared to conventional dentures or root overdentures, in the future most likely they will be standard treatment options widely used. Supporting the previous, McGill consensus states that two-implant overdenture is the minimum standard of care for mandibular edentulism, taking into account performance, patient satisfaction, cost and clinical time [6]. Implant use for prosthetic rehabilitation will probably increase over time in relation to the advancement of research and technology in the dental field, combined with decrease of the implant treatment costs and increase of the acceptance for this treatment option by the general public.

Out of the variety of implant prosthetic options that can be used, the minimally invasive implant treatment alternatives may be more appropriate for the aged edentulous patients, considering their oral and systemic status, needs, expectations and barriers [7-9]. Usage of fewer and less invasive surgical procedures (e.g., avoiding bone grafting; using flapless technique for implant placement; using a reduced number of implants) is beneficial due to a shorter healing period and a decreased patient discomfort, represented by either pain or stress [10]. Additionally, the possibility of immediate implant loading with the regain of functionality, the decreased clinical time needed for their execution and the relatively moderate treatment burden are all positive aspects that should be considered [11-13].

Subsequently, two minimally invasive implant treatment options for the edentulous patient, one fixed, namely Sky Fast & Fixed (concept derived from All-on-4), and one removable, namely implant overdentures, will be presented. These are perceived as being minimally invasive compared to other implant treatment options, with regards to the limited surgical interventions (they usually don't require bone grafting; a reduced number of implants are placed; when appropriate, flapless technique is used) and reduced clinical time, favoring rapid healing and functionality regaining through immediate implant loading. Both fixed and removable treatment option were chosen considering patient's needs and expectations. Therefore, fixed prosthetic restorations are more appropriate for younger patients, who usually don't easily accept removable prosthesis, and have better dexterity that is needed in order to properly maintain the oral hygiene. The implant overdentures are more appropriate for older edentulous patients, especially for the ones dissatisfied with the conventional dentures, ensuring a satisfying performance and esthetic rehabilitation, requiring simpler procedures for oral hygiene maintenance [14].

## 2. SKY Fast & Fixed — Fixed-prosthetic implant restoration

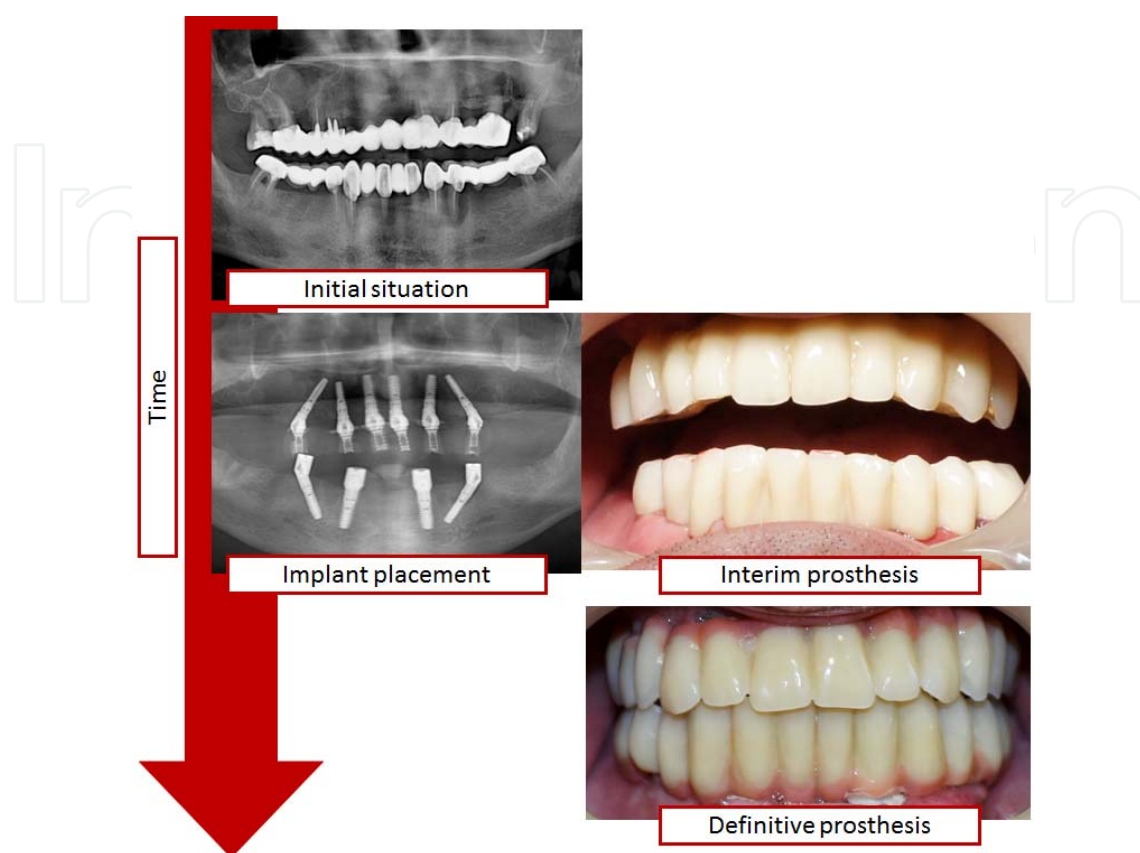
**General presentation.** Sky Fast & Fixed defines an option of immediate fixed-prosthetic implant restoration for complete edentulism, with specific protocol and materials, developed by Bredent Medical (Senden, Germany). Basically, this treatment concept is derived from All-on-4 and All-on-6 concepts, previously developed by Professor Paulo Malo, together with

Nobel Biocare (Göteborg, Sweden) [15-17]. Sky Fast & Fixed differs mainly through the particularities of the system components, such as implant and abutment design.

The main characteristics of Sky Fast & Fixed treatment concept are presented below:

- It is designed for complete edentulism, as current or imminent condition.
- It can be applied in one or both jaws.
- This treatment concept uses 6 implants in the maxilla and 4 implants in the mandible. The distal implants are placed tilted, and the other implants are placed axial. Placement of the distal implants tilted is due to several aspects. It associates a decrease of clinical time and number of appointments, through avoiding extensive bone grafting, frequently needed in the posterior area of the jaws in order to have sufficient bone for implant placement and to avoid maxillary sinus or the inferior alveolar nerve injury. An increase of the prosthesis' implant bearing area occurs-as prosthesis' dental arch length, that reduces the need of using cantilever extremities, and as the occlusal tooth-surface areas that ensures good load distribution to the dental arch. Tilted position of the distal implants associates an increase of the osseointegration surface and using longer implants favors a good primary stability [18,19].
- A rigid fixed provisional prosthesis, without cantilever extensions, is used through immediate implant loading. Therefore, for the dentate patients, edentulism treated by removable prosthesis can be avoided-teeth extraction, implant placement and provisional prosthesis are done during one appointment. The prosthesis is usually designed as a shortened dental arch, comprising the anterior teeth and the premolars.
- A rigid fixed prosthesis that splints the implants, provides cross arch stabilization, designed with or without cantilever extensions, is used for definitive restoration [20]. Usually it is designed as a shortened dental arch, comprising the anterior teeth, the premolars and the first molars.
- Treatment implementation requires a well-trained team, with knowledge of the treatment concept that must include a dentist with clinical experience in prosthodontics and implantology, and a dental technician.
- Sky Fast & Fixed implies the use of some specific materials, components and instruments of Bredent Medical, some of them developed especially for this concept, such as the implants and the abutments. The distal implants that are meant to be placed tilted are designed with length of 14 or 16 mm and diameters over 4 mm. The axial implants should have a length of at least 10 mm and a diameter over 3.5mm. For implant divergence, compensation abutments are designed with angulations of 0°, 17.5° and 35°, and an outer cone of 17.5°. Also, the abutments have an unique platform of 4mm and are designed for variable gingiva heights, from 0.9 mm to 3.6 mm.
- Ensures a simpler and fast oral rehabilitation, with limited surgical procedures performed during one single appointment and with reduced costs, compared to conventional fixed-prosthetic implant restorations.

Time sequence of the main phases of Sky Fast & Fixed can be observed in figure 1.



**Figure 1.** Sky Fast & Fixed – time sequence of the main treatment phases

**Clinical phases.** Sky Fast & Fixed is implemented following the regular steps of fixed-prosthetic implant restorations, with some specific aspects related to this concept and to patient features. Some of the aspects that should be accounted in treatment planning are synthetized in table 1, followed by a more detailed presentation.

**Patient evaluation** should comprise information regarding the oral and systemic health, considering anatomical and functional aspects, in order to accurately collect diagnostic data, essential for treatment planning and execution.

Oral examination must consider, among others, the initial dental condition (as dentulous or edentulous), maxillomandibular relationship, the vertical interarch space (restorative space), bone features (quality, quantity, anatomical limitations) and plaque control. Dentate patients, compared to the edentulous ones, present an increased treatment time, linked to the procedures performed previous to implant placement (teeth extraction, bone leveling, removal of infected tissue), that may have specific complications. Even so, it may be a more favorable clinical situation considering implants associate a reduction of bone resorption, it is possible to register the maxillomandibular relationship and identify some of the patient's natural esthetic particularities. In edentulous patients, severity of bone resorption and its consequen-

|   |  |
|---|--|
| Diagnostic procedures                       | <ul style="list-style-type: none"> <li>• oral and systemic health assessment</li> <li>• facial esthetic evaluation</li> <li>• analyze of radiographs and computed tomography</li> <li>• wax-up</li> <li>• informed consent</li> </ul>  |
| Preoperative interventions and instructions | <ul style="list-style-type: none"> <li>• instruction and motivation on maintaining a proper oral hygiene (antibacterial mouthwash, such as Chlorhexidine 0.12%, is recommended)</li> <li>• record of maxillomandibular relations and occlusion</li> <li>• impression used for fabricating the provisional prosthesis</li> <li>• surgical template (guide)</li> <li>• medication - antibiotics (amoxicillin with clavulanic acid, administered for 5-7 days, starting 1 hour prior to surgical intervention) and sometimes sedatives</li> </ul> |
| Anesthesia                                  | <ul style="list-style-type: none"> <li>• local anesthesia is usually required</li> </ul>   |
| Preprosthetic surgery                       | <ul style="list-style-type: none"> <li>• teeth extraction, bone leveling, removal of infected tissue</li> <li>• alveolectomy, when ridge crest is displayed during smiling</li> <li>• bone grafting procedures</li> </ul>  |
| Implant placement                           | <ul style="list-style-type: none"> <li>• implant number, position and design (diameter, length)</li> <li>• usually, first the mesial implants are placed and last the distal implants</li> <li>• exposure of implant site - flap or flapless technique</li> </ul>  |
| Additional surgical procedures              | <ul style="list-style-type: none"> <li>• bone grafting (socket grafting; with autograft and synthetic alternatives; with or without membrane)</li> <li>• suture</li> </ul>   |
| Interim prosthesis                          | <ul style="list-style-type: none"> <li>• abutments selection (angulation)</li> <li>• impression and record of maxillomandibular relationship</li> <li>• design - dental arch length (number of teeth)</li> <li>• materials – as acrylic or Visio.lign</li> </ul>   |
| Postoperative instructions                  | <ul style="list-style-type: none"> <li>• radiological exam</li> <li>• instructions for oral hygiene, diet (soft diet, for at least 10 weeks) and medication (antibiotics, analgesic drugs)</li> <li>• informing about the need to make an appointment if bleeding, pain, implant mobility, detachment or damage of the prosthesis occur</li> <li>• establishing the next appointment</li> </ul>  |
| Definitive prosthesis                       | <ul style="list-style-type: none"> <li>• design – dental arch length (number of teeth, usage of cantilever extremities); occlusion scheme; fixation type, as occlusal screw-retained</li> <li>• materials</li> </ul>   |
| Maintenance                                 | <ul style="list-style-type: none"> <li>• regular check-ups</li> <li>• addressing complications</li> </ul>  |

**Table 1.** Main coordinates of the clinical interventions of Sky Fast & Fixed

ces (e.g., deficient lip support), particularities of maxillomandibular relationship are important to be correctly acknowledged in order to obtain an aesthetic and functional outcome. Additionally to alveolar ridge particularities (bone width, vertical ridge orientation and aspect of the surface-uniform or with irregularities), the characteristics of the mucosa, such as resilience



and amount of keratinized mucosa, may be decision-factors for using either a flap or a flapless technique for implant placement. In dentate patients, registration of maxillomandibular relations for the implant prosthesis can be eased by initial records or preservation of posterior occluding teeth. Bone assessment is essential for establishing if this treatment option is viable, and if it is, it's very important for treatment planning, as for deciding upon implant number, position and design (diameter and length). In this respect, a quantitative and qualitative bone evaluation is required, which includes aspects like ridge width, ridge height, anatomical limitations and bone density, additional to panoramic radiographies, computed tomography being highly recommended. Considering that oral hygiene is an important prognosis factor for all implant prosthesis, patient's behavior in this respect should be assessed and deficiencies of it addressed by mechanisms as awareness, motivation and training.

Facial appearance with this type of prosthetic restoration must be assessed and predicted, in order to provide an adequate esthetic result. The analysis should start with the evaluation of initial situation (natural teeth or prosthetic rehabilitation), acknowledging also patient's perception and preferences. Difficulties in this regard are mainly found in edentulous patients that have severe facial changes related to tooth loss and bone resorption, especially in the maxilla due to the centripetal bone resorption. Assessment of facial and lip support can be done comparing the facial appearance with and without the dentures or using a wax try-in without the buccal flange [21]. In patients with severe ridge resorption, if between the ideal artificial teeth location and the ridge there is an increased sagittal discrepancy, in order to obtain a satisfactory esthetic outcome, a removable denture with a buccal flange may be more appropriate. For a natural appearance, vertical bone loss is addressed also through the use of pink acrylic or ceramic.

Implementing this treatment concept should be done in patients with good overall health, considering the inherent risks of the surgical intervention, but also the considerable physical and psychological stress related to the increased number of clinical procedures done in only one day. Therefore, acknowledgement of patient general health status is needed and constant monitoring of the blood pressure and pulse rate in the dental office is recommended.

**The surgical phase** mainly comprises preprosthetic procedures and implants placement.

Preprosthetic surgery aims to obtain optimal conditions for implant placement and for the prosthetic reconstruction (Figure 2). Teeth extraction and related interventions, alveolectomy, bone grafting, excision of hyperplastic lesions and bone leveling may be included.

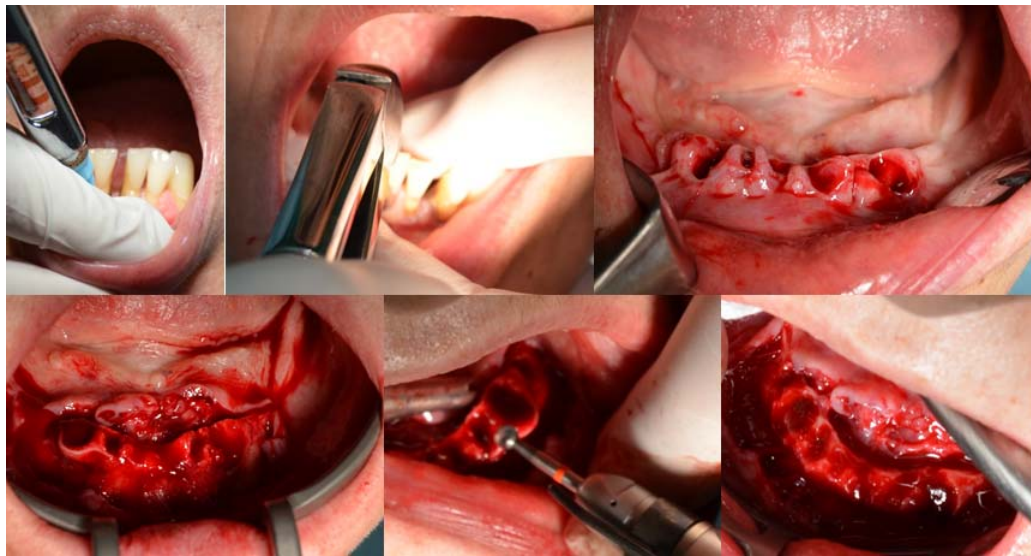
Implant placement may be done using a flap or flapless technique. Flap technique is usually selected, due to the better assessment of available bone and thickness of the crestal area, but flapless surgery has also numerous advantages related to preservations of circulation and bone tissue volume at implant site, decrease of surgical time and accelerated healing [22]. In edentulous patients that do not require preprosthetic surgery and a flapless technique is used, the interim prosthesis can be done prior to the surgical phase, and minor adjustment are needed, contributing to a considerable decrease of the clinical time.

Implant placement should be done according to the treatment plan; for a more accurate position a surgical template can be used. Usually, the axial implants are placed first (Figure

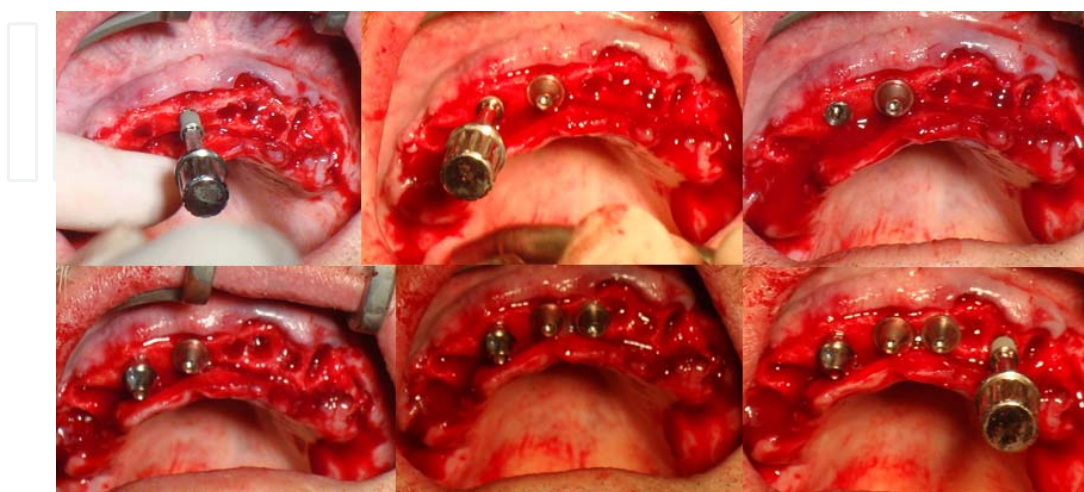
3), and then the tilted ones (Figure 4). For verifying implant angulation, parallelizing pins can be used.

Immediate implant loading requires a good primary stability for achieving a successful osseointegration. This is related to multiple factors, such as bone density, implant diameter and length and insertion torque of 45 N cm or more. Using the long tilted implants favors a good primary stability due to the fact that they follow a dense bone structure-the anterior wall of the sinus [23].

After the selected abutments are placed, the sutures follow. Therefore, there is no need for another surgical phase, as there is in the case of using healing abutments.

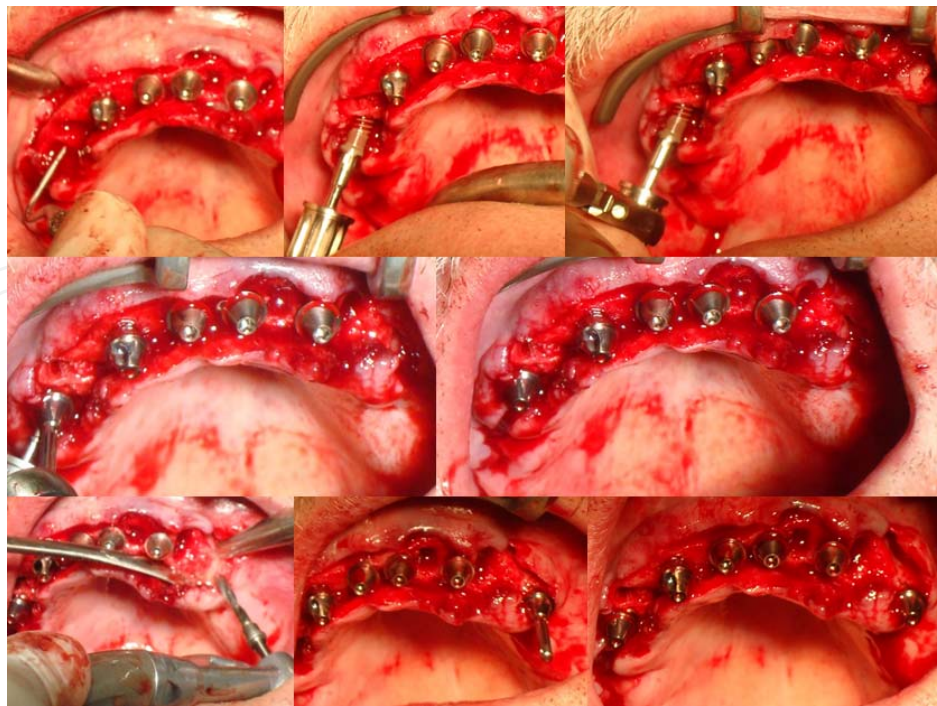

**Figure 2.** Preprosthetic surgery that included teeth extraction and bone leveling



**Figure 3.** Axial implant are placed first





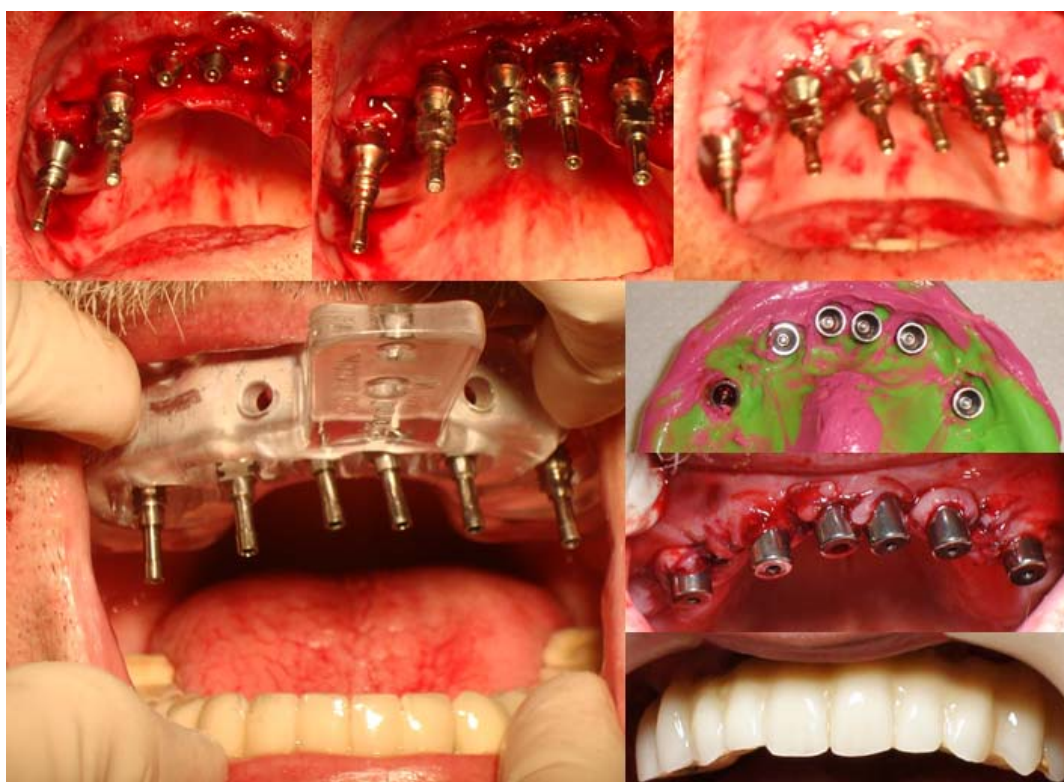
**Figure 4.** Tilted implants are placed second

**Interim prosthesis** is fixed, usually made from rigid acrylic material and splints the implants, protecting them from adverse loading and reducing the stress in the bone around the implant [20,24]. It is manufactured and placed in the same day with implant insertion. Therefore, it is mandatory to include a dental technician in the team that, ideally, has the dental laboratory in the same location with the dental office.

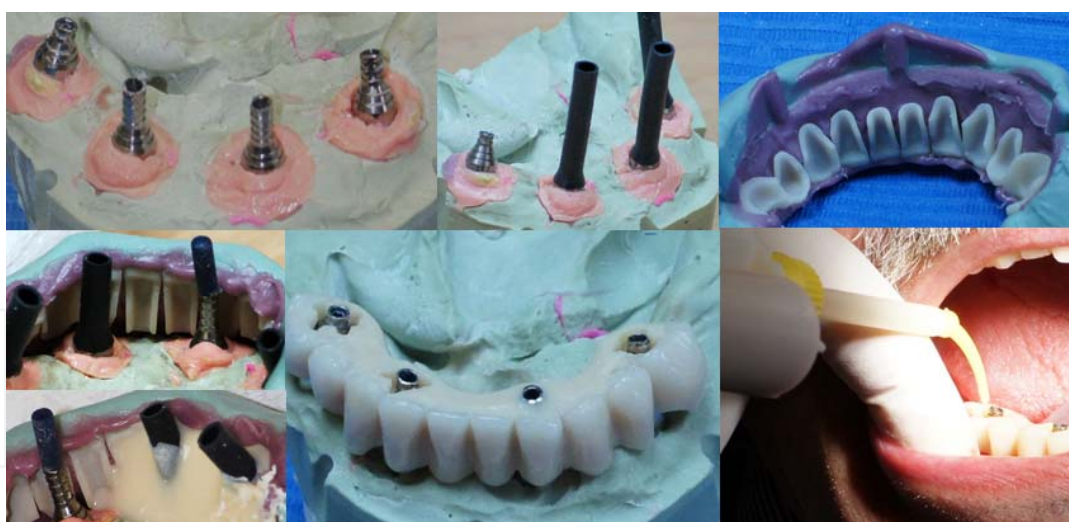Manufacturing the interim prosthesis basically follows the same steps as other fixed-prosthetic implant restoration. After placement of abutments and suture, an impression is taken with a closed or open tray (Figure 5). The impression copings are attached to the implant abutment without splinting, that associates the risk of positional errors that are reflected as deficiencies on all forthcoming laboratory phases. After that, maxillomandibular relationship is recorded.

The dental technician manufactures the interim prosthesis, the procedure being simpler, faster and better adapted to patient's features (e.g., maxillomandibular relationship) when a wax-up is previously made. For shortening of the laboratory phase and obtaining a better esthetic outcome, composite or acrylic prefabricated veneers can be used. The prefabricated veneers are used for a wax set-up, followed by manufacturing a positioning template for them, through the use of a silicone impression. Finishing of the interim prosthesis is achieved by transferring the set-up, adding rigid acrylic material, and fixation of only one implant coping (Figure 6).

After manufacturing of the interim prosthesis by the dental technician, fixation of the remaining implant copings and adjustments are made in the dental office. All implant copings except one are fixed insitu, directly intraorally by the dentist, in order to address coping errors and to ensure passive fit and tension-free placement. Only after that occlusal adjustments are made.



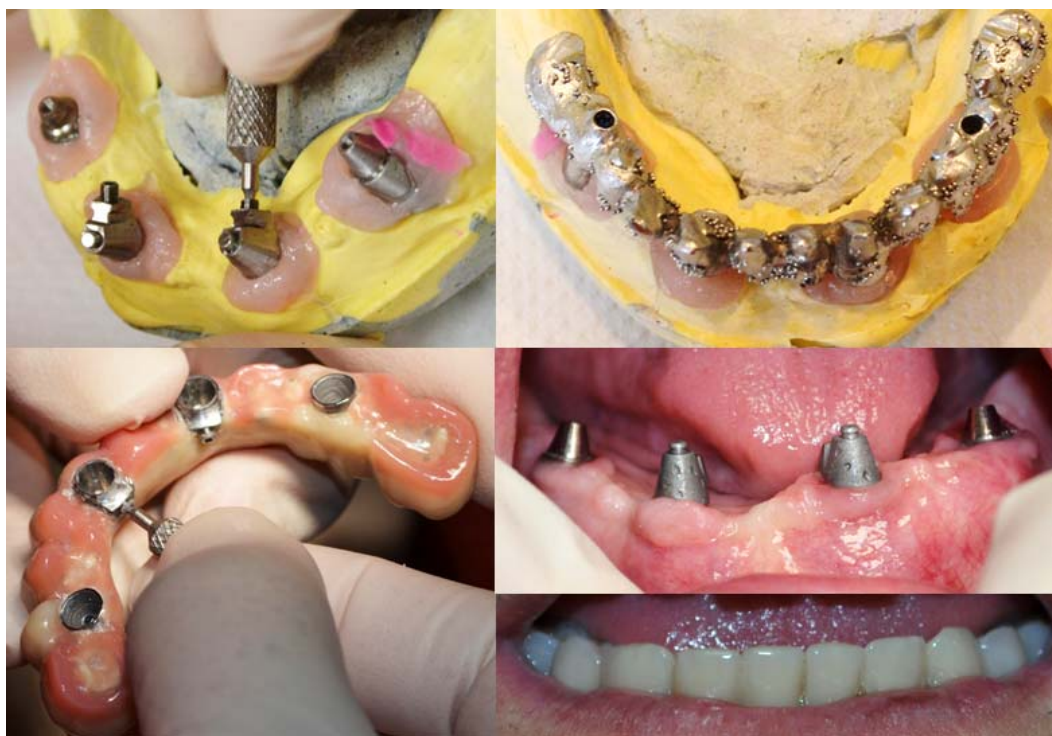**Figure 5.** Interim prosthesis – clinical phases



**Figure 6.** Interim prosthesis – laboratory phases

Therefore, during the osseointegration phase, a comfortable fixed interim restoration is used, that ensures esthetic and functional rehabilitation, which can be used for a moderate period of time. Also, during this interim phase, the patient has the time to analyze and form his own opinion about the esthetic outcome, and declare his own requirements about the changes desired for the definitive prosthesis.





**Figure 7.** Definitive prosthesis execution

**Postoperative instructions** target mainly postoperative medications, the adequate plaque control and using a soft diet during the first weeks. In the next appointment, scheduled in the following days after surgery, occlusal adjustments should be done, considering their impact on the prognosis..

**The definitive prosthesis** is a splinted implant fixed restoration, by a rigid metal-based ceramic or acrylic prosthesis. It is manufactured after at least 4 months after surgery in the maxilla, respectively after at least 3 months in the mandible.

Clinical phase of definitive prosthesis manufacture are similar to those used for fixed-prosthetic implant restorations (Figure 7). If desired, implant abutments can be replaced with others, with different angulation or gingival height. Special attention must be given to accurately register the implant abutment position. In this respect, a preliminary impression is taken in order to fabricate an acrylic splint and a custom tray. The acrylic splint manufactured in the dental laboratory is sectioned in the area between the implants and then splinted intraorally with acrylic resin. Using this procedure for custom tray impression ensures an accurate tension-free registration of implant abutment position.

Definitive prosthetic design, as the length of dental arch and decision upon using cantilever extensions depends on the site of the most distal implant abutment and patient features, as number of teeth exposed during smile. It is best to use cantilever extension with reduced length, below 6-8 mm in the maxilla and 10 mm in the mandible [25].

Definitive prostheses are screw-retained, the screw-access opening being placed on the occlusal or the lingual side of the prosthesis. Through this method of retention, removal of prosthesis and professional hygiene procedures are easy to perform.

Metal or zirconium-based ceramic, metal-based acrylic or composite, are all options that can be used for manufacturing the definitive prosthesis. In the mandible, metal based acrylic and composite restorations are preferred when opposed by maxillary ceramic prosthesis, as prevention factor of negative complication that may appear in relation to occlusal or parafunctional forces. In order to obtain a natural aspect, pink material is used for replacing the lost hard and soft tissue and for restoring the artificial gingival contour.

**Indications.** Sky Fast & Fixed treatment concept addresses rehabilitation of complete edentulism, as current or imminent condition, through an immediate fixed-prosthetic implant restoration. It is especially indicated in the cases with severe ridge resorption in the posterior regions of the jaws that prohibit the axial placement of dental implants, in patients for whom extensive bone grafting procedures are not an option. It can be used for either dentate patients that are soon to be edentulous and absolutely refuse interim or definitive removable prosthesis, or for edentulous patients extremely dissatisfied by their conventional or implant removable prosthesis who desire a fixed prosthetic restoration. In some systemic conditions or elderly patients, this treatment option may be more indicated compared to conventional fixed implant restorations (that usually require major grafting procedures), considering that there are fewer and less invasive surgical procedures, that cause less trauma and stress, shorter healing period and a lower risk of developing complications [26, 27].

**Contraindications.** This treatment alternative basically has the same contraindications as all implant based restorations, mainly in relation to the risks associated to surgical procedures. Even so, there are few absolute contraindications (e.g., recent myocardial infarction, stroke, cardiovascular surgery, and transplant; profound immunosuppression; radiotherapy or bisphosphonate use), the degree of disease-control being far more important than the nature of systemic disorder itself [27,28]. Additionally, there are complications or behavioral aspects that may increase the treatment failure or complication rate, which should be acknowledged (e.g., diabetes, oral hygiene status, smoking, decreased frequency of using the dental services).

Using this specific treatment concept is limited to cases with severe ridge resorption in the anterior region of the jaws, in patients for whom extensive bone grafting procedures are not an option.

**Advantages.** Sky Fast & Fixed has the general advantages of immediately loaded fixed implant prosthesis, provided through a less invasive treatment compared to the conventional option.

As an immediately-loaded implant-prosthesis, it ensures immediate functional and esthetic rehabilitation, with a positive impact on patient's wellbeing and quality of life. Even more, for the dentate patients it is possible to avoid the edentulism condition treated by removable prosthesis, the imminence of this situation being frequently a major stressor for patients.

Compared to conventional fixed implant prosthesis, Sky Fast & Fixed is considered to be less invasive. The surgical procedure used is simpler, by avoiding extensive bone grafting,

placement of fewer implants, using when appropriate a flapless technique, no need for a second stage implant surgery. Also, there is only one-day of surgery. Minor preprosthetic surgery, if required, is done in the same appointment with implant placement, and there is no need of a second stage implant surgery. Correspondently, the less the surgical trauma is, the faster the healing and recovery of the patient is.

Using a reduced number of implants, avoiding some procedures like bone grafting, the possibility of using metal-based acrylic prosthesis, decrease of the number of clinical appointments required, are all factors that may contribute to a decrease of the treatment cost. This may be an important aspect for the edentulous patient that is often aged and has limited financial means.

This treatment concept has advantages also for the dental team. Aspects like the standardized treatment protocol, the reduced number of clinical appointments, the relatively easy way of manufacturing and placement of the interim prosthesis, patient's satisfaction, all have a positive impact.

**Complications.** This treatment option basically has the same complications with any immediately loaded fixed implant prosthesis. Some aspects, mainly related to Sky Fast & Fixed particularities will be highlighted.

The acrylic interim prosthesis can fracture, this occurring mainly after the ten week period of recommendation of eating soft diet, when patients fell confident to chew harder food. If unmanaged, it can lead to implant failure, due to the alteration of the splinting process. Therefore, the interim prosthesis should not be reinforced, because it may mask the fracture and delay the patient's addressing to the dental office.

If chipping of the ceramic of the definitive prosthesis occurs, this being a relative frequent complication, the interim prosthesis can be used for the time needed for laboratory repairing.

One important risk factor for all implant prosthesis, including this treatment option, that is linked to sometimes severe complications, is the correctness of the registration of maxillo-mandibular relations (respecting the coincidence of maximal intercuspal position and centric relation, and the functional vertical dimension of occlusion). Acknowledging that, in a dentate patient with posterior occluding teeth it is recommended their preservation until after the interim prosthesis is manufactured, in order to ensure a correct registration.

### 3. Implant overdentures

**General presentation.** An implant overdenture is a removable dental prosthesis supported or retained by dental implants, through various attachment systems (e.g., ball, locator, magnets, bar). Benefits of overdentures include increased retention and stability of the prosthesis, improved mastication and phonation, decrease of the rate of ridge resorption, all having a positive impact on patients' well-being and quality of life.

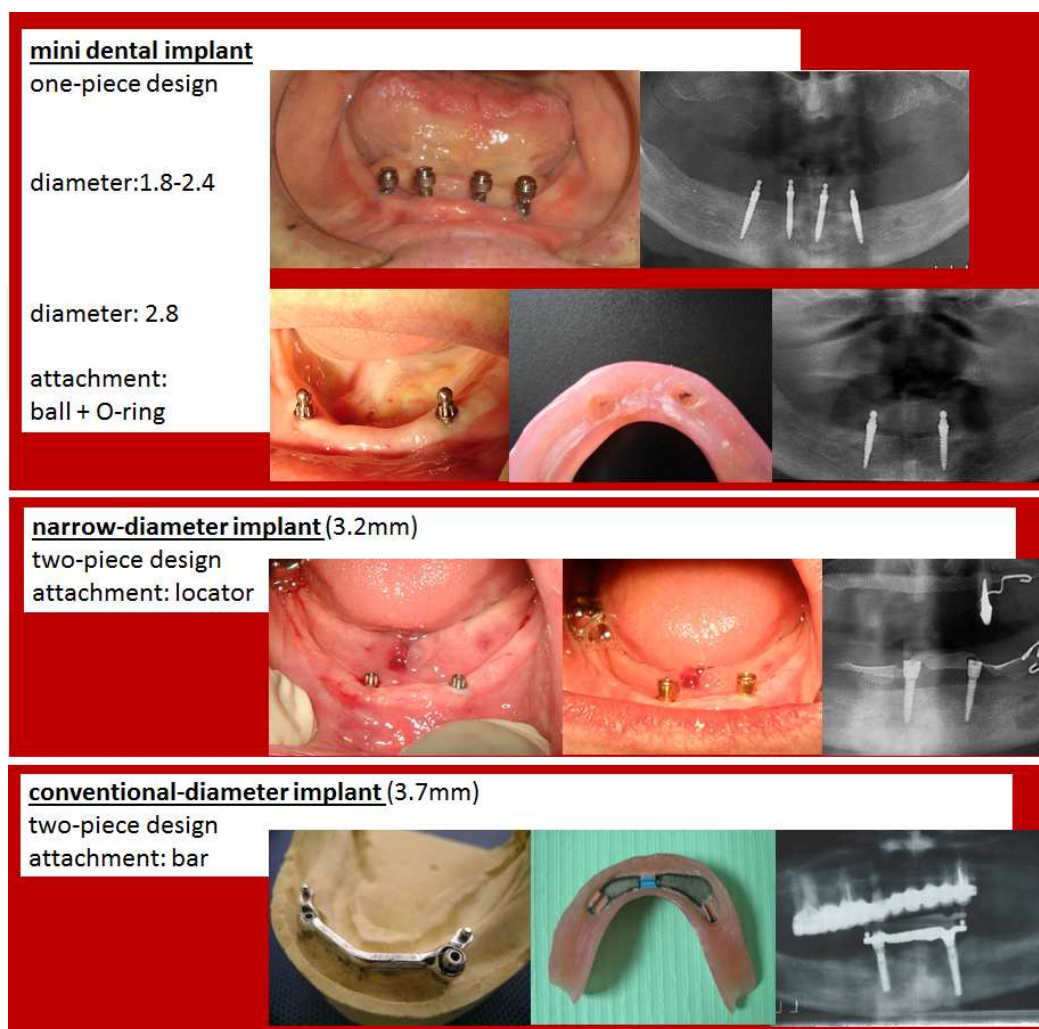
An increased usage of this treatment option occurred as a reaction to the relatively frequent retention and stability deficiencies of complete dentures that are addressed at more affordable



costs compared to the ones of fixed implant prosthesis [29]. Moreover, nowadays two implant overdentures are considered the minimum standard of care for mandibular edentulism, taking into account performance, patient satisfaction, cost and clinical time [6]. Most probably, overdenture use will increase even more, in relation to its indications, being most appropriate for the aged population segment that is estimated to be increasing.

Implant overdenture treatment concept has the following main features:

- It is designed for complete edentulism, as interim or definitive removable prosthesis, and can be applied in one or both jaws.
- Overdenture has, with regards to their role, three structural elements: the infrastructure (the implants), the mesostructure (the connector between implants and overdentures, the attachment system) and the superstructures (the partial or complete overdentures).
- The use of implants and attachment system aims to improve overdenture retention (1), or retention and stability (2), or retention, stability and support (3).
- Implant overdentures can be supported exclusively by implants (1), by implants and soft tissue (2), or only by the soft tissue (3).
- There are different types of implants that can be used for implant overdentures (e.g., conventional diameter, narrow or mini dental implants; narrow implants with one-piece or two-piece design). These are available in different lengths, diameters and sometimes have different attachment systems (Figure 8).
- The number of dental implants placed in the case of implant overdentures vary between 1 to 4 for mandibular overdenture, and 2 to 6 for maxillary overdenture.
- Selection of the dental implant, as type, diameter and length and establishing their number and position must consider the bone features (ridge width and length; bone density) and treatment objectives (e.g., enhance only overdenture retention, or retention and support). Usually, implant placement without bone grafting can be done anteriorly to the mental foramen in the mandible, and anteriorly to the maxillary sinus in the maxilla. Frequently, for the implants placed in the posterior area of the jaws, bone grafting is required. In order to avoid bone grafting, narrow dental implants can be used in narrow ridges, and short dental implants can be used in reduced ridge height. Bone density, according to Misch classification, should be D1, D2 or D3, not D4 because it is usually accompanied by implant failure [30].
- Depending on patient's features and the material and treatment option chosen, implant placement can be done with or without a flap, using one-stage or two-stage implantation protocol.
- Implants can be unsplinted (e.g., with ball as attachment system) or splinted (e.g., with bar as attachment system). In the first case, implant problems can be more easily addressed by implant replacement or by placing an additional implant. In case of implants splinted by a bar, implant failure may be followed by treatment failure. There is no difference between



**Figure 8.** Different type of implants, according to their diameter and attachment system

splinted and unsplinted implant overdentures regarding the peri-implant outcome and patients' satisfaction. Therefore, considering unsplinted implants prostheses have simpler manufacturing and repairing procedure, these may be more indicated for aged edentulous patients [31].

- There are many types of attachment system that can be used for implant overdentures, e.g., ball, bar, locator, magnets, telescope, TiSiSnap. Selecting the attachment system must consider their role, such as only improving overdenture retention (e.g., ball attachment), or retention and stability (e.g., round bar attachment with non-rigid anchorage), or retention, stability and support (e.g., milled bars with rigid anchorage). Aspects related to patient's features (bone resorption, interarch vertical space, patient ability to perform maintenance procedures and expectations), situation of the opposite jaw (dentate or edentulous patient, treated by fixed or removable conventional or implant prosthesis), financial costs, should be all considered.

- The overdenture design is related to the other features of the implant prosthesis. Namely, if ball attachment system are used, that only improve overdenture retention, overdenture is best to be designed as a conventional denture, with complete coverage of the support area, until the anatomical and functional borders, with complete peripheral seal. If an implant-supported overdenture is used, an open palate overdenture can be used, and if desired can be screw-retained, similar to a fixed implant restoration.
- Overdenture reinforcement, in order to prevent its fracture, is mainly indicated when more than two unsplinted implants are used and in bars (considering the costs of the repairing procedure are higher, sometimes being necessary to renew the overdenture).
- In previous denture wearers, sometimes the old denture can be modified and used as the overdenture.
- Oral hygiene maintenance for implant overdentures is relatively easy to perform, considering that by removal of the prosthesis patients can have good access to the peri-implant tissue.
- Usually performing an implant overdenture requires reduced clinical time and number of appointments, additional to those usually required for a complete denture. In immediate loaded implant ball-retained overdentures, implant placement and overdenture adjustment can be done in one day, being accompanied by an immediate functional rehabilitation. In other cases, a delayed loading is required.
- Regular check-ups are most important during the osseointegration phase and in the first year of functioning, considering this is the period when most severe complications usually occur.

There are many treatment planning options when considering treatment of edentulism with implant overdentures, some being more invasive than other. Selection of one of them depends mainly on patient's preferences and needs, and on oral and general health status and particularities.

Among implant overdenture treatment options, those requiring easier and less invasive interventions for execution and maintenance will be detailed further on. There will be addressed mainly the alternatives that require the minimum necessary surgery (mainly implant placement, according to the anatomical limitations), preferably with immediate implant loading (ensures rapid functional reestablishment), and unsplinted implants (give more flexibility in managing future complications, that usually are less severe; maintenance is simpler). These overdentures mainly improve the retention of the prosthesis, and are implemented at moderate biological, financial and time costs.

### **Clinical phases.**

**Patient evaluation** should comprise the common diagnostic data collection for complete dentures, and implant prosthesis, some of the aspects mentioned below being very important for treatment planning in case of implant overdenture.

Patient's needs, expectations and chief complaints related to the previous prosthetic treatment should be well-acknowledged. Most often, previous complete denture wearers are dissatisfied by its retention, aspect that is usually well addressed by implant overdentures. Dentate patients are often frightened by the idea of removable denture, and have psychological difficulties in accepting it. Therefore, explaining to the patient the main treatment options, with their benefits, limitations and cost, is mandatory.

Considering that often edentulous patients are aged, with multiple comorbidities, less invasive surgery is beneficial. Therefore, bone offer needs to be accurately analyzed, in order to establish implants type, position, diameter and length. Frequently, sufficient natural bone for implant placement is found anteriorly to the mental foramen in the mandible, and anteriorly to the maxillary sinus in the maxilla. In the mandible, bone deficiencies are mostly related to severe ridge resorption and decreased ridge width. In the maxilla, bone deficiencies are mostly related to decreased ridge height and reduced bone density. Consequently, when conventional dental implants cannot be applied without bone grafting, narrow or mini dental implants may be used in the mandible, and an increased number of conventional diameter implants are recommended in the maxilla [32]. In the mandible, two conventional diameter implants (diameter greater than 3.5mm), two narrow diameter implants (diameter below 3.5mm), or four mini dental implants (diameter below 3mm) are usually placed. In the maxilla four conventional diameter implants, four narrow diameter implants or six mini dental implants, of minimum 10 mm length are usually placed.

Thickness of keratinized mucosa should be evaluated in order to properly select the implant and attachment system that are usually designed with alternatives for different gingiva height.

Treatment planning should consider the condition and treatment of the opposite jaw. For example, planning an implant overdenture in the mandible should consider if teeth or fixed restoration, or edentulism treated by conventional denture are found in the maxilla. If teeth or fixed prosthesis are found in the maxilla, it is recommended to increase the number of mandibular implants and special consideration should be given to the vertical prosthetic space that is frequently reduced. If a complete denture is found in the maxilla, signs of combination syndrome may appear due to anterior movement of the masticatory field, favoring the instability of the maxillary denture and the increased bone resorption rate in the anterior maxilla. Consequently, this iatrogenic effect can be managed by using implant overdenture also in the maxilla [33].

Previous denture analysis may offer diagnostic data and further on, depending on their correctness, can be transformed or not into the future overdenture. Aspects like registration of an increased vertical dimension of occlusion or errors in artificial teeth mounting should lead to the decision of manufacturing a new denture, because these may become risk factors for implant overdenture complications.

**Surgical procedure** includes teeth extractions, preprosthetic interventions and implants placement.

Preprosthetic surgery aims towards obtaining favorable conditions for denture execution and improving the treatment prognosis. It may include intervention on the bone (for exostosis, tori)



or the soft tissue (for frenum, hyperplasia). Sometimes, major surgical interventions, such as bone grafting, sinus lift or mental nerve relocation, are needed. Decision regarding the preprosthetic surgical intervention used is linked to patient features and treatment parameters (e.g., using narrow dental implants usually requires less invasive preprosthetic surgical interventions compared to conventional diameter implants). Preprosthetic surgery can be performed before or during implant placement.

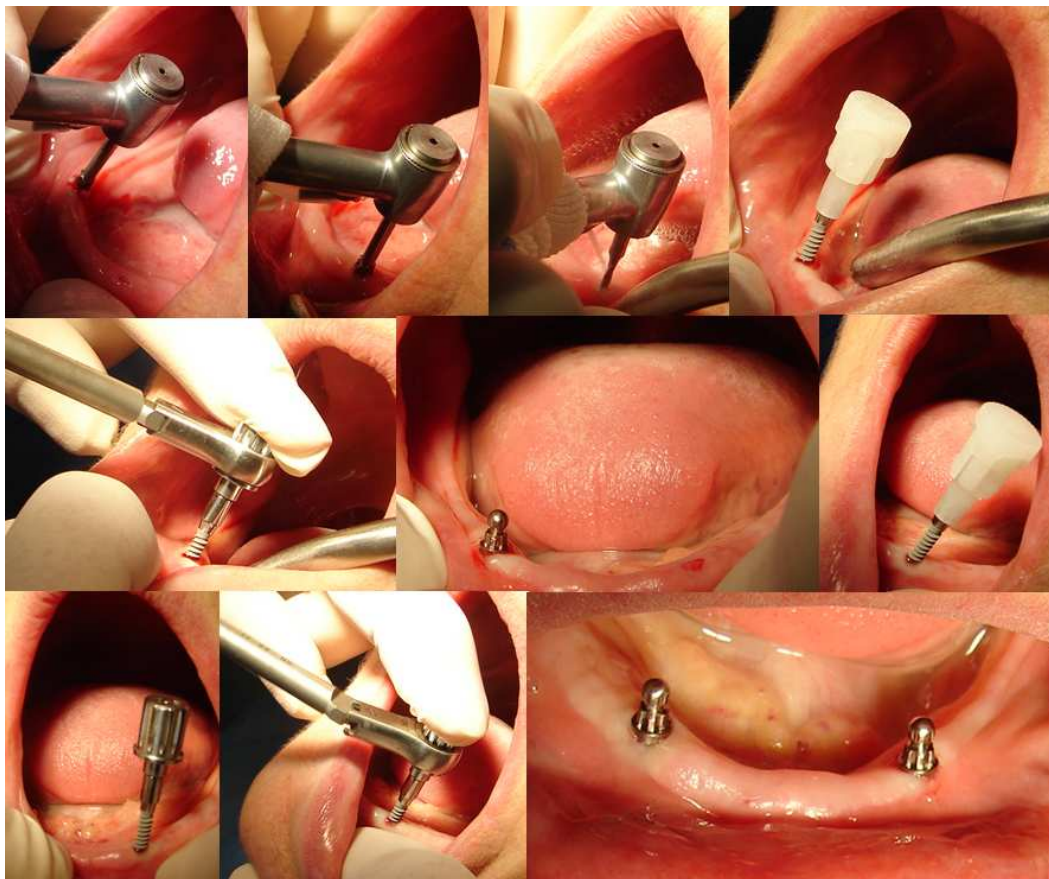
Implant placement, as implant number and position, is done according to the treatment plan previously established. In order to obtain the desired implant position and angulation, a surgical guide or template can be used.

Surgical steps of implant placement vary according to patient's features, implant placement protocol and implant type, respecting the manufacturer's instructions.

Case particularities are determinant for choosing a specific treatment conduct. Alveolar ridge width and height, bone density, cortical bone thickness, mucosal resilience and width of keratinized mucosa are decision factors for using flap or flapless technique, one-stage or two-stage implantation protocol with immediate or delayed loading [30].

Implant surgical protocol is achieved using the main following steps, with variation depending on the implant type used (e.g., mini, narrow or conventional diameter implant). Firstly, a surgical exposure of the implant site is done, through flap elevation or mucosal punch, with a flapless technique. Using a flap technique has the advantage of a better assessment of available bone and thickness of the crestal area, information deficiently acknowledged when only clinical examination and panoramic radiographs are used. Flapless technique is mostly used for narrow dental implants (Figure 9). It has the advantage of reduced bleeding and decrease of the clinical time required (avoiding incision and flap elevation in the beginning, and suture in the end), is less invasive compared to the previous therefore promoting a shortened healing period. Afterwards, initial osteotomy is done with the marking or trepan drill, this aiming to pierce the cortical bone and define the implant site. With the same or another drill, usually called pilot drill, the implant osteotomies is initiated, in this stage being important to verify the implant angulation with a parallel pin. Implant placed with an unfavorable divergent angle may associate difficulties related to abutment and attachment system selection and exertion of excessive pressure on the implant during overdenture placement or removal. Osteotomy depth varies according to bone density, being approximately 2/3 of implant length in low bone density (D3) and as implant length in increased bone density (D1, D2). The implant osteotomy is enlarged as necessary using the twist drills. All previous drilling procedures need to be accompanied by irrigation with refrigerated sterile saline. Consequently, implant is placed with the ratchet and handpiece. After that, depending on the implant type and the treatment plan, if the surgical phase is over, placement of cover screw, healing abutment or prosthetic abutment, with suturing flap, are necessary. The surgical appointment usually ends with giving the patient the postoperative instructions regarding care (hygiene, diet and medication), also being scheduled for the next appointment. When needed, a second stage implant surgery is applied for removal of the cover screw and abutment placement [34,35].





**Figure 9.** Flapless surgical technique used for placement of mini and narrow dental implants

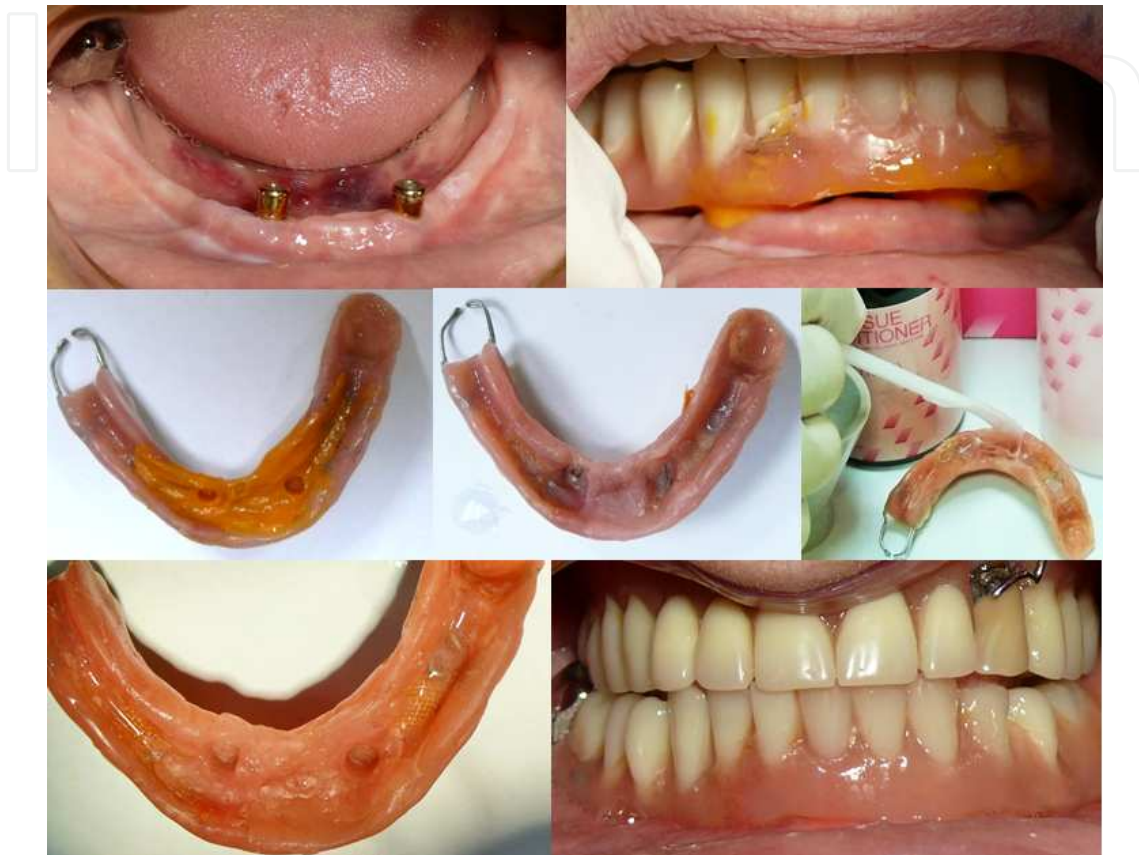Considering that generally edentulous patients are aged, with systemic comorbidities and less availability to complex surgical intervention, simpler one-stage surgical interventions are usually preferred [36]. Considering that, mini or narrow dental implants may be preferred for increasing the denture retention, due to the simpler and shorter medical intervention [37-39].

**The overdenture** can be executed before or after implant placement. If applicable, the previous complete denture can be used as interim prosthesis or can be transformed into the new overdenture.

Overdentures that aim only towards improvement of retention, should be designed as a conventional denture, with proper support, retention and stability. If previous dentures are preserved, their correctness should be assessed in order to decide to either keep or replace them.

Using an implant overdenture associates more frequently a less accurate extension of overdenture bearing area, due to the misconception that the attachment system will provide all the retention needed. Overextended flanges dislodge the overdenture during chewing or speaking. Short flanges enhance food and plaque accumulation and retention. Existence of a space between the overdenture and the oral mucosa in the implant site is a risk factor for peri-implantitis or peri-implant mucositis. Therefore, a complete coverage of the overdenture

support area, reaching the anatomical and functional borders, with complete peripheral seal should be obtained. For the maxillary denture, complete palatal coverage, with posterior palatal seal is recommended. In order to correctly register the functional limits of the denture bearing area, a mucodynamic functional impression technique can be used.



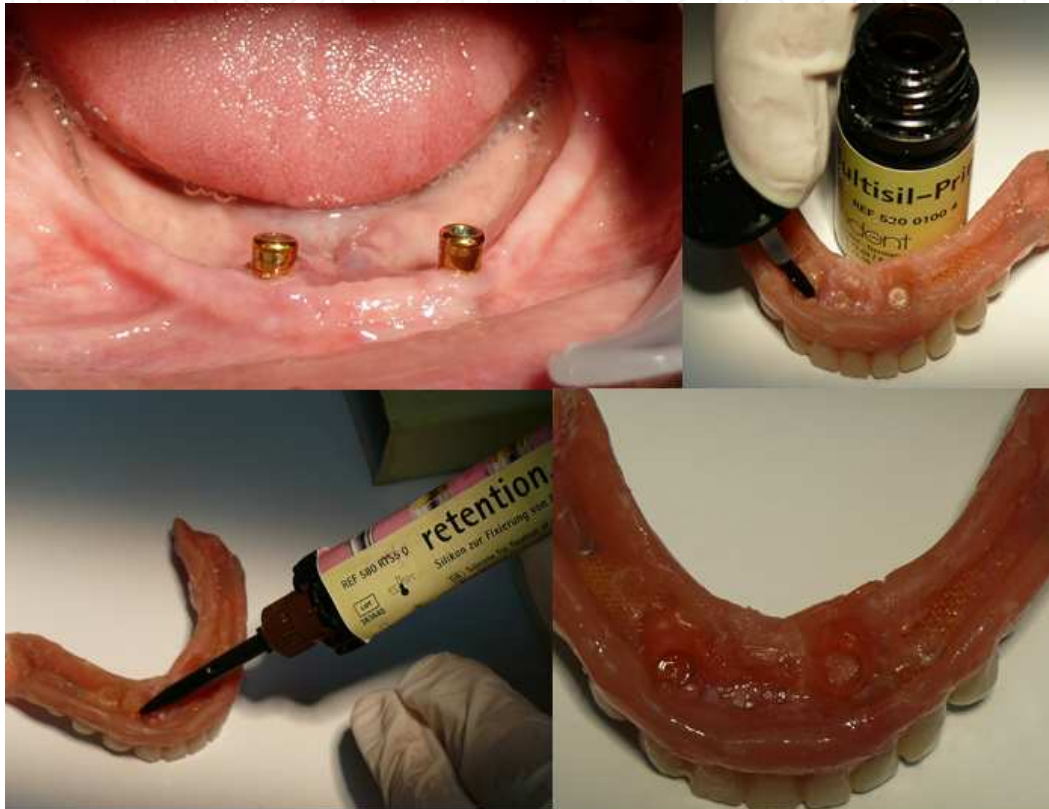**Figure 10.** The worn denture was modified as overdenture, and used as an interim prosthesis during the osseointegration period

Registration of maxillomandibular relations aims towards recording the correct functional vertical dimension of occlusion and centric relation. Correctness of this clinical procedure has a major impact of the treatment outcome. Registration of an increased vertical dimension of occlusion can lead to prosthesis intolerance and implant loss, consecutive to the high pressure exerted on them.

In order to obtain a good esthetic outcome, the overdenture can be manufactured first, according to the esthetic principles and patient wishes, followed by implant placement using a surgical template.

For implant overdentures, immediate or delayed implant loading protocols can be used. Delayed implant loading is mainly used for conventional diameter implants. After implant placement, the healing abutments are placed for 10 to 13 weeks; in this period it is important to verify the denture, in order not to exert excessive pressure on implant site and interfere with

implant osseointegration. Immediate implant loading is always used for one-piece mini dental implants, and sometimes used for narrow and conventional diameter implants. Using it requires a good primary stability of the implant, linked to a high insertion torque, of 35-40 Ncm. When the value of insertion torque is reduced, immediate implant loading can be done using soft acrylic or silicone materials [40]. In this respect, there are silicone materials especially developed to be used as matrices, such as Retension.Sil (Bredent), that offer three retention levels, i.e., 200, 400, 600 gf (Figure 11).



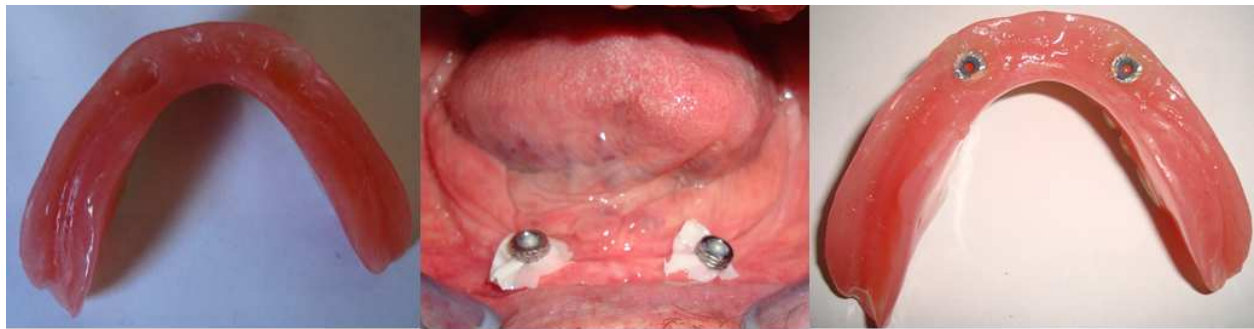**Figure 11.** Immediate implant loading with silicone materials.

Attachment systems ensure stable balance (support, retention, stability) of the overdenture. The usual attachment systems used are: round, ovoid or parallel wall shaped bar; ball; Locator; magnets; telescopes. Selection of the attachment system depends on oral and prosthesis features, such as:

- overdenture type (partial or complete) and the role of connection systems (to improve support, stability and/or retention of the prosthesis);
- the implant number, site, angulation and their parallelism (two implant overdenture can be splinted with a bar, or used unsplinted with ball attachment; the selection of the attachment system must take into account the parallelism of the implants, ball attachments can be used up to 30° divergence while Locator allows up to 40° divergence);



- prosthetic conditions: interarch vertical space, resilience of the mucosa, magnitude of occlusal forces, functional particularities, the need for retention;
- patient manual dexterity may be related to selecting a more or less retentive system (dexterity is relevant for denture handling and oral hygiene maintenance, and elderly patients frequently have reduced dexterity);
- biomechanical treatment features (splinting the implants with a bar ensures a more uniform distribution of stress on the implants, but damage to one implant can cause the loss of the entire attachment system; screw of the connection system must be performed at a torque lower than the one used for implant insertion);
- financial and clinical time costs of the treatment (selecting the treatment option should not be based only on finances, but some of them are more expensive than others, e.g., costs of bar attachments are superior to those for ball attachments).



**Figure 12.** Placement of the metal matrices in the overdenture base

**Postoperative instructions** usually target the postoperative medications, the adequate plaque control, having a soft diet and wearing the overdentures as little as possible until the next appointment. It is mandatory to schedule the next appointment in the following days, in order to verify if the overdenture is supported only by the oral mucosa and to make occlusal adjustments. During osseointegration phase, pressure exercised on the implants is a major risk factor for implant failure. Additionally, in overdentures with immediate implant loading, patients have difficulties in assessing the cause of a perceived discomfort (implant pain is usually mistaken for trauma related to the prostheses or healing after surgery). Therefore, regular check-ups are recommended and the denture should not be worn overnight.

**Indications.** Implant overdentures are removable prostheses designed for treatment of edentulism, considered as the minimum standard of care for this condition. They are indicated for unsatisfied complete denture wearers, because by a relative simple intervention patient's complaints can be addressed, usually solving the problem of ill-fitting dentures. Also, they can be used as preventive factor for alveolar ridge resorption in high risk patients (e.g., patients with tooth loss due to periodontitis, with diabetes, during the menopause and postmenopause). Overdenture can be used as palliative treatment in patients with sensitive mucosa or hyposialia. They are particularly recommended in the older completely edentulous patients,

which show a more frequent rate of denture intolerance, this way favoring a better adaptability with the prosthesis. Implant overdenture are recommended to be used when there are objective reasons that favor instability of the conventional denture (e.g., mandibular implant overdentures are indicated in skeletal class II patients; maxillary overdentures are indicated in skeletal class III patients). They are also recommended in oral and maxillofacial defects (clefts; after tumors removal, trauma) and in those with poor neuro-muscular coordination.

**Contraindications.** Implant overdentures have contraindications, mainly in relation to the risks associated to the surgical procedures, even if in some cases it can be regarded as a minimally invasive one. Additionally, using this specific treatment concept is limited to cases with reduced prosthetic vertical space that makes it impossible to apply the attachment systems and also provide adequate prosthesis resistance (e.g., using Locators requires a minimum of 8.5 mm vertical space and 9 mm horizontal space; bar attachments require 10 to 12 mm vertical space) [41]. Implant overdentures are not recommended when there is a decreased D4 bone density, in bruxism and in severe oral hygiene deficiency.

**Advantages.** Implant overdentures are a viable alternatives to conventional dentures, being considered the optimal solution for the edentulous seniors. Its main advantages are related to the improved retention, stability and support, depending on the attachment system that is used (e.g., improved chewing efficiency, speaking and comfort, with positive consequences on the quality of life). Using it associates a lower bone resorption rate, compared to conventional dentures, due to dental implants and improved denture stability, thus limiting the magnitude of pressures to a biological tolerance level. For the upper arch, if a vomiting reflex exists, the extension of the maxillary base can be reduced. Plaque control for implant overdenture is easier compared to implant fixed prostheses, but more difficult compared to conventional dentures. Considering the relatively easy surgical intervention and the reduced number of implants used, it is better accepted by patients with fear of complex medical interventions. Their execution and maintenance implies lower costs compared to the fixed implant prosthesis, and even if they are not the gold standard treatment, they can be considered as being cost effective due to their obvious benefits.

**Complications.** The implant overdenture complications occur in relation to patient's features, to surgical procedures or to prosthetic factors, during or after treatment execution. Some of them are considered as being more specific to this treatment option.

The implants' failure, as lack of osseointegration or peri-implantitis, can be linked to factors that affect healing of the bone, such as diabetes, steroids or bisphosphonates treatment, and smoking, to inadequate bone site and poor quality of the bone, to implant trauma exercised by the denture, to poor oral hygiene and decreased patient compliance. Prosthetic complications occur mainly within the first year of functioning [42]. Biomechanical or technical complications of the overdentures or attachment system used can be encountered, such as overdenture fracture, retention loss, aging of the material, teeth wear and attachment system loosening, loss or damage.

Addressing overdenture complications should take into account their nature, etiology and severity. Acknowledgement of patient's general and local features, respecting the removable



implant prosthodontic principles, additional to regular check-ups, represent the basis of their prevention and control.

#### 4. Conclusion

Sky Fast & Fixed is one of the less invasive fixed-prosthetic implant restoration for edentulism. It is a relatively simple and quick approach to the patient's medical problem, implemented through a decreased number of appointments, using limited surgery and reduced number of implants. The interim prosthesis is fixed, applied in the same day as implant placement, therefore the removable prosthesis is avoided. This rapid, less invasive, cost-effective fixed implant restoration usually ensures rapid regaining of functionality and resumption of social activities.

The implant overdenture is acknowledged as having a high predictability and numerous advantages compared to the most widely used treatment alternative, namely complete denture. It is important to identify the simpler and less invasive options of implant overdenture when considering the trends of decreasing tooth loss that associate an increasing of the age when edentulism occurs. Elderly patients require prosthetic rehabilitations that ensure good functionality, but considering their multiple systemic comorbidities and reduced availability to complex medical interventions, less invasive treatments with limited surgery, with easy maintenance procedures and that are cost-effective are more realistic and appropriate to their expectations. Therefore, the frequent problem of ill-fitting dentures can be relatively simply approached through placement of a reduced number of conventional diameter, narrow, or even mini implants, this requiring one clinical appointment, a relatively simple medical procedure and moderate costs.

Identifying and presenting to the reluctant edentulous patient the less invasive implant treatment strategies, fixed and removable, with their advantages, disadvantages and limitation, may help overcome their misconceptions and fears towards the implant prosthesis and lead to applying a treatment with a better outcome that promotes higher satisfaction and improved quality of life.

#### Author details

Elena Preoteasa<sup>1</sup>, Laurentiu Iulian Florica<sup>2</sup>, Florian Obadan<sup>3</sup>, Marina Imre<sup>1</sup> and Cristina Teodora Preoteasa<sup>4\*</sup>

\*Address all correspondence to: [cristina\\_5013@yahoo.com](mailto:cristina_5013@yahoo.com)

1 Department of Prosthodontics, Faculty of Dental Medicine, Carol Davila University of Medicine and Pharmacy, Bucharest, Romania

2 Private Practice, Bucharest, Romania

3 Private Practice, Alexandria, Romania

4 Department of Oral Diagnosis, Ergonomics, Scientific Research Methodology, Faculty of Dental Medicine, Carol Davila University of Medicine and Pharmacy, Bucharest, Romania

## References

- [1] Felton D, Cooper L, Duqum I, Minsley G, Guckes A, Haug S, Meredith P et al. Evidence-Based Guidelines for the Care and Maintenance of Complete Dentures: a Publication of the American College of Prosthodontists. The Journal of the American Dental Association 2011;142 (Supplement 1):1S-20S.
- [2] Douglass CW, Shih A, Ostry L. Will There Be a Need for Complete Dentures in the United States in 2020? Journal of Prosthetic Dentistry 2002;87:5–8.
- [3] Carlsson GE<sup>1</sup>, Omar R. The Future of Complete Dentures in Oral Rehabilitation. A Critical Review. Journal of Oral Rehabilitation 2010;37(2):143-56.
- [4] Fitzpatrick AL, Powe NR, Cooper LS, Ives DG, Robbins JA. Barriers to Health Care Access Among the Elderly and Who Perceives Them. American Journal of Public Health 2004; 94(10):1788-94.
- [5] Dolan TA, Atchison K, Huynh TN. Access to Dental Care Among Older Adults in the United States. Journal of Dental Education 2005; 69(9): 961-74.
- [6] Thomason JM, Kelly SA, Bendkowski A, Ellis JS. Two Implant Retained Overdentures-a Review of the Literature Supporting the McGill and York Consensus Statements. Journal of Dentistry 2012;40(1):22-34.
- [7] Nowjack-Raymer RE, Sheiham A. Association of Edentulism and Diet and Nutrition in US Adults. Journal of Dental Research 2003;82(2):123-6.
- [8] MacEntee MI, Walton JN. The Economics of Complete Dentures and Implant-Related Services: a Framework for Analysis and Preliminary Outcomes. Journal of Prosthetic Dentistry 1998;79(1):24-30.
- [9] Fitzpatrick B. Standard of Care for the Edentulous Mandible: a Systematic Review. Journal of Prosthetic Dentistry 2006;95(1):71-8.
- [10] Esposito M, Grusovin MG, Chew YS, Coulthard P, Worthington HV. One-stage versus two-stage implant placement. A Cochrane Systematic Review of Randomised Controlled Clinical Trials. European Journal of Oral Implantology 2009;2(2):91-9.
- [11] Visser A, de Baat C, Hoeksema AR, Vissink A. Oral Implants in Dependent Elderly Persons: Blessing or Burden? Gerodontology 2011;28(1):76-80.
- [12] Brennan M, Houston F, O'Sullivan M, O'Connell B. Patient Satisfaction and Oral Health-Related Quality of Life Outcomes of Implant Overdentures and Fixed Com-

plete Dentures. *The International Journal of Oral & Maxillofacial Implants* 2010;25(4):791-800.

- [13] Carr AB, Choi YG, Eckert SE, Desjardins RP. Retrospective Cohort Study of the Clinical Performance of 1-Stage Dental Implants. *The International Journal of Oral & Maxillofacial Implants* 2003;18(3):399-405.
- [14] Preoteasa E, Marin M, Imre M, Lerner H, Preoteasa CT. Patients' Satisfaction With Conventional Dentures and Mini Implant Anchored Overdentures. *Revista Medico-Chirurgicala a Societatii de Medici si Naturisti din Iasi* 2012;116(1): 310-16.
- [15] Malo P, Rangert B, Nobre M. All-on-4 Immediate-Function Concept with Branemark System Implants for Completely Edentulous Maxillae: a 1-year Retrospective Clinical Study. *Clinical Implant Dentistry and Related Research* 2005;7(Supplement 1):S88-94.
- [16] Lopes A, Malo P, de Araujo Nobre M, Sanchez-Fernández E. The NobelGuide® All-on-4® Treatment Concept for Rehabilitation of Edentulous Jaws: A Prospective Report on Medium-and Long-Term Outcomes. *Clinical Implant Dentistry and Related Research* 2014. doi: 10.1111/cid.12260.
- [17] Malo P, de Araujo Nobre M, Lopes A, Moss SM, Molina GJ. A Longitudinal Study of the Survival of All-on-4 Implants in the Mandible with up to 10 Years of Follow-up. *The Journal of the American Dental Association* 2011;142(3):310-20.
- [18] Kistler F, Kistler S. All-on-four, Neue Philosophie Bei der Implantologischen Versorgung im Zahnlosen Kiefer. *Bayerisches Zahnärzteblatt* 2005. [www.bzb-online.de/apr05/46.pdf](http://www.bzb-online.de/apr05/46.pdf) (accessed 20 September 2014).
- [19] Ata-Ali J, Peñarrocha-Oltra D, Candel-Marti E, Peñarrocha-Diago M. Oral Rehabilitation with Tilted Dental Implants: a Metaanalysis. *Medicina Oral Patologia Oral y Cirugia Bucal* 2012;17(4):e582-7.
- [20] Jivraj S, Zarrinkelk H. Graftless Solutions in Implant Dentistry: Part 2. Diagnosis, Treatment Planning and Delivery of the Immediate Load Prosthesis. *Dental Tribune* 2012; 4:6-14.
- [21] Jivraj S, Zarrinkelk H. Graftless Solutions in Implant Dentistry: Part 1. Diagnosis, Treatment Planning and Delivery of the Immediate Load Prosthesis. *Dental Tribune* 2012; 3:8-19.
- [22] Choi BH, Jeong SM, Kim J, Engelke W. *Flapless Implantology*. Hanover Park: Quintessence Pub Co; 2010.
- [23] Spinelli D, Ottria L, DE Vico G, Bollero R, Barlattani A, Bollero P. Full Rehabilitation with Nobel Clinician(®) and Procera Implant Bridge(®): Case Report. *Oral & Implantology* 2013;6(2):25-36.
- [24] Bergkvist G. Immediate Loading of Implants in the Edentulous Maxilla. *Swedish Dental Journal. Supplement* 2008;(196):10-75.

- [25] Armellini D, von Fraunhofer JA. The Shortened Dental Arch: a Review of the Literature. *Journal of Prosthetic Dentistry* 2004;92(6):531-5.
- [26] Preoteasa E, Imre M, Preoteasa CT. A 3-Year Follow-up Study of Overdentures Retained by Mini-Dental Implants. *The International Journal of Oral & Maxillofacial Implants* 2014; 29(5): 1034-41.
- [27] Diz P, Scully C, Sanz M. Dental Implants in the Medically Compromised Patient. *Journal of Dentistry* 2013;41(3):195-206.
- [28] Gomez-de Diego R, Mang-de la Rosa M, Romero-Pérez MJ, Cutando-Soriano A, Lopez-Valverde-Centeno A. Indications and Contraindications of Dental Implants in Medically Compromised Patients: Update. *Medicina Oral Patologia Oral y Cirugia Bucal* 2014;19(5):e483-9.
- [29] Attard NJ, Zarb GA, Laporte A. Long-Term Treatment Costs Associated with Implant-Supported Mandibular Protheses in Edentulous Patients. *The International Journal of Prosthodontics* 2005;18(2):117-23.
- [30] Misch CE. *Contemporary Implant Dentistry* 2<sup>nd</sup> edition. St. Louis: Mosby Inc; 1999.
- [31] Al-Ansari A. No Difference Between Splinted and Unsplinted Implants to Support Overdentures. *Journal of Evidence Based Dental Practice* 2012;13(2):54-5.
- [32] Preoteasa E, Meleşcanu-Imre M, Preoteasa CT, Marin M, Lerner H. Aspects of Oral Morphology as Decision Factors in Mini-Implant Supported Overdenture. *Romanian Journal of Morphoogy and Embryology* 2010;51(2): 309-14.
- [33] Kreisler M, Behneke N, Behneke A, d'Hoedt B. Residual Ridge Resorption in the Edentulous Maxila in Patients With Implant-Supported Mandibular Overdentures: An 8-Years Retrospective Study. *International Journal of Prosthodontics* 2003;16(3): 265-300.
- [34] Al-Faraje L. *Oral Implantology Surgical Procedures-Quintessence Checklist Series*. Quintessence Publishing Co; 2013.
- [35] Al-Faraje L. *Surgical Complications in Oral Implantology Etiology, Prevention, and Management*. Quintessence Publishing Co, 2011.
- [36] Esposito M, Grusovin MG, Chew YS, Coulthard P, Worthington HV. One-Stage versus Two-Stage Implant Placement. A Cochrane Systematic Review of Randomised Controlled Clinical Trials. *European Journal of Oral Implantology* 2009;2(2):91-9.
- [37] Elsyad MA, Gebreel AA, Fouad MM, Elshoukouki AH. The Clinical and Radiographic Outcome of Immediately Loaded Mini Implants Supporting a Mandibular Overdenture. A 3-year Prospective Study. *Journal of Oral Rehabilitation* 2011;38(11): 827-34.
- [38] Tadić A, Mirković S, Petronijević B, Knezević MJ. Stabilisation of Lower Denture Using Mini Dental Implants. *Medicinski pregled* 2012;65(9-10):405-8.



- [39] Scepanovic M, Calvo-Guirado JL, Markovic A, Delgado-Ruiz R, Todorovic A, Milić B, Misic T. A 1-year Prospective Cohort Study on Mandibular Overdentures Retained by Mini Dental implants. *European Journal of Oral Implantology* 2012;5(4): 367-79.
- [40] Preoteasa CT, Nabil Sultan A, Popa L, Ionescu E, Iosif, L, Ghica, MV, Preoteasa E. Wettability of Some Dental Materials. *Optoelectronics and Advanced Materials – Rapid Communications* 2011; 5(8): 874-8.
- [41] Massad JJ1, Ahuja S, Cagna D. Implant Overdentures: Selections for Attachment Systems. *Dentistry Today* 2013;32(2):128, 130-2.
- [42] Walton JN, MacEntee MI. Problems with Prostheses on Implants: a Retrospective Study. *Journal of Prosthetic Dentistry* 1994;71(3):283-8.

IntechOpen

