

# We are IntechOpen, the world's leading publisher of Open Access books Built by scientists, for scientists

6,900

Open access books available

185,000

International authors and editors

200M

Downloads

Our authors are among the

154

Countries delivered to

TOP 1%

most cited scientists

12.2%

Contributors from top 500 universities



WEB OF SCIENCE™

Selection of our books indexed in the Book Citation Index  
in Web of Science™ Core Collection (BKCI)

Interested in publishing with us?  
Contact [book.department@intechopen.com](mailto:book.department@intechopen.com)

Numbers displayed above are based on latest data collected.  
For more information visit [www.intechopen.com](http://www.intechopen.com)



---

# **The Role of Advanced Endoscopy in Management of Acute Pancreatitis**

---

Charing Ching Ning Chong,  
Anthony Yuen Bun Teoh, Paul Bo San Lai,  
James Yun Wong Lau and Francis Ka Leung Chan

Additional information is available at the end of the chapter

<http://dx.doi.org/10.5772/58975>

---

## **1. Introduction**

Acute pancreatitis is the inflammation of the pancreas as a result of pre-mature activation of the pancreatic enzymes leading to auto-digestion and inflammation.

The Atlanta's classification is the most commonly used classification of acute pancreatitis. [1] It defines acute pancreatitis as acute inflammation of the pancreas which is further classified into mild, moderate and severe forms. Mild acute pancreatitis refers to an attack with no organ dysfunction, local or systemic complications and usually resolves in the first week. Moderately severe acute pancreatitis is defined by the presence of transient organ failure, local complications or exacerbation of co-morbid disease. Severe acute pancreatitis is associated with persistent organ failure, with or without local complications, for more than 48 hours. Local complications include peripancreatic fluid collections, pancreatic and peripancreatic necrosis (sterile or infected), pseudocyst and walled-off necrosis (sterile or infected).

The majority of patients suffer from mild disease but around 20% may suffer from severe disease with local and systemic complications. [2, 3] The use of advanced endoscopy is dramatically changing the management of these patients. Although morbidity and mortality is usually encountered in the group with severe pancreatitis,, it is wise to treat every patient aggressively until disease severity has been established. The goals of initial management are fluid replacement, electrolyte balance, caloric support, and prevention of local and systemic complications.

Gallstone is the leading cause of pancreatitis and accounts for 30-60% of patients in most series. [4-8] Endoscopic retrograde cholangiopancreatography (ERCP) is most helpful in patients

with incarcerated bile duct stones and concomitant cholangitis and pancreatic ductal disruption. Endoscopic ultrasound (EUS) guided therapy is replacing surgery in the management of pancreatic fluid collections.

## 2. Role of early endoscopic retrograde cholangiopancreatography

Acute biliary pancreatitis is believed to result from transient obstruction of the common bile duct (CBD). [6-8] The majority of stones will pass out spontaneously. However, some patients will suffer from persistent obstruction and the duration of CBD obstruction is believed to be a critical factor contributing to the severity of pancreatitis. [6] In patients suffering from acute cholangio-pancreatitis, ERCP may provide drainage and relieve the obstruction caused by the presence of a persistent common bile duct stone.

Two early meta-analyses summarized the outcomes from 4 initial randomized trials. [9, 10] The results were controversial. (Table 1) The results from the United Kingdom and Hong Kong studies showed that early ERCP reduced the odds of having complications in patients with predicted severe disease. [11, 12] However, the effect was not significant in mild disease and the reduction in mortalities was also not significant. On the other hand, the Germany study, which only included patients with acute pancreatitis without obstructive jaundice, showed no significant differences in mortalities and morbidities in both groups. [13] The Polish study was the only study demonstrating the significant reduction in mortalities and morbidities in both mild and severe disease. However, the results of this study should be reviewed with caution and the study was only published in abstract form. [14]

After that, two more randomized studies had shown that ERCP in patients without biliary obstruction and cholangitis offered no benefit. [15, 16] These results were included in two more recent meta-analyses which showed that early ERCP in patients with biliary pancreatitis without acute cholangitis did not result in reduced risk of local pancreatic complications, overall complications and mortalities. [17, 18] The Dutch Acute Pancreatitis Study Group had performed a prospective, multicenter study on 153 patients with predicted severe acute biliary pancreatitis without cholangitis who were randomized to conservative treatment or ERCP within 72 hours after symptom onset. [19] Patients without and with cholestasis and/or dilated common bile duct were analyzed separately. They found that early ERCP was only beneficial to the cholestasis group by lowering the complications rate.

The current AGA guideline on gallstone pancreatitis is that, urgent ERCP should be performed in patients with concomitant cholangitis and this should be done within 24 hours after admission. [20] While in patients with high suspicion of a persistent common bile duct stone, early ERCP should be performed within 72 hours after admission. A numbers of studies have attempted to look at the predictive value of ultrasound, biochemical or clinical factors in patients with low to intermediate probability of ductal stones. [21-25] Where used in isolation, these factors all suffer from low sensitivity. However, when used in combination, the variables can help the clinician predict the probability of the presence a CBD stone.

	United Kingdom [11]	Hong Kong [12]	Germany [13]	Poland [14]
No. of patients	121	195	238	280
Timing of ERCP	<72 hours	<24 hours	<72 hours	<24 hours
Inclusion	Acute pancreatitis	Acute pancreatitis	Acute pancreatitis without obstructive jaundice	Acute pancreatitis
Intervention	ERCP +/- ES	ERCP +/- ES	ERCP +/- ES	ERCP +/- ES
Reduction in mortality	18% vs 4% (P = NA), (Severe group)	18% vs 3% (P = NA) (Severe group)	NS	13% vs 2% (P<0.001)
Reduction in morbidity	61% vs 24% (P = NA) (Severe group)	54% vs 13% (P = NA) (Severe group)	NS	36% vs 17% (P<0.001)
Other significant outcomes	Reduction in hospital stay (Severe group)	/	No difference between mild and severe group	Reduction in both mild and severe groups

ERCP: Endoscopic Retrograde Cholangiopancreatography; ES: Endoscopic Sphincterotomy;

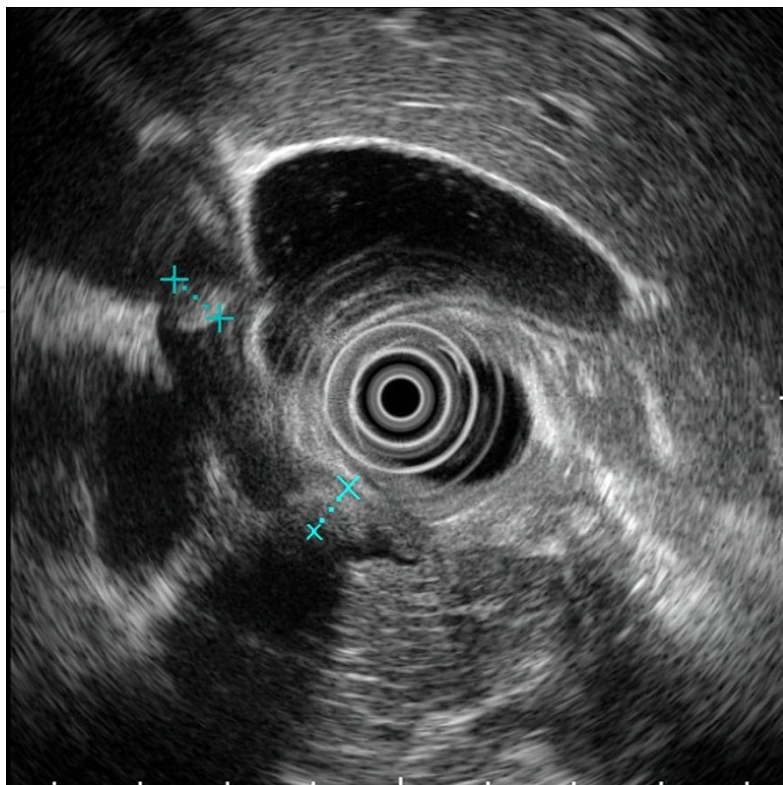
NA: Not Available; NS: Not Significant

**Table 1.** Outcomes from Initial Randomized Trials

### 3. Who to perform endoscopic ultrasound on?

Endoscopic Ultrasound (EUS) combines endoscopic visualization with 2-dimensional ultrasound and is well suited for biliary imaging given the close proximity of the extrahepatic bile duct to the proximal duodenum. (Figure 1) Both radial and linear array echo-endoscopes are excellent in detecting common bile duct stones, with a reported sensitivity of 89% to 94% and specificity of 94% to 95%. [26, 27] The benefit of EUS would be most pronounced in patients with intermediate probability of CBD stones. The advantages include the avoidance of the risk associated with a diagnostic ERCP and ERCP can be performed in the same session if stones were detected. [28]

Two meta-analyses have showed that both EUS and magnetic resonance cholangiopancreatography (MRCP) demonstrated excellent efficacy in diagnosing choledocholithiasis. [26, 27] The reported pooled sensitivity and specificity were around 90% for EUS and >95% for MRCP. Furthermore, the use of EUS to select patients for therapeutic ERCP has a significantly lower risk of complications as compared to performing diagnostic ERCP for detecting CBD stones.



**Figure 1.** Endoscopic Ultrasound Image of Two Stones in Common Bile Duct

#### 4. Pancreatic pseudocyst

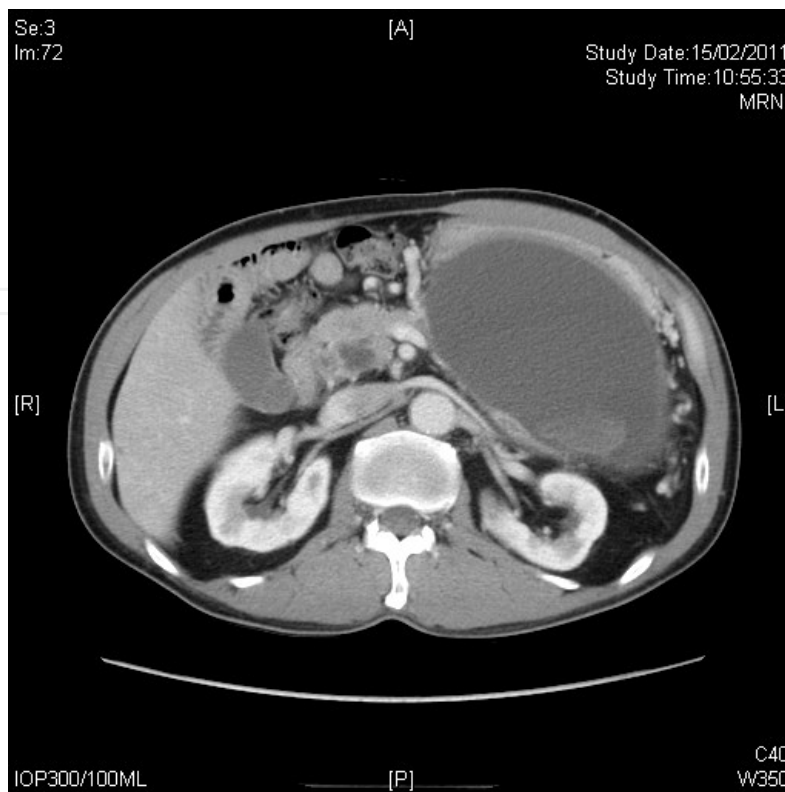
It is estimated that 15 to 30% of patients will suffer from severe pancreatitis that is characterized by the presence of local complications including pancreatic necrosis, pseudocyst and abscess and organ failure. [20]

Pancreatic pseudocyst is a collection of pancreatic juice enclosed by a wall of fibrous or granulation tissue, occurring at least 4 weeks after the onset of symptoms. (Figure 2) Clinical presentation of pseudocysts varies, ranging from asymptomatic to life threatening condition. Intervention is indicated if patients are symptomatic, suffering from complications, with size greater than > 6 cm, increasing in size or if it does not resolve after 6 weeks.

When compared with surgery and percutaneous methods, endoscopic drainage of pseudocyst is less invasive with decreased risk of morbidities. It can also provide direct access to the cyst.

Endoscopic drainage of pseudocyst can be performed under esophagogastroduodenoscopy (EGD) or EUS guidance. An EGD-guided puncture is essentially a blind procedure, as this requires bulging of cyst into the stomach for localization. Furthermore, there is a risk of bleeding from interposed vessels and also mal-positioning of the stents during the procedure. EUS overcomes these difficulties and has been shown by two randomized studies to be associated with higher rates of success (100% vs 33% & 94% vs 72%) with comparable morbidities. [29, 30]



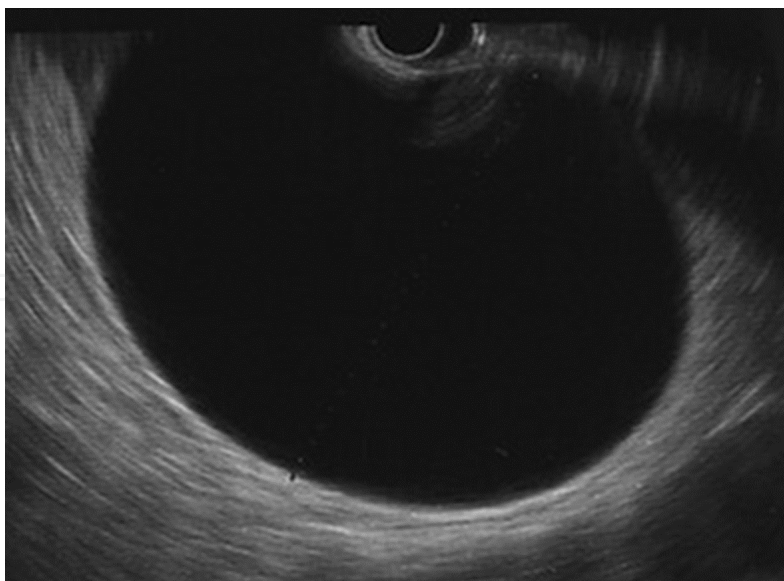


**Figure 2.** CT film demonstrating the presence of an 8cm pseudocyst located at the pancreatic tail region.

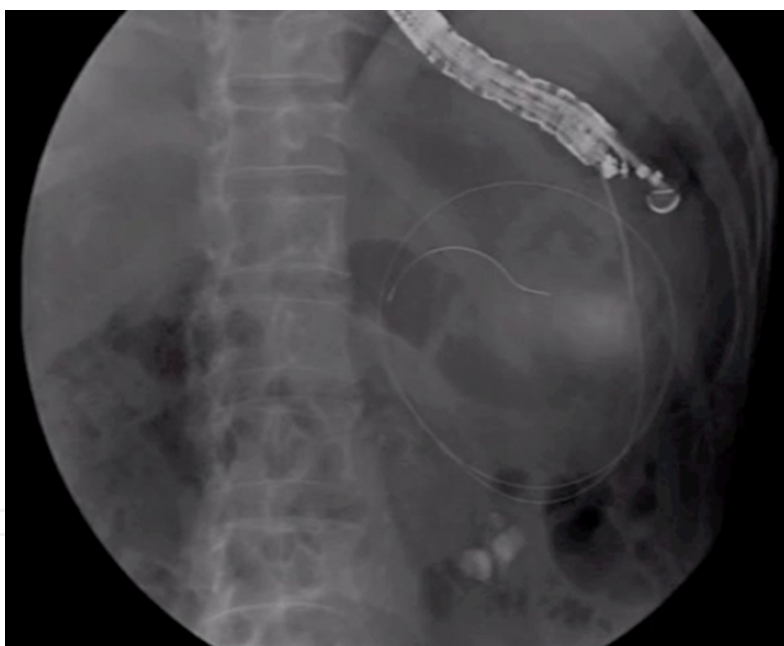The outcomes of EUS-guided pseudocyst drainage were reported in a number of studies. [31-35] A high success rate ranging from 82 to 94% with an acceptable complication rate of 9.1 to 33.3% were reported. These studies demonstrated the feasibility and efficacy of the procedure.

Endoscopic drainage of pseudocyst is usually performed with combined EUS and fluoroscopy guidance. EUS is first used to identify the optimal site of puncture that is free of intervening vascular structures. (Figure 3) The pseudocyst is then punctured with a 19-gauge needle and the track dilated with a needle knife or cystotome. A guide-wire (or double guidewires) is then advanced via the needle under fluoroscopic control. At least two loops should be formed before the needle was withdrawn to prevent dislodgement of guidewire during manipulation. A cysto-gastrostomy is then created and dilated to 6-8mm. Two or more double pigtail stents is then inserted. (Figure 4)

The results of 20 EUS cysto-gastrostomies were compared with 10 surgical cysto-gastrostomies in a retrospective review. The success rate, complication rate and re-intervention rate were similar in both groups. The author concluded that EUS-guided cysto-gastrostomy, should be considered as first-line treatment because of a lower cost and shorter hospital stay, with no difference in clinical outcomes. [36] A recent randomized trial comparing endoscopic and surgical cysto-gastrostomy for pancreatic pseudocyst drainage also produced similar results. [37] Varadarajulu et al showed that endoscopic treatment was associated with shorter hospital stays, better physical and mental health of patients, and lower cost.



**Figure 3.** Picture of Pancreatic Pseudocyst by Linear Endoscopic Ultrasound (EUS)



**Figure 4.** Fluoroscopic Picture of EUS-guided Drainage of Pancreatic Pseudocyst Showing the Guidewire Forming Loops within the Pseudocyst.

## 5. Forward-viewing vs oblique-viewing EUS in drainage of pseudocyst

Conventional echoendoscopes are oblique viewing devices and the angle of the instrument channel results in tangential puncturing of the pseudocyst. This may lead to inadequate

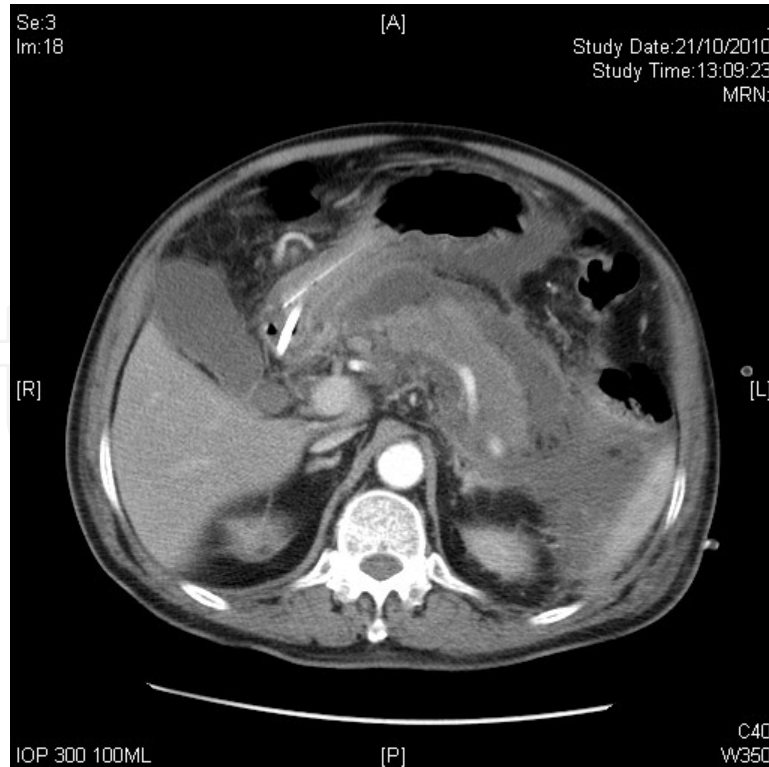
transmission of force during insertion of the stents. Furthermore, re-cannulation of an angulated track for multiple stent insertion may be difficult after tangential puncturing.

Recently, forward-viewing echoendoscopes have become available. This device allows forward sonographic imaging, with an axis for puncturing and insertion of stents being parallel to the direction of the scanning plane. In contrast to the oblique-viewing device where tangential puncturing results in an angulated track, the forward-viewing endoscope allows for insertion of the needle along the same plane as the direction of scanning.

Voermans et al studied the performance of forward viewing versus oblique viewing EUS in drainage of pseudocyst under a multi-centered setting. [38] Four tertiary centers and 58 patients with pseudocyst greater than 6cm in size were recruited. There were no differences in the procedural time, ease of the procedure, morbidities and success rates.

## 6. Pancreatic necrosis and abscess

Pancreatic necrosis is characterized by diffuse or focal areas of non-viable pancreatic parenchyma, which is typically associated with peri-pancreatic fat necrosis. Radiologically, it is defined as non-enhanced pancreatic parenchyma greater 3 cm or when more than 30% of the area of the pancreas is involved on the computed tomography. (Figure 5)

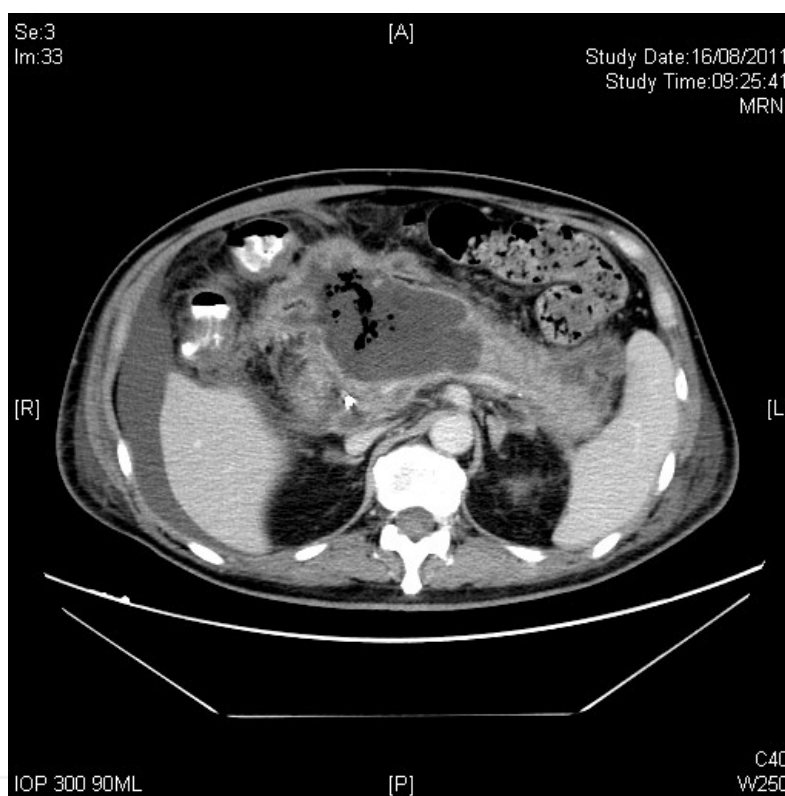


**Figure 5.** This CT film of a patient with pancreatic necrosis characterized by non-enhanced pancreatic parenchyma.



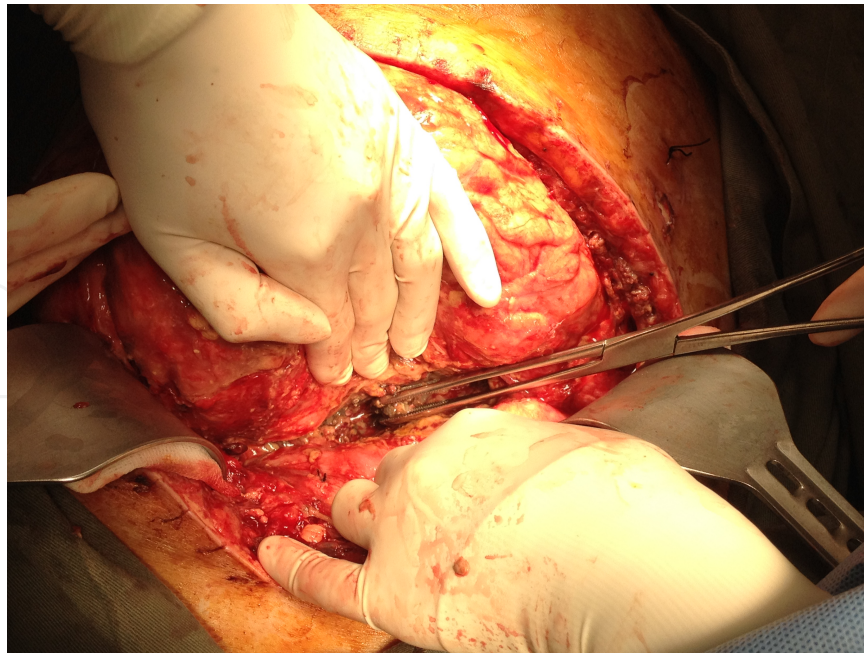
The presence of a sterile necrosis is not an indication for necrosectomy. However, if patients develop worsening symptoms and deteriorating clinical condition, infected necrosis should be suspected. Fine-needle aspiration of the collection should be performed. The sample should be cultured and gram stained to document infection and necrosectomy is indicated in those with documented infection.

Pancreatic abscess is a circumscribed, intra-abdominal collection of pus containing little or no pancreatic necrosis, which arises as a consequence of acute pancreatitis or pancreatic trauma. (Figure 6)



**Figure 6.** CT scan of a patient suffering from pancreatic abscess as evident by the presence of a fluid collection at the neck of the pancreas and associated air locules.

For the treatment of pancreatic necrosis, open necrosectomy was once considered as the standard definitive treatment. (Figure 7) However, it was associated with many problems such as intraoperative collateral tissue damage, bleeding, worsening organ failure due to surgical trauma, multiple operations, stormy postoperative course, lengthy stay in the intensive care unit, incisional hernias, new-onset diabetes, and for the use of pancreatic enzymes, with a high morbidity up to 95%. [39-42] The mortality of open necrosectomy is high, almost 40-75%, particularly if performed early. [40, 43]



**Figure 7.** Operative picture of open necrosectomy showing the necrotic materials being removed by the forceps.

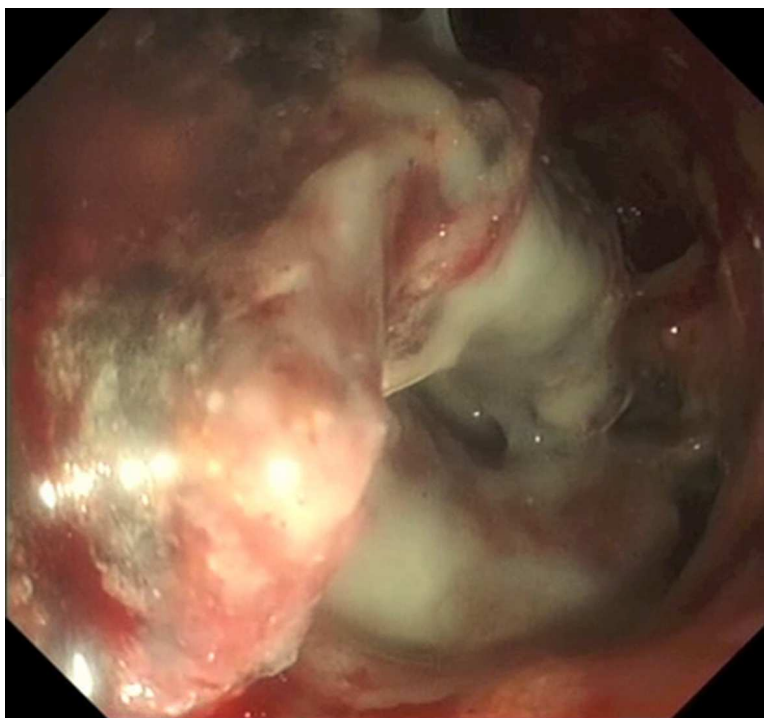
## 7. Endoscopic necrosectomy

Recently, pancreatic necrosectomy has been performed by the endoscopic approach. [44, 45] This was achieved by either the percutaneous retroperitoneal approach or the transgastric approach. Endoscopic approach has been in favor, as it leads to reduced inflammatory response and decreased complications. [46]

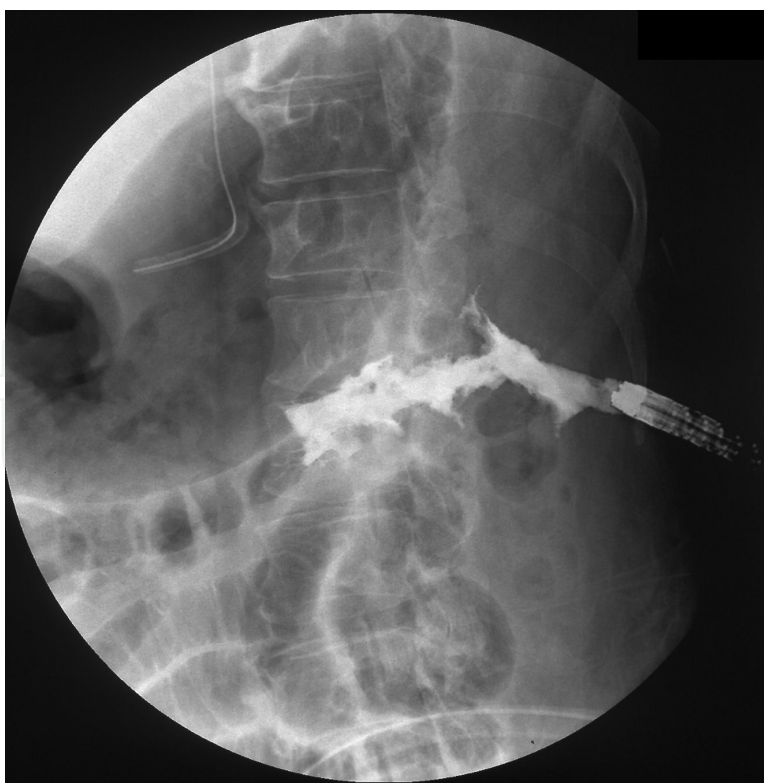
## 8. Percutaneous retroperitoneal approach

Percutaneous retroperitoneal pancreatic necrosectomy allows the use of high volume post-operative lavage that can be performed under local anesthesia. [47, 48] Percutaneous drainage was first achieved with ultrasound-guided pigtail insertion. The track was then dilated to allow for insertion of a 30Fr drain and this would be used later for introduction of a 9.8mm endoscope. On insertion of the endoscope, the necrotic pancreas was seen within the cavity with surrounding pus and turbid material. (Figure 8) The procedure could be done under fluoroscopic guidance. (Figure 9)

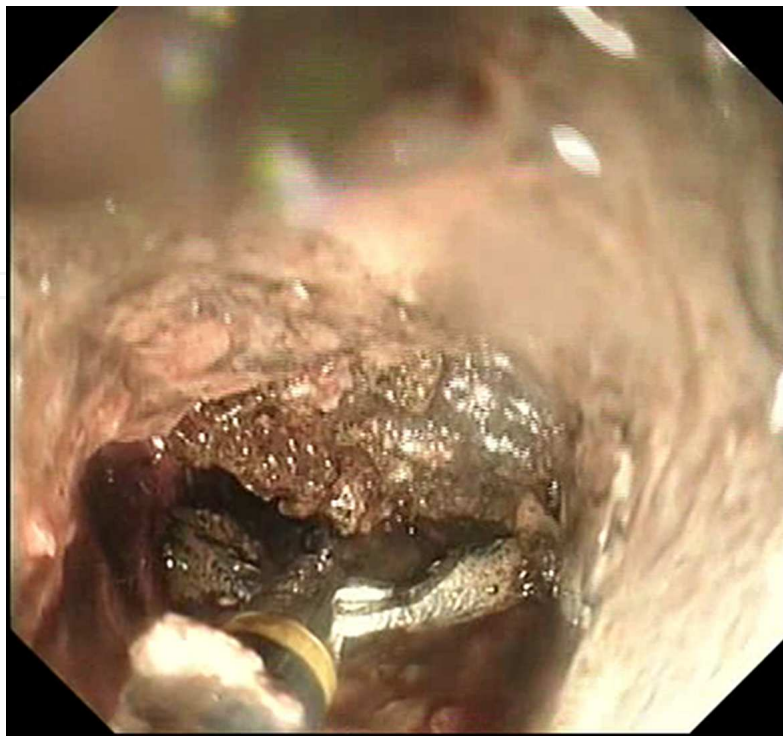
The cavity was irrigated generously with saline to flush out the material. Endoscopic necrosectomy was then performed to remove the necrotic pancreas. This could be performed with a number of accessories including forceps, snares or grasping forceps. (Figure 10) The loop snare allowed removal of larger pieces of necrotic material. The process should be repeated until all the necrotic materials were removed.



**Figure 8.** Endoscopic Picture of Pancreatic Necrosis



**Figure 9.** Fluoroscopic Image of Percutaneous Retroperitoneal Pancreatic Necrosectomy



**Figure 10.** Removal of Necrotic Materials with Grasping Forceps via Percutaneous Approach

## 9. Endoscopic transgastric approach

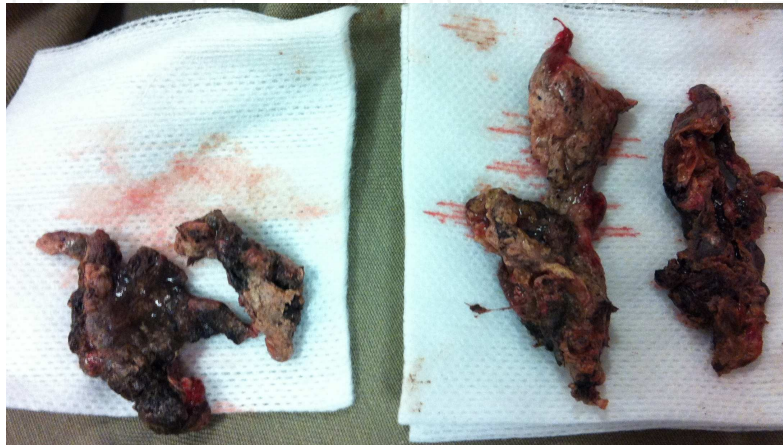The results and techniques of EUS transgastric drainage in walled off pancreatic necrosis were well reported. [49-52] The procedure begins with the insertion of stents under EUS guidance, followed by the dilation of the track to allow transmural introduction of the endoscope into the walled off pancreatic necrosis for necrosectomy. Repeated endoscopic debridement could be performed via the same route and it is indicated when there is lack of window for percutaneous drainage. Figure 10 showed the necrotic materials that were removed.

The transgastric approach can avoid the complications associated with the percutaneous approach including bleeding, visceral perforation and the risk of pancreatocutaneous fistula. Furthermore, the approach provides a more direct approach to the necrotic cavity. However, with this approach, one cannot monitor the output of the drainage material and also, the presence of a fistula may lead to possible contamination of the abscess cavity by gastrointestinal contents.

The outcomes of endoscopic necrosectomy were recently reviewed. [53] Between 1990 and 2009, 10 case series including 260 patients with 1100 endoscopic necrosectomies were performed. The overall mortality was 5% and the mean procedure-related morbidity was 27%. Bleeding was most common complication followed by exacerbation of sepsis and free perforation. Complete resolution of the pancreatic necrosis was achieved by endoscopic means alone in 76% of the patients.



In a Dutch multi-centred randomized study, 88 patients with infected necrotizing pancreatitis were randomized to endoscopic step-up approach or open necrosectomy. [54] In the endoscopic step-up approach, both the percutaneous left retroperitoneal and the transgastric routes were used. The step-up approach had shown a number of benefits, including significantly decreased rates of major complications, new-onset multi-organ failure and also the need for intensive care admission. In addition, the rates of incisional hernias and new-onset diabetes were also significantly reduced.



**Figure 11.** Pictures of Necrotic Materials Removed by Endoscopic Transgastric Approach

## 10. Retroperitoneal or transgastric approach for endoscopic necrosectomy

Currently, there is no study comparing which approach is superior. Both approaches are complementary with their respective benefits and risks. Their application will depend on the anatomical location of the collection and should be tailored according to the patient. Bleeding is the most common complication encountered. [54] It could happen during the dilatation of transmural tract debridement of necrotic materials. Care should be taken on necrosectomy as any trauma to blood vessels could result in catastrophic bleeding, especially if branches of the splenic artery or vein were injured. The use of EUS can enhance the identification of vascular structure and reduce the risk of bleeding.

## 11. Is irrigation necessary?

A number of studies have reported on the use of repeat endoscopic irrigation as a part of the treatment in endoscopic necrosectomy to improve outcomes. [49, 51, 55-61] (Table 2) It was performed via an external nasocystic or percutaneous drainage. Dissolution of necroses could be achieved through liquefying the necrotic material through constant flushing and drainage of debris. On the other hand, Jurgensen et al found that neither endoscopic nor external



flushing was needed for successful endoscopic treatment for symptomatic necroses once they were grossly cleared mechanically by endoscopy and the discomfort from the use of nasocystic or percutaneous drainage could be avoided. [62] Stenting alone demonstrated good short-and long-term results. It can lead to avoidance of repeated and lengthy procedures, immediate mobilization, better tolerance by patients and potential reduction of hospital stay.

Reference (year)	N	Mortality / Surgery	Mean no. of Endoscopies for endoscopic necrosectomy and lavage (range)	Use of Irrigation
Seewald (2005) [49]	10	0/4	23.6 (4-64)	Endoscopic 13/13 Nasocystic 12/13
Charnley (2006) [55]	13	2/4	4 (1-6)	Endoscopic 13/13 Nasocystic 5/13
Papchristou (2007) [51]	22	1/NS	3 (1-12)	Nasocystic 22/22
Voermans (2007) [59]	25	0/2	1.7 (1-4)	Nasocystic 20/25
Escourror (2008) [56]	13	0/0	1.8 (1-3)	Endoscopic 13/13 Nasocystic 13/13
Hocke (2008) [58]	19	2/2	NS	Endoscopic 19/19
Coelho (2008) [60]	36	2/6	4 (2-8)	Endoscopic 36/36
Gardner (2009) [57]	17	0/1	2.2 (NS)	Nasocystic 14/17
Seifert (2009) [61]	93	7/11	NS	NS
Jurgensen (2012) [62]	35	2/0	2.9 (1-11)	None

NS: Not Specified

**Table 2.** Summary of Studies (with more than 10 patients) on Endoscopic Irrigation With Regard of Outcomes

## 12. Is immediate necrosectomy necessary for infected pancreatic necrosis?

While various guidelines have advocated surgical necrosectomy for patients with infected pancreatic necrosis, [63, 64] the issue of conservative versus surgical treatment for infected pancreatic necrosis has been intensely debated. [65] Current evidence suggests that conservative treatment might be successful for infected pancreatic necrosis in a proportion of patients. [66-71] In the recent decades, a number of case series and comparative trials, as well as a meta-analysis, have shown that primary conservative treatment could be successful for infected pancreatic necrosis. [66-68, 72-76] (Table 3) However, patient selection bias and/or publication bias in these case series, which have shown a successful outcome following conservative treatment for infected pancreatic necrosis, could be taken into account when interpreting these results. Mouli et al, in a systemic review and meta-analysis, analyzed 8 studies that have reported conservative treatment as the initial and primary treatment for all consecutive patients with infected necrosis to minimize these biases. [76] They found that conservative management was successful for 64% of patients (95% confidence interval, 51%–78%) and mortality was 12% (95% confidence interval, 6%–18%). Among 324 patients included, 26% of

patients required necrosectomy or additional surgery for complications (95% confidence interval, 15%–37%).

Conservative treatment for infected pancreatic necrosis should include intensive care with full organ support, use of effective antimicrobials, and aggressive nutritional support. Percutaneous drainage, despite it is a form of intervention and not truly conservative, has also been considered a part of conservative treatment because it does not involve surgery or formal necrosectomy in some of the reported studies. [77-80]

Reference (year)	No. of patients with infected pancreatic necrosis on conservative treatment	Patients undergoing percutaneous drainage (%)	Successful conservative treatment (%)	Need for surgery (%)	Median/ mean hospital stay (days)	Mortality (%)
©Freeny (1998) [77]	34	100 (34/34)	47.1 (16/34)	52.9 (18/34)	45	11.8 (4/34)
Runzi (2005) [68]	28	18.75 (3/16) #	50 (14/28)	42.9 (12/28)	54 ± 10 *	14.3 (4/28)
Song (2006) [72]	19	NR	78.9 (15/19)	21.1 (4/19)	70	5.3 (1/19)
©Navalho (2006) [78]	30	100 (30/30)	63.3 (19/30)	33.3 (10/30)	24	16.6 (5/30)
Lee (2007) [67]	31	67.7 (21/31)	71 (22/31)	12.9 (4/31)	37.7 ± 28.5 *	3.2 (1/31)
©Bruennler (2008) [79]	80	100 (80/80)	47.5 (38/80)	20 (16/80)	51	33.8 (27/80)
©Mortele (2009) [80]	13	100 (13/13)	46.2 (6/13)	53.8 (7/13)	33	7.7 (1/13)
Garg (2010) [66]	77	45.45 (35/77)	54.4 (42/77)	23.4 (18/77)	26.5	28.6 (22/77)
Van Santvoort (2010) [54]	43	95.3 (41/43)	34.9 (15/43)	60.4 (26/43)	50	18.6 (8/43)
Zerem (2011) [73]	86	80.2 (69/86)	84.9 (73/86)	12.8 (11/86)	13	9.3 (8/86)
Gluck (2012) [74]	20	100 (20/20)	70 (14/20)	15 (3/20)	54	15 (3/20)
Alsasser (2012) [75]	20	50 (10/20)	65 (13/20)	30 (6/20)	NR	5 (1/20)

© Studies reported the results of only those patients who underwent percutaneous drainage for the management of infected pancreatic necrosis

# Eliminated 12 patients required surgical treatment

\* Data expressed in mean ± standard deviation NR: Not Reported

**Table 3.** Outcomes of Patients with Infected Pancreatic Necrosis Receiving Primary Conservative Management

The principle for the indication necrosectomy is shifting from infection-based to organ failure- or complication-based. While conservative-first approach is a reasonable approach for the management of infected pancreatic necrosis, it is important to recognize those patients might require necrosectomy later as a step-up therapy at an appropriate time. [76] Indications for necrosectomy include nonresponse to conservative treatment and development of local

complications such as bleeding and colonic perforation. Extend and infection of pancreatic necrosis correlated with the development of organ failure and mortality in acute pancreatitis. [81,82] Large amount of thick necrotic debris at difficult-to-drain locations and resistant organisms could be the reasons for failure of conservative therapy. Two studies sought to identify the predictive factors for the need for early surgery. Zerem et al showed that Ranson, Glasgow, and APACHE II scores, CTSI, and C-reactive protein could predict the need for surgery in their patients, but the 95% confidence interval showed that none of the factors were found to be a significant predictor. [73] Garg et al showed that high APACHE II score and serum creatinine level were predictive of mortality. [66] Unfortunately, no predictive factor that could guide a clinician to move towards early surgical intervention was identified in the currently available studies.

### 13. Conclusion

In conclusion, the use of advanced endoscopy is dramatically changing the management of patients with acute pancreatitis. With continued advancement of technology, there is a diminishing need for open surgical intervention. Management of these patients is best under a multidisciplinary team consisting of gastroenterologists, radiologists and surgeons.

### Author details

Charing Ching Ning Chong<sup>1\*</sup>, Anthony Yuen Bun Teoh<sup>1</sup>, Paul Bo San Lai<sup>1</sup>,  
James Yun Wong Lau<sup>1,2</sup> and Francis Ka Leung Chan<sup>2</sup>

\*Address all correspondence to: [chongcn@surgery.cuhk.edu.hk](mailto:chongcn@surgery.cuhk.edu.hk)

1 Department of Surgery, Prince of Wales Hospital, the Chinese University of Hong Kong, SAR

2 Institute of Digestive Disease, Prince of Wales Hospital, the Chinese University of Hong Kong, SAR

### References

- [1] Banks PA, Bollen TL, Dervenis C, Gooszen HG, Johnson CD, Sarr MG, et al. Classification of acute pancreatitis--2012: revision of the Atlanta classification and definitions by international consensus. *Gut*. 2013;62(1):102-11.

- [2] van Santvoort HC, Bakker OJ, Bollen TL, Besselink MG, Ahmed Ali U, Schrijver AM, et al. A conservative and minimally invasive approach to necrotizing pancreatitis improves outcome. *Gastroenterology*. 2011;141(4):1254-63.
- [3] Lankisch PG. Natural course of acute pancreatitis: what we know today and what we ought to know for tomorrow. *Pancreas*. 2009;38(5):494-8.
- [4] Andersson R, Andersson B, Haraldsen P, Drewsen G, Eckerwall G. Incidence, management and recurrence rate of acute pancreatitis. *Scandinavian journal of gastroenterology*. 2004;39(9):891-4.
- [5] Malecka-Panas E, Juszynski A, Wilamski E. The natural course of acute gallstone pancreatitis. *Materia medica Polona Polish journal of medicine and pharmacy*. 1996;28(1):8-12.
- [6] Acosta JM, Rubio Galli OM, Rossi R, Chinellato AV, Pellegrini CA. Effect of duration of ampullary gallstone obstruction on severity of lesions of acute pancreatitis. *Journal of the American College of Surgeons*. 1997;184(5):499-505.
- [7] Runzi M, Saluja A, Lerch MM, Dawra R, Nishino H, Steer ML. Early ductal decompression prevents the progression of biliary pancreatitis: an experimental study in the opossum. *Gastroenterology*. 1993;105(1):157-64.
- [8] Senninger N, Moody FG, Coelho JC, Van Buren DH. The role of biliary obstruction in the pathogenesis of acute pancreatitis in the opossum. *Surgery*. 1986;99(6):688-93.
- [9] Sharma VK, Howden CW. Metaanalysis of randomized controlled trials of endoscopic retrograde cholangiography and endoscopic sphincterotomy for the treatment of acute biliary pancreatitis. *The American journal of gastroenterology*. 1999;94(11):3211-4.
- [10] Ayub K, Imada R, Slavin J. Endoscopic retrograde cholangiopancreatography in gallstone-associated acute pancreatitis. *The Cochrane database of systematic reviews*. 2004(4):CD003630.
- [11] Neoptolemos JP, Carr-Locke DL, London NJ, Bailey IA, James D, Fossard DP. Controlled trial of urgent endoscopic retrograde cholangiopancreatography and endoscopic sphincterotomy versus conservative treatment for acute pancreatitis due to gallstones. *Lancet*. 1988;2(8618):979-83.
- [12] Fan ST, Lai EC, Mok FP, Lo CM, Zheng SS, Wong J. Early treatment of acute biliary pancreatitis by endoscopic papillotomy. *The New England journal of medicine*. 1993;328(4):228-32.
- [13] Folsch UR, Nitsche R, Ludtke R, Hilgers RA, Creutzfeldt W. Early ERCP and papillotomy compared with conservative treatment for acute biliary pancreatitis. The German Study Group on Acute Biliary Pancreatitis. *The New England journal of medicine*. 1997;336(4):237-42.

- [14] Nowak A, Nowakowska-Dulawa E, Marek TA, Rybicka J. Final results of the prospective, randomized, controlled study on endoscopic sphincterotomy versus conventional management in acute biliary pancreatitis (abstract). *Gastroenterology* 1995;108:A380.
- [15] Acosta JM, Katkhouda N, Debian KA, Groshen SG, Tsao-Wei DD, Berne TV. Early ductal decompression versus conservative management for gallstone pancreatitis with ampullary obstruction: a prospective randomized clinical trial. *Annals of surgery*. 2006;243(1):33-40.
- [16] Oria A, Cimmino D, Ocampo C, Silva W, Kohan G, Zandalazini H, et al. Early endoscopic intervention versus early conservative management in patients with acute gallstone pancreatitis and biliopancreatic obstruction: a randomized clinical trial. *Annals of surgery*. 2007;245(1):10-7.
- [17] Petrov MS, Uchugina AF, Kukosh MV. Does endoscopic retrograde cholangiopancreatography reduce the risk of local pancreatic complications in acute pancreatitis? A systematic review and metaanalysis. *Surgical endoscopy*. 2008;22(11):2338-43.
- [18] Petrov MS, van Santvoort HC, Besselink MG, van der Heijden GJ, van Erpecum KJ, Gooszen HG. Early endoscopic retrograde cholangiopancreatography versus conservative management in acute biliary pancreatitis without cholangitis: a meta-analysis of randomized trials. *Annals of surgery*. 2008;247(2):250-7.
- [19] van Santvoort HC, Besselink MG, de Vries AC, Boermeester MA, Fischer K, Bollen TL, et al. Early endoscopic retrograde cholangiopancreatography in predicted severe acute biliary pancreatitis: a prospective multicenter study. *Annals of surgery*. 2009;250(1):68-75.
- [20] American Gastroenterological Association Institute on "Management of Acute Pancreatitis" Clinical P, Economics C, Board AGAIG. AGA Institute medical position statement on acute pancreatitis. *Gastroenterology*. 2007;132(5):2019-21.
- [21] Barkun AN, Barkun JS, Fried GM, Ghitulescu G, Steinmetz O, Pham C, et al. Useful predictors of bile duct stones in patients undergoing laparoscopic cholecystectomy. McGill Gallstone Treatment Group. *Annals of surgery*. 1994;220(1):32-9.
- [22] Alponat A, Kum CK, Rajnakova A, Koh BC, Goh PM. Predictive factors for synchronous common bile duct stones in patients with cholelithiasis. *Surgical endoscopy*. 1997;11(9):928-32.
- [23] van Santvoort HC, Bakker OJ, Besselink MG, Bollen TL, Fischer K, Nieuwenhuijs VB, et al. Prediction of common bile duct stones in the earliest stages of acute biliary pancreatitis. *Endoscopy*. 2011;43(1):8-13.
- [24] Jovanovic P, Salkic NN, Zerem E, Ljuca F. Biochemical and ultrasound parameters may help predict the need for therapeutic endoscopic retrograde cholangiopancrea-



tography (ERCP) in patients with a firm clinical and biochemical suspicion for cholelithiasis. *European journal of internal medicine*. 2011;22(6):e110-4.

- [25] Sotoudehmanesh R, Kolahdoozan S, Asgari AA, Dooghaei-Moghaddam M, Ainechi S. Role of endoscopic ultrasonography in prevention of unnecessary endoscopic retrograde cholangiopancreatography: a prospective study of 150 patients. *Journal of ultrasound in medicine : official journal of the American Institute of Ultrasound in Medicine*. 2007;26(4):455-60.
- [26] Romagnuolo J, Bardou M, Rahme E, Joseph L, Reinhold C, Barkun AN. Magnetic resonance cholangiopancreatography: a meta-analysis of test performance in suspected biliary disease. *Annals of internal medicine*. 2003;139(7):547-57.
- [27] Garrow D, Miller S, Sinha D, Conway J, Hoffman BJ, Hawes RH, et al. Endoscopic ultrasound: a meta-analysis of test performance in suspected biliary obstruction. *Clinical gastroenterology and hepatology : the official clinical practice journal of the American Gastroenterological Association*. 2007;5(5):616-23.
- [28] Liu CL, Fan ST, Lo CM, Tso WK, Wong Y, Poon RT, et al. Comparison of early endoscopic ultrasonography and endoscopic retrograde cholangiopancreatography in the management of acute biliary pancreatitis: a prospective randomized study. *Clinical gastroenterology and hepatology : the official clinical practice journal of the American Gastroenterological Association*. 2005;3(12):1238-44.
- [29] Varadarajulu S, Christein JD, Tamhane A, Drelichman ER, Wilcox CM. Prospective randomized trial comparing EUS and EGD for transmural drainage of pancreatic pseudocysts (with videos). *Gastrointestinal endoscopy*. 2008;68(6):1102-11.
- [30] Park DH, Lee SS, Moon SH, Choi SY, Jung SW, Seo DW, et al. Endoscopic ultrasound-guided versus conventional transmural drainage for pancreatic pseudocysts: a prospective randomized trial. *Endoscopy*. 2009;41(10):842-8.
- [31] Vosoghi M, Sial S, Garrett B, Feng J, Lee T, Stabile BE, et al. EUS-guided pancreatic pseudocyst drainage: review and experience at Harbor-UCLA Medical Center. *MedGenMed : Medscape general medicine*. 2002;4(3):2.
- [32] Yasuda I, Iwata K, Mukai T, Iwashita T, Moriwaki H. EUS-guided pancreatic pseudocyst drainage. *Digestive endoscopy : official journal of the Japan Gastroenterological Endoscopy Society*. 2009;21 Suppl 1:S82-6.
- [33] Ahlawat SK, Charabaty-Pishvaian A, Jackson PG, Haddad NG. Single-step EUS-guided pancreatic pseudocyst drainage using a large channel linear array echoendoscope and cystotome: results in 11 patients. *JOP : Journal of the pancreas*. 2006;7(6):616-24.
- [34] Ang TL, Teo EK, Fock KM. EUS-guided drainage of infected pancreatic pseudocyst: use of a 10F Soehendra dilator to facilitate a double-wire technique for initial transgastric access (with videos). *Gastrointestinal endoscopy*. 2008;68(1):192-4.

- [35] Khashab MA, Lennon AM, Singh VK, Kalloo AN, Giday SA. Endoscopic ultrasound (EUS)-guided pseudocyst drainage as a one-step procedure using a novel multiple-wire insertion technique (with video). *Surgical endoscopy*. 2012;26(11):3320-3.
- [36] Varadarajulu S, Lopes TL, Wilcox CM, Drelichman ER, Kilgore ML, Christein JD. EUS versus surgical cyst-gastrostomy for management of pancreatic pseudocysts. *Gastrointestinal endoscopy*. 2008;68(4):649-55.
- [37] Varadarajulu S, Bang JY, Sutton BS, Trevino JM, Christein JD, Wilcox CM. Equal efficacy of endoscopic and surgical cystogastrostomy for pancreatic pseudocyst drainage in a randomized trial. *Gastroenterology*. 2013;145(3):583-90 e1.
- [38] Voermans RP, Ponchon T, Schumacher B, Fumex F, Bergman JJ, Larghi A, et al. Forward-viewing versus oblique-viewing echoendoscopes in transluminal drainage of pancreatic fluid collections: a multicenter, randomized, controlled trial. *Gastrointestinal endoscopy*. 2011;74(6):1285-93.
- [39] Buchler MW, Gloor B, Muller CA, Friess H, Seiler CA, Uhl W. Acute necrotizing pancreatitis: treatment strategy according to the status of infection. *Annals of surgery*. 2000;232(5):619-26.
- [40] Connor S, Alexakis N, Raraty MG, Ghaneh P, Evans J, Hughes M, et al. Early and late complications after pancreatic necrosectomy. *Surgery*. 2005;137(5):499-505.
- [41] Traverso LW, Kozarek RA. Pancreatic necrosectomy: definitions and technique. *Journal of gastrointestinal surgery : official journal of the Society for Surgery of the Alimentary Tract*. 2005;9(3):436-9.
- [42] Cirocchi R, Trastulli S, Desiderio J, Boselli C, Parisi A, Noya G, et al. Minimally invasive necrosectomy versus conventional surgery in the treatment of infected pancreatic necrosis: a systematic review and a meta-analysis of comparative studies. *Surgical laparoscopy, endoscopy & percutaneous techniques*. 2013;23(1):8-20.
- [43] Besselink MG, Verwer TJ, Schoenmaeckers EJ, Buskens E, Ridwan BU, Visser MR, et al. Timing of surgical intervention in necrotizing pancreatitis. *Archives of surgery*. 2007;142(12):1194-201.
- [44] Friedland S, Kaltenbach T, Sugimoto M, Soetikno R. Endoscopic necrosectomy of organized pancreatic necrosis: a currently practiced NOTES procedure. *Journal of hepato-biliary-pancreatic surgery*. 2009;16(3):266-9.
- [45] Bradley EL, 3rd, Dexter ND. Management of severe acute pancreatitis: a surgical odyssey. *Annals of surgery*. 2010;251(1):6-17.
- [46] Bakker OJ, van Santvoort HC, van Brunschot S, Geskus RB, Besselink MG, Bollen TL, et al. Endoscopic transgastric vs surgical necrosectomy for infected necrotizing pancreatitis: a randomized trial. *JAMA : the journal of the American Medical Association*. 2012;307(10):1053-61.

- [47] Connor S, Ghaneh P, Raraty M, Sutton R, Rosso E, Garvey CJ, et al. Minimally invasive retroperitoneal pancreatic necrosectomy. *Digestive surgery*. 2003;20(4):270-7.
- [48] Carter CR, McKay CJ, Imrie CW. Percutaneous necrosectomy and sinus tract endoscopy in the management of infected pancreatic necrosis: an initial experience. *Annals of surgery*. 2000;232(2):175-80.
- [49] Seewald S, Groth S, Omar S, Imazu H, Seitz U, de Weerth A, et al. Aggressive endoscopic therapy for pancreatic necrosis and pancreatic abscess: a new safe and effective treatment algorithm (videos). *Gastrointestinal endoscopy*. 2005;62(1):92-100.
- [50] Lopes CV, Pesenti C, Bories E, Caillol F, Giovannini M. Endoscopic-ultrasound-guided endoscopic transmural drainage of pancreatic pseudocysts and abscesses. *Scandinavian journal of gastroenterology*. 2007;42(4):524-9.
- [51] Papachristou GI, Takahashi N, Chahal P, Sarr MG, Baron TH. Peroral endoscopic drainage/debridement of walled-off pancreatic necrosis. *Annals of surgery*. 2007;245(6):943-51.
- [52] Seewald S, Ang TL, Teng KY, Groth S, Zhong Y, Richter H, et al. Endoscopic ultrasound-guided drainage of abdominal abscesses and infected necrosis. *Endoscopy*. 2009;41(2):166-74.
- [53] Haghshenasskashani A, Laurence JM, Kwan V, Johnston E, Hollands MJ, Richardson AJ, et al. Endoscopic necrosectomy of pancreatic necrosis: a systematic review. *Surgical endoscopy*. 2011;25(12):3724-30.
- [54] van Santvoort HC, Besselink MG, Bakker OJ, Hofker HS, Boermeester MA, Dejong CH, et al. A step-up approach or open necrosectomy for necrotizing pancreatitis. *The New England journal of medicine*. 2010;362(16):1491-502.
- [55] Charnley RM, Lochan R, Gray H, O'Sullivan CB, Scott J, Oppong KE. Endoscopic necrosectomy as primary therapy in the management of infected pancreatic necrosis. *Endoscopy*. 2006;38(9):925-8.
- [56] Escourrou J, Shehab H, Buscail L, Bournet B, Andrau P, Moreau J, et al. Peroral transgastric/transduodenal necrosectomy: success in the treatment of infected pancreatic necrosis. *Annals of surgery*. 2008;248(6):1074-80.
- [57] Gardner TB, Chahal P, Papachristou GI, Vege SS, Petersen BT, Gostout CJ, et al. A comparison of direct endoscopic necrosectomy with transmural endoscopic drainage for the treatment of walled-off pancreatic necrosis. *Gastrointestinal endoscopy*. 2009;69(6):1085-94.
- [58] Hocke M, Will U, Gottschalk P, Settmacher U, Stallmach A. Transgastral retroperitoneal endoscopy in septic patients with pancreatic necrosis or infected pancreatic pseudocysts. *Zeitschrift fur Gastroenterologie*. 2008;46(12):1363-8.

- [59] Voermans RP, Veldkamp MC, Rauws EA, Bruno MJ, Fockens P. Endoscopic transmural debridement of symptomatic organized pancreatic necrosis (with videos). *Gastrointestinal endoscopy*. 2007;66(5):909-16.
- [60] Coelho D, Ardengh JC, Eulalio JM, Manso JE, Monkemuller K, Coelho JF. Management of infected and sterile pancreatic necrosis by programmed endoscopic necrosectomy. *Digestive diseases*. 2008;26(4):364-9.
- [61] Seifert H, Biermer M, Schmitt W, Jurgensen C, Will U, Gerlach R, et al. Transluminal endoscopic necrosectomy after acute pancreatitis: a multicentre study with long-term follow-up (the GEPARD Study). *Gut*. 2009;58(9):1260-6.
- [62] Jurgensen C, Naser F, Boese-Landgraf J, Schuppan D, Stolzel U, Fritscher-Ravens A. Endoscopic ultrasound-guided endoscopic necrosectomy of the pancreas: is irrigation necessary? *Surgical endoscopy*. 2012;26(5):1359-63.
- [63] Working Party of the British Society of Gastroenterology, Association of Surgeons of Great Britain and Ireland, Pancreatic Society of Great Britain and Ireland, Association of Upper Gastroenterologists, et al. UK guidelines for the management of acute pancreatitis. *Gut*. 2005;54 Suppl 3:iii1-9.
- [64] Uhl W, Warshaw A, Imrie C, Bassi C, McKay CJ, Lankisch PG, et al. IAP Guidelines for the Surgical Management of Acute Pancreatitis. *Pancreatology : official journal of the International Association of Pancreatology*. 2002;2(6):565-73.
- [65] Connor S, Raraty MG, Neoptolemos JP, Layer P, Runzi M, Steinberg WM, et al. Does infected pancreatic necrosis require immediate or emergency debridement? *Pancreas*. 2006;33(2):128-34.
- [66] Garg PK, Sharma M, Madan K, Sahni P, Banerjee D, Goyal R. Primary conservative treatment results in mortality comparable to surgery in patients with infected pancreatic necrosis. *Clinical gastroenterology and hepatology : the official clinical practice journal of the American Gastroenterological Association*. 2010;8(12):1089-94 e2.
- [67] Lee JK, Kwak KK, Park JK, Yoon WJ, Lee SH, Ryu JK, et al. The efficacy of nonsurgical treatment of infected pancreatic necrosis. *Pancreas*. 2007;34(4):399-404.
- [68] Runzi M, Niebel W, Goebell H, Gerken G, Layer P. Severe acute pancreatitis: nonsurgical treatment of infected necroses. *Pancreas*. 2005;30(3):195-9.
- [69] Ramesh H, Prakash K, Lekha V, Jacob G, Venugopal A. Are some cases of infected pancreatic necrosis treatable without intervention? *Digestive surgery*. 2003;20(4):296-9; discussion 300.
- [70] Dubner H, Steinberg W, Hill M, Bassi C, Chardavoyne R, Bank S. Infected pancreatic necrosis and peripancreatic fluid collections: serendipitous response to antibiotics and medical therapy in three patients. *Pancreas*. 1996;12(3):298-302.

- [71] Adler DG, Chari ST, Dahl TJ, Farnell MB, Pearson RK. Conservative management of infected necrosis complicating severe acute pancreatitis. *The American journal of gastroenterology*. 2003;98(1):98-103.
- [72] Song JH, Seo DW, Byun SW, Koo DH, Bae JH, Lee SS, et al. [Outcome of intensive medical treatments in patients with infected severe necrotizing pancreatitis]. *The Korean journal of gastroenterology=Taehan Sohwagi Hakhoe chi*. 2006;48(5):337-43.
- [73] Zerem E, Imamovic G, Susic A, Haracic B. Step-up approach to infected necrotising pancreatitis: a 20-year experience of percutaneous drainage in a single centre. *Digestive and liver disease : official journal of the Italian Society of Gastroenterology and the Italian Association for the Study of the Liver*. 2011;43(6):478-83.
- [74] Gluck M, Ross A, Irani S, Lin O, Gan SI, Fotoohi M, et al. Dual modality drainage for symptomatic walled-off pancreatic necrosis reduces length of hospitalization, radiological procedures, and number of endoscopies compared to standard percutaneous drainage. *Journal of gastrointestinal surgery : official journal of the Society for Surgery of the Alimentary Tract*. 2012;16(2):248-56; discussion 56-7.
- [75] Alsfasser G, Schwandner F, Pertschy A, Hauenstein K, Foitzik T, Klar E. Treatment of necrotizing pancreatitis: redefining the role of surgery. *World journal of surgery*. 2012;36(5):1142-7.
- [76] Mouli VP, Sreenivas V, Garg PK. Efficacy of conservative treatment, without necrosectomy, for infected pancreatic necrosis: a systematic review and meta-analysis. *Gastroenterology*. 2013;144(2):333-40 e2.
- [77] Freeny PC, Hauptmann E, Althaus SJ, Traverso LW, Sinanan M. Percutaneous CT-guided catheter drainage of infected acute necrotizing pancreatitis: techniques and results. *AJR American journal of roentgenology*. 1998;170(4):969-75.
- [78] Navalho M, Pires F, Duarte A, Goncalves A, Alexandrino P, Tavora I. Percutaneous drainage of infected pancreatic fluid collections in critically ill patients: correlation with C-reactive protein values. *Clinical imaging*. 2006;30(2):114-9.
- [79] Bruennler T, Langgartner J, Lang S, Wrede CE, Klebl F, Zierhut S, et al. Outcome of patients with acute, necrotizing pancreatitis requiring drainage-does drainage size matter? *World journal of gastroenterology : WJG*. 2008;14(5):725-30.
- [80] Morteale KJ, Girshman J, Szejnfeld D, Ashley SW, Erturk SM, Banks PA, et al. CT-guided percutaneous catheter drainage of acute necrotizing pancreatitis: clinical experience and observations in patients with sterile and infected necrosis. *AJR American journal of roentgenology*. 2009;192(1):110-6.
- [81] Garg PK, Madan K, Pande GK, Khanna S, Sathyanarayan G, Bohidar NP, et al. Association of extent and infection of pancreatic necrosis with organ failure and death in acute necrotizing pancreatitis. *Clinical gastroenterology and hepatology : the official*



clinical practice journal of the American Gastroenterological Association. 2005;3(2):159-66.

- [82] Isenmann R, Rau B, Beger HG. Bacterial infection and extent of necrosis are determinants of organ failure in patients with acute necrotizing pancreatitis. The British journal of surgery. 1999;86(8):1020-4.

IntechOpen

IntechOpen

