

# We are IntechOpen, the world's leading publisher of Open Access books Built by scientists, for scientists

6,900

Open access books available

186,000

International authors and editors

200M

Downloads

Our authors are among the

154

Countries delivered to

TOP 1%

most cited scientists

12.2%

Contributors from top 500 universities



WEB OF SCIENCE™

Selection of our books indexed in the Book Citation Index  
in Web of Science™ Core Collection (BKCI)

Interested in publishing with us?  
Contact [book.department@intechopen.com](mailto:book.department@intechopen.com)

Numbers displayed above are based on latest data collected.  
For more information visit [www.intechopen.com](http://www.intechopen.com)



---

# Clinical Effects of Saireito for Patients with Advanced Stage Glioblastoma

---

Yasushi Shibata

Additional information is available at the end of the chapter

<http://dx.doi.org/10.5772/58979>

---

## 1. Introduction

Glioblastoma is the one of the most malignant brain tumors. The average survival of patients with glioblastoma is approximately one year, despite aggressive therapeutic efforts. Glioblastoma is associated with peritumoral brain edema. This brain edema is caused by tumor infiltration into the normal brain and breakdown of the blood brain barrier. Osmotic diuretics, like glycerol and mannitol, are frequently used to reduce brain edema. The effective duration of these osmotic diuretics is a few hours, so frequent intravenous infusions are required to control brain edema in these patients. Steroids are effective for repairing the damaged blood brain barrier. Therefore, the patients with advanced glioblastoma need to be administered long-term osmotic diuretics and steroids. Both of these types of agents have various side effects. Saireito is a commercially available Chinese herbal medicine that combines Syousaikotou and Goreisan, both of them are also commercially available Chinese herbal medicine. Syousaikotou has steroid-like effects and Goreisan has a diuretic effect. There have been some clinical reports of a beneficial effect of Saireito or Goreisan for chronic subdural hematoma and other conditions. However, there have been no reports about the clinical effects of Saireito in patients with malignant brain tumors. We evaluated the clinical effects of Saireito for patients with advanced stage glioblastoma.

## 2. Patients and methods

Saireito was administered to eight patients diagnosed with advanced stage glioblastoma. The tumor locations were cerebral in seven cases and in the pons in one case. There were four males and four females. The age of the patients ranged from 38 to 86 years old. Seven patients underwent tumor resection and were pathologically diagnosed with glioblastoma. One patient

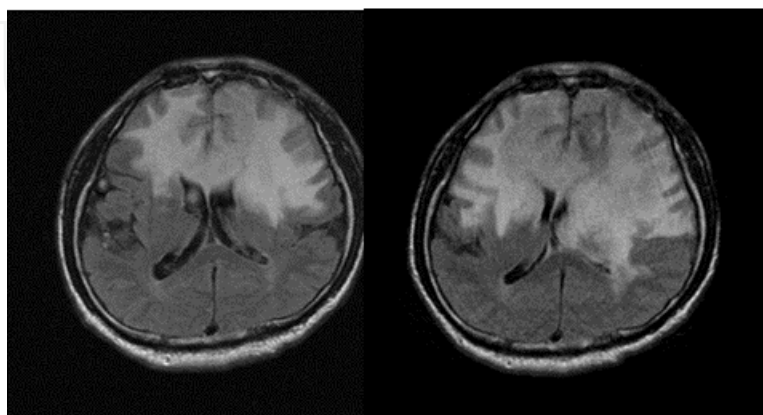
did not receive surgery because of the high age, so glioblastoma was diagnosed clinically. The seven patients who received surgery were treated with postoperative radiation and chemotherapy. Five patients underwent repeat surgery and additional radiation therapy for recurrence. All patients received temozolomide chemotherapy and interferon immunotherapy wherever possible. Saireito (2.7 g) was given three times a day for all patients with advanced stage disease. Saireito was given through a nasogastric tube for the patients who could not take the medication orally.

### 3. Representative case report

A 74-year-old male presenting with memory disturbance and right hemiparesis was diagnosed to have a left frontal brain tumor using brain magnetic resonance imaging (MRI). The tumor was surgically removed, and the pathological diagnosis was glioblastoma. He received postsurgical radiation therapy and concomitant oral chemotherapy with temozolomide. After these initial therapies, maintenance chemotherapy with temozolomide and intravenous infusion of interferon were continued. His consciousness deteriorated one year after the initial therapy. He could not take medication orally, so we started parenteral nutrition using a nasogastric tube. Brain MRI showed an increase in bilateral frontal edema (Fig. 1). Therefore, we first administered intravenous glyceol; however, we considered permanent intravenous administration of glyceol to be difficult. Therefore, we started parenteral Saireito administration and terminated the intravenous glyceol treatment. The patient's condition remained unchanged, so he discharged, and the nasogastric parenteral nutrition and Saireito administration were continued at his home. He underwent repeat short-term hospitalization for scheduled chemotherapy and intravenous infusion of interferon (Fig. 2)

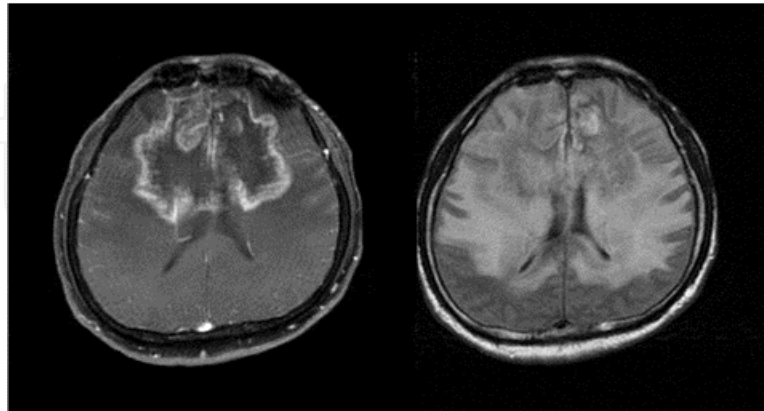
2010/11/16

2011/4/14



**Figure 1.** Fluid attenuated inversion recovery (FLAIR) MRI image

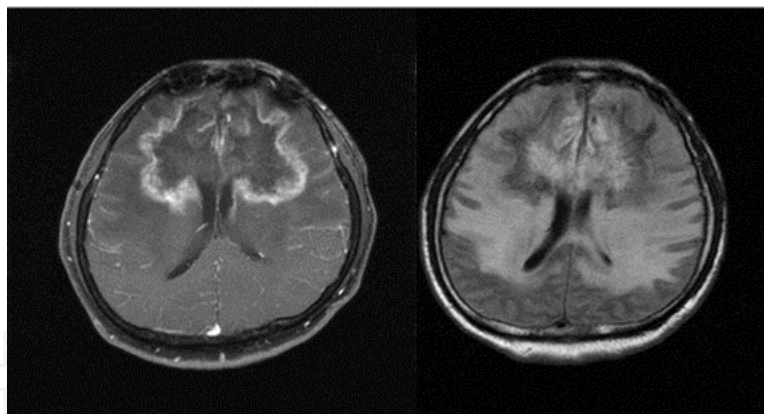
2011/10/6



**Figure 2.** Gadolinium-DTPA enhanced T1 weighted image and FLAIR image

2012/1/4

2012/3/15



**Figure 3.** Gadolinium-DTPA enhanced T1 weighted image and FLAIR image

About one year after the initiation of Saireito, he developed intestinal bleeding and pleural effusion. Chest and abdominal computed tomography showed multiple tumors. The parenteral nutrition and medication were terminated. He died because of intestinal bleeding two years after the initial diagnosis of the brain tumor. The final brain MRI showed a stable brain tumor and perifocal edema (Fig. 3). The tumor diameter on fluid attenuated inversion recovery (FLAIR) and gadolinium-diethylene triamine pentaacetic acid (DTPA)-enhanced T1-weighted MRI (GdT1) was plotted in Figure 4. Before the administration of Saireito, the tumor diameter in FLAIR was continuously increasing. After the initiation of Saireito administration, the tumor

diameter in FLAIR became stable, although the tumor diameter in GdT1 continuously increased. Because of his poor renal function, GdT1 MRI was not performed during the early stage of follow-up.

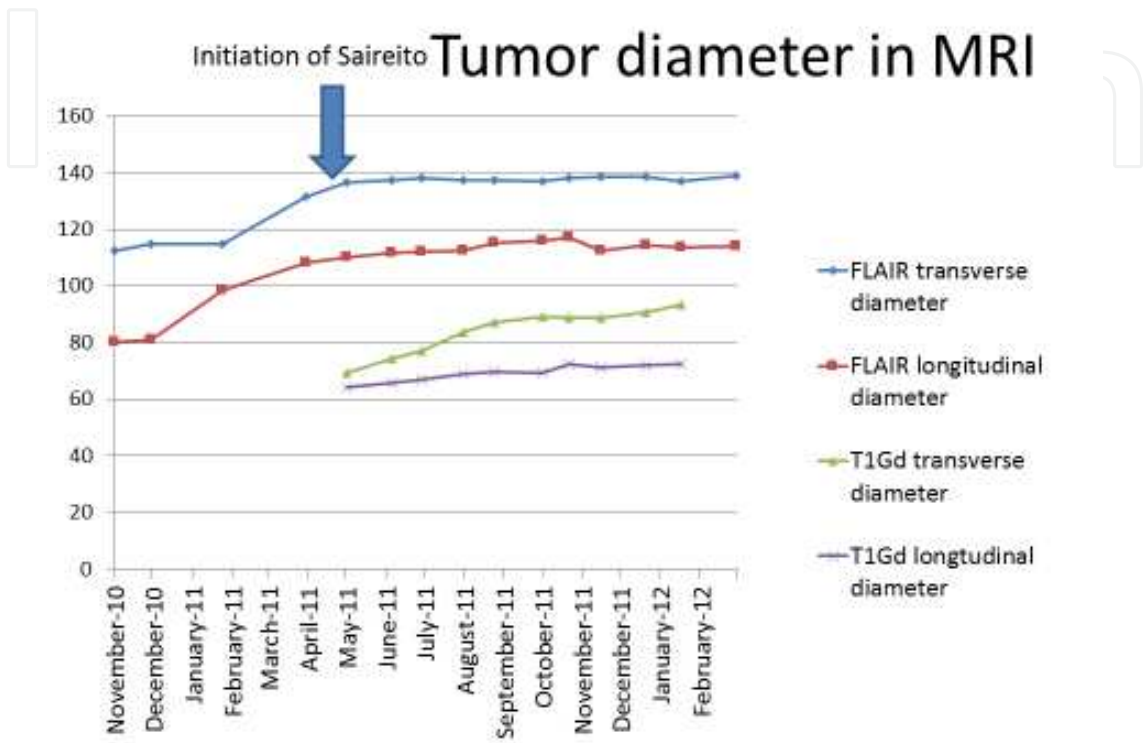


Figure 4. Temporal change of Tumor diameter in MRI

#### 4. Results

All eight patients died. The survival time of the patients ranged from four to 35 months, with a mean of 18.4 months, and a median of 22 months. Saireito was given to all of the patients until almost the end of the life. The direct causes of death were tumor growth in four patients, central nervous system failure without tumor growth in one patient, and another malignancy, pneumonia and a hyperglycemic coma in one patient each. The continuous glycerol infusion was stopped after Saireito administration in all patients. The steroid administration was stopped for two patients and reduced for two patients after Saireito administration. The interval from the initiation of Saireito to death ranged from one to 12 months, with a mean of 5.9 months and a median of three months. The Karnofsky performance status (KPS) was used to assess the patient's general condition [1]. The KPS of all patients who received Saireito was less than 50 at the time of initiation. The radiation therapy oncology group recursive partitioning analysis (RTOG RPA) was used as an index of the prognosis [2]. The RTOG RPA of all patients who received Saireito was Stage VI. The mean prognosis of RTOG RPA Stage VI is

five months. Therefore, a prolongation of survival was observed for four of the eight patients. For the patients who took Saireito for less than four months, no prolongation of survival was observed. On the other hand, prolonged survival was observed in the patients who took Saireito for more than six months. No significant side effects of Saireito were observed. The administration of Saireito is covered by the Japanese health insurance system, and the cost of Saireito is less than 400 Japanese yen per day.

Age	Sex	onset to death	Saireito Intake	Intake to death	Cause of death
75	M	24	12	13	Intestinal bleeding
68	F	35	4	4	neural without tumor
86	M	4	2	2	hyperglycemic coma
62	F	4	1	1	Brain Tumor
59	M	20	2	2	Brain Tumor
58	M	31	8	8	Pneumonia
38	F	11	11	11	Brain Tumor
38	F	20	7	8	Brain Tumor
Mean		19.7	5.9	6.1	
Median		22	3	3	

**Table 1.** Summary of the patients

## 5. Discussion

Saireito is a mixture of Syousaikotou and Goreisan. Syousaikotou has mild steroid-like effects. In animal studies, Syousaikotou increased the secretion of corticotrophin-releasing hormone and adrenocorticotrophic hormone (ACTH), resulting in an increased cortisol concentration [3] [4]. Cortisol is effective for decreasing inflammation and brain edema. Long-term administration of Saireito does not have the typical side effects of conventional steroids. Saireito and Goreisan have diuretic effects by controlling the aquaporin function at the cell membrane [5]. Long-term glycerol infusion is associated with some side effects, such as electrolyte imbalance. However, these side effects have been reported to be rare for Saireito.

There have been some clinical reports about the effective applications of Saireito and Goreisan for cerebral edema, chronic subdural hematoma and edema at the extremities [6, 7]. However, the clinical application of Saireito for malignant brain tumors has not been reported previously. The clinical effects should be confirmed by a randomized controlled study. However, the low cost and apparently rare side effects appear to be major advantages of this Chinese herbal medicine.



## 6. Conclusion

Saireito was found to be both safe and effective for patients with advanced stage glioblastoma. Some patients could stop taking glycerol and steroids. Among the eight patients evaluated in the study, death due to tumor growth was observed in four patients. A prolongation of survival was observed in four of the eight patients. This Chinese herbal medicine appears to be effective, and is associated with both a low cost and rare side effects, thereby warranting further studies in a larger number of patients.

## Acknowledgements

I appreciate my mentors, collaborators and the patients.

## Author details

Yasushi Shibata\*

Department of Neurosurgery, Mito Medical Center, University of Tsukuba/ Mito Kyodo General Hospital, Mito, Ibaraki, Japan

## References

- [1] Mackworth N, Fobair P, Prados MD. Quality of life self-reports from 200 brain tumor patients: comparisons with Karnofsky performance scores. *J Neurooncol* 1992;14:243-253.
- [2] Curran WJ, Jr., Scott CB, Horton J, Nelson JS, Weinstein AS, Fischbach AJ, Chang CH, Rotman M, Asbell SO, Krisch RE, et al. Recursive partitioning analysis of prognostic factors in three Radiation Therapy Oncology Group malignant glioma trials. *J Natl Cancer Inst* 1993;85:704-710.
- [3] Nakano Y, et. a. The effect of Saireito on the Human hypothalamic-pituitary-adrenal axis.. *Hormone and clinic (In Japanese)* 1993;41:97-99.
- [4] Nakano Y, Suda T, Tozawa F, Dobashi I, Sato Y, Ohmori N, Sumitomo T, Demura H. Saireito (a Chinese herbal drug)-stimulated secretion and synthesis of pituitary ACTH are mediated by hypothalamic corticotropin-releasing factor. *Neurosci Lett* 1993;160:93-95.
- [5] Isohama Y. Diuretic effect of chinese herbal medicine and aquaporin (In Japanese). *Pharmacia* 2011;47:1117-1120.

- [6] Hayashi A. Effectiveness of Gorei-San for eliminating brain edema due to intracranial malignant brain tumors (In Japanese). *Kampo and recent therapy* (In Japanese) 2008;17:226-231.
- [7] Kitahara M. Clinical effect of Saireito for chronic subdural hematoma (In Japanese). *Science of Kampo Medicine* 2010;34.

IntechOpen

IntechOpen



