

We are IntechOpen, the world's leading publisher of Open Access books Built by scientists, for scientists

6,900

Open access books available

185,000

International authors and editors

200M

Downloads

Our authors are among the

154

Countries delivered to

TOP 1%

most cited scientists

12.2%

Contributors from top 500 universities



WEB OF SCIENCE™

Selection of our books indexed in the Book Citation Index
in Web of Science™ Core Collection (BKCI)

Interested in publishing with us?
Contact book.department@intechopen.com

Numbers displayed above are based on latest data collected.
For more information visit www.intechopen.com



Laparoscopic Adjustable Gastric Banded Plication (LAGBP)

Chih-Kun Huang and Jasmeet Singh

Additional information is available at the end of the chapter

<http://dx.doi.org/10.5772/58695>

1. Introduction

The acceptance of bariatric surgery among morbidly obese patients is highly credited to the introduction of laparoscopy. It has been proven beyond doubt that in morbid obesity, bariatric surgery remains the mainstay management. [1] Although Roux-en-Y gastric bypass has enjoyed the status of being gold standard bariatric surgery for long, it not only involves creation of a severely restrictive gastric pouch, but also excludes a portion of the small bowel. This puts patients at a high risk of developing nutritional deficiencies and some metabolic complications. [2, 3].

Laparoscopic adjustable gastric banding (LAGB) became popular because of its safety profile but its use has decreased over the last decade due to its unfavourable long term outcomes.[4]. Last decade has seen rise in popularity of laparoscopic sleeve gastrectomy (LSG) and has shown promise in medium term results.[5] However, this procedure has the longest staple line among all bariatric procedures which gives rise to the concerns of staple line leak, bleeding and stricture. Furthermore, post-operative decrease in lower esophageal sphincter pressure has been observed.[6] Talebpour and Amoli introduced plication of greater curvature as an alternative to cutting it and recently published their 12 year results with good outcome. [7] However, the possibility of postoperative weight regain owing to plicated gastric tube dilation remains debatable.

In 2009 we introduced a new bariatric procedure to overcome the concerns raised by LSG, LAGB and plication and named it as laparoscopic adjustable gastric banded plication (LAGBP).[8] It involves dual restriction by combining plication with banding. No cutting of stomach is involved. Plication results in initial rapid weight loss and adjustable band ensures long term maintenance of weight loss. Our case-matched comparative study with

LSG, LAGBP showed similar results at 2 years in terms weight loss, comorbidity resolution and complications. [9]

2. Case selection

Indications: As for other bariatric procedures, $\text{BMI} \geq 40$ or $\text{BMI} \geq 35$ with co-morbidity is an indication for surgery.[10] This BMI limit may be reduced by 3 for Asian population as per Asia Pacific surgical criteria; $\text{BMI} \geq 37$ or $\text{BMI} \geq 32$ with co-morbidity. [11]

Thorough pre-operative evaluation should be done as for any other bariatric procedure as per protocols of the institution.

Super-obesity ($\text{BMI} > 50 \text{ kg/m}^2$) patients may be better served with a mal-absorptive or combined (LRYGB) procedures.

Large hiatus hernia or severe gastro-esophageal reflux is a relative contra-indication.

Patients who cannot follow-up in the clinic for weight loss monitoring and band adjustments must not be offered this procedure.

Patients allergic to silicon must not be offered LAGBP.

3. Surgical technique

All patients should receive prophylaxis against deep vein thrombosis and antibiotics as per the policy of the hospital before starting the procedure.

A bariatric operating table providing at least 45° of reverse Trendelenburg position is preferable.

Room Setup: Patient lies supine on the table with arms extended. Patient must be fastened to the table to prevent slippage during change of posture. Adequate padding must be ensured. Surgeon stands on the right side, camera-man and first assistant on the left side of the patient. Room set-up is depicted in Figure 1.

Port placement: Four or five ports are used (Figure 2). Pneumo-peritoneum is created using Veress needle. Surgeon's left hand port in right upper quadrant (5mm) and right hand at supra-umbilicus (15mm). 5mm assistant port is in left upper quadrant.

Liver retraction: The left lobe of liver could be retracted by Nathanson liver retractor or elevated using T-shaped liver suspension technique.[12] A silicon or rubber drain attached to 2-0 polypropylene suture on long straight needle is used. Two such suspensions usually suffice. The needle is then passed into the inferior surface of the left lobe of the liver so as to exit at the superior surface. The needle is exteriorized by piercing the anterior abdominal wall. The thread is clamped close to the abdominal wall after lifting the left lobe of liver

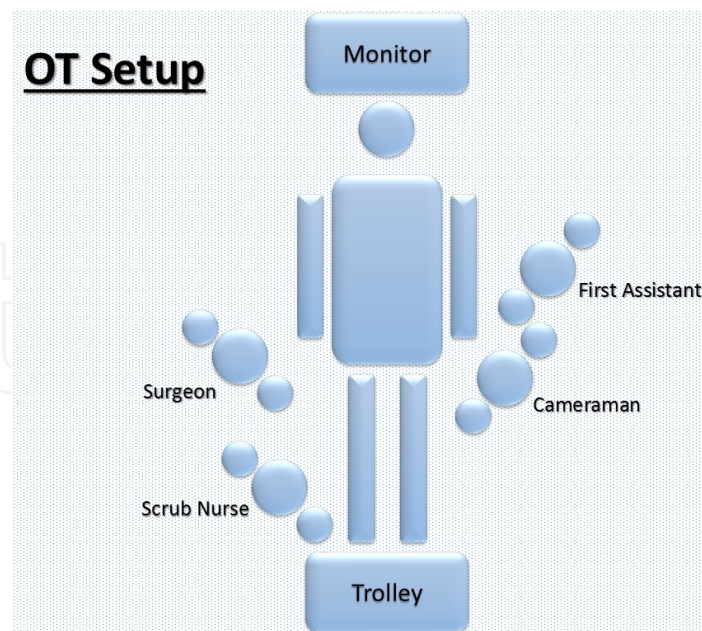


Figure 1. Operation Theater Setup

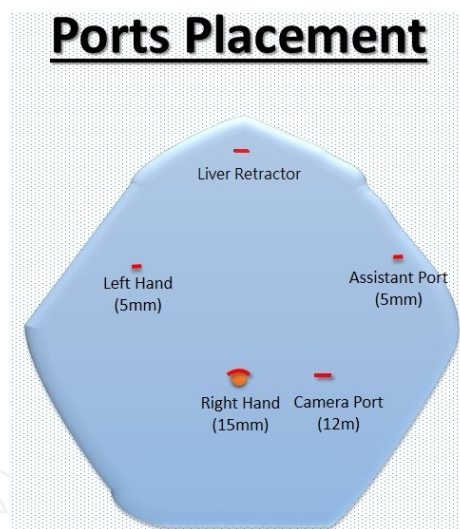


Figure 2. Trocar Placement

Mobilisation of greater curvature: The junction of right and left gastro-epiploic vessels is seen and greater omentum is divided close to the stomach above this point till left crus of diaphragm is clearly seen. Below this point the omentum is divided distal to right gastro-epiploic vessels thereby maintaining venous drainage of the stomach. This helps in decreasing oedema of the stomach wall. Dissection is carried out distally till 3 cm from the pylorus.

Gastric plication formula: Stomach is measured transversely at the level of 6 cm below gastro-esophageal junction (x cm) and plication formula is applied to determine the amount of plication ($y = (x+1) / 2$). Stomach is marked from lesser curvature side y cm away. (Figure 3)

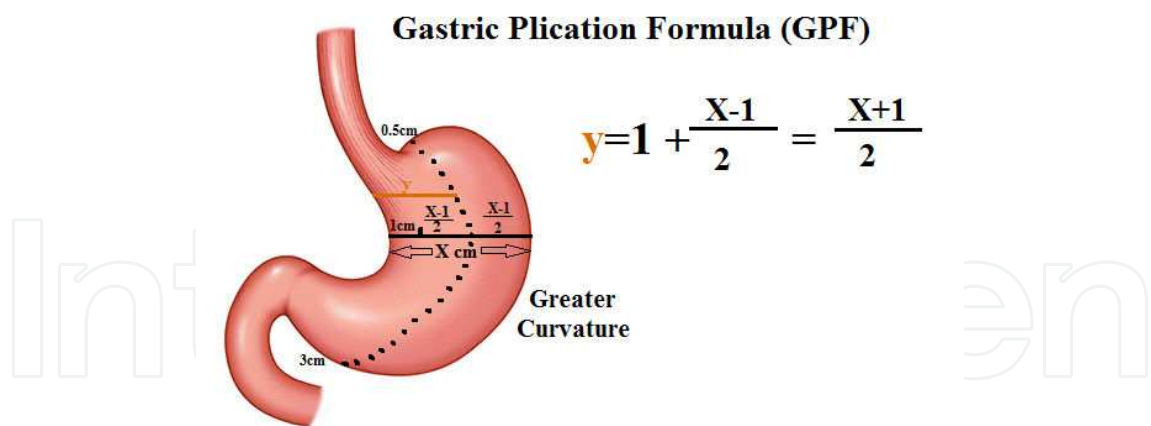


Figure 3. Plication Formula

Plication: It is started from the fundus and progresses towards the pylorus stopping 3 cm from it. The greater curvature is inverted using non-absorbable sutures (2-0 Ethibond Excel Ethicon, St. Stevens-Woluwe, Belgium) at every 2 cm and is then reinforced with a continuous sero-muscular suture (polypropylene 2-0). Second continuous layer is important in preventing the herniation of inverted stomach out of the first layer.

Adjustable band: Band is then inserted using *pars flaccida* technique with minimal dissection and is locked in proper position. The band is checked for proper functioning after its placement. Band need not be fixed to the stomach (Figure 4). The reservoir port is placed over rectus sheath near the umbilicus.

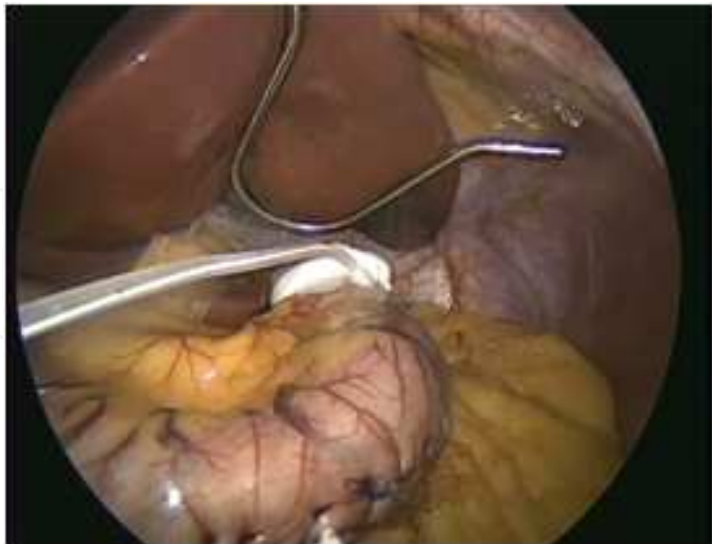


Figure 4. Completed LAGBP

Wound closure: The ports are removed, fascial defects closed and skin is closed with sub-cuticular sutures.

4. Post-operative course

Patients were given oral sips of water 4–6 hours after the surgery. Proton pump inhibitors (PPIs), anti-emetics and dexamethasone are given for 1–2 days.

Patients are discharged if there is no vomiting and they are able to drink enough liquids. Oral PPIs are given for 1 month following surgery.

Liquid diet is prescribed for first week followed by pureed diet for the second week.

This is followed by semi-solid diet for another 2 weeks after which solid food is introduced in a stepwise fashion.

Patient is seen in clinic one week following surgery and thereafter at 1, 3, 6, 9, 12 months. Following which every 6 monthly follow-up is done.

Adjustment of the gastric band is started after 3 months from the surgery if patient complains of less satiety, increased food intake volume or there is inadequate weight loss.

Full evaluation of patient including upper GI endoscopy is performed after 1 year for surveillance and yearly thereafter.

5. Complications

Nausea/vomiting: This can be usually managed with anti-emetics, prokinetics, antacids and adequate hydration.

Acute gastric obstruction: A very tight plication can result in acute gastric obstruction and will require emergent release of plication sutures. This condition settles promptly after the reversal of plication.

Herniation of plicated stomach: May be asymptomatic or may cause acute gastric obstruction presenting with pain, vomiting etc. It may further complicate to ischemia and perforation. Maintaining no more than 2 cm distance between first layer of sutures and a continuous second layer is important to prevent this complication. If symptomatic, surgical correction is necessary by de-plication or re-plication depending upon the condition of the patient.

Perforation peritonitis: This is a rare but serious complication of LAGBP. A high degree of clinical suspicion is important. Pain, tachycardia and high leukocyte count should raise alarm. Computed tomography of abdomen or contrast study may be performed but in the end, clinical judgement must prevail. Laparoscopic exploration should be performed, band removed and plication must be released. Perforation can usually be repaired primarily. However, wedge resection or sleeve gastrectomy may be required for ischemic part.

Band infection: As with LAGB, band may get infected and usually needs removal.

Band adjustment schedule: First adjustment is not done before 3 months from surgery so as to let the oedema subside. Later, patient is followed at intervals as mentioned before and band is adjusted according to weight loss and feeling of satiety.

6. Technical tips

Proper case selection is important. Patients must understand the need for follow-up and band adjustment.

By preserving the right gastroepiploic vessels, the oedema of stomach can be decreased thereby decreasing the post-operative vomiting. And adopting the gastric plication formula could facilitate and standardize the surgery to prevent the complications from over-plication.

Advantages of LAGBP: It avoids cutting of stomach thereby decreasing chances of leak, haemorrhage and stricture. The placement of adjustable band over plication helps in preventing dilatation of stomach over long time. Plication decreases number of band adjustments required for adequate weight loss and hence decreases complications of banding. Stomach wall near cardia is not cut as in LSG and hence may decrease gastro-esophageal reflux. No part of stomach is removed and hence vitamin / mineral deficiencies may be less as compared to LSG.

Proper follow-up is of paramount importance for adequate weight loss.

7. Conclusion

Laparoscopic adjustable gastric banded plaction (LAGBP) owns dual effect of plication and band adjustment without side effects of gastrointestinal anastomosis and mal-absorption, proved to be a safe and effective bariatric surgery.

Author details

Chih-Kun Huang and Jasmeet Singh

Bariatric & Metabolic International (B.M.I) Surgery Center, E-Da Hospital, Taiwan

References

- [1] Karlsson J, Taft C, Ryden A, et al. Ten-year trends in health-related quality of life after surgical and conventional treatment for severe obesity: the SOS intervention study. *Int J Obes.* 2007;31:1248–61.
- [2] Segaran E. Provision of nutritional support to those experiencing complications following bariatric surgery. *ProcNutrSoc* 2010;10: 1–7.

- [3] D Kumpf VJ, Slocum K, Binkley J, Jensen G. Complications after bariatric surgery: survey evaluation impact on the practice of specialized nutritional support. *Nutr-ClinPract* 2007;22:673– 8.
- [4] Suter M, Calmes JM, Paroz A, Giusti V. A 10-year experience with laparoscopic gastric banding for morbid obesity: high long-term complication and failure rates. *Obes-Surg* 2006;16:829 –35.
- [5] Updated position statement on sleeve gastrectomy as a bariatric procedure. soard. 2012.02.001.
- [6] Braghetto I, Lanzarini E, Korn O, Valladares H, Molina JC, Henriquez A. Manometric changes of the lower esophageal sphincter after sleeve gastrectomy in obese patients. *ObesSurg* 2010;20:357– 62.
- [7] Mohammad Talebpour, Seyed Mohammad KalantarMotamedi, AtiehTalebpour and HamedVahidi. Twelve year experience of laparoscopic gastric plication in morbid obesity: development of the technique and patient outcomes. *Annals of Surgical Innovation and Research* 2012, 6:7.
- [8] Huang CK, Lo CH, Shabbir A, Tai CM (2012) Novel bariatric technology: laparoscopic adjustable gastric banded plication: technique and preliminary results. *SurgObes-Relat Dis* 8(1):41–5.
- [9] Huang CK, Chhabra N, Goel R, Hung CM, Chang PC, Chen YS (2013) Laparoscopic adjustable gastric banded plication: a case-matched comparative study with laparoscopic sleeve gastrectomy. *ObesSurg* 23(8):1319-23.
- [10] NIH conference. Gastrointestinal surgery for severe obesity. Consensus Development Conference Panel. *Ann Intern Med.* 1991 Dec 15;115(12):956-61.
- [11] Lee WJ, Wang W. Bariatric surgery: Asia-Pacific perspective. *Obes Surg.* 2005;15(6): 751–7.
- [12] Zachariah SK, Tai CM, Chang PC, Se AO, Huang CK. The "T-suspension tape" for liver and gallbladder retraction in bariatric surgery: feasibility, technique, and initial experience. *J LaparoendoscAdvSurg Tech A.* 2013 Apr;23(4):311-5.
- [13] Laparoscopic Adjustable Gastric Banded Plication (LAGBP)

