

We are IntechOpen, the world's leading publisher of Open Access books Built by scientists, for scientists

6,900

Open access books available

185,000

International authors and editors

200M

Downloads

Our authors are among the

154

Countries delivered to

TOP 1%

most cited scientists

12.2%

Contributors from top 500 universities



WEB OF SCIENCE™

Selection of our books indexed in the Book Citation Index
in Web of Science™ Core Collection (BKCI)

Interested in publishing with us?
Contact book.department@intechopen.com

Numbers displayed above are based on latest data collected.
For more information visit www.intechopen.com



Retinopathy of Prematurity

Vikas Tah, Walid Sharif, Imran Yusuf,
Marcus Posner, Louise Ramskold, Farihah Tariq,
Dev Mukhey and Zuhair Sharif

Additional information is available at the end of the chapter

<http://dx.doi.org/10.5772/58585>

1. Introduction

Retinopathy of prematurity (ROP) is a disease of premature infants and a leading worldwide cause of child blindness [1]. An epidemic of ROP occurred between 1941 and 1953, when an estimated 12,000 infants in affluent countries suffered visual loss from ROP. The first case of ROP, known then as retrolental fibroplasia (RLF), was identified in 1942 [2] with likely total retinal detachment [1]. However, RLF is currently applied to describe later stage cicatricial (severe retinal scarring) disease with retinal detachment and formation of retrolental fibroplastic membrane [2]. It is likely that the severe, advanced disease stage of RLF would have been more readily identifiable in 1942, in the absence of technological advancements that have added precision and clarity to ophthalmic diagnosis. Cases of ROP were reported throughout the developed world over the following decade. Intensive oxygen therapy as the key determinant of ROP was not known until the early 1950s when the suggestion of oxygen toxicity in ROP was made.

ROP is a biphasic condition comprising an initial phase of vessel growth retardation followed by a second phase of vessel proliferation characterised by abnormal retinal vasculature development [2]. Broadly it is thought to be caused by disorganised blood vessel growth that may result in scarring of the retina and retinal detachment.

The precise aetiology of ROP remains unclear [1]. Onset is associated with immaturity. The three factors that have shown a consistently significant association with retinopathy of prematurity are low birth weight, low gestational age and prolonged supplementary oxygen exposure after delivery [3].

The pathological process includes several risk factors that impact on each other. These include premature birth, multiple gestation, prenatal complications, genetic factors, immature pulmonary function, intraventricular haemorrhage, sepsis, anaemia, patent ductus arteriosus, growth factors, prostaglandin synthetase inhibitors, vitamin E deficiency, lactic acidosis [1,23], vasoactive substances development of retinal vessels, maturation of retinal cells with subsequent growth of metabolic demands and the state of the antioxidant system. The exact role of these remains undetermined [3].

ROP is one of the few preventable causes of childhood visual impairment [5]. Early identification and treatment prevent blindness and offer the affected child better visual development [6]. Thus, new, innovative evidence-based approaches to the investigation, screening, prevention and treatment of ROP are still required [1].

2. Epidemiology

Increases in the incidence and prevalence of ROP became recognised as specialists began to theorise that oxygen toxicity might be a contributory factor in pathology among premature babies [1,23] this leading to a perceived 'epidemic' of ROP. Two epidemics of ROP have occurred in the last 70 years in the developed world. The first occurred in 1941-53. This was thought to be related to hyperoxia from incubators[7].

Subsequent research has confirmed that high blood level oxygen causes obliteration of retinal vessels [24-26]. Based on this, recommendations to lower oxygen supply were undertaken and the levels of ROP declined dramatically. Consequently, incubator oxygen concentrations, frequency of administration and duration of oxygen therapy became reduced in many neonatal units throughout the developed world [31].

In the 1970-80s, despite closer oxygen supply monitoring, a second epidemic was recorded, with more extreme low birth weight infants surviving in developed countries [8].

Currently it is thought a possible third epidemic is occurring in industrial medium-developed countries, with several explanations attributable [9-10]. Firstly, there is a higher ratio of premature born to newborns owing to progress in neonatology. The survival of extremely low birth weight infants has increased from 5% to 65% in the last 40 years. Whilst compulsory screening is available in some countries like those of the UK, this is no longer the case in other western countries owing to lack of resources and adequate training. This means that there are a higher number of advanced ROP cases in immature and mature children.

The incidence of the disease was first reviewed in the Cryotherapy for Retinopathy of Prematurity Cooperative Group (CRYO-ROP) study, based on a multicentre trial in the United States. 9751 infants from 23 centres were recruited, and 65.8% of those premature babies with a birth-weight less than 1251 grams were noted to have some form of ROP. 18% developed stage 3 disease and 6% were treated [11].

The Early Treatment of ROP study (ET-ROP) study [12] looked at 317 newborns from 26 different centres with birth weight less than 1251 grams. The incidence was very similar at

68%, and was noted to decrease sharply with increasing birth weight and gestational age. Other trials have been undertaken, but have used different criteria (notable birth weight) to these trials listed, meaning a direct comparison is futile. These trials are listed in the table 1 below [13-19].

author	age (weeks of gestation)	weight (grams)	incidence %
Al Amro2003	<37	<2000	3.4
Hussan1999		<1500	21.3
Fortes, 2007	<36	<1000	48.9
		<1500	16.2
Good 2005		<1251	68
Shah 2005		<1500	29.2
Martin Begué 2003		<1501	29.2
Rehka, 1996	<34	<1500	46%

Table 1. Trials undertaken for incidence retinopathy of prematurity looking at the gestational age and weight

3. Classification

The International Classification of Retinopathy of Prematurity (ICROP) was devised by expert ophthalmologists in the field from 11 countries to help more suitably describe the observations of the disease. This was designed to help clarify what stage of disease was being treated, and to help audit results of treatment. The original ICROP was devised in 1984 [20], with subsequent minor revision in 1987 [21] and with enhanced imaging techniques further modification in 2005 [22].

The classification system has always been based on 3 basic paradigms; *location*, *extent* and *staging* of the disease.

3.1. Location

The original classification in 1984 describes 3 concentric zones of retinal involvement to define the antero-posterior location of the retinopathy. Each zone is centered on the optic disc rather than the macula, since normal retinal growth proceeds forward from the optic disc towards the ora serrata in a systematic fashion (although it is observed that the extent of retinal vascularisation and ROP may be observed closer to the optic disc nasally than temporally).

Zone I (posterior pole or inner zone consists of a circle), the radius of which extends from the centre of the optic disc to twice the distance from the centre of the optic disc to the centre of the macula. The radius of this zone subtends an angle of 30 degrees. The limits of the zone are consequently defined as twice the disc-foveal distance in all directions from the optic disc; an arc of 60 degrees.

Zone II is the area extending from the edge of zone I peripherally to a point tangential to the nasal ora serrata (at the 3 o'clock position in the right eye and the 9 o'clock position in the left eye. The temporal edge of zone II cannot be more accurately defined as the anatomic landmarks needed to identify the equator in premature infants are obscured.

Zone III is the residual crescent of retina anterior to zone II. By convention zones I and II are considered mutually exclusive. Retinopathy of prematurity should be considered in zone II until it can be confirmed that the nasal most 2 clock hours are vascularised to the ora serrata.

For the clinician as a practical approach, using a 25D or 28 diopter (D) condensing lens can help to determine the approximate temporal extent of zone I. The limit of zone I is at the temporal field of view by placing the nasal edge of the optic disc at one edge of the field of view.

3.2. Extent

The extent of the disease specified as the hours of the clock or as 30 degree sectors. As the observer looks at each eye, the 3 o'clock position is to the right and nasal in the right eye and temporal in the left eye. The 9 o'clock position is to the left and temporal in the right eye and nasal in the left eye.

3.3. Staging of the disease

This refers to the amount of abnormal vascular response observed. Prior to ROP development in the premature infant, vascularisation of the retina is incomplete. There are now 5 stages used to describe the abnormal vascular response at the junction of the vascularised and avascular retina. Initially the ICROP had 4 stages, but this has been modified to 5 stages for the eye as a whole, based on the most severe manifestation present since more than one ROP stage may be present in the same eye. For the purpose of recording the examination, each stage is defined and the extent of clock hours is recorded.

Stage 1: Demarcation line

This is a thin but destructive structure separating the avascular anteriorly and vascular retina posteriorly. There is abnormal arcading or branching of vessels leading up to the demarcation line that is relatively flat, white, and lies within the plane of the retina. Vascular changes can be apparent prior to the development of the demarcation line, such as dilatation rather than tapering of the peripheral retinal vessels, but these changes are subtle and difficult to quantify, inadequate for diagnosing early ROP.

Stage 2: Ridge

This is the hallmark of stage 2 ROP. It arises in the region of the demarcation line that has now grown, has height and width, and extends above the plane of the retina. The ridge may change colour from white to pink and vessels may leave the plane of the retina to enter it. Small isolated tufts of new vessels lying on the surface of the retina may be seen posterior to this ridge structure. They do not make part of the growth necessary for stage 3. These small isolated tufts are commonly referred to as 'popcorn'.

Stage 3: Extraretinal fibrovascular proliferation

In stage 3 extraretinal fibrovascular retinal proliferation tissue develops from the ridge and extends into the vitreous. This extraretinal proliferating tissue has 3 characteristics; first it is continuous with the posterior aspect of the ridge, causing a ragged appearance as the proliferation becomes more extensive. Second, it is immediately posterior to the ridge but not always appearing to be connected with it. Third it projects the into the vitreous perpendicular to the retinal plane. The severity of a stage 3 disease can be subdivided into mild, moderate or severe depending on the extent of the extraretinal fibrovascular tissue infiltrating the vitreous.

Stage 4: Partial Retinal Detachment

Stage 4 is divided into extrafoveal (stage 4A) and foveal (stage 4B) partial retinal detachments. This may be caused by exudative effusion of fluid, traction or both. These are generally concave and most tend to be circumferentially orientated. The extent of retinal detachment depends on the number of clock hours of fibrovascular traction and their degree of contraction. Typically, retinal detachments begin at the point of fibrovascular attachment to the vascularised retina. In progressive cases, the fibrous tissue continues to contract and the tractional retinal detachment increases in height, extending both anteriorly and posteriorly. Radial detachments and more complex configurations of retinal detachments are less common.

Stage 5: Total Retinal Detachment

Typically retinal detachments are tractional, but may occasionally be exudative. They are usually funnel shaped. Funnel configuration permits a subdivision of this stage. The funnel is divided into anterior and posterior parts. When open, both anteriorly and posteriorly the detachment often has a concave configuration to the optic disc. A second frequent configuration is one where the funnel is narrow in both the anterior and posterior aspects, and the detached retina is located just behind the lens. A third less common type is where the funnel is open anteriorly but narrowed posteriorly. Least common is a funnel that is narrow anteriorly and open posteriorly.

'Threshold' and 'Pre-threshold' categories of ROP severity were also developed as a result of the CRY-ROP findings [35,36]. 'Threshold ROP', as a subdivision of ROP Stage 3, was associated with an approximate 50% risk of blindness if untreated. These definitions have prognostic importance, as 47% of threshold ROP categorisations culminated in retinal detachment [37].

3.4. "Plus" and "Pre-Plus" disease

The terms 'Pre-plus and Plus disease' denote increased venous dilation and arteriolar tortuosity of the posterior retinal vessels, which often lead to increased ROP severity [35-38]. These may be accompanied by vitreous haze, iris vascular engorgement and inadequate dilation of pupils

3.4.1. "Plus" disease

Progressive vascular incompetence occurring along with the change at the edge of the abnormally developing retinal vasculature may have additional signs indicating the severity

of active ROP that can occur. These include venous dilatation and arteriolar tortuosity of the posterior retinal vessels and may later increase in severity to include iris vascular engorgement, poor papillary dilatation and vitreous haze. This group of supplementary signs was referred to as 'plus' disease in the ICROP original classification. Subsequent refinement from clinical trials has resulted in diagnosis of plus disease that can be made if sufficient vascular dilatation and tortuosity are present in at least 2 quadrants of the eye. A+sign is added to the ROP stage number where there is plus disease present. For example stage 3 ROP combined with posterior vascular dilatation is written as 'stage 3+ROP'. Progression may be rapid where ROP is located in zone I or posterior zone II with plus disease present.

In the CRY-ROP study, significant retinal venous dilation and arteriolar tortuosity in all 4 vascular arcade quadrants served as diagnostic criteria for 'Plus disease'[35-38]. However, currently, changes in at least 2 quadrants are required for the diagnosis of 'plus disease' [51] representing a terminological modification with implications for screening and treatment decisions.

3.4.2. "Pre-Plus" disease

This has been a more recent addition to classification. Abnormal dilatation and tortuosity of posterior pole vessels that demonstrate more than normal arterial and venous tortuosity, but are insufficient for the diagnosis of plus disease is termed 'preplus' disease [8,51]. These changes may over time progress to plus disease as vessels dilate and become more tortuous.

Despite absence of simultaneous manifestation, these symptoms are likely indicators of ROP progression and the 'Pre-plus disease' category may be a useful indicator of sudden increases in ROP activity.

3.5. Aggressive Posterior ROP (AP-ROP)

This is an uncommon rapidly progressing severe form of ROP, termed AP-ROP. Not included in the original ICROP classification, it has recently been defined by ICROP revisited as aggressive posterior ROP and is noted for its rapid progression to stage 5 ROP if not treated [34]. It has been referred to as type II ROP and Rush disease. The characteristic features of this type of ROP are the posterior location, prominence of plus disease and ill defined nature of the retinopathy.

AP-ROP is observed most commonly in zone I, but can occur in posterior zone II. Early in the development of AP-ROP, the posterior pole vessels show increased vascular dilatation and tortuosity in all 4 quadrants that is out of proportion to the degree of retinopathy peripherally. These changes progress rapidly. Shunting does not occur solely at the junction of the avascular and vascular retina but occurs from vessel to vessel within the retina. This can make AP-ROP difficult to distinguish arterioles and venules owing to significant dilatation of both vessel types. There may also be haemorrhages at the junction of the vascular and avascular retina.

AP-ROP is deceptively featureless and does not usually progress through the classic stages 1-3 [40,9], appearing as a flat network of neovascularisation at the junction between the vascular-

isaed and nonvascularised retina. It typically extends circumferentially and is often accompanied by a circumferential vessel. The use of a 20-D condensing lens instead of a 25-D lens in indirect ophthalmoscopy may help distinguish the featureless neovascularisation.

On the basis of this evidence it was concluded that when the characteristics of rapidly progressing disease are observed, or when aggressive posterior ROP is present, the baby should be monitored closely and screening should be undertaken at least weekly [39].

4. Investigations of retinopathy of prematurity: A chronological overview of change, development and future directions

Effective investigation of ROP is dependent on reliable classification. However, as we have mentioned, ROP classification is not a static entity and is subject to evolutionary change resulting from research findings, modifications to practice, technological advances and terminological refinements. Accordingly, standard screening should be performed more frequently, perhaps on a weekly basis [8,39].

Determining and maintaining optimal oxygen saturation levels in preterm infants has remained something of a challenge because data regarding early mortality and long-term neuro-developmental outcomes resulting from effects of different oxygen saturation ranges are lacking [23,33]. The CRYO-ROP study found that the rate of progression of ROP (mean \pm standard error) was faster in eyes with an unfavourable outcome (8.2 ± 1.2 days between first observation of ROP to pre-threshold) compared with those with a favourable outcome (12.3 ± 1.2 days), suggesting that in some situations even twice-weekly examinations are not frequent enough [36,37].

The findings from a meta-analysis of infants with postmenstrual ages of < 32 weeks published in 2010 indicated an association between early low levels of oxygen saturation and reduced risk for severe ROP among and late high oxygen saturation the effect of oxygen on the development and progression of ROP is not straight forward. Ongoing investigation is necessary to understand the relationships among oxygen concentration, variability in oxygen concentration, and timing of oxygen delivery. Low oxygen saturation appears to decrease the risk of severe ROP in preterm newborns when administered during the first few weeks after birth. High oxygen saturation seems to reduce the risk at later postmenstrual ages [32]. However, individual clinical studies have not been conclusive.

A recent study by the Benefits of Oxygen Saturation Targeting (BOOST) Collaborative Group, evaluated the effects of targeting an oxygen saturation of 85 to 89%, as compared with a range of 91 to 95%, on disability-free survival at 2 years in 2,448 infants born before 28 weeks' gestation in three international randomized, controlled trials [8]. Halfway through the trials, the oximeter-calibration algorithm was revised. Recruitment was stopped early when an interim analysis showed an increased rate of death at 36 weeks in the group with a lower oxygen saturation [8]. The rate of death was significantly higher in the lower-target group than in the higher-target group (23.1% vs. 15.9%; relative risk in the lower-target group, 1.45; 95%

confidence interval (CI), 1.15 to 1.84; $P=0.002$) [8]. Oxygen saturation levels below 90% in extremely preterm infants was associated with an increased risk of death [8]. Although the lower targeted saturation group had a significantly reduced incidence of ROP, the infants also had a significant increase in the rate of developing necrotizing enterocolitis [8].

5. Evidence to inform investigations

The first evidence of successful treatment came from the multi-centre CRYO-ROP study reported in 1988 [35]. The CRYO-ROP study reported findings after 3 months, then at 1, 3.5, 5.5, 10 and 15 years. Unfavourable outcomes (defined by ROP in the posterior retina and retinal detachment) were less in the treated group than in the untreated group at every time point [35-38].

The percentage of eyes with unfavourable outcomes increased over time in both groups from 25.1% at one year to 30.0% at 15 years for treated eyes, compared with 44.7% vs 51.9% for untreated eyes [35-38]. CRYO-OP study data, describing the natural history of ROP, are probably the most comprehensive, with current understanding of ROP based largely on the findings of this study. Indeed, it is apparent that the CRYO-ROP study findings have influenced redefinition of ROP classification and as noted, this has implications for investigations, screening and treatment as well as identification of risk factors, clinical course of ROP and outcomes.

However, while outcomes of treatment in the CRYO-ROP study were superior to the untreated controls, they are perceived less than ideal [42]. Outcomes among treated patients were frequently poor, with 21.8% progression to macular distortion or retinal detachment and long-term loss of vision. Cryotherapy did not benefit neonates with stage 4 ROP with partial retinal detachment [42]. Over the longer term, even eyes with favorable anatomic outcomes still had poor vision. ROP located in Zone 1, young gestational age, multiple births, birth outside hospital, low birth weight, white race, plus disease (based on 4 affected eye quadrants), stage 3, >6 clock hour stage 3, and iris vessel dilatation were associated with an unfavorable anatomic outcome [42].

Subsequent to the theory that supplemental oxygen therapy was an important factor in the causal chain of ROP, randomized controlled trial findings indicated that restricting oxygen might result in a lower incidence of severe ROP [43,44], but at a cost of increased mortality [41]. Indeed, current evidence suggests that it is unadvisable to target oxygen-saturation concentrations below 90% in infants born prior to 28 weeks' gestation [46]. However, after seven decades of investigation, knowledge regarding optimal concentrations of oxygen required to balance risk in favor of avoiding adverse effects of both hyperoxia and hypoxia remains inadequate with no 'safe' level of supplementation identified [1] the clinically appropriate range for oxygen saturation in preterm infants remains unknown. In the absence of complete consensus over the oxygen issue, including a definition of optimal oxygen concentration' [39], it is apparent that new approaches to the investigation and prevention of ROP are required [45-48].

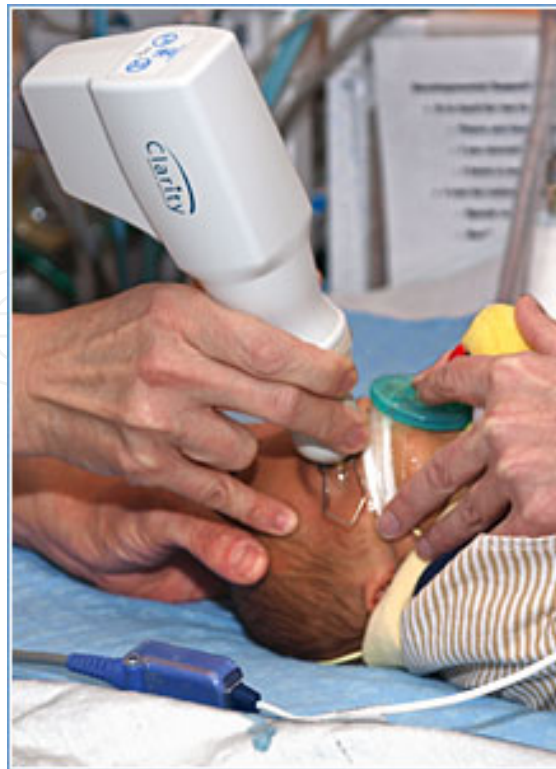

Figure 1. Courtesy of Hoag Levins. Clarity Medical Solutions. [72]

6. Current screening for ROP

An audit of UK ophthalmologists in 1999 established that although many of the 1995 Guideline recommendations were followed, practice varied in relation to when screening should stop and at what stage ROP should be treated [49]. Concerns were also expressed that the recommendations in the 1995 Guideline resulted in too many babies being screened, causing a heavy workload for ophthalmologists and distress to babies receiving unnecessary retinal examinations [33-35].

Key recommendations for good practice in the UK were published in 2008 by the Royal College of Paediatrics and Child Health and Royal College of Ophthalmologists [49]. These were based largely on ICROP revisited publication [34], findings from the CRY-OP study [38] and the Early Treatment for Retinopathy of Prematurity study [53].

Babies of less than 32 weeks gestational age (up to 31 weeks and 6 days) or less than 1501g birth weight should be screened for ROP [49]. One criterion to be met for inclusion [49]: Babies of less than 31 weeks gestational age (up to 30 weeks and 6 days) or less than 1251g birth weight must be screened for ROP. Ophthalmological notes should be made after each ROP examination, detailing zone, stage, and extent in terms of clock hours of any ROP and the presence of any pre-plus or plus disease [49]. These notes should include a recommendation for the timing of the next examination (if any) and be kept with the baby's medical record [32]. Comfort care

techniques (e.g. administering sucrose solution, nesting, swaddling and use of a pacifier) during the screening examination may be considered [49]. Babies with aggressive ROP (as defined in ICROP revisited) should be treated as soon as possible and within 48 hours. ROP requiring treatment but which is not aggressive posterior ROP should normally be treated within 48-72 hours [49].

The current screening guideline of ROP in the United States calls for dilated fundus examination by indirect ophthalmoscopy for all premature infants below 30 week gestational age or less than 1500g birth weight with the first examination performed by 31 week postmenstrual age or by 4 weeks chronologic age, with additional examinations performed repeatedly thereafter to detect late stage ROP requiring treatment [54]. Additional screening for older or larger babies is recommended at the discretion of the attending neonatologist [54].

Risk of sight-threatening ROP developing is considered to be minimal beyond 37 weeks postmenstrual age although any decision to cease screening certain babies before this point in time must be considered with caution. Examination of data from the CRYO-ROP study indicated that babies developing stage 1 or 2 ROP in zone III were at very low risk of developing sight-threatening ROP [55,56]. Investigations for serious ROP should be between 33 and 39 weeks post-conceptual age, while realizing that there is a degree of individual variability in the development of retinal vasculature [56].

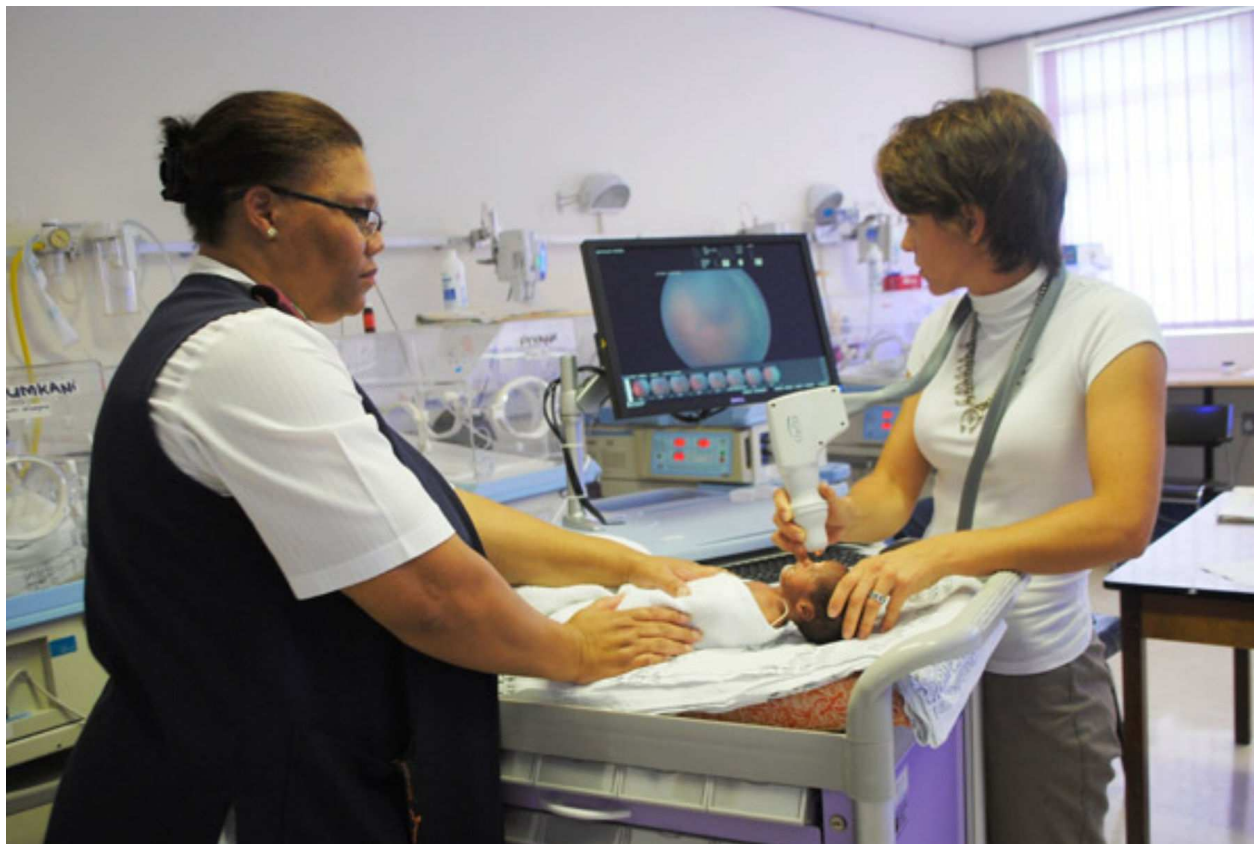

Figure 2. Courtesy of Tygerberg Children's Hospital. [71]

Risk of sight defect is regarded as minimal when regression occurs in babies with moderate ROP, with vascularisation of the retina spreading into zone III. However, it was shown that in 3% of babies, regression and zone III vascularisation had still not occurred by 3 months post term [56]. Therefore, the UK Guideline Development Group decided criteria for termination of screening should be when signs of regression of active ROP are apparent as opposed to vascularisation [49]. Signs of ROP regression have been defined by the ICROP revisited publication as lack of increase in severity, complete or partial resolution, reduction of pre-plus/plus disease, transgression of vessels through the demarcation line and the commencement of the process of replacement of active ROP lesions by scar tissue [51]. The signs of regression should be confirmed by at least two examinations [49]. In babies without ROP, eye examinations may be stopped when vascularisation has extended into zone III, usually after 36 weeks post-conceptual age [57].

Babies with ROP that did not require treatment can have screening stopped when clear regression is seen on 2 successive examinations [57]. Babies that required treatment for ROP and babies diagnosed with stage 3 ROP, which resolved spontaneously, require ophthalmic review at least until 5 years of age [57]. Babies with stages 1 or 2 ROP can have routine vision screening, unless there is specific concern [49]. It should be noted that the process of regression may differ between individuals and ophthalmologists should err on the side of caution when they believe that there is still the possibility of sight-threatening ROP [49].

Until recently, universally accepted treatment criteria of 'threshold' ROP have been used and there is a requirement for new studies using pre-threshold treatment criteria [49]. The UK recommendations were drawn up with the intention not to negate use of clinical judgment by experienced and competent ophthalmologists [49].

As with the classification, the screening for ROP is constantly evolving. Screening investigations include frequent retinal examinations of at-risk preterm infants [57]. Delaying or postponing a screening examination could mean that the window of opportunity for treatment is missed [58,62].

7. Future screening

Newly developed ROP screening and prediction methods based on post-natal weight gain and IGF-1 levels can predict infants who are at high risk for ROP. These infants may be monitored more closely while those identified to be at low risk may be spared unnecessary diagnostic procedures. ROP evaluations and weekly weight measurements from birth to postmenstrual week 36 were entered into a computer-based surveillance system.

A prospective study of 50 preterm infants with a mean gestational age of 26 weeks was conducted to validate a surveillance algorithm for detecting infants at risk for proliferative ROP [59]. Weekly measures of body weight and (IGF-I) level from birth until postmenstrual age 36 weeks were compared using the Weight, insulin like growth factor I (IGF-1), Neonatal Retinopathy of Prematurity (WINROP) algorithm [59]. Gestational age, birth weight, and IGF

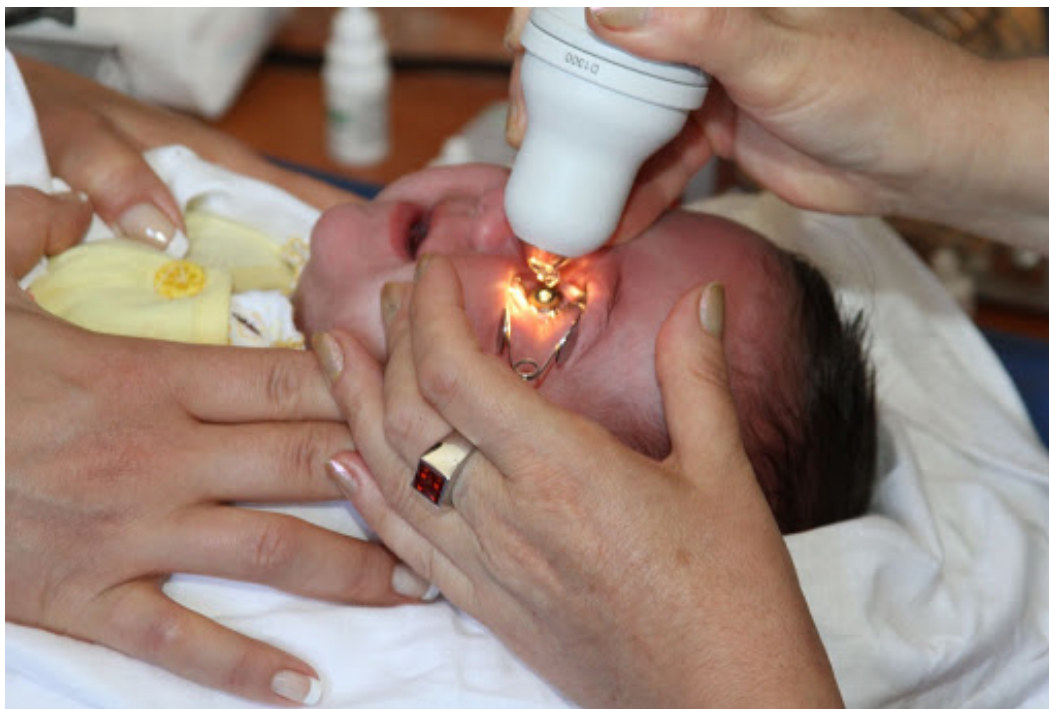

Figure 3. Courtesy of Minas Hambardzumyan. [73]

binding protein 3 level are entered. An alarm is raised if any of the variables indicate a certain degree of negative deviation [59]. The WINROP algorithm identified all infants (100% sensitivity) who were diagnosed with proliferative ROP 1. No infants with no alarm or with alarm at low risk developed proliferative ROP. Alarm at high risk before postmenstrual age 32 weeks was raised for 22 of 50 infants (44%); 9 of these infants developed proliferative ROP (54% specificity), of whom 8 were treated [60]. It was concluded that the WINROP algorithm may be a useful modification for ROP screening [59].

In another study using WINROP a total of 1706 infants with a median gestational age of 28 weeks (range, 22-31 weeks) and median birth weight of 1016 g (range, 378-2240 g) were included in the study analysis [60]. An alarm occurred in 1101 infants (64.5%), with a median time from birth to alarm of 3 weeks (range, 0-12 weeks) and from alarm to treatment of 8 weeks (range, 1 day to 22 weeks). The sensitivity of WINROP was 98.6% and the negative predictive value was 99.7%. Two infants with type 1 ROP requiring treatment after 40 weeks' postmenstrual age did not receive an alarm [60].

In a Mexican patient population, the WINROP algorithm correctly predicted severe retinopathy of prematurity in 84.7% of extremely preterm infants and correctly identified only 26.6% of infants in whom severe retinopathy of prematurity did not develop [61]. These findings suggest that potential differences exist among preterm infants with retinopathy of prematurity in different regions of the world.

The WINROP algorithm was recently tested using a retrospective cohort study in the South East of Scotland [63]. Anonymised clinical data were uploaded to the online WINROP site, and infants at risk of developing severe ROP were identified. The results using WINROP were

compared with the actual ROP screening outcomes. Infants with incomplete weight data were included in the whole group, but were excluded from a subgroup analysis of infants with complete weight data. In addition, data were manipulated to test whether missing weight data points in the early neonatal period would lead to loss of sensitivity of the algorithm. The WINROP algorithm had 73% sensitivity for detecting infants at risk of severe ROP when all infants were included and 87% when the complete weight data subgroup was analysed. Manipulation of data from the complete weight data subgroup demonstrated that one or two missing weight data points in the early postnatal period lead to loss of sensitivity performance by WINROP [63]. It was concluded that the WINROP program offers a non-invasive method of identifying infants at high risk of severe ROP and also identifying those not at risk. However, for WINROP to function optimally, it has to be used as recommended and designed, namely weekly body weight measurements are required [63].



Figure 4. Courtesy of BIOPHOTONICS [74].

8. Digital imaging

Interpretation of digital images have been found to have good inter/intra-reader reliability [64,65] which enhances its potential for use in what is termed 'telemedicine' [49]. The use of

digital photographic retinal images that are captured and sent for remote interpretation is a developing approach to ROP screening however, outcomes comparison between large-scale operational digital-imaging systems with remote interpretation versus binocular indirect ophthalmoscopy have not been published.

While there is not sufficient research evidence to demonstrate that wide field digital fundus photography is as effective as the indirect ophthalmoscope for ROP screening, some UK screeners already the technique 'RetCam' is of choice although the cost is likely to remain a deterrent for many units [49]. However, training of operators is an important issue and no studies have yet demonstrated that cameras operated by non-ophthalmologists are as sensitive at detecting ROP as the indirect ophthalmoscope in the hands of a skilled ophthalmologist [66].

Accurate assessment of ROP is essential in ensuring correct and timely treatment of this potentially blinding condition [67,68]. Current modes of assessment are based upon clinical grading by expert examination of retinal changes. However, this may be subjective, unreliable and difficult and there has been significant interest in alternative means of measurement. These have been made possible through technological advancements in image capture and analysis as well as progress in clinical research, highlighting the specific importance of the plus disease category in ROP [68]. Progress in these two fields has highlighted the potential for digital image analysis of plus disease to be used as an objective, reliable and valid measurement of ROP. However, with the potential benefits, there are significant challenges such as in image capture, segmentation, measurement of vessel width and tortuosity [68].

The standard method for diagnosis of ROP has been bedside indirect ophthalmoscopy for both routine clinical care and clinical trials. With this approach, the examiner's interpretations of the clinical findings are transcribed onto grading sheets, rather than a photographic record of the actual retinal features. One limitation to this approach is that the examiner's interpretation of fundus findings is presumed to be correct without opportunity for review. Photographic documentation would serve to confirm diagnosis and distinguish true therapeutic failure from poor outcome caused by incomplete treatment [68]. Thus, telemedicine may offer a solution to many of the current geographic and resource problems preventing a comprehensive ROP screening program throughout the world. Future additions to telemedicine could comprise weight-gain algorithms combined with other reliable quantitative data such as IGF-1 levels.

Furthermore, computer-based image analysis using quantitative methods has the potential to improve the objectivity of plus disease diagnosis [69]. Plus disease diagnosis is critical for decision-making in ROP, as it is necessary for threshold disease and sufficient for type 1 ROP. Plus disease is defined as abnormal arteriolar tortuosity and venular dilation in the posterior pole greater than that of a standard published photograph, which was selected by expert consensus for the CRYO-ROP study and is still widely used [69]. During the past 10 years, several computer-based systems have been developed for ROP, particularly for detection of plus disease. This has potential to improve clinical ROP management [69,70]. However, more large-scale, robust clinical trials are still required to provide the necessary evidence to inform optimum investigation and screening for all aspects of ROP.

RISA analysis:

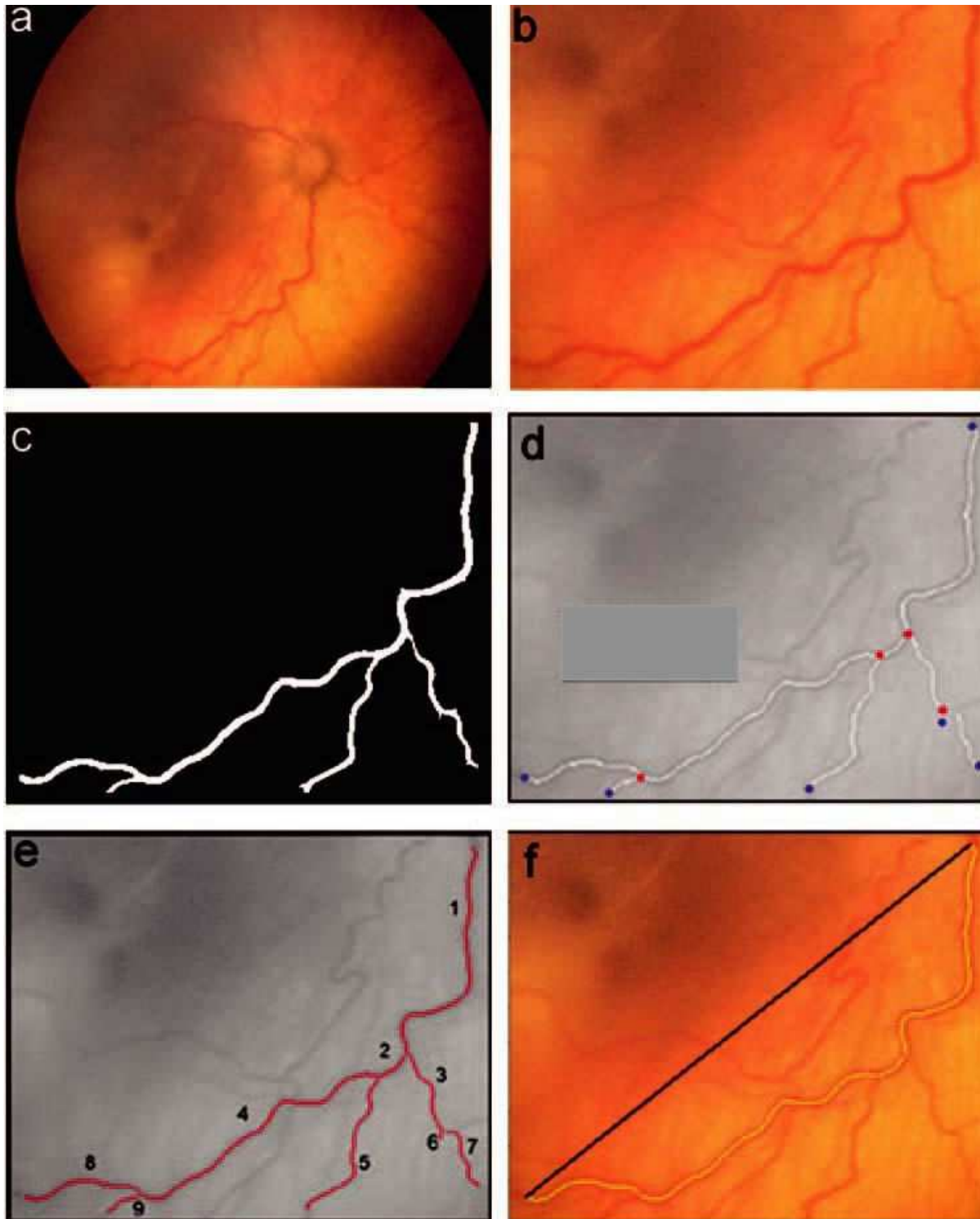


Figure 5. Image documented via RETCAM from (Gelman *et al.*, 2005) [70] : a). (a) Retina (b) Choose the vessel. (c) High-light the vessel. (d) & (e) Mark the vessel. (f) Tortuosity index :Measure actual vessel length, measure the length of point 1 to point 9, divide actual length by length of points 1&9

9. Management of retinopathy of prematurity medical management

9.1. Optimising oxygen therapy

Although incubators for infants had been developed around the mid-nineteenth century, it was not until the 1920s that neonates were grouped together for specialist care in early neonatal intensive care units. Special Care Baby Units became established in many hospitals in the 1940s, although incubators were expensive, oxygen, heat, humidity were considered desirable but influence of such parameters on clinical outcomes were anecdotal – hard clinical data were lacking.

The development of neonatal care, technology and research has reduced gestational age compatible with life to less than 24 weeks with additional challenges in the prevention of ROP. Identifying a safe level of oxygen therapy to prevent the development of ROP in such babies without increasing mortality has been the subject of numerous clinical trials [45, 76-82].

The efficacy and safety of supplemental oxygen therapy for premature infants with pre-threshold ROP was evaluated in the STOP-ROP trial [43]. Infants with oxygen saturations maintained at less than 94% with pre-threshold ROP were assigned to conventional oxygen of 89-94%, or supplemental oxygen with target saturations 96-99%. Supplemental oxygen did not increase progression to threshold ROP or reduce the numbers of infants requiring laser photocoagulation or cryotherapy. There was some suggestion in post-hoc subgroup analysis that infants without plus disease may be more responsive to supplemental oxygen therapy [43].

The HOPE study analysed data from the STOP-ROP trial, including infants who were excluded from STOP ROP with oxygen saturations >94% prior to enrolment [83]. The HOPE-ROP cohort were of a higher gestational age, progressing to threshold ROP in 25% of cases, compared to 46% of the STOP-ROP cohort. Logistic regression analysis identified oxygen saturation at the time of pre-threshold diagnosis to be of borderline significance once gestational age, race, post-menstrual age at diagnosis, zone I disease, and plus disease had been accounted for [83].

The NeOProM study is a prospective meta-analysis collaboration seeking to recruit 5,000 extremely premature neonates to detect rates of death and disability, including visual outcomes from ROP measured at 18 months gestation [85]. Results are expected from this study in 2014.

Increasing neonatal mortality with oxygen restriction suggests that ROP cannot be prevented by oxygen restriction alone in premature infants.

9.2. ROP: When to treat

The “ET-ROP” was a landmark study evaluating the *timing* of treatment of ROP [86], with some concern that a proportion of neonates would receive treatment for ROP that would regress spontaneously and therefore carry an excess risk of surgical complications. The ET-ROP trial was a nationally funded, prospective, randomized, controlled clinical trial that sought to identify clinical criteria to predict those neonates who had the highest risk for an

adverse visual or structural outcome [86], and evaluate the implications for timing of ablative treatment for ROP. Natural history data of ROP from the CRYO-ROP study was used to formulate an algorithm, randomization occurred when the risk was calculated to be 15% or greater (high risk pre-threshold), either to early ablative treatment or observation until threshold or regression. Functional outcomes were assessed by grating visual acuity at 9 months gestation, and structural outcomes were evaluated through fundus examination with unfavourable outcome defined as retinal fold involving the macula, retinal detachment involving the macula, retrolental tissue obscuring posterior pole.

499 high risk pre-threshold neonates with ROP were randomized. The ET-ROP study identified that peripheral retinal ablation should be considered in any eye with zone I ROP with plus disease (any stage), zone I ROP stage 3 with or without plus, or zone II stage 2 or 3 ROP with plus disease (two quadrants, or six clock hours). Those neonates with type II ROP should be considered for treatment when progression to threshold or any of the above criteria are met. These treatment criteria have been influential and are incorporated into many national standards for ROP screening, defining thresholds for treatment [86,87].

9.3. ROP: How to treat

9.3.1. Cryotherapy

Reduction of VEGF production may be achieved with peripheral retinal ablation using cryotherapy. The (CRYO-ROP) studies evaluated the safety and efficacy of cryotherapy for stage 3 ROP. A randomised, controlled clinical trial evaluated 9,751 neonates, 291 of whom developed severe ROP. Cryotherapy reduced the incidence of unfavourable outcomes and improved functional outcomes in neonates with threshold ROP [88]. No intraoperative, or immediate post-operative complications were identified, and no deaths were attributed to cryotherapy treatment [89]. Risk reduction was found to be around 50% [35,36], and consequently recommendations were made for cryotherapy treatment to both eyes of neonates with stage 3 ROP in zone I [36]. The CRYO-ROP study was terminated prematurely due to significant treatment benefit with cryotherapy at the 3 month interim analysis [89,90]. A structural and functional benefit of cryotherapy was demonstrated after evaluation 3 years post-intervention [91]. 10 year follow-up revealed a clear protective effect of cryotherapy in ROP in the long-term in neonates with ROP [92]. New retinal detachments were identified in 15 year follow up [93].

The CRYO-ROP study provided numerous insights into the natural history of ROP, risk factors [94] and racial predilection [95], predictors of disease severity [96], prognosis [37,56,97], symmetry or concordance of disease between eyes [98], functional outcomes [99-101], involutional change [56], myopia [102], strabismus [103] and ocular comesis [104]. Cryotherapy did not benefit neonates with stage 4 ROP with partial retinal detachment [105]. The CRYO-ROP study identified a small loss of peripheral field around 6.4 degrees compared to controls [106] in eyes with severe ROP [107], and an increased incidence of myopia [108].

9.3.2. Laser photocoagulation

9.3.2.1. Anterior to the ridge laser photocoagulation (Avascular retina)

Zone I ROP owing to posterior location and area of ischaemic or avascular retina cannot be treated with cryotherapy alone. Diode laser photocoagulation anterior to the neovascular ridge in neonates with threshold zone I ROP has been demonstrated effective treatment, in contrast to cryoablation [109]. Further studies have demonstrated diode laser photocoagulation for stage 3 ROP to be at least as effective as cryotherapy treatment, with 40 of 42 eyes of eyes regressing after a single laser treatment; only 1 eye progressed to stage 4 ROP.

A study of 48 eyes found argon laser photocoagulation to be effective in the management of threshold ROP in zone I or posterior zone II with confluent laser to the avascular retina, with only 7 eyes progressing to stage 4A retina or beyond, without any recorded complications attributable to laser itself [110]. The mechanism of argon laser photocoagulation in stage 3 ROP is thought to be through reduced peripheral retinal oxygen consumption and reduction of VEGF.

Laser photocoagulation may be achieved with scattered laser; near-confluent [111] or confluent laser burns [112]. Confluent laser burns anterior to the ridge through 360 degrees in threshold ROP demonstrated low rates of progression to stage 4 or 5 ROP (6%), with mean spherical equivalent of -3.80DS in infants [112]. Near confluent laser photocoagulation anterior to the neovascular ridge prevented progression in 4 of 7 eyes with zone I ROP, and all with zone II ROP [111]. A larger combined retrospective and prospective study evaluated 107 neonates with threshold ROP compared near-confluent with scatter diode laser, finding that near-confluent laser photocoagulation was superior to scatter laser in reducing progression in eyes with both zone I and zone 2 ROP [113]. However, randomized trials of anterior to the ridge laser photocoagulation have not been conducted to evaluate the relative efficacy of burn distribution; it is likely that large studies are required to detect a difference as rate of progression to stage 4 and 5 ROP are low.

9.3.2.2. Ridge laser photocoagulation

A randomized, interventional comparative study evaluated the efficacy of argon laser photocoagulation to the neovascular ridge and anterior avascular retina versus laser to the avascular retina only [114] in neonates with threshold ROP. No immediate benefit of ridge laser photocoagulation was apparent, but longterm analysis is awaited. A retrospective study of anterior and ridge laser photocoagulation for threshold ROP with a favourable anatomical outcome in 96% of eyes, although long-term sequelae were not reported [115]. No vitreous haemorrhage was reported in this series. The additional benefit of direct laser photocoagulation of the neovascular ridge in ROP remains unproven [116].

9.3.2.3. Posterior to the ridge laser (Vascular retina)

Posterior to the ridge argon laser photocoagulation is a surgical approach that considers the presence of ischaemic retina posterior to the neovascular ridge, with or without confirmation

of ischaemia with fluorescein angiography. Posterior to the ridge laser has been demonstrated in a non-comparative case series (no control arm) to be effective in the management of stage 3 ROP in zone II, where only 2 of 18 eyes progressed to stage 4A ROP. None developed stage 4B [117]. Aggressive posterior ROP (AP-ROP) may benefit from posterior argon laser photocoagulation in neonates with late stage 3 or stage 4A ROP following unsuccessful treatment to the avascular retina in threshold stage 3 disease [109]. The benefit of FFA guided posterior to the ridge laser has not been evaluated.

9.3.3. *Anti-VEGF agents*

9.3.3.1. *Bevacizumab*

Bevacizumab (Avastin) is a humanized monoclonal antibody raised against vascular endothelial growth factor (VEGF) isoform A, directly inhibiting angiogenesis. Avastin was originally developed and licensed for treatment of metastatic colorectal cancer, non-small cell lung cancer, renal carcinoma and glioblastoma multiforme. Avastin has been used off-label for the treatment of choroidal neovascularisation secondary to age-related macular degeneration, degenerative myopia, retinal vein occlusion, diabetic macular oedema and other disorders characterised by retinal or choroidal vascular abnormalities.

Retinopathy of prematurity is associated with high levels of VEGF within the vitreous and the rationale of administering intravitreal biologic drugs to inactivate it was considered as early as 2008. Avastin for stage 3 ROP with plus disease in zone I or posterior zone II was shown in a limited, non-comparative series to prevent progression of ROP with a single intravitreal injection of Avastin [118]. The BEAT-ROP study was the first prospective, randomized controlled trial comparing laser photocoagulation with intravitreal Avastin for zone I or posterior zone II stage 3+ROP, finding a significant benefit for zone I disease with Avastin, with continued vascularisation compared with conventional laser photocoagulation [119]. Laser photocoagulation for Zone I ROP involves extensive retinal ablation, with increased risk of visual field loss and secondary myopia.

Some studies have evaluated the outcome of combined laser and bevacizumab (0.25mg) for zone I ROP, finding all 18 study eyes demonstrated regression of plus disease without recurrence and vascularisation retina in zone I in all patients. The authors argue that a lower dose of bevacizumab may be used if combined with laser photocoagulation, reduced recurrence than with monotherapy and preservation of central field [120]. Others demonstrate the use bevacizumab as monotherapy (0.625mg), demonstrating efficacy in zone I stage 3 ROP [119,121]. Other groups demonstrate efficacy with rescue intravitreal bevacizumab following laser photocoagulation in aggressive posterior ROP [122]. The optimal dosage for ROP remains to be determined [123]. Late recurrence of ROP in has been reported with subsequent late tractional retinal detachment following initial regression of ROP [124]. Bevacizumab is associated with less significant myopia and astigmatism compared to laser [125].

Systemic absorption of bevacizumab is of concern, and although short-term follow-up studies and surveillance has not demonstrated any attributable systemic morbidity or mortality, this remains unproven. Fellow eyes demonstrate response to contralateral bevacizumab in ROP, suggesting significant systemic absorption of the drug [126].

9.3.3.2. *Ranibizumab*

Ranibizumab (Lucentis) is a monoclonal antibody directed against all isoforms of VEGF. It has been used off-label in retinopathy of prematurity, although data is more limited compared to that of bevacizumab. Experience from studies with ranibizumab in adult disorders, particularly neovascular age-related macular degeneration, has demonstrated fractionally increased systemic risk with bevacizumab versus ranibizumab but not enough to reach statistical significance. Logic would therefore consider ranibizumab in the treatment of ROP, particularly zone I ROP in which the ETROP study demonstrated a 55% treatment failure rate.

Combined laser-ranibizumab in this patient group has demonstrated promising control of stage 3 zone I ROP with regression in all cases, in a non-comparative series of 34 eyes [127]. Combination laser-ranibizumab has been demonstrated effective in the treatment of aggressive, posterior ROP, although this was a limited series of two neonates [128]. Three year outcomes with ranibizumab monotherapy in a series of six eyes with high-risk pre-threshold or threshold ROP with plus disease demonstrated complete regression of neovascularisation with a single treatment and continued vascularisation [129]. No attributable ocular or systemic side-effects were recorded [129]. Single case series of efficacy add limited evidence in favour of ranibizumab in ROP [130] Late retinal detachment in stage 3 zone I ROP has been reported similar to bevacizumab after initial neovascular regression [131].

Different pharmacokinetic and pharmacodynamic properties of ranibizumab and bevacizumab require randomized clinical studies to compare the efficacy in AP-ROP, threshold ROP. Ocular effects and systemic absorption, and non-inferiority demonstrated between ranibizumab and bevacizumab in neovascular AMD cannot be extrapolated to neonates with ROP. Long-term surveillance is required to document systemic outcomes in neonates treated with anti-VEGF agents for ROP to detect late adverse effects not currently encompassed in short-term published trial data.

9.3.3.3. *Pegaptinib*

Pegaptinib (Macugen, 0.3mg in 0.02mls) has been evaluated for stage 3+ROP with adjunctive laser photocoagulation in a randomized controlled clinical trial found to be more efficacious than laser alone [132]. Recurrence of neovascularisation was noted at 14.4 weeks with bevacizumab, at 15.1 weeks with pegaptinib with laser, and 5.9 weeks with laser alone [133]. Risk factors for recurrence, the interval for follow-up examination, and length of time required for follow-up is unknown [133].

10. Surgical management

Surgical intervention is necessary for patient with stage 4 partial retinal detachments, which may or may not involve the fovea, or those with open or closed funnel retinal detachments. Surgical approaches include scleral buckle, vitrectomy and combined vitrectomy-lensectomy.

Factors affecting surgical outcome of stage 4 and 5 ROP have been examined and a poorer surgical outcome may be associated with vitreous haze, active neovascularisation and plus disease [134]. Plus disease was identified as the most significant factor associated with failed retinal reattachment; additional surgery or intravitreal anti-VEGF agents may be considered pre-operatively to improve outcome in this group [134].

Outcomes from neonates from the ET-ROP study who stage 4 or 5 ROP were generally poor. Vitreoretinal surgery was associated with macular attachment in 16 of 48 eyes (33%). Normal acuity was maintained in 21% of eyes after 4a retinal detachment. Stage 5 ROP was associated with good anatomical but poor functional outcome [135].

10.1. Scleral buckling

Stage 4 ROP, partial retinal detachment with or without foveal involvement (stage 4a/ stage 4b respectively) may be treated with lens-sparing vitrectomy with or without the use of external tamponade with a scleral buckle. Studies on the outcome of scleral buckles for stage 4 ROP are limited, and limited study numbers, without randomization make conclusions on the efficacy of scleral buckles difficult. Variability in surgical experience and expertise with scleral buckles in stage 4 ROP makes comparison between studies difficult. Long-term outcome in patients from the ETROP trial with retinal detachments (stage 4a/4b/5 ROP) were reported [87]. Vitrectomy with or without scleral buckle resulted in macular attachment in 17 of 50 eyes, scleral buckle only achieved macular attachment in 6 of 9 eyes after 7 years. This data was from multiple centres and surgeons, and not randomized making cross comparison difficult. A high proportion of retinal detachments (20%) were not classified [87].

A small retrospective interventional case series identified 21 eyes with stage 4 ROP, comparing anatomical outcomes of lens-sparing vitrectomy versus combined lens-sparing vitrectomy and scleral buckle [135]; 12 undergoing combined LSV and SB, and 9 LSV alone. The authors conclude that scleral buckle adds little to the success or failure of LSV with similar outcomes in each group [135], but this small series may not have been adequately powered to detect a difference in treatment outcome. Another retrospective series of 16 eyes who underwent scleral buckling for stage 4 ROP reported anatomical success of 100% in stage 4a and 50% in stage 4b ROP [136]. The buckle was removed in 11 of 12 infants, and mean refraction was -8.68 diopters. There was no control group in this study, but evidence was offered of reducing progression to stage 5 ROP [136].

A further single-surgeon series of 8 neonates who underwent scleral buckling for stage 4a ROP conclude efficacy in preventing progression of retinal detachment, although this study was non-comparative [137].

Scleral buckling requires further procedures under general anaesthetic to reduce the tension of the buckle, or remove it altogether. The tension created by the buckle causes axial myopia (reduced by 5.5 dioptres after division of the buckle), and removal or adjustment of tension necessitates repeat refraction to prevent ametropic amblyopia [138]. Removal of scleral buckle has been demonstrated without resulting retinal detachment or vitreous traction [139].

Anatomical success in patients with repair of stage 4 or 5 ROP may not equate simply to visual improvement in such studies [134]. This is supported by evidence from a systematic review of outcomes of surgical intervention for ROP [140], which demonstrated poor vision in many patients regardless of retinal attachment status. There is difficulty in many studies of measuring low visual acuity in infants; this may not be achieved by grating acuity that is often used as an output in many ROP series.

Large, multicentre, long term studies with randomization are required to determine the efficacy of scleral buckling, but variations in surgical expertise and preference may be prohibitive. It is unlikely that meta-analysis will be valid for this reason. A systematic review of anatomical and visual function outcomes in ROP with vitrectomy and scleral buckle identified a wide variation of retinal reattachment rates between centres of 0.8 to 90% [140]. Earlier surgery was associated with a superior retinal reattachment rate, although longer follow-up was associated with increasing anatomical failure [140].

10.2. Vitrectomy

Evaluating surgical outcomes in ROP is difficult due to the long interval between intervention and reliable recording of monocular visual acuities, variability in surgical technique and experience, and the effect of neurological co-morbidity in clinical evaluation. Many studies are retrospective case series with non-standardised follow-up intervals, and no control arms which limits inferences of efficacy.

Early data from the CRYO-ROP study evaluated the functional outcome of neonates with stage 5 ROP (total retinal detachment) who underwent lensectomy-vitrectomy procedures before one year of age, comparing this cohort with infants who did not. Almost all infants had visual acuity of light perception or worse at 5 years [141].

Further studies demonstrate more promising results. A single-centre retrospective case series reported 37 eyes treated with LSV for stage 4A and 4B ROP, with follow up of 5 years. 63% had measureable visual acuity, 18% had form vision, and 19% had light perception vision or worse [142]. Further similar series evaluated LSV in the setting of progressive posterior-type stage 4A ROP with plus disease, documenting low anatomical success of LSV in progressive posterior stage 4A ROP, particularly associated with plus disease [143].

A consecutive, non-randomized, retrospective series comparing outcomes patients with stage 4 ROP treated with scleral buckle or lens-sparing vitrectomy found that LSV was associated with retinal reattachment in 72% of patients versus 31% of SB patients. At final follow-up, after further procedures, LSV and SB were found comparable in outcome as a first procedure. LSV was favoured in this study as more effective as a single procedure to stop stage 4 ROP [144].

The advent of anti-VEGF agents has led to widespread adjuvant use prior to vitrectomy in vasoproliferative disease to augment surgical outcome. Stage 4A ROP with plus disease has poorer surgical outcomes, and many reports have evaluated the benefit of bevacizumab prior to vitrectomy in these patients [145-148]. Several reports have documented the apparent pro-fibrotic effect of bevacizumab with contraction of fibrovascular membranes which may increased tractional retinal detachment [149] and require surgical treatment. Case reports document acute retinal fibrosis 1 day following bevacizumab despite acute resolution of the vascular component, with centripetal contraction of fibrovascular tissue and retinal detachment [150]. One series evaluated the efficacy of intravitreal bevacizumab 72 hour prior to vitrectomy or laser, finding improved visualisation in high risk ROP [151]. This finding has been demonstrated in other series [87,154], with no adverse effects attributable to bevacizumab in the short-term [152].

Author details

Vikas Tah¹, Walid Sharif², Imran Yusuf⁵, Marcus Posner⁴, Louise Ramskold³, Fariyah Tariq¹, Dev Mukhey² and Zuhair Sharif²

1 Stoke Mandeville Hospital, UK

2 UCL Institute of Ophthalmology, UK

3 East and North Hertfordshire NHS Trust, UK

4 Royal Free Hospital, UK

5 Oxford, UK

References

- [1] Hartnett ME, Penn JS. Mechanisms and management of retinopathy of prematurity. *New England Journal of Medicine*. 2012; 367:2515-2526.
- [2] Terry TL. Extreme prematurity and fibroblastic overgrowth of persistent vascular sheath behind each crystalline lens. *Am J Ophthalmol*. 1942;25:203-4
- [3] Akkoyun I, Oto S, Yilmaz G, Gurakan B, Tarcan A, Anuk D, Akgun S, Akova YA. Risk factors in the development of mild and severe retinopathy of prematurity. *J AA-POS*. 2006 Oct; 10(5):449-53
- [4] Kim TI, Sohn J, Pi SY, Yoon YH. Postnatal risk factors of retinopathy of prematurity. *Paediatr Perinat Epidemiol*. 2004 Mar; 18(2):130-4.

- [5] Coats DK, Aaron MM, Mohamed AH. Involution of retinopathy of prematurity after laser treatment: Factors associated with development of retinal detachment. *Am J Ophthalmol.* 2005;140:214-22
- [6] Fanaroff AA, Martin RJ, editors. Neonatal perinatal medicine. 7th ed. *Louis: Mosby;* 2002. pp. 676-74
- [7] Saugstad OD. Is oxygen more toxic than currently believed? *Pediatrics.* 2001; 108:1203-1205
- [8] Gilbert C. Retinopathy of prematurity ; a global perspective of the epidemics, population of babies at risk and implications for control. *Early Hum Dev.* 2008; 84:77-82
- [9] Bouzas L, Bauer G, Novali L et al. Retinopathy of prematurity in the XXI century in a developing country; an emergency that should be resolved. *Annals de paediatrica.* 2007; 66: 551-8
- [10] Chen Y, Li X. Characteristics of severe retinopathy of prematurity patients in China: a repeat of the first epidemic? *Br J Ophthalmol.* 2006; 90: 268-271
- [11] Palmer EA, Flynn JT, Hardy RJ et al. The cryotherapy for retinopathy cooperative study group. Incidence and early course of ROP. *Ophthalmology.* 1991; 98: 1628-1640
- [12] Good VW, Hardy RJ, Dobson V et al. Early Treatment for Retinopathy of Prematurity Cooperative Study Group. The incidence and course of retinopathy of prematurity; findings from the early treatment for retinopathy of prematurity study. *Pediatrics.* 2005; 116: 15-23 (<http://pediatrics.aappublications.org/cgi/content/full/116/1/15>)
- [13] Al-Amro SA, Al-Kharfi TM, Thabit AA et al. Retinopathy of prematurity at a university hospital in Riyadh, Saudi Arabia. *Saudi Medical Journal Online.* 2002. (<http://www.smj.org.sa/DetailArticle.asp?ArticleId=862>)
- [14] Hussan N, Clive J, Bhandari V. Current incidence of retinopathy of prematurity 1989-97. *Pediatrics.* 1999 Sep;104(3):e26 (<http://pediatrics.aappublications.org/cgi/content/full/104/e26>)
- [15] Fortes Filho JB, Eckert GU, Procianoy L. Incidence of retinopathy of prematurity in very low and in extremely low birthweight infants in a unit based approach in Brazil. *EYE(Lon).* Jan 2009; 23(1): 25-30 (<http://nature.com/eye/journal/v23/n/full/6702924a.html>)
- [16] Good WV. Screening for retinopathy of prematurity; no ophthalmologist required? *Brit Ophthalmol.* 2000; 84: 124-7
- [17] Shah VA, Yeo CL, LingYL et al. Incidence, risk factors of retinopathy of prematurity among very low birthweight infants in Singapore. *Annals Academy of Medicine.* 2005; 34: 169-178 (<http://annals.edu.sg/pdf//34vol200501/V34N2p169.pdf>)
- [18] M Begué N, Perapoch Lopez J. Retinopathy of prematurity; incidence, severity and outcome. *Anales de Pediatria.* 2003; 58; 156-61

- [19] Rekha S, Battu RR; Retinopathy of prematurity; incidence and risk factors. *Indian Pediatr.* 1996; 33(12): 999-1003 (<http://indianpediatrics.net/dec1996/999.pdf>)
- [20] The International Committee for the Classification of Retinopathy of Prematurity. An International Classification of Retinopathy of Prematurity.. *Arch Ophthalmol.* 1984;102: 1130-1134
- [21] An International Classification of Retinopathy of Prematurity. The International Committee for the Classification of Retinopathy of Prematurity. *Arch Ophthalmol.* 1987; 105
- [22] The International Classification of Retinopathy of Prematurity revisited. The International Committee for the Classification of Retinopathy of Prematurity. *Arch Ophthalmol.* 2005;123.
- [23] Lucey JF, Dangman B. A re-examination of the role of oxygen in retrolental fibroplasia. *Pediatrics.* 1984;73(1):82-96.
- [24] Michaelson IC. The mode of development of the vascular system of the retina with some observations on its significance for certain retinal diseases. *Trans Ophthalmol Soc.* 1948; 68:137–180.
- [25] Ashton N, Ward B, Serpell G. Effect of oxygen on developing retinal vessels with particular reference to the problem of retrolental fibroplasia. *Br J Ophthalmol.* 1954; 38:397–432.
- [26] Patz A, Eastham A, Higginbotham DH, Kleh T. Oxygen studies in retrolental fibroplasia. *Am J Ophthalmol.* 1953;36:1511–1522.
- [27] Kinsey VE, Arnold HJ, Kalina RE, et al. PaO₂ levels and retrolental fibroplasia: a report of the cooperative study. *Pediatrics.* 1977;60(5):655–668.
- [28] Flynn JT. Acute proliferative retrolental fibroplasia: multivariate risk analysis. *Trans Am Ophthalmol Soc.* 1983; 81:549–591.
- [29] Smith LE. Pathogenesis of retinopathy of prematurity. *Semin Neonatol.* 2003;8(6):469–473.
- [30] Tasman W, Patz A, McNamara JA, Kaiser RS, Trese MT, Smith BT. Retinopathy of prematurity: the life of a lifetime disease. *Am J Ophthalmol.* 2006;141(1):167–174.
- [31] Luttly GA, Chan-Ling T, Phelps DL, et al. Proceedings of the Third International Symposium on Retinopathy of Prematurity: an update on ROP from the lab to the nursery (November 2003, Anaheim, California) *Mol Vis.* 2006;12:532–580.
- [32] Silverman W. Retrolental fibroplasia: a modern parable. New York: *Grune and Stratton.* 1980.
- [33] Askie, LM. Optimal oxygen saturations in preterm infants: a moving target. *Current Opinion in Pediatrics.* 2013; 25: 2:188–192.

- [34] Palmer EA, Hardy RJ, Dobson V, Phelps DL, Quinn GE, Summers CG et al. International Committee for the Classification of Retinopathy of Prematurity. The International Classification of Retinopathy of Prematurity Revisited. *Arch Ophthalmol*. 2005;123:991-999.
- [35] Cryotherapy for Retinopathy of Prematurity Cooperative Group. Multicentre trial of cryotherapy for retinopathy of prematurity: Preliminary results. *Arch Ophthalmol*. 1988;106: 471-479.
- [36] Cryotherapy for Retinopathy of Prematurity Cooperative group. Multicentric trial of cryotherapy for retinopathy of prematurity. Three-month outcome. *Arch Ophthalmol* 1990;108: 195-204.
- [37] Cryotherapy for Retinopathy of Prematurity Cooperative Group. The natural ocular outcome of premature birth and retinopathy status at 1 year. *Arch Ophthalmol*. 1994; 112(7):903-912.
- [38] Cryotherapy for Retinopathy of Prematurity Cooperative group. Multicentric trial of cryotherapy for retinopathy of prematurity: natural history ROP: ocular outcome at 5 ½ years in premature infants with birth weight less than 1251 g. *Arch Ophthalmol*. 2002;120: 595-599.
- [39] Ellsbury, D, Ursprung, R. Comprehensive Oxygen Management for the Prevention of Retinopathy of Prematurity: The Pediatrix Experience. *Clinics in Perinatology*. 2010; 37:1: 203–215.
- [40] Flynn JT, Chan-Ling T. Retinopathy of prematurity: two distinct mechanisms that underlie zone 1 and zone 2 disease. *Am J Ophthalmol*. 2006; 142(1):46-59.
- [41] Stenson BJ, Tarnow-Mordi WO, Darlow Ba, et al. Oxygen Saturation and Outcomes in Pre-term Infants. *N Engl J Med*. 2013; 368:2094-2104.
- [42] Mills, MD. Evaluating the Cryotherapy for Retinopathy of Prematurity Study (CRYO-ROP). *Arch Ophthalmol*. 2007;125 (9):1276-1281.
- [43] The STOP-ROP Multi-center Study Group. Supplemental Therapeutic Oxygen for Pre-threshold Retinopathy of Prematurity (STOP-ROP), a randomized, controlled trial. I: primary outcomes. *Pediatrics*. 2000;105:295–310.
- [44] Chow, LC. et al. Can Changes in Clinical Practice Decrease the Incidence of Severe Retinopathy of Prematurity in Very Low Birth Weight Infants? *Pediatrics*. 2003;111:1:339-345.
- [45] Chen ML, Guo L, Smith LE, Dammann CE, Dammann O. High or low oxygen saturation and severe retinopathy of prematurity: a meta-analysis. *Pediatrics*. 2010;125:6: e1483-1492.

- [46] Fleck BW, Stenson, BJ. Retinopathy of Prematurity and the Oxygen Conundrum: Lessons Learned from Recent Randomized Trials. *Clinics in Perinatology*. 2013; 40: 2229–2240.
- [47] Wilson CM, Ells AL, Fielder AR. The Challenge of Screening for Retinopathy of Prematurity. *Royal College of Paediatrics and Child Health, Royal College of Ophthalmologists and British Association of Perinatal Medicine*. 2007.
- [48] Blakeman, TC. Evidence for Oxygen Use in the Hospitalized Patient: Is More Really the Enemy of Good? *Respiratory Care*. 2013;58 :10: 1679-169.
- [49] Guideline for the Screening and Treatment of Retinopathy of Prematurity. Royal College of Paediatrics and Child Health, Royal College of Ophthalmologists and British Association of Perinatal Medicine. 2008.
- [50] Fielder AR, Haines L, Scrivener R, Wilkinson AR, Pollock JI on behalf of the Royal Colleges of Ophthalmologists and Paediatrics and Child Health and the British Association of Perinatal Medicine. Retinopathy of prematurity in the UK II: audit of national guidelines for screening and treatment. *Eye*. 2002; 16(3):285-291.
- [51] Goble RR, Jones HS, Fielder AR. Are we screening too many babies for retinopathy of prematurity? *Eye*. 1997; 11(Pt 4):509-514.
- [52] Mathew MR, Fern AI, Hill R. Retinopathy of prematurity: are we screening too many babies? *Eye*. 2002; 16(5):538-542.
- [53] Early Treatment for Retinopathy of Prematurity Cooperative Group. Revised indications for the treatment of retinopathy of prematurity: results of the early treatment for retinopathy of prematurity randomized trial. *Arch Ophthalmol*. 2003; 121(12): 1684-1694.
- [54] AMERICAN ACADEMY OF OPHTHALMOLOGY, AMERICAN ASSOCIATION FOR PEDIATRIC OPHTHALMOLOGY AND STRABISMUS, AMERICAN ASSOCIATION OF CERTIFIED ORTHOPTISTS. Policy Statement: Screening Examination of Premature Infants for Retinopathy of Prematurity. *Pediatrics*. 2013;l: 131:89-195.
- [55] Reynolds JD, Dobson V, Quinn GE, Fielder AR, Palmer EA, Saunders RA et al. Evidence-based screening criteria for retinopathy of prematurity: natural history data from the CRYO-ROP and LIGHT-ROP studies. *Arch Ophthalmol* 2002; 120(11): 1470-1476.
- [56] Repka MX, Palmer EA, Tung B. Cryotherapy for Retinopathy of Prematurity Cooperative Group. Involution of retinopathy of prematurity. *Arch Ophthalmol* 2000; 118(5): 645-649.
- [57] Kanski J. Clinical Ophthalmology; A Systematic Approach (7th Ed) Butterworth Heinemann 2011.

- [58] Chen, J, Stahl, A, Hellstrom, A, Smith, LE. Current update on retinopathy of prematurity: screening and treatment. *Curr Opin Pediatr*. 2011; 23(2): 173–178.
- [59] Löfqvist C, Hansen-Pupp I, Andersson E, et al. Validation of a new retinopathy of prematurity screening method monitoring longitudinal postnatal weight and insulin like growth factor I. *Arch Ophthalmol* 2009;127:622-627.
- [60] Wu C, Löfqvist C, Smith LH, VanderVeen DK, Hellström A. Importance of early postnatal weight gain for normal retinal angiogenesis in very preterm infants: a multicenter study analyzing weight velocity deviations for the prediction of retinopathy of prematurity. *Arch Ophthalmol*. 2012;130:992–999.
- [61] Zepeda-Romero LC, Hård AL, Gomez-Ruiz LM, et al. Prediction of retinopathy of prematurity using the screening algorithm WINROP in a Mexican population of preterm infants. *Arch Ophthalmol* 2012; 130:720-3.
- [62] Mohamed, S, Murray, JC, Dagle, JM, Colaizy, T. Hyperglycemia as a risk factor for the development of retinopathy of prematurity. *BMC Pediatr*. 2013; 13
- [63] Piyasena C, Dhaliwal C, et al. Prediction of severe retinopathy of prematurity using the WINROP algorithm in a birth cohort in South East Scotland. *Archives of Disease in Childhood Fetal and Neonatal Edition*. 2014; 99:1 29-33.
- [64] Chiang MF, Keenan JD, Starren JB, Du YE, Schiff WM, Barile GR et al. Accuracy and reliability of remote retinopathy of prematurity diagnosis. *Arch Ophthalmol*. 2006; 124:322-327.
- [65] Chiang MF, Starren JB, Du YE, Keenan JD, Schiff WM, Barile GR et al. Remote image based retinopathy of prematurity diagnosis: a receiver operating characteristic analysis of accuracy. *Br J Ophthalmol*. 2006; 90(10):1292-1296.
- [66] Roth DB, Morales D, Feuer WJ, Hess D, Johnson RA, Flynn JT et al. Screening for retinopathy of prematurity employing the Retcam 120: sensitivity and specificity. *Arch Ophthalmol*. 2001; 119(2):268-272.
- [67] Capone, A. The Photographic Screening for Retinopathy of Prematurity Study Group. The Photographic Screening for Retinopathy of Prematurity Study (PhotoROP): Study design and baseline characteristics of enrolled patients. *Retina*. 2006; 26(7 Suppl):S4-S10.
- [68] Aslam T, Fleck B, Patton N, Trucco M, Azegrouz H. Digital image analysis of plus disease in retinopathy of prematurity. *Acta Ophthalmologica*. 2009;87:4: 368–377.
- [69] Wittenberg LA, Jonsson L, Chan RVP, Chiang, MF. Computer-Based Image Analysis for Plus Disease Diagnosis in Retinopathy of Prematurity. *Journal of Pediatric Ophthalmology and Strabismus*. 2012;49 :1: 11-19.

- [70] Gelman R, Martinez-Perez M, Vanderveen D, Moskowitz A, Fulton A. Diagnosis of Plus Disease in Retinopathy of Prematurity using Retinal Image multiscale Analysis. *Invest Ophthalmol Vis Sci*. 2005;46(12):4734-4738
- [71] Courtesy of Tygerberg Children's Hospital. From: <http://www.tch-trust.org.za/improve-the-care-of-children-and-babies-by-acquiring-the-most-modern-technology/>. (Accessed : 28/12/13)
- [72] Courtesy of Hoag Levins. Clarity Medical Solutions. From: <http://ldihealtheconomist.com/he000017.shtml>. (Accessed:24/12/14)
- [73] Courtesy of Minas Hambardzumyan.. From: <https://picasaweb.google.com/lh/photo/47DVdk1Ed1eD6wmgEtcVyw> (Accessed: 28/12/14)
- [74] Courtesy of BIOPHOTONICS. From: <http://photonics.com/Product.aspx?PRID=38590> (Accessed: 28/12/13)
- [75] Kinsey VE. Retrolental fibroplasia; cooperative study of retrolental fibroplasia and the use of oxygen. *AMA Arch Ophthalmol* 1956;56:481-543.
- [76] Higgins RD, Bancalari E, Willinger M, et al. Executive summary of the workshop on oxygen in neonatal therapies: controversies and opportunities for research. *Pediatrics* 2007;119:790-6.
- [77] Kirchner L, Weninger M, Unterasinger L, et al. Is the use of early nasal CPAP associated with lower rates of chronic lung disease and retinopathy of prematurity? Nine years of experience with the Vermont Oxford Neonatal Network. *J Perinat Med* 2005;33:60-6.
- [78] Flynn JT, Bancalari E, Bawol R, et al. Retinopathy of prematurity. A randomized, prospective trial of transcutaneous oxygen monitoring. *Ophthalmology* 1987;94:630-8.
- [79] Berkowitz BA, Berlin ES, Zhang W. Variable supplemental oxygen during recovery does not reduce retinal neovascular severity in experimental ROP. *Curr Eye Res* 2001;22:401-4.
- [80] Mills MD. STOP-ROP results suggest selective use of supplemental oxygen for pre-threshold ROP. *Arch Ophthalmol* 2000;118:1121-2.
- [81] Flynn JT, Bancalari E. Supplemental therapeutic oxygen for prethreshold retinopathy of prematurity (STOP-ROP), a randomized, controlled trial. I: Primary outcomes. *J Aapos* 2000;4:65-6.
- [82] Hay WW, Jr., Bell EF. Oxygen therapy, oxygen toxicity, and the STOP-ROP trial. *Pediatrics* 2000;105:424-5.
- [83] McGregor ML, Bremer DL, Cole C, et al. Retinopathy of prematurity outcome in infants with prethreshold retinopathy of prematurity and oxygen saturation >94% in room air: the high oxygen percentage in retinopathy of prematurity study. *Pediatrics* 2002;110:540-4.

- [84] Askie LM, Henderson-Smart DJ, Irwig L, et al. Oxygen-saturation targets and outcomes in extremely preterm infants. *N Engl J Med* 2003;349:959-67.
- [85] Askie LM, Brocklehurst P, Darlow BA, et al. NeOProM: Neonatal Oxygenation Prospective Meta-analysis Collaboration study protocol. *BMC Pediatr* 2011;11:6.
- [86] Good WV. Final results of the Early Treatment for Retinopathy of Prematurity (ETROP) randomized trial. *Trans Am Ophthalmol Soc* 2004;102:233-48; discussion 248-50.
- [87] Repka MX, Tung B, Good WV, et al. Outcome of eyes developing retinal detachment during the Early Treatment for Retinopathy of Prematurity Study (ETROP). *Arch Ophthalmol* 2006;124:24-30.
- [88] Multicenter trial of cryotherapy for retinopathy of prematurity. One-year outcome--structure and function. Cryotherapy for Retinopathy of Prematurity Cooperative Group. *Arch Ophthalmol* 1990;108:1408-16.
- [89] Palmer EA, Hardy RJ, Davis BR, et al. Operational aspects of terminating randomization in the Multicenter Trial of Cryotherapy for Retinopathy of Prematurity. Cryotherapy for Retinopathy of Prematurity Cooperative Group. *Control Clin Trials* 1991;12:277-92.
- [90] Hardy RJ, Davis BR, Palmer EA, et al. Statistical considerations in terminating randomization in the Multicenter Trial of Cryotherapy for Retinopathy of Prematurity. Cryotherapy for Retinopathy of Prematurity Cooperative Group. *Control Clin Trials* 1991;12:293-303.
- [91] Multicenter trial of cryotherapy for retinopathy of prematurity. 3 1/2-year outcome--structure and function. Cryotherapy for Retinopathy of Prematurity Cooperative Group. *Arch Ophthalmol* 1993;111:339-44.
- [92] Multicenter Trial of Cryotherapy for Retinopathy of Prematurity: ophthalmological outcomes at 10 years. *Arch Ophthalmol* 2001;119:1110-8.
- [93] Palmer EA, Hardy RJ, Dobson V, et al. 15-year outcomes following threshold retinopathy of prematurity: final results from the multicenter trial of cryotherapy for retinopathy of prematurity. *Arch Ophthalmol* 2005;123:311-8.
- [94] Hardy RJ, Palmer EA, Dobson V, et al. Risk analysis of prethreshold retinopathy of prematurity. *Arch Ophthalmol* 2003;121:1697-701.
- [95] Saunders RA, Donahue ML, Christmann LM, et al. Racial variation in retinopathy of prematurity. The Cryotherapy for Retinopathy of Prematurity Cooperative Group. *Arch Ophthalmol* 1997;115:604-8.
- [96] Kivlin JD, Biglan AW, Gordon RA, et al. Early retinal vessel development and iris vessel dilatation as factors in retinopathy of prematurity. Cryotherapy for Retinop-

athy of Prematurity (CRYO-ROP) Cooperative Group. *Arch Ophthalmol* 1996;114:150-4.

- [97] Schaffer DB, Palmer EA, Plotsky DF, et al. Prognostic factors in the natural course of retinopathy of prematurity. The Cryotherapy for Retinopathy of Prematurity Cooperative Group. *Ophthalmology* 1993;100:230-7.
- [98] Quinn GE, Dobson V, Biglan A, et al. Correlation of retinopathy of prematurity in fellow eyes in the cryotherapy for retinopathy of prematurity study. The Cryotherapy for Retinopathy of Prematurity Cooperative Group. *Arch Ophthalmol* 1995;113:469-73.
- [99] Dobson V, Quinn GE, Tung B, et al. Comparison of recognition and grating acuities in very-low-birth-weight children with and without retinal residua of retinopathy of prematurity. Cryotherapy for Retinopathy of Prematurity Cooperative Group. *Invest Ophthalmol Vis Sci* 1995;36:692-702.
- [100] Dobson V, Quinn GE, Summers CG, et al. Effect of acute-phase retinopathy of prematurity on grating acuity development in the very low birth weight infant. The Cryotherapy for Retinopathy of Prematurity Cooperative Group. *Invest Ophthalmol Vis Sci* 1994;35:4236-44.
- [101] Reynolds J, Dobson V, Quinn GE, et al. Prediction of visual function in eyes with mild to moderate posterior pole residua of retinopathy of prematurity. Cryotherapy for Retinopathy of Prematurity Cooperative Group. *Arch Ophthalmol* 1993;111:1050-6.
- [102] Quinn GE, Dobson V, Repka MX, et al. Development of myopia in infants with birth weights less than 1251 grams. The Cryotherapy for Retinopathy of Prematurity Cooperative Group. *Ophthalmology* 1992;99:329-40.
- [103] Bremer DL, Palmer EA, Fellows RR, et al. Strabismus in premature infants in the first year of life. Cryotherapy for Retinopathy of Prematurity Cooperative Group. *Arch Ophthalmol* 1998;116:329-33.
- [104] Summers G, Phelps DL, Tung B, et al. Ocular cosmesis in retinopathy of prematurity. The Cryotherapy for Retinopathy of Prematurity Cooperative Group. *Arch Ophthalmol* 1992;110:1092-7.
- [105] Gilbert WS, Quinn GE, Dobson V, et al. Partial retinal detachment at 3 months after threshold retinopathy of prematurity. Long-term structural and functional outcome. Multicenter Trial of Cryotherapy for Retinopathy of Prematurity Cooperative Group. *Arch Ophthalmol* 1996;114:1085-91.
- [106] Quinn GE, Dobson V, Hardy RJ, et al. Visual fields measured with double-arc perimetry in eyes with threshold retinopathy of prematurity from the cryotherapy for retinopathy of prematurity trial. The CRYO-Retinopathy of Prematurity Cooperative Group. *Ophthalmology* 1996;103:1432-7.

- [107] Quinn GE, Dobson V, Hardy RJ, et al. Effect of retinal ablative therapy for threshold retinopathy of prematurity: results of Goldmann perimetry at the age of 10 years. *Arch Ophthalmol* 2001;119:1120-5.
- [108] Quinn GE, Dobson V, Siatkowski R, et al. Does cryotherapy affect refractive error? Results from treated versus control eyes in the cryotherapy for retinopathy of prematurity trial. *Ophthalmology* 2001;108:343-7.
- [109] O'Keefe M, Burke J, Algawi K, et al. Diode laser photocoagulation to the vascular retina for progressively advancing retinopathy of prematurity. *Br J Ophthalmol* 1995;79:1012-4.
- [110] Axer-Siegel R, Snir M, Cotlear D, et al. Diode laser treatment of posterior retinopathy of prematurity. *Br J Ophthalmol* 2000;84:1383-6.
- [111] Rezai KA, Elliott D, Ferrone PJ, et al. Near confluent laser photocoagulation for the treatment of threshold retinopathy of prematurity. *Arch Ophthalmol* 2005;123:621-6.
- [112] Gonzalez VH, Giuliari GP, Banda RM, et al. Confluent laser photocoagulation for the treatment of retinopathy of prematurity. *J Pediatr Ophthalmol Strabismus* 2010;47:81-5; quiz 86-7.
- [113] Banach MJ, Ferrone PJ, Trese MT. A comparison of dense versus less dense diode laser photocoagulation patterns for threshold retinopathy of prematurity. *Ophthalmology* 2000;107:324-7; discussion 328.
- [114] Uparkar M, Sen P, Rawal A, et al. Laser photocoagulation (810 nm diode) for threshold retinopathy of prematurity: a prospective randomized pilot study of treatment to ridge and avascular retina versus avascular retina alone. *Int Ophthalmol* 2011;31:3-8.
- [115] Steinmetz RL, Brooks HL, Jr. Diode laser photocoagulation to the ridge and avascular retina in threshold retinopathy of prematurity. *Retina* 2002;22:48-52.
- [116] Tasman W. To laser the ridge or not laser the ridge, that is the question. *Retina* 2002;22:4-5.
- [117] Ells AL, Gole GA, Lloyd Hildebrand P, et al. Posterior to the ridge laser treatment for severe stage 3 retinopathy of prematurity. *Eye (Lond)* 2013;27:525-30.
- [118] Mintz-Hittner HA, Kuffel RR, Jr. Intravitreal injection of bevacizumab (avastin) for treatment of stage 3 retinopathy of prematurity in zone I or posterior zone II. *Retina* 2008;28:831-8.
- [119] Mintz-Hittner HA, Kennedy KA, Chuang AZ. Efficacy of intravitreal bevacizumab for stage 3+retinopathy of prematurity. *N Engl J Med* 2011;364:603-15.
- [120] Kim J, Kim SJ, Chang YS, et al. Combined Intravitreal Bevacizumab Injection and Zone I Sparing Laser Photocoagulation in Patients with Zone I Retinopathy of Prematurity. *Retina* 2013.

- [121] Sahin A, Sahin M, Cingu AK, et al. Intravitreal bevacizumab monotherapy for retinopathy of prematurity. *Pediatr Int*.
- [122] Dani C, Frosini S, Fortunato P, et al. Intravitreal bevacizumab for retinopathy of prematurity as first line or rescue therapy with focal laser treatment. A case series. *J Matern Fetal Neonatal Med* 2012;25:2194-7.
- [123] Spandau U. What is the optimal dosage for intravitreal bevacizumab for retinopathy of prematurity? *Acta Ophthalmol* 2013;91:e154.
- [124] Mireskandari K, Adams GG, Tehrani NN. Recurrence of retinopathy of prematurity following bevacizumab monotherapy: is it only the tip of the iceberg? *JAMA Ophthalmol* 2013;131:544-5.
- [125] Harder BC, Schlichtenbrede FC, von Baltz S, et al. Intravitreal bevacizumab for retinopathy of prematurity: refractive error results. *Am J Ophthalmol* 2013;155:1119-1124 e1.
- [126] Karaca C, Oner AO, Mirza E, et al. Bilateral effect of unilateral bevacizumab injection in retinopathy of prematurity. *JAMA Ophthalmol* 2013;131:1099-101.
- [127] Orozco-Gomez LP, Hernandez-Salazar L, Moguel-Ancheita S, et al. Laser-ranibizumab treatment for retinopathy of prematurity in umbral-preumbral disease. Three years of experience. *Cir Cir* 2011;79:207-214, 225-32.
- [128] Mota A, Carneiro A, Breda J, et al. Combination of intravitreal ranibizumab and laser photocoagulation for aggressive posterior retinopathy of prematurity. *Case Rep Ophthalmol* 2011;3:136-41.
- [129] Castellanos MA, Schwartz S, Garcia-Aguirre G, et al. Short-term outcome after intravitreal ranibizumab injections for the treatment of retinopathy of prematurity. *Br J Ophthalmol* 2013;97:816-9.
- [130] Lin CJ, Chen SN, Hwang JF. Intravitreal ranibizumab as salvage therapy in an extremely low-birth-weight infant with rush type retinopathy of prematurity. *Oman J Ophthalmol*;5:184-6.
- [131] Jang SY, Choi KS, Lee SJ. Delayed-onset retinal detachment after an intravitreal injection of ranibizumab for zone I plus retinopathy of prematurity. *J Aapos* 2010;14:457-9.
- [132] Autrata R, Krejcirova I, Senkova K, et al. Intravitreal pegaptanib combined with diode laser therapy for stage 3+retinopathy of prematurity in zone I and posterior zone II. *Eur J Ophthalmol* 2012;22:687-94.
- [133] Mintz-Hittner HA. Intravitreal pegaptanib as adjunctive treatment for stage 3+ROP shown to be effective in a prospective, randomized, controlled multicenter clinical trial. *Eur J Ophthalmol* 2012;22:685-6.
- [134] Hartnett ME. Features associated with surgical outcome in patients with stages 4 and 5 retinopathy of prematurity. *Retina* 2003;23:322-9.

- [135] Sears JE, Sonnie C. Anatomic success of lens-sparing vitrectomy with and without scleral buckle for stage 4 retinopathy of prematurity. *Am J Ophthalmol* 2007;143:810-3.
- [136] Ratanasukon M, Visaetsilpanonta S, Tengtrisorn S, et al. Outcomes of scleral buckling for stage 4 retinopathy of prematurity in Thai children. *J Med Assoc Thai* 2006;89:1659-64.
- [137] Hinz BJ, de Juan E, Jr., Repka MX. Scleral buckling surgery for active stage 4A retinopathy of prematurity. *Ophthalmology* 1998;105:1827-30.
- [138] Chow DR, Ferrone PJ, Trese MT. Refractive changes associated with scleral buckling and division in retinopathy of prematurity. *Arch Ophthalmol* 1998;116:1446-8.
- [139] Choi MY, Yu YS. Efficacy of removal of buckle after scleral buckling surgery for retinopathy of prematurity. *J Aapos* 2000;4:362-5.
- [140] Ertzbischoff LM. A systematic review of anatomical and visual function outcomes in preterm infants after scleral buckle and vitrectomy for retinal detachment. *Adv Neonatal Care* 2004;4:10-9.
- [141] Quinn GE, Dobson V, Barr CC, et al. Visual acuity of eyes after vitrectomy for retinopathy of prematurity: follow-up at 5 1/2 years. The Cryotherapy for Retinopathy of Prematurity Cooperative Group. *Ophthalmology* 1996;103:595-600.
- [142] Singh R, Reddy DM, Barkmeier AJ, et al. Long-term visual outcomes following lens-sparing vitrectomy for retinopathy of prematurity. *Br J Ophthalmol* 2012;96:1395-8.
- [143] Choi J, Kim JH, Kim SJ, et al. Long-term results of lens-sparing vitrectomy for progressive posterior-type stage 4A retinopathy of prematurity. *Korean J Ophthalmol* 2012;26:277-84.
- [144] Hartnett ME, Maguluri S, Thompson HW, et al. Comparison of retinal outcomes after scleral buckle or lens-sparing vitrectomy for stage 4 retinopathy of prematurity. *Retina* 2004;24:753-7.
- [145] Kychenthal A, Dorta P. Vitrectomy after intravitreal bevacizumab (Avastin) for retinal detachment in retinopathy of prematurity. *Retina*;30:S32-6.
- [146] Xu Y, Zhang Q, Kang X, et al. Early vitreoretinal surgery on vascularly active stage 4 retinopathy of prematurity through the preoperative intravitreal bevacizumab injection. *Acta Ophthalmol*;91:e304-10.
- [147] Axer-Siegel R, Snir M, Ron Y, et al. Intravitreal bevacizumab as supplemental treatment or monotherapy for severe retinopathy of prematurity. *Retina*;31:1239-47.
- [148] Wu WC, Yeh PT, Chen SN, et al. Effects and complications of bevacizumab use in patients with retinopathy of prematurity: a multicenter study in taiwan. *Ophthalmology*;118:176-83.

- [149] Sun HJ, Choi KS, Lee SJ. Adjunctive effect of intravitreal bevacizumab prior to lens-sparing vitrectomy in aggressive posterior retinopathy of prematurity: a case report. *Jpn J Ophthalmol* 2012;56:476-80.
- [150] Honda S, Hirabayashi H, Tsukahara Y, et al. Acute contraction of the proliferative membrane after an intravitreal injection of bevacizumab for advanced retinopathy of prematurity. *Graefes Arch Clin Exp Ophthalmol* 2008;246:1061-3.
- [151] Law JC, Recchia FM, Morrison DG, et al. Intravitreal bevacizumab as adjunctive treatment for retinopathy of prematurity. *J Aapos* 2010;14:6-10.
- [152] Kychenthal A, Dorta P. Vitrectomy after intravitreal bevacizumab (Avastin) for retinal detachment in retinopathy of prematurity. *Retina* 2010;30:S32-6.
- [153] Xu Y, Zhang Q, Kang X, et al. Early vitreoretinal surgery on vascularly active stage 4 retinopathy of prematurity through the preoperative intravitreal bevacizumab injection. *Acta Ophthalmol* 2013;91:e304-10.
- [154] Ittiara S, Blair MP, Shapiro MJ, et al. Exudative retinopathy and detachment: a late reactivation of retinopathy of prematurity after intravitreal bevacizumab. *J Aapos* 2013;17:323-5

