

# We are IntechOpen, the world's leading publisher of Open Access books Built by scientists, for scientists

6,900

Open access books available

186,000

International authors and editors

200M

Downloads

Our authors are among the

154

Countries delivered to

TOP 1%

most cited scientists

12.2%

Contributors from top 500 universities



WEB OF SCIENCE™

Selection of our books indexed in the Book Citation Index  
in Web of Science™ Core Collection (BKCI)

Interested in publishing with us?  
Contact [book.department@intechopen.com](mailto:book.department@intechopen.com)

Numbers displayed above are based on latest data collected.  
For more information visit [www.intechopen.com](http://www.intechopen.com)



---

# Paranasal Sinus Mucocèles – Ophthalmic Manifestations, Radiological Imaging, Endoscopic Endonasal Marsupialization and Outcome

---

Balwant Singh Gendeh

Additional information is available at the end of the chapter

<http://dx.doi.org/10.5772/58331>

---

## 1. Introduction

Langeback first described paranasal sinus mucocèles in 1820. It was only in the early 1900s that mucocèles were given their name by Rollet and popularized by Gerber, who published 178 cases. In 1995, Lambert attributed frontal or ethmoid mucocèles as the most common nasal condition to produce proptosis [1]

A mucocèle is an epithelial-lined mucus containing sac that fills a paranasal sinus and is able to expand by alternative bone resorption and bone formation. A mucocèle occurs when a sinus ostium or a compartment of a septated sinus becomes obstructed, thus causing the sinus cavity to become filled with mucus or to become airless. Paranasal sinus mucocèles may result from inflammation, tumor, trauma or surgical manipulation [2]. Because of the anatomic proximity of the orbit, the pathologic process of paranasal sinus mucocèle will easily affect the orbit [3,4]. Anatomically, the frontal, ethmoid, sphenoid and maxillary sinuses all interface with the orbit. The maxillary sinus shares the floor of the orbit, the frontal sinus is part of the orbital roof, the ethmoid extends along most of the medial wall of orbit and the sphenoid almost completely surrounds the orbital apex [3, 4]. Thus, mucocèles of the paranasal sinuses can easily affect the orbit and cause ophthalmic symptoms such as proptosis, blurred vision and displacement of globe [4,5]. Patients with paranasal mucocèles with orbital symptoms are often seen by the ophthalmologist first and then referred to otorhinolaryngologist [5]. Occasionally they can present with intracranial complications.

It is essential to differentiate a mucocèle from a mucus retention cyst. A mucus retention cyst is just a fluid filled sac along the sinus lining which does not expand and push into the eye socket, nose or brain and does not cause problems in the vast majority of cases. Notably, mucus

retention cysts in the sinuses are more common than expected. Infact, about 30-40% of the population with absolutely no complaints of sinus problems will have cysts of the paranasal sinuses when they have CT scans performed. Most retention cysts of sinuses spontaneously shrink or do not change in size over the long term [6]. In the absence of associated complaints “wait and see” may be the appropriate management strategy for these retention cysts.

2. Material and methods

From 2005 to 2012, 13 patients with paranasal sinus mucoceles were treated with wide endoscopic endonasal marsupialization at the UKM Medical Center in Kuala Lumpur, Malay-sia. Review of the patients’ complete medical records, including out-patient clinical records, operative notes and reports of imaging and histopathology were performed. The radiological imaging (CT/MRI) on preoperative coronal and axial views were reviewed.

3. Results

The demographic data on the 13 patients includes the age, sex, race, clinical presentation, type of radiological imaging performed, the surgical details and the post-operative follow-up are listed in Table 1. The most common sinus involved was the frontal, followed by the ethmoid, maxillary and sphenoid (Table 2). The most common clinical presentation was headache followed by eye and nasal symptoms (Table 3). Figure 1 shows a radiological image of a right ethmoidal mucocele in an adult patient with diplopia and headache. Figure 2 shows a radiological image of a gross right frontal mucocele in an adult patient with headache, reduced vision and proptosis. Figure 3 shows a radiological image of a sphenoid mucocele in a child with headache and vomiting. Figure 4 shows a radiological image of left maxillary mucocele in an adult patient with nasal blockage and foul smelling discharge.

Patient / Age/sex/ race	Presentation	Sinus involvement on endoscopy	Imaging	Surgery	Follow-up
1. 40/M/C	supra orbital swelling, no diplopia or nasal symptoms	Left frontal and ethmoid sinuses involvement	CT: Expansile cystic mass Lt fronto ethmoid region	Endoscopic marsupialization of fronto-ethmoidal mucocele	Symptom free at 1 year follow up with no sign of recurrence
2. 59/M/C	Right frontal swelling with diplopia	Right frontal sinus involvement	CT: Expansile cystic lesion pushing interfrontal sinus septum with	Bicoronal flap cranialization with endoscopic endonasal frontal sinusotomy and marsupialization	Symptom free at 1 year follow up with no evidence of recurrence

Patient / Age/sex/ race	Presentation	Sinus involvement on endoscopy	Imaging	Surgery	Follow-up
			orbital roof involvement		
3. 40/M/M	Nasal block, rhinorrhoea with anosmia	Right frontal sinus involvement with bilateral nasal polyposis	CR & MRI: Right frontal expansile cystic mass with intracranial extension, no evidence of mass effect or ring enhancement	Endoscopic right frontal sinusotomy and bilateral ethmoidectomy with marsupialization	Symptoms improvement with no evidence of recurrence of nasal polyps at 6 month follow-up
4. 55/F/M	Headaches with, right diplopia	Right ethmoid sinuses involvement	CT & MRI: Expansile right ethmoidal mass with thinning of lamina papyracea	Endoscopic anterior and posterior ethmoidectomy with marsupialization	Symptom free at 6 month follow up with no evidence of recurrence
5. 59/M/Bengali	Headaches, proptosis with reduced left eye movement	Bilateral frontal sinus involvement	CT: Expansile mass involving bilateral frontal sinuses	Endoscopic drainage of bilateral frontal mucopyocele with marsupialization	Symptom free at 6 month follow up with no evidence of recurrence
6. 73/M/C	Reduced vision, eye pain, headaches with nasal blockage	Sphenoid sinus involvement	CT: Expansile mass within sphenoid sinus compressing on optic nerves	Endoscopic sphenoethmoidectom y and marsupialization	Symptom free at 1 year follow up with no evidence of recurrence
7. 75/F/C	Left epiphora with swelling at medial cantus	Left Fronto- Ethmoid sinuses involvement	CT: Opacification of left frontal and ethmoidal sinuses	Endoscopic left frontal sinusotomy with anterior and posterior ethmoidectomy with marsupialization	Symptom free at 1 year follow up with no evidence of recurrence
8. 71/F/C	Right nasal blockage, rhinorrhea, sneezing with epiphora	Right maxillary sinus involvement	CT: Hypodense mass in right maxillary sinus with remodeling of maxillary wall and hard plate	Endoscopic right MMA with Marsupialization	Symptom free at 6 months follow up with no evidence of recurrence

Patient / Age/sex/ race	Presentation	Sinus involvement on endoscopy	Imaging	Surgery	Follow-up
9. 63/F/C	Pain left eye with reduced vision and headaches	Left spheno- Ethmoid sinuses involvement	CT & MRI: Bilateral opacity of ethmoid and sphenoid sinuses with evidence of compression of optic nerve and cavernous sinus	Endoscopic ethmoidectomy with marsupialization	Symptom free at 1 year follow up with no evidence of recurrence
10. 39/M/I	Headaches with right ptosis, and diplopia	Right frontal sinus involvement	MRI: Opacity within right frontal sinus with mass effect on right superior and medial wall	Endoscopic right frontal sinusotomy with marsupialization	Symptoms improvement with no evidence of recurrence at 1 year follow up
11. 8/M/I	Headaches with vomiting	Sphenoid sinus involvement	MRI: Expansile mass within sphenoid sinus involving the sphenoidal recess	Endoscopic sphenoidectomy with marsupialization	Symptoms improved with no recurrence at 3 months
12. 62/M/C	Lt nasal blockage with foul smelling nasal discharge	Left maxillary sinus involvement	CT: Expansile left maxillary mass	Endoscopic wide left MMA with marsupialization	Post DXT NPC with no recurrence at 3 months
13. 58/M/M	Rt nasal blockage with foul smelling nasal discharge	Right maxillary sinus involvement	CT: Expansile right maxillary mass	Endoscopic wide right MMA with marsupialization	Symptoms improved with no recurrence at 6 months
M – Male					
F – Female					
Race-M (Malay), C (Chinese), I (Indian)					
Rt– Right					
Lt – Left					
MMA – Middle meatal antrostomy					

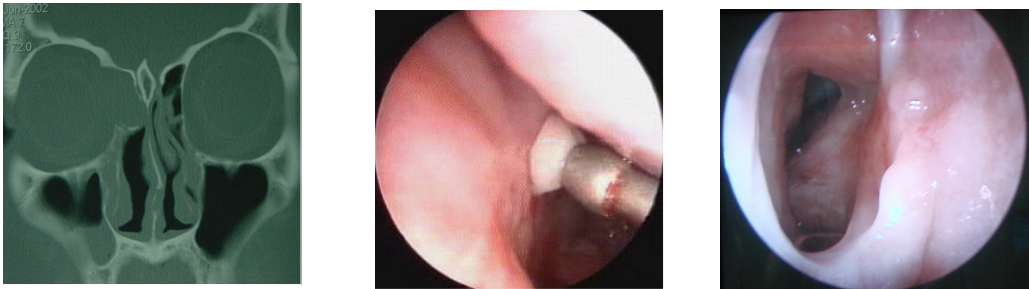
**Table 1.** Dermographic presentation of 13 patients with paranasal sinus mucocele

	Frontal	Ethmoid	Maxillary	Sphenoid
Number of cases	6	4	3	3

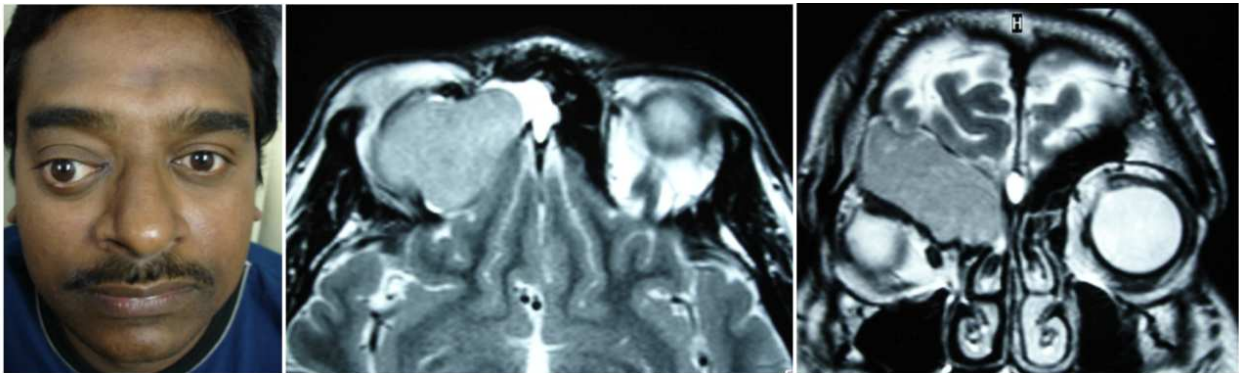
**Table 2.** Sites of involvement of paranasal sinuses

	Headache	Diplopia	Proptosis	Reduced vision	Reduced eye movement	Nasal symptoms	Vomiting
Number of cases	7	2	5	3	2	5	1

**Table 3.** Clinical presentation of head and eye symptoms

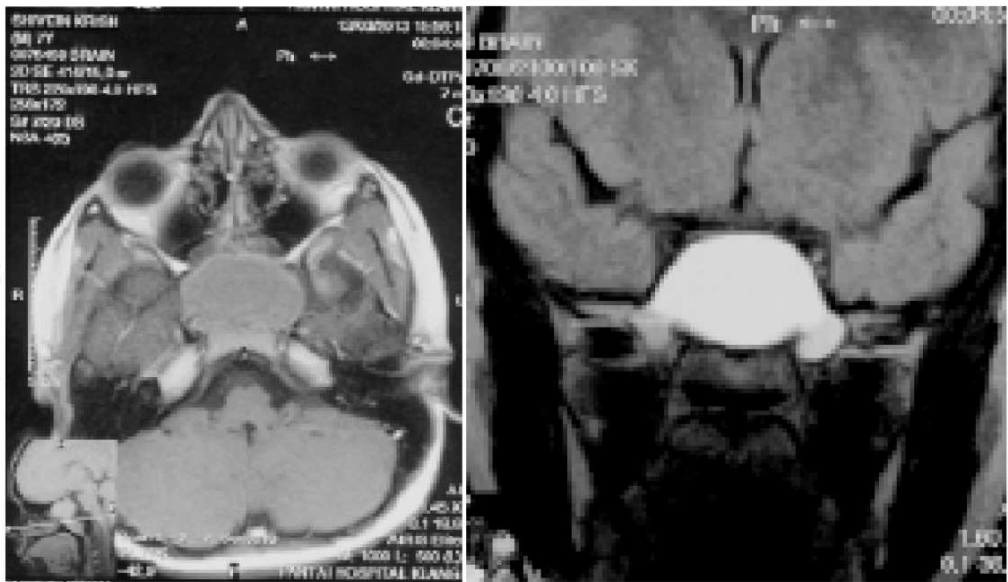

**Figure 1.** Coronal CT imaging of patient number 4 showing a right iatrogenic frontoethmoid mucocoele with intraoperative endoscopic drainage and follow up at 3 months post surgery showing a patent frontal sinostomy

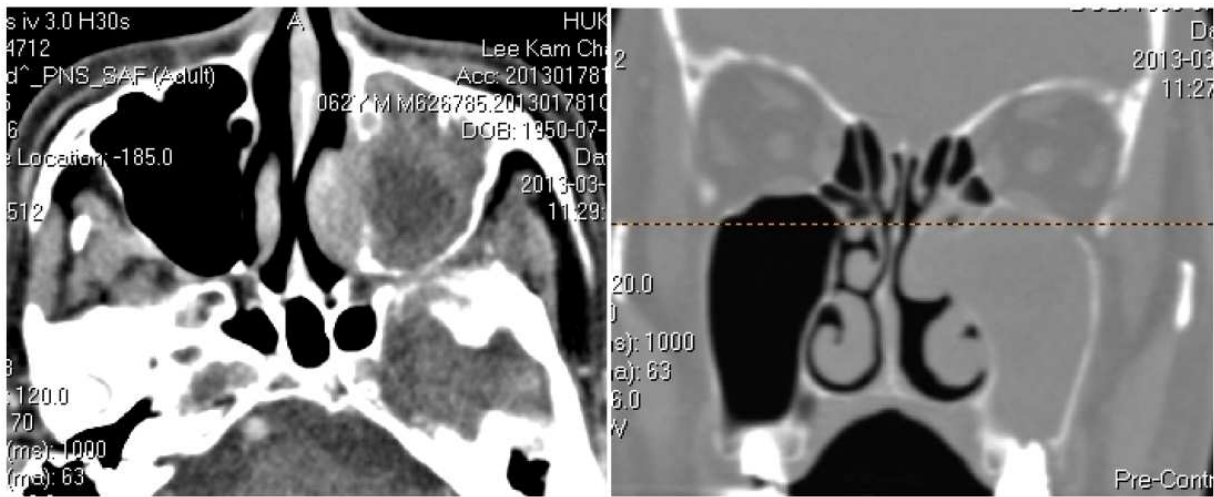


**Figure 2.** Picture of patient number 10 showing gross right protosis and the respective axial and coronal MRI sections revealing expansile frontal sinus lesion with loss of scalloping suggestive of a mucocoele





**Figure 3.** Axial views and coronal sections of T1 and T2 weighted MRI images of patient number 11 showing an expansile sphenoid lesion suggestive of mucocele in a 8-year Indian male.



**Figure 4.** Axial views and coronal sections of CT images of patient number 12 showing a left expansile mass in the maxillary sinus suggestive of a mucocele in a 62 year male Chinese.

3.1. Surgical technique

All patients were operated under general anaesthesia. The patient is placed in supine position with head slightly elevated. Packing that has been soaked in a 4% cocaine solution is placed in the nasal cavity to initiate mucosal vasoconstriction. Both eyes are exposed in the surgical field. Under endoscopic visualization, submucosal injections of 1% lidocaine with epinephrine are administred along the lateral nasal wall and middle turbinate. Briefly the endoscopic endonasal marsupilization is as follows: wide middle meatal antrostomy and marsupilization

for maxillary mucocèle; initially complete ethmoidectomy followed by removal of antero-inferior wall of the sphenoid mucocèle and marsupilizing the cavity for ethmoid and sphenoid mucocèle;uncinectomy, anterior ethmoidectomy and widening of the frontal recess (Draf type 2 procedure) and marsupilization for fronto-ethmoid mucocèle. Patients' are observed at weekly follow-up with secretion aspirated and sinonasal washing with saline solution upto one month post-surgery. Patients are checked upon at follow-ups every three months for first year than once a year.

#### 4. Discussion

Paranasal sinus mucocèles are rare in children but relatively common in adults. In the literature, the etiologies of pediatric mucocèles have focused on impaired secretion process such as cystic fibrosis, pathological pneumatization processus, atopy and trauma, [7,8].

Mucocèles are commonly caused by post-operative ostial obstruction or secondary to trauma but can also present as primary disease. Paranasal sinus mucocèles predominantly occur in the fronto-ethmoid region (64%), followed by the maxillary sinus (18.6%), the sphenoid sinus (8.4%) and the posterior ethmoid sinus (6.7%) [9] which was similar to that in our study. Another common site for occurrence of mucocèle is within the supraorbital ethmoid region. Primary sphenoid mucocèles can be found in association with chronic ethmoid sinusitis and/or nasal polyposis and are uncommon in isolation [10].

In the literature review, proptosis, periorbital pain and impairment of ocular mobility were the most common manifestations of mucocèles in the anterior paranasal sinuses while blurred vision and impairment of ocular mobility [11] were frequently seen in mucocèles in the posterior sinuses. Mucocèles of the anterior paranasal sinuses may expand the anterior and medial sinus walls, pushing the globe outward and downward and restrict movement of the extraocular muscles, thus causing proptosis and impairment of ocular mobility [4, 12, 13].

The natural development of sinus mucocèles consists of gradual expansion. This slow growing expansion can result in bone remodeling, bulging and erosion and reaches adjacent structures such as other sinuses, orbit, clivus, skull base or brain. In case of an intracranial complication, infection may even lead to conditions such as meningitis, subdural or brain abscess [14]. By extension into adjacent structures, the mucocèle gives rise to a variety of clinical manifestations. The most common symptoms reported are headaches, facial pain, anosmia, ocular displacement, ocular palsy and visual failure. Visual symptoms in patients with sphenoid mucocèle include diplopia, ocular muscle paresis, exophthalmus and complete visual loss [15, 16, 17, 18]. One should also be aware of unusual presentation including hypopituitarism [19, 20, 21].

The anatomical proximity and fragility of the orbital structures explains the high occurrence of ocular complications in sinusopathy. As the optic nerve enters the orbital apex from the intracranial portion, the nerve is encompassed by the narrow bony canal and is in close proximity to the posterior ethmoid and/or sphenoid sinus. In majority of cases the bony wall



between the nerve and the sinuses is as thin as 40-60µm [22, 23]. Intracranially the optic nerve is covered by the pia mater, arachnoid and CSF. As the nerve enters the canal, it is surrounded by two layers of nerve sheath, the outer which is continuous with the periorbita and the inner which ensheathes the nerve to the eyeball. The optic nerve canal can be identified as a semi-circular tube when viewed from the inside of the posterior ethmoid or sphenoid sinus. Since the optic nerve canal contains the nerve and two layers of nerve sheath without any soft tissues such as fat, pressure due to expansion of the mucocoele may easily impact the nerve if the thin protecting bony wall is resorbed or if it is dehiscent congenitally.

Blurred vision is more often associated with mucocoeles in the posterior than anterior paranasal sinuses and can affect the optic or other cranial nerves via two pathways. Firstly, expansion of the paranasal sinus wall may compress the optic nerve or compromise its blood supply with subsequent optic atrophy [12, 24, 25]. Secondly, optic neuritis may result from direct spread of suppuration from adjacent paranasal sinuses via bone loss or bone fissure [12, 26]. Both optic nerve compression and neuritis can cause deterioration of visual acuity [12, 26]. Besides the optic nerve, other cranial nerves (abducent or oculomotor) passing through the orbital apex or superior orbital fissure may be involved, thus resulting in impairment of ocular mobility [12, 25, 26, 27].

In a review of 47 patients suffering from ethmoid or sphenoid mucocoeles, Moriyama et al [28] highlighted 70 per cent of patients first sought help from the ophthalmology department. The mucocoele may compress the optic canal and cause visual disturbances, leading to loss of eye sight in severe cases. Further to direct pressure, ischemia or venous congestion around the optic nerve subsequently occurs [28]. Besides compression and its local effects, inflammation due to infection of the mucocoele can spread to the nerve through zones of bony erosion. Therefore, the visual loss may be due to a local inflammatory response which responds to steroid therapy [29] but further diagnosis and immediate surgical drainage are imperative.

Preoperative diagnosis is usually based on CT and MRI. On CT scan, mucocoeles usually fill a sinus structure and bulge against adjacent anatomical structures, but without infiltration and usually the bony margins of the lesion are well defined. MRI of mucocoeles in both T1 and T2 weighted images show variable signal intensities as depicted in Fig 3. CT scans are preferable for definitive evaluation, assessment of bony involvement and presurgical planning. MRI scans are helpful in the evaluation of orbital or intracranial extension and in ruling out a neoplasm or fungus disease [30]. Therefore, CT and MRI imaging are complementary for the diagnostic evaluation of an expansile mass around the posterior ethmoid and sphenoid sinus. In the differential diagnosis, one should rule out a mucopyocoele, sinus malignancy, hypophyseal tumor, craniopharyngioma, meningioma or optic nerve glioma, intracranial chordoma, cholesteatoma and neoplastic lesions of nasopharynx.

An urgent surgical intervention is advocated in a paranasal sinus mucocoele with vision loss. The endoscopic endonasal approach is the most convenient for the treatment of mucocoele in view of easy access, lower morbidity and a reduction in potential complications compared to intracranial route [31]. Several recent literatures have reported successful results in the management of mucocoeles with endoscopic marsupialization as the main choice of treatment [32]. It has the advantage of magnification of the operative field, is minimally invasive,

preserves the sinus architecture and produces good long-term results with adequate post-operative care. Some conditions are not suitable for endoscopic surgery alone including a far laterally placed frontal mucocèle, hypertrophic bone occluding the area of the fronto-nasal recess and a mucocèle arising secondarily from a malignancy [33]. With respect to patient number 2, the extensive mucocèle with intraorbital extension was removed using both an endoscopic and an external approach through bicoronal flap and cranialization [34].

The paranasal sinus mucocèle is widely opened and a sufficient part of the wall or outflow pathway is resected for adequate drainage and ventilation. With exposure of the dura or peri-orbital wall, the wall of the mucocèle acts as a cover and no attempts are made to remove this mucosal lining to protect the orbit, optic nerve, dura and carotid artery. On adequate marsupilization of the mucocèle, one should expect a rapid improvement of visual acuity but in cases with complete loss of vision prior to surgery, the prognosis may be much poorer. The micro-debrider is used in endonasal surgery with great easiness and good surgical outcome. The degree of improvement of the visual acuity after mucocèle marsupilization depends on the severity of the initial loss prior to surgery, the mode of development and the location of the mucocèle and the time from onset of the ophthalmological disorder until the surgical marsupilization [9]. Prompt surgical treatment is necessary in order to avoid permanent visual impairment and other sequel [3, 18]. If vision is seriously impaired, immediate surgery should be performed, preferably within 24 hours after the onset of visual disturbances [35].

## 5. Differential diagnosis

### 5.1. Paranasal sinus tumors

The differential diagnosis of mucocèle includes paranasal sinus tumors as shown in Table 4.

Non-neoplastic	Neoplastic
Mucosal cyst	Papillomas
Antrochonal polyp	Mesenchymal tumors (fibroma, lipoma, myxoma)
Fungal disease	Vasiform tumors (hemangioma, aneurysmal bone cyst, hemangiopericytoma)
Cholesterol granuloma	Tumors of muscle origin (leiomyoma, rhabdomyoma)
Hematoma	Odontogenic tumors
Antrolithiasis	Fibroosseous lesions (osteoma, ossifying fibroma, fibrous dysplasia, osteoblastoma)
Eosinophilic angiocentric fibrosis	Neuroectodermal tumors (schwannoma, neurofibroma)

**Table 4.** Classification of benign lesions of the paranasal sinus tumors

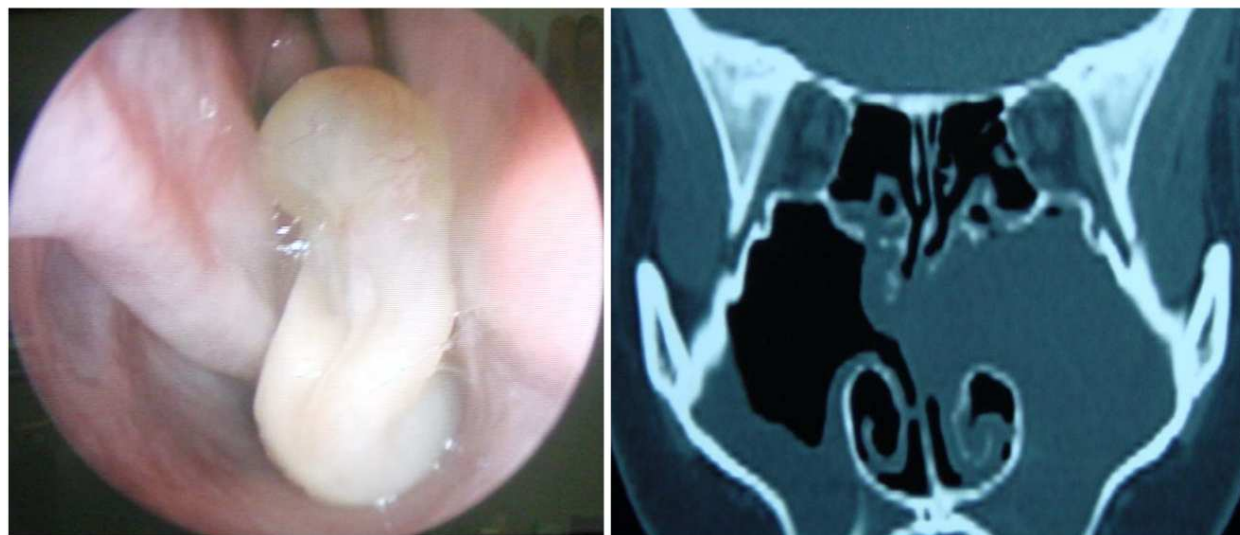
## 6. Non-neoplastic

### 6.1. Mucosal cyst

Mucosal cyst of the paranasal sinuses are common with an incidence between 12 and 36% detected on radiography [36, 37, 38]. They are broadly classified into secretory and non-secretory cysts [39]. Obstruction of mucosal gland leads to formation of secretory cysts which are less common. The more common non secretory cysts are presumably caused by an accumulation of exudates in the sinus mucosa lifting the epithelial lining. The aetiologic factors behind cyst formation remain unknown. They are mostly unilateral but can be bilateral in 10 to 20% cases [40], [41]. They are usually seen as homogenous, dome-shaped opacities on CT scanning and are usually a chance diagnosis on sinus radiography.

### 6.2. Antrochoanal polyp (ACP)

ACP is a benign lesion that originates from the mucosa of the maxillary sinus and grows into the nasal cavity to reach the choana (Fig 5). ACPs account for 4 to 6% of all nasal polyps with increased incidence of 33% in children [42], [43]. ACPs are usually unilateral with only a small number of reported cases with bilateral polyps [16]. It has been suggested that most ACPs originate from the posterior-medial wall [44]. Mean age of presentation is 17 years and it is reported to be twice as common in males than females [44].



**Figure 5.** (A) A zero degree endoscope view of a left antrochoanal polyp in an adult male and (B) a coronal CT section of same patient showing a homogenous opaque mass in the maxillary sinus with opacification of the middle meatus and extension into choana.

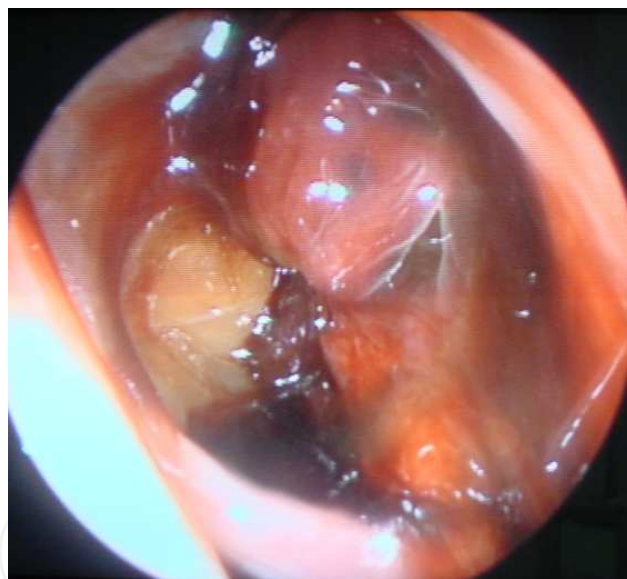Clinical manifestations usually start with unilateral nasal obstruction but other symptoms have been reported such as epistaxis, purulent rhinorrhea, post-nasal drip, snoring, obstructive sleep apnea, dysphonia and dysphagia [42, 44].

### 6.3. Fungal disease

Most sinus fungal infections are caused by *Aspergillus* species. *Aspergillus flavus* is the most common cause of sinus fungal ball. Infections by dematiaceous fungi such as *Bipolaris*, *Curvularia* or *Alternaria* are commonly seen in patients with allergic fungal sinusitis. Zygomycetes, such as *Mucorales* or *Rhizopus* are well-described aggressive organisms implicated in many cases of invasive fungal sinusitis [45, 46, 47]. Fungal rhinosinusitis can be classified as invasive or non-invasive (Table 5). The prognosis of the fungal sinus infections is more dependent on the manifestation of the disease than on the specific causative species.

Noninvasive	Invasive
Saprophytic	Acute invasive fungal sinusitis
Allergic fungal sinusitis	Chronic granulomatous invasive sinusitis
Fungal ball	Chronic invasive fungal sinusitis

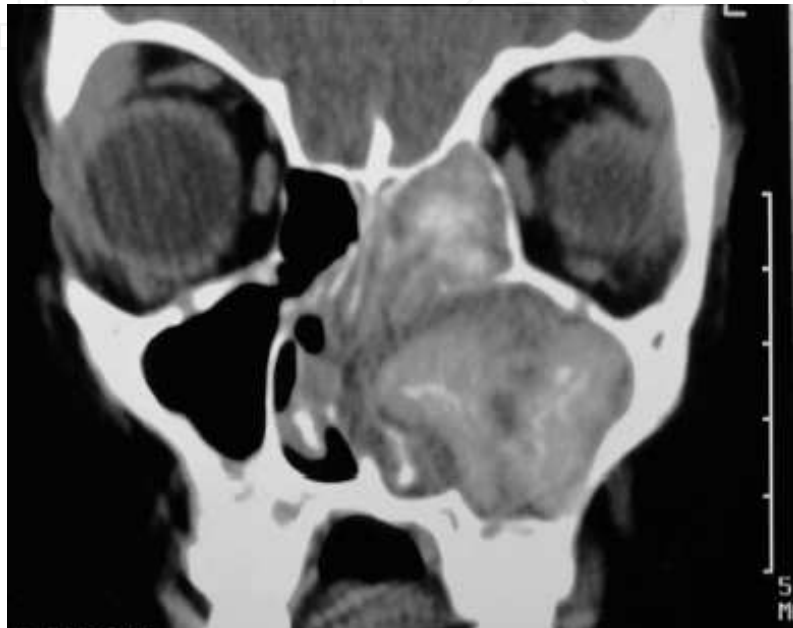**Table 5.** Classification of fungal sinusitis



**Figure 6.** A zero degree endoscopic view of right nasal cavity showing evidence of allergic mucin in an adult male presenting with chronic rhinosinusitis

Associated nasal polyposis is seen in up to 10% due to the chronic inflammatory response. Maxillary sinus fungal ball often presents with unilateral sinus disease and unrelenting symptoms of rhinosinusitis. Allergic fungal sinusitis is characterized by the presence of allergic mucin in patients with symptoms of chronic rhinosinusitis, polyposis and an IgE-mediated hypersensitivity reaction to fungal elements resulting in a self-perpetuating inflammatory cascade (Fig 6). A high index of suspicion for invasive fungal sinusitis is necessary in patients with immunodeficiency, fever and symptoms referable to the paranasal sinuses. CT of

paranasal sinuses is often ordered to evaluate refractory symptoms. Complete or subtotal opacification of the involved sinus is not uncommon. Up to 41% demonstrated heterogenous opacification with calcifications (Fig 7). Bony erosion or sclerosis from mass effect can be identified in 17 to 36% [48, 49, 50].



**Figure 7.** A CT scan coronal section showing heterogenous opacification of the left nasal cavity with calcification in an adult female with fungal sinusitis

#### 6.4. Cholesterol granuloma (CG)

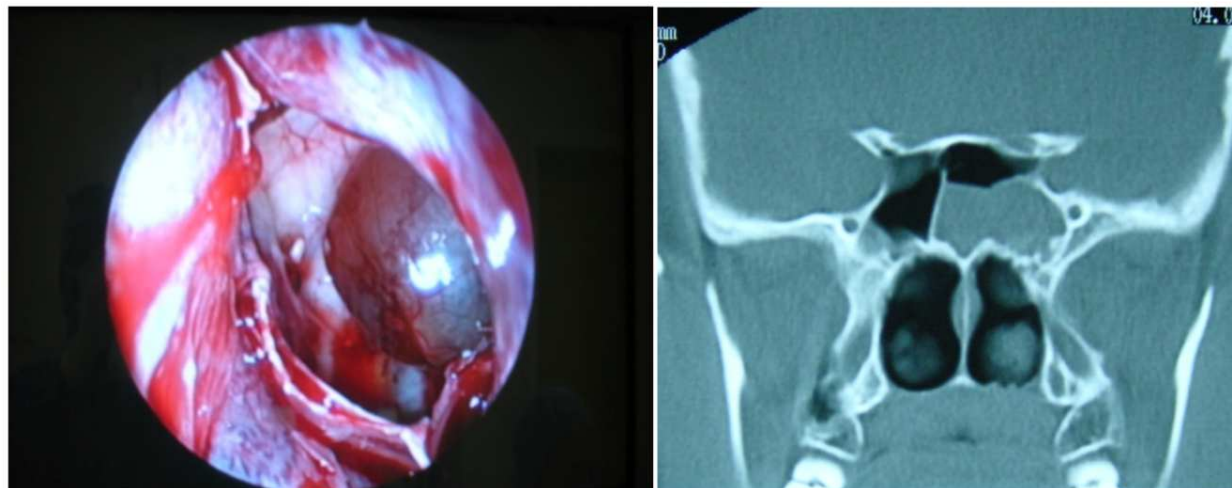CG is a histologic term used to describe the coexistence of granulation tissue with cholesterol crystals and foreign body giant cells [51]. The condition is well described in the temporal bone but is rarely encountered in the paranasal sinuses [52]. The maxillary sinus is most commonly involved [52, 53]. Only one case of bilateral maxillary sinus involvement has been reported [53]. CG has been observed more in men with 3:1 male to female ratio and an average age of 41 years. Only a small number of patients had a history of previous trauma or surgery [52, 53].

The factors contributing to the formation of CG includes disturbed ventilation in a bony cavity, impaired drainage and hemorrhage [52, 53, 54, 55]. Impaired drainage would result in obstruction to venous and lymphatic circulation thus predisposing to mucosal hemorrhage. The insufficient lymphatic drainage would fail to eliminate lipid components in red blood cells and contribute to accumulation of cholesterol crystals. These act as foreign material that stimulates the granulomatous reaction in the sinus cavity [52, 53, 56].

Patients with CG present with symptoms and signs resembling chronic sinusitis [52, 53]. Most of the patients present with nasal obstruction, post-nasal drip, rhinorrhea, facial pain or



headaches (Fig 8 A). CT shows a cyst-like opacity which does not enhance with contrast (Fig 8B). Bony erosion or expansion has been reported in a small number of cases [53, 56].



**Figure 8.** (A) Intraoperative view with 45 degree endoscope showing a polypoid left sphenoid sinus cholesterol granuloma in a young adult female presenting with persistent vertex headaches and (B) a CT scan coronal section showing a homogenous partial opacification of the affected sphenoid sinus

## 6.5. Hematoma

Hematoma of the maxillary sinus is also known as organized hematoma or hemorrhagic pseudotumor [57, 58, 59]. It is an uncommon cause of maxillary sinus mass with only a small number of reported cases from Korea and Japan [58]. Some of the hematoma have been reported in patients with bleeding diathesis such as Von Willebrand disease but there are several patients who present with what appears to be a spontaneous etiology [58, 59, 60]. Initially, a blood clot accumulates in the maxillary sinus secondary to facial trauma, operative bleeding, recurrent epistaxis or bleeding diathesis. Subsequently the hematoma develops and due to poor ventilation and obstruction of drainage it transforms into an organized hematoma by means of neovascularization and fibrosis [58, 59]. Encapsulation of the blood clot by fibrous tissue prevents reabsorption of the hematoma. Further bleeding causes increasing pressure and progressive expansion which leads to erosion of adjacent structures [59], [60].

The most common symptom at presentation is epistaxis followed by unilateral obstruction and facial swelling [57, 58]. Symptoms due to pressure on adjacent structures such as proptosis and infraorbital hypoaesthesia have been reported [61, 62]. CT scanning shows the hematoma as a nonenhancing soft tissue mass which can be heterogeneous or homogenous. Histologically the hematoma has a peripheral wall that consists of dense fibrous tissue with a spindle-shaped myofibroblast cells. The center of the hematoma consist of loose fibrous tissue which is relatively acellular and contains some intact erythrocytes [57, 58, 62].



## 6.6. Antrolithiasis

Antrolithiasis are calcified bodies that are formed from mineral salt deposition around a nucleus within the maxillary sinus cavity [63]. These are synonymous with rhinoliths which are reported within the nasal cavity. Anthroliths result from either endogenous (blood clot, mucus or pus) or exogenous factors (teeth and roots or other foreign material). The majority of cases reported had tooth extraction prior to presentation. The patients can be asymptomatic and may present with symptoms of unilateral chronic maxillary sinusitis. CT scan shows antroliths as radiopaque masses of varying sizes and shapes with irregular borders.

## 6.7. Eosinophilic Angiocentric Fibrosis (EAF)

EAF is an uncommon inflammatory fibrotic lesion that affects the submucosa of the nose, larynx and orbit [64, 65]. The pathologic process is manifested by predominantly eosinophilic perivascular inflammation and gradual replacement with progressive fibrosis [64, 67]. EAF is found with slightly higher incidence in young to middle-aged women than men [64]. The etiology of EAF is unknown but it has been closely linked to granuloma faciale [64, 68]. Majority of the lesions involve the nasal septum and lateral nasal wall with only few cases involving the maxillary sinus.

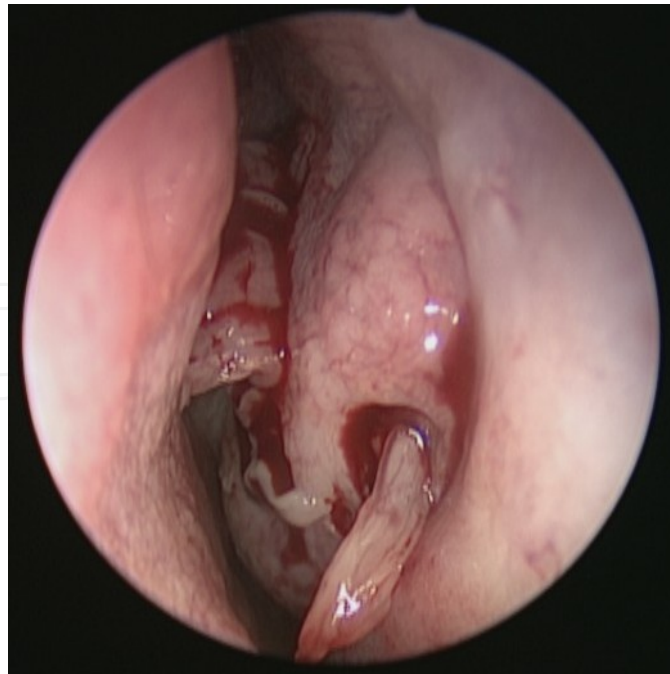
EAF is slow growing and can take many years to manifest [64, 65]. Symptoms are non specific and can initially include nasal obstruction, rhinorrhea, epistaxis and facial pain [64, 67, 68]. Due to mass expansion the patients will present later with facial swelling [64, 65]. Involvement of the orbit can lead to periorbital edema and proptosis [64]. Nasal endoscopy reveals thickening of the nasal septum with an intranasal mass [64, 65].

# 7. Neoplastic

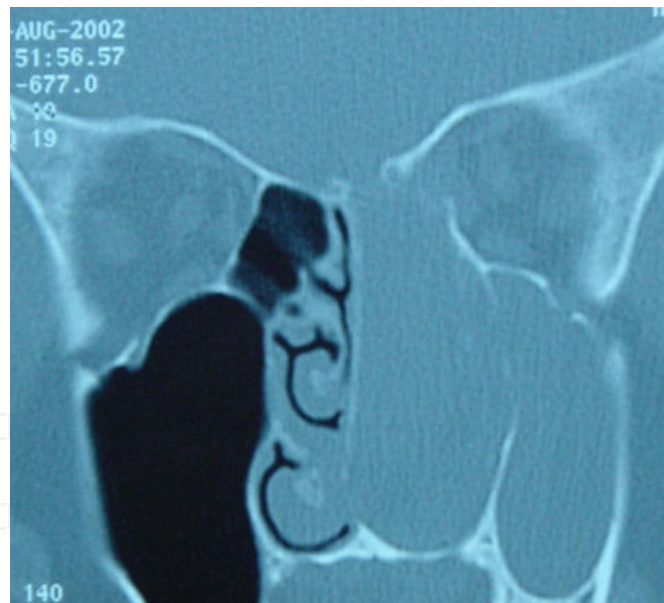
## 7.1. Papillomas

Papillomas are the most common benign epithelial tumor found in the sinonasal area accounting for 10% of all neoplasms in this region [66]. Histologically they are divided into inverted, cylindrical and everted [67]. Everted papilloma more often arises on the nasal septum whereas both inverted and cylindrical papillomas mostly arise on the lateral nasal wall within the middle meatus (Fig 9). The age of presentation is from 35 to 60 years with a male preponderance of 3.5: 1 [66, 68]. It is more common in Caucasians compared with other racial groups. A viral aetiology has been suggested with a link to papilloma viral subtypes 6, 11, 16 and 18 [68].

Patients generally present with obstructive nasal symptoms, rhinorrhea and chronic rhinosinusitis [66, 68]. CT scans shows a mass in lateral nasal wall with areas of apparent calcification and there may be sclerosis of the walls of the sinus [81] (Fig 10). Both a high recurrence rate and malignant transformation have been documented. A recent review of the literature of over 200 cases calculated 7.1% synchronous carcinoma and 3.6% metachronous carcinoma [70].



**Figure 9.** A zero degree endoscopic view of a left inverted papilloma arising from the lateral nasal wall in an elderly male



**Figure 10.** A coronal CT scan section showing an aggressive inverted papilloma (hybrid tumor) arising from the left nasal cavity with evidence of anterior skull base erosion in an elderly Chinese male presenting with CSF rhinorrhea

## 7.2. Mesenchymal tumors: Fibroma, lipoma and myxoma

These rare tumors may be encountered in the nose and sinuses and generally present prior to adulthood. Isolated tumors within maxillary sinus are very rare.

### 7.2.1. *Fibromas*

Fibromas result from progressive inflammation or fibroblastic proliferation of the nasal mucosa [71]. They present as slow-growing, grey-white, smooth surfaced masses producing obstructive nasal symptoms.

### 7.2.2. *Lipoma*

Lipoma is the most common soft tissue tumor in adulthood in contrast to intraosseous lipoma which is a rare condition. The etiology of intraosseous lipoma is unknown but infarction, ischaemia, trauma and irradiation may be contributing factors [72]. Cases have been reported within the nasal cavity and very rarely in the maxillary sinus. The presentation is of nasal swelling and possible nasal obstruction.

### 7.2.3. *Myxoma*

Myxoma of the maxillary sinus is very rare but more frequent than fibromas and lipomas [73]. The age of presentation is between 2 and 15 years and may be related to dental malformations or missing teeth.

## 7.3. **Vasiform Tumors: Hemangioma, Aneurysmal Bone Cyst and Hemangiopericytoma**

These benign lesions arise from vascular tissue within the mucosa or bone of the nose and sinuses.

### 7.3.1. *Hemangiomas*

Hemangiomas represent about 20% of benign non-epithelial tumors of nasal cavity and paranasal sinuses [74]. Mean age of diagnosis is 40 years and the most frequent presenting symptoms are nasal obstruction and epistaxis. Involvement of maxillary sinus have been reported less frequently [91]. Both cavernous and capillary hemangiomas have been reported.

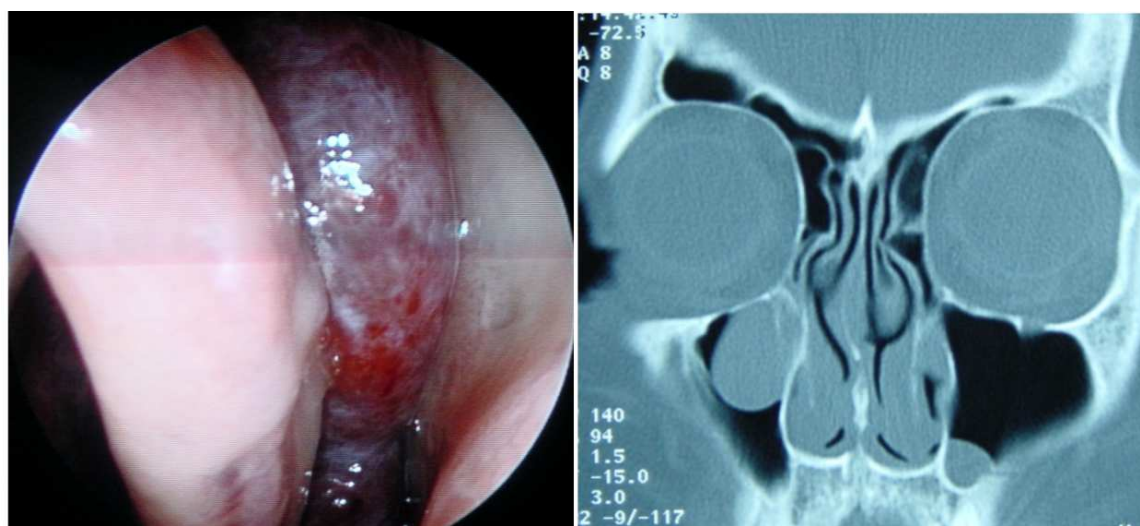
### 7.3.2. *Aneurysmal bone cyst (ABCs)*

ABCs are expansile lesions of unknown etiology that involves long bones and vertebrae of patients younger than 20 years. About 2% of ABCs are encountered in the head and neck region with jaw being the most frequently involved site. The present with facial swelling and obstructive nasal symptoms in the age group between 5 and 23 years. ABCs consist of multiple cavities filled with blood and serous fluids which are separated by septa and surrounded by rim of bone [75]. ABCs have a “honeycomb” appearance on gadolinium-enhanced MRI studies [75].

### 7.3.3. *Hemangiopericytoma (HPC)*

HPC is a rare benign vascular tumor derived from extracapillary cells (pericytes). Less than one-third of HPC occur in the head and neck and 5% are located in the nasal cavity and

paranasal sinuses [76, 77]. Sphenoid and ethmoid sinuses are involved more frequently than the maxillary sinus. Both sexes are equally affected and can occur at any age but often develop after the second decade. The patients usually present with epistaxis and nasal obstruction with reddish submucosal nasal mass (Fig 11).



**Figure 11.** (A) View with 30 degree endoscope in an adult Chinese female presenting with right nasal obstruction and maxillary sinus discomfort and (B) CT scan coronal section showing a polypoidal mass arising from the right maxillary sinus and histopathology report consistent with hemangiopericytoma

## 7.4. Tumors of muscle origin: Leiomyoma and rhabdomyoma

### 7.4.1. Leiomyoma

Leiomyoma is a smooth muscle tumor that originates in areas of abundance of muscle like the uterus.

It is extremely rare for these tumors to present in the sinonasal tract because of the paucity of smooth muscle. And only a handful of cases have been reported in the maxillary sinus [78]. The tumor seem to be slow-growing and non-aggressive and presenting with obstructive nasal symptoms.

### 7.4.2. Rhabdomyoma

Rhabdomyoma is a skeletal muscle tumor and is extremely rare in the paranasal sinus, which has a benign behavior and low recurrence rate [79, 80].

## 7.5. Odontogenic tumors

Odontogenic tumors originate either within the maxillofacial skeleton (intraosseous) or within the gingival or alveolar mucosa overlying the tooth bearing areas (extraosseous). They are usually slow growing and have been associated with non-eruption of the teeth. Patients usually



present with swelling of alveolar process along with nasal obstruction and epistaxis. Superior displacement of globe has been reported with large odontogenic tumors.

#### 7.5.1. *Ameloblastoma*

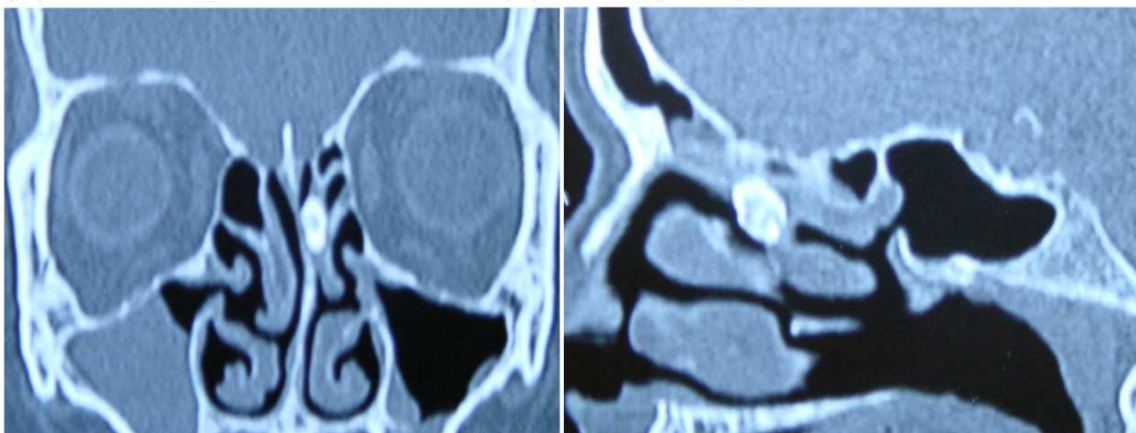
Ameloblastoma is the most common odontogenic tumor. It is slow growing, locally invasive and has a high rate of recurrence if not treated effectively. Patients between the ages of 16 and 60 years are generally affected with the region of canine tooth and maxilla being the most common sites. They are often asymptomatic but can present with a painless swelling of the cheek, gingival and palate that may reach a large size. Ameloblastoma presents as a unilocular or multilocular radiolucency that may be associated with an impacted tooth.

### 7.6. Fibro-osseous lesions: Osteoma, ossifying fibroma, fibrous dysplasia and osteoblastoma

Fibro-osseous lesions represent a class of bony abnormalities: osteoma, ossifying fibroma, fibrous dysplasia and osteoblastoma. They are distinct but lie along a continuum from the most to the least content. They have some similarities in appearance but their clinical implications differ.

#### 7.6.1. *Osteomas*

Osteomas are frequent incidental finding in up to 3% of CT scans of the paranasal sinuses [81] (Fig 12). Eighty percent occur in the frontal sinuses followed by the ethmoids and least in the maxillary sinuses. The etiology is either embryologic or secondary to trauma or an infective process. There is an association with Gardner syndrome which is an autosomal dominant condition characterized by intestinal polyposis and pigmented skin lesions in addition to osteomas [82]. Maxillary sinus osteomas are slow growing and usually asymptomatic but they may become symptomatic depending on the location and onset [83].



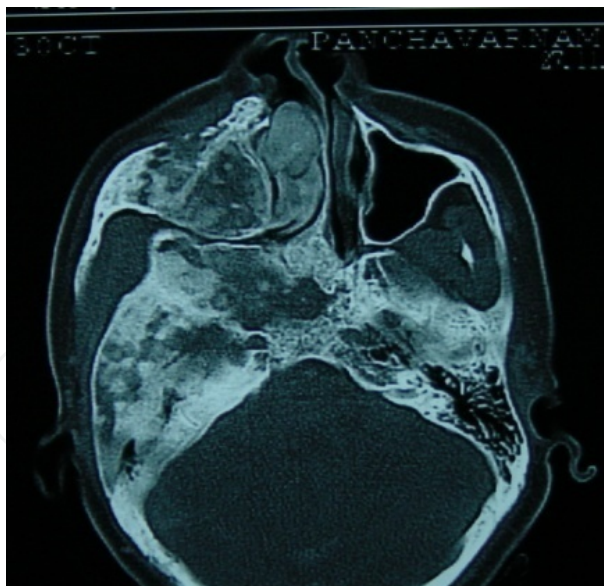
**Figure 12.** (A) A CT scan coronal and (B) sagittal section showing osteoma arising from the anterior ethmoid sinuses in an adult female presenting with frequent headaches

### 7.6.2. *Ossifying fibroma (OF)*

OF is a well-circumscribed lesion that continues to grow after sexual maturity and can attain dramatic proportions [81, 84]. The vast majority is located in the posterior region of the mandible; those involving the maxillary sinus are uncommon [85]. Patient usually present between the third and forth decades and the lesion is more common in women [85]. The most common presentation is of painless cheek swelling but involvement of the orbit or nasal cavity may be signified by proptosis, loss of visual acuity, epiphora, nasal obstruction and epistaxis [81, 85]. Radiologically, the lesion is sharply circumscribed with an egg shell rim and central radiolucency which differentiates it from fibrous dysplasia with its indistinguishable borders.

### 7.6.3. *Fibrous dysplasia (FD)*

FD is a slow, progressive disorder where normal bone is replaced by fibrous tissue and immature woven bone [81, 84]. There are two main forms of FD: monostatic (70-85%) that involves only one bone and polystatic (15-30%) where multiple bones can be involved (Fig 13). The maxilla and mandible are the most commonly involved bones generally in the monostatic form. FD is a disease of the young where patients present in their first or second decade and is assumed to be “burnt out” as the patients reach skeletal maturity. The usual symptom is of painless facial deformity although other complaints such as loosening of teeth, nasal obstruction or epistaxis have been encountered [86]. CT scans shows lesions with indistinct borders and a homogenous “ground glass” appearance.



**Figure 13.** An axial CT section showing a polystatic fibrous dysplasia in an adult female

### 7.6.4. *Osteblastoma*

Osteblastoma is an uncommon neoplasm characterized by proliferation of osteoblasts forming bone trabeculae set in a vascularized fibrous connective tissue stroma [87]. The tumor

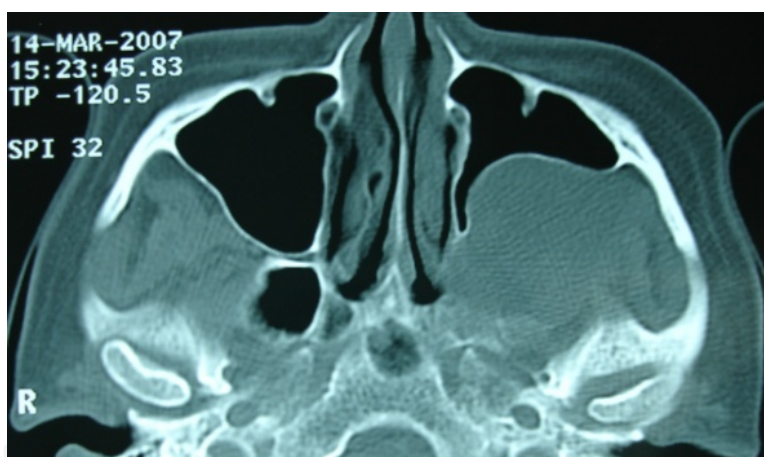


occur predominantly in vertebrae and long bones and can affect craniofacial bones with the mandible being the most commonly involved. It is reported less in the maxillary bone and rarely in the maxillary sinus [88]. The majority of the patients are under 30 years and present with a facial swelling and is often painful [87]. CT scan features range from radiolucent to radiopaque lesions and are often mistaken for other fibro-osseous lesions.

## 7.7. Neuroectodermal tumors: Schwannoma and neurofibroma

### 7.7.1. Schwannomas

Schwannomas are benign nerve sheath tumors of which 50% occur in the head and neck region. They are very uncommon in the paranasal sinuses (only 4%) and a very small number involve the maxillary sinus [84]. The lesion slowly expands in the sinus cavity resulting in swelling, pressure symptoms and bony necrosis. The patients mostly present with nasal obstruction but other symptoms such as proptosis, epiphora, headaches, facial anesthesia and epistaxis have been reported [90]. CT scan shows a homogenous radio-opaque mass with evidence of bone remodeling (Fig 14).



**Figure 14.** An axial CT section showing a left homogenous radio-opaque mass involving the maxillary sinus and infra-temporal region in an adult female

### 7.7.2. Neurofibromas

Neurofibromas are heterogenous peripheral nerve tumors that arise from the connective tissue of the nerves especially the endoneurium [91]. They may occur as sporadic lesions but are much more common in association with neurofibromatosis type 1 (NF 1). Neurofibromas of the maxillary sinus are exceedingly rare. As with schwannomas, they slowly grow and expand within the sinus cavity causing swelling, pressure symptoms and bone necrosis. Presentation is similar to other expanding masses in the maxillary sinus. CT scan shows a well-circumscribed mass with some bony erosion.

## 8. Conclusion

Mucocele of the paranasal sinuses are well described complication of chronic sinusitis in adults but they rarely occur in the pediatric population. Mucocele can be associated with ophthalmic complications or intracranial complications. Radiological imaging includes CT-scan and sometimes MRI when intracranial complications are suspected. The differential diagnosis of mucocele includes paranasal sinus tumors. Usually a wide endoscopic endonasal marsupialization of paranasal sinus mucocele is a safe and less invasive than external approaches. Thus, a good understanding of paranasal sinus mucoceles by ophthalmologists and otorhinolaryngologists is essential for early diagnosis and rapid surgical intervention.

## Author details

Balwant Singh Gendeh\*

Address all correspondence to: [bsgendeh@gmail.com](mailto:bsgendeh@gmail.com)

Department of Otorhinolaryngology-Head Neck Surgery, UKM Medical Center, Jalan Yaacob Latif, Bandar Tun Razak, Kuala Lumpur, Malaysia

## References

- [1] Alberti PW, Marshall HF, Black JI. 1968. Fronto-ethmoidal mucocele as a cause of unilateral proptosis. *Br J Ophthalmol* 52: 833-838
- [2] Johnson JT, Ferguson BJ. 1998. Infection in: Cummings CW, Fredrickson JM, Harker LA, Krause CJ, Schuller DE, Rhicharson MA, eds *Otolaryngology Head Neck Surgery*, 3<sup>rd</sup> edition. St Louis: Mosby 1115-1116
- [3] Maniglia AJ, Kronberg FG, Culbertson W. 1984. Visual loss associated with orbital and sinus disease. *Laryngoscope* 94(8): 1050-1059
- [4] Curtin HD, Rabinov JD. 1998. Extension to the orbit from paraorbital disease. *Radiol Clin North Am* 36: 1201-1213
- [5] Moriyama H, Hesaka H, Tachibana T, Honda Y. 1992. Mucoceles of ethmoid and sphenoid sinus with visual disturbance. *Arch Otolaryngol Head Neck Surg* 118: 141-146
- [6] Wang JW, Jang YT, Lee BJ. 2007. Natural course of retention cysts of the maxillary sinus: long term follow-up results. *Laryngoscope* 117(2):341-344

- [7] Olze H, Matthias C, Degenhardt P. 2006. Pediatric paranasal sinus mucoceles. *Eur J Pediatr Surg* 16: 192-196
- [8] Timon CL, O'Dwyer TP. 1989. Ethmoidal mucoceles in children. *J Laryngol Otol* 103: 284-246
- [9] Rombaux Ph, Bertrand B, Eloy Ph, Collet S, Daela J, Bachert C, Claes J. 2000. Endoscopic endonasal surgery for paranasal sinus mucoceles. *Acta Oto-Rhinol-Laryngologica Belg* 54:115-122
- [10] Daniilidis J, Nikolaou A, Kondopoulos V. 1992. An unusual case of sphenoid sinus mucocele with severe intracranial extension. *Rhinology* 31:135-137
- [11] Tseng CC, Ho CY, Kao SC. 2005. Ophthalmic manifestation of paranasal sinus mucocele. *J Chin Med Ass* 68(6): 260-264
- [12] Shimo-Oku M, Miyazaki S, Shiraki K, Sugimoto T, Sotani H. 1989. Optic nerve involvement in posterior paranasal sinus diseases. *Neuroophthalmology* 9:145-155
- [13] Lund VJ, Rolfe ME. 1989. Ophthalmic considerations in fronto-ethmoid mucoceles. *J Laryngol Otol* 103:667-669
- [14] Nugent GR, Sprinkle P, Bloor BM. 1970. Sphenoid sinus mucocele. *J Neurosurg* 32:443-451
- [15] McCarthy WL, Frenkel M. 1972. Visual loss as the only symptom of sphenoid sinus mucocele. *Am J Ophthalmol* 74: 1140-1143
- [16] Casteels F, De Loof E, Brock P, Jorissen M, Dralands L, Missotten L, Wilms G. 1992. Sudden blindness in a child: Presenting symptoms of sphenoid sinus mucocele. *Br J Ophthalmol* 76: 502-504
- [17] Hao SP. 1994. Mucocele of sphenoid sinus with acute blindness: report of a case. *J Formosan Med Ass* 93: 519-521
- [18] Muneer A, Jones NS. 1997. Unilateral abducens nerve palsy: a presenting sign of sphenoid mucoceles. *J Laryngol Otol* 111: 644-646
- [19] Valvasoori G, Putterman AM. 1973. Ophthalmological and radiological findings in sphenoid mucoceles. *Arch Ophthalmol* 90:416-419
- [20] Rosselet PO, Gomez F, Mange B, Savary M, Grigorin D. 1984. Sphenoid sinusitis and panhypopituitarism. *Schweiz Med Wochenschr* 114: 1340-1342
- [21] Pitkaranta A, Atula T, Lindokki P, Saxen H, Malmberg H. 2000. Unilateral blindness in a child with acute sinusitis. *Rhinology* 38:43-44
- [22] Slavin ML, Glaser JS. 1987. Acute severe irreversible visual loss with sphenothmoiditis – "Posterior" orbital cellulitis. *Arch Ophthalmol* 105: 345-348

- [23] Kainz J, Stammberger H. 1992. Danger areas of the posterior rhinobasis. *Acta Otolaryngol* 112:852-861
- [24] McCrary JA. 1997. Spheno-ethmoidal mucocoele, chondrosarcoma and unilateral visual loss. In: Smith JL, ed. *Neuroophthalmology Update*. New York: Masson Publishing, 105-109
- [25] Weille FL, Vang RR. 1953. Sinusitis as focus of infection in uveitis, keratitis and retrobulbar neuritis. *Arch Ophthalmol*, 58:154-165
- [26] Rothstein J, Maisel RH, berlinger NT, Writschaffer JD. 1984. Relationship of optic neuritis to disease of the paranasal sinuses. *Laryngoscope* 94:1501-1508
- [27] Lundgren A, Olin T. 1961. Mucopyocoele of sphenoidal sinus or posterior ethmoidal cells with special reference to apex orbital syndrome. *Acta Otolaryngol* 53:61-79
- [28] Moriyama H, Nakajima T, Honda Y. 1992. Studies on mucocoeles of the ethmoid and sphenoid sinuses. Analysis of 47 cases. *J Laryngol Otol* 106:23-27
- [29] Fujitani T, Takahashi T, Asai T. 1984. Optic nerve disturbance caused by frontal and fronto-ethmoidal mucopyocoeles. *Arch otolaryngol* 110:257-269
- [30] Kennedy DW, Josephson JS, Zinreich SJ, Mattox DE, Goldsmith MW. 1989. Endoscopic sinus surgery for mucocoeles: A viable alternative. *Laryngoscope* 99:885-895
- [31] Bheasley NTP, Jones NS. 1995. Paranasal sinus mucocoeles: modern management. *Am J Rhinol* 9: 251-256
- [32] Kennedy DW, Keogh B, Senior B, Lanza DC. 1996. Endoscopic approach to tumors of anterior skull base and orbit. *Oper Tech Otolaryngol Head Neck Surg* 7:257-263
- [33] Conboy PJ, Jones NS. 2003. The place of endoscopic sinus surgery in the treatment of paranasal sinus mucocoeles. *Clin Otolaryngol Allied Sci* 28;207-210
- [34] Namavar E, loh JCN, Gendeh BS. 2012. Paranasal sinus mucocoele:Endoscopicmarsupilization and surgical outcome, *Egyptian J Otolaryngol* 28(2): 95-97
- [35] Yomoto E, Hyodo M, Kawatika S, Aibara R. 1997. Effect of sinus surgery on visual disturbances caused by Sphenoethmoidal mucocoeles. *Am j Rhinol* 11: 337-343
- [36] Bhattacharyya N. 2000. Do maxillary sinus retention cysts reflect obstructive sinus phenomena? *Arch Otolaryngol Head Neck Surg* 126(11):1369-1371
- [37] Harar RPS, Chadha NK, Rogers G. 2007. Are maxillary sinus mucosal cysts a manifestation of inflammatory sinus disease? *J Laryngol Otol* 121(8):751-754
- [38] Kanagalingham J, Bhatia K, Georgalas C, Fokkens W, Miszkiel K, Lund VJ. 2009. Maxillary mucosal cyst is not a manifestation of rhinosinusitis: results of prospective three-dimensional CT study of ophthalmic patients. *Laryngoscope* 119(1):8-12

- [39] Gardner DG. Pseudocysts and retention cysts of the maxillary sinus. 1984. *Oral Surg Oral Med Oral Pathol* 58(5):561-567
- [40] Casamassimo PS, Lilly GE. 1980. Mucosal cysts of the maxillary sinus: a clinical and radiographic study. *Oral Surg Oral Med Oral Pathol* 50(3):282-286
- [41] Fisher EW, Whittet HB, Croft CB. 1989. Symptomatic mucosal cysts of the maxillary sinus: antroscopic treatment. *J Laryngol Otol* 103(12):1184-1186
- [42] Maldonado M, Martinez A, Alobid I, Mullol J. 2004. The antrochoanal polyp. *Rhinology* 42(4):178-182
- [43] Mahfouz ME, Elsheikh MN, Ghoname NF. 2006. Molecular profile of the antrochoanal polyp: up-regulation of basic fibroblast growth factor and transforming growth factor beta in maxillary sinus mucosa. *Am J Rhinol* 20(4):178-182
- [44] Aydin O, Keskin G, Ustundag E, Iseri M, Ozkarakas H. 2007. Choanal polyps: an evaluation of 53 cases. *Am J Rhinol* 21(2):164-168
- [45] Deshazo RD. 2009. Syndromes of invasive fungal sinusitis. *Med Mycol* 47(Suppl 1):S309-S314
- [46] Michael RC, Michael JS, Ashbee RH, Matthews MS. 2008. Mucological profile of fungal sinusitis: an audit of specimens over a 7-year period in a tertiary care hospital in Tamil Nadu. *Indian J Pathol Microbiol* 51(4): 493-496 Abstract
- [47] Plszewski J, Milonski J. 2008. The analysis of the bacterial and fungal flora in maxillary sinuses in patients operated due to FESS method. *Otolaryngol Pol* 62(4):458-461
- [48] Ferguson BJ. 2000. Fungal balls of the paranasal sinuses. *Otolaryngol Clin North Am* 33(2):389-398
- [49] Ferreiro JA, Carlson BA, Cody DT. 1997. Paranasal sinus fungal balls. *Head Neck* 19(6):481-486
- [50] Klossek JM, Serrano E, Peloquin L, Percodi J, Fontanel JP, Pessey JJ. 1997. Functional endoscopic sinus surgery and 109 mycetomas of paranasal sinuses. *Laryngoscope* 107(1):112-117
- [51] Friedmann I, Osborn DA. 1982. Pathology of granulomas and neoplasms of the nose and paranasal sinuses. In: WStC Symmers, ed. *Systemic Pathology*. Edinburgh/London/New York: Churchill Livingstone:1920235
- [52] Astarci HM, Sungu N, Samim EE, Ustun H. 2008. Presence of cholesterol granuloma in the maxillary and ethmoid sinuses. *Oral Maxillofac Surg* 12(2):101-103
- [53] Chao TK. 2006. Cholesterol granuloma of the maxillary sinus. *Eur Arch Otorhinolaryngol* 263(6):592-597
- [54] Graham J, Michaels L. 1978. Cholesterol granuloma of the maxillary antrum. *Clin Otolaryngol Allied Sci* 3(2):155-160



- [55] Niho M. 1986. Cholesterol crystals in the temporal bone and the paranasal sinuses. *Int J Pediatr Otorhinolaryngol* 11(1):79-95
- [56] Kunt T, Ozturkan S, Egilmez R. 1998. Cholesterol granuloma of the maxillary sinus: six cases from the same region. *J Laryngol Otol* 112(1):65-68
- [57] Lim M, Lew-Ghor S, Beale T, Ramsay A, Lund VJ. 2008. Maxillary sinus haematoma. *J Laryngol Otol* 122(2): 210-212
- [58] Song HM, Jang YJ, Chung YS, Lee BJ. 2007. Organizing hematoma of the maxillary sinus. *Otolaryngol Head Neck Surg* 136(4):616-620
- [59] LeePK, Wu JK, Ludemann JP. 2004. Hemorrhagic pseudotumor of the maxillary sinus. *J Otolaryngol* 33(3):206-208
- [60] Ozhan S, Arac M, Isik S, Oznur 11, Atilla S, Kemaloglu Y. 1996. Pseudotumor of the maxillary sinus in a patient with von Willebrand's disease. *Am J Roentgenol* 166(4): 950-951
- [61] Lee BJ, Park HJ, Hoe SC. 2003. Organized hematoma of the maxillary sinus, *Acta Otolaryngol* 123(7): 869-872
- [62] Tabae A, Kacker A. 2002. Hematoma of the maxillary sinus presenting as a mass- a case report and review of literature. *Int J Pediatr Otorhinolaryngol* 65(2):153-157
- [63] Guneri P, Kaya A, Caliskan MK. 2005. Antroliths:survey of the literature and report of a case. *Oral Surg Oral Med Oral Pathol Oral Radiol Endod* 99(4):517-521
- [64] Kosarac O, Luna MA, RoJ Y, Ayala AG. 2008. Eosinophilic angiocentric fibrosis of the sinonasal tract. *Ann Diagn Pathol* 12(4):267-270
- [65] Paun S, Lund VJ, Gallimore A. 2005. Nasal fibrosis:long-term follow-up of four cases of Eosinophilic angiocentric fibrosis. *J Laryngol Otol* 119(2):119-124
- [66] Lund VJ. 2000. Optimum management of inverted papilloma. *J Laryngol Otol* 114(3): 194-197
- [67] Michaels L. 1996. Benign mucosal tumors of the nose and paranasal sinuses. *Semin Diagn Pathol* 13(2):113-117
- [68] Minovi A, Kollert M, Draf W, Bockmuhl U. 2006. Inverted papilloma: feasibility of endonasal surgery and long-term results of 87 cases. *Rhinology* 44(3):205-210
- [69] Savy L, Lloyd G, Lund VJ, Howard D. Optimum imaging for inverted papilloma. *J Laryngol Otol* 114(11):891-893
- [70] Mirza S, Bradley PJ, Acharya A, Stacey M, Jones NS. 2007. Sinonasal inverted papillomas:recurrence and synchronous and metachronous malignancy. *J Laryngol Otol* 121(9):857-864



- [71] Lin HL, Huang CC, Lee TJ. 2004. Endoscopic sinus surgery treatment for a huge sino-nasal fibroma. *Chang Gung Med J* 27(3):233-237
- [72] Uysal A, Kayiran O, Cuzdan SS, Bektas CI, Aslan G, Caydere M. 2007. Maxillary sinus lipoma: an unanticipated diagnosis. *J Craniofac Surg* 18(5):1153-1155
- [73] Gregor RT, Loftus-Coll B. 1994. Myxoma of the paranasal sinuses. *J Laryngol Otol* 108(8):679-681
- [74] Rabaso E, Rosell A, Plaza G, Martinez-Vidal A. Haemangioma of the maxillary sinus. *J Laryngol Otol* 111(7):638-640
- [75] Fyrmpas G, Constantinidis J, Televantou D, Konstantinidis I, Daniilidis J. 2006. Primary aneurismal bone cyst of the maxillary sinus in a child: case report and review of the literature. *Eur Arch Otorhinolaryngol* 263(7):695-698
- [76] Herve S, AbdAlsamad I, Beautru R, et al. 1993. Management of sinonasal hemangio-pericytomas. *Rhinology* 37(4):153-158
- [77] Stomeo F, Fois V, Cossu A, Meloni F, Pastore A, Bozzo C. 2004. Sinonasal hemangio-pericytoma: a case report. *Eur Arch Otorhinolaryngol* 261(10): 555-557
- [78] LaBruna A, Reagan B, Papageorge A, 1995. Leiomyoma of the maxillary sinus; a diagnostic dilemma. *Otolaryngol Head Neck Surg* 112(4): 595-598
- [79] Fu YS, Perkin KH. 1976. Nonepithelial tumors of the nasal cavity, paranasal sinuses and nasopharynx: a clinicopathologic study of skeletal muscle tumors (rhabdomyoma and rhabdosarcoma). *Cancer* 37(1):364-376
- [80] Reitter GS. 1921. Rhabdomyosarcoma of the nose: report of case. *JAMA* 76:22-23
- [81] Eller R, Sillers M. 2006. Common fibro-osseous lesions of the paranasal sinuses. *Otolaryngol Clin North Am* 39(3): 585-600
- [82] Alexander AA, Patel AA, Odland R. 2007. Paranasal sinus osteomas and Gardner's syndrome. *Ann OtolRhinolLaryngol* 116(6):658-662
- [83] Park W, Kim HS. 2006. Osteoma of maxillary sinus: a case report. *Oral Surg Oral Med Oral Pathol Oral Radiol Endod* 102(6):e26-e27
- [84] Harrison DF. 1984. Osseous and fibro-osseous conditions affecting the craniofacial bones. *Ann OtolRhinolLaryngol* 93(3 Pt 1):199-203
- [85] Chong VF, Tan LH. 1997. Maxillary sinus ossifying fibroma. *Am J Otolaryngol* 18(6): 419-424
- [86] Muraoka H, Ishihara A, Kumagai J. 2001. Fibrous dysplasia with cystic appearance in maxillary sinus. *Auris Nasus Larynx* 28(1):103-105
- [87] Jones AC, Prihoda TJ, Kacher JE, Odingo NA, Freedman PD. 2006. Osteoblastoma of the maxilla and mandible: A report of 24 cases and review of literature and discus-

sion of its relationship to osteodosteoma of the jaw. *Oral Surg Oral Med Oral Pathol Oral Radiol Endod* 102(5):639-650

- [88] Osguthorpe JD, Hungerford GD. 1983. Benign osteoblastoma of the maxillary sinus. *Head Neck Surg* 6(1): 605-609
- [89] Sarioglu S, Ozkal S, Guneri A, et al 2002. Cystic schwannoma of the maxillary sinus. *Auris Nasus Larynx* 29(3):297-300
- [90] Sheikh HY, Chakravathy RP, Slevin NJ, Sykes AJ, Banerjee SS. 2008. Benign schwannoma in paranasal sinuses: a clinic-pathological study of five cases emphasizing diagnostic difficulties. *J Laryngol Otol* 122(6):598-602
- [91] Boedeker CC, Ridder GJ, Kayser G, Schipper J, Maier W. 2005. Solitary neurofibroma of the maxillary sinus and pterygopalatine fossa. *Otolaryngol Head Neck Surg* 133(3): 458-459

