

We are IntechOpen, the world's leading publisher of Open Access books Built by scientists, for scientists

6,900

Open access books available

186,000

International authors and editors

200M

Downloads

Our authors are among the

154

Countries delivered to

TOP 1%

most cited scientists

12.2%

Contributors from top 500 universities



WEB OF SCIENCE™

Selection of our books indexed in the Book Citation Index
in Web of Science™ Core Collection (BKCI)

Interested in publishing with us?
Contact book.department@intechopen.com

Numbers displayed above are based on latest data collected.
For more information visit www.intechopen.com



Imaging in Hyperthyroidism

Javier L. Pou Ucha

Additional information is available at the end of the chapter

<http://dx.doi.org/10.5772/58324>

1. Introduction

Abnormalities in the thyroid anatomy or physiology often arise when the clinician suspect hyperthyroidism or hypothyroidism detecting on physical examination a goiter or a thyroid nodule and confirms the suspicion by serum measurements of thyroxine (T4), or thyroid stimulating hormone (TSH).

Hyperthyroidism is the result of several diseases that may be located in the thyroid gland (primary), as well as in other locations (secondary), or be the product of an overeating of high-iodinated foods or being an undesirable effect of some drugs (amiodarone, antitussives). They will have different expressions in the clinical, laboratory and diagnostic imaging.

Primary hyperthyroidism is the most common condition where diseases like Graves Basedow disease, toxic multinodular goiter and toxic adenoma are the most common pathologies. Although rare, also the hyperthyroidism associated with thyroid carcinoma [1], extracervical ectopic thyroid tissue [2], mutation with activation of the TSH receptor [3], activating mutations of the stimulatory G protein in the McCune-Albright syndrome [4], Struma Ovarii [5] and medications such as the excess of iodine intake (Jod-Basedow phenomenon).

The secondary hyperthyroidism is characterized by an increased thyroid hormone caused by extrathyroid pathologies like the TSH high secreting pituitary adenoma [7], thyroid hormone resistance syndrome [8], human chorionic gonadotropin secreting tumor [9].

Within the thyrotoxicosis without hyperthyroidism will be the acute, subacute and silent thyroiditis and other causes such as medication with amiodarone, radiation, adenoma infarction or excessive thyroid hormone intake (factitious hyperthyroidism). These diseases will present a clinical picture similar to hyperthyroidism.

All these pathology will need to be studied using various imaging techniques (Figure 1).

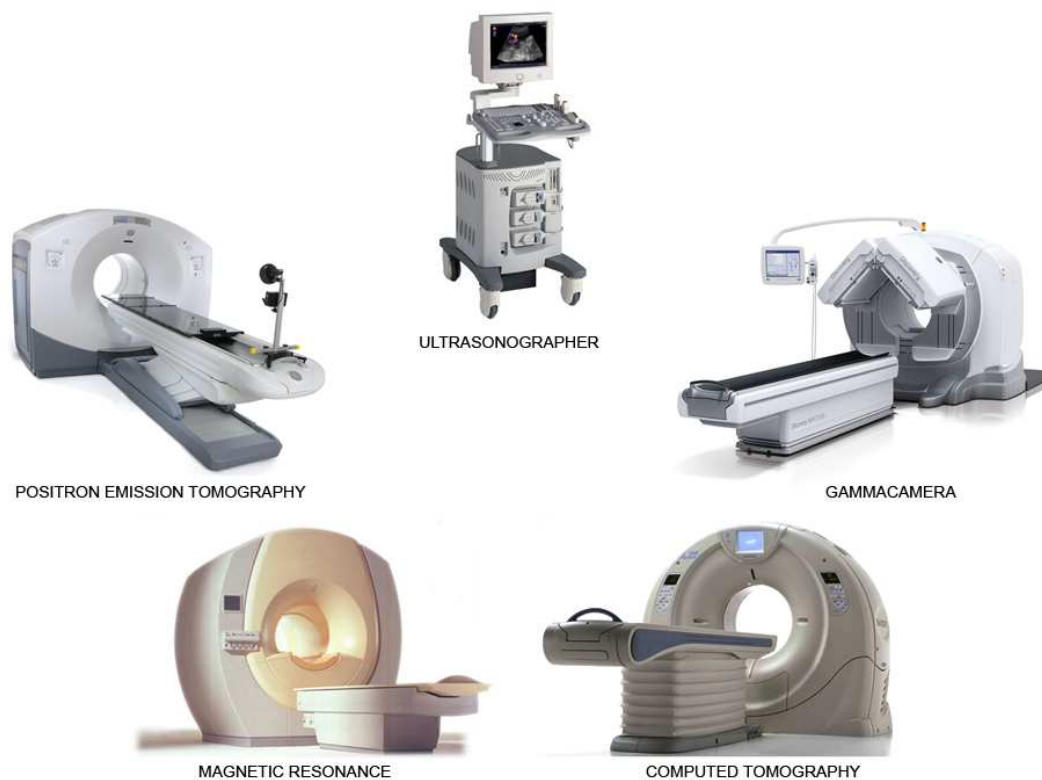

Figure 1. Medical imaging devices used in Radiology and Nuclear Medicine Departments.

Imaging studies will be in the first line for thyroid exploration techniques. There will be others that will serve to confirm or distinguish between thyroid pathologies as well as to locate pathology in extracorporeal way when it is secondary.

2. Introduction to imaging studies

Ultrasonography is a technique of first choice, based on the study of the thyroid gland by the emission and reception of ultrasound signal that according to its characteristic of reflection of sound wave in the different tissues studied will display them in different graduations of gray color on a scale that will go from white to black. Main advantages are their cost, non-invasive and that they not emit ionizing radiation. Within the disadvantages will be the need for experienced staff.

Then we will have a second imaging technique that will be of great importance in the study of hyperthyroidism, the scintigraphy, a non-invasive technique that through the use of radioactive material will be able to assess not only anatomy and glandular function, but exploring the whole body searching for extraglandular pathology. Of additional contribution will be the Radioactive Iodine Uptake (RAIU), is a test that evaluate the thyroid function,, it measures how much radioactive iodine is taken up by the thyroid gland in a certain time period, normally obtaining values in a few hours (4-6), 24 hours, and 48 hours.

And two imaging methods of high resolution, computed tomography (CT) and magnetic resonance imaging (MRI) techniques are used to assess cervical gland pathologies as well as extracervical level giving a greater resolution than other imaging studies. It is useful in the surgical planning and for their subsequent evaluation and monitoring. MRI will allow improved visualization of soft tissues and the identification of pathologies at thoracic as in abdominopelvic level.

When an intraglandular lesion is identified in thyroid, ultrasound technique will be useful for the intralesional correct approach and extraction of material by the Fine Needle Aspiration Biopsy (FNAB) for the cytopathology evaluation (Figure 2).

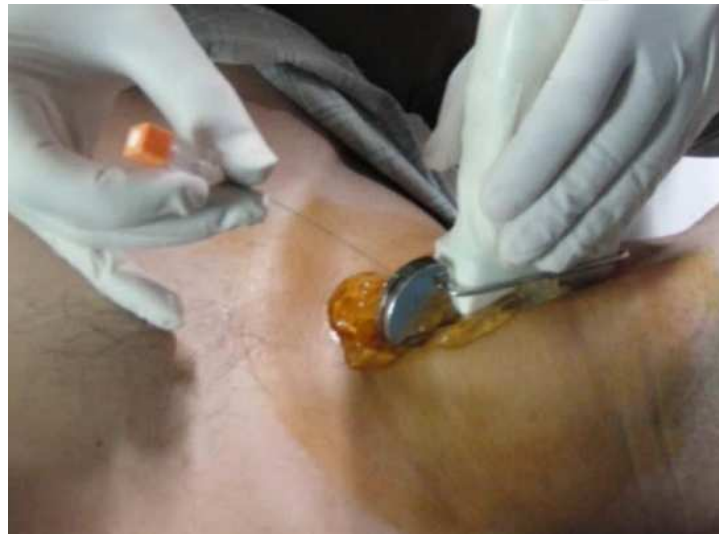

Figure 2. Fine needle aspiration biopsy guided by ultrasonography.

FNAB is the cornerstone in the solitary thyroid node assessment detected in the clinical exam as well as the evaluation of the dominant node in multinodular goiter disease.

In places where a nodule or a lymph node is difficult to be identified by physical exam, or if there are multiple nodules, an echo-guided biopsy provides high precision for the nodule/ganglion sampling.

As we mentioned above the procedure requires skilled and experienced hands as well as an experienced cytopathologist. Even more, in experienced hands, 10% approximately of the biopsies are non diagnostics.

Thyroid nodules are discovered by palpation in a 3-7 percent of cases and by ultrasound in a 20-76% in the general population [10].

3. Ultrasonography

The ultrasound images tend to be reserved for those cases in which there are doubts about whether it is a nodule or palpable nodule is inside the thyroid. They are also used to distinguish

between a suspicious nodule and a prominent lobe or thyroid hemiagenesis, to distinguish between a solitary nodule and a multinodular goiter, for the evaluation of a thyroid mass when cytology is not diagnostic.

Thyroid nodules are common. The most palpable nodules are benign (solid, cystic, mixed) being the minor, less than 10%, malignant [11]; however, the risk of malignancy in nodule rises in children, adolescents, and adults. The risk is substantially increased if the patient has been previously irradiated by head and neck pathology [12].

Multiple publications have documented that certain sonographic features by B-mode ultrasound and Doppler color, Figure 3, (hypoechoogenicity, irregular margin, microcalcifications, intralesional vascular signals) are suggestive of malignancy [13-17].

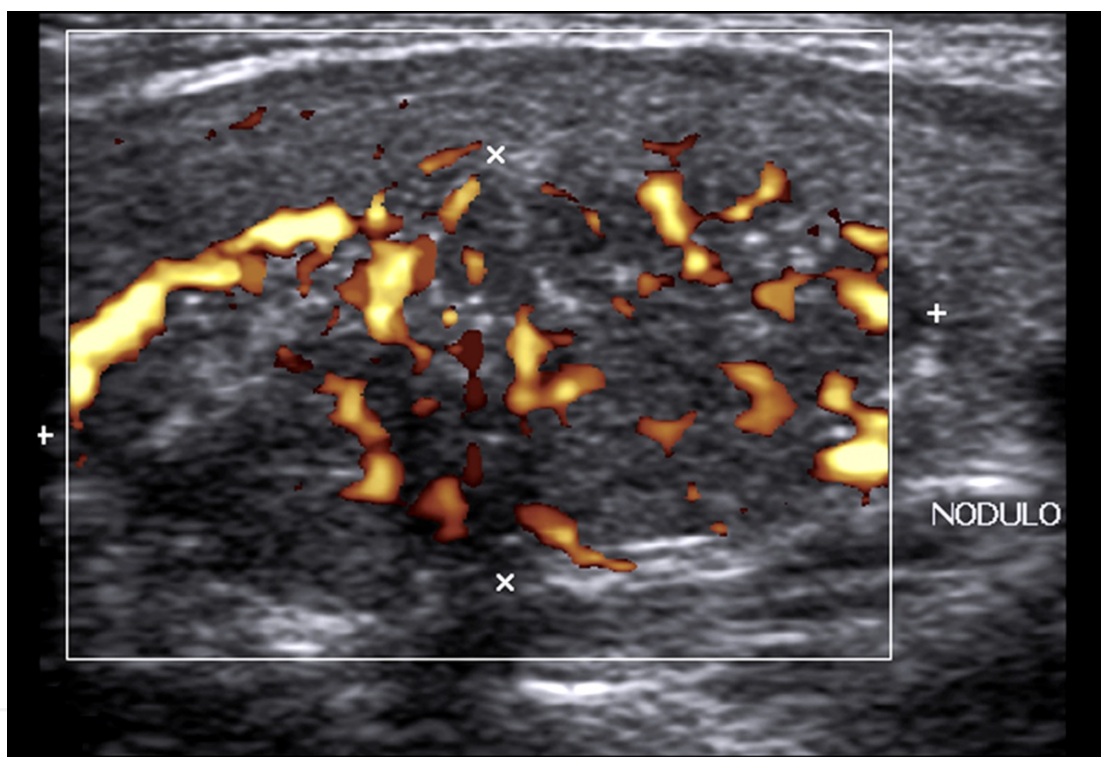


Figure 3. Colour Doppler of a thyroid nodule. In color is displayed the vascular distribution inside the nodule, showing periferic and central vascularization. The image shows multiple microcalcifications too, being in relation to papillary carcinoma. (Image courtesy by Dr. Alejandro Blando)

Ultrasound clearly defines the thyroid gland, it is more sensitive than scintigraphy in the detection of thyroid nodules and determines their intra/extra glandular location. Ultrasound is done when a clinician suspect the presence of a thyroid nodule or for the confirmation of the location inside or outside the gland.

Although radiation dose in scintigraphic studies and RAIU are extremely low and that there is no known health risk up to date, the ultrasonography avoid ionizing radiation and always it is used as initial imaging technique for the gland evaluation in children. Also, the ultrasonography is the initial imaging method for pregnancy assessment. In the presence of a nodule,

the ultrasonography will be helpful in determinate his composition (cystic, solid, miced). The ultrasound technique has an important limitation, being unable to differentiate between malignant and benigne nodule, only giving an estimation.

Ultrasonography also can be used for the degree of the nodule growth in patients under suppresing therapy. Their limitations are the necessity of experienced operator, high interoperator variability in the nodule identification and the uncertain signification of the thyroid micronodule in the moment of the detection in the adult population. The ultrasonography is so sensitive and the nodules so prevalent that may be difficult to be interpreted in some situations.

4. Doppler

Also the Doppler Ultrasonography is useful for the thyroid gland evaluation. It meassures the vascular flow in the inferior thyroid artery, being 6 ml/min in norml gland and increased more than 5-folds in hyperthyroidism. Doppler is very useful in Graves Disease for the global flow increase assessment (Figure 4), also the therapeutic response control showing a flow constant reduction and the posterior increase in case of recurrence.

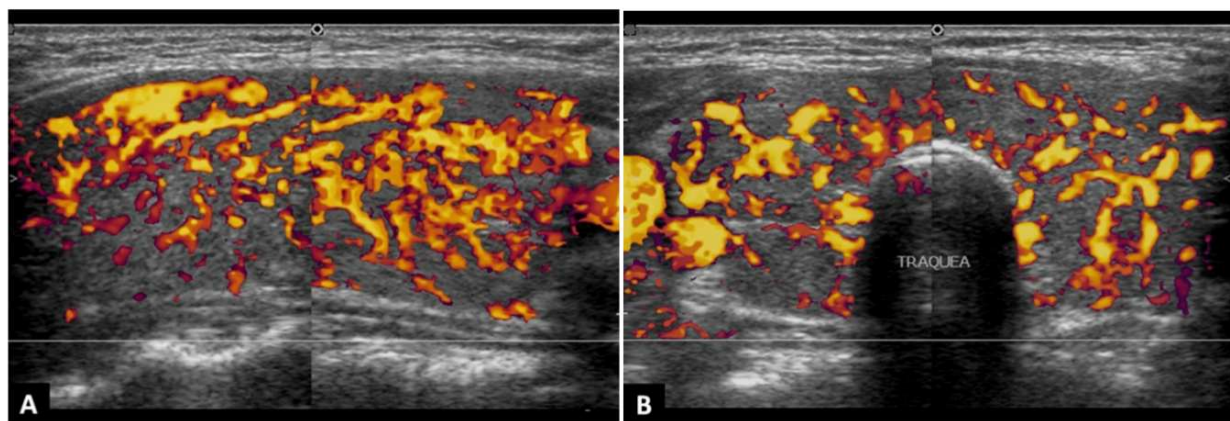


Figure 4. Color Doppler Ultrasound of the Thyroid Gland in longitudinal view (image A) as in transversal view (image B). High and diffuse hypervascular thyroid related to Graves Disease ("Thyroid Inferno Sign"). (Image courtesy by Dr. Alejandro Blando).

In the last years also it has also been evaluated the Doppler utility in the nodule feature determination between malignancy and benign as weel as inflammatory or malignant lymph nodes [18].

5. Elastography

Even more, recent studies shows that are ultrasopnography techniques that reduce the false negative probability using the Elastography Ultrasonographyic method, first described in

thyroid lesions in 2005 by Lyshchik et al. [19] This method consist in the evaluation in real time (RTE) of a region of interest during the application of external force with the probe of the ultrasonography, the software measure the tissue displacement wich is visualized in color scale depending on the nodular/extranodular consistency. It has been reported as a great tool that could optimize the thyroid nodule management because of his high sensitivity and specificity in the prediction of thyroid carcinoma (Figure 5). [20,21]

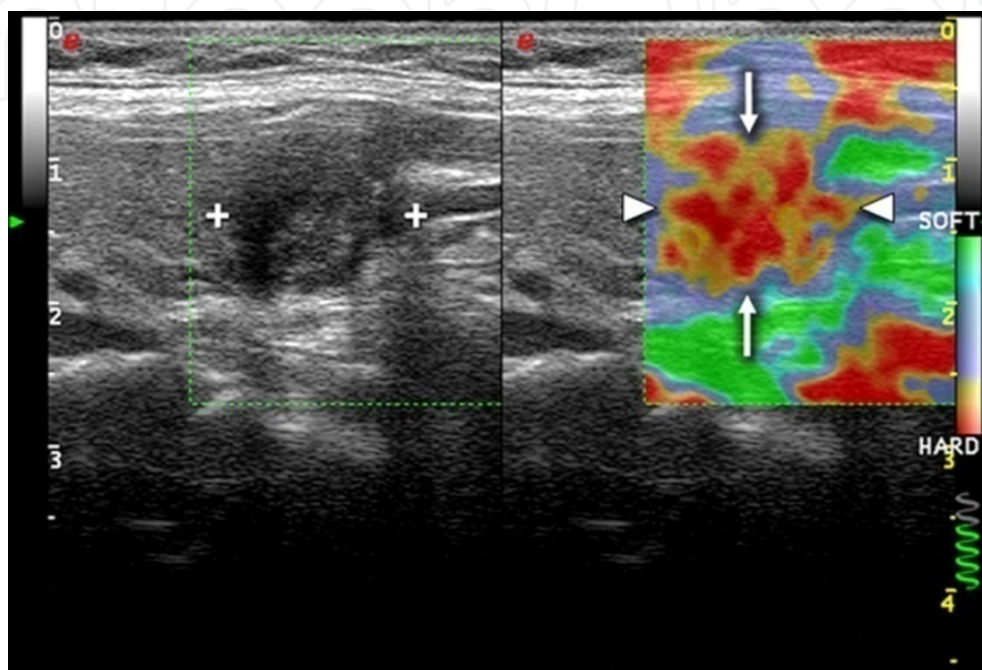


Figure 5. Dual Modality US Imaging. There is a small hypoechoic solid nodule related to papillary carcinoma (image at the left). Elastography method (image at the right) showing a nodular stiffness, hence the lack of nodular elasticity represented as red colour between arrows. (Image courtesy by Dr. Alejandro Blando)

6. Thyroid scintigraphy and radioactive iodine uptake

Thyroid assessment by radionuclides can contribute to the management of the patient under thyroid disease suspicious.

Thyroid scintigraphy helps to determinate the gland location, morfology and functional features (Figure 6).

Unlike ultrasonography, the scintigraphy assess the thyroid nodule and gland physiology.

Hot nodules (Figure 7) acumulates I-123 or Tc-99m in a major degree than normal thyroid, they are very uncommon to express malignancy and FNAB or surgery can be avoided.

Warm nodules acumulates radiotracers in the same intensity as normal thyroid tissue. They are low probably to be malignant, but doctors would try FNAB depending on the size, consistency and clinical presentation.

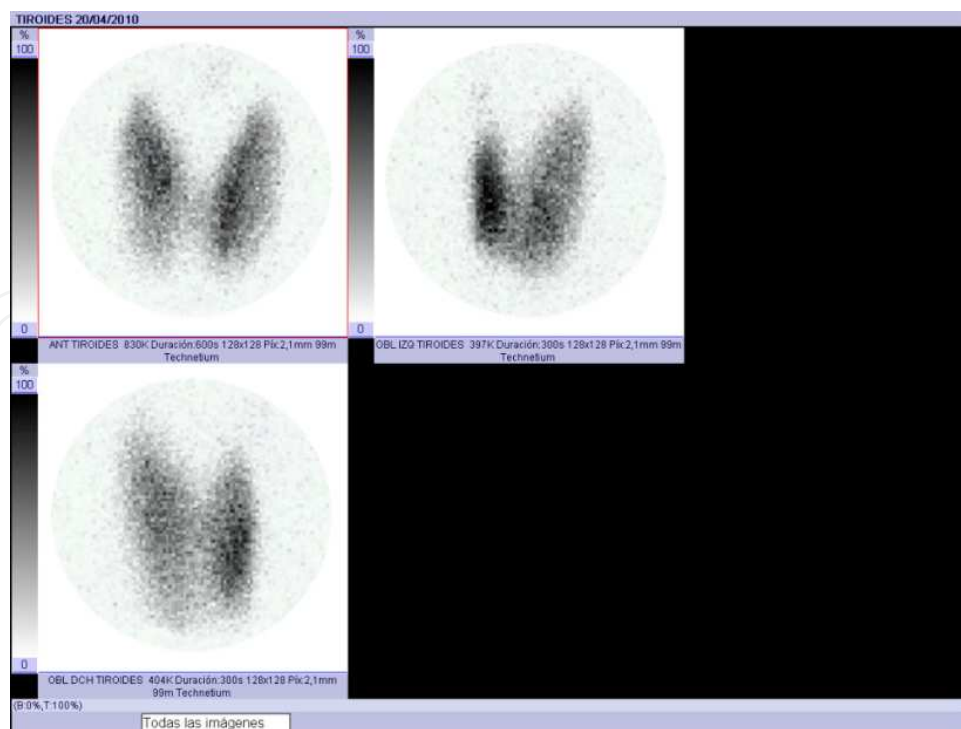

Figure 6. Thyroid Scintigraphy with Tc-99m-Per technetate. Anterior, Left Oblique and Right Oblique projections (top left, top right and bottom right respectively) magnified with pin-hole collimator. Showing a normal thyroid gland with a normal radiotracer distribution.

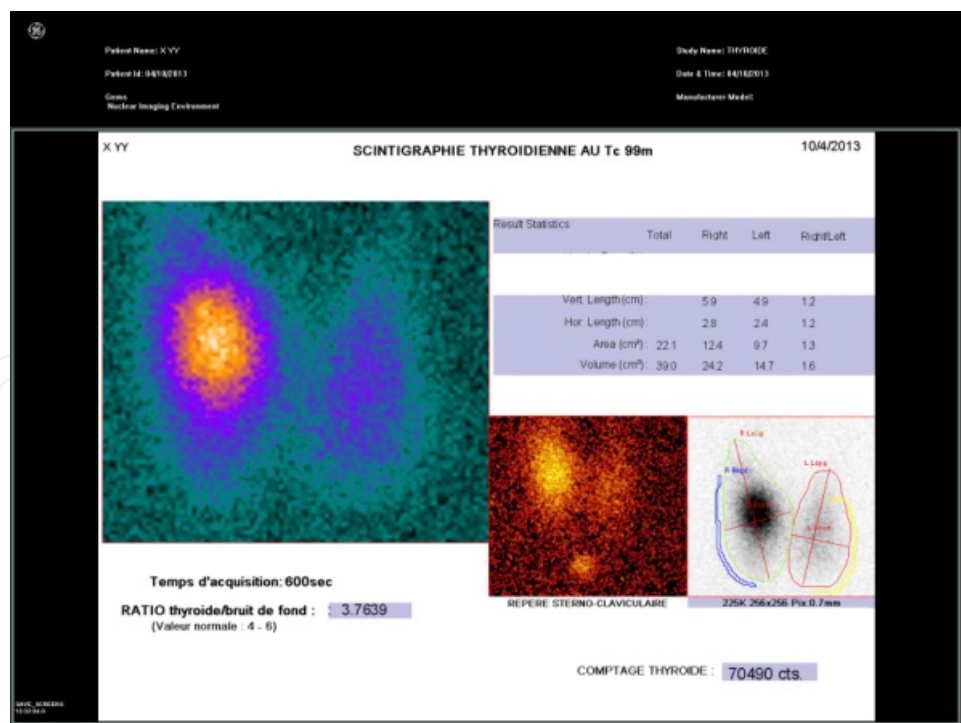


Figure 7. Thyroid Scintigraphy with Tc-99m-Per technetate in anterior projection. High focal uptake in right lobe related to Toxic Nodular Adenoma. (Image courtesy by Dr. Charles Bouirsot)

Cold nodules (Figure 8) lack of radioisotope accumulation, they do not trap Tc-99m nor organify I-123 either. They have a 10-20 % of probability of malignancy [22], for this reason, the thyroid scintigraphy can be useful when a FNAB result is uncertain [23].

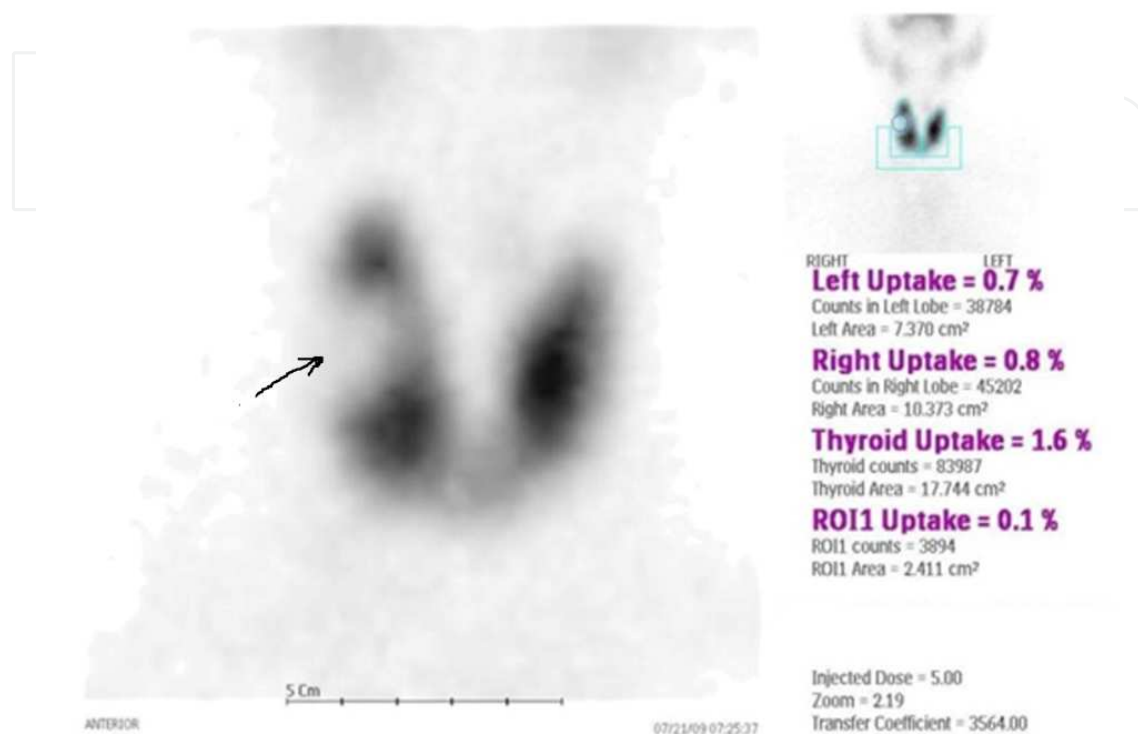


Figure 8. Thyroid Scintigraphy with Tc-99m-Pertechnetate in anterior projection. The image displays a cold nodule (arrow) in the right lobe. (Image courtesy by Dr. Charles Bouirsot)

The presence of toxic multinodular goiter diminishes the malignancy risk. The typical multinodular scintigraphic image shows areas of high and low uptake of radiotracer and always the two thyroid lobes affected (Figure 9). There are last articles that inform that multinodular goiter and solitary nodules have the same risk of malignancy.

Nevertheless, the presence of a dominant cold nodule it will be recommended a FNAB (Figure 10).

Radioactive Iodine Uptake complements the thyroid scan, and can measure the percentage of glandular iodine uptake in order to find utility to the I-131 therapy (Figure 11). There are pathologies in which uptake will be negligible and not I-131 therapy will be needed such as subacute Thyroiditis, struma ovarii, or factitious hyperthyroidism.

The functional and structural information given by the Scintigraphy thyroid and thyroid uptake combined with physical exam and hormonal serology always allows a correct diagnosis and a logical therapeutic approach or next diagnostic procedures.

It is important to distinguish between hyperthyroidism associated with an increased iodine uptake (Graves, BMN, toxic adenoma disease) and a decreased uptake (Thyroiditis, factitious

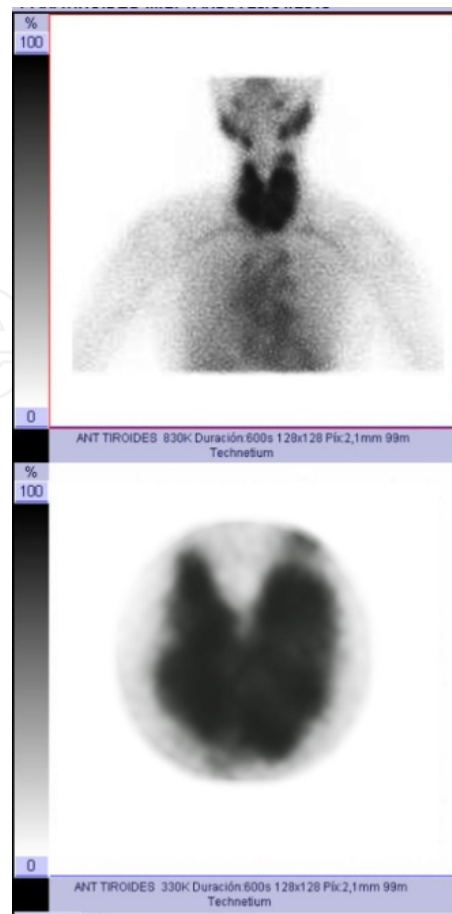

Figure 9. Thyroid Scitigraphy with Tc-99m-Perfecnetate, anterior projection images with different collimators (paralel hole and pin-hole, top and bottom respectively). The images displayed show a great hyperactivity with heterogenous distribution in an enlarged thyroid gland (goiter) related to multinodular goiter.

hyperthyroidism, struma ovarii, functioning metastasis of thyroid carcinoma, extracervical ectopic thyroid tissue), because the treatment for these two categories of hyperthyroidism is going to be different.

The diagnosis of Graves disease can be based on clinical data and laboratory. A thyroid scintigraphy and a thyroid uptake curve can be usefull to confirm the Graves disease when it is a hyperthyroidism without signs of proptosis, pretibial myxedema and exophthalmos.

Thyroid scan shows a homogeneous uptake of radiotracer in both lobes. Sometimes the Graves disease can be confused with toxic Multinodular goiter, but both can be easily recognized by a thyroid scintigraphy. This differentiation is important because the therapeutic dose is much higher for toxic Nodular goiter.

Occasionally, a silent or subacute thyroiditis can be confused with Graves disease because in both situations the patient is hyperthyroid with abnormal analytic function. The patient with thyroiditis may have fever, pain and local inflammation, but it could be confused with an infection or inflammation of upper air tract. It could also happen that at the time of the elevated thyroid hormones in blood the clinic of thyroiditis had already disappeared.

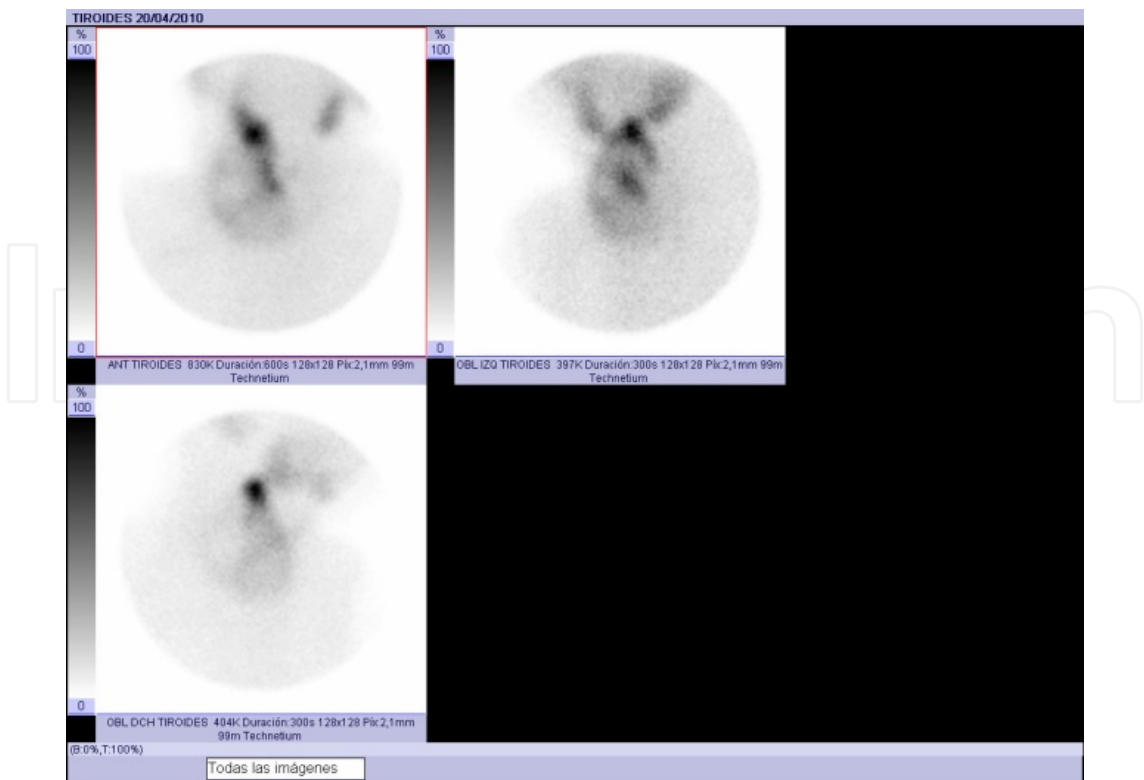


Figure 10. Thyroid Scintigraphy with Tc-99m-Per technetate. Anterior, Left Oblique and Right Oblique projections (top left, top right and bottom right respectively) magnified with pin-hole collimator. Showing a right enlarged thyroid lobe (patient with hemithyroidectomy) with heterogeneous distribution of the radiotracer. There is a hot nodule in the upper pole and a cold area at the right of the midlower part of the lobe.

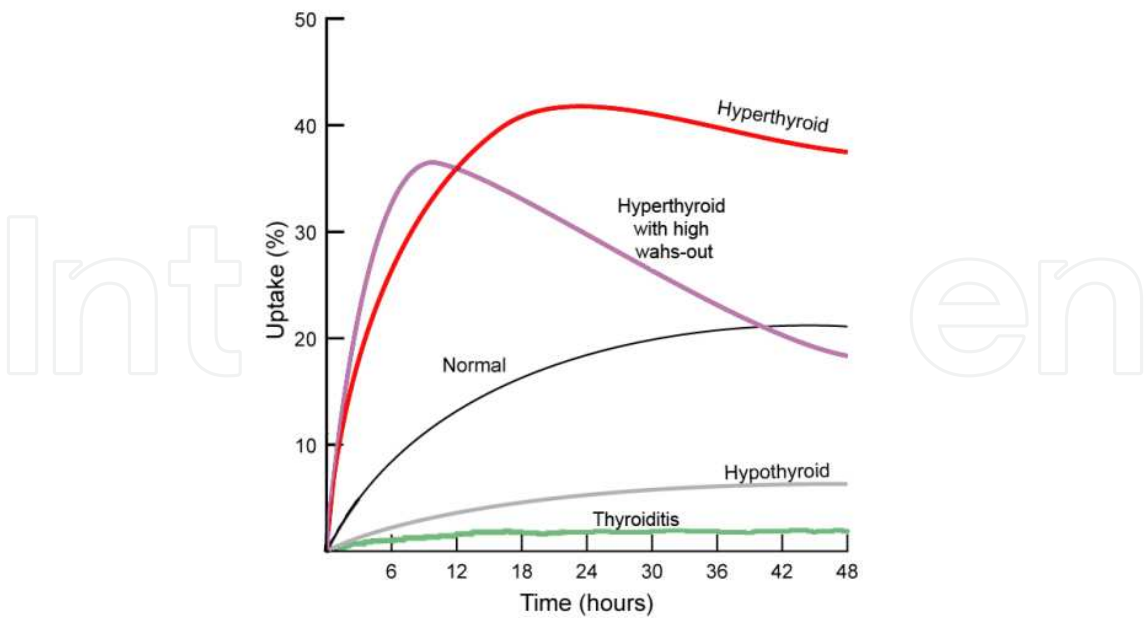


Figure 11. Radioactive Iodine Uptake Curve Plot. The image shows different uptake intensity (in percentage) depending on the thyroid disease represented in time (hours).

Because of glandular inflammation in acute or subacute Thyroiditis, this is not able to trap Tc-99m or organify I-123, consequently, the capture of 24 hours will be close to 0% (Figure 12).

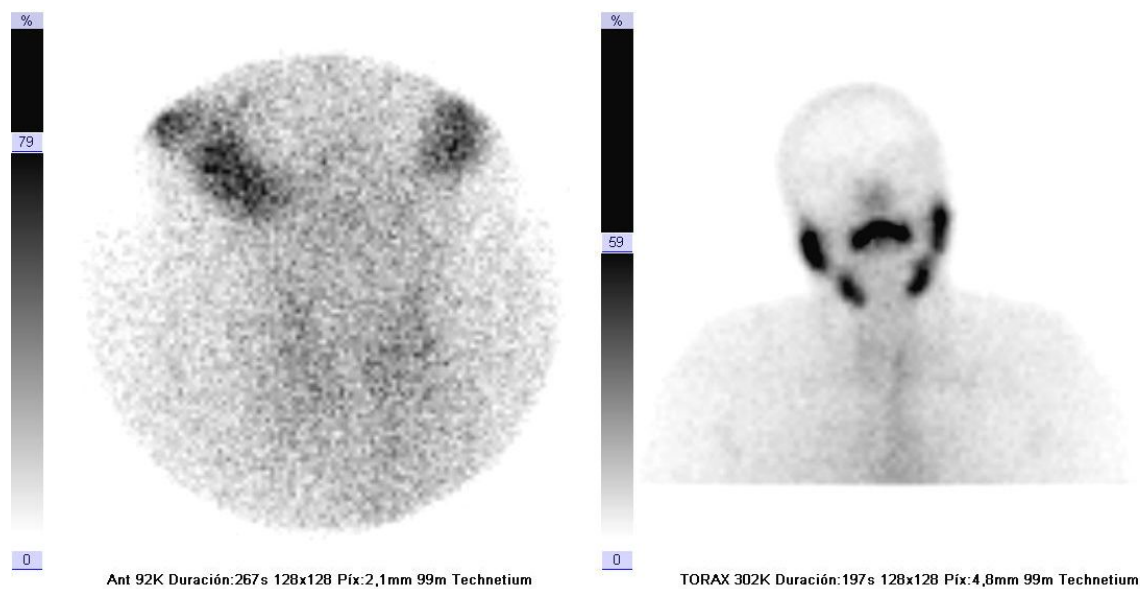


Figure 12. Thyroid Scintigraphy with Tc-99m-Pertechnetate in anterior projection with two different collimators (pin-hole and parallel hole, left and right respectively). The image displayed show no uptake of radiotracer by the thyroid gland.

The scintigraphy can be used to distinguish between the thyroiditis and Graves disease.

Another problem that can arise is that of a patient with hyperthyroidism in which we do not know if the pathology is toxic adenoma or toxic multinodular goiter. Thyroid scintigraphy is suitable technique for their differentiation. The importance of the difference between toxic adenoma, multinodular goiter and Graves disease is that the first two needs higher therapeutic dose.

Another situation is that the factitious hyperthyroidism where the scintigraphy will help showing absence of glandular uptake and a radioactive iodine uptake value of 24 hours close to 0%. The difference between thyroiditis and factitious hyperthyroidism will be through laboratory, where the values of TG and Ac anti thyroid (AAT) will be the key.

Extremely rare conditions where a hyperthyroidism due to struma ovarii will suppress the thyroid gland activity uptake. 24-Hour uptake will be close to 0%. If this condition is suspected, the solution will be a whole body Tc-99m scintigraphy or MRI imaging of the pelvis. A case of struma ovarii is displayed in Figure 13.

There are also rare situations like functioning thyroid carcinoma metastases where they are going to be seen enhanced hot spots dispersed in multiple parts of the body (Figure 14).

When a mass in neck or retrosternal area is detected and the suspicion could be a goiter, Thyroid Scintigraphy will be of great use to confirm this suspicion. With the help of a cutaneous

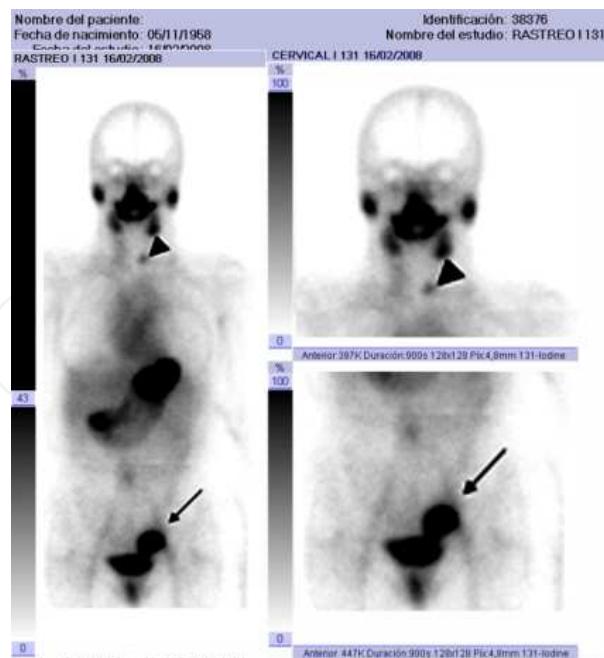


Figure 13. Thyroid Scintigraphy with I-131 in a patient under control for his thyroidectomy. There are displayed partially wholebody scan and craniocervical and pelvic statics views in anterior projection. There is a focal uptake at cervical level and a high activity mass lesion at the left hemipelvic region. This images is related to Struma Ovarii.

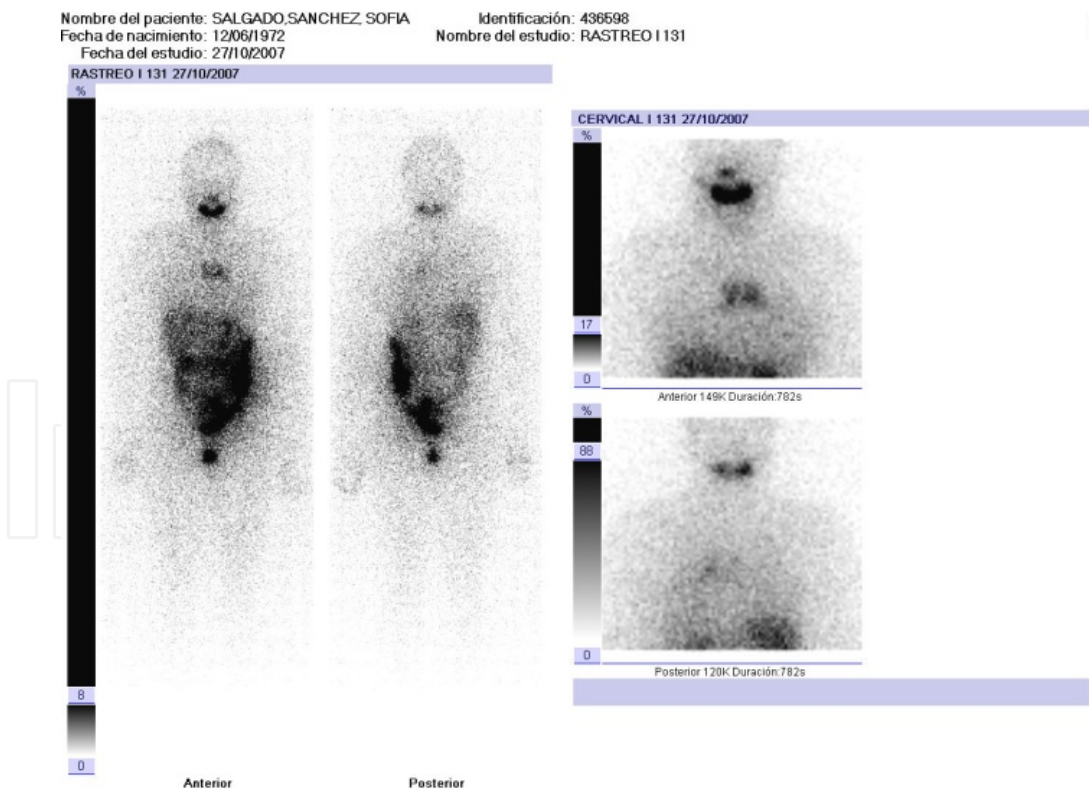


Figure 14. Thyroid Scintigraphy with I-131. Wholebody scanning in anterior and posterior views (at left) and cervico-mediastinal statics in anterior and posterior views (at right, top and bottom respectively).

radioactive labelling at the level of the suprasternal notch location cervicomediastinal thyroid or thyroid nodule in study can be defined with great precision.

A retrosternal goiter may be the manifestation of a multinodular goiter, which characteristically will presents with decreased radiotracer uptake of the area. There has been published a case of hyperthyroidism for multinodular ectopic goiter (Figure 15) where can be observed the great utility that will have the anatomical as well as functional images [2].

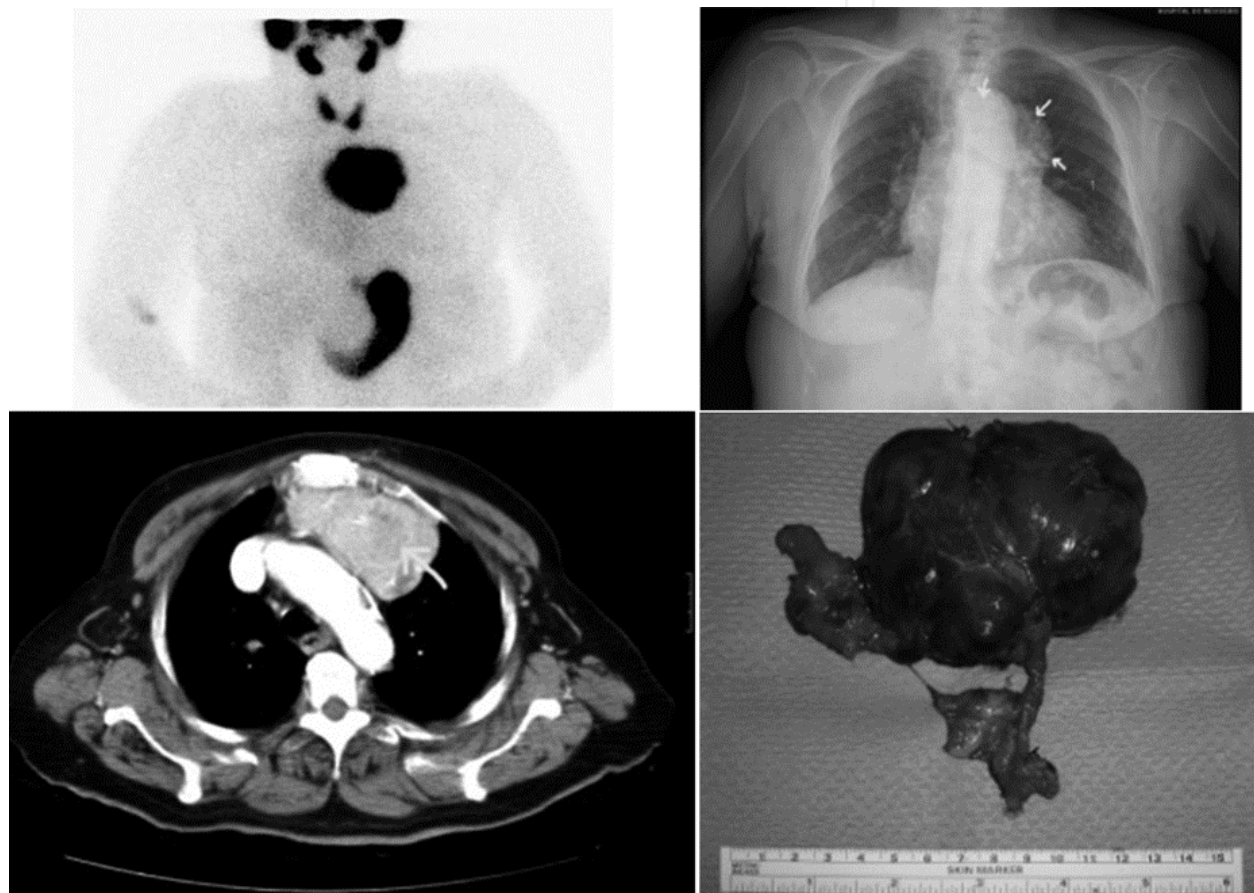


Figure 15. Thyroid Scintigraphy with I-131 radiotracer, Chest Radiograph, Axial contrast enhanced CT scan at mediastinum level and a the ectopic goiter extracted by surgery (Top left, top right, bottom left, bottom right, respectively).

Thyroid scintigraphy can also differentiate between benign adenomatous nodule or a hot nodule. The scintigraphy is made after intravenous administration of thyroid hormone and can differentiate between a hot nodule if this decrease its level of uptake or will still be hot when we are in the presence of a autonomous node. It will be useful to measure the therapeutic approach, where is going to be useful to use thyroid hormone in order to decrease the size of the hot nodule not being useful to adenomatous autonomous nodules.

Scintigraphic characteristics between I-123/I-131 and Tc-99m	
I-123 / I-131	Tc-99m
<ul style="list-style-type: none">• Half life: 13,22 Hs / 8 days• Energy: 159 keV / 354 keV• Administration path: oral• Trasported actively to the intracelular space (Trapped)• Bounded to thyrosine (Organified)• The scintigraphy will show tissue distribution of both functions (Trapped and Organified)• 3-4 hs pos oral administration imaging• Thyroid nodule evaluation• Nodular function assessment• To determine retrosternal mass• To confirm the presence of Graves Disease• To confirm the presence of multi nodular goiter• To confirm the presence of toxic adenoma• It is useful in Radioactive Iodine Uptake study and to determine the I-131 dose for radiotherapy.	<ul style="list-style-type: none">• Half life: 6,02 Hs• Energy: 140 keV• Administration path: intravenous• Transported actively to the intracelular space (Trapped)• NOT bounded to thyrosine (NOT organified)• The scintigraphy will show distribution of the function of Trap but no of organification.• 10-30 minutes pos intravenous administration• Thyroid nodule evaluation• Nodular function assessment• To determine retrosternal mass• To confirm the presence of multi nodular goiter• To confirm the presence of toxic adenoma• The Thyroid uptake is not standardized like I-123 y Tc- The measure of thyroid uptake has NO standard like I-123 y I-131, but can be evaluated in order to see the capacity of the glandular trap.

7. Positron emission tomography

PET/CT study is a nuclear medicine imaging based on the gamma acquisition coming from the aniquilation of the posittron emitted by a radiotracer administered intravenously, that in their majority of nuclear medicine centers is going to be F-18-FDG (fluorodeoxyglucose), useful for the measurement of the glucose metabolism in the wholebody, being higher in those very active and normal tissue (heart, brain, brown adipose tissue, Waldeyer ring), pathologic tissue (adenomas, multinodular goiter, Graves disease, autoimmune disease, cancer) and the radiotracer's collecting and excreting system (kidney, ureter, urinary bladder).

Primary hyperthyroidism will present a pathological increase in the activity of the thyroid gland, which can be presented as a homogeneous hyperactivity as is the typical case of Graves disease or can be a focal hyperactivity like toxic adenoma, which must be studied by FNAB since the focal hyperactivity may also been caused by malignant processes such as papillary or follicular carcinomas.

A recent publication relates the hyperthyroidism with an increase in the glucose metabolism by the brown adipose tissue. That means a problem in the assessment in the cervical soft tissue surrounding the thyroid gland because sometimes it is difficult to determine if the increased focal activity comes from a lymph node, metastasis or brown adipose tissue [24].

The PET study also is useful for assessing patients with hyperthyroidism and its mental behavior change. An article has been published in which there is a relationship between

hyperthyroidism and alteration in brain glucose metabolism, showing a decrease in glucose activity at the level of the limbic system (uncus and inferior temporal gyrus), metabolic activation in the lower area of the parietal lobe and posterior cingulated level which was related to depression and anxiety, this last symptom was also associated with the increased metabolic activity at the level of the bilateral sensory associative cortex [25]

Multiple retrospective studies have reported that incidentalomas in thyroid gland with increased focal uptake of F-18 FDG has been found in 1.2 to 4.3% of healthy patients under study by PET/CT [26-29].

It was also suggested that a diffuse increase of the uptake into the thyroid gland was more in relation with benign lesion such as chronic thyroiditis or Graves disease [30].

We display in Figure 16 a normal thyroid gland with a normal F-18 FDG activity.

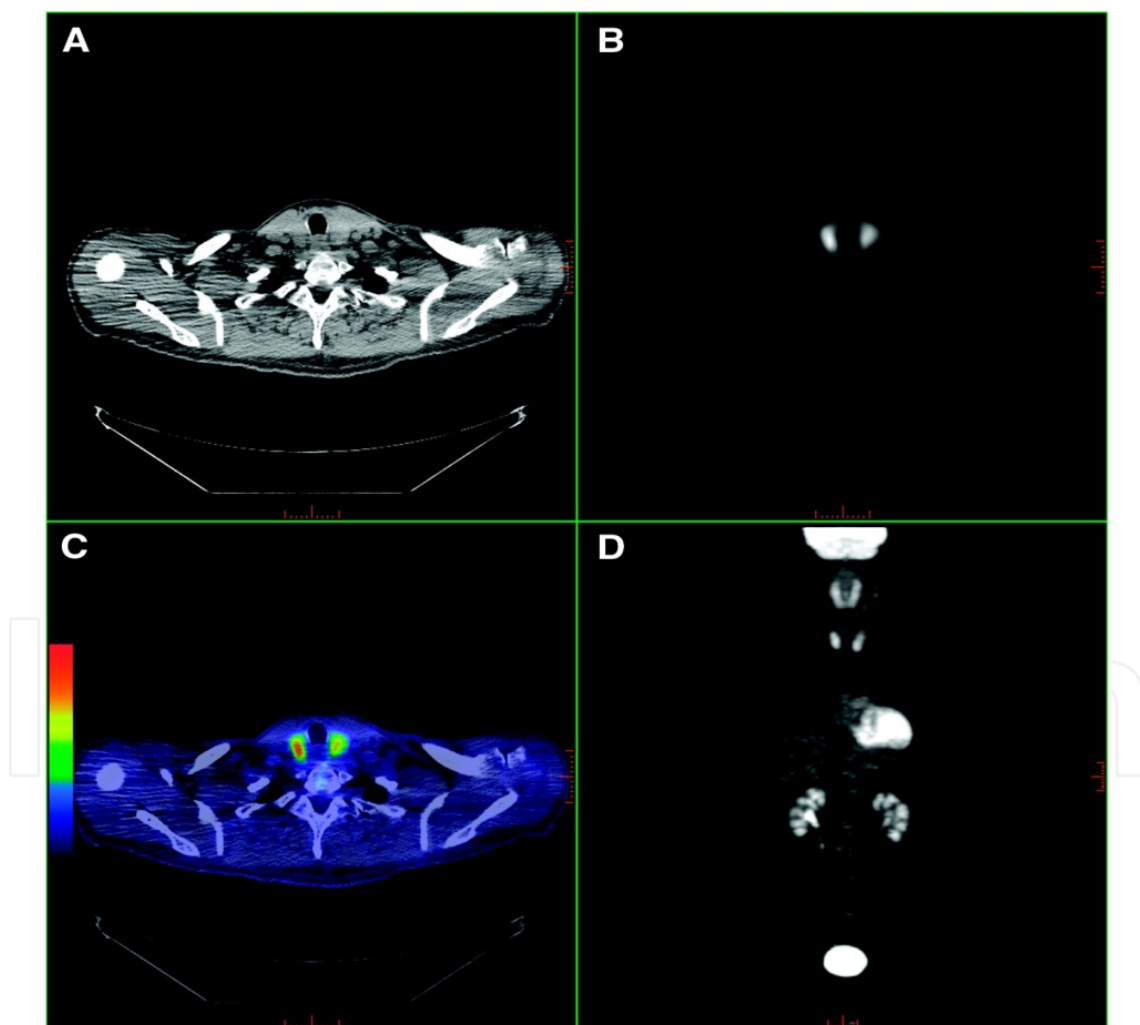


Figure 16. PET/CT scan at the thyroid gland level. Axial CT scan, emission image at thyroid level, axial PET/CT hybrid image and MIP emission image from mid-brain to bladder. The image displayed show an homogeneous activity in both thyroid lobes related to normal gland activity.

Although focal lesions with a high SUV (>10) had a high probability of malignancy, the thyroid lesions with SUV <10 have not demonstrated a high probability of benign lesion.

Inside those non-FDG radiotracers, the I-124 used for volumetric measure for dosimetric planning in the treatment of hyperthyroidism with I-131, being their results better than those obtained by ultrasonography or conventional scintigraphy [31-33]. Although I-124 is not generally available and its use is limited to specialized centres.

Either, it has been done multiple studies with the radiotracer Ga-68 DOTATOC in an attempt to find differences between benign and malignant thyroid diseases, but no good conclusion were obtained. An increased DOTATOC uptake (target to background ratio >3.4) was found in hot nodules, disseminated thyroid autonomy, and in most cases (5 of 8) of active Hashimoto's disease. In Ga-68 DOTATOC PET, normal thyroid glands show a clearly detectable radiotracer uptake with a large variability and significantly higher target to background ratios in male patients. All patients with thyroid autonomy and most patients with active Hashimoto's disease have an increased thyroid DOTATOC uptake [34].

8. Computed tomography and magnetic resonance imaging

Both studies are useful for the anatomic description in high resolution of the thyroid gland, their nodes compositions, the adjacent structures characteristics when a thyroid goiter is present (trachea and esophagus principally), ophtalmopatias associated to Graves Disease, pituitary gland in secondary hyperparathyroidism, mediastinal structures in ectopic goiters and pelvic alteration when a struma ovarii exist.

They will be useful in the gland measurement for the surgery planning or metabolic therapy with I-131.

In pos-therapy control period, both imaging studies are going to be useful for the follow-up of the cervical and extracervical region.

One of the most undesirable effects that might occur in a thyroid enhanced contrast CT is the induction of a thyrotoxicosis or thyroid storm [35-39].

9. Characteristic of imaging reports

9.1. Ultrasonography report

- Classification of a palpated nodule. eg solid, cystic, mixed
- Evaluate adjacent structures
- Determining the location of a palpable lump (within or outside of the thyroid)
- Identifying a cause for *Hyperthyroidism*

- Post surgical complications eg abscess, oedema
- Multi Nodular Goiter: Follow up nodules
- Guidance of injection, aspiration or biopsy
- Relationship of normal anatomy and pathology to each other

9.2. Scintigraphic report

- Configuration of the thyroid gland (homogeneity, nodules, size, location)
- Nodules activity (hot-warm-cold) respect to normal thyroid parenchima
- Extracervical pathologic activities
- Wholebody physiologic activities
- Thyroid Radioiodide Uptake Curve (RAIU)

9.3. Positron emission tomography report

- Metabolic feature of the thyroid gland (homogeneity, size, location)
- Nodular metabolic activity respect the normal thyroid parenchima
- Metabolic activity of Thyroid Goiter
- Semicuantification by SUV (Standard Uptake Value)
- Metabolic scanning of the whole body
- Metabolic activity of the pituitary gland, mediastinum and genitals (secondary hyperthyroidism)

9.4. Computed tomography report

- Configuration of thyroid gland (homogeneity, nodules, size, location)
- Nódules density (solid, cystic, mixed, calcium inside, abscess)
- Cervical and mediastinal lymphadenopathies
- Extracervical metastatic lesions (cranial, thorax, abdomen, pelvis, limbs)

9.5. Magnetic resonance imaging report

- Configuration of thyroid gland (homogeneity, nodules, size, location)
- Nódules density (solid, cystic, mixed, abscess)
- Cervical and mediastinal lymphadenopathies
- Extracervical metastatic lesions (cranial, thorax, abdomen, pelvis, limbs)

10. Metabolic radiotherapy

This therapy has a high success rate and carries a minimum risk. More than 80% of patients are successfully treated with a single dose. The disadvantages are minimal between them:

- Hypothyroidism (0-45 %)
- cervical compressive symptoms (2-4 days post administration of I-131)
- acute inflammation
- post-radiation thyroiditis (1-5%) (5-10 days post administration of I-131)
- exacerbation of thyrotoxicosis (7-10 days post administration of I-131)
- development of Graves (< 1%) disease
- acute sialitis

If there is no suspicion of malignancy, metabolic radiotherapy is indicated when the goiter causes local symptoms, such as dyspnoea or dysphagia. It is the therapy of choice, particularly in elderly patients, with diseases that increase the risk of surgical results or have a recurrence in post-surgery period (they have 10 times more likely to suffer damage to the laryngeal nerve).

The radiation dose to the thyroid following an administration of I-131 depends on:

- administered dose
- glandular size
- homogeneity in glandular distribution
- percentage of uptake at 24 hours
- Time of the I-131 inside the gland.

Patients with multi nodular goiter or toxic adenoma need one radioactive dose greater than grave's disease to achieve an euthyroid state.

10.1. Measuring procedure

The pretherapy dosimetry should include the following tasks [40]:

- Target mass delineation by sonography or other suitable procedure.
- Quantification of the tracer activity with a dose calibrator.
- Measurement of the tracer activity with the test device, probe or gamma camera, with the activity located in the phantom or in free air with the relevant count rate correction.
- Verification that the observed count rate per activity matches the expected sensitivity value of the device.
- Administration of the tracer activity with accurate documentation

- If liquid ^{131}I -NaI is administered, measurement of the residual activity and determination of the activity administered and the corresponding count rate.
- In-vivo measurements of the ^{131}I uptake in the target tissue at the times stated in section Time lines.
- Calculation of the radioiodine activity needed for therapy according to section Data evaluation.

10.2. Potential sources of error

The evaluation of the therapeutic activity necessary to administer a specified target dose might be erroneous due to [40]:

- Errors in target volume determination
- Inappropriate attenuation correction (no or inadequate phantom)
- Contamination of the phantom
- Incorrect distance between the detector and the patient or phantom
- Deviation of the individual target tissue depth from the calibration depth
- Inappropriate centring of the probe over the phantom or the target tissue (target tissue partially outside the probe's FoV)
- Instability of the electronics of the measuring device, especially if quality control is inadequate
- Variation in background count rate (e.g. from radiation emitted by other patients) for the different uptake measurements
- Reduced or delayed absorption due to recent food intake
- Recent administration of another radionuclide
- Unfavourable choice of timing of the uptake measurements

11. Nanoparticles and future vision

According to Ramsden [41], increased vascularity in the thyroid can occur in hyperplastic goiter, Graves' disease and cancer, and may be associated with a vascular hum because of increased blood flow.

Interestingly, in experimental induction of goiter by low Iodine and thiouracil in rats, Wollman et al. [42] showed that the capillaries within the thyroid clearly enlarged within 3 days of treatment, and by 20 days, they surrounded the follicles with a continuous endothelial sheet. There was both fusion of capillaries and mitosis of endothelial cells.

Data suggest that, in human thyroid tumors, angiogenesis factors seem involved in neoplastic growth and aggressiveness.

The thyroid is an excellent model for the integrated control of angiogenesis, because of the vascularity of the thyroid gland, and its capacity to increase its blood flow in disease [43].

Biomolecular nanotechnology defined as “the threedimensional positional control of molecular structure to create materials and devices to molecular precision” recently has grown to the multifaceted industry providing new approaches to the old problems [44].

Nanodevices can receive the natural chemical messages transmitted from and between cells simply by eavesdropping on the natural molecular message traffic. Of course, mechanical (e.g., cytoskeletal) and electrical (e.g., ionic) cellular emanations may also be detectable by nanodevices [44].

Nanoparticles have emerged as agents for diagnosis and treatment with the distinction of being manipulated in their surface structure, thereby allowing a longer intravascular circulation period, physical and chemical manipulation of energy, and being directed specifically to the target, achieving a target cell-specific uptake, allowing increased detection sensitivity through pathological signal amplification [45].

The application of nanoparticle-labelbased all-in-one dry-reagent immunoassay for thyroid stimulating hormone was reported by Huntinen et al. [46]. The magnetic properties of magnetic nanoparticles (MNPs) allow them to be imaged via magnetic resonance imaging (MRI) and targeted to a particular region by an externally applied MF (magnetic field). Once loaded with drug, MNPs can be targeted to a region of interest through an externally applied MF, and the drug released over a period of weeks. This helps to achieve optimal dosing by reducing the systemic toxicity of the drug, and decreases the likelihood of drug resistance that would result from insufficient drug present. Through MRI imaging, the biodistribution of MNPs and indirectly the drug concentration may be determined [47].

Mousa et al. [48] described methods of treating subjects having conditions related to angiogenesis including administering an effective amount of a polymeric nanoparticle form of thyroid hormone agonist, partial agonist or an antagonist to promote or inhibit angiogenesis in the organism.

Huang et al. [49] demonstrated an implementation of a time-resolved luminescence (TRL) assay for the sensitive and selective detection of thyroglobulin (Tg), a thyroid cancer marker, in homogeneous solution using water-soluble alpha-Dmannose-conjugated Au nanodots (Man-Au NDs). They employed those nanodots as a luminescence sensor for the detection of the thyroid-cancer marker thyroglobulin (Tg) in homogeneous solutions. Because luminescence quenching of the Man-Au NDs by Con A is inhibited by Tg selectivity, scientists obtained a highly sensitive and selective assay for Tg.

Many drugs can be delivered as NP and the opportunities for applying single and combined experimental medical therapy are almost inexhaustible.

12. Future works

The other idea is to investigate the effect of ionizing radiation and cancerogens on vascular structures observed in thyroid tissues. That research might elucidate the pathological changes similar to those which occur in nuclear atomic disaster survivors and provide knowledge for the implementation of drugs for radiation damage prevention and cancer treatment.

Could be interesting to develop more works into the endocrine imaging field in order to improve the differentiation between benign and malignant thyroid lesions.

Regarding the nanotechnology applied to the sphere of endocrine cancers and thyroid disease in particular, it is difficult to predict all the effects of NP to the alive human organism and that is why the major sources of experimental evidence are animal studies where tumors are produced unnaturally and NP are delivered during various stages of pathological process.

Acknowledgements

I would like to express my sincere appreciation to Ms Melina Masciotra for her great contribution to this chapter to english translation.

Author details

Javier L. Pou Ucha

Nuclear Medicine Department, Hospital Provincial de Rosario, Rosario, Argentina

Author is a permanent Member of the European Association of Nuclear Medicine

References

- [1] Steffensen FH, Aunsholt NA. Hyperthyroidism associated with metastatic thyroid carcinoma. *Clin Endocrinol (Oxf)*. 1994 Nov;41(5):685-7
- [2] Pou Ucha J, Loira Bamio F, Campos Villarino LM, Serena Puig A, Nuño Vázquez-Garza J, Pena González E. Hyperthyroidism due to an ectopic intrathoracic thyroid. *Rev Esp Med Nucl*. 2009 Jan-Feb;28(1):15-7
- [3] Sunthornthepvarakui T, Gottschalk ME, Hayashi Y, Refetoff S. Brief report: resistance to thyrotropin caused by mutations in the thyrotropin-receptor gene. *N Engl J Med*. 1995 Jan 19;332(3):155-60

- [4] Mastorakos G, Mitsiades NS, Doufas AG, Koutras DA. Hyperthyroidism in McCune-Albright syndrome with a review of thyroid abnormalities sixty years after the first report. *Thyroid*. 1997 Jun;7(3):433-9
- [5] Dunzendorfer T, deLas Morenas A, Kalir T, Levin RM. Struma ovarii and hyperthyroidism. *Thyroid*. 1999 May;9(5):499-502
- [6] El-Shirbiny AM, Stavrou SS, Dnistrian A, Sonenberg M, Larson SM, Divgi CR. Jod-Basedow syndrome following oral iodine and radioiodinated-antibody administration. *J Nucl Med*. 1997 Nov;38(11):1816-7
- [7] Hamilton CR Jr, Adams LC, Maloof F. Hyperthyroidism due to thyrotropin-producing pituitary chromophobe adenoma. *N Engl J Med*. 1970 Nov 12;283(20):1077-80
- [8] McDermott MT, Ridgway EC. Thyroid hormone resistance syndromes. *Am J Med*. 1993 Apr;94(4):424-32
- [9] Hershman JM. Human chorionic gonadotropin and the thyroid: hyperemesis gravidarum and trophoblastic tumors. *Thyroid*. 1999 Jul;9(7):653-7
- [10] Hegedüs L. Clinical practice. The thyroid nodule. *N Engl J Med* 351:1764-1771
- [11] Ezzat S, Sarti DA, Cain DR, Braunstein GD. Thyroid incidentalomas. Prevalence by palpation and ultrasonography. *Arch Intern Med* 154:1838-1840
- [12] Favus MJ, Schneider AB, Stachura ME, Arnold JE, Ryo UY, Pinsky SM, Colman M, Arnold MJ, Frohman LA. Thyroid cancer occurring as a late consequence of head-and-neck irradiation. Evaluation of 1056 patients. *N Engl J Med* 1976; 294:1019-1025
- [13] Solbiati L, Osti V, Cova L, Tonolini M. Ultrasound of thyroid, parathyroid glands and neck lymph nodes. *Eur Radiol* 11:2411-2424
- [14] Kim EK, Park CS, Chung WY, Oh KK, Kim DI, Lee JT, Yoo HS. New sonographic criteria for recommending fine-needle aspiration biopsy of nonpalpable solid nodules of the thyroid. *Am J Roentgenol* 178:687-691
- [15] Görges R, Eising EG, Fotescu D, Renzing-Köhler K, Frilling A, Schmid KW, Bockisch A, Dirsch O. Diagnostic value of high-resolution B-mode and power-mode sonography in the follow-up of thyroid cancer. *Eur J Ultrasound*. 2003 Feb;16(3):191-206
- [16] Fukunari N, Nagahama M, Sugino K, Mimura T, Ito K, Ito K. Clinical evaluation of color Doppler imaging for the differential diagnosis of thyroid follicular lesions. *World J Surg*. 2004 Dec;28(12):1261-5
- [17] Fukunari N. Thyroid ultrasonography B-mode and color-Doppler. *Biomed Pharmacother*. 2002;56 Suppl 1:55s-59s
- [18] Belzarena C, Lago G, Lang R, et al. Propuesta 2000 para el tratamiento y seguimiento del carcinoma diferenciado de tiroides. *Endocrinología y nutrición* 2001; 48(3): 70-77

- [19] Lyshchik A, Higashi T, Asato R, Tanaka S, Ito J, Mai JJ, Pellot-Barakat C, Insana MF, Brill AB, Saga T, Hiraoka M, Togashi K. Thyroid gland tumor diagnosis at US elastography. *Radiology*. 2005 Oct;237(1):202-11
- [20] Rago T, Santini F, Scutari M, Pinchera A, Vitti P. Elastography: new developments in ultrasound for predicting malignancy in thyroid nodules. *Clin Endocrinol Metab* 92:2917-2922
- [21] Unlütürk U, Erdoğan MF, Demir O, Güllü S, Başkal N. Ultrasound elastography is not superior to grayscale ultrasound in predicting malignancy in thyroid nodules. *Thyroid* 2012 Oct;22(10):1031-8
- [22] Arturi F, Russo D, Schlumberger M, du Villard JA, Caillou B, Vigneri P, Wicker R, Chiefari E, Suarez HG, Filetti S. Iodide symporter gene expression in human thyroid tumors. *Clin Endocrinol Metab* 83:2493-96
- [23] Pino Rivero V, Montero García C, Keituaqwa Yáñez T, Rejas Ugena E, Blasco Huelva A. The use of scintigraphy and fine needle aspiration biopsy (FNAB) in thyroid surgery and review of literature. *An Otorrinolaringol Ibero Am*. 2003;30(2):161-9.
- [24] Lahesmaa M, Orava J, Schalin-Jäntti C, Soinio M, Hannukainen JC, Noponen T, Kirjavainen A, Iida H, Kudomi N, Enerbäck S, Virtanen KA, Nuutila P. Hyperthyroidism increases brown fat metabolism in humans. *J Clin Endocrinol Metab*. 2013 Oct 23 [Epub ahead of print]
- [25] Schreckenberger MF, Egle UT, Drecker S, Buchholz HG, Weber MM, Bartenstein P, Kahaly GJ. Positron emission tomography reveals correlations between brain metabolism and mood changes in hyperthyroidism. *J Clin Endocrinol Metab*. 2006 Dec; 91(12):4786-91
- [26] Cohen MS, Arslan N, Dehdashti F, Doherty GM, Lairmore TC, Brunt LM, Moley JF. Risk of malignancy in thyroid incidentalomas identified by fluorodeoxyglucose-positron emission tomography. *Surgery*. 2001;130:941-946
- [27] Kang KW, Kim SK, Kang HS, Lee ES, Sim JS, Lee IG, Jeong SY, Kim SW. Prevalence and risk of cancer of focal thyroid incidentaloma identified by 18F-fluorodeoxyglucose positron emission tomography for metastasis evaluation and cancer screening in healthy subjects. *J Clin Endocrinol Metab*. 2003;88:4100-4104
- [28] Chen YK, Ding HJ, Chen KT, Chen YL, Liao AC, Shen YY, Su CT, Kao CH. Prevalence and risk of cancer of focal thyroid incidentaloma identified by 18F-fluorodeoxyglucose positron emission tomography for cancer screening in healthy subjects. *Anticancer Res*. 2005;25:1421-1426
- [29] Yi JG, Marom EM, Munden RF, Truong MT, Macapinlac HA, Gladish GW, Sabloff BS, Podoloff DA. Focal uptake of fluorodeoxyglucose by the thyroid in patients undergoing initial disease staging with combined PET/CT for non-small cell lung cancer. *Radiology*. 2005;236:271-275

- [30] Yasuda S, Shohtsu A, Ide M, Takagi S, Takahashi W, Suzuki Y, Horiuchi M. Chronic thyroiditis: diffuse uptake of FDG at PET. *Radiology*. 1998;207:775-778
- [31] Eschmann SM, Reischl G, Bilger K, Kupferschläger J, Thelen MH, Dohmen BM, Besenfelder H, Bares R. Evaluation of dosimetry of radioiodine therapy in benign and malignant thyroid disorders by means of iodine-124 and PET. *Eur J Nucl Med Mol Imaging*. 2002 Jun;29(6):760-7
- [32] Matheoud R, Canzi C, Reschini E, Zito F, Voltini F, Gerundini P. Tissue-specific dosimetry for radioiodine therapy of the autonomous thyroid nodule. *Med Phys*. 2003;30:791-8
- [33] Canzi C, Zito F, Voltini F, Reschini E, Gerundini P. Verification of the agreement of two dosimetric methods with radioiodine therapy in hyperthyroid patients. *Med Phys*. 2006;33:2860-7
- [34] Lincke T, Orschekowski G, Singer J, Sabri O, Paschke R. Increased gallium-68 DOTA-TOC uptake in normal thyroid glands. *Horm Metab Res*. 2011 Apr;43(4):282-6
- [35] Blum M, Weinberg U, Shenkman L, Hollander CS. Hyperthyroidism after iodinated contrast medium. *N Engl J Med*. 1974 Jul 4;291(1):24-5
- [36] Hehrmann R, Klein D, Mayer D, Ploner O. Risk of hyperthyroidism in examinations with contrast media. *Aktuelle Radiol*. 1996 Sep;6(5):243-8
- [37] Alkhuja S, Pyram R, Odeyemi O. In the eye of the storm: iodinated contrast medium induced thyroid storm presenting as cardiopulmonary arrest. *Heart Lung*. 2013 Jul-Aug;42(4):267-9
- [38] Rhee CM, Bhan I, Alexander EK, Brunelli SM. Association between iodinated contrast media exposure and incident hyperthyroidism and hypothyroidism. *Arch Intern Med*. 2012 Jan 23;172(2):153-9
- [39] Grady D. Another reason to be cautious about imaging: comment on "association between iodinated contrast media exposure and incident hyperthyroidism and hypothyroidism". *Arch Intern Med*. 2012 Jan 23;172(2):161
- [40] *Eur J Nucl Med Mol Imaging*. 2013 Jul;40(7):1126-34
- [41] Rhee CM, Bhan I, Alexander EK, Brunelli SM. Association between iodinated contrast media exposure and incident hyperthyroidism and hypothyroidism. *J Endocrinol*. 2000 Sep;166(3):475-80
- [42] Wollman SH, Herveg JP, Zeligs JD, Ericson LE. Blood capillary enlargement during the development of thyroid hyperplasia in the rat. *Endocrinology*. 1978 Dec;103(6):2306-14
- [43] Ramsden JD. Angiogenesis in the thyroid gland. *J Endocrinol*. 2000 Sep;166(3):475-80
- [44] Freitas, R.A., Nanomedicine. 1999, Austin, TX: Landes Bioscience

- [45] Pou Ucha, Javier L. (2013). Nanoparticles in bioimaging. In Arun Kumar, et al (Ed.), *Nanomedicine in Drug Delivery*. Boca Ratón, FL: Taylor & Francis Group; 2013 (pp. 187-212).
- [46] Huhtinen P, Pelkkikangas AM, Jaakohuhta S, Lövgren T, Härmä H. Quantitative, rapid europium(III) nanoparticle-label-based all-in-one dry-reagent immunoassay for thyroid-stimulating hormone. *Clin Chem*. 2004 Oct;50(10):1935-6
- [47] Varadan, Vijay K., Linfeng Chen, and Jining Xie, "Magnetic nanomaterials, nanotubes, and nanomedicine", Chapter 9, "Nanomedicine-Design of particles, sensors, motors, implants, robots, and devices", Artech House, 2009
- [48] Mousa SA, Davis PJ, Hercbergs A (2009). Nanoparticle and polymer formulations for thyroid hormone analogs, antagonists and formulations and uses thereof. United States Patent and Trademark Office Pre-Grant Publication
- [49] Huang CC, Hung YL, Shiang YC, Lin TY, Lin YS, Chen CT, Chang HT. Photoassisted synthesis of luminescent mannose-Au nanodots for the detection of thyroglobulin in serum. *Chem Asian J*. 2010 Feb 1;5(2):334-41

