

We are IntechOpen, the world's leading publisher of Open Access books Built by scientists, for scientists

6,900

Open access books available

185,000

International authors and editors

200M

Downloads

Our authors are among the

154

Countries delivered to

TOP 1%

most cited scientists

12.2%

Contributors from top 500 universities



WEB OF SCIENCE™

Selection of our books indexed in the Book Citation Index
in Web of Science™ Core Collection (BKCI)

Interested in publishing with us?
Contact book.department@intechopen.com

Numbers displayed above are based on latest data collected.
For more information visit www.intechopen.com



A Review of the Pathogenesis and Management of Multinodular Goiter

Shi Lam and Brian Hung-Hin Lang

Additional information is available at the end of the chapter

<http://dx.doi.org/10.5772/57547>

1. Introduction

1.1. Definition and gross pathology

Multinodular goiter (MNG) is a clinicopathological entity characterized by an increased volume of the thyroid gland with formation of nodules. Goiter is defined as a thyroid gland weighing over 20-25g or with a volume of over 19ml in women and 25ml in men. [1-2] Gross examination of a MNG specimen with full-blown features would reveal a heterogeneous formation of solid and cystic nodules. A solid nodule can be adenoma, as defined by possession of a well-formed capsule, or more commonly a hyperplastic nodule, which lacks a complete encapsulation. Cystic lesions can be colloid cysts or hemorrhagic cyst from a degenerated nodule. Lymphocytic infiltration and fibrous deposition among the follicular parenchyma is a common microscopic observation seen in about 10% of cases. [3, 4]

2. Epidemiology

MNG is endemic in regions with low iodine level in the soil, such as countries in the mountainous areas in South-East Asia, Latin America and Central Africa. The World Health Organization reported a worldwide iodine deficiency rate of 9.8 – 56.9% and total goiter prevalence of 4.7 – 37.3% by year 2003. [5] The Whickham study conducted in the 1970s found 15.5% of participants had a palpable goiter with a female to male ratio of 4.5 to 1. [6] In the iodine-deficient Danish population, the goiter prevalence is 9.8 – 14.6%. [7] And in the iodine sufficient areas of Framingham, Massachusetts and Connecticut, the goiter prevalence is 1 – 2%. [8-10] By ultrasound screening, the prevalence of nodular goiter worldwide ranges between 15 – 22.6%. [11] Thyroid nodules are more commonly diagnosed in women, with

incidence increasing with age and plateauing by the age of 60. Other risk factors for developing thyroid nodules and increased thyroid volume include number of childbirths, smoking and increased body mass index. [12-13]

3. Pathogenesis

The pathogenesis of MNG encompasses processes of diffuse follicular hyperplasia, focal nodular proliferation and eventual acquisition of functional automaticity. The development of MNG is a result of long-term exposure of the thyroid gland to proliferative stimuli, such as iodine deficiency, goitrogens and inborn error of thyroid hormone synthesis. All of the above results in insufficient thyroid hormone production and stimulate pituitary secretion of thyroid stimulating hormone (TSH).

TSH is a glycoprotein with stimulatory effect on the trophic and iodine metabolism pathway in the thyroid follicular cells. TSH binding to the cell membrane G protein-coupled receptor activates the cAMP and phospholipase C signalling pathways, which in turn upregulates the process of iodine uptake and organification, thyroglobulin synthesis, iodotyrosine coupling and iodothyronine (T₃, T₄) secretion, leading to a short-term response in thyroid hormone production. [14] In the long-term, TSH also stimulates proliferation of follicular cells to increase the functional mass of thyroid gland. Clinically, TSH stimulation results in enlargement of thyroid gland, increased radio-iodine uptake and increased T₄ and T₃ levels. (Figure 1)

Nodule formation is postulated to be the result of both an inherent and acquired heterogeneity in proliferative and functional upregulation of the follicular cells. The thyroid follicular cells are inherently heterogeneous with regard to thyroid hormone production and proliferation in response to TSH stimulation, such that under intermediate level of stimulation, a subpopulation of follicular cells outgrows other cells and expand into macroscopic nodules. [15] On the other hand, follicular cells acquiring activating somatic mutations in the cell proliferation pathways can expand clonally to form a nodule. About 60 – 70% of nodules form by the later mechanism and are monoclonal in origin. Somatic mutations leading to constitutive activation of TSH receptors are found in about 60% of autonomously functioning nodules. The remaining 40% of functioning nodules are TSH receptor mutation negative with poorly understood genetic mechanism behind.

An adenoma with reduced iodine uptake is scintigraphically detected as a “cold nodule”. A defective iodine transport (membrane expression of sodium / iodine symporter protein) and iodine organification is implicated in the hypofunctionality. However, the molecular event accounting for the proliferative advantage is yet to be identified. [16] Unlike thyroid carcinomas, which also manifest as cold nodules in scintigraphy, *BRAF* and *ras* mutation are uncommon in benign cold adenoma. [17, 18] Recently, oestrogen was shown to stimulate growth of thyroid progenitor cells while simultaneously inhibiting the expression of sodium / iodine symporter mRNA, providing a possible explanation of growth / function dissociation in cold thyroid adenomas. [19]

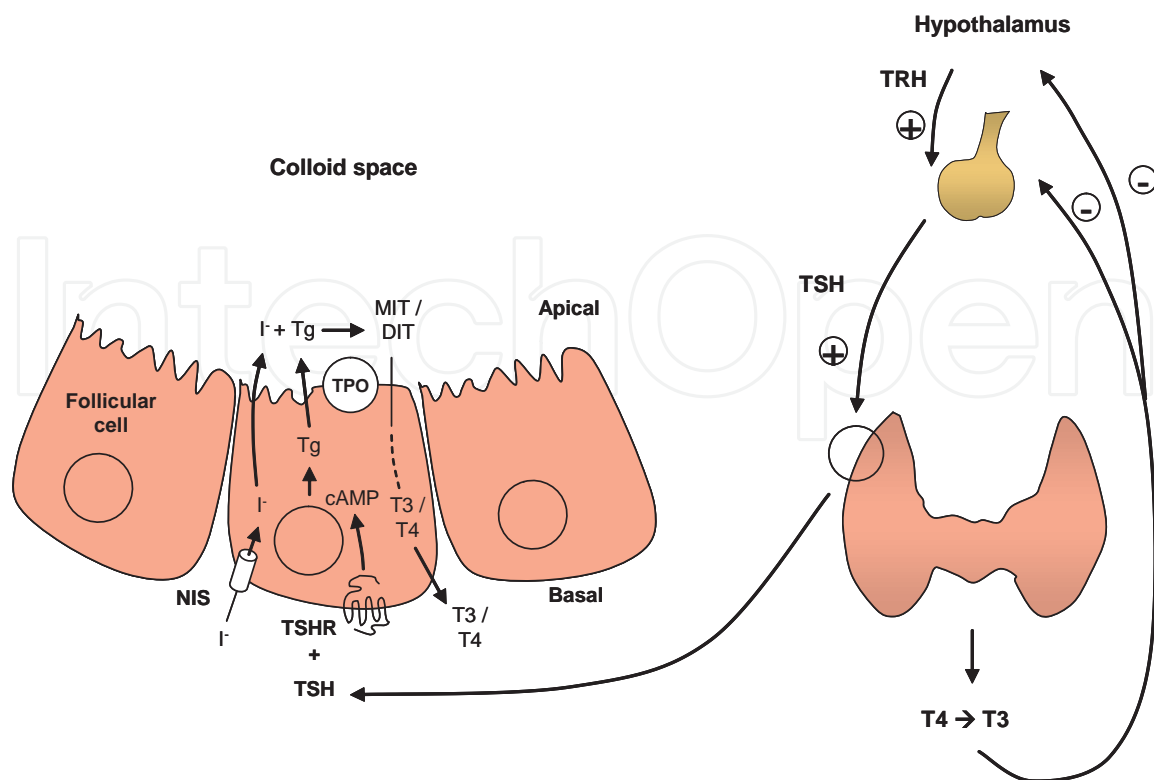


Figure 1. Regulation of thyroid hormone production

Although the majority of thyroid nodules are benign, about 5-10% of nodules may harbour a cancerous focus. In addition, it is known that about 6% of goiter patients eventually develop thyroid cancer, especially from MNG to thyroid cancer, suggesting a possible progression from benign thyroid lesions to malignant disease. [20] More recently, one group has identified a germline missense mutation (1016C>T) in TITF-1/NKX2. 1 encoding a mutant TTF-1 protein (A339V), which may contribute to predisposition for MNG patients to papillary thyroid carcinoma (PTC), further highlighting a causal link between these two diseases. [21] Ectopic expression of the A339V mutant protein in a normal rat thyroid PCCL3 cell line results in a significant up-regulation of cellular proliferation of these thyroid cells and promotes their TSH-independent growth, which was in part attributed to activated Stat3 survival signal in these cells.

4. Natural history

The natural history of MNG is nodular growth and acquisition of autonomy. Yet not all patients with nodular goiter will progress to develop compressive or thyrotoxic complications that indicates treatment intervention. The reported incidence rate of nodule growth is 39% of patients over a period of 5 years in the North America, 2 – 56% of patients over 2 – 5 years in European countries and 21% over 11 years in Japan. Nodule with cystic component is less likely to grow than solid nodules. Patient's age, gender or nodule size and function at presen-

tation did not predict subsequent growth of nodules. Based on cross-sectional studies, the age-related increase in thyroid volume in patients with MNG is 4.5% per year. [16, 22]

Functional autonomy develops in long-standing MNGs. Thyroid autonomy in euthyroid nodular goiters, as determined by presence of TSH suppression by thyrotropin releasing hormone (TRH) stimulation tests and failure of T3 suppression of radio-iodine uptake, was shown to precede development of biochemical and overt hyperthyroidism. Up to 40% of euthyroid goiters harbour areas of autonomy.

Transition to overt hyperthyroidism in euthyroid MNGs occurs at an incidence rate of 9 – 10% over a period of 7 – 12 years. Development of hyperthyroidism is more likely in patients with autonomously functioning nodules of larger than 3cm and an autonomous goiter volume of 16ml. Hyperthyroidism can be induced by exposing an autonomous gland to excessive iodine, such as the iodine-containing amiodarone. [23–25]

5. Clinical evaluation & investigation

Clinical evaluation of MNG aims at establishing diagnosis and clinical stage of disease, stratifying risk of occurrence of malignancy, identifying indications for thyroid ablation and addressing patient's concern.

Diagnosis of MNG is usually straight forward with the readily evaluable location of the thyroid gland. Clinically inconspicuous MNG are usually documented by imaging studies covering the neck and thoracic inlet performed for unrelated indications. MNGs with predominant retrosternal component are difficult to diagnose with patients undergoing prolonged investigations for symptoms of exertional or recumbent dyspnoea that mimic asthma, congestive heart failure or obstructive sleep apnoea. The tell-tail clue leading to thoracic inlet imaging and diagnosis of retrosternal goiter is frequently a flow-volume loop spirometry suggesting extra-thoracic airway obstruction or chest X-ray showing a mediastinal shadow causing tracheal deviation. Symptoms arising from airway irritation, compression and dragging by the goiter should be noted and addressed in patient counselling for treatment indications. Physical findings of nodule consistency and mobility, cervical lymphadenopathy, tracheal deviation, retromanubrial extension, thoracic outlet obstruction and thyrotoxicosis are determined. When thyrotoxicosis is suspected, the differential diagnosis of Grave's disease with nodules should be considered and the signs specific to Grave's disease, including ophthalmopathy and pre-tibial myxoedema be documented.

Serum thyroid stimulating hormone and free serum thyroxine levels are measured to determine the functioning status of the nodular goiter. A suppressed TSH level is commonly found in long-standing MNGs in which functional autonomy has developed. Hypothyroidism, on the other hand, may suggest Hashimoto thyroiditis and measurement of anti-thyroperoxidase antibody titre helps to confirm the diagnosis.

Thyroid scintigraphy using iodine-123 or technetium-99m is recommended for patients with suppressed serum TSH level to determine the relative iodine uptake of a nodule in contrast to its adjacent thyroid tissue. A hyperfunctioning nodule that can account for the thyrotoxicosis

carries low risk of malignancy and further investigation is not required. An index nodule that is iso- or hypofunctional against the rest of thyroid gland has a reported malignancy risk of 3% to 15% and should be investigated with fine needle aspiration cytology (FNAC). [26-29]

Evaluating for risk of malignancy in MNG follows the same approach as in solitary thyroid nodules. Demographical risk factors include age of < 20 or > 60 years, male gender, history of head and neck irradiation, history of multiple endocrine neoplasia or family history of thyroid cancer. Suspicious symptoms include progressive enlargement, recent onset of voice change, airway irritation and compression. Objective physical findings of hard and fixed nodule, size > 4cm, cervical lymphadenopathy and vocal cord paralysis all points to features of local-regional invasion and prompts investigation for definitive diagnosis. If the rarer entity of medullary carcinoma is suspected from a positive family history or features of multiple endocrine neoplasia (type 2), spot serum calcitonin level should be measured as a screening test. A 33% risk of malignancy is reported in avid nodules detected by fluorodeoxyglucose positron emission tomography (¹⁸FDG-PET), so such nodules should also undergo cytological evaluation. [30]

Use of ultrasound as routine clinical examination has compensated for the lack of sensitivity and precision of neck palpation alone in determining the number and size of nodules. Fifty percent of patients with single palpable thyroid nodule will demonstrate additional nodules when ultrasound exam is performed. More importantly, nodules with high risk features of malignancy, including irregular margin, lack of circumferential halo, heterogenous echogenicity, increased vascularity and presence of microcalcification, can be selected for cytological sampling.

FNAC is an accurate, safe, simple, and cost-effective investigation in the evaluation of nodular goiter. Diagnostic performance of FNAC is enhanced by ultrasound guidance in the identification of nodules with high risk features for aspiration. In complex cystic lesions, ultrasound guidance also allows positioning of needle to the solid component while avoiding acellular cystic area. Availability of pre-operative diagnostic information has increased diagnostic yield of thyroidectomies while reducing the number of surgeries performed for suspected malignancy by 35 – 75%. [31–33]

A review of diagnostic performance of FNAC reported a sensitivity of 65 – 98% and specificity of 72 – 100% for the detection of thyroid carcinoma. In general, the relative frequencies of FNAC findings in thyroid nodules are benign in 69%, suspicious 10%, malignant 4% and non-diagnostic in 17%. [34] In the “non-diagnostic” category, repeating FNA under ultrasound guidance will produce satisfactory specimen in 50% of the cases. The risk of malignancy in nodules with non-diagnostic cytology is 2 – 9%, and such lesions should be closely monitored or excised for histological evaluation. The category of “suspicious” cytology includes findings of follicular and Hurthle cell neoplasm. Differentiation between adenoma and carcinoma cannot be made because histological evidence of capsular or vascular invasion cannot be obtained from cytological examination. In patients referred for surgery for suspicious cytology, 20 – 30% are proven to have carcinoma on final pathology. [35-36] Molecular markers upregulated in thyroid carcinomas are being evaluated for their diagnostic value. Detection of protein markers (Galectin-3, HBME-1, cytokeratin-19, telomerase) by immunocytochemistry,

gene mutations (BRAF, RAS, RET/PTC rearrangement, PAX8-PPAR γ) by polymerase chain reaction (PCR), microRNAs by reverse transcriptase PCR, or multi-gene assays. [37] Yet a test with sufficient sensitivity that allows exclusion of malignancy in an indeterminate cytological category is still awaited. [38]

6. Treatment of MNG

MNG is benign disease with slow progression and at different stage of its natural history presents with different clinical problems. The clinical problem at earlier stage of disease before gross enlargement of the thyroid gland is usually a concerning dominant nodule, while later in the course patients tends to present with the mass effect of a voluminous goiter or hyperthyroidism. The indications of treatment include suspected or confirmed malignancy, thyrotoxicosis, goiters giving rise to compressive, irritative symptoms or cosmetic concern. Only the management of benign non-toxic MNG is discussed in the following text.

Asymptomatic non-toxic MNG with malignancy being ruled-out should be observed clinically or with ultrasound surveillance for nodule growth. TSH suppression by levothyroxine was shown to prevent increase in nodule size but nodule growth resumed after cessation of therapy. Long-term TSH suppression with levothyroxine is not recommended because of the increased risk of cardiac arrhythmia and osteoporosis associated with chronic subclinical hyperthyroidism. [39-40]

Evidence of significant mass effect of a nodular goiter, including symptoms of recumbent or exertional dyspnoea and signs of tracheal deviation and thoracic inlet obstruction, prompts amelioration by radio-iodine or surgery.

¹³¹I radio-iodine is effective in reducing volume of euthyroid MNG with a response rate of 80%. Volume reductions at 1 to 3 years are up to 40 – 60% respectively, with half of volume reduction occurring within 3 months of treatment. The efficacy of radio-iodine is proportional to the absorbed radiation dose, which in turn depends on the goiter volume and functioning status. Therefore, in goiters with less than 20% radioactive iodine uptake, conventional ¹³¹iodine therapy is not recommended as an unacceptably high dose of radioactivity would be required to achieve satisfactory goiter volume reduction. Pre-treatment with rhTSH before ¹³¹iodine administration can stimulate radioactive iodine uptake and was shown by randomized controlled trials to increase goiter volume reduction by 35 – 56%. rhTSH-augmentation may therefore extend the application of ¹³¹iodine therapy in euthyroid multinodular goiters by reducing the radioactive dose requirement, especially in goiters with low radioactive iodine intake. [41] Adverse effects of radio-iodine include radiation thyroiditis in 3%, transient thyrotoxicosis in 5% and later hypothyroidism in 22 – 58% in 5 – 8 years after therapy. For large goiters, radio-iodine is probably an inferior option due to incomplete volume reduction, requirement of higher radiation dose and, transient post-treatment increase in thyroid volume leading to risk of airway compression.

Surgery provides instantaneous relief of pressure effects and cosmetic concern of MNG. Subtotal thyroidectomy carries low risk of recurrent laryngeal nerve injury and hypoparathyroidism but results in a recurrence rate up to 40% in the long term. Total thyroidectomy

can achieve a negligible recurrence rate [42] and carries low complication rate in specialized centers, with < 1% risk of permanent recurrent laryngeal nerve injury or hypoparathyroidism, even in the elderly population where massive goiters are more common. [43] Due to the loss of normal tissue plane and anatomical relationship between the thyroid tissue, recurrent laryngeal nerve and parathyroid glands, reoperating on a previously explored surgical field carries a 3-to 10-fold increase in risk of permanent recurrent laryngeal nerve damage or hypoparathyroidism, rendering sub-total thyroidectomy the less preferred option. [44] Total thyroidectomy has an added advantage in case of incidentally diagnosed thyroid carcinoma, which is diagnosed in about 10% of MNG specimens [45], that completion thyroidectomy is avoided. Other forms of thyroid resection, namely hemithyroidectomy or hemithyroidectomy with contralateral subtotal resection (Dunhill's operation) may have merits in the management of selected patient group, such as those with predominantly unilateral disease and without pre-operative suspicion of malignancy. Hemithyroidectomy has the advantage of preserving thyroid function in 65 – 88% of cases and avoiding life-long thyroxine replacement. [46-47] A summary of management of MNG is schematically presented in Figure 2.

TRH, thyrotropin releasing hormone; TSH, thyroid stimulating hormone; Tg, thyroglobulin; NIS, sodium-iodine symporter; TPO, thyroperoxidase; DIT, di-iodotyrosine; MIT, monoiodo-tyrosine.

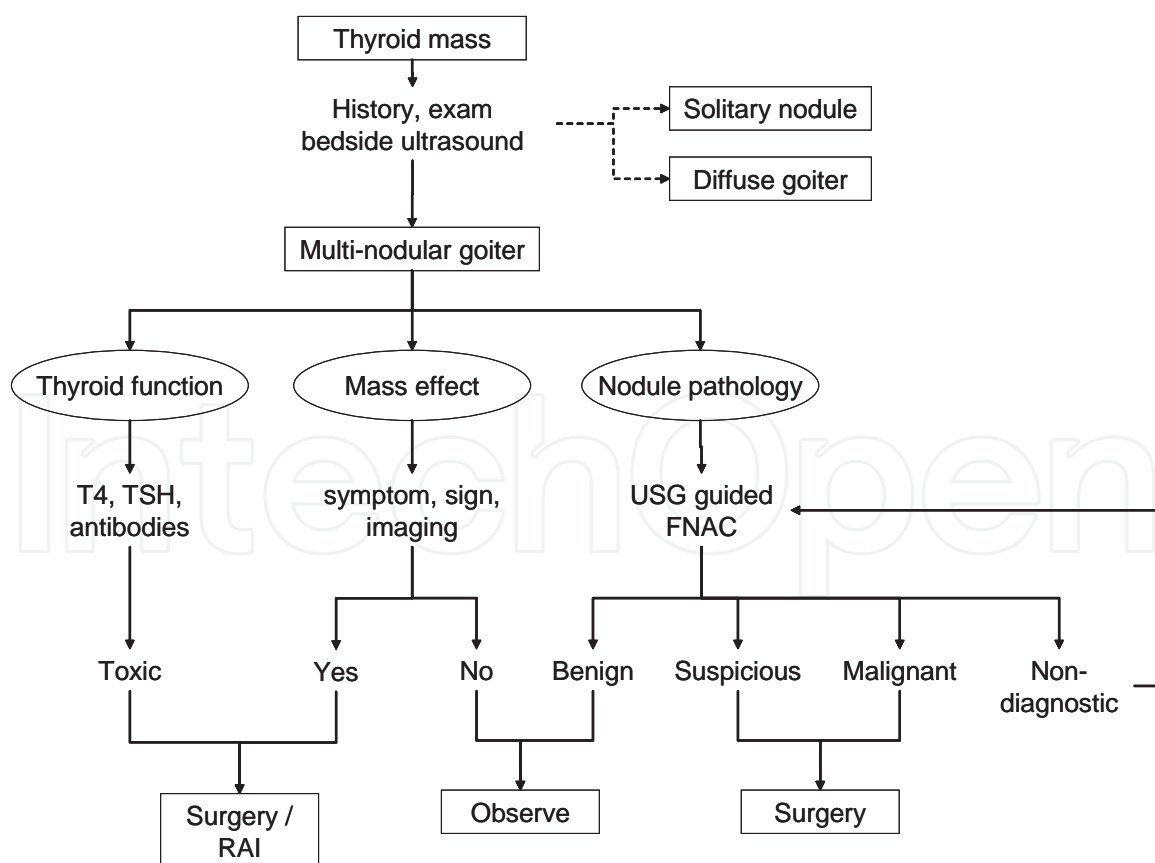


Figure 2. Management of a multinodular goiter (MNG)

Author details

Shi Lam and Brian Hung-Hin Lang*

*Address all correspondence to: blang@hku.hk

Department of Surgery, The University of Hong Kong, Hong Kong SAR, China

References

- [1] Teng W, Shan Z, Teng X, Guan H. Effect of iodine intake on thyroid diseases in China. *N Engl J Med*. 2006 Jun 29;354(26):2783-93.
- [2] Langer P. Discussion about the limit between normal thyroid and goiter: minireview. *Endocrine regulations* 1999
- [3] Ramelli F, Studer H, Bruggisser D. Pathogenesis of thyroid nodules in multinodular goiter. *Am J Pathol*. 1982 Nov;109(2):215-23.
- [4] De Smet MP. Pathological anatomy of endemic goitre. *Monogr Ser World Health Organ*. 1960;44:315-49.
- [5] WHO, Iodine Status Worldwide, WHO Global Database on Iodine Deficiency, World Health Organization Department of Nutrition for Health and Development, Geneva, Switzerland, 2004.
- [6] Tunbridge WM, Evered DC, Hall R, Appleton D, Brewis M, Clark F, Evans JG, Young E, Bird T, Smith PA The spectrum of thyroid disease in a community: the Whickham survey. *Clin Endocrinol (Oxf)* 1977; 7:481–493
- [7] Knudsen N, Perrild H, Christiansen E, Rasmussen S, Dige-Petersen H, Jørgensen T. Thyroid structure and size and two-year follow-up of solitary cold thyroid nodules in an unselected population with borderline iodine deficiency. *Eur J Endocrinol* 2000; 142:224–230
- [8] Vander JB, Gaston EA, Dawber TR. Significance of solitary nontoxic thyroid nodules. Preliminary report. *N Engl J Med* 1954; 251:970
- [9] Baldwin DB, Rowett D. Incidence of thyroid disorders in Connecticut. *JAMA* 1978; 239:742–744
- [10] Vander JB, Gaston EA, Dawber TR. The significance of nontoxic thyroid nodules. Final report of a 15-year study of the incidence of thyroid malignancy. *Ann Intern Med* 1968; 69:537–540
- [11] Wang C, Crapo LM. The epidemiology of thyroid disease and implications for screening. *Endocrinol Metab Clin North Am* 1997; 26: 189–218

- [12] Laurberg P, Jørgensen T, Perrild H, Ovesen L, Knudsen N, Pedersen IB, Rasmussen LB, Carlé A, Vejbjerg P. The Danish investigation on iodine intake and thyroid disease, DanThyr: status and perspectives. *Eur J Endocrinol*. 2006 Aug;155(2):219-28.
- [13] Guth S, Theune U, Aberle J, Galach A, Bamberger CM. Very high prevalence of thyroid nodules detected by high frequency (13 MHz) ultrasound examination. *Eur J Clin Invest*. 2009 Aug;39(8):699-706.
- [14] Szkudlinski MW, Fremont V, Ronin C, Weintraub BD. Thyroid-stimulating hormone and thyroid-stimulating hormone receptor structure-function relationships. *Physiol Rev*. 2002 Apr;82(2):473-502.
- [15] Studer H, Peter HJ, Gerber H. Natural heterogeneity of thyroid cells: the basis for understanding thyroid function and nodular goiter growth. *Endocr Rev*. 1989 May;10(2):125-35.
- [16] Paschke R. Molecular pathogenesis of nodular goiter. *Langenbecks Arch Surg*. 2011 Dec;396(8):1127-36.
- [17] Krohn K, Reske A, Ackermann F, Müller A, Paschke R. Ras mutations are rare in solitary cold and toxic thyroid nodules. *Clin Endocrinol*. 2001 Aug;55(2):241-8.
- [18] Krohn K, Paschke R. BRAF mutations are not an alternative explanation for the molecular etiology of ras-mutation negative cold thyroid nodules. *Thyroid*. 2004 May;14(5):359-61.
- [19] Xu S, Chen G, Peng W, Renko K, Derwahl M. Oestrogen action on thyroid progenitor cells: relevant for the pathogenesis of thyroid nodules? *J Endocrinol*. 2013 Jun 1;218(1):125-33.
- [20] Arora N, Scognamiglio T, Zhu B, Fahey TJ 3rd. Do benign thyroid nodules have malignant potential? An evidence-based review. *World J Surg*. 2008 Jul;32(7):1237-46.
- [21] Ngan ES, Lang BH, Liu T, Shum CK, So MT, Lau DK, Leon TY, Cherny SS, Tsai SY, Lo CY, Khoo US, Tam PK, Garcia-Barceló MM. A germline mutation (A339V) in thyroid transcription factor-1 (TTF-1/NKX2. 1) in patients with multinodular goiter and papillary thyroid carcinoma. *J Natl Cancer Inst*. 2009 Feb 4;101(3):162-75.
- [22] Berghout A, Wiersinga WM, Smits NJ, Touber JL. Interrelationships between age, thyroid volume, thyroid nodularity, and thyroid function in patients with sporadic nontoxic goiter. *Am J Med*. 1990 Nov;89(5):602-8.
- [23] Bähre M, Hilgers R, Lindemann C, Emrich D. Thyroid autonomy: sensitive detection in vivo and estimation of its functional relevance using quantified high-resolution scintigraphy. *Acta Endocrinol (Copenh)*. 1988 Feb;117(2):145-53.
- [24] Elte JW, Bussemaker JK, Haak A. The natural history of euthyroid multinodular goitre. *Postgrad Med J*. 1990 Mar;66(773):186-90.

- [25] Wiener JD, de Vries AA. On the natural history of Plummer's disease. *Clin Nucl Med*. 1979 May;4(5):181-90.
- [26] Campbell JP, Pillsbury HC 3rd. Management of the thyroid nodule. *Head Neck*. 1989;11:414-425.
- [27] Gharib H, Goellner JR. Fine-needle aspiration biopsy of the thyroid: An appraisal. *Ann Intern Med*. 1993;118:282-289.
- [28] La Rosa GL, Belfiore A, Giuffrida D, et al. Evaluation of the fine needle aspiration biopsy in the preoperative selection of cold thyroid nodules. *Cancer*. 1991;67:2137-2141.
- [29] Slowinska-Klencka D, Klencki M, Sporny S, Lewinski A. Fine-needle aspiration biopsy of the thyroid in an area of endemic goitre: Influence of restored sufficient iodine supplementation on the clinical significance of cytological results. *Eur J Endocrinol*. 2002;146:19-26.
- [30] Are C, Hsu JF, Ghossein RA, Schoder H, Shah JP, Shaha AR. Histological aggressiveness of fluorodeoxyglucose positron-emission tomogram (FDG-PET)-detected incidental thyroid carcinomas. *Ann Surg Oncol*. 2007 Nov;14(11):3210-5.
- [31] Werk Jr EE, Vernon BM, Gonzalez JJ, Ungaro PC, McCoy RC 1984 Cancer in thyroid nodules: a community hospital survey. *Arch Intern Med* 144:474-476
- [32] Asp AA, Georgitis W, Waldron EJ, Sims JE, Kidd 2nd GS 1987 Fine needle aspiration of the thyroid: use in an average health care facility. *Am J Med* 83:489-493
- [33] Hamburger JI 1987 Consistency of sequential needle biopsy findings for thyroid nodules: management implications. *Arch Intern Med* 147:97-99
- [34] Gharib H, Goellner JR. Fine-needle aspiration biopsy of the thyroid: an appraisal. *Ann Intern Med*. 1993 Feb 15;118(4):282-9.
- [35] Baloch ZW, Fleisher S, LiVolsi VA, Gupta PK 2002 Diagnosis of "follicular neoplasm": a gray zone in thyroid fine-needle aspiration cytology. *Diagn Cytopathol* 26:41-44.
- [36] Sahin M, Gursoy A, Tutuncu NB, Guvener DN 2006 Prevalence and prediction of malignancy in cytologically indeterminate thyroid nodules. *Clin Endocrinol (Oxf)* 65:514-518.
- [37] Hodak SP, Rosenthal DS; American Thyroid Association Clinical Affairs Committee. Information for clinicians: commercially available molecular diagnosis testing in the evaluation of thyroid nodule fine-needle aspiration specimens. *Thyroid*. 2013 Feb; 23(2):131-4.
- [38] Kato MA, Fahey 3rd TJ 2009 Molecular markers in thyroid cancer diagnostics. *Surg Clin North Am* 89:1139-1155

- [39] Papini E, Petrucci L, Guglielmi R, et al. Long-term changes in nodular goiter: a 5-year prospective randomized trial of levothyroxine suppressive therapy for benign cold thyroid nodules. *J Clin Endocrinol Metab.* 1998;83:780-783.
- [40] Wemeau JL, Caron P, Schvartz C, et al. Effects of thyroid-stimulating hormone suppression with levothyroxine in reducing the volume of solitary thyroid nodules and improving extranodular nonpalpable changes: a randomized, double-blind, placebo-controlled trial by the French Thyroid Research Group. *J Clin Endocrinol Metab.* 2002;87:4928-4934.
- [41] Fast S, Nielsen VE, Bonnema SJ, Hegedüs L. Time to reconsider nonsurgical therapy of benign non-toxic multinodular goitre: focus on recombinant human TSH augmented radioiodine therapy. *Eur J Endocrinol.* 2009 Apr;160(4):517-28.
- [42] Snook KL, Stalberg PL, Sidhu SB, Sywak MS, Edhouse P, Delbridge L. Recurrence after total thyroidectomy for benign multinodular goiter. *World J Surg.* 2007 Mar;31(3):593-8.
- [43] Lang BH, Lo CY. Total thyroidectomy for multinodular goiter in the elderly. *Am J Surg.* 2005 Sep;190(3):418-23.
- [44] Lima N, Knobel M, Cavaliere H, Szejnsznajd C, Tomimori E, Medeiros-Neto G 1997 Levothyroxine suppressive therapy is partially effective in treating patients with benign, solid thyroid nodules and multinodular goiters. *Thyroid* 7:691–697.
- [45] Gandolfi PP, Frisina A, Raffa M, Renda F, Rocchetti O, Ruggeri C, Tombolini A. The incidence of thyroid carcinoma in multinodular goiter: retrospective analysis. *Acta Biomed.* 2004 Aug;75(2):114-7.
- [46] Piper HG, Bugis SP, Wilkins GE, Walker BA, Wiseman S, Baliski CR. Detecting and defining hypothyroidism after hemithyroidectomy. *Am J Surg.* 2005 May;189(5):587-91.
- [47] Rayes N, Steinmüller T, Schröder S, Klötzler A, Bertram H, Denecke T, Neuhaus P, Seehofer D. Bilateral subtotal thyroidectomy versus hemithyroidectomy plus subtotal resection (Dunhill procedure) for benign goiter: long-term results of a prospective, randomized study. *World J Surg.* 2013 Jan;37(1):84-90.

