

We are IntechOpen, the world's leading publisher of Open Access books Built by scientists, for scientists

6,900

Open access books available

186,000

International authors and editors

200M

Downloads

Our authors are among the

154

Countries delivered to

TOP 1%

most cited scientists

12.2%

Contributors from top 500 universities



WEB OF SCIENCE™

Selection of our books indexed in the Book Citation Index
in Web of Science™ Core Collection (BKCI)

Interested in publishing with us?
Contact book.department@intechopen.com

Numbers displayed above are based on latest data collected.
For more information visit www.intechopen.com



Surgical Management of Hyperthyroidism

Z. Al Hilli, C. Cheung, E.W. McDermott and
R.S. Prichard

Additional information is available at the end of the chapter

<http://dx.doi.org/10.5772/57499>

1. Introduction

Hyperthyroidism is a syndrome characterised by the signs and symptoms of hyper-metabolism and excess sympathetic nervous system activity. It has an overall prevalence of 27 per 1000 women and 2.3 per 1000 men within the United Kingdom [1]. Hyperthyroidism occurs as a result of either the excess synthesis or secretion of thyroid hormones by the thyroid gland itself. It must be distinguished from thyrotoxicosis, in which excess thyroid hormone may come from other sources, such as excess thyroid hormone ingestion, struma ovarii and functional metastatic thyroid carcinoma[2,3].

Patients present with a variety of symptoms and clinical findings on physical examination. It is important for clinicians to remember that these may be more subtle in the elderly population who may present with fatigue or weakness, a condition known as apathetic hyperthyroidism, or with predominantly cardiovascular signs such as atrial fibrillation, ischaemic heart disease and congestive cardiac failure [4,5]. The routine use of serum thyrotropin (TSH) as a screening investigation may allow earlier identification and treatment of the disease [6,7]. Radiological imaging with iodine-123 uptake scanning and thyroid scintigraphy may aid in the identification of the underlying cause [6].

The management of hyperthyroidism is based on three treatment modalities, namely anti-thyroid medication, radioactive iodine ablation or surgery. Patient, physician and geographically preferences may dictate the choice of therapy. Given the overall healthcare costs of hyperthyroidism, surgical intervention performed with minimal morbidity in high volume centres may offer the highest chance of success with the lowest chance of recurrence [8].

The aim of this chapter is to discuss the role of surgical intervention in hyperthyroidism. Firstly, to examine the evidence supporting surgical intervention in the management of Graves' disease and that of toxic nodular goitres including toxic multi-nodular goitre and solitary toxic

nodule. Secondly, and perhaps more controversially, the evidence for the extent of surgical intervention in hyperthyroidism will be discussed focusing specifically on the evidence for total compared with subtotal thyroidectomy.

2. Surgical anatomy

The thyroid gland is derived from the median thyroid diverticulum at the floor of the pharynx. The thyroglossal duct extends from the foramen caecum at the base of the tongue to the isthmus and is derived from the stalk of the diverticulum, which is later obliterated, with the distal portion forming the pyramidal lobe of the thyroid. The ultimobranchial bodies that arise from the fourth pharyngeal pouch become related to the lateral aspect of the gland and constitute the para-follicular and C cells, which produce calcitonin [9,10,11].

The thyroid gland consists of two lobes connected by an isthmus that is situated antero-lateral to the trachea and cricothyroid muscle. The gland itself has a bi-lobed shape and weighs 15 – 25g often depending on age and sex. Superiorly, the pyramidal extension (lobe) of the gland may be found on the anterior surface of the cricothyroid. Laterally, the tubercles of Zuckerkandl, which arise from median anlage and ultimobranchial fusion, may form significant protrusions of thyroid tissue within the tracheo-esophageal groove. Inferior to the thyroid lie the thyrothymic rests. These occur in up to 50% of individuals and are classified according to their connection to the thyroid [12].

The blood supply to the thyroid is derived from two main arteries; the superior thyroid artery, which is a branch of the external carotid artery, and the inferior thyroid artery, which is a branch of the thyrocervical trunk that itself is a branch of the subclavian artery. The main venous drainage is through the middle thyroid vein directly into the internal jugular vein. Other venous drainage includes the paired superior thyroid veins and a plexus of veins draining the inferior poles of the gland. The lymphatic drainage is to local lymph nodes situated in the central neck compartment and subsequently to cervical nodes [10,11].

The recurrent laryngeal nerve (RLN) and the external branch of the superior laryngeal nerve (EBSLN) are closely related to the thyroid gland and can be vulnerable to damage during thyroid surgery. An intimate knowledge of their anatomy in the neck is crucial to safe thyroid surgery. The recurrent laryngeal nerve (RLN) originates from the vagus (X Cranial nerve) nerve. The right RLN branches from the vagus as it crosses the subclavian artery and loops around it, while the left nerve arises at the level of the arch of aorta and loops under it. Both nerves lie and ascend in the tracheo-oesophageal groove, where they pass deep to the postero-medial surface of the thyroid lobes [10,11]. The angle of the nerve relative to the trachea is usually more oblique on the right. The nerve subsequently enters the larynx by passing behind the inferior constrictors, supplying all the intrinsic muscles of the larynx except the cricothyroid and sensation to the mucosa below the vocal cords [10,11]. The right RLN may have a non-recurring course (0.3%) and derive directly from the vagus, approaching the cricothyroid directly without travelling in the tracheo-esophageal groove. This occurs as a consequence of a displaced right subclavian arterial takeoff from the aortic arch and may be identified pre-

operatively if cross-sectional imaging is performed. Both left and right RLNs may give multiple branches to the oesophagus and trachea. The RLN may bifurcate prior to insertion into the cricothyroid, with the majority of the motor fibres being carried in the anterior portion of the nerve [9,10,11].

The superior laryngeal nerve (SLN) also emanates from the vagus and travels deep and medial to the carotid arteries where it then divides into an internal and external branch above the superior horn of hyoid [all books Grays]. The internal branch travels in relation to the superior laryngeal vessels and supplies the mucosa to the level of the vocal cords. The external branch supplies the cricothyroid muscle and lies deep to superior thyroid artery [10], where it can be particularly vulnerable to damage. In an attempt to minimise trauma to the EBSLN numerous classifications have been proposed, the most widely adopted being that devised by Cernea et al [13,14]. Type 1 EBSLN is where the EBSLN crosses the superior thyroid artery (STA) greater than 1cm above the upper pole of the thyroid. It is the commonest (40 – 62%) type and suggests that the nerve may not be significantly at risk. In type 2a and b, the EBSLN crosses the artery less than 1 cm above the upper pole and may therefore be at risk during dissection [13,14]. Kierner et al proposed that these be further divided into type 3 EBSLN where the nerve crosses the STA under the cover of the thyroid gland and type 4 is where the EBSLN had descended dorsal to the artery and only crosses the branches of the STA immediately above the upper pole of the thyroid [14].

The paired inferior and superior parathyroid glands are derived from the third and fourth pharyngeal pouches respectively and are closely related to the thyroid in position. The majority of individuals (85%) will have four glands while approximately 13% will have five glands and an even smaller proportion will have greater than this. The superior gland is found in over 90% of cases within 1cm of the junction of the inferior thyroid artery and the recurrent laryngeal nerve on the posterior aspect of the middle third of the thyroid gland. The inferior parathyroid glands, in conjunction with the thymus, have a longer migration path and their location is therefore more variable. The majority will be found on the anterior or postero-lateral aspect of the thyroid lobe or within the thyrothymic tract and are typically symmetrical in location [9,10,11].

3. Hyperthyroidism

Hyperthyroidism, a disorder of the thyroid gland, arises as a result of either excess hormone synthesis or secretion [2,3]. It has a population prevalence of 2% for women and 0.2% for men [1]. It is common with the incidence of new cases in the UK per year among women being reported at 3 per 1000 [6]. The mean age of diagnosis is 48 years with an increasing incidence with age [6,15]. Grave's disease, being the most common cause of hyperthyroidism, accounts for 60-80% of all cases [16]. Other causes include hyperthyroidism resulting from a toxic nodular goitre (single or multiple nodule) and these constitute the remaining 5-15% of all causes. [16].

Hyperthyroidism must be distinguished from thyrotoxicosis, which is defined as the excess of circulating thyroid hormones in the bloodstream [17]. Causes for thyrotoxicosis vary and include excess thyroid hormone ingestion, struma ovarii and functional metastatic thyroid carcinoma [18]. These will not be discussed further in this chapter

4. Clinical features

Hyperthyroidism has a multi-system effect on the body, giving rise to a range of classic signs and symptoms which are caused by increased catabolism [19]. Patients present with nervousness, fatigue, palpitations, heat intolerance, polyphagia and weight loss [6,9]. It is important to note that the elderly may present with a different range of symptoms and exhibit more subtle signs [20]. Weight loss and anorexia are common symptoms in older patients and may be mistaken for the presence of a neoplastic process which can lead to over investigation [21].

As a result of the increased basal metabolic rate patients often present with a persisting tachycardia. This occurs characteristically during sleep and may be associated with palpitations [22]. In the elderly and in those with pre-morbid cardiac disease, cardiac arrhythmias may develop on this background [22]. Atrial fibrillation is the commonest arrhythmia and is present in up to 20% of patients [18]. Interestingly, up to 15% of new onset atrial fibrillation in the elderly population is due to hyperthyroidism [23]. This may be resistant to medical treatment and resolves only when the underlying hyperthyroidism itself is treated [24]. Cardiovascular mortality is increased in hypertoxic states primarily as a result of ischaemic heart disease and congestive heart failure [25,26].

Increasing dyspnoea may occur in hyperthyroid patients, limiting exercise tolerance. This is thought to be due to a reduction in respiratory muscle mass and strength with a corresponding reduction in the vital capacity [18]. Bone turnover is also increased in the thyrotoxic state due to the direct stimulation of osteoclasts and osteoblasts to increase bone resorption [27,28]. Low TSH levels, of themselves, have also been implicated in the dysregulation of bone turnover [29]. Longstanding thyrotoxicosis can lead to increase bone loss and subsequent osteoporosis. Thyrotoxic patients can be emotionally labile and restless. Other less common complaints include poor concentration and changes in personality[3]. Overt psychosis, although rare may occur [7].

5. Diagnosis

5.1. Biochemical

Serum thyrotropin (TSH) is the most commonly used screening test to diagnose hyperthyroidism with levels being low or undetectable [2]. TSH levels are measured using immunoradiometric and chemiluminescent methods which have a high sensitivity (100%) and specificity (99.1%) [30,31]. When an abnormally low TSH is detected, free Thyroxine (T4) and free Tri-

iodothyronine (T3) levels are measured to determine the degree of hyperthyroidism. Indirect assays measure the free T4 and T3 level while sensitive and specific radioimmunoassays are used to measure total T4 and T3 levels [7]. The presence of a low TSH with normal T4 and T3 level is defined as sub-clinical hyperthyroidism [32]. Atrial fibrillation, other cardiac arrhythmias and cardiovascular mortality are all associated with prolonged sub-clinical hyperthyroidism, especially in the elderly [33,34]. The identification of a normal T4 but a high free T3 is known as T3 Thyrotoxicosis and may be an early manifestation of Grave's disease [3,35].

The measurement of auto antibodies, thyroglobulin, thyroxine peroxidase (TPO) and TSH receptor (TSHR) antibodies, may help in elucidating the underlying aetiology [6]. More than 90% of patients with Graves' disease have increased levels of circulating TSHR antibodies and in the setting of thyrotoxicosis it can confirm the diagnosis [3]. Similarly, TPO antibodies are also present in approximately 75% of patients with Graves' disease [2].

5.2. Radiological imaging

Radionuclide scanning and radioactive iodine uptake assesses the activity within the thyroid gland and may be used as an adjunct to biochemical analysis to identify the underlying aetiology of hyperthyroidism. Lesions are classified into three main categories: hot, whereby there is hyper-accumulation of radiotracer; warm, where there is increased uptake with suppression of background thyroidal tissue; or cold where the thyroid nodule is non-functioning [36]. Warm and hot nodules represent an increase in thyroid tissue turnover and may therefore suggest a benign toxic cause (Figure 1). Cold nodules, on the other hand are concerning for malignancy and should proceed to an ultrasound and FNAC [36,37]. Typically in Graves' disease, thyroid tissue is diffusely hyper-active with increased radio-tracer throughout the gland. In toxic nodular goitres, the radioactive iodine is focally concentrated in the nodules with suppression of the background tissue giving patchy uptake [38].

Early radionuclide scans were performed using radioactive iodine. This had been subsequently replaced by technetium (Tc-99m) pertechnetate. This has been shown to mimic the behaviour and uptake of iodine within the thyroid gland but involves a much lower dose of radioactivity and is cheaper [39].

Thyroid ultrasound has a limited role in patients with hyperthyroidism. It has been recommended to assess thyroid nodules, palpable thyroid abnormalities, nodular goitres and lesions found incidentally by other imaging modalities [37]. However, in the presence of a low TSH and a discrete hot nodule fine needle aspiration cytology should be avoided. Suspicious nodules on ultrasound or cold nodules should be subjected to a FNAC to allow for a cytological diagnosis to be made pre-operatively [37,38].

Chest radiography, CT and MRI scans can help in surgical planning for patients with compressive or obstructive symptoms although it is rarely used. CT scanning may allow assessment of size and extent of the goitre, including the presence of a retro-sternal component but predominantly aids in pre-operative assessment of the airway (narrowing and displacement) and the need for an awake fiber-optic intubation (Figure 1). When undertaking cross-sectional

imaging, contrast should be avoided due to the high iodine content, which may acutely worsen or induce symptoms of hyperthyroidism [40].

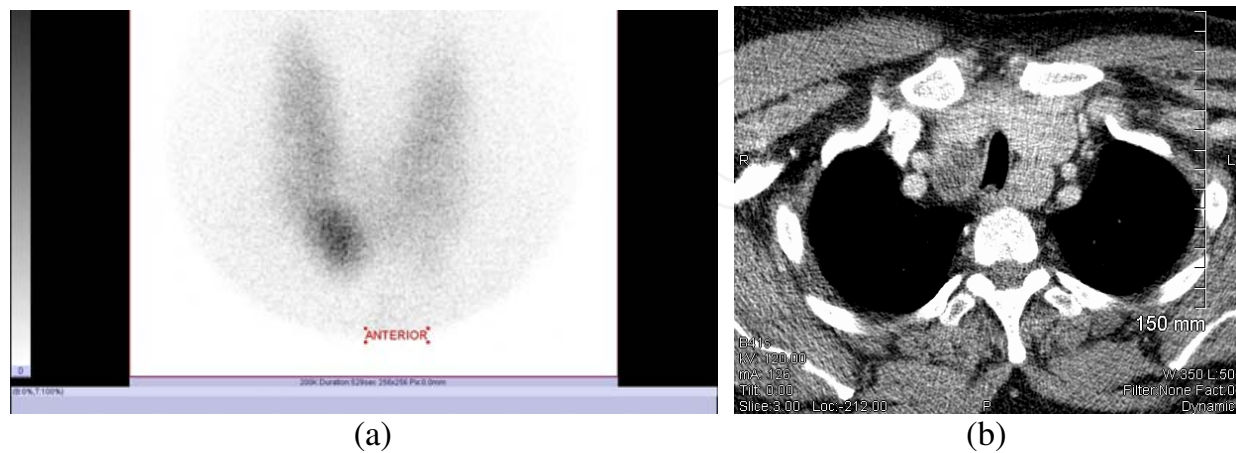


Figure 1. (a) Solitary nodule (b) Retrosternal extension of a large multinodular goitre

6. Aetiology of hyperthyroidism

6.1. Graves' disease

Graves' disease is an autoimmune disorder with a familial predisposition first described by Robert James Grave in 1835 [41]. Overall the incidence of the disease is approximately 100-200 cases per 100,000 per year with a marked female predominance and accounts for approximately 60–80% of all causes of hyperthyroidism [1,16]. A strong family history among affected patients suggests a genetic predisposition however the incidence in monozygotic twins is approximately 20% suggesting that penetrance is not 100% and other environmental causes may play a role in pathogenesis [3,42]. It is typically associated with other autoimmune conditions such as rheumatoid arthritis, SLE, Sjogrens, Type 1 Diabetes Mellitus and pernicious anaemia [43]. Graves' disease is also closely associated with myasthenia gravis occurring in 3-5% of patients [18].

Graves' disease classically consists of a triad of hyperthyroidism with diffuse goitre, ophthalmopathy and pretibial myxoedema [44]. Each of these may run an independent course. The clinical presentation includes signs and symptoms of thyrotoxicosis, a symmetrically enlarged non tender goitre often with a palpable thrill or audible bruit [5]. However, it may also present with a variable degree of extra-thyroidal manifestations such as ophthalmopathy, pretibial myxoedema and acropachy [6]. Ophthalmopathy, proptosis, extra-ocular muscle involvement and rarely optic nerve compression, are thought to arise as a result of an immune response to antigens within the retro-orbital tissues that are shared with the thyroid leading to oedema and glycosaminoglycan deposition and fibrosis of the retro-orbital tissues [45,46].

The diagnosis of Graves' disease is made by establishing the presence of hyperthyroidism, the presence of TSH auto-antibodies and diffuse increased symmetrical uptake on radio-iodine scanning [47].

Treatment options include anti-thyroid medication, radioactive iodine ablation or surgical intervention. The aim of treatment is to achieve a euthyroid state and in the presence of ophthalmopathy to ensure overall stability. The ultimate decision regarding optimal management is tailored to an individual patient.

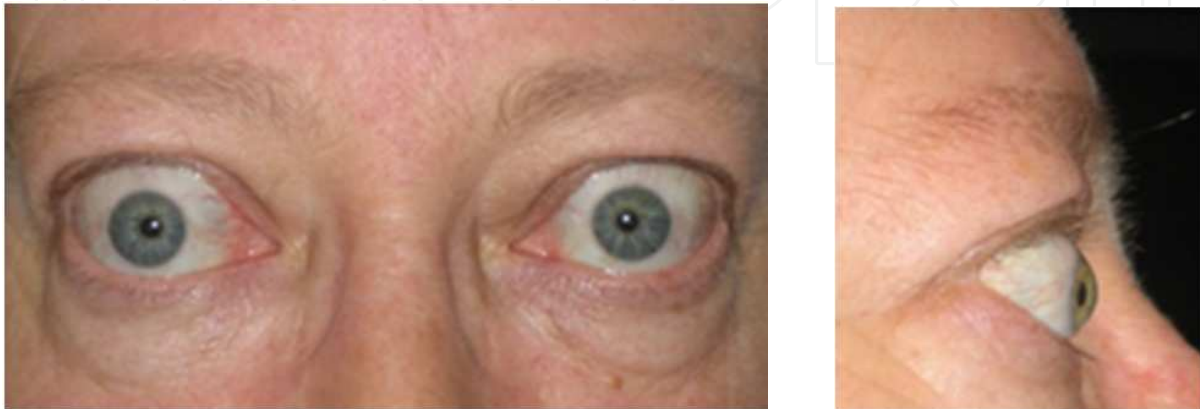

Figure 2. Graves ophthalmopathy

6.2. Toxic nodular goitre

Toxic nodular disease, resulting from either multiple or single adenomatous nodules was first described as a separate entity to Graves' disease in 1913 by Henry Plummer [48]. Toxic nodular goitre includes two distinct entities, toxic multi-nodular goitre and a solitary toxic nodule, also known as Plummer's Disease. Both are characterised by abnormal thyroid function independent of TSH regulation. Together, they account for the second commonest cause of hyperthyroidism but there are differences in their pathogenesis and treatment and therefore will be considered separately.

Toxic Multi-nodular Goitre

Toxic multinodular goitre is defined as a thyroid gland with two or more autonomously functioning nodules [49]. Its incidence ranges from 5% of all hyperthyroid cases in iodine replete areas to 50% in iodine deficient areas and typically presents in older females [19]. Many aetiological factors are involved in the pathogenesis of toxic multi-nodular goitre including the functional heterogeneity of the thyroid follicles, the effects of growth factors and goitrogens, the presence or absence of iodine and genetic abnormalities. Concurrent autoimmune diseases are uncommon [50].

Patients present with less severe symptoms of hyperthyroidism and the onset may be more insidious [51]. Typically they have compressive symptoms from an enlarging multi-nodular goitre with retro-sternal extension [3]. The diagnosis is confirmed with a combination of

biochemistry and radio-iodine scanning. Nuclear medicine scanning may show a heterogeneous gland with mixed areas of hyper and hypo-activity [3,32]. Thyroid auto-antibodies are negative. [32].

The treatment of multinodular goitres is aimed at eradication of all autonomously functioning thyroid tissue. Given the concurrent compressive symptoms surgery may provide the most definitive treatment. Recurrence of disease is more common with either medical anti-thyroid medication or radio-iodine ablation [6,32].

Solitary Toxic Nodule

A solitary toxic nodule is an autonomously hyper-functioning nodule present within an otherwise normal thyroid gland. Approximately 50% of solitary nodules are truly solitary, while typically it presents as part of a nodular gland constituting a dominant nodule [52]. The prevalence of palpable nodules in a population ages 30-59 years can be up to 4.2% [53].

Patients present with a neck lump, visible or palpable. Appropriate investigation of a solitary nodule is crucial as the risk of malignancy is higher than in the presence of a multi-nodular goitre [37]. The incidence of malignancy in truly solitary nodules is 5-15%, but this figure would increase for solid or cold nodules to more than 25% [37]. Surgery remains the treatment of choice for these patients although they may be observed if asymptomatic.

Treatment Options

The management of hyperthyroidism is based on three different treatment modalities, namely anti-thyroid medication, radioactive iodine ablation or surgery. Patient, physician and geographical preferences will dictate the choice of therapy. The overall aim of treatment is to provide symptom relief, achieve a euthyroid state and to prevent recurrence. Given the overall healthcare costs of hyperthyroidism, surgical intervention performed with minimal morbidity in high volume centres may offer the highest chance of success with the lowest chance of recurrence [8]. However, a prospective study by Topping et al examining such outcome measures as patient satisfaction, time to euthyroidism and rates of sick leave demonstrated equivalence between all three treatment modalities [54].

6.3. Anti thyroid drugs

Anti-thyroid medication is used to render patients euthyroid to either induce long-term remission or as preparation for definitive treatment with radioactive ablation or surgery [2]. The main thioamide agents used are Carbimazole, Methimazole and Propylthiouracil (PTU). By inhibiting thyroxine peroxidase and interfering with both the organification of iodide and the coupling of iodo-thyronines a reduction in hormone synthesis is achieved [6,55]. Initial doses of medication are usually high and a euthyroid state can be achieved after 8-12 weeks of treatment whereupon doses can be titrated downwards to a maintenance dose [2]. PTU is preferred in pregnancy as it is less likely to cross the placenta due to protein binding [56,57]. Treatment may be discontinued after one year if sustained remission is achieved with the patient being euthyroid and TSH-R antibodies undetectable [19]. Remission can be variable with reported relapse rates of between 50% to 60% [19]. Factors influencing relapse include

smoking, compliance with medication, the presence of a large goitres and the elevated TSH-R antibodies at end of treatment [58]. Side effects range from mild symptoms of urticaria, fever and rash to more serious neutropenia, hepatotoxicity and vasculitis [55,59,60]. Agranulocytosis occurs in approximately 0.1-0.5% of treated patients and the rate of development of hypothyroidism is 0.6% per annum [61,62].

6.4. Radio-iodine ablation

Radio-iodine (RAI) can be used as first line treatment or for patients who have either failed medical management or present with recurrent disease following a sub-total thyroidectomy. Within the USA RAI is the first line treatment for patients with Graves' disease [55]. Iodine-131 is taken up by the thyroid cells causing local apoptosis and subsequent fibrosis of the gland thereby reducing the overall functional thyroid mass [22]. RAI is most suitable for patients with a small goitre in the absence of ophthalmopathy. A wide variety of dosages (200–600MBq) can be used [22]. The dosage however depends on the size and activity of the gland, associated failure rates with low doses and the increased rate of hypothyroidism when higher doses are utilised [19,63]. Absolute contra-indications include pregnancy, breastfeeding and coexisting differentiated thyroid cancer [55]. RAI is usually avoided in patients with severe ophthalmopathy as in approximately 15% of patient symptoms may worsen following treatment [64,65]. It may be used cautiously in patients with stable eye disease in combination with high dose glucocorticoids. [65].

Anti-thyroid agents are given for four to six weeks prior to radio-ablation in an attempt to render patients euthyroid and thus prevent the development of a thyrotoxic crisis during initial treatment [2]. These are discontinued two to three days prior to treatment to ensure functional thyroid tissue which is required to take up iodine [2,66]. The majority of patients (75%) require only a single dose of radio-iodine [67]. The effects of the RAI are not immediate and continue for months following treatment. Symptomatic improvement can take up to two months. Immediate complications include thyroid gland tenderness [32]. Long-term complications include the development of hypothyroidism in approximately 60% of patients at 1 year, and therefore regular long-term surveillance is warranted with T4 replacement as necessary [68].

6.5. Surgery

Surgery provides high cure rates in hyperthyroidism with minimal morbidity in high volume centres. It gives almost immediate relief of the compressive symptoms of large goitres, achieves euthyroidism rapidly and consistently, and avoids the long term risks of radioactive iodine and anti-thyroid medications [69]. Surgical intervention is warranted where the disease has proved refractory to medical management, including both anti-thyroid medication and radioactive iodine. Other indications for surgery include large goitres with compressive symptoms, where RAI is contra-indicated including pregnancy (usually performed in the 2nd trimester) and severe ophthalmopathy, desire for pregnancy soon after treatment, suspicion or presence of underlying thyroid malignancy, for children and patient preference [5].

Historically thyroid surgery was rarely performed for indications other than cancer until the last quarter of the twentieth century [70]. The high peri-operative and post-operative morbidity and mortality made the procedure untenable and indeed in 1850 it was banned by the French Academy of Medicine [71]. However improvements in anti-sepsis, anaesthesia and the introduction of anti-thyroid medication to render patients euthyroid pre-operatively revolutionised thyroid surgery. It is now well established as an acceptable and efficacious form of treatment and the controversy focuses on the extent of intervention; sub-total versus total thyroidectomy.

Currently, total thyroidectomy is regarded as the surgical procedure of choice for Graves' disease, multi-nodular toxic and non toxic nodules [70,72-74]. A study by Efermidou et al reviewing 932 cases of total thyroidectomy for benign thyroid disease showed that surgery is safe and is associated with minimal morbidity. Patients achieved immediate and permanent cure with no risk of disease recurrent or repeated surgery [75]. This was supported by Ballentine et al who demonstrated in over 500 patients a postoperative rates of haemorrhage of 1.5%, a permanent RLN palsy of 0.4% and a permanent rate of hypocalcaemia of 3.4% [76]. There were no recurrences noted during their follow-up of 44 months (Ballentine). Another study by Pappalardo et al randomised 141 patients into receiving a total thyroidectomy or subtotal thyroidectomy and patients were followed up for a median of 14.5 months. The rate of goitre recurrence in the subtotal thyroidectomy group was higher at 14% [77].

Finally, a meta-analysis which included 1402 patients from 5 continents demonstrated higher relapse rates with anti-thyroid drugs than radioactive iodine (52.7% vs 15%) and with anti-thyroid drugs than surgery (52.7% vs 10%). In addition, examination of 31 cohort studies which included 5136 patients found an adverse effect rate of 13% in patients treated with anti-thyroid drugs [78].

It is now widely accepted that high surgical volume in specialised units provides better patient outcome. A systematic review published in the British Journal of Surgery in 2007 examined 1075 studies and found that high volume surgeons had better outcomes in 75% of the studies and that specialised surgeons had significantly better outcomes than general surgeons in 91% of the studies [79]. The association between volume and outcome has also been demonstrated in thyroid surgery. Boudourakis et al performed a cross sectional analysis of a number of surgeries deemed to have demonstrated a volume-outcome relationship. There was a significant increase in number of procedures performed by high volume surgeons during the study period (23% for thyroidectomies). Unadjusted mortality and length of stay was significantly lower for high-volume surgeons compared with low-volume surgeons [80]. In a study by Pieracci et al, substernal thyroidectomy was compared with cervical thyroidectomy, with the main aim of assessing outcomes (all volume type hospitals were included). Increasing hospital volume predicted a decreased likelihood of overall complications, post-operative bleeding, blood transfusion, respiratory failure, mortality and length of stay [81].

7. Extent of surgery

7.1. Graves

Historically, a subtotal thyroidectomy was the procedure of choice in Graves' disease, minimizing the complications of surgery with potential cure of the disease. However, a randomized trial comparing anti-thyroid drugs, radioiodine treatment, and surgery in Graves' disease found all are equally effective in normalizing serum thyroid hormone concentrations within six weeks and over 95% of the patients were satisfied with their therapy [54].

The type of surgery in Graves' disease remains controversial. A total thyroidectomy ensures complete cure of symptoms but is obviously associated with surgical hypothyroidism and the need for lifelong thyroxine treatment. Conversely, subtotal thyroidectomy, given that a proportion of thyroid tissue is left in-situ is associated with a higher likelihood of recurrence and may still be associated with hypothyroidism. In a randomized trial of subtotal versus total thyroidectomy for Graves' disease involving 191 patients followed over five years, recurrent hyperthyroidism occurred in 4.7% of patients after subtotal versus 0% after total thyroidectomy, while transient hypoparathyroidism was seen in 6.8% and 12.6% respectively, and permanent hypoparathyroidism in 0% and 0.5% respectively confirming the advantages of total thyroidectomy without adversely affecting morbidity [82]. A meta-analysis published by Palit et al demonstrated in 35 studies with over 7241 patients that the rates of RLN injury and permanent hypo-parathyroidism were similar between subtotal and total thyroidectomy. More importantly they also demonstrated an 8% recurrence risk in those patients who had a subtotal thyroidectomy versus none in the total thyroidectomy group [83]. A further randomised trial published in the same year added weight to the call for total thyroidectomy as it failed to demonstrate a significant difference in the complication rates between a total or subtotal thyroidectomy [84]. Therefore total thyroidectomy should be considered the gold standard surgical intervention in Graves' disease.

7.2. Toxic multinodular goitre

Surgical resection remains the treatment of choice especially in the presence of a large goitre and compressive symptoms where surgery gives prompt relief [85]. The extent of surgical intervention and the comparative results of performing a near total or total thyroidectomy have been topical in the last decade. Attempts to perform more minimal surgery have been proposed to minimise the complications, such as RLN damage and permanent hypoparathyroidism, of thyroid surgery but are typically associated with higher rates of recurrence and an increased requirement for re-operative surgery. Stenmuller et al showed that a lobectomy plus a contralateral subtotal resection (known as the Dunhill procedure) and bilateral subtotal resection resulted in a low overall incidence of permanent hypoparathyroidism and RLN injury [86]. Rayes et al performed a prospective randomised study on 200 patients and concluded both can be performed with similar complication rates [87]. Remnant size was found to determine recurrence rates. Barczynski et al compared total thyroidectomy, Dunhill procedure and bilateral subtotal resection in 570 patients. Recurrence rates were 0.5% 4.7% and 11.6% respectively with recurrence highest in bilateral subtotal resection. However this

study also shows that although recurrence rates differ, reoperation rates for these recurrences are comparable showing that not all of these recurrences may be clinically significant and require further surgery [88]. Several other papers have also supported the role for total thyroidectomy for multinodular goitre showing that it completely eradicates the disease process, lowers the local recurrence rate, allows for avoiding the substantial risk of reoperative surgery, and involves only a minimal risk of morbidity [89,90-91].

7.3. Toxic solitary nodule

For patients with a solitary toxic adenoma without evidence of nodules in the contralateral lobe, a thyroid lobectomy is adequate. For patients with toxic adenoma and a coexisting nonfunctioning nodule in the contralateral lobe, total thyroidectomy may be warranted especially if there is any suspicion regarding thyroid malignancy. The main advantages of surgery include immediate resolution of hyperthyroidism symptoms, relief from compressive symptoms, avoidance of radiation exposure to normal tissue and confirmation of diagnosis in rare cases of suspected carcinoma [40]. The reported incidence of hypothyroidism is low (14% with surgery compared with 22% with radioiodine treatment [40]).

8. Preparation for surgery

Historically the mortality and morbidity associated with thyroid surgery was extremely high, not only from intra-operative complications but from post-operative hormonal dysregulation [92,93]. Meticulous pre-operative preparation of hyperthyroid patients has reduced this to less than 1% in high volume centres [92,94].

8.1. Anti-thyroid drugs

The aim of preoperative preparation as previously discussed is to render patients as close as possible to being clinically and biochemically euthyroid [22]. Antithyroid drugs interfere with the incorporation of iodine into tyrosine residues and prevent the coupling of iodotyrosines into iodothyronines [55]. Anti thyroid agents such as Carbimazole and Propylthiouracil are prescribed to achieve a euthyroid state [93,95]. The last dose should be given the day prior to surgery [22].

8.2. Beta-blockers

Many manifestations of hyperthyroidism relate to the cardiovascular system and to the sensitisation of the B-adrenergic receptors to catecholamines in patients who are thyrotoxic. Pre-operative treatment with a beta-blocker such as propranolol controls adrenergic effects [93]. It has also been shown to reduce the peripheral conversion of T4 to T3 [96]. Beta-blockers are used in combination with antithyroid drugs and play an important role in pre-operative patient preparation [97]. It is crucial to note that this drug should not be omitted on the morning of surgery and must be continued for at least 5 days postoperatively [22]. Beta-blockers are contraindicated in asthmatics, where a cardio-selective B-blocker may be considered [3].

8.3. Iodine treatment

The use of iodines in the pre-operative management of Graves disease was first documented in 1923 and its introduction saw a significant reduction in the mortality associated with thyroid surgery [98]. Iodines are now routinely used in the peri-operative management of hyperthyroid patients [93]. It is prescribed in the form of oral Lugol's iodine (drops) at a dose of 24mg divided over three doses administered 7–10 days pre-operatively to reduce the vascularity of the gland [93]. It has been postulated that organic iodide such as Lugol's solution usage can decrease the vascularity of the thyroid gland pre-operatively by inhibiting vascular endothelial growth factor A expression in thyroid follicles [99]. A randomised control trial by Erbil et al using colour flow Doppler ultrasonography, immunohistochemical and western blot analysis to compare thyroid vascularity with or without preoperative Lugol's solution in 36 patients. It showed a decrease in rate of blood flow to thyroid, thyroid vascularity and intra-operative blood loss in the preoperative Lugol solution treatment group. They concluded that preoperative Lugol's treatment reduces intraoperative bleeding which in turn improves the safety profile of the procedure [100].

Large doses of iodine act by producing a transient remission of hormone synthesis by 'stunning' the thyroid gland an effect known as the Wolff-Chaikoff effect. It is a phenomenon where higher than normal doses of iodine inhibit organification of thyroid hormone resulting in a decrease in hormone synthesis and release [101]. Onset of action begins 24 hours post administration peaking at approximately 10 days [102]. This can be seen as an auto-regulatory system in dealing with supra-physiologic levels of iodine [93]. In normal euthyroid subjects thyroid synthesis normalises due to down-regulation of the sodium iodine symporter known as the escape phenomenon [103].

However, in hyperthyroid patients the escape phenomenon does not occur and Jod-Basedow phenomenon occurs instead [93]. The Jod Basedow effect occurs due to dysregulation of iodine in hyperthyroid patients where excess iodine stimulates more hormone production by acting as the substrate [104]. It can result in a temporary hyperthyroidism, worsening of existing hyperthyroidism or rarely a permanent rise in thyroid hormone [93]. Therefore iodines should be used cautiously and for a limited time period in conjunction with anti-thyroid medication in the pre-operative period.

9. Surgical intervention

9.1. Anaesthesia

The majority of thyroid surgery is performed under general anaesthetic without neuromuscular blockade using an endotracheal cuffed tube to allow for intra-operative neuromonitoring. Local anaesthetic is given pre-operatively along the incision to ensure minimal post-operative discomfort. In selective patients with small thyroid nodules and favourable anatomy local anaesthetic has been documented as being utilised. Local anesthetic techniques require the use of cervical block anesthesia. The disadvantage of this is risk of bilateral paralysis of the

recurrent laryngeal nerve resulting from blockade with the local anaesthetic, with consequent difficulty in breathing postoperatively [105].

9.2. Intra-operative nerve monitoring

The primary complication of thyroid surgery is damage to either the recurrent laryngeal nerve or the external branch of the superior laryngeal nerve. Routine visual identification of the RLN decreases the incidence of injury and is standard practice (Figure 3). However, a recent survey of members of the American Association of Endocrine Surgeons found that 63% of respondents do not use neuromonitoring, 14% of surgeons used it routinely and 23% were selective users [106]. Non-users were in practice longer, reported a lower case volume, were less familiar with the technology and had limited access to the equipment [106].

The main role for intra-operative monitoring is to identify the RLN nerve, to aid in safe dissection once it is identified and for prognostication of neural function postoperatively [107]. The two main components of monitoring are stimulation of the RLN and assessment of the vocal cord response to stimulation. Several techniques have been described and are in routine use. The most common method is the use of a laryngeal surface electrode which is applied to the surface of the endotracheal tube in a proximal location to the vocal cord [108,109]. An attached probe is used to deliver the low voltage electric current. During thyroid resection an auditory signal or visual EMG signal can be used to provide information about the presence and course of the RLN.

A systematic review of the literature demonstrated that neuromonitoring of the RLN during thyroid surgery reduced RLN injury compared with routine nerve identification [110]. Other studies comparing intra-operative nerve monitoring have demonstrated a benefit for its use although a statistically significant difference between the groups could not be identified [111, 112]. A randomized trial of 1000 patients showed a decrease in transient but not permanent RLN paresis compared to visualization alone [113]. In addition, there are studies which show low sensitivity and positive predictive value of intra-operative neuromonitoring for predicting nerve injury [114]. Despite this evidence, monitoring, when used appropriately, has been shown to be feasible, safe and reproducible and should be considered for all cases. It must be noted that neuromonitoring does not replace adequate intra-operative visualization and meticulous surgical technique.

10. Surgical procedures in hyperthyroidism

10.1. Dunhill and Holtz procedures

Hartely and Dunhill described the procedure of subtotal thyroidectomy where a total thyroid lobectomy is performed on one side and a small remnant is left in situ (weighing approximately 4 grams) on the contralateral side [5]. However it has been consistently difficult to assess the residual remnant thyroid size and it may vary between 2–12 gms. The surgery is performed through a collar incision placed halfway between the sternal notch and the thyroid cartilage.



Figure 3. Nerve stimulator used for intra-operative recurrent laryngeal nerve monitoring

As the thyroid gland is approached, the middle thyroid vein is identified and ligated. The entire lobe and isthmus are excised on the diseased side. On the contralateral side, the superior pole is freed by dividing the superior vessels and the remaining thyroid lobe is approached from a postero-lateral plane through the thyroid tissue leaving a posterior remnant. This keeps the dissection plane away from the parathyroid glands and the recurrent laryngeal nerve on this sub-total operative side [115].

The Enderlen Holtz procedure involves performing a subtotal bilateral thyroidectomy. The procedure is similar to the Dunhill procedure and involves mobilisation of the thyroid gland supero-laterally. In this case remnant tissue of 2 grams or more are left on both sides. Disadvantages of both these procedures, as previously discussed include the high risk of recurrence as well as an increased rate of complications (RLN damage and permanent hypoparathyroidism) associated with re-operative surgery [115].

10.2. Total thyroidectomy

The patient is positioned supine on the operating table in a slight reverse Trendelenburg position. A gel pad or sand bag is placed transversely under the shoulders and the neck is extended and placed in a head ring. This allows the thyroid gland to become more prominent and applies tension to the skin, platysma, and strap muscles aiding in dissection. In a total thyroidectomy complete excision of the gland, including the pyramidal lobe is performed [22,105].

A curved incision is made midway between the suprasternal notch and the thyroid cartilage. The incision is deepened through the skin, subcutaneous tissue and platysma. Skin flaps are then raised upwards to the thyroid notch and downwards to the suprasternal notch. The deep cervical fascia is then divided in the midline down and in-between the strap muscles to the plane of the thyroid gland. The strap muscles are then retracted laterally and mobilised off the

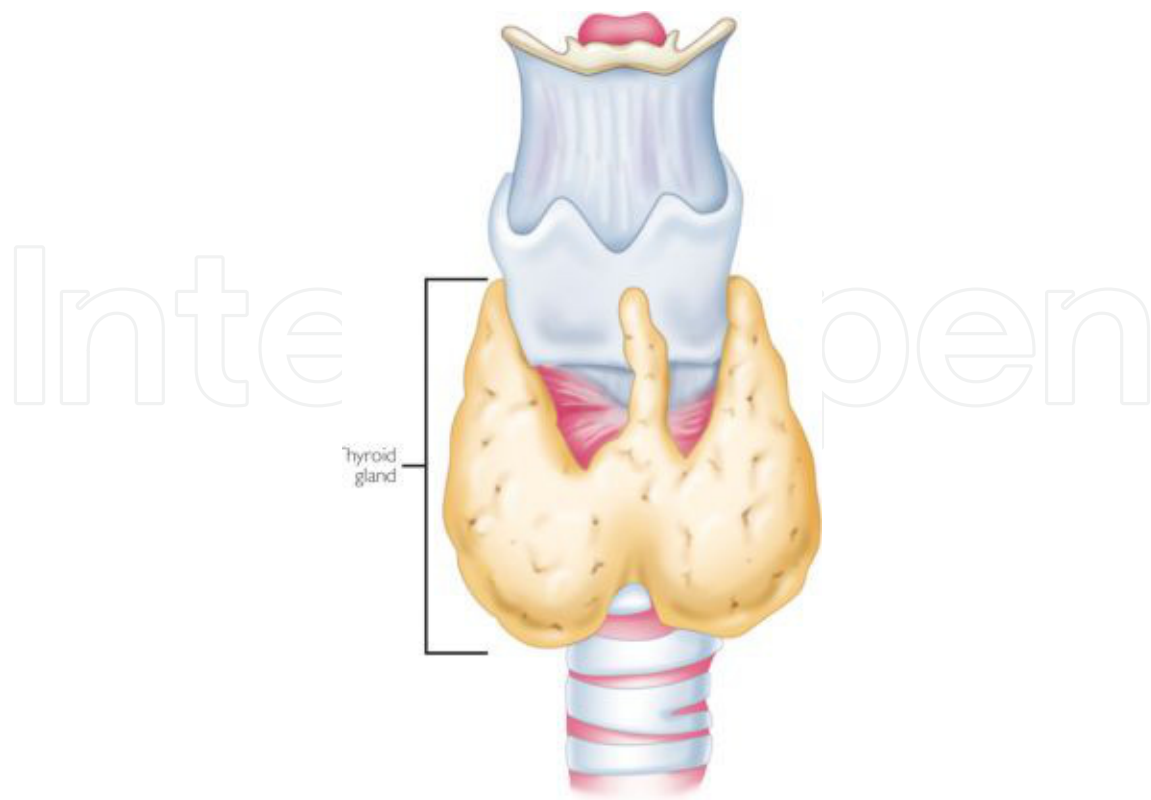


Figure 4. Thyroid gland and pyramidal lobe [116]

thyroid gland using an advanced surgical sealing instrument, such as the Ligasure vessel sealing device (Covidien) [22,105].

The middle thyroid vein is encountered laterally, and this drains directly into the internal jugular vein. This is ligated and divided. The plane between the medial pole of the upper lobe and the cricothyroid muscle is subsequently developed, ensuring close proximity to the thyroid in order to avoid trauma or injury to the external branch of the superior laryngeal nerve. The branches of the superior thyroid artery are then ligated and divided, allowing downward delivery of the upper pole. Capsular dissection is then performed and this involves commencing the lateral component of the dissection high on the surface of the thyroid gland, dividing only the tertiary branches of the inferior thyroid artery and progressing posteriorly. In this process, the vascular supply of the parathyroid glands is often well preserved [22,105,117].

The recurrent laryngeal nerve is identified in its course in the tracheo-esophageal groove. This is first identified and sought below the level of the inferior thyroid artery, where it passes obliquely upwards and forwards. The tubercle of Zuckerkandl serves as a useful landmark in the identification of the RLN. Situated on posterolateral aspect of the gland in the tracheo-esophageal groove in proximity of the cricothyroid membrane it is a constant landmark for RLN identification which is aided by further mobilisation of the thyroid. The nerve is followed upwards until it passes into the larynx under the inferior border of the inferior constrictor behind the inferior cornu of the thyroid cartilage. In cases where the right nerve is difficult to

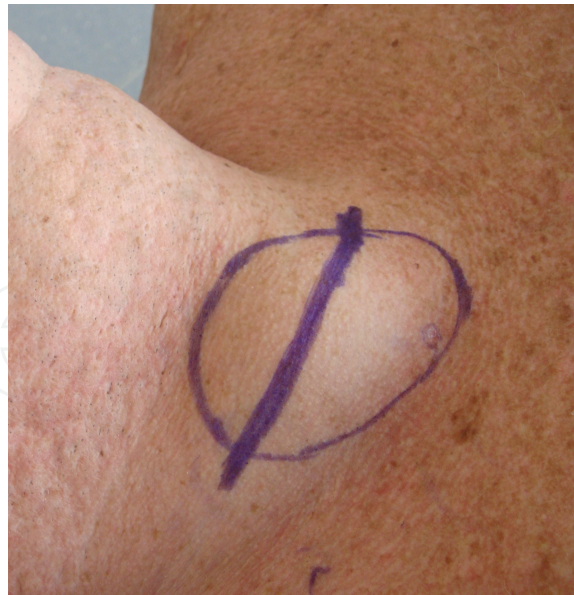

Figure 5. Marking of incision

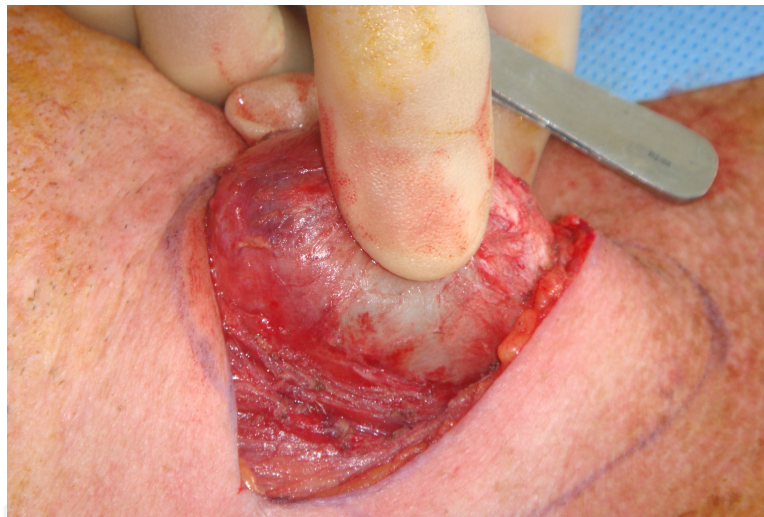


Figure 6. Mobilisation of the thyroid

identify one must consider an anomalous (non-recurrent) nerve, which is present in 1 percent of patients. A non-recurrent RLN passes behind the carotid sheath and curves medially, forwards and upwards and can be mistaken for the inferior thyroid artery. It is important to be careful with diathermy and newer advanced sealing devices as heat conduction may damage the RLN, the blood supply to the parathyroid's or to the delicate areas within the larynx [22,105,117].

The parathyroid glands must be identified in all cases. This is done by careful inspection of the common locations and by utilising capsular dissection they can be peeled away from the thyroid gland itself. Care is taken not to damage the branches of the inferior thyroid artery which supply the parathyroid glands. If a parathyroid gland is accidentally excised or

devascularised inadvertently then it should be fragmented into small pieces and auto-transplanted immediately within the sternocleidomastoid muscle [22,105,117].

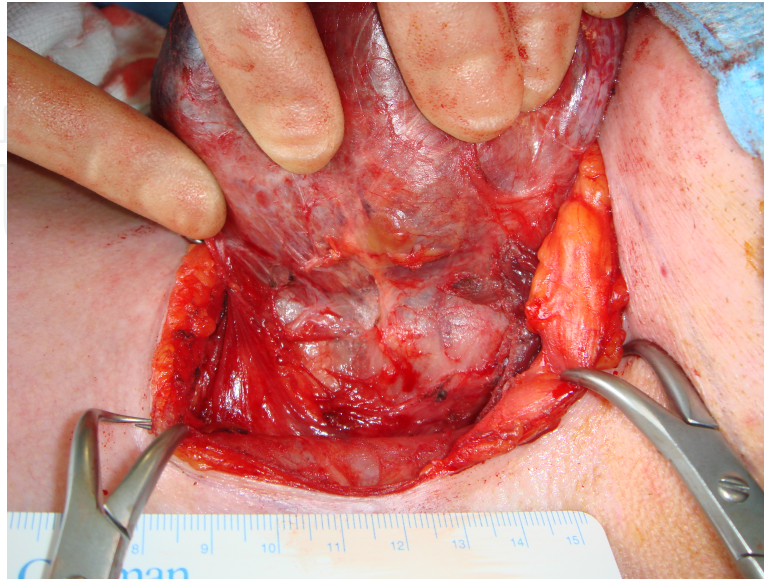


Figure 7. Postero-lateral aspect of the thyroid

The pretacheal and cervical fascia are closed using interrupted sutures. Routine drain placement after thyroid surgery is not necessary. A meta-analysis of 11 randomized clinical trials showed no significant difference in the incidence of hematoma or seroma between routine drainage and no drainage [118]. If the thyroid is very large with a significant retrosternal component or the dissection is extensive, a closed-suction drain can be placed to prevent a serous fluid collection [118]. This can be removed safely when the drain output is serous and decreasing in volume.

10.3. Thyroid lobectomy

Thyroid lobectomy is predominantly the treatment of choice in the management of solitary toxic nodules because it not only removes the stimulus of excess thyroid production, but it also allows definitive histological assessment of the nodule.

The details of the procedure, patient positing and exposure are similar to that of a total thyroidectomy, as described above. In a thyroid lobectomy, the isthmus is transected using a haemostatic device such as the harmonic scalpel or Ligasure [22,105,116].

10.4. Subtotal thyroidectomy

The thyroid gland is exposed in a similar manner to a total thyroidectomy. The middle thyroid vein is encountered upon retraction of the strap muscles and is ligated and divided. The superior poles of the thyroid are then ligated taking care to avoid the EBSLN [22,105,116]. The inferior thyroid artery is identified and ligated lateral to the recurrent laryngeal nerve. The

procedure then entails dividing across each lobe of the thyroid from the lateral edge towards the trachea, leaving intact a posterior capsule with the attached remnant of the thyroid. For ease of closure the thicker remnant of the gland is left laterally and incised more on the medial aspect. This allows the folding over of the remnant laterally to medially, allowing the capsular edges to be sutured together using a Vicryl suture. As a general guide the remnant strip is often recommended to be 3cm x 1cm on each side. This operation is rarely used in modern surgical practice [22,105,116].

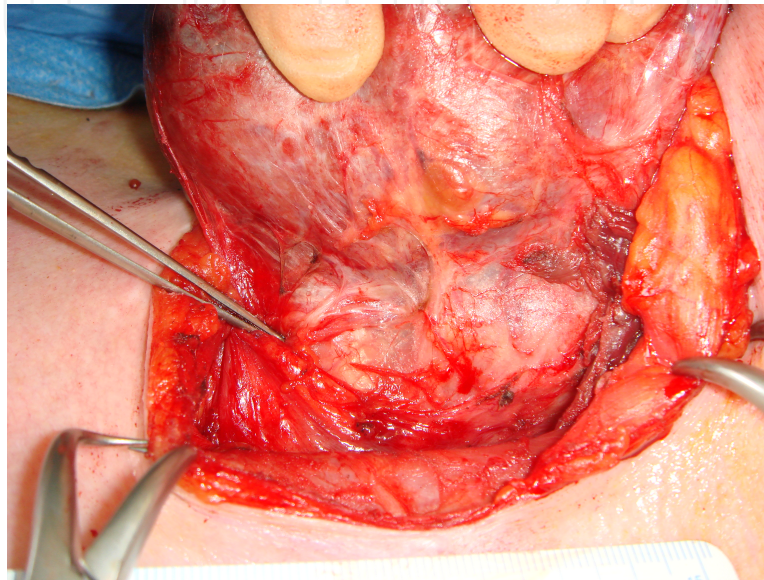


Figure 8. Identification of recurrent laryngeal nerve

10.5. Surgery in recurrent thyroid disease

Re-operative thyroid surgery is technically challenging due to the formation of adhesions and scar tissue, and is associated with increased rates of recurrent laryngeal nerve injury and hypoparathyroidism [119,120,121]. Operative intervention for recurrence accounts for anywhere between 5–12% of all thyroidectomies performed [122,123]. However, the last twenty years have seen a shift away from conservative primary operations such as bilateral subtotal thyroidectomy and this should begin to be mirrored by declining recurrence rates [124].

The risks associated with reoperation should be carefully examined and balanced with the options of medical management or observation [119,120,121]. The extent of the disease should be assessed in addition to the location and possible complications such as nerve injury and excision of the parathyroid glands [124].

The operation of choice in all cases of recurrent nodular goitre should be a completion total thyroidectomy. The surgical approach is dependent on the extent of the initial operation and the size and location of the recurrent goitre. Re-operation following a subtotal or total thyroidectomy is hazardous and requires a methodical and standardized operative approach [124]. The key is the initial identification of anatomical landmarks outside the original operative field.

The dissection must commence laterally by mobilization of the sternocleidomastoid muscle to expose the carotid sheath. The carotid sheath may however be displaced medially and lie abutting both fibrous tissue and the thyroid remnant. Dissection continues until the lateral aspect of the gland is encountered. It is important to ensure that the nerve is not encased within the strap muscles prior to their division. Identification of standard landmarks is vital. Therefore the esophagus posteriorly and the trachea anteriorly should be identified next. This helps to narrow down the location of the recurrent laryngeal nerve, which should be lying within the trachea-oesophageal groove. Protection of the recurrent laryngeal nerve is best achieved by identifying it in virgin territory. Dissection should thus begin low down in the trachea-oesophageal groove, if necessary as low as the thoracic inlet, where the nerve can be safely identified in an undisturbed, non-operated field. Once the nerve has been identified, its course is traced through to the insertion into the cricothyroid muscle. The recurrent laryngeal nerve should not be sought at the fibrosed upper pole, as the risk of subsequent damage is extremely high. Mobilization of the thyroid is by capsular dissection. Sub-sternal recurrent goitre may increase the difficulty of surgical management and may be associated with a significantly higher rate of recurrent laryngeal nerve damage as it exits the thoracic inlet. A sternal split is rarely required. However, where there is excessive local bleeding or where removal of the gland is prevented by excessive fibrosis a partial sternal split provides adequate access [124].

10.6. Retrosternal thyroid extension

Given the embryological descent of the thyroid most extension of the thyroid gland is into the anterior and superior mediastinum. In the majority of cases the retrosternal component of the thyroid gland can be delivered into the neck with gentle traction upwards given the position the patient on the operation table [105]. In the small number of cases where the thyroid extends behind the trachea and enters into the posterior mediastinum, there is a risk of injury to major vessels and structures within the chest and a median sternotomy in conjunction with the cardio-thoracic surgeons should be performed [105].

10.7. Postoperative care

Post operative patients are monitored closely for complications. Typically, thyroid surgery is performed as a 23 hour surgical stay but increasingly in smaller cases there has been a move to day case surgery. Patients are observed for exclusion of a post-operative haematoma and subsequent airway compromise as well as for signs and symptoms of hypocalcemia in the immediate post-operative period. Close monitoring of calcium levels especially in symptomatic patients is crucial. Clinical tests of hypocalcaemic, including Chvostek's sign (tapping of facial nerve causing facial muscles to twitch) and Trousseau's sign (finger and wrist spasm on insufflation of a sphygmomanometer cuff around arm), may be present [125]. Studies have shown that oral calcium and vitamin D supplementation has been found to decrease the development of hypocalcaemic symptoms. However, a randomized trial that included 143 patients undergoing a total thyroidectomy, showed that patients with a PTH level >10 pg/mL obtained on post-operative day one could be safely discharged without routine calcium supplementation [126]. Calcium levels need to be followed up as hypercalcaemia may occur.

In addition short term courses are usually sufficient and supplementation may be discontinued once levels are normalised.

It is recommended that thyroid hormone is started on the first post-operative day in patients who have undergone a total thyroidectomy. Serum TSH and free T4 are tested 6 weeks postoperatively and the dose of oral thyroxine adjusted accordingly. Anti-thyroid medications are stopped following surgery and beta-blockers may be weaned.

11. Complications of surgery

The most important complications of thyroid surgery include recurrent laryngeal nerve injury, external superior laryngeal nerve injury, hypoparathyroidism, laryngeal oedema, bleeding, hypothyroidism/hyperthyroidism, wound infection and keloid scarring. Morbidity from thyroid surgery is minimised with meticulous anatomical dissection and operating in a bloodless field.

11.1. Airway obstruction

This complication, although rare, remains life-threatening. This can be due to sub-glottic and laryngeal oedema caused by venous and lymphatic obstruction, post-operative haematoma formation or bilateral recurrent laryngeal nerve damage. The identification of early signs of airway obstruction are crucial. It is recognised by a distressed patient and the presence of increasing stridor. Immediate suture removal and exploration of the wound is warranted. If no haematoma is demonstrated then one may proceed with conservative treatment with humidified oxygen and the administration of intravenous glucocorticoids. Anaesthetic input is recommended as intubation may be necessary to secure the patient's airway [22].

11.2. Haemorrhage

Haemostasis is paramount in thyroid surgery. Bleeding from the thyroid arteries and veins or the thyroid remnant can lead to the development of a haematoma deep to the strap muscles. A haematoma requires immediate decompression by opening all the layers of the wound and return to the operating room to control the underlying bleeding. The airway must be secured and sometimes a definitive airway is required although intubation for 24 hours with use of glucocorticoids and subsequent trial of extubation may save the patient a tracheostomy [22].

11.3. Nerve damage

Recurrent laryngeal nerve injury is rare and has been reported to occur 0.3-3% of cases permanently [127]. The incidence is increased in recurrent thyroid surgery and total thyroidectomy compared with thyroid lobectomy. The nerve can be typically injured or divided during ligation of the inferior thyroid artery or as it enters the larynx at the ligament of Berry. Mobilisation of large goitres can also stretch the nerve and make it more vulnerable to damage [10]. Paresis or partial damage of RLN, which is more common than complete transection,

results in the vocal cord on the affected side adopting a midline adducted position [10]. Transient paresis of the RLN can occur with rates of 1.8% at one month and 0.5% at 3 months for first time operations suggesting improvement with time [22]. Symptoms of unilateral RLN damage include hoarseness, inability to speak loudly, fatigable of the voice and an increased risk of aspiration [128]. In bilateral RLN damage both cords adopt a midline position and symptoms include total loss of voice, stridor and airway compromise requiring tracheostomy [10]. Measures to reduce RLN injury include pre-operative laryngoscopy to assess vocal cord function, direct identification of RLN and use of vocal cord stimulator intra-operatively.

The external branch of the superior laryngeal nerves lies close to the superior thyroid artery and can be damaged as the vessels are ligated and divided. Damage to the SLN causes the inability of the cricothyroid to tighten the vocal cords resulting in a weakness in phonation and a change in pitch of the voice [10]. These findings are more subtle than damage to the RLN and may be overlooked unless patients are specifically asked regarding symptoms [10]. Measures to avoid SLN injury include individually ligating the arterial branches close to the thyroid gland and identifying the nerve where possible [22].

11.4. Hyperthyroidism / Hypothyroidism

Hypothyroidism occurs with total thyroidectomy. In thyroid lobectomy, the incidence of hypothyroidism can be as high as 50% although the rate quoted is predominantly less than this, typically 20% [129]. Post-operative monitoring and follow-up of thyroid function is therefore needed. Hyperthyroidism, on the other hand, represents failure of the operation or the presence of thyroid remnants left in situ at the time of the operation. This occurs in around 5% of patients. The three common sites of embryological recurrence or persistence of nodular goitre are within the pyramidal lobe, within thyroid rests in the thyrothymic tract or within posterior remnants associated with the tubercle of Zuckerkandl (Figure 9).

11.5. Parathyroid insufficiency and hypocalcaemia

Inadvertent damage or removal of a parathyroid gland can result in either temporary or permanent hypoparathyroidism post operatively. Careful identification of the parathyroid glands and their preservation are crucial in order to avoid this complication as discussed above. A study by Thomusch et al demonstrated transient hypoparathyroidism in 7.3% of patients and permanent parathyroid dysfunction in 1.5% of patients [130]. Ionised calcium and PTH levels should be measured immediately postoperatively, before discharge and at outpatient review. Thomusch et al demonstrated a correlation between long term hypoparathyroidism and the extent of initial surgery [130]. Further work within this group demonstrated other significant factors for the development of hypoparathyroidism which included patient gender, hospital operative volume, and Graves' disease [131].

The symptomatic outcome of hypoparathyroidism is either temporary or permanent hypocalcaemia [132]. Symptoms of hypocalcaemia include paresthesia (especially circumorally and in digits), cramps, carpal pedal spasm, tetany and convulsions. Treatment is with calcium supplementation orally or intravenously depending on degree of hypocalcaemia and the

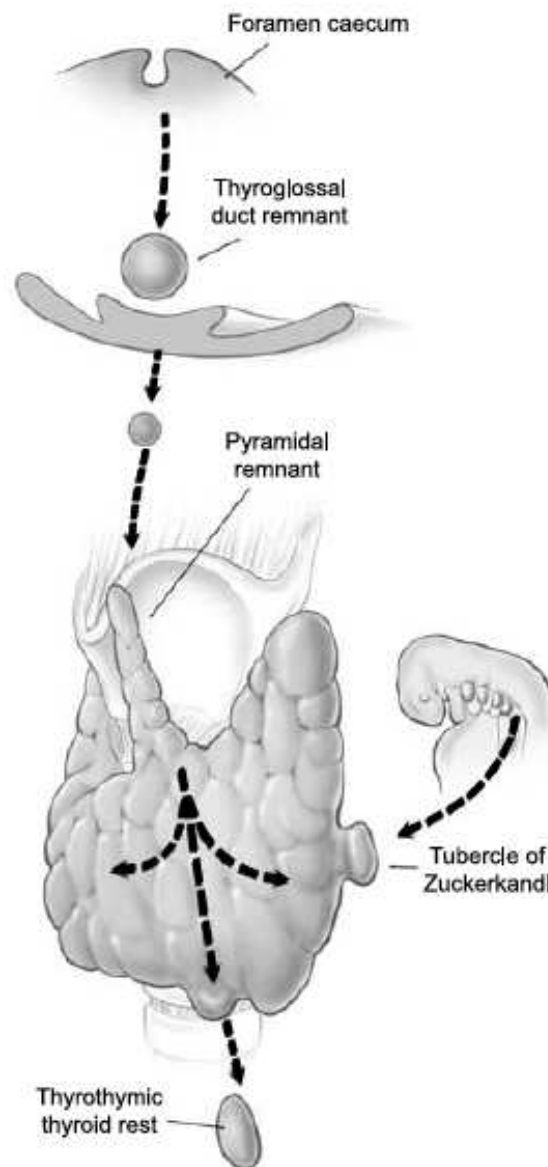


Figure 9. Embryological development of the thyroid gland [118]

presence of symptoms. Oral Vitamin D replacement can also be required. If calcium levels fail to increase the serum magnesium should be assessed and replaced as required [132].

Surgeons should be aware of the possibility of thyrotoxic patients developing Hungry bone syndrome post-operatively. As previously mentioned the presence of hyperthyroidism increases bone turnover [133,134] Therefore similar to its pathogenesis in parathyroid bone disease, removal of the excess thyroid hormone stimulation post thyroidectomy causes an imbalance in bone formation-resorption leading to an increase uptake of calcium, phosphate and magnesium in the osteoporotic bones [135,136] This leads to profound hypocalcemia, hypophosphatemia and hypomagnesemia. Treatment is with careful monitoring and electrolyte replacement [136].

11.6. Thyroid storm

This life-threatening condition is rarely seen post-operatively and is an acute exacerbation of thyrotoxicosis with an associated adrenergic response [137]. It accounts for less than 1–2% of all hospital admissions with hyperthyroidism but the mortality remains high at approximately 20–30% [138,139]. It typically occurs in patients who do not have an underlying diagnosis of hyperthyroidism. The crisis has an abrupt onset and is almost always evoked by a precipitating factor, such as infection, trauma, thyroidal surgery or radioactive iodine [3,16]. It is usually documented in patients undergoing thyroid surgery without adequate pre-operative preparation or where the diagnosis of thyrotoxicosis was not established [22]. Hormones released as a result of thyroid gland manipulation result in acute post-operative thyrotoxicosis [140]. Patients in crisis present with fever, abdominal pain, vomiting, diarrhoea, psychosis, altered mental state and coma. Signs include tachycardia, hypertension or hypotension, hyperpyrexia, atrial fibrillation and signs of congestive heart failure [141]. Treatment is aimed at reducing thyroid hormone secretion, supportive treatment and treatment of any underlying cause. It includes immediate fluid resuscitation, cooling with ice packs, supplemental oxygen, intravenous dextrose, diuretics and digoxin [22]. Specific treatments include intravenous beta blockers, propylthiouracil, potassium iodide and high dose steroids. Ensuring adequate and meticulous pre-operative preparation of patients should prevent this situation.

11.7. Tracheomalacia

Tracheomalacia represents a rare entity that is not completely understood. This condition is postulated to occur secondary to longstanding extrinsic tracheal compression with subsequent loss of tracheal cartilage rigidity, culminating in dynamic airway collapse in excess of 50% of diameter [142]. The typical manifestation of post-operative tracheomalacia is acute respiratory distress following extubation not explained by any other cause. This necessitates prompt re-intubation or a tracheostomy and the addition of high doses of glucocorticoids. A number of series failed to show cases of tracheomalacia [143,144], while a small number has been reported in others [145]. It has been postulated that this entity has been mistaken for unrecognised bilateral vocal cord paralysis [146]. Tracheomalacia is treated with intubation, tracheotomy, mesh repair of the posterior tracheal wall, trachelopexy and grafting.

12. Conclusion

Hyperthyroidism occurs as a result of an increase in thyroid hormone synthesis and secretion by the thyroid gland. This most commonly manifests as Graves' disease, multi-nodular goitre or a solitary toxic nodule. The management of hyperthyroidism is based on three treatment modalities, namely anti-thyroid medication, radioactive iodine ablation or surgery. Surgery increasingly plays an important role in the management of benign thyroid disease and has evolved into a cost-effective treatment with minimal associated morbidity and mortality. Total thyroidectomy is the surgery of choice in Graves' disease, while a total thyroidectomy or thyroid lobectomy are utilised in patients with toxic nodular goitres and this choice is dictated

by the disease site and extent. Although thyroid surgery can be associated with significant complications, in high volume operative centres surgery provides effective long-lasting resolution of hyperthyroidism and therefore should be considered an integral component of treatment rather than the last resort of clinicians

Author details

Z. Al Hilli, C. Cheung, E.W. McDermott and R.S. Prichard

Department of Endocrine Surgery, St Vincent's University Hospital, Dublin, Ireland

References

- [1] Turnbridge WM, Evered DC, Hall R, Appleton D, Brewis M, Clark F, et al. (2012) The spectrum of thyroid disease in a community: the Wickham survey. *Clin Endocrinol (Oxf)* 1977;7:481-93
- [2] Franklyn JA, Boelaert K. Thyrotoxicosis. *Lancet*. 2012 Mar 24;379(9821):1155-66
- [3] Cooper DS. Hyperthyroidism. *Lancet*. 2003 Aug 9;362(9382):459-68
- [4] Lahey FA. Nonactivated (apathetic) type of hyperthyroidism. *N Engl J Med* 1931; 204: 747-48.
- [5] Alsanea O, Clark OH. Treatment of Graves' disease: the advantages of surgery. *Endocrinol Metab Clin North Am*. 2000 Jun;29(2):321-37
- [6] Little JW. Thyroid disorders. Part I: hyperthyroidism. *Oral Surg Oral Med Oral Pathol Oral Radiol Endod*. 2006 Mar;101(3):276-84
- [7] Jameson JL, Weetman AP. Disorders of the thyroid gland: thyrotoxicosis. In: Kasper DL, Braunwald E, Fauci AS, Hauser SL, Longo DL, Jameson JL, et al., editors. *Harrison's principles of internal medicine*. 16th ed. New York: McGraw-Hill; 2005. p. 2113-2117, Chapter 320
- [8] Pieracci FM, Fahey TJ 3rd. Effect of hospital volume of thyroidectomies on outcomes following substernal thyroidectomy. *World J Surg*. 2008 May;32(5):740-6
- [9] Jameson JL, Weetman AP. Disorders of the thyroid gland: anatomy and development. In: Kasper DL, Braunwald E, Fauci AS, Hauser SL, Longo DL, Jameson JL, et al., editors. *Harrison's principles of internal medicine*. 16th ed. New York: McGraw-Hill; 2005. p. 2105, Chapter 320
- [10] Harold Ellis (2002) *The Thyroid Gland in Clinical Anatomy Tenth Edition* Blackwell p284-285

- [11] Drake RL, Vogl W, Mitchell AWM (2005) Head and Neck In Gray's Anatomy for medical students. Elsevier Churchill Livingstone p916-918
- [12] McMullen TPW, Delbridge LW Thyroid Embryology, Anatomy, and Physiology: A Review for the Surgeon In Hubbard J, Inabnet WB, Lo CY (editors), Endocrine Surgery, Principles and Practice, Springer London 2009 p3-16
- [13] Cernea CR, Ferraz AR, Nishio S, Dutra A Jr, Hojaij FC, dos Santos LR. Surgical anatomy of the external branch of the superior laryngeal nerve. Head Neck. 1992 Sep-Oct; 14(5):380-3
- [14] Kierner AC, Aigner M, Burian M. The external branch of the superior laryngeal nerve: its topographical anatomy as related to surgery of the neck. Arch Otolaryngol Head Neck Surg. 1998 Mar;124(3):301-3
- [15] Levy EG. Thyroid disease in the elderly. Med Clin North Am. 1991 Jan;75(1):151-67
- [16] Weetman AP. Graves' disease. N Engl J Med. 2000 Oct 26;343(17):1236-48
- [17] O'Hanlon KM, Baustian GH, Toth DW, In: Hyperthyroidism. contributors: First Consult [database on the internet]. St. Louis: Elsevier, Inc.; c2006 [cited 2006 Aug 10]. Available from: http://www.firstconsult.com/fc_home/members/?urn=com.firstconsult/1/101
- [18] Davies TF, Larsen PR. Thyrotoxicosis In Larsen PR, Kronenberg HM, Melmed D, Polonsky KS editors. Willams Textbook of Endocrinology 10th ed Philadelphia W.B. Saunders:2003 p374-414
- [19] Reid JR, Wheeler SF. Hyperthyroidism: diagnosis and treatment. Am Fam Physician. 2005 15;72(4):623-30
- [20] Knudson PB. Hyperthyroidism in adults: variable clinical presentations and approaches to diagnosis. J Am Board Fam Pract 1995;8:109-13
- [21] Ronnov-Jessen V, Kirkegaard C. Hyperthyroidism: a disease of old age? BMJ 1973;1: 41-43.
- [22] Krukowski ZH (2008) The Thyroid and Parathyroid glands. In: Williams N, Bulstrode CJK, O'Connell PR Bailey and Love's Short Practice of Surgery 25th edition. Hodder Arnold p772-800
- [23] Cobler JL, Williams ME, Greenland P. Thyrotoxicosis in institutionalized elderly patients with atrial fibrillation. Arch Intern Med 1984; 144: 1758-60
- [24] Shimizu T, Koide S, Noh JY, Sugino K, Ito K, Nakazawa H. Hyperthyroidism and the management of atrial fibrillation. Thyroid 2002; 12: 489-93
- [25] Franklyn JA, Sheppard MC, Maisonneuve P. Thyroid function and mortality in patients treated for hyperthyroidism. JAMA. 2005 Jul 6;294(1):71-80

- [26] Siu CW, Zhang XH, Yung C, Kung AW, Lau CP, Tse HF. Hemodynamic changes in hyperthyroidism-related pulmonary hypertension: a prospective echocardiographic study. *J Clin Endocrinol Metab.* 2007 May;92(5):1736-42
- [27] Barsal G, Taneli F, Atay A, Hekimsoy Z, Erciyas F. Serum osteocalcin levels in hyperthyroidism before and after antithyroid therapy. *Tohoku J Exp Med.* 2004 Jul;203(3):183-8
- [28] Britto JM, Fenton AJ, Holloway WR, Nicholson GC. Osteoblasts mediate thyroid hormone stimulation of osteoclastic bone resorption. *Endocrinology.* 1994 Jan;134(1):169-76
- [29] Galliford TM, Murphy E, Williams AJ, Bassett JH, Williams GR. Effects of thyroid status on bone metabolism: a primary role for thyroid stimulating hormone or thyroid hormone? *Minerva Endocrinol.* 2005 Dec;30(4):237-46
- [30] Wang, X, et.al. Development of a Highly Sensitive and Selective Microplate Chemiluminescence Enzyme Immunoassay for the Determination of Free Thyroxine in Human Serum. *Int. J. Biol. Sci.* 2007; 3(5):274-280
- [31] Villalta D. et.al. Analytical and diagnostic accuracy of "second generation" assays for thyrotropin receptor antibodies with radioactive and chemiluminescent tracers. *J Clin Pathol.* 2004; 57:378-382
- [32] Sharma M, Aronow WS, Patel L, Gandhi K, Desai H. Hyperthyroidism. *Med Sci Monit.* 2011 ;17(4): 85-91.
- [33] Auer J, Scheibner P, Mische T, Langsteger W, Eber O, Eber B. Subclinical hyperthyroidism as a risk factor for atrial fibrillation. *Am Heart J.* 2001 Nov;142(5):838-42.
- [34] Haentjens P, Van Meerhaeghe A, Poppe K, Velkeniers B. Subclinical thyroid dysfunction and mortality: an estimate of relative and absolute excess all-cause mortality based on time-to-event data from cohort studies. *Eur J Endocrinol.* 2008 Sep;159(3):329-41
- [35] Horace K. Ivy, MD; Heinz W. Wahner, MD; Colum A. Gorman, MB, BCh "Triiodothyronine (T3) Toxicosis" Its Role in Graves' Disease *Arch Intern Med.* 1971;128(4):529-534.
- [36] Grossman ET, Yousmen DM. Extramucosal Diseases of the Head and Neck In *Neuroradiology*. Second Edition: Mosby: 2003. p 697-750
- [37] American Thyroid Association (ATA) Guidelines Taskforce on Thyroid Nodules and Differentiated Thyroid Cancer, Cooper DS, Doherty GM, Haugen BR, Kloos RT, Lee SL, Mandel SJ, Mazzaferri EL, McIver B, Pacini F, Schlumberger M, Sherman SI, Steward DL, Tuttle RM. Revised American Thyroid Association management guidelines for patients with thyroid nodules and differentiated thyroid cancer. *Thyroid.* 2009 Nov;19(11):1167-214.

- [38] Randolph GW. Surgery of the Thyroid and Parathyroid Glands. Second Edition: Elsevier: 2013
- [39] Lee JC, Harris AM, Khafagi FA. Thyroid scans. Aust Fam Physician. 2012 Aug;41(8): 584-6.
- [40] McHenry CR, Lo CY. The Surgical Management of Hyperthyroidism. In Randolph GW. Surgery of the Thyroid and Parathyroid Glands. Second Edition: Elsevier: 2013p 85-94
- [41] Graves RJ. Clinical lectures delivered during the sessions 1834-5 and 1836-7. In: Dunglison's American Medical Library. Philadelphia: Adam Waldie; 1838. p.134-6.
- [42] Brand OJ, Gough SC. Genetics of thyroid autoimmunity and the role of the TSHR. Mol Cell Endocrinol. 2010 Jun 30;322(1-2):135-43
- [43] Boelaert K, Newby PR, Simmonds MJ, Holder RL, Carr-Smith JD, Heward JM, Manji N, Allahabadia A, Armitage M, Chatterjee KV, Lazarus JH, Pearce SH, Vaidya B, Gough SC, Franklyn JA. Prevalence and relative risk of other autoimmune diseases in subjects with autoimmune thyroid disease. Am J Med. 2010 Feb;123(2):183.e1-9
- [44] Maitra A, Abbas AK. Thyroid Gland In:Robbin's and Cotran Pathologic Basis of Disease, Kumar, Abbas, Fausto 7th edition. Elsevier Saunders p1164-1183
- [45] Burch HB, Wartofsky L. Graves' ophthalmopathy: current concepts regarding pathogenesis and management. Endocr Rev. 1993 Dec;14(6):747-93
- [46] Bartalena L, Pinchera A, Marcocci C. Management of Graves' ophthalmopathy: reality and perspectives. Endocr Rev. 2000 Apr;21(2):168-99
- [47] Schott M, Hermesen D, Broecker-Preuss M, Casati M, Mas JC, Eckstein A, Gassner D, Golla R, Graeber C, van Helden J, Inomata K, Jarausch J, Kratzsch J, Miyazaki N, Moreno MA, Murakami T, Roth HJ, Stock W, Noh JY, Scherbaum WA, Mann K. Clinical value of the first automated TSH receptor autoantibody assay for the diagnosis of Graves' disease (GD): an international multicentre trial. Clin Endocrinol (Oxf). 2009 Oct;71(4):566-73.
- [48] Hamburger JI. The autonomously functioning thyroid nodule: Goetsch's disease. Endocr Rev. 1987 Nov;8(4):439-47
- [49] Siegel RD, Lee SL. Toxic nodular goiter: toxic adenoma and toxic multinodular goiter. Endocrinol Metab Clin North Am 1998; 27:151-68
- [50] Baliga R R 250 cases in Clinical Medicine 4th edition. Saunders Elsevier Case 140 Multinodular Goitre: p524-527
- [51] Corvilain B, Dumont JF, Vassart G. Toxic adenoma and toxic multinodular goiter. In: Werner SC, Ingbar SH, Braverman LE, Utiger RD, eds. Werner & Ingbar's the thyroid: a fundamental and clinical text. 8th ed. Philadelphia: Lippincott Williams & Wilkins, 2000:564-72.

- [52] Hegedus L: Clinical practice. The thyroid nodule. *N Engl J Med* 2004, 351:1764-1771
- [53] Vander JB, Gaston EA, Dawber TR. The significance of non toxic thyroid nodules: final report of a 15 year study of the incidence of thyroid malignancy. *Ann Intern Med* 1968; 69: 537-540
- [54] Törring O, Tallstedt L, Wallin G, Lundell G, Ljunggren JG, Taube A, Sääf M, Hamberger B. Graves' hyperthyroidism: treatment with antithyroid drugs, surgery, or radioiodine--a prospective, randomized study. Thyroid Study Group. *J Clin Endocrinol Metab.* 1996 Aug;81(8):2986-93
- [55] Poshyachinda M Management of Hyperthyroidism in Therapeutic applications of radiopharmaceuticals, Proceedings of an international seminar held in Hyderabad, India, 18–22 January 1999 International Atomic Energy Agency 2001. P39-46 available online at http://www-pub.iaea.org/MTCD/publications/PDF/te_1228_prn.pdf
- [56] Wartofsky L, Treatment options for hyperthyroidism, *Hosp. Prac.* 31(1996 Sep 15) 69–83
- [57] Bender JM, Dworkin JM., "Therapy of hyperthyroidism", *Nuclear Medicine*, Vol II (Henkin, R., et al., Eds.), Mosby-Year Book, St Louis (1996) p 1549–1556.
- [58] Nedrebo BG, Holm PI, Uhlving S, Sorheim JI, Skeie S, Eide GE, Husebye ES, Lien EA, Aanderud S. Predictors of outcome and comparison of different drug regimens for the prevention of relapse in patients with Graves' disease. *Eur J Endocrinol.* 2002 Nov;147(5):583-9
- [59] Woeber KA. Methimazole-induced hepatotoxicity. *Endocr Pract.* 2002 May-Jun;8(3): 222-
- [60] Noh JY, Asari T, Hamada N, Makino F, Ishikawa N, Abe Y, Ito K, Ito K. Frequency of appearance of myeloperoxidase-antineutrophil cytoplasmic antibody (MPO-ANCA) in Graves' disease patients treated with propylthiouracil and the relationship between MPO-ANCA and clinical manifestations. *Clin Endocrinol (Oxf).* 2001 May; 54(5):651-4
- [61] Cooper DS. Antithyroid drugs. *N Engl J Med.* 2005 Mar 3;352(9):905-17
- [62] Lamberg BA, Salmi J, Wägar G, Mäkinen T. Spontaneous hypothyroidism after antithyroid treatment of hyperthyroid Graves' disease. *J Endocrinol Invest.* 1981 Oct-Dec;4(4):399-402
- [63] Harper MB, Mayeaux EJ Jr. Thyroid disease. In: Taylor RB. *Family medicine: principles and practice.* 6th ed. New York: Springer, 2003:1042-52
- [64] Ginsberg J. Diagnosis and management of Graves' disease. *CMAJ.* 2003 Mar 4;168(5): 575-85
- [65] Bartalena L, Marcocci C, Bogazzi F, Manetti L, Tanda ML, Dell'Unto E, Bruno-Bossio G, Nardi M, Bartolomei MP, Lepri A, Rossi G, Martino E, Pinchera A. Relation be-

tween therapy for hyperthyroidism and the course of Graves' ophthalmopathy. *N Engl J Med.* 1998 Jan 8;338(2):73-8.

- [66] Bonnema SJ, Bennedbaek FN, Vejse A, Marving J, Hegedüs L. Continuous methimazole therapy and its effect on the cure rate of hyperthyroidism using radioactive iodine: an evaluation by a randomized trial. *J Clin Endocrinol Metab.* 2006 Aug;91(8):2946-51
- [67] Poshyahinda M, Boonvisut S, Buacum V, Onthum Y. "Analysis of I-131 treatment for Graves' disease with long term follow-up", the Third Asia and Oceania Congress of Nuclear Medicine (Abstract), Seoul (1984) 112
- [68] Kendall-Taylor P, Keir MJ, Ross WM. Ablative radioiodine therapy for hyperthyroidism: long term follow up study. *Br Med J (Clin Res Ed).* 1984 Aug 11;289(6441):361-3
- [69] Boger MS, Perrier ND. Advantages and disadvantages of surgical therapy and optimal extent of thyroidectomy for the treatment of hyperthyroidism. *Surg Clin North Am.* 2004 Jun;84(3):849-74
- [70] Gough IR, Wilkinson D. Total thyroidectomy for management of thyroid disease. *World J Surg* 2000; 24:962-965
- [71] Bliss R, Gauger PG, Delbridge L. Surgeon's approach to the thyroid gland: Surgical anatomy and the importance of technique. *World J S* 2000; 24: 891-897
- [72] Bron LP, O'Brien CJ. Total thyroidectomy for clinically benign disease of the thyroid gland. *Br J Surg* 2004;91:569-574
- [73] Friguglietti CU, Lin CS, Kulesar MA. Total thyroidectomy for benign thyroid disease. *Laryngoscopy* 2003; 113: 1820-1826
- [74] Rios A, Rodriguez JM, Balsalbore MD et al. Results of surgery for toxic multinodular goiter. *Surg Today* 2005;35:901-906
- [75] Efremidou EI, Papageorgiou MS, Liratzopoulos N, Manolas KJ. The efficacy and safety of total thyroidectomy in the management of benign thyroid disease: a review of 932 cases. *Can J Surg.* 2009 Feb;52(1):39-44
- [76] Ballentone R, Lombardi CO, BOssola M, Boscherini M, De Crea C, Alesina P, Traini E, Princi P, Raffaelli M. Total thyroidectomy for the management for benign thyroid disease: review of 526 cases. *World J Surgery* 2002; 26(12): 1468-1471
- [77] Pappalardo G, Guadalaxara A, Frattaroli FM, Illomei G, Falaschi P. Total compared with subtotal thyroidectomy in benign nodular disease: personal series and review of published reports. *Eur J Surg.* 1998 Jul;164(7):501-6
- [78] Sundaresh V, Brito JP, Wang Z, Prokop LJ, Stan MN, Murad MH, Bahn RS. Comparative Effectiveness of Therapies for Graves' Hyperthyroidism: A Systematic Review and Network Meta-analysis. *J Clin Endocrinol Metab.* 2013 Jul 3

- [79] Coudhury MM, Dagash H, Pierro A. A systematic review of the impact of volume of surgery and specialization on patient outcome. *Br J Surg* 2007; 94(2): 145-161
- [80] Boudourakis LD, Want TS, Roman SA, Desei R, Sosa JA. Evolution of the surgeon-volume, patient-outcome relationship. *Ann Surg* 2009; 250(1): 159-165
- [81] Pieracci FM, Fahey TJ 3rd. Effect of hospital volume of thyroidectomies on outcomes following substernal thyroidectomy. *World J Surg* 2008; 32(5): 740-746
- [82] Barczyński M, Konturek A, Hubalewska-Dydejczyk A, Gołkowski F, Nowak W. Randomized clinical trial of bilateral subtotal thyroidectomy versus total thyroidectomy for Graves' disease with a 5-year follow-up. *Br J Surg*. 2012 Apr;99(4):515-22
- [83] Palit TK, Miller CC 3rd, Miltenburg DM. The efficacy of thyroidectomy for Graves' disease: A meta-analysis. *J Surg Res*. 2000 May 15;90(2):161-5
- [84] Witte J, Goretzki PE, Dotzenrath C, Simon D, Felis P, Neubauer M, Röher HD. Surgery for Graves' disease: total versus subtotal thyroidectomy-results of a prospective randomized trial. *World J Surg*. 2000 Nov;24(11):1303-11
- [85] Erickson D, Gharib H, Li H, van Heerden JA. Treatment of patients with toxic multinodular goiter. *Thyroid* 1998; 8: 277-82
- [86] Steinmüller T, Ulrich F, Rayes N, Lang M, Seehofer D, Tullius SG, Jonas S, Neuhaus P. Surgical procedures and risk factors in therapy of benign multinodular goiter. A statistical comparison of the incidence of complications. *Chirurg*. 2001 Dec;72(12): 1453-7
- [87] Rayes N, Steinmüller T, Schröder S, Klötzler A, Bertram H, Denecke T, Neuhaus P, Seehofer D. Bilateral subtotal thyroidectomy versus hemithyroidectomy plus subtotal resection (Dunhill procedure) for benign goiter: long-term results of a prospective, randomized study. *World J Surg*. 2013 Jan;37(1):84-90
- [88] Barczynski M, Konturek A, Hubalewski-Dydejczyk A et al (2010) Five-year follow up of a randomized clinical trial of total thyroidectomy versus Dunhill operation versus bilateral subtotal thyroidectomy for multinodular nontoxic goiter. *World J Surg* 34:1203-1213
- [89] Wheeler MH (1998) Total thyroidectomy for benign thyroid disease. *Lancet* 351:1526-1527
- [90] Agarwal G, Aggarwal V (2008) Is total thyroidectomy the surgical procedure of choice for benign multinodular goiter? An evidence-based review. *World J Surg* 32:1313-1324
- [91] Delbridge L (2008) Symposium on evidence-based endocrine surgery (2): benign thyroid disease. *World J Surg* 32:1235-1236
- [92] Mayo CH, Mayo CW. Pre-iodine and post-iodine days: a review of 37,228 cases of goiter at the Mayo Clinic. *Western J Surg* 1935;9:477-820

- [93] Langley RW, Burch HB. Perioperative management of the thyrotoxic patient. *Endocrinol Metab Clin North Am*. 2003 Jun;32(2):519-34
- [94] Lahey FH. The decisions for surgery and the management of the patient with hypertension. *Surg Clin N Am* 1933;13:731-4
- [95] Wool MS. Hyperthyroidism. In: Cady C, Rossi RL, editors. *Surgery of the thyroid and parathyroid glands*. 3rd edition. Philadelphia: WB Saunders; 1991. p. 121-30
- [96] Cooper DS, Daniels GH, Ladenson PW, Ridgway EC. Hyperthyroxinemia in patients treated with high-dose propranolol. *Am J Med* 1982;73:867-71
- [97] Farling PA. Thyroid disease. *Br J Anaesth*. 2000 Jul;85(1):15-28
- [98] Plummer HS. Results of administering iodine to patients having exophthalmic goiter. *JAMA* 1923;80:155-6.
- [99] Yamada E, Yamazaki K, Takano K, Obara T, Sato K 2006 Iodide inhibits vascular endothelial growth factor-A expression in cultured human thyroid follicles: a microarray search for effects of thyrotropin and iodide on angiogenesis factors. *Thyroid* 16:545-554
- [100] Erbil Y, Ozluk Y, Giriş M, Salmaslioglu A, Issever H, Barbaros U, Kapran Y, Ozarman S, Tezelman S. Effect of lugol solution on thyroid gland blood flow and microvessel density in the patients with Graves' disease. *J Clin Endocrinol Metab*. 2007 Jun;92(6):2182-9
- [101] Wartofsky L, Ransil BJ, Ingbar SH. Inhibition by iodine of the release of thyroxine from the thyroid glands of patients with thyrotoxicosis. *J Clin Invest* 1970;49:78-86.
- [102] Wolff J, Chaikoff IL, Goldberg RC, Meier JR. The temporary nature of the inhibitory action of excess iodide on organic iodine synthesis in the normal thyroid. *Endocrinology* 1949;45:504-13
- [103] Eng PH, Cardona GR, Fang SL, Previti M, Alex S, Carrasco N, Chin WW, Braverman LE. Escape from the acute Wolff-Chaikoff effect is associated with a decrease in thyroid sodium/iodide symporter messenger ribonucleic acid and protein. *Endocrinology*. 1999 Aug;140(8):3404-10
- [104] Vagenakis AF, Braverman LE. Adverse effects of iodides on thyroid function. *Med Clin N Am* 1975;59:1075-88
- [105] Kirk RM. *General Surgical Operations*. Fifth Edition: Chirchill Livingstone: 2006
- [106] Sturgeon C, Sturgeon T, Angelos P Neuromonitoring in thyroid surgery: attitudes, usage patterns, and predictors of use among endocrine surgeons *World J Surg*. 2009;33(3):417
- [107] Randolph GW, Dralle H, International Intraoperative Monitoring Study Group, Abdullah H, Barczynski M, Bellantone R, Brauckhoff M, Carnaille B, Cherenko S, Chiang FY, Dionigi G, Finck C, Hartl D, Kamani D, Lorenz K, Miccolli P, Mihai R,

- Miyauchi A, Orloff L, Perrier N, Poveda MD, Romanchishen A, Serpell J, Sitges-Serra A, Sloan T, Van Slycke S, Snyder S, Takami H, Volpi E, Woodson G Electrophysiologic recurrent laryngeal nerve monitoring during thyroid and parathyroid surgery: international standards guideline statement. *Laryngoscope*. 2011 Jan;121 Suppl 1:S1-16
- [108] Dralle H, Sekulla C, Haerting J, Timmermann W, Neumann HJ, Kruse E, Grond S, Mühlig HP, Richter C, Voss J, Thomusch O, Lippert H, Gastinger I, Brauckhoff M, Gimm O. Risk factors of paralysis and functional outcome after recurrent laryngeal nerve monitoring in thyroid surgery. *Surgery*. 2004;136(6):131
- [109] Angelos P Recurrent laryngeal nerve monitoring: state of the art, ethical and legal issues. *Surg Clin North Am*. 2009;89(5):1157
- [110] Dralle H, Sekulla C, Lorenz K, Brauckhoff M, Machens A; German IONM Study Group. Intraoperative monitoring of the recurrent laryngeal nerve in thyroid surgery. *World J Surg*. 2008 Jul;32(7):1358-66. doi: 10.1007/s00268-008-9483-2. Review.
- [111] Atallah I, Dupret A, Carpentier AS, Weingertner AS, Volkmar PP, Rodier JF. Role of intraoperative neuromonitoring of the recurrent laryngeal nerve in high-risk thyroid surgery. *J Otolaryngol Head Neck Surg*. 2009 Dec;38(6):613-8
- [112] Chan WF, Lang BH, Lo CY. The role of intraoperative neuromonitoring of recurrent laryngeal nerve during thyroidectomy: a comparative study on 1000 nerves at risk. *Surgery*. 2006 Dec;140(6):866-72; discussion 872-3
- [113] Barczyński M, Konturek A, Cichoń S. Randomized clinical trial of visualization versus neuromonitoring of recurrent laryngeal nerves during thyroidectomy. *Br J Surg*. 2009 Mar;96(3):240-6
- [114] Chan WF, Lo CY. Pitfalls of intraoperative neuromonitoring for predicting postoperative recurrent laryngeal nerve function during thyroidectomy. *World J Surg*. 2006 May;30(5):806-12
- [115] Clark OH, Caron NR. Chapter 34: Fine needle aspiration biopsy of the thyroid, Thyroid lobectomy and sub-total and total thyroidectomy. In Josef E. Fischer, Kirby I. Bland, Mark P. Callery: *Mastery of Surgery, Volume 1*, Lippincott Williams & Wilkins, p398-411
- [116] Mosby's Dental Dictionary, 2nd edition. © 2008 Elsevier, Inc available at <http://medical-dictionary.thefreedictionary.com/thyroid+gland>
- [117] Delbridge L. Total thyroidectomy: the evolution of surgical technique *ANZ J Surg*. 2003 Sep;73(9):761-8
- [118] Sanabria A, Carvalho AL, Silver CE, Rinaldo A, Shaha AR, Kowalski LP, Ferlito A. Routine drainage after thyroid surgery--a meta-analysis. *J Surg Oncol*. 2007 Sep 1;96(3):273-80

- [119] Shaha AR Revision thyroid surgery-technical considerations. *Otolaryngol Clin North Am.* 2008;41(6):1169
- [120] Lefevre JH, Tresallet C, Leenhardt L, Jublanc C, Chigot JP, Menegaux F Reoperative surgery for thyroid disease. *Langenbecks Arch Surg.* 2007;392(6):685
- [121] Levin KE, Clark AH, Duh QY, Demeure M, Siperstein AE, Clark OH Reoperative thyroid surgery. *Surgery.* 1992;111(6):604
- [122] Kraim ps JL, Marechaud R, Gineste D, Fieuzal S, Metaye T, Carretier M, Barbier J. Analysis and pre prevention of recurrent goitre. *Surg Gynecol Obstet* 1993: 176; 319 – 322
- [123] Seiler CA, Glaser C, Wagner HE. Thyroid gland surgery in an endemic region. *World J Surg* 1996: 20:20; 593–597
- [124] Prichard RS, Delbridge L. Reoperation for Benign Disease. p95-104. In: Randolph GW. *Surgery of the Thyroid and Parathyroid Glands.* Second Edition: Elsevier: 2013
- [125] Cushieri A, Grace PA, Darzi A, Borley, Rowley DI Chapter 34 Disorders of the Endocrine Gland In *Clinical Surgery* second edition Blakwell Publishing p441-449
- [126] Cayo AK, Yen TW, Misustin SM, Wall K, Wilson SD, Evans DB, Wang TS Predicting the need for calcium and calcitriol supplementation after total thyroidectomy: results of a prospective, randomized study. *Surgery.* 2012 Dec;152(6):1059-67. Epub 2012 Oct 13
- [127] Hayward NJ, Grodski S, Yeung M, Johnson WR, Serpell J. Recurrent laryngeal nerve injury in thyroid surgery: a review. *ANZ J Surg.* 2013 Jan;83(1-2):15-21
- [128] Banerjee S Chapter 3 Ear, Nose and Throat, Head and Neck In *Parchment Smith Essential Revision Notes for Intercollegiate MRCS Book 2 PasTest* p809-814
- [129] Sadler GP, Mihai R. The thyroid gland. Lennard TWJ. *A Companion to Specialist Surgical Practice. Endocrine Surgery.* Fourth Edition: Saunders: 2009 p39-72
- [130] Thomusch O, Machens A, Sekulla C, Ukkat J, Brauckhoff M, Dralle H. The impact of surgical technique on postoperative hypoparathyroidism in bilateral thyroid surgery: a multivariate analysis of 5846 consecutive patients. *Surgery.* 2003 Feb;133(2):180-5.
- [131] Thomusch O, Machens A, Sekulla C, Ukkat J, Lippert H, Gastinger I, Dralle H. Multivariate analysis of risk factors for postoperative complications in benign goiter surgery: prospective multicenter study in Germany. *World J Surg.* 2000 Nov;24(11): 1335-41
- [132] Tait C (2010) Chapter 5 Endocrine Surgery In *Parchment Smith Essential Revision Notes for Intercollegiate MRCS Book 2 PasTest* p937-953
- [133] Dent CE, Harper CM. Hypoparathyroid tetany (following thyroidectomy) apparently resistant to vitamin D. *Proc R Soc Med* 1958; 51:489

- [134] Jones RM, Davidson CM. Thyrotoxicosis and the hungry bone syndrome: a cause of postoperative tetany. *J R Coll Surg Edinb* 1987; 32:24
- [135] Brasier AR, Nussbaum SR. Hungry bone syndrome: clinical and biochemical predictors of its occurrence after parathyroid surgery. *Am J Med* 1988; 84:654.
- [136] Berkoben, M, Quarles D Hungry bone syndrome following parathyroidectomy. Aug, 2012. Up to Date, Editors: Goldfarb S, Sheridan A. Available at <http://www.uptodate.com/contents/hungry-bone-syndrome-following-parathyroidectomy>
- [137] Green MF. The endocrine system. In: Pathy MSJ, editor. *Principles and practice of geriatric medicine*. 2nd ed. New York:John Wiley & Sons; 1991. p. 1061-122
- [138] Jameson L, Weetman A: Disorders of the thyroid gland. *Harrison's principles of internal medicine*. 15th edition. Edited by Brawnwald E, Fauci A, Kasper D. New York: McGraw-Hill; 2001::2060-2084
- [139] Tietgens ST, Leinung MC: Thyroid storm. *Med Clin North Am* 1995, 79:169-184
- [140] Carroll R, Matfin G. Endocrine and metabolic emergencies: thyroid storm. *Ther Adv Endocrinol Metab*. 2010 Jun;1(3):139-45
- [141] Burch HB, Wartofsky L. Life-threatening thyrotoxicosis: thyroid storm. *Endocrinol Metab Clin North Am* 1993; 22: 263–77
- [142] Kandaswamy C, Balasubramanian V. Review of adult tracheomalacia and its relationship with chronic obstructive pulmonary disease. *Curr Opin Pulm Med* 2009;15:113-9
- [143] Mellièrè D, Guterman R, Danis RK. [Substernal goitre. Report of 45 cases (author's transl)]. [Article in French] *J Chir (Paris)*. 1980 Jan;117(1):13-8
- [144] McHenry CR, Piotrowski JJ. Thyroidectomy in patients with marked thyroid enlargement: airway management, morbidity, and outcome. *Am Surg*. 1994 Aug;60(8): 586-91.
- [145] Geelhoed GW. Tracheomalacia from compressing goiter: management after thyroidectomy Surgery. 1988 Dec;104(6):1100-8
- [146] Randolph GW, Shin JJ, Grillo HC, Mathisen D, Katlic MR, Kamani D, Zurakowski D. The surgical management of goiter: Part II. Surgical treatment and results. *Laryngoscope*. 2011 Jan;121(1):68-76

