

We are IntechOpen, the world's leading publisher of Open Access books Built by scientists, for scientists

6,900

Open access books available

186,000

International authors and editors

200M

Downloads

Our authors are among the

154

Countries delivered to

TOP 1%

most cited scientists

12.2%

Contributors from top 500 universities



WEB OF SCIENCE™

Selection of our books indexed in the Book Citation Index
in Web of Science™ Core Collection (BKCI)

Interested in publishing with us?
Contact book.department@intechopen.com

Numbers displayed above are based on latest data collected.
For more information visit www.intechopen.com



The Cancer Patient/Oral Complications of Cancer Therapy and Management

With the advance in early diagnosis and new modalities of therapy, cancer patients survive for many years after completion of therapy. However, cancer therapies are also toxic to normal tissues and organs in the human body and can cause both acute and chronic complications. Some of these complications occur in the oral cavity and require that the dental clinician be competent in diagnosing and managing the patients. Acute complications occur during cancer therapy and chronic complications are called late effects because they occur after completion of therapy and can persist for many years. There are different modalities of cancer therapies and some of them are used in combination. Depending on the toxicity of each therapy, the risk of oral complications can increase. Table 2 shows types of cancer therapy and the estimated risk of oral complications.

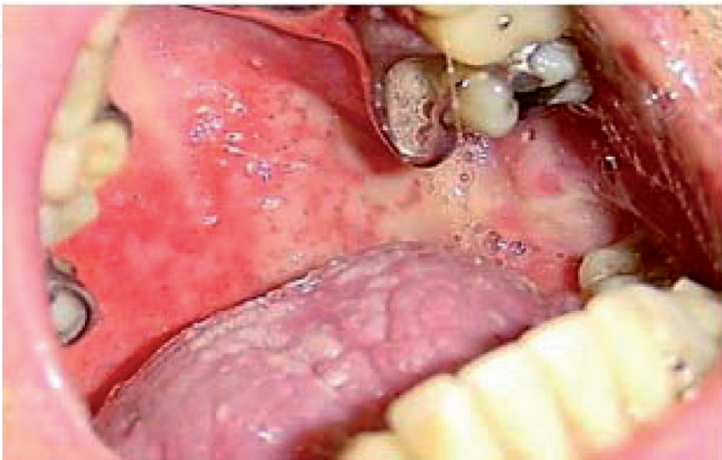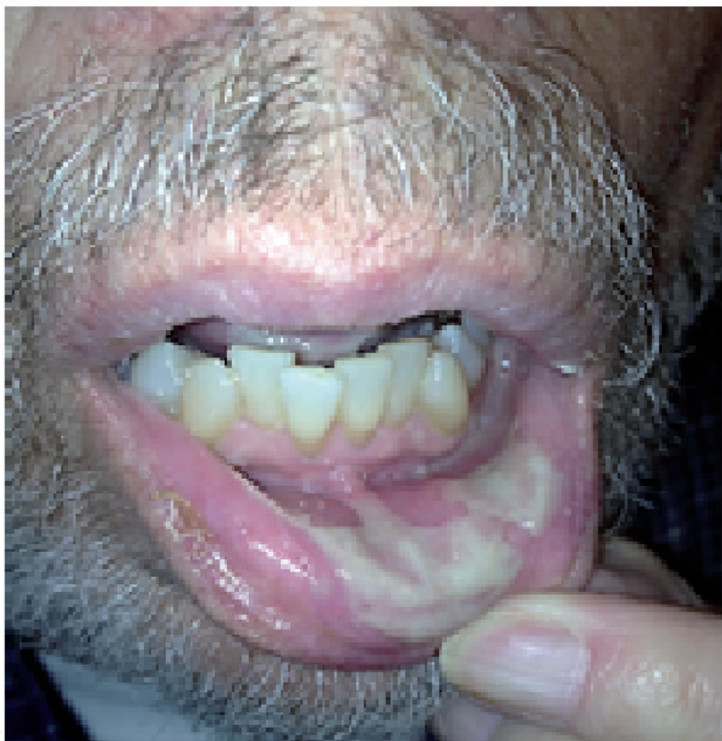Cancer Treatment Modality	% of patients at risk for oral complications
Head & neck radiation therapy with salivary glands in radiation field	100
Hematopoietic Stem Cell Transplantation	80
Chemotherapy (primary)	40
Adjuvant (additional treatment with) chemotherapy or immunotherapy	10

Table 1. Cancer treatment modalities and risk of oral complications

Dentists in private practice may be referred cancer patients in two common situations: a patient recently diagnosed with cancer that needs dental treatment prior to starting cancer therapy. These usually are head and neck cancer patients who will be treated with radiation therapy and will be problematic to receive dental surgical treatment because of the risk of infection and osteoradionecrosis. The other type of referral will be a patient who has completed cancer therapy and may now have oral complications such as dry mouth and need continued dental treatment and follow-up. It is important to keep in mind that such oral complications as dry mouth can be permanent and place the patient at risk of severe caries and periodontal disease. Therefore, maintenance of good oral health and hygiene will be very important for the rest of the patient’s life. Some specific oral hygiene protocols for this patient population are discussed in chapter 12. Following, we will describe some of the oral complications of cancer therapy.

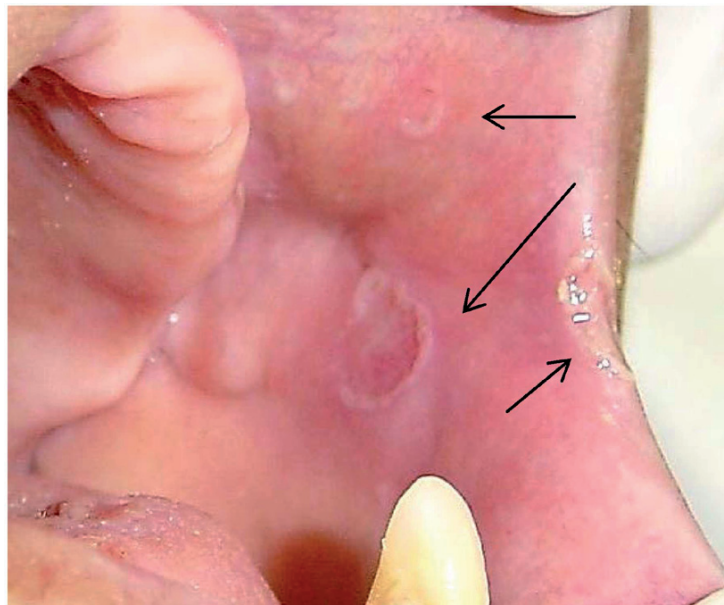
1. Mucositis

Oral mucositis is an acute complication in the oral cavity of patients treated with radiation and chemotherapy. It is characterized by oral mucosal ulcerations that can start as erythema and progress to large ulcerative lesions that are very painful. The ulcers result from the toxicity of the therapy and usually have an onset around the 7th through the 11th day after starting therapy and can remain active until the effects of therapy end. Patients are usually managed symptomatically, as there is no effective prevention or treatment for this condition. The ulcers can become infected with *Candida* and/or bacteria. Oral rinses with steroids such as dexamethasone can be associated with antifungals like nystatin and topical xylocaine. Oral bacterial and viral infections can also be included in the differential diagnosis of oral mucositis.



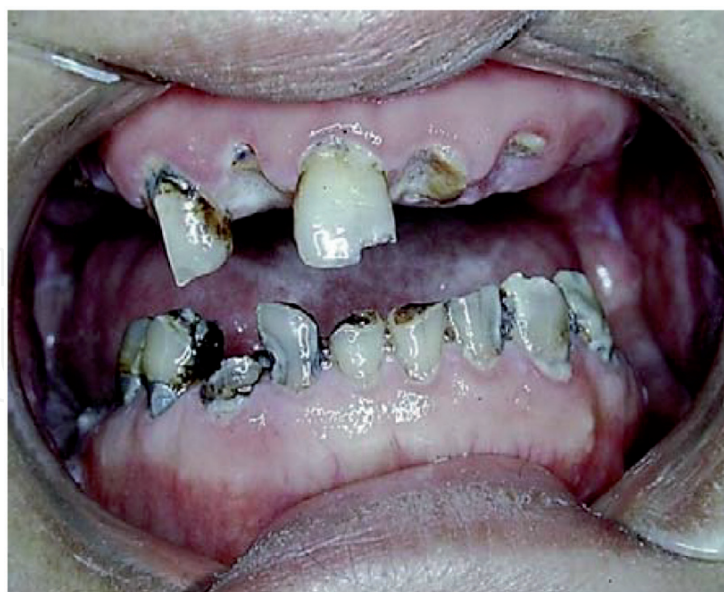2. Herpetic infection

Herpes infection can be reactivated during cancer therapy. This patient was receiving chemotherapy and developed sudden onset of severe pain that prevented her from eating, drinking and performing oral hygiene. Observe that the herpetic lesions have an unusual clinical presentation of an ulcerated area that can appear anywhere in the oral mucosa, with raised and somewhat keratotic borders. Systemic antiviral therapy with valacyclovir is recommended.



3. Hyposalivation/xerostomia

The photograph shows a patient with dry mouth and foamy saliva post radiation therapy of a tumor in the oral cavity. The decreased amount of saliva in the mouth, associated with poor oral hygiene, leads to the development of severe and rampant decay. Because part of the alveolar bone was included in the fields of radiation, the extraction of teeth could lead to the development of osteoradionecrosis. Such involvement of teeth and mouth tissues with disease could have been prevented with a good oral hygiene protocol and high content fluoride toothpaste, rinse, or fluoride gel in a tray that the patient uses once a day.

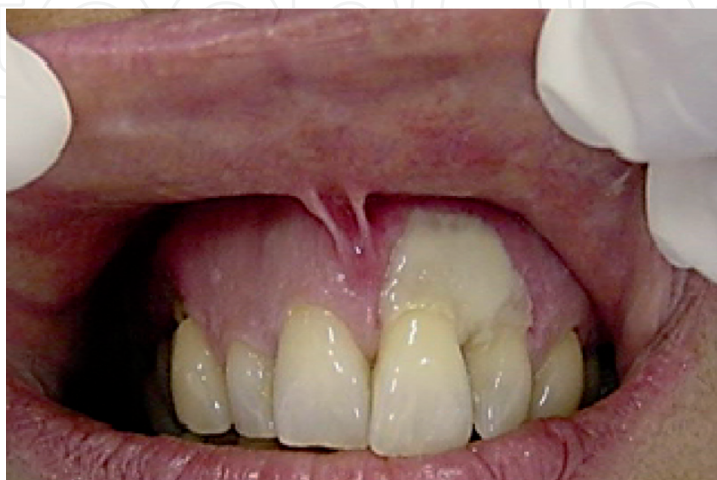

4. Infections/bleeding

Because of changes in saliva quantity and quality, and because of effects on the bone marrow, cancer patients may develop infections in the oral cavity. The quick diagnosis and management of these complications is of utmost importance. Patients are susceptible to fungal, bacterial and viral infections. Photographs below demonstrate examples of infections of various etiologies. The required therapy will be adjusted according to the type of infecting agent.

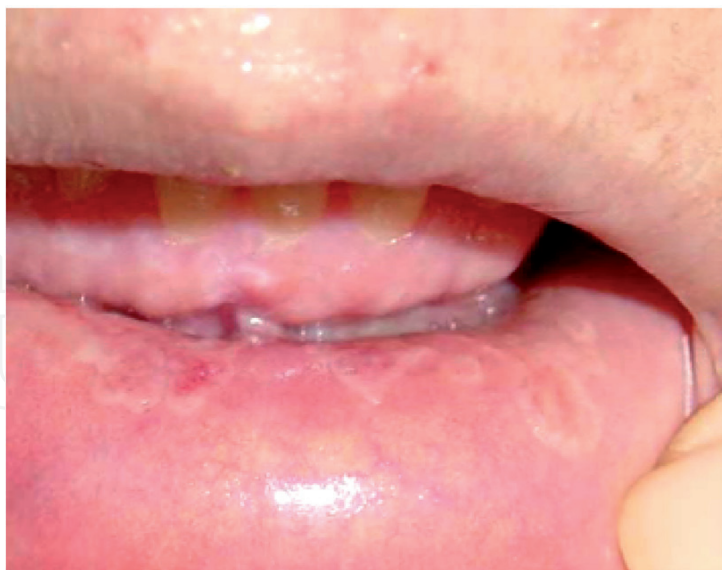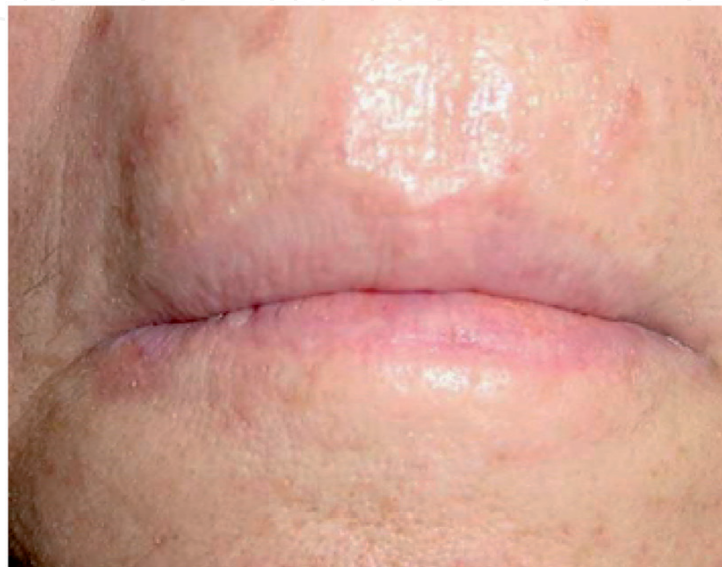5. Chemotherapy patient with *pseudomonas aeruginosa* infection

Observe areas of necrotic tissue on the buccal gingiva and vestibule. The patient was in pain and needed immediate care. The infectious agent was sensitive to ciprofloxacin and clindamycin. Topical rinses with chlorhexidine complemented the treatment.



6. Chemotherapy patient with herpetic outbreak

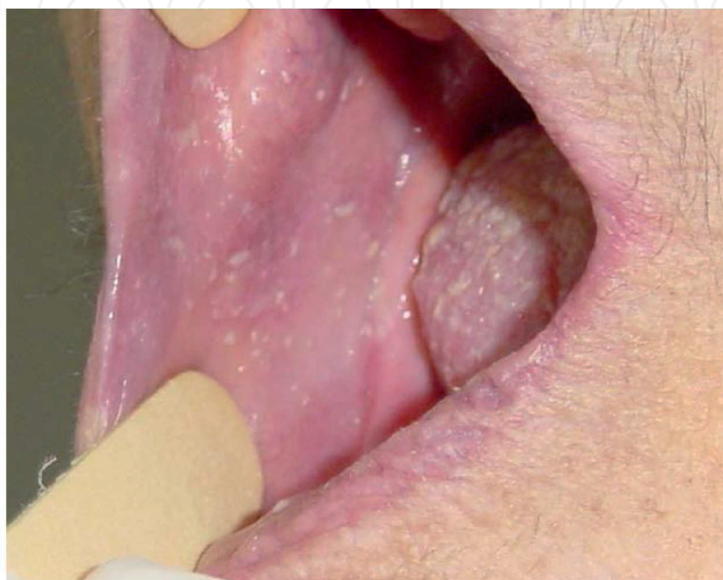The patient below developed an overnight onset of distressing pain and discomfort in the mouth. She presented with a large number of ulcerated lesions distributed throughout the oral mucosa. The ulcers were painful and presented with a whitish and raised periphery. The diagnosis of a herpetic infection was suspected based on the rapid onset, the severe pain, and the clinical appearance of the lesions. The patient was immediately treated with acyclovir tablets and responded well to therapy.



7. Chemotherapy patient with oral candidiasis

The patient in the photograph presented with the lip and oral lesions following a course of chemotherapy from an abdominal malignancy. She developed a general discomfort in the oral

cavity and could no longer taste food. She complained of a burning sensation. Clinically, she presented with areas of white plaques and colonies that could be scraped with gauze suggesting oral candidiasis. The lesions extended to all walls of the mouth. She was treated with an antifungal agent, fluconazole, and responded well to therapy.

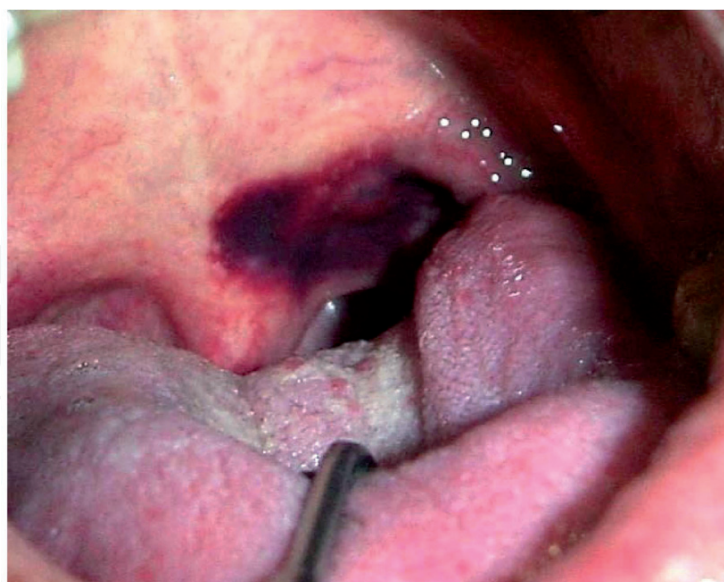


8. Dental treatment of myelosuppressed patients

Some types of chemotherapy can alter bone marrow function leading to suppression. This will place the patient at risk for infections and bleeding. During periods of marrow suppression, patients should not receive elective dental treatment. The treatment of dental emergencies should be planned with the oncology team and precautions should be in place to prevent the initiation and dissemination of mouth infections and bleeding. For this reason, dental disease should be ideally treated prior to the start of cancer therapy. Therefore, good communication between the oncology team, the dental provider and the patient should be established so information can be shared and patient safety can be in place to prevent complications. Stages of immunosuppression occur during high dose chemotherapy and hematopoietic stem cell transplantation. Immunosuppression of transplanted patients persists for years in order to prevent organ rejection. Thus, patients will be at risk of complications for prolonged periods of time. Dental care for these individuals should only be provided when there is good communication amongst the team caring for the individual.

9. Submucosal bleeding in a patient with bone marrow suppression

This chemotherapy patient had a minor trauma while eating and developed submucosal bleeding due to platelet deficiency.



10. Osteoradionecrosis (ORN)

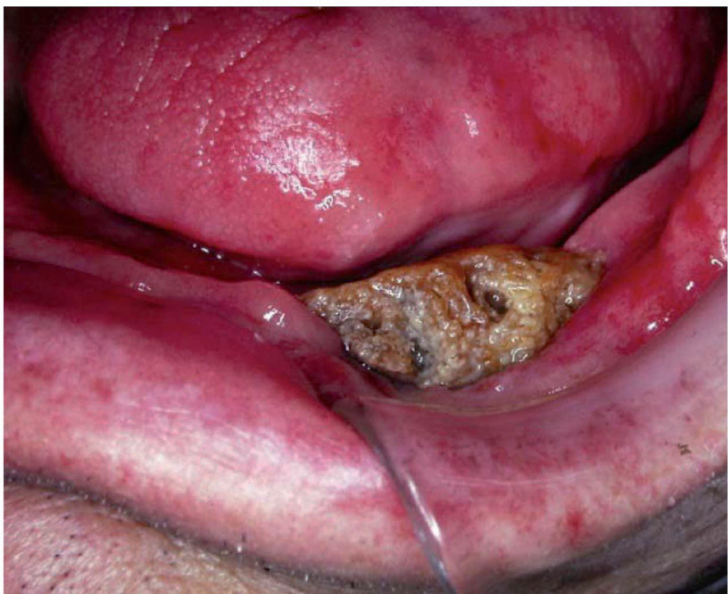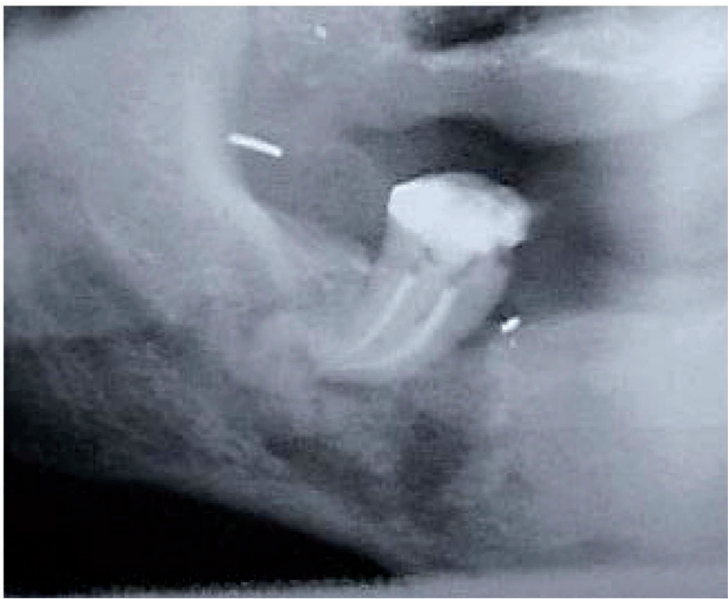
Radiation therapy of the head and neck area can increase the risk for serious complications. One of the late effects of radiation is ORN. Bones included in the field of radiation can develop deficient healing capability because of the effects of radiation on vascularization and cells. It is commonly said that irradiated jaw bones will be avascular, acellular, and hypoxic due to lack of blood vessels. Trauma or chronic infection in irradiated areas can be the stimuli for the development of necrosis because the bones cannot remodel, leading to the formation of ORN. This is a serious complication of radiation and is dependent on the dose of radiation to the bones and the patient's oral health. This complication is usually started by a dental extraction or a periodontal infection and can be non-responsive to antibiotic therapy and local measures. In more severe cases, surgical resection of the affected area is indicated. Patients at risk for this complication usually have received about 5,000 centigrays of radiation and the risk is life-long.

The mandible is the most commonly affected area. Patients complain of pain, partial or complete loss of sensation, infection and fistula formation. In advanced cases, bone fracture can occur.

The management of ORN is multidisciplinary and should involve the oncology team, dental providers and physical therapists. In areas of bone that received high doses of radiation, care must be taken prior to doing invasive dental procedures such as dental extractions or any type of surgery. The determination of radiation dose to the area that needs to be surgically treated must be determined with the help of the radiation oncologist. Only with this information can safer surgical procedures be assured. It has been proposed that prior to doing surgery in irradiated areas in the oral cavity, hyperbaric oxygen therapy (HBO) can be used to increase tissue oxygenation. However, this type of therapy is expensive and there is no scientific prove that it can decrease the risk of ORN. Areas of established ORN can be managed conservatively by local and systemic measures. Broad spectrum systemic antibiotics and topical antiseptic

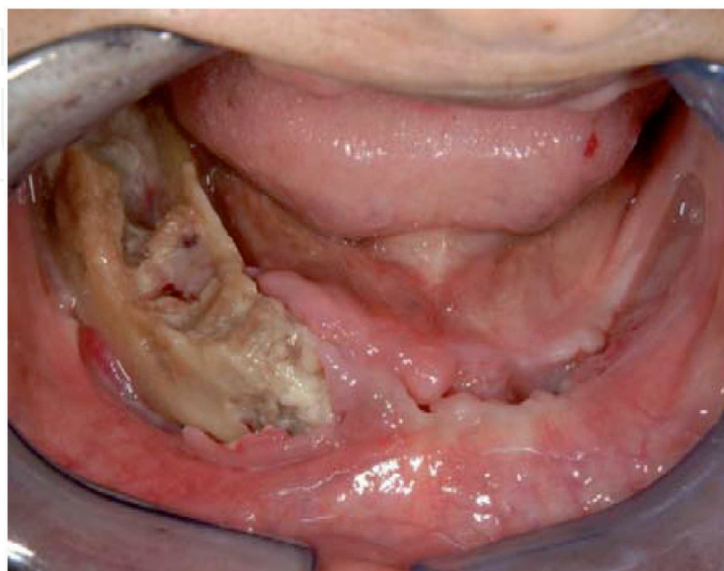
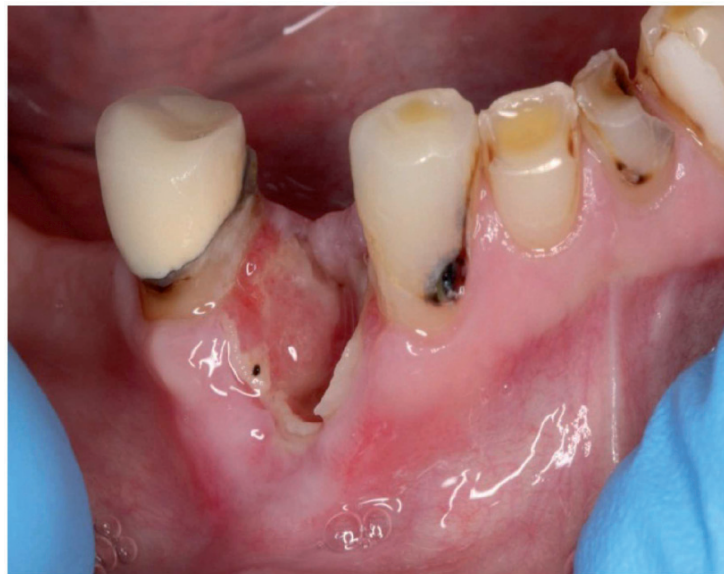rinses can be helpful. Partial debridement of bone can decrease the risk of local trauma to the soft tissues. Pain medication can help control symptoms effectively.

The photographs show the radiographic appearance of an early case of ORN in a patient who was treated with radiation for a tumor of the right cheek. Note that the endodontic therapy of the involved molar was not enough to control the progress of the local infection leading to the bone necrosis. The clinical photograph shows a more advanced area of necrotic bone that has been uncovered by the oral mucosa. The area is very painful and surgical resection will be required in order to control the process of ORN.



11. Osteonecrosis of the jaws (ONJ)

This is a new oral complication in cancer patients associated with the use of medications that inhibit osteoclasts by various mechanisms. With the inhibition of bone resorption by the osteoclasts, bone cannot be renewed. More recently, new medications with antiangiogenic effect have also been reported to cause ONJ. This complication is defined as the presence of necrotic bone exposed to the oral environment in a patient who is taking an antiresorptive or an antiangiogenic medication and who has not had radiation therapy in the head and neck area. Medications associated with ONJ include the bisphosphonates and denosumab (antiresorptives), and bevacizumab and sorafenib (antiangiogenics). Patients may complain of pain and malodor, loss of sensation and discomfort. There may be evidence of active infection with swelling and pus secretion.



ONJ does not usually respond to standard therapy and in more advanced cases may require resection and primary closure of the surgical defect. Early cases can be controlled with topical measures such as mouth rinses with chlorhexidine. When there is active infection and pain or loss of sensation, systemic antibiotics should be used. More advanced cases that do not respond to therapy should be managed by providers with expertise in the field.

The photographs above show: an early case with a non-healing alveolus after the extraction of a mandibular premolar. Observe the exposed necrotic bone and granulation tissue; this is an advanced case in which about one half of the mandible is necrotic and not covered by oral mucosa.

Additional reading

<http://www.cancer.gov/cancertopics/pdq/supportivecare/oralcomplications/HealthProfessional/page1>

Hupp W, Brennan M, Migliorati CA. Co-Editors: The Dental Management of the Cancer Patient, 1st edition. American Academy of Oral Medicine, 2012.