

We are IntechOpen, the world's leading publisher of Open Access books Built by scientists, for scientists

6,900

Open access books available

186,000

International authors and editors

200M

Downloads

Our authors are among the

154

Countries delivered to

TOP 1%

most cited scientists

12.2%

Contributors from top 500 universities



WEB OF SCIENCE™

Selection of our books indexed in the Book Citation Index
in Web of Science™ Core Collection (BKCI)

Interested in publishing with us?
Contact book.department@intechopen.com

Numbers displayed above are based on latest data collected.
For more information visit www.intechopen.com



Robotic Colorectal Cancer Surgery

Ray Swayamjyoti, Jim Khan and Amjad Parvaiz

Additional information is available at the end of the chapter

<http://dx.doi.org/10.5772/58350>

1. Introduction

A robot is a mechanical or virtual agent, usually an electro-mechanical machine that is guided by a computer program or electronic circuitry. Robots have been linked with the future and modern civilization but have been around for more than 2000 years since ancient Greek automata. Their real surgical application has been in the last 20 years [1, 2].

Robots were first used in medicine to help people with disabilities to aid in their rehabilitation process. The Edinburgh Modular Arm System [3] was one of the first bionic arm which was engineered by Dr. David Gow in the early eighties.

The National Aeronautics and Space Administration (NASA) developed the first telemanipulator robot in 1985 at the behest of the Defense Department of the United States of America with the aim to decrease war casualties using telerobotic surgery [4].

It was believed that robots could have prevented more than a third of the soldiers from dying during the Vietnam War secondary to haemorrhage [5].

Robotic colorectal operations have gained considerable interest after successful implementation in the field of urology and gynaecology. The advantages of a stable platform, better vision and better access has made this an attractive tool in many specialities. [6] Pelvic and rectal resections are best suited for robotic operations [6].

2. The Da Vinci surgical robotic system

The Federal Drug and Administration approved the use of the da Vinci robotic system for surgical treatment in 2000 and it was first used at the Ohio State University Hospital for oesophageal and pancreatic surgery [22].

Year	Milestones
1985	• PUMA 560 was used under computerised tomography guidance to orient a needle for brain biopsy [7]
1992	• PROBOT - developed at Imperial College, London and was used to perform prostatic surgery at Guy's and St Thomas' Hospital, London [8] • The ROBODOC developed by Integrated Surgical Systems was used to curve out accurate fittings in the femur for hip replacement [8]
1998	• Zeus robotic surgical system – used for reconstruction of the Fallopian tube performed at the Ohio State University Medical Center [9]
1999	• Robotics assisted closed chest bypass on a beating heart was performed at the London Health Sciences Centre [10]
2000	• FDA approval of da Vinci robotic system [11]
2002	• Robotic cholecystectomy [12] • Robotic Right Hemicolectomy [13] • Robotic bowel resections [14]
2006	• Unassisted robotic surgery using artificial intelligence to correct atrial fibrillation at a hospital in Milan [15]
2007	• Denervation of spermatic cord for testicular pain using robotic assisted microsurgery performed at Winter Haven Hospital and University of Florida [16]
2008	• Magnetic Resonance guided neurosurgical procedure performed at University of Calgary [17] • Microsurge developed by German Aerospace Center [18]
2010	• Sophie Surgical System developed by Eindhoven University of Technology [19] • Femoral reconstruction [20] • World's first all robotic operation i.e. prostatectomy using the da Vinci robot along with McSleepy robot used for anaesthesia at McGill University Hospital, Canada [21]

Table 1. Development of Robotics to aid in Surgical Procedures.

At present it is extensively used throughout the world and has sold over 2000 units worldwide in 2013. It is estimated then more than 200,000 operations have been performed in 2012 [23, 24].

The initial model of da Vinci was released in the year 1999, later this was updated to “S” in 2007 and in 2009 Si was released with improved functions and better performance. The author uses the da Vinci “Si” robotic system for his colorectal operations.

The da Vinci system consists of a surgeon’s console and four interactive robotic arms attached to the robotic cart controlled by the surgeon from the console. One of the arms carries an endoscopic camera via a 12mm port. The camera has two lenses, which gives a 3D image with stereoscopic vision when the surgeon looks through the eyepiece in the console. The three other arms are used to hold tools and tissues i.e. scissors, bovies, electrocautery. The arms are maneuvered using two-foot pedals and two hand controllers.

Unlike laparoscopy the da Vinci system allows the surgeon to perform operation seated at the console, with the hands and eyes positioned in line with the instruments. The operating surgeon is able to control the movements of the camera using the foot pedal rather than relying on an assistant. The system is able to filter and decipher surgeon's hand movements into steady and precise micro movements.

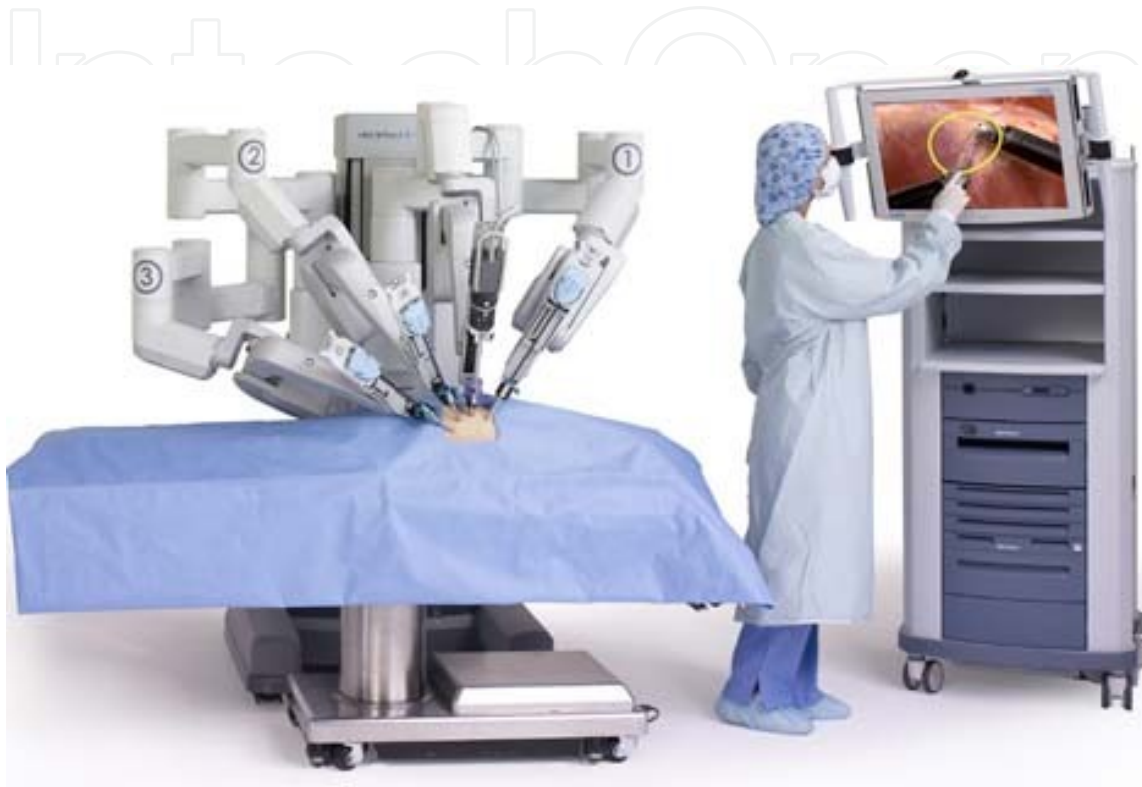

Figure 1. [25]: showing the robotic stack/cart and the monitor used by the assistant to follow the operation

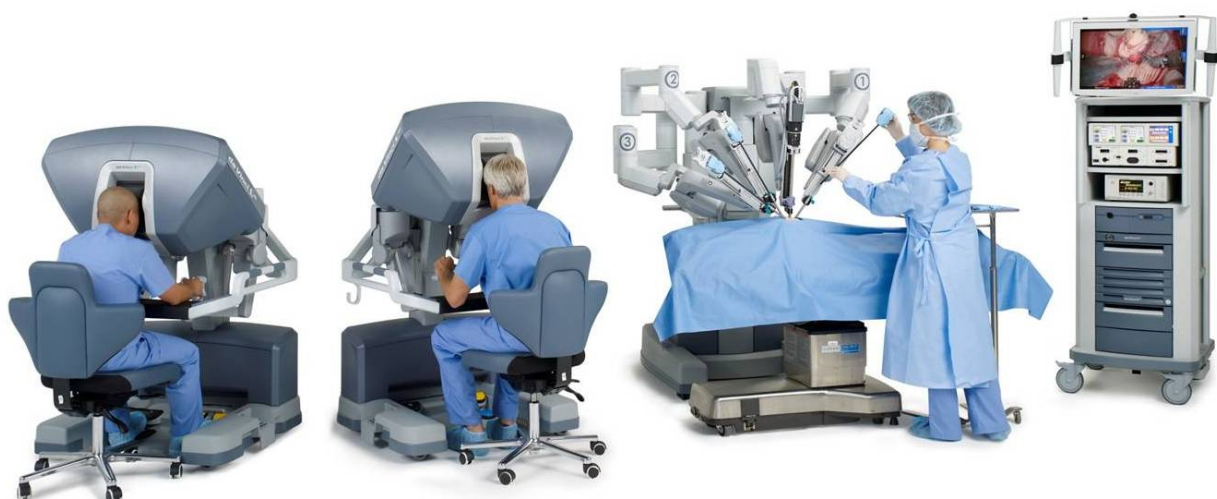

Figure 2. [26] : showing robotic and vision carts and the surgeon's console with an additional teaching console

3. Evidence of robotics in colorectal surgery

Robotic colorectal surgery is gaining widespread interest worldwide and in the continent. Data collected in 2012 suggests that most of the reported or published data shows that majority of the robotic colorectal operations have been performed in the United States (32%) followed by South Korea (20%), Italy (15%), Canada, Germany and Netherlands accounted for 5% and the rest of the world less than 2% [13].

The first colorectal surgical publication was published by Weber et al in 2002 [27] and since then there has been a tenfold rise in publication in colorectal surgery [13]. The important landmark studies are summarized in table 2.

Laparoscopic colorectal operations have many advantages over conventional open operations. The benefits in terms of short term outcomes are well established and include shorter hospital stay, faster return to work, better cosmesis, less post operative pain, less risk of bleeding and ileus. Long term outcomes including cancer specific and disease free survival have been subject of many well-designed trials.

The COLOR (Colon cancer Laparoscopic or Open resection) trial (330 stated that laparoscopic colectomy was associated with less significant blood loss, earlier recovery of bowel function, use of fewer analgesics and with a shorter hospital stay when compared with open colectomy. It however took half an hour longer than open operations and had 19% chances of converting to open operation. The reasons for conversion were mainly attributed to tumour size of more than 6cms and in patients who had involvement of adjacent structures.

There were concerns regarding tumour recurrence associated with laparoscopic colectomy. The meta-analysis of four randomized control trials (CLASICC trial, COST trial, Barcelona trial and COLOR trial) where patients with colonic cancers were randomised to either open or laparoscopically assisted colectomy concluded that the positive margins were found in specimens after open operations were 2.1% as compared to 1.3% after laparoscopic operation. The overall disease free survival at three years was 83.5% for open operations and 82.2% for laparoscopic operations [34]. Hence, the evidence shows that laparoscopic colonic operation is oncologically safe and viable with comparable outcomes to open surgery [34, 35].

The safety and viability for rectal cancers is still less clear especially with the higher circumferential margin (CRM) involvement with laparoscopic rectal operations when compared to open rectal operations as mentioned in the CLASSIC trial [34]. There was however, no difference in local recurrence at three years [36]. There was a higher conversion rate in the laparoscopic rectal subgroup (34%) in comparison to laparoscopic colonic group (25%). Conversions to open operations led to higher mortality and morbidity [34, 37]. Conversions were mainly attributed to bulky tumours [33] and increased technical difficulty [37]. The robot promises to abolish some of these technical problems faced during dissection of rectal tumours using laparoscopy and the ROLARR (RObotic versus LAParoscopic Resection for Rectal cancer) trial results are awaited. It is an international, multicentre, prospective, randomised, and controlled, unblinded, parallel-group trial of robotic-assisted versus laparoscopic surgery for the curative treatment of rectal cancer [37].

Year	Reference	Country	Study type	Number of patients
2002	Weber et al.	USA	Case series	2,
				3,
	Hashizume et al.	Japan		18
2003	Talamini et al.	USA		
	Vibert et al.	France	Case series	3,
	Giulianotti et al.	Italy		16
2004	Hubens et al.	Belgium	Case series,	8,
	Anvari et al.	Canada	Prospective Comparative	10,
	D'Annibale	Italy	Comparative	53
2005	Woeste et al.	Germany	Comparative,	6,
	Bonder et al.	Austria	Case series,	14,
	Ruurda et al.	Holland	Case series	23
2007	Heemskerk et al.	Netherlands	Comparative	19
2008	Baik et al.	Korea,	Randomized trial,	18,
	Spinoglio	Italy,	Comparative,	50,
	Huettnner et al.	USA,	Comparative,	70,
	Soravia et al.	Switzerland	Case series	40
2009	Baik et al.	Korea	Comparative,	56,
	DeHoog et al.	Netherlands	Case control	20
2010	Tsoraides et al.	USA,	Retrospective,	102,
	Kim and kang	Korea,	Comparative,	100,
	Bianchi et al.	Italy,	Comparative,	56,
	Pernazza and Morpurgo	Italy,	Case series,	50,
	DeSouza et al.	USA,	Case control,	40,
	Zimmern et al.	USA,	Case series,	131,
	Popescu et al.	Romania	Comparative	122
2011	Kang and kim	Korea	Retrospective	204
2012	Antoniou SA et al [28]	Germany	Case series	39
2013	Casillas MA Jr et al [29]	USA	Case series	344
	Germain A et al [30]	France	Case Series	77
	Barrie J et al [31]	UK	Comparative	34
	Wormer BA et al [32]	USA	Comparative	1809

Table 2. [13]

The skills required for laparoscopic operations are different to open operations.

Limitations of laparoscopic surgery include loss of depth perception, reduced tactile feedback and a declined range of motion [33]. The author believes that limited space in the pelvis, with two-dimensional visions and a bulky specimen can make laparoscopic operations very difficult.

Laparoscopic TME rectal resections have a steep learning curve [38], requiring precise pelvic dissection with preservation of autonomic nerves. There is higher incidence of male sexual dysfunction due to inadvertent injury to the nerves following TME resections [39]. It is estimated that 50% of colorectal surgeons perform laparoscopic colorectal operations in the UK and only a quarter of them perform laparoscopic TME resections [40]. Approximately 50-70 cases are needed to surmount the laparoscopic colorectal learning curve [35, 38, 41].

The COREAN trial [42] trial compared open surgery with laparoscopic surgery for mid or low rectal cancer after neoadjuvant chemoradiotherapy. There was a conversion rate of 1.2% in the COREAN trial as compared to 34% in the CLASSIC trial. The low conversion rate in the COREAN trial was attributed to greater experience of the surgeons who has performed an average of seventy laparoscopic operations as compared to twenty per average surgeon in the CLASSIC trial [43].

The learning curve for performing robotic colorectal operations is shorter and is achieved after 15-20 cases [37, 38]. There are three phases that has been identified in the learning curve for robotic colorectal operations [44, 45, 46]

- Phase 1 – initial learning (1-15 cases)
- Phase 2 – increased competence (15-25 cases)
- Phase 3 – period of highest skill (>25 cases)

The other advantages of robotic colorectal resections are that

- It is superior in narrow areas like the pelvis and it's safe and feasible [47] with good three dimensional view and zoom magnification [37]
- It has 7 degrees of freedom of movement [37]
- It is associated with lower conversion rates to open operation [48]
- It has better pathologic and functional outcomes. It is associated with less complication rates, shorter duration of hospital stay, time to recover to normal bowel function or first flatus and time to start diet. It also causes less postoperative pain [49].
- Hospitals who perform high-volume robotic colorectal operations have significantly lower rates of postoperative bleeding and ileus [50]
- the double console that comes with the robotic cart allow trainees to take part actively at the surgical procedure and learn from it [51]
- simulators are available than can be attached to the console which provides a platform for surgical trainees to practice their skills before actually performing the procedures

There are however some limitations of the da Vinci system. In particular

- there is a definite learning curve for this technique
- loss of tactile feedback although partly compensated by better vision, still can have its effects on the performance and outcomes
- Hospitals that perform less robotic colorectal operations had more complications with longer length of hospital stay causing higher cost for the hospital. [19]
- High cost of purchasing as well as maintaining the robotic system [22]

	LNs (mean N)			Distal margin(mean, cm)			Positive CRM (%)		
	ROB	LAP	<i>p</i>	ROB	LAP	<i>p</i>	ROB	LAP	<i>p</i>
Park et al, 2010	17.3	14.2	0.06	2.1	2.3	ns	4.9	3.7	0.5
Kim et al, 2010	14.7	16.6	ns	2.7	2.6	0.09	3	2	ns
Kwak et al, 2011	20	21	0.7	2.2	2.0	0.8	1.7	0	>0.9
Baek et al, 2011	13	16	0.07	3.6	3.8	0.6	2.4	4.9	1
Bianchi et al, 2010	18	17	0.7	2	2	1.0	0	4	0.9
Baik et al, 2009	18.4	18.7	0.8	4	3.6	0.4	7	8	0.7
Patriti et al, 2009	10.3	11.2	>0.05	2.1	4.5	>0.05	0	0	ns

(LNs: lymph nodes, CRM: circumferential resection margin, ns: not significant, ROB: robotic procedure, LAP: laparoscopic procedure.)

Table 3. Oncologic results of robotic and laparoscopic surgery for rectal cancer [52].

	LNs (mean)			Distal margin (mean, cm)			Positive CRM (%)		
	ROB	OPEN	<i>p</i>	ROB	OPEN	<i>p</i>	ROB	OPEN	<i>p</i>
De Souza et al], 2011	15	16.8	0.26	na	na		0	3	0.25
Kim et al, 2012	20	19.6	0.7	2.7	1.9	0.001	1	1	1
Park et al, 2011	19.4	18.5	0.06	2.8	2.3	0.002	1	2	0.9

(LN: lymph nodes, CRM: circumferential resection margin, na: not assessed, ROB: robotic procedure, OPEN: laparoscopic procedure.)

Table 4. Oncologic results of open and robotic surgery for rectal cancer [52].

4. Patient selection

Patient selection is the key especially in the early stages of the learning curve. The author would recommend choosing patients with

- ASA grade 1-3
- BMI <30
- Age <75 years
- No previous pelvic or intra-abdominal surgery
- T1/T2 tumours
- Tumors that are at or just above the peritoneal reflection of the rectum
- Avoid patients who received neo-adjuvant chemo-radiotherapy and
- Avoid patients who for medical reasons will not be able to tolerate Trendelenburg position

5. Patient preparation

- Bowel preparation – phosphate enema for left sided operations. Bowel preparation not necessary for right sided colonic operations.

Bowel preparation is controversial in colorectal surgery. Surgeons differ in their approach. Mechanical bowel preparation results in a colon that is clear of feces. However, it can leave liquid stool in the bowel that is more likely to contaminate the operative field and the pelvis in the event of an anastomotic leak. In our experience, bowel preparation also results in small bowel distension that can make operations more difficult. The authors do not use bowel preparation for right-sided colonic resections. Two-phosphate enemas are used for left sided colorectal resections.

- low residue diet 3-4 days before operation
- 4 high calorie drinks to be taken the night before operation
- Eating and drinking normally up to 6 hours before operation
- 2 high calorie drinks to be taken up to 2 hours before operation
- Intra-operative fluids are restricted to 500 mL per hour as tolerated by the patient. This minimizes the risk of edema of the face and neck that can occur due to the steep Trendelenburg position and excessive fluids. Goal directed therapy is the standard approach using esophageal Doppler.

6. Operating room configuration

The floor plan for equipment and personnel during robotic-assisted colectomy.

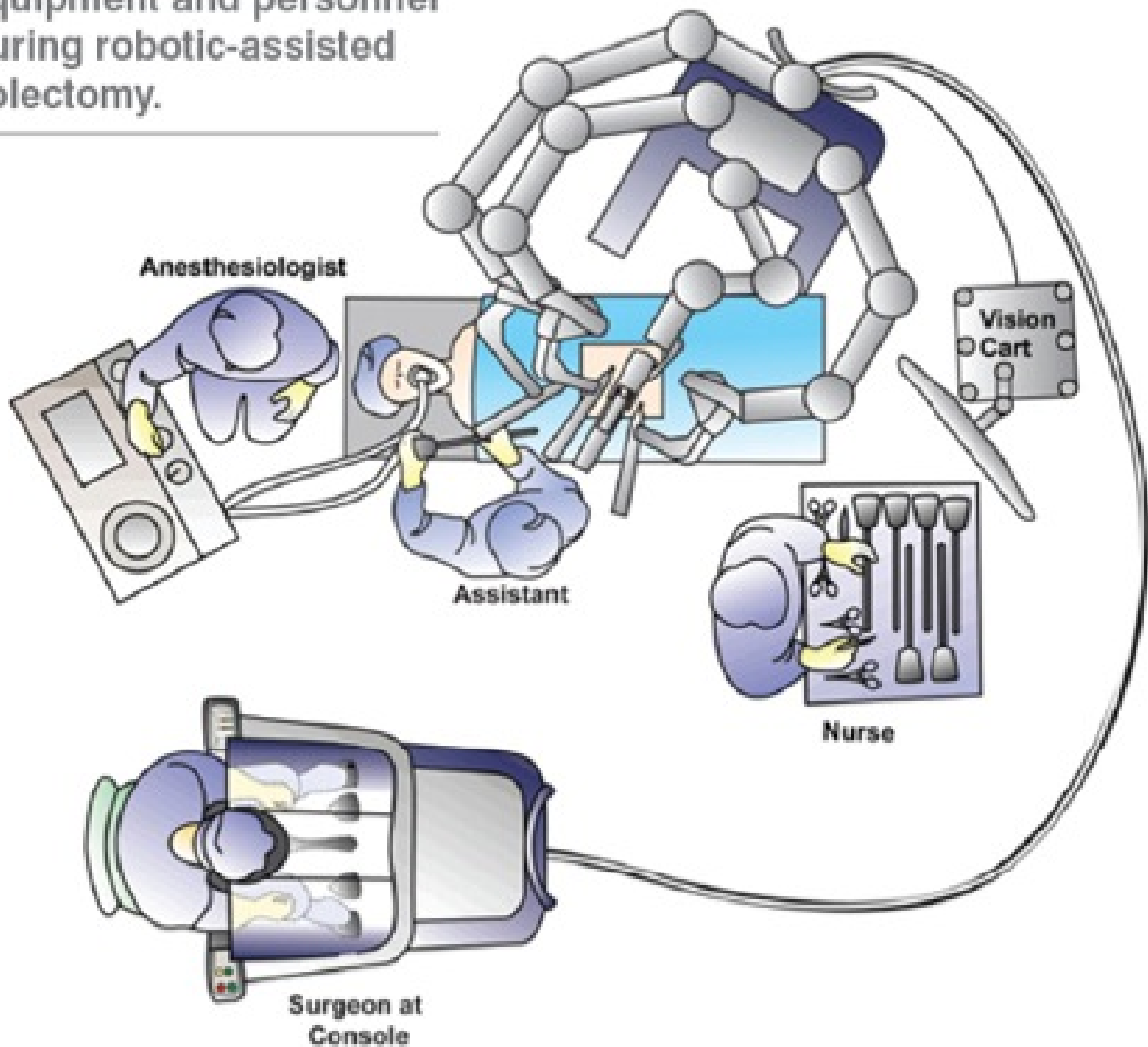


Figure 3. [53]: showing operating room set up during colectomy

7. Positioning

- Patient is positioned supine in a modified lithotomy position with legs wrapped around adjustable stirrups
- Legs are abducted and slightly flexed at the knees

- Patient's arms are wrapped alongside the body to reduce possibility of shoulder injury and additional shoulder harness can be placed to support Trendelburg's position
- Pressure points and bony prominences are padded and the body position is secured with vacuum-mattress device, especially lateral on the right side.
- Secure the patient to the table to avoid any shifting with the Trendelenburg position.
- Patient is tilted right side down and adjust the angle during initial exposure
- A body warmer (bear hugger) is applied to prevent patient hypothermia.
- Sequential compression devices (Flowtrons) are applied to the legs for DVT prophylaxis.
- After positioning, padding, securing and preparing the patient in the supine position, the table is then placed in a Trendelenburg position, whereby the steepness should be adjusted as per exposure needs during the initial exposure step.

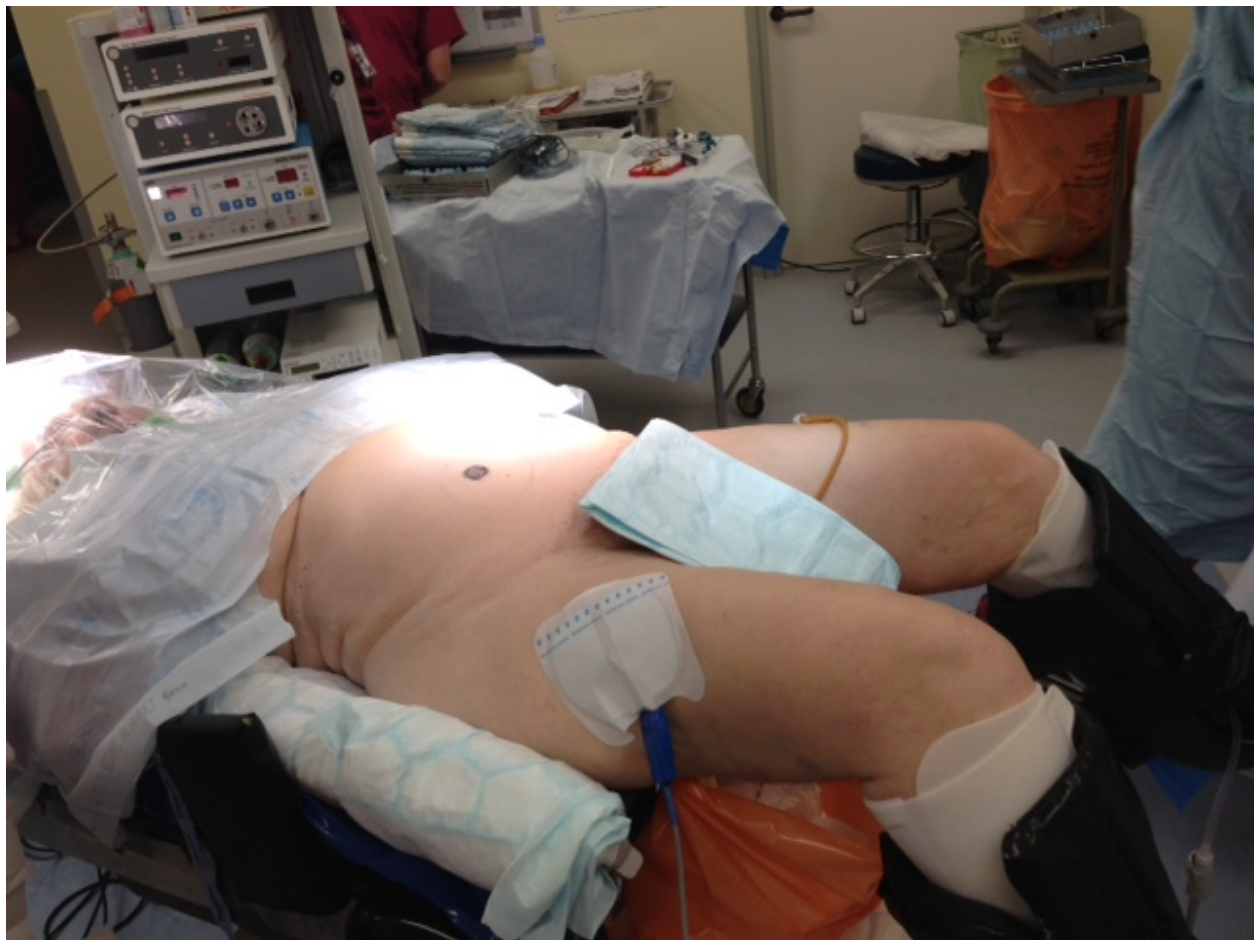

Image 1. Showing positioning of patient

8. Right-sided operations

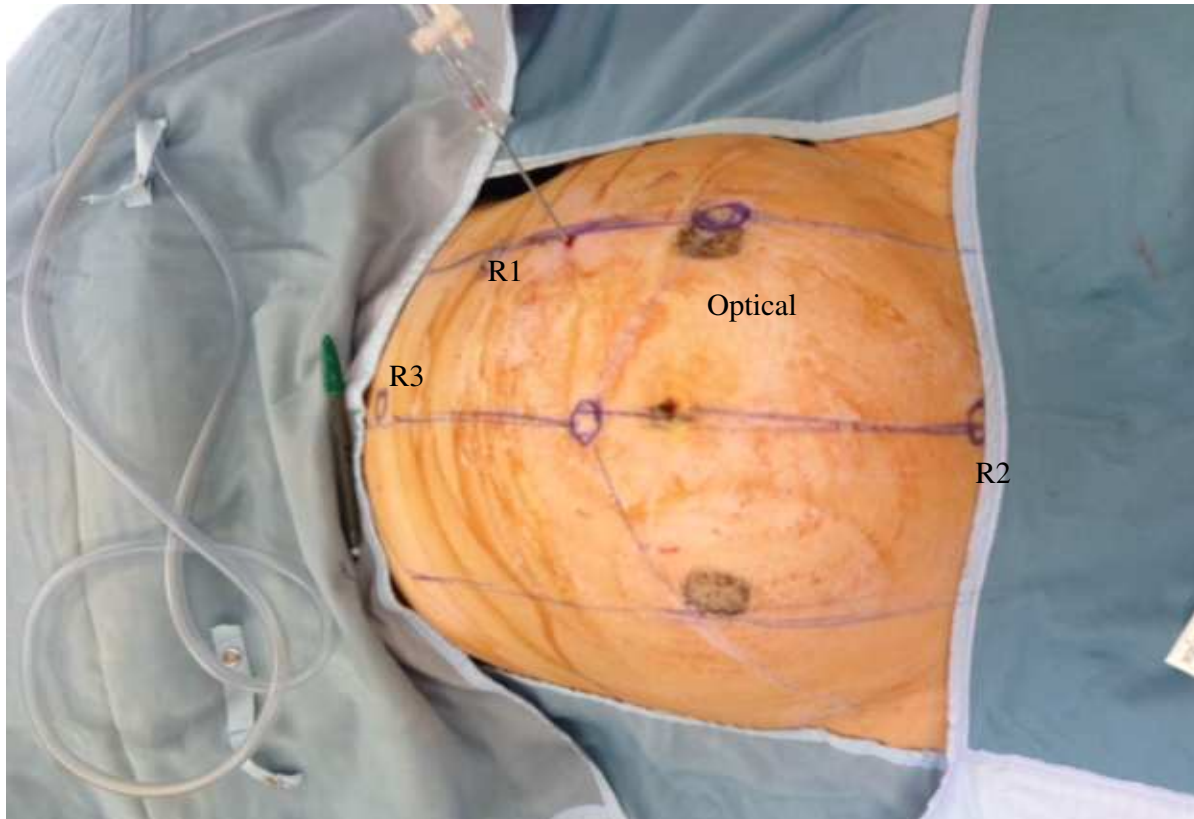


Image 2. Showing marking for Right Colonic resections. Insufflation via Veress needle at LUQ.

9. Port placements

9.1. Preparing for port placement

- Port placement is the key for a successful robotic procedure. Narrow space between the ports will result in clashing of the arms and poor ergonomics. We recommend marking of the abdomen for port placement after CO₂ insufflation.
- The initial pneumoperitoneum can be established with a Veress needle or Hassan's technique at LUQ or at camera port site.
- Initial assessment of entire anatomy of the abdomen focusing on adhesions, peritoneal seedlings and liver metastasis is carried out once the camera port is inserted. Place remaining ports under endoscopic vision avoiding injury to the inferior epigastric vessels.

9.2. Instrument port placements for left sided colorectal operations [54]

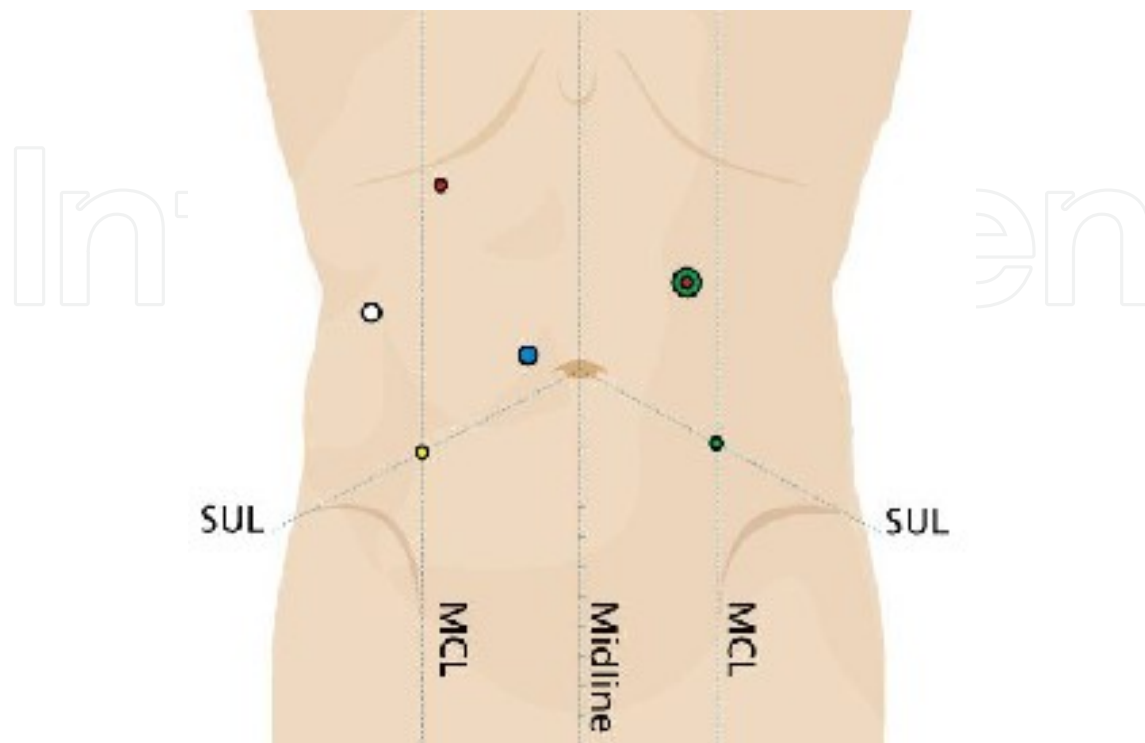


Diagram 1 Showing post placements for left sided colorectal operations

- **Robotic camera port, 12 mm (Blue):** Place the port 3-4 cm right and 3-4 cm above umbilicus. Distance to symphysis pubis should be ~22-24 cm.
- **Robotic instrument arm port, 8 mm (Yellow):** Place the port a minimum of 8 cm from the camera port, on the right spinoumbilical line (SUL) at the crossing of the mid-clavicular line (MCL). Distance to symphysis pubis should be ~14-16 cm. Linear stapler can be used from this port.
- **Robotic instrument arm port, 8 mm (Green):** Place the port a minimum of 8 cm from the camera port, on the left spinoumbilical line (SUL) at the crossing of the mid-clavicular line (MCL). The distance to the symphysis pubis should be ~14-16 cm.
- **Robotic instrument arm port, 8 mm (Red):** Place the port ~ 3 cm sub-xyphoid and ~ 2 cm medial to the right MCL
- **Robotic instrument arm port, 8 mm (Green-Red):** Place the port 7-8 cm below the left costal margin, slightly medial to the left MCL. Place the port a minimum of 8 cm from the other instrument ports and the camera port.
- **Assistant port, 5 mm (White):** Place the port 8-10 cm cephalad to the instrument arm port and ~ 4 cm lateral to the right MCL (a minimum of 8 cm from the camera port). This port is used for suction/irrigation, ligation and retraction.

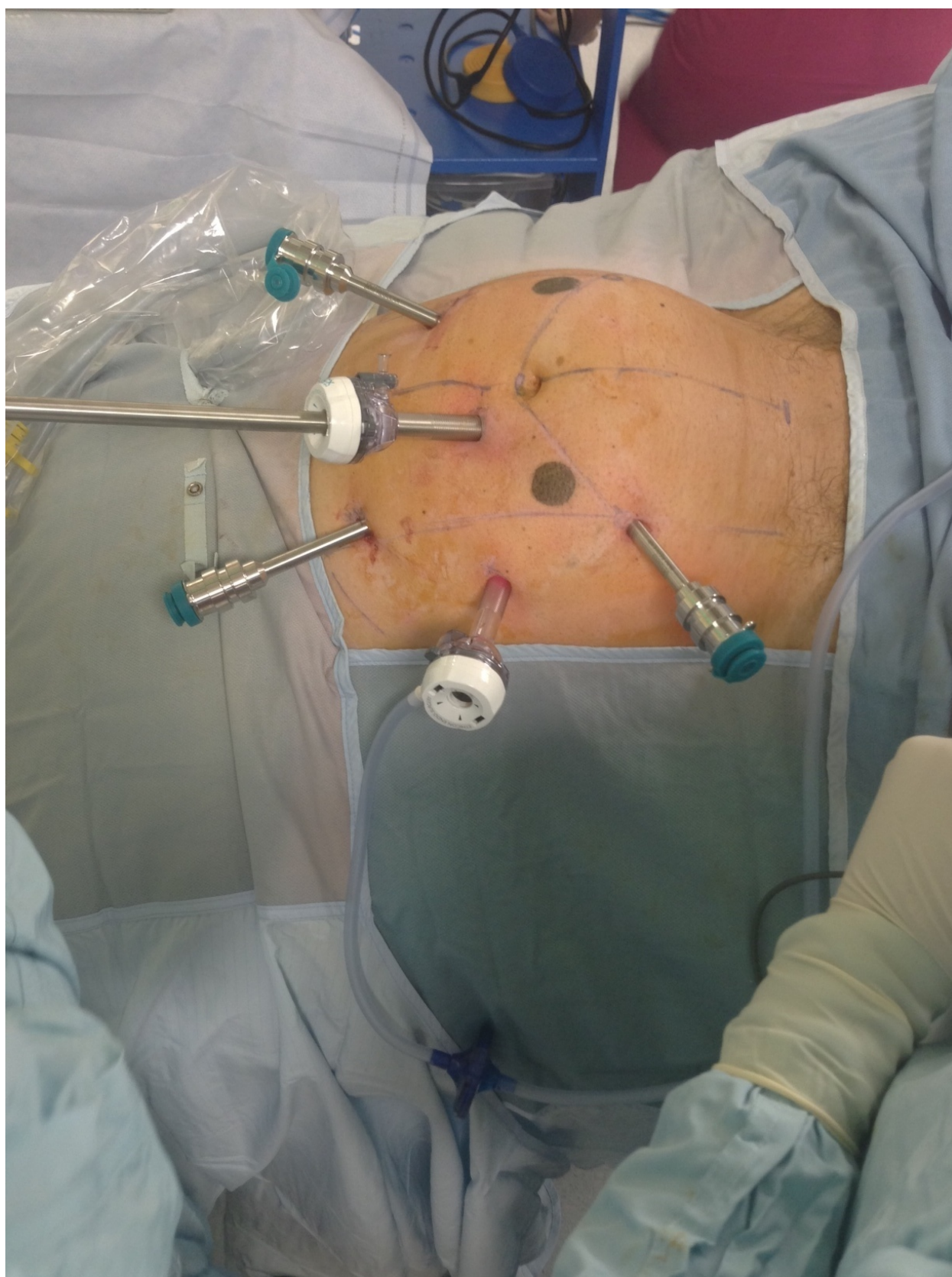


Image 3. Showing port placements for left sided colorectal operations

9.3. Port placement for right sided colonic resections

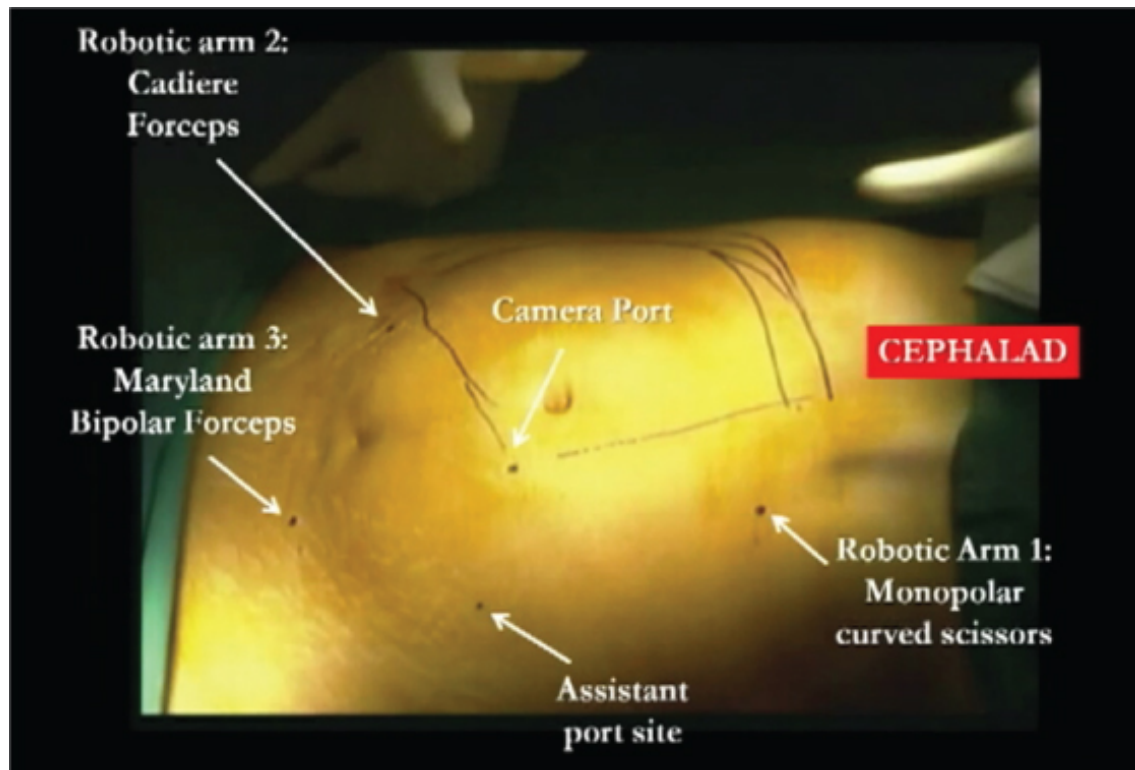


Image 4. [74]: showing port placements for right sided colonic resections

9.4. Instrument port placements for right sided colorectal operations

- Camera port 12mm, at left spinoumbilical line (SUL)
- Robotic arm port 1, 8mm, at left mid-clavicular line (MCL) 8cms below costal margin
- Robotic arm port 2, 8mm, is placed in at right SUL 2cms lateral to right MCL
- Robotic arm port 3, 8mm, is placed in midline 3 cms from pubic symphysis
- Assistant port, 5mm, place at LIF lateral to left MCL

9.5. Operative steps for left sided colorectal operations

- Initial exposure is acquired by cephalad retraction of the omentum to expose the transverse colon and by moving the small bowel out of the pelvis. Loops of small bowel can be stacked in the right upper quadrant to expose the Inferior Mesenteric Vein (IMV). A small swab placed against the small bowel loops can sometimes help by preventing the bowel from slipping into the operative area.
- Primary vascular control is achieved by ligating the Inferior Mesenteric Artery (IMA) and IMV earlier in the operation. Disposable locking clips are used to secure these vessels before division.

- Medial to lateral mobilization of sigmoid and descending colon is carried out towards the left sidewall and superiorly towards the spleen. The plane between mesocolon and Gerota's fascia is developed. Left ureter and gonadal vessels should be identified at this stage.
- Splenic flexure mobilization (SFM) is not mandatory. However, if the anastomosis is likely to be at tension, SFM is strongly recommended. If SFM is needed, IMV is divided high and the plane above the pancreas is developed which can lead the surgeon into the lesser sac. Gastrocolic omental division from above can complete this step safely.
- Rectal dissection and division – Total Mesorectal Excision (TME) is carried out to the pelvic floor for a mid to low rectal cancer or to the peritoneal reflection for an upper rectal cancer. Great care is taken to avoid injury to the parasympathetic nerves.
- Anastomosis - Rectal division and anastomosis is performed using surgical staplers. Care should be taken not to damage the pelvic floor at this stage. For rectal division, stapler can be inserted through the assistant port or the R1 can be disabled and undocked and the port changed to a 12 mm port to allow the stapler to pass through. In patients with a very narrow pelvis, a supra-pubic port can be used to divide the rectum anteroposteriorly. We perform a routine flexible sigmoidoscopy to check for anastomotic bleeding, viability of the colon and rectum and at the same time perform a leak test to check for anastomotic leak.

9.6. Operative steps for right sided colonic resections

- The patient is positioned in modified Lloyd –Davis position with slight Trendelenberg tilt. The ileocolic and Superior Mesenteric Artery (SMA) pedicles are exposed by retraction of the small bowel and appropriate traction and counter traction on the mesentery. Dissection along the Superior Mesenteric Vein (SMV) will expose the ileocolic vein and artery that are then divided after clipping. Duodenum is identified early and dissection carried out towards the liver to enter the lesser sac.
- Lateral to medial mobilization allows the right colon to be freed up. Sub ileal dissection completes this dissection allowing the whole specimen to come to the midline. Gastrocolic omental division results in complete mobilization of the hepatic flexure.
- Ileocolic anastomosis can be performed intra or extra corporeally depending upon the surgeons preference. Specimen is extracted either through a midline or suprapubic incision.

9.7. Post-operative management — (Enhanced Recovery Programme [55])

Day of operation:

- Pain management with epidural followed by PCA and then oral/IV/IM analgesia
- Post-operatively the patients are transferred to Surgical High Care for close monitoring
- All patients should have DVT (unless contraindicated) and antibiotic prophylaxis
- Patients encouraged to sit out of bed and encouraged to drink straight after the operation including 2 protein drinks

First post-operative day:

- The patient will have an epidural and urinary catheter
- Will be encouraged to drink 2 litres of fluid and drink 4 high protein drinks
- Will be encouraged to eat normal food
- Will be encouraged out of bed for 8 hours and take 3 walks of 50 meters each with help from the physiotherapists

Second post-operative day:

- Epidural and urinary catheter removed. Pain management using PCA.
- Will be encouraged to drink 2 litres of fluid and drink 4 high protein drinks
- Will be encouraged to eat normal food
- Will be encouraged out of bed for 8 hours and take 3 walks of 50 meters each with help from the physiotherapists

Post-operative days 3-5:

- The patient is discharged from the hospital if stable in three to five days i.e. passed flatus and or opening bowels
- Pain controlled with oral medications
- Able to mobilize and physiotherapists happy with progress

Outpatient follow-up:

- Follow up at OPD 2-3 weeks post-operatively
- All Cancer patients are discussed at Multidisciplinary Team Meeting, regarding additional therapy or adjuvant radiation with or without chemotherapy as indicated.

10. Future developments**10.1. Role of ICG in bowel anastomosis and lymph node mapping using da Vinci robot**

Indocyanine green (ICG) is a cyanine fluorescent dye that absorbs near infrared wavelengths of light. It binds to plasma proteins and travels in the vascular system [56]. ICG emits an infrared signal when excited by laser light *in situ*, which can be detected with near-infrared fluorescence camera system (NIRF) [57].

The image from NIRF gives visual assessment of blood vessels, blood flow, and tissue perfusion. ICG has been widely used by the ophthalmologists to visualise retinal blood vessels [58] and the technique has been amalgamated into the da Vinci Si robotic system.

Water soluble ICG can be given intravenously during surgical procedure. The surgeon is able switch into fluorescence imaging modes from normal white light mode by pressing pedals in

the console and is able to view infrared images of blood flow in the microvasculature as well as tissue perfusion in real time. This is particularly useful during bowel anastomosis and improving patient outcomes [59].

Lymph nodes harvesting can be a difficult procedure to perform in cancer surgery.

The use of ICG is an attractive method to facilitate visualisation of lymphatic vessels, sentinel nodes, and metastatic lymph nodes. It was first introduced by Lim and Soter [60].

ICG has been used in the recent past to harvest lymphnodes for cutaneous rectal carcinoma metastasis [61] and cutaneous Kaposi's sarcoma [62] with successful outcome.

It has also been used in transcutaneous Sentinel Lymph Node detection in vulvar cancer patients [63] and for identification of lymphatic pathway involved in the spreading of prostate cancer [64].

10.2. Robotic Single Incision Laparoscopic Surgery (SILS) or Colectomy (SILC)

Single incision laparoscopic colectomy (SILC) is well established. SILC is associated with shorter post-operative length of hospital stay and smaller skin incision. There is no difference in operating time or in conversion rate when compared to multiport laparoscopic colorectal operations [65]. The main drawback with SILC is exposure, conflict of instruments, ease of instrumentation, camera operation and ergonomics [66].

Robotic single incision laparoscopic surgery may be the answer to some of the problems associated with SILC. The author believes that robotic single incision colectomy will result in less abdominal wall trauma, less pain, needing fewer analgesics, early mobilisation and decreased length of hospital stay. It will have better cosmetic result due to fewer numbers of incisions. There is good evidence to suggest that multiple laparoscopic port incisions can cause port site hernias even with 5mm ports [67, 68].

Early experience with robotic SILC performing right hemicolectomy is safe and feasible [69]. We need more studies to validate robotic SILC for left sided operations.

Other surgical specialties where robotic SILS is gaining interest are listed below:

- Spinioglio G et al mentioned that it took them less time to perform robotic single port laparoscopic cholecystectomies than laparoscopic SILS [70].
- Robotic single-port trans-umbilical total hysterectomy is technically feasible in selected patients with gynaecological disease [71].
- Hahn Tran et al have successfully performed robotic single-port inguinal hernia repair without any complications [72].
- The authors believe that robots will also play a role in natural orifice endoscopic surgery and specimen retrieval via the natural orifice in the near future

The perfect robotic platform should have a low external profile, which can be deployed through a single access site. It should be able to restore intra-abdominal triangulation while

maintaining the maximum degree of freedom for accurate maneuvers and strength for reliable traction. Several purpose-built robotic prototypes for single-port surgery are being tested [73].

The author believes that robots will also play a role in natural orifice endoscopic surgery and specimen retrieval via the natural orifice in the near future.

11. Summary

In summary the developments of surgical robotics over the last decade has been very exciting. The technology is improving rapidly. Robots certainly allow the surgeons to perform better operations with improved safety. In colorectal surgery robotics will find its place in pelvic and rectal cancer surgery. The cost of instruments and the system are the biggest barrier to the widespread uptake of robotic surgery by the surgical community. The future applications of this technology may result in further benefits that will offset the cost issue.

Author details

Ray Swayamjyoti, Jim Khan and Amjad Parvaiz

Portsmouth Hospitals NHS Trust, Queen Alexandra Hospital, Portsmouth, UK

References

- [1] Ewing DR, Pigazzi A, Wang Y, Ballantyne GH. Robots in the operating room--the history. *Semin Laparosc Surg.* 2004 Jun;11(2):63-71.
- [2] Valero R, Ko YH et al Robotic surgery: history and teaching impact. *Actas Urol Esp.* 2011 Oct;35(9):540-5. doi: 10.1016/j.acuro.2011.04.005. Epub 2011 Jun 22.
- [3] Dharia SP, Falcone T. Robotics in reproductive medicine. *Fertil Steril* 2005; 84: 1–11. 4)
- [4] Prem N Kakar, Jyotirmoy Das, Preeti Mittal Roy, and Vijaya Pant Robotic invasion of operation theatre and associated anaesthetic issues: A review *Indian J Anaesth.* 2011 Jan-Feb; 55(1): 18–25. doi: 10.4103/0019-5049.76577
- [5] Satava R, Richard M. Surgical robotics: The early chronicles: A personal historical perspective. *Surg Laparosc Endosc Percutan Tech.* 2002;12:6–16.

- [6] Robot-assisted right colectomy: surgical technique and review of the literature Wojciech Witkiewicz, Marek Zawadzki, Marek Rząca, Zbigniew Obuszko, Videosurgery Miniinv 2013; 8 (3): 253–257 DOI:10.5114/wiitm.2011.33761
- [7] Kwoh YS, Hou J, Jonckheere EA, Hayati S. A robot with improved absolute positioning accuracy for CT guided stereotactic brain surgery. IEEE Trans Biomed Eng 1988; 35: 153–60.
- [8] <http://www.robot.md/publications/robodoc-surgical-robot-sucess-story.pdf>
- [9] McConnell, PI; Schneeberger, EW; Michler, RE (2003). "History and development of robotic cardiac surgery". Problems in General Surgery 20 (2): 20–30.
- [10] http://biomed.brown.edu/Courses/BI108/BI108_2000_Groups/Heart_Surgery/Robotics.html Biomed.brown.edu. Retrieved 13/11/2013
- [11] http://en.wikipedia.org/wiki/Da_Vinci_Surgical_System
- [12] Marescaux J, Smith MK, Foelscher D, Jamali F, Malassagne B, Leroy J. Telerobotic laparoscopic cholecystectomy: initial clinical experience with 25 patients. Ann Surg 2001;234:1-7.
- [13] Robotic Colorectal Surgery: A Systematic Review, Sami AlAsari and Byung Soh Min, *ISRN Surg.* 2012; 2012: 293894. Published online 2012 May 13. doi: 10.5402/2012/293894
- [14] Robotic gastrointestinal surgery: early experience and system description. Talamini M, Campbell K, Stanfield C. *J Laparoendosc Adv Surg Tech A.* 2002 Aug;12(4):225-32.
- [15] <http://www.engadget.com/2006/05/19/robot-surgeon-performs-worlds-first-unassisted-operation/>
- [16] <http://www.roboticinfertility.com/main.html>
- [17] <http://www.ucalgary.ca/news/may2008/neuroArm>
- [18] Hagn, U., Nickl, M., Jörg, S., Tobergte, A., Kübler, B., Passig, G., Gröger, M., Fröhlich, F., Seibold, U., Konietzschke, R., Le-Tien, L., Albu-Schäffer, A., Grebenstein, M., Ortmaier, T. & Hirzinger, G. (2008). "DLR MiroSurge – towards versatility in surgical robotics". Proceedings of CURAC 7: 143–146.
- [19] http://w3.wtb.tue.nl/nl/nieuws/artikel/?tx_ttnews%5Btt_news%5D=10041&tx_ttnews%5BbackPid%5D=465&cHash=ebb243e7ff
- [20] http://med.over.net/clanek/php?full=1&id=25545&title=V_UKC_Ljubljana_prvi__na_svetu_uporabili__ilnega_robota_za_posege_na_femoralnem__ilju#.UoN3TaWc9MI
- [21] <http://www.smartplanet.com/blog/smart-takes/worlds-first-all-robotic-surgery-performed-in-canada/>

- [22] Melvin, W. S.; Needleman, B. J.; Krause, K. R.; Ellison, E. C. (February 2003). "Robotic Resection of Pancreatic Neuroendocrine Tumor". *Journal of Laparoendoscopic & Advanced Surgical Techniques* 13 (1): 33–36. doi:10.1089/109264203321235449.
- [23] Babbage Science and technology (18 January 2012). "Surgical robots: The kindness of strangers" (<http://www.economist.com/blogs/babbage/2012/01/surgical-robots>). *The Economist*. Retrieved 21 February 2013.
- [24] "da Vinci Products FAQ" (http://www.intuitivesurgical.com/products/products_faq.html#18). Intuitive Surgical. Retrieved 21 February 2013.
- [25] http://intuitivesurgical.com/company/media/images/davinci_si_images.html
- [26] http://intuitivesurgical.com/company/media/images/systems-si/Si_0185_%20two_male_surgeons_lookin_in_sm.jpg
- [27] Weber PA, Merola S, Wasielewski A, Ballantyne GH, Delaney CP. Telerobotic-assisted laparoscopic right and sigmoid colectomies for benign disease. *Diseases of the Colon and Rectum*. 2002; 45(12):1689–1696.
- [28] Robot-assisted laparoscopic surgery of the colon and rectum. Antoniou SA, Antoniou GA, Koch OO, Pointner R, Granderath FA. *Surg Endosc*. 2012 Jan;26(1):1-11. doi: 10.1007/s00464-011-1867-y. Epub 2011 Aug 20.
- [29] Improved perioperative and short-term outcomes of robotic versus conventional laparoscopic colorectal operations. Casillas MA Jr, Leichtle SW, Wahl WL, Lampman RM, Welch KB, Wellock T, Madden EB, Cleary RK. *Am J Surg*. 2013 Oct 23. pii: S0002-9610(13)00608-9. doi: 10.1016/j.amjsurg.2013.08.028.
- [30] Long-term outcome of robotic assisted laparoscopic rectopexy for full-thickness rectal prolapse in elderly patients. Germain A, Perrenot C, Scherrer ML, Ayav C, Brunaud L, Ayav A, Bresler L. *Colorectal Dis*. 2013 Dec 5. doi: 10.1111/codi.12513.
- [31] Attaining Surgical Competency and Its Implications in Surgical Clinical Trial Design: A Systematic Review of the Learning Curve in Laparoscopic and Robot-Assisted Laparoscopic Colorectal Cancer Surgery. Barrie J, Jayne DG, Wright J, Murray CJ, Collinson FJ, Pavitt SH. *Ann Surg Oncol*. 2013 Nov 12.
- [32] The first nationwide evaluation of robotic general surgery: a regionalized, small but safe start. Wormer BA, Dacey KT, Williams KB, Bradley JF 3rd, Walters AL, Augenstein VA, Stefanidis D, Heniford BT. *Surg Endosc*. 2013 Nov 7.
- [33] Wittich P, Kazemier G, Schouten WR, Jeekel J, Lange JF, Bonjer HJ. The 'Colon cancer laparoscopic or open resection' (COLOR) trial. *Ned Tijdschr Geneesk*. 1997 Sep 27;141(39):1870-1. 34)
- [34] Bonjer, H. J., et al. "Laparoscopically assisted versus open colectomy for colon cancer: a meta-analysis." *Arch Surg* 142 (2007): 298-303.

- [35] Nelson H, Sargent DJ, Wieand HS, et al. A comparison of laparoscopically assisted and open colectomy for colon cancer. *New England Journal of Medicine*. 2004;350(20): 2050–2059.
- [36] Jayne DG et al. *J Clin Oncol* 2007; 25: 3061-8.
- [37] <http://www.eme.ac.uk/projectfiles/085201protocol.pdf>
- [38] Jayne DG, Guillou PJ, Thorpe H, et al. Randomized trial of laparoscopic-assisted resection of colorectal carcinoma: 3-Year results of the UK MRC CLASICC trial group. *Journal of Clinical Oncology*. 2007;25(21):3061–3068.
- [39] 8. Jayne DG et al. *Br J Surg*. 2005; 92: 1124-32.
- [40] Schwab KE, Dowson HM, Van Dellen J, Marks CG, Rockall TA. The uptake of laparoscopic colorectal surgery in Great Britain and Ireland: a questionnaire survey of consultant members of the ACPGBI. *Colorectal Disease*. 2009;11(3):318–322.
- [41] Neutel CI, Gao RN, Wai E, Gaudette LA. Trends in in-patient hospital utilization and surgical procedures for breast, prostate, lung and colorectal cancers in Canada. *Cancer Causes and Control*. 2005;16(10):1261–1270.
- [42] Sung-Bum Kang, et al. Open versus laparoscopic surgery for mid or low rectal cancer after neoadjuvant chemoradiotherapy (COREAN trial): short-term outcomes of an open-label randomised controlled trial. *Lancet Oncol*. 2010;11:637–45. doi: 10.1016/S1470-2045(10)70131-5.
- [43] Paolo Pietro Bianchi, Fabrizio Luca, Wanda Petz, Manuela Valvo, Sabine Cenciarelli, Massimiliano Zuccaro, and Roberto Biffi, The role of the robotic technique in minimally invasive surgery in rectal cancer, *Ecancermedicalscience*. 2013; 7: 357. Published online 2013 September 26. doi: 10.3332/ecancer.2013.357
- [44] Malak B. Bokhari, Chirag B. Patel, Diego I. Ramos-Valadez, Madhu Ragupathi, and Eric M. Haas, Learning curve for robotic-assisted laparoscopic colorectal surgery, *Surg Endosc*. 2011 March; 25(3): 855–860. Published online 2010 August 24. doi: 10.1007/s00464-010-1281-x
- [45] Jiménez-Rodríguez RM, Díaz-Pavón JM, de la Portilla de Juan F, Prendes-Sillero E, Dussort HC, Padillo J. Learning curve for robotic-assisted laparoscopic rectal cancer surgery. *Int J Colorectal Dis*. 2013 Jun;28(6):815-21. doi: 10.1007/s00384-012-1620-6. Epub 2012 Dec 15.
- [46] Sng KK, Hara M, Shin JW, Yoo BE, Yang KS, Kim SH. The multiphasic learning curve for robot-assisted rectal surgery. *Surg Endosc*. 2013 Sep;27(9):3297-307. doi: 10.1007/s00464-013-2909-4. Epub 2013 Mar 19.
- [47] Halabi WJ, Kang CY, Jafari MD, Nguyen VQ, Carmichael JC, Mills S, Stamos MJ, Pigazzi A, Robot-assisted laparoscopic colorectal surgery. Alimoglu O, Atak I, Orhun K, Eren

- T, *Minerva Chirurgica*, October 2013, vol./is. 68/5(471-8), 0026-4733;0026-4733 (2013 Oct)
- [48] Robotic-assisted Colorectal Surgery in the United States: A Nationwide Analysis of Trends and Outcomes. *World Journal of Surgery*, 12 2013, vol./is. 37/12(2782-90), 0364-2313;1432-2323 (2013 Dec)
- [49] Kim CW, Baik SH, Robotic rectal surgery: what are the benefits?. *Minerva Chirurgica*, October 2013, vol./is. 68/5(457-69), 0026-4733;0026-4733 (2013 Oct)
- [50] Deborah S. Keller, Lobat Hashemi, Minyi Lu, and Conor P. Delaney, Short-Term Outcomes for Robotic Colorectal Surgery by Provider Volume, *Journal of the American College of Surgeons*, 2013-12-01, Volume 217, Issue 6, Pages 1063-1069.e1
- [51] Bertani E, Chiappa A, Ubiali P, Cossu ML, Arnone P, Andreoni B, Robotic colectomy: is it necessary?, *Minerva Chirurgica*, October 2013, vol./is. 68/5(445-56), 0026-4733;0026-4733 (2013 Oct)
- [52] http://www.gastroendonews.com/ViewArticle.aspx?d_id=187&a_id=13617
- [53] <https://www.davincisurgerycommunity.com/>
- [54] <http://www.colorectal-surgeon.com/enhanced-recovery-programme.htm>
- [55] <http://www.cancer.gov/>
- [56] Jarmo T. Alander, Ilkka Kaartinen, Aki Laakso, Tommi Pätälä, Thomas Spillmann, Valery V. Tuchin, Maarit Venermo, and Petri Välisuo, A Review of Indocyanine Green Fluorescent Imaging in Surgery. *Int J Biomed Imaging*. 2012; 2012: 940585. Published online 2012 April 22. doi: 10.1155/2012/940585
- [57] Flower RW. Injection technique for indocyanine green and sodium fluorescein dye angiography of the eye. *Investigative Ophthalmology*. 1973;12(12):881–895.
- [58] Bae, Se Jin Baek, Hyuk Hur, Seung Hyuk Baik, Nam Kyu Kim, and Byung Soh Min, Intraoperative Near Infrared Fluorescence Imaging in Robotic Low Anterior Resection: Three Case Reports *Sung Uk, Yonsei Med J*. 2013 July 1; 54(4): 1066–1069. Published online 2013 May 14. doi: 10.3349/ymj.2013.54.4.1066
- [59] Lim H, Soter N. *Clinical Photomedicine*. New York, NY, USA: Marcel Dekker Inc.; 1993.
- [60] Karrer S, Abels C, Bäuml W, Steinbauer M, Landthaler M, Szeimies RM. Photochemotherapie von kutanen Rektumkarzinom- Metastasen mit Indocyaningrün [photochemotherapy with indocyanine green in cutaneous metastases of rectal carcinoma] *Deutsche medizinische Wochenschrift*. 1997;122(37):1111–1114.
- [61] Abels C, Karrer S, Bäuml W, Goetz AE, Landthaler M, Szeimies R-M. Indocyanine green and laser light for the treatment of AIDS-associated cutaneous Kaposi's sarcoma. *British Journal of Cancer*. 1998;77(6):1021–1024.

- [62] Crane LMA, Themelis G, Arts HJG, et al. Intraoperative near-infrared fluorescence imaging for sentinel lymph node detection in vulvar cancer: first clinical results. *Gynecologic Oncology*. 2011;120(2):291–295.
- [63] Inoue S, Shiina H, Arichi N, et al. Identification of lymphatic pathway involved in the spreading of prostate cancer by fluorescence navigation approach with intraoperatively injected indocyanine green. *Journal of the Canadian Urological Association*. 2011;5(4):254–259.
- [64] Maggiori L, Gaujoux S, Tribillon E, Bretagnol F, Panis Y., Single-incision laparoscopy for colorectal resection: a systematic review and meta-analysis of more than a thousand procedures. *Colorectal Dis*. 2012 Oct;14(10):e643–54. doi: 10.1111/j.1463-1318.2012.03105.x.
- [65] Ross H, Steele S, Whiteford M, Lee S, Albert M, Mutch M, Rivadeneira D, Marcello P. Early multi-institution experience with single-incision laparoscopic colectomy. *Dis Colon Rectum*. 2011 Feb;54(2):187–92. doi: 10.1007/DCR.0b013e3181f8d972.
- [66] Khurshid N, Chung M, Horrigan T, Manahan K, Geisler JP., 5-millimeter trocar-site bowel herniation following laparoscopic surgery. *JLS*. 2012 Apr-Jun;16(2):306–10.
- [67] Yamamoto M, Minikel L, Zaritsky E., Laparoscopic 5-mm trocar site herniation and literature review. *JLS*. 2011 Jan-Mar;15(1):122–6. doi: 10.4293/108680811X13022985131697.
- [68] Ostrowitz MB, Eschete D, Zemon H, DeNoto G., Robotic-assisted single-incision right colectomy: early experience. *Int J Med Robot*. 2009 Dec;5(4):465–70. doi: 10.1002/rcs.281.
- [69] Spinoglio G, Lenti LM, Maglione V, Lucido FS, Priora F, Bianchi PP, Single-site robotic cholecystectomy (SSRC) versus single-incision laparoscopic cholecystectomy (SILC): comparison of learning curves. First European experience., Grosso F, Quarati R. *Surg Endosc*. 2012 Jun;26(6):1648–55. doi: 10.1007/s00464-011-2087-1. Epub 2011 Dec 17.
- [70] Eun Ji Nam, Sang Wun Kim, Maria Lee, Ga Won Yim et al, Robotic single-port transumbilical total hysterectomy: a pilot study, *Gynecol Oncol*. 2011 June 30; 22(2): 120–126. Published online 2011 June 30. doi: 10.3802/jgo.2011.22.2.120. PMID: PMC3152752
- [71] Hanh Tran, Robotic Single-Port Hernia Surgery, *F JLS*. 2011 Jul-Sep; 15(3): 309–314. doi: 10.4293/108680811X13125733356198. PMID: PMC3183567
- [72] Autorino R, Kaouk JH, Stolzenburg JU, Gill IS, Mottrie A, Tewari A, Cadeddu JA. Current status and future directions of robotic single-site surgery: a systematic review. *Eur Urol*. 2013 Feb;63(2):266–80. doi: 10.1016/j.eururo.2012.08.028. Epub 2012 Aug 23.

- [73] Mathew R, Kim SH. Robotic right hemicolectomy with D3 lymphadenectomy and complete mesocolic excision: Technical detail. OA Robotic Surgery 2013 Jun 01;1(1):6. <http://www.oapublishinglondon.com/article/710>,

IntechOpen

IntechOpen