

We are IntechOpen, the world's leading publisher of Open Access books Built by scientists, for scientists

6,900

Open access books available

185,000

International authors and editors

200M

Downloads

Our authors are among the

154

Countries delivered to

TOP 1%

most cited scientists

12.2%

Contributors from top 500 universities



WEB OF SCIENCE™

Selection of our books indexed in the Book Citation Index
in Web of Science™ Core Collection (BKCI)

Interested in publishing with us?
Contact book.department@intechopen.com

Numbers displayed above are based on latest data collected.
For more information visit www.intechopen.com



New Application of ^{123}I -Iodoamphetamine SPECT for the Diagnosis of Primary Central Nervous System Lymphoma

Yasushi Shibata

Additional information is available at the end of the chapter

<http://dx.doi.org/10.5772/58321>

1. Introduction

^{123}I -iodoamphetamine (IMP) single photon emission computed tomography (SPECT) is used to evaluate the cerebral blood flow (CBF) in patients with either cerebrovascular or neurodegenerative diseases [3, 6]. However, its application for patients with brain tumors has so far only been rarely reported [2, 8, 11]. Primary central nervous system lymphoma (PCNSL) is a rare tumor that shows a delayed IMP uptake [1, 5, 7, 9, 10]. The relatively low spatial resolution of SPECT is a clinical problem when it is used to diagnose brain tumors.

Anatomical standardized statistical mapping is a useful method for improving the diagnostic ability of SPECT. We examined the statistical mapping of IMP SPECT in patients with brain lesions. In this report, we analyzed the diagnostic performance of the usual reconstructed images and statistical mapping of IMP SPECT of patients with brain tumors.

2. Patients and methods

This study included IMP SPECT images for 49 patients with brain lesions: 20 with PCNSL, one with Burkitt's lymphoma, 15 with glioma, two with meningioma, one with a metastatic tumor, two with multiple sclerosis (MS), five with cerebritis and three without any pathological diagnosis, but a clinical diagnosis of PCNSL. No patients had received prior radiation or chemotherapy for brain tumors. Three patients had previously received steroid medication at the time of IMP SPECT examination.

We examined the normal reconstructed images and statistical mapping of IMP SPECT. After the intravenous injection of 222 Megabecquerel (MBq) of ^{123}I -IMP, the early (15 minutes) and delayed (3 hours) images were acquired using a multi-detector SPECT machine (E.CAM, Siemens Medical, Erlangen, Germany) and a high resolution collimator (LEHR, Siemens Medical, Erlangen, Germany). The Butterworth pre-correction filter and the Chang method were used for pre- and post-attenuation corrections. The Ramp filter was used for reconstruction. The image matrices, the pixel sizes and the slice thickness of the IMP SPECT were 128 x 128, 3.31 mm and 6.62 mm, respectively. All SPECT data were saved in the Digital Imaging and Communication in Medicine (DICOM) format. The DICOM data were transferred to a newly developed software program, the iNeurostat+ (Nihon Medi-physics, Hyogo, Japan), which runs on a Windows personal computer. The SPECT data were anatomically standardized on normal brain images. The increased uptakes of IMP were statistically mapped on the tomographic images of the normal brain. The image quality, diagnostic ability and imaging artifacts were evaluated by a visual inspection (Figure 1).

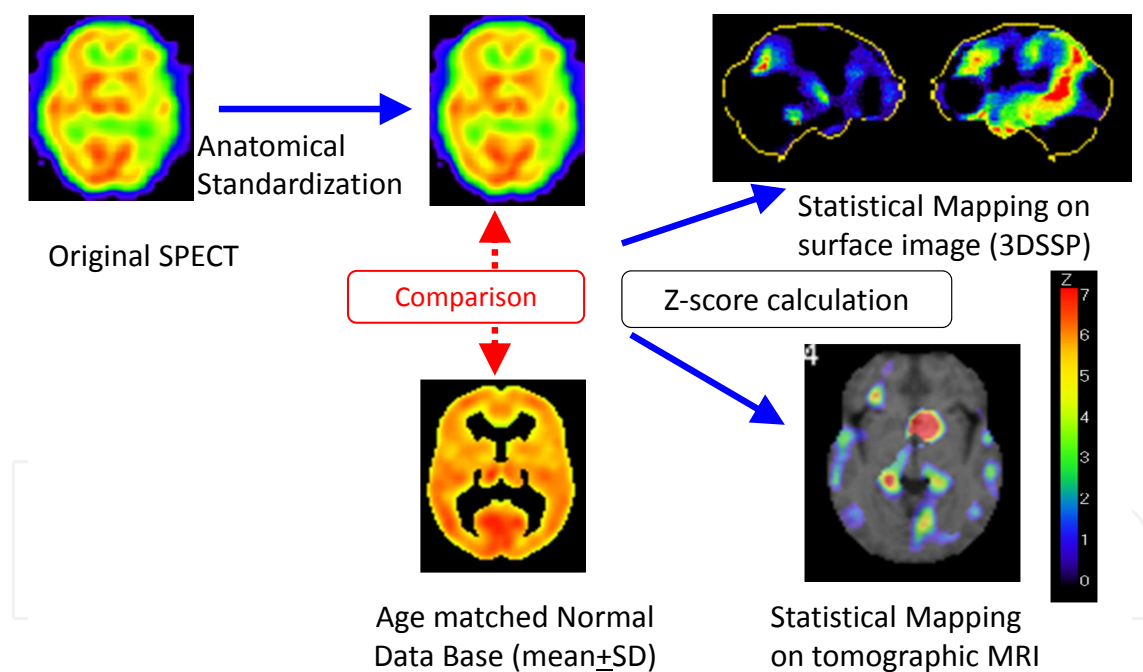


Figure 1. Automatic Process Flow of iNeurostat+

Magnetic resonance imaging (MRI) data were acquired with 1.5 Tesla instrument (Gyrosan NT Intera, Philips, Amsterdam, The Netherlands). The tumor diameters and size were measured using gadolinium-diethyltriaminepentaacetic acid (Gd-DTPA)-enhanced T1-weighted MRI.

The statistical analysis was performed with the Chi-square test. Values of $p < 0.05$ were considered to be significant.

3. Representative cases

3.1. Case 1 (Figure 2)

A 58-year-old female had a Gd-enhanced MRI scan, which showed a homogeneously enhanced tumor at the left putamen. Delayed IMP SPECT showed tumor uptake, however, other normal brain uptake was also detected. Statistical mapping of IMP SPECT data demonstrated hot tumor uptake and no uptake into the normal brain. A tumor biopsy revealed a pathological diagnosis of PCNSL.

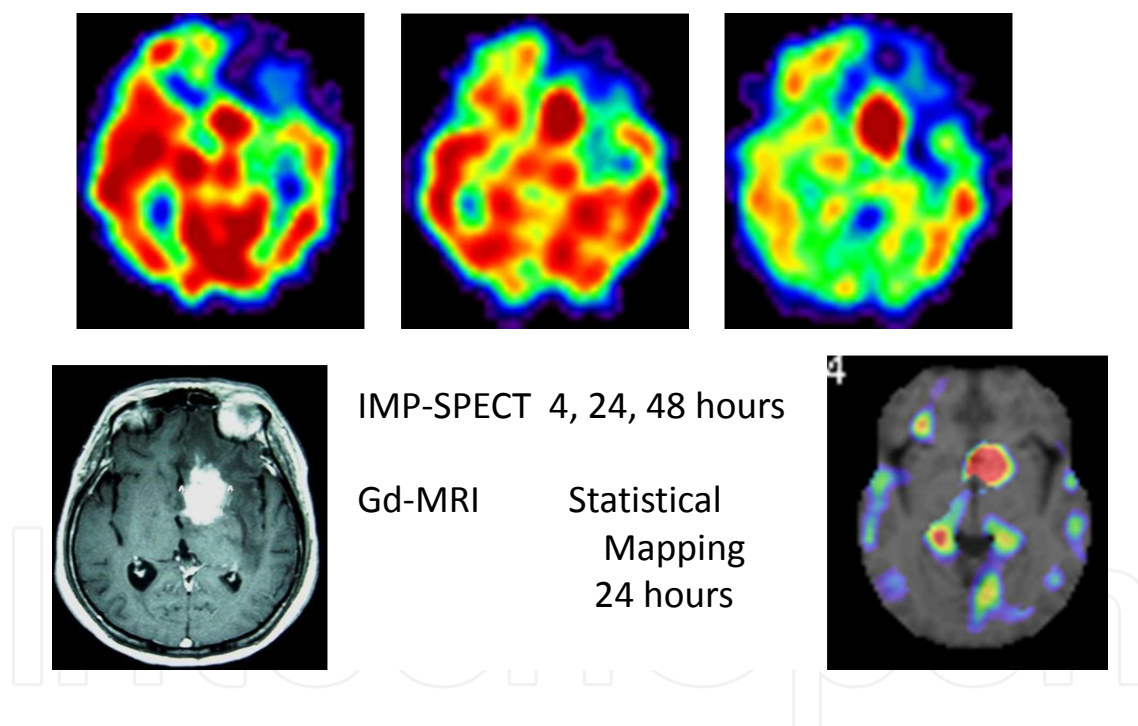


Figure 2. 58 Woman: PCNSL

3.2. Case 2 (Figure 3)

A 71-year-old female underwent a Gd-enhanced MRI scan, which showed a homogeneously enhanced tumor at the left cerebellum. Delayed IMP SPECT did not show clear uptake into the cerebellar lesion. Statistical mapping of IMP SPECT demonstrated clear uptake of IMP into the tumor. The tumor was pathologically diagnosed as PCNSL by biopsy.

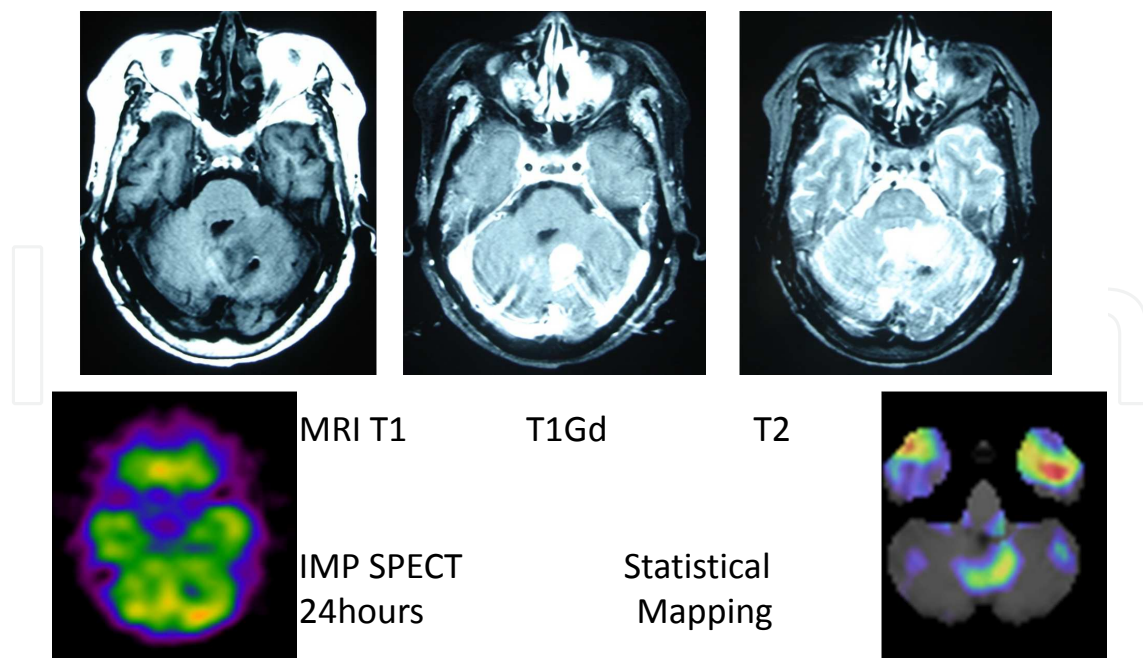


Figure 3. 71 Woman: PCNSL

4. Results

Eighteen patients showed a high uptake in the delayed IMP SPECT images (16 PCNSL, two unknown). All unknown patients were successfully treated with steroids and radiation therapy, so their clinical diagnosis was PCNSL. Other tumors or lesions did not show a high uptake on delayed IMP SPECT, so there were no false positives (Table 1). Four patients with pathologically proven PCNSL showed no uptake in the original IMP SPECT. These tumors were either too small to detect by IMP SPECT or the IMP SPECT images were taken after the administration of steroids. However, statistical mapping revealed the IMP uptake in two of these four patients. A heterogeneous IMP uptake was seen in homogenous tumors in MRI. For patients with a hot IMP uptake, statistical mapping showed clearer uptake. The sensitivity and specificity of original IMP SPECT were 80 and 100% (Chi-test $p < 0.01$), respectively. Those of statistical mapping were 90 and 100% (Chi-test $p < 0.01$), respectively.

The patients who had received steroid treatment showed negative of IMP SPECT findings. However, patients with glioma, MS and Burkitt's lymphoma did not show a high uptake of delayed IMP SPECT. IMP SPECT is therefore useful for the diagnosis of PCNSL, especially for the differentiation from glioma, MS and Burkitt's lymphoma. A heterogeneous IMP uptake was seen in homogenous tumors in MRI. For patients with a hot IMP uptake, statistical mapping showed an even clearer uptake. There were some artifacts on the statistical mapping, however, these artifacts did not result in diagnostic problems due to comparisons of the statistical mapping and original SPECT or MRI findings.

Original IMP	PCNSL	other	unknown
uptake +	16	0	2
uptake -	4	26	1

Sensitivity 80%, specificity 100%, Chi-test p<0.01

Statistical Mapping	PCNSL	other	unknown
uptake +	18	0	2
uptake -	2	26	1

Sensitivity 90%, specificity 100%, Chi-test p<0.01

5. Discussion

5.1. Sensitivity and specificity of IMP SPECT

Our results revealed a high sensitivity (80%) and high specificity (100%) of IMP SPECT in the diagnosis of PCNSL. Our IMP SPECT of 3.31 mm in pixel size could not detect one small supratentorial tumor less than 5 mm. Because our patient series included only one patient with a tumor less than 20 mm in diameter, the detection threshold could not be demonstrated. However, two cerebellar tumors more than 30 mm in diameter could be detected with the usual IMP SPECT, while two cerebellar tumors smaller than 25 mm in diameter could not be detected. Based on our results, the detection threshold of cerebellar tumors seems to be around 25 to 30 mm in diameter.

Akiyama reported that the PCNSL larger than 3 ml could be detected in delayed IMP SPECT [1]. Their patient series included some patients with brain stem tumors and no patients with cerebellar tumor. Shinoda reported the IMP SPECT findings in 10 patients with PCNSL [9]. There were two patients with cerebellar tumors in their study, but the tumor size or volume was not described.

SPECT has some physical and radiological limitations. The absorption of gamma rays in each tissue decreases the detected signal. Scattering radiation from the gamma ray source leads to low spatial resolution of the reconstructed SPECT images. The posterior fossa is covered by a thick area of the skull, so the signal from the brain stem and cerebellum is attenuated more than that from the cerebrum. Homogeneous attenuation correction could not correct for the low signal from the posterior fossa. These reasons might underlie the low sensitivity at the cerebellum. Some methods of correcting the absorption and scattering have been employed, however, all of these correction methods are associated with some limitations [4]. In our facility, the scatter was corrected with a Butterworth filter, and the absorption and attenuation were corrected with the chang method. The chang method assumes homogenous attenuation, however, the head is not homogenously attenuated. Therefore, using the Chang method leads to an overestimation of the regional CBF values in IMP SPECT in low CBF regions and an

underestimation in high CBF regions [4]. The cerebellum is a high CBF region. Therefore, the tumors at the cerebellum might be less detectable by IMP SPECT than the tumors at the brain stem.

5.2. Mechanism of IMP uptake

The mechanisms underlying the uptake and retention of IMP in PCNSL are not fully understood. The amine receptor is one of the IMP binding sites [6]. A specific amine receptor in PCNSL was hypothesized to be responsible for the IMP retention in PCNSL [10] [11]. Most IMP binding is considered to be mainly associated with high capacity, relatively nonspecific binding sites in brain synaptosomes [6]. The IMP SPECT findings suggested that there is strong IMP binding to PCNSL. In the future, the mechanisms of IMP uptake and the retention in PCNSL may be revealed by clinical and basic studies of PCNSL.

5.3. Standardization of SPECT images

The CBF is dependent on the patient age. Each patient's CBF should therefore be evaluated in comparison with a normal standardized database for specific age groups. Each patient also has different cerebral morphology. In order to compare the SPECT data of each patient with the normal standardized database, each patient's SPECT data should be transformed to fit standard SPECT data. Using the iNeurostat+ software program, a statistical evaluation of an anatomically standardized tomographic image is possible. Anatomical standardization and statistical mapping are useful methods to reduce the differences based on the individual brain morphology and to objectively evaluate the image findings.

Based on our results, the IMP uptake into PCNSL was highly specific. At present, the final definite diagnosis of PCNSL should be determined by biopsy and pathological examination. However, a biopsy is an invasive surgical procedure. Therefore, there is currently no definitive non-invasive method for diagnosing PCNSL. Some patients, such as those with tumors in the brain stem, or who are in poor general condition, are not candidates for surgical procedures. In such cases, IMP SPECT may be helpful to diagnose PCNSL without the surgical risk associated with a biopsy. Our results warrant further clinical prospective research to evaluate the clinical significance of IMP SPECT for the diagnosis of PCNSL.

The statistical mapping method was especially useful to detect small tumors that were not detected using usual IMP SPECT. Statistical mapping has the same spatial resolution as the original SPECT images. The detectability of tumors at the posterior fossa and skull base is affected by absorption and scattering corrections. Statistical mapping method reduces these affects, and as a result, improves the detectability of tumors at the posterior fossa or skull base.

Reconstructed SPECT images include some error and artifacts by nature. A statistical analysis can reduce some errors and artifacts, however, it can also lead to new errors and artifacts. In our study, some artifacts were observed in the statistical mapping results that were not seen in original SPECT images. These artifacts were recognizable as artifacts by comparing the statistical mapped images with original reconstructed SPECT images. However, it should be

kept in mind that the statistical mapping images are not original images, and should not be overrated. The final clinical evaluation should be based on careful image interpretation.

5.4. Study limitations

Our study has some limitations. The patient population was small and selected based on the criteria of suspected PCNSL. All patients with brain lesions were not included in this study. However, the patient population in this study represents the actual target population who need a differential diagnosis. Therefore, this study demonstrated the actual clinical usefulness of IMP SPECT for the differential diagnosis of PCNSL.

IMP SPECT is useful for the diagnosis of PCNSL because the uptake is specific, as shown in our results. The gold standard for the diagnosis of PCNSL is the pathological examination of surgical specimens. There is currently no definitive non-invasive diagnostic method. Because some patients with PCNSL are contraindicated for surgery, IMP SPECT may represent an alternative to biopsy for obtaining a diagnosis. Further collection of experiences and improvements of the diagnostic methods will increase the reliability and decrease the limitations of diagnostic imaging using IMP SPECT for PCNSL. In the actual clinical diagnosis of PCNSL, we generally acquire additional information from other examinations, including tumor marker levels and gallium and/or thallium scintigraphy. In our patient population, we also examined the findings by these modalities. A detailed discussion of the results of these examinations is not within the scope of this paper, but such combined evaluations may help overcome some of the limitations of IMP SPECT.

6. Conclusion

IMP-SPECT and statistical mapping are considered to be useful for the diagnosis of PCNSL. Multi-modal images should be taken before steroid therapy, because steroids affect the diagnostic performance of both of MRI and SPECT. Statistical mapping is useful for detecting small tumors which cannot be detected by usual IMP SPECT. However, some artifacts also exist in statistical mapping images. The careful interpretation of such image findings is essential. Anatomical standardized statistical mapping is thus considered a useful method for improving the diagnostic sensitivity, specificity and accuracy of IMP SPECT for brain lesions.

Author details

Yasushi Shibata*

Address all correspondence to: yshibata@md.tsukuba.ac.jp

Department of Neurosurgery, Mito Medical Center, University of Tsukuba, Mito, Ibaraki, Japan

References

- [1] Akiyama Y, Moritake K, Yamasaki T, Kimura Y, Kaneko A, Yamamoto Y, Miyazaki T, Daisu M: The diagnostic value of 123I-IMP SPECT in non-Hodgkin's lymphoma of the central nervous system. *J Nucl Med*. 41:1777-1783., 2000.
- [2] Fukahori T, Tahara T, Mihara F, Kato A, Masumoto H, Kudo S, Tsuji T, Tabuchi K: [Diagnostic value of high N-isopropyl-p-[123I] iodoamphetamine (IMP) uptake in brain tumors]. *Nippon Igaku Hoshasen Gakkai Zasshi*. 56:53-59., 1996.
- [3] Greenberg JH, Kushner M, Rango M, Alavi A, Reivich M: Validation studies of iodine-123-iodoamphetamine as a cerebral blood flow tracer using emission tomography. *J Nucl Med* 31:1364-1369, 1990.
- [4] Hayashi M, Deguchi J, Utsunomiya K, Yamada M, Komori T, Takeuchi M, Kanna K, Narabayashi I: Comparison of methods of attenuation and scatter correction in brain perfusion SPECT. *J Nucl Med Technol* 33:224-229, 2005.
- [5] Kitanaka C, Eguchi T, Kokubo T: Secondary malignant lymphoma of the central nervous system with delayed high uptake on 123I-IMP single-photon emission computerized tomography. Case report. *J Neurosurg*. 76:871-873., 1992.
- [6] Nishizawa S, Tanada S, Yonekura Y, Fujita T, Mukai T, Saji H, Fukuyama H, Miyoshi T, Harada K, Ishikawa M, Kikuchi H, Konishi J: Regional Dynamics of N-Isopropyl-(123I)p-iodo-Amphetamine in Human Brain. *J Nucl Med* 30:150-156, 1989.
- [7] Ohkawa S, Yamadori A, Mori E, Tabuchi M, Ohsumi Y, Yoshida T, Yoneda Y, Furumoto M: A case of primary malignant lymphoma of the brain with high uptake of 123I-IMP. *Neuroradiology*. 31:270-272., 1989.
- [8] Sagiuchi T, Oka H, Utsuki S, Sato K, Kobayashi I, Asano Y, Ishii K, Fujii K: Increased accumulations of N-isopropyl-p-[123I]-iodoamphetamine related to tumefactive multiple sclerosis. *Ann Nucl Med* 19:603-606, 2005.
- [9] Shinoda J, Yano H, Murase S, Yoshimura S, Sakai N, Asano T: High 123I-IMP retention on SPECT image in primary central nervous system lymphoma. *J Neurooncol*. 61:261-265., 2003.
- [10] Yamamoto Y, Nishiyama Y, Kawakita K, Toyama Y, Ohkawa M, Tanabe M: Malignant lymphoma of the central nervous system with delayed increased accumulation on I-123 IMP SPECT. *Clin Nucl Med*. 26:105-108., 2001.
- [11] Yoshikai T, Fukahori T, Ishimaru J, Kato A, Uchino A, Tabuchi K, Kudo S: 123I-IMP SPET in the diagnosis of primary central nervous system lymphoma. *Eur J Nucl Med* 28:25-32, 2001.