

We are IntechOpen, the world's leading publisher of Open Access books Built by scientists, for scientists

6,900

Open access books available

185,000

International authors and editors

200M

Downloads

Our authors are among the

154

Countries delivered to

TOP 1%

most cited scientists

12.2%

Contributors from top 500 universities



WEB OF SCIENCE™

Selection of our books indexed in the Book Citation Index
in Web of Science™ Core Collection (BKCI)

Interested in publishing with us?
Contact book.department@intechopen.com

Numbers displayed above are based on latest data collected.
For more information visit www.intechopen.com



Laparoscopic Inguinal Preperitoneal Injection (LIPI) — Novel Experimental Technique for Inguinal Hernia Repair in Children

Yury Kozlov, Vladimir Novozhilov,
Vitaly Kovalev and Pavel Krasnov

Additional information is available at the end of the chapter

<http://dx.doi.org/10.5772/57159>

1. Introduction

Inguinal hernia repair is the most common procedure in pediatric surgery. Suture techniques for laparoscopic inguinal hernia repair in children are easy to perform and popular with a low recurrence rate. The aim of this study was to evaluate the effect of laparoscopic preperitoneal injection of 3-dimensional gel on closing of the inguinal hernia sac (IHS) in laboratory animals. We performed peritoneoscopy by 12 male Chinchilla rabbits weighing 1200 to 1400 g. Endoscope was introduced in abdominal cavity and bilateral deep inguinal rings were identified. The needle Tuohy with the injectable polymeric bulking agent DAM+ (3-Dimensional Polyacrylamide gel with Ions of Silver “Argiform”, Bioform®) was introduced preperitoneally. The implant was then injected across the entire orifice of the deep inguinal rings and draped over the cord structures. After completion of bilateral repairs, the rabbits were extubated and observed in animal laboratory. Then the second laparoscopy was performed 6 months after and the deep inguinal rings were inspected. At second laparoscopy no reopening to the entire orifice of the deep inguinal rings were noted. Accurate placement the polymeric agent and adequate coverage of the vas deferens was accomplished in all animals. This scientific report demonstrates that the biopolymeric implant gives good postoperative results and a stable trend of closing IHS in long-term follow-up. We hope that the injectable polymeric bulking agents can be used for treatment of inguinal hernias at pediatric patients after additional animal and human researches.

Inguinal hernia is the most frequent diagnosis in pediatric surgery. Familiarity with embryology is necessary to understand the inguinal abnormalities. During fetal life, the descent of

the testis into the inguinal canal and scrotum brings a small pouch of peritoneum alongside. This peritoneal extension is the processus vaginalis. In females, the formation of the labia has the same peritoneal remnant, referred to as the canal of Nuck. The peritoneal canals are obliterated in up to 95–98% of fetuses before birth. Failure of this peritoneal fusion results in a spectrum of abnormalities. The degree of fusion failure results in either a hydrocele or a hernia [1, 2]. There are two types of inguinal hernia: direct, where the abdominal musculature is weak and visceral contents protrude through the wall of the inguinal canal and exit via the superficial inguinal ring, and indirect inguinal hernia, where visceral contents pass into the patent processus vaginalis (PPV) via an open deep inguinal ring and exit via the superficial inguinal rings. The latter is the most common finding in children.

Inguinal hernia in children can be repaired through either an open or laparoscopic technique. In 1995, Shcheben'kov [3] first reported on laparoscopic inguinal hernia repair in pediatric patients. Since that time, laparoscopic ligation of inguinal hernias has been performed in many institutions with a variety of methods of suturing of open inguinal rings.

The laparoscopic approach can be performed either transperitoneally or through a preperitoneal approach with transperitoneal visualization. The transperitoneal method incorporates a telescope through an umbilical port, allowing direct visualization of the deep inguinal rings, followed by the controlled passage of instruments either with or without the assistance of trocars. The deep ring is then closed with either an absorbable or nonabsorbable suture either as purse string or similar (Fig.1).

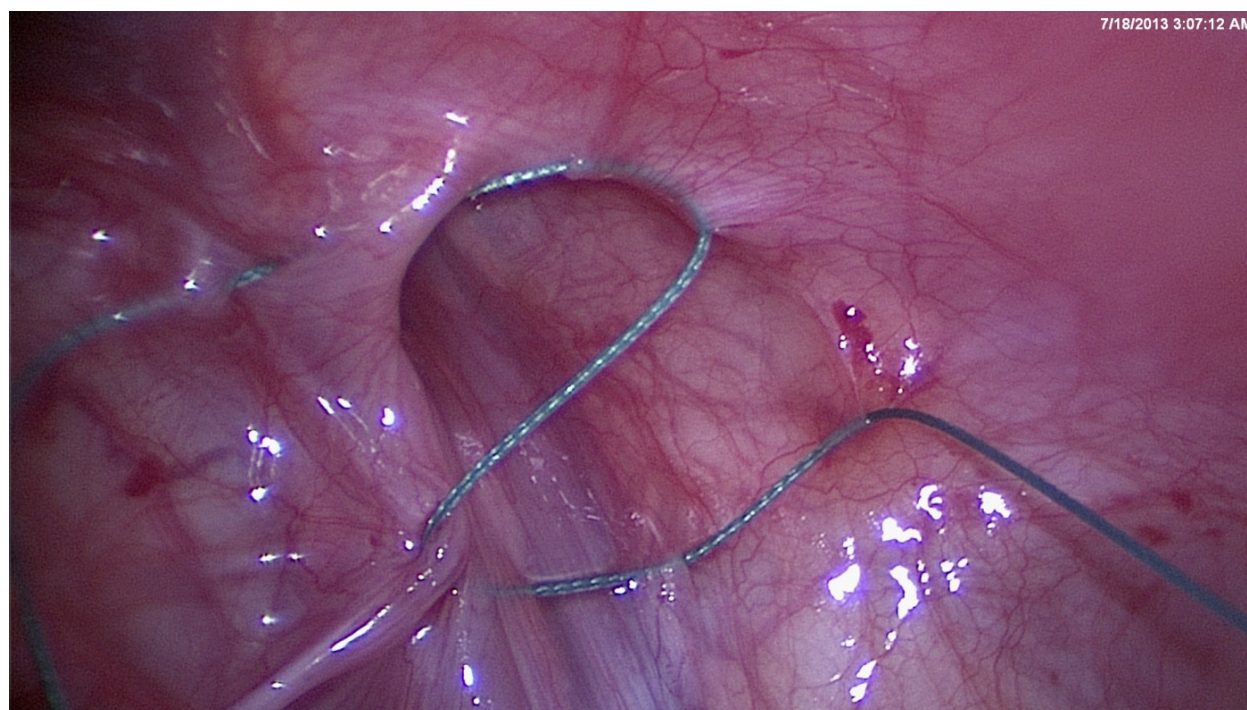


Figure 1. Transperitoneal ligation of the internal inguinal ring by Schier (Z-suture)

Since the description of extraperitoneally ligation of the internal inguinal ring by Takehara [4] and Ozdegiz [5], the treatment of inguinal hernias at children was transformed to «story of needles and hooks». A small hook or Tuohy needle, loaded with a suture, is passed around the deep ring after making a small inguinal skin incision. The passage of the suture is observed via an endoscope at the umbilicus (Fig.2). The ligature is then brought extracorporally and tied, thus closing the hernial orifice. The transabdominal extraperitoneal repair has some support for a lower recurrence rate, when compared to the traditional open procedure. A slightly higher recurrence rate appears to exist when comparing the transperitoneal to the extraperitoneal and open repair. The advantages of a reduced injury to the vas and vessels, a reduction in testicular atrophy, and improved cosmesis are not supported by current levels of evidence.

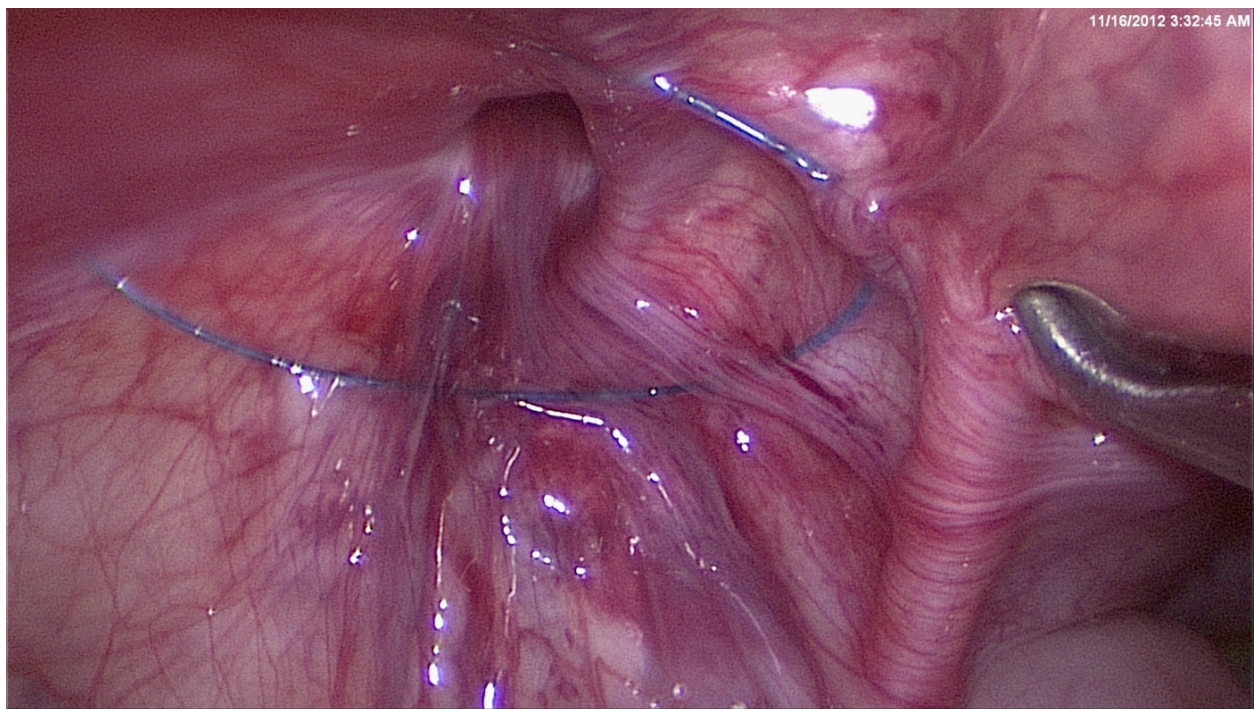


Figure 2. Preperitoneal ligation of the internal inguinal ring by Ozdegiz

Complications are rare following surgery for hernia or hydrocele. Injury to the vas deferens during inguinal or hydrocele repair is a potential risk [6] with treatment requiring microsurgical repair. Visceral injury during laparoscopic repair is very rare and can be treated either by open or laparoscopic surgery. Injury to the genitofemoral nerve, resulting in chronic pain, is a rare occurrence [7]. Testicular ascent following inguinal tissue contracture is another possible long-term problem as well as testicular atrophy, though the latter is associated usually with preoperative incarceration.

The surgical principal in laparoscopic repair in children is to close the inguinal hernia sac (IHS) at its neck as in the open repair. Different techniques of laparoscopic hernia repair have been developed, but there are two basic approaches – a purely intracorporeal [8-11] ligation and

laparoscopic-assisted extracorporeal ligation [4, 5]. Therefore, further development in minimal access surgery for pediatric inguinal hernia is to decrease the number and size of skin incisions. With a trend toward increasing use of extracorporeal knotting and decreasing use of working ports and endoscopic instruments, single-port endoscopy-assisted percutaneous extraperitoneal closure with variable devices is the attainment.

Laparoscopic approach to inguinal hernia in children has become an alternative to the conventional open procedure. Advantages of endoscopic repairs include the ability to evaluate the contralateral side, avoidance of access trauma to the vas deferens and gonadal vessels, iatrogenic cryptorchidism, shorter operative time, less postoperative pain and length of hospital stay. According to the literature, open herniorrhaphy in children has been reported to have recurrence rate of 0.8% to 3.8% and postoperative contralateral hernia rates up to 30% [12, 17]. Recurrence rates in laparoscopic approach has ranged from 0.7% to 4.3% [13, 14].

There are some technical limitations, although modifications on laparoscopic surgery continue to be refined. The known limitations of the laparoscopic surgery are as follows - the necessity for intra-abdominal skills, such as intracorporeal suturing, knot tying, and manipulation of the suture on a needle, high operating costs and cardiorespiratory changes by pneumoperitoneum. In fact, compared with open herniotomy, laparoscopic approach did not take any superiority in cosmesis. Conversely, the procedure was thought not to be a minimally invasive surgery because of the necessity of multiple skin incisions and pneumoperitoneum during operation.

2. Polymers in inguinal surgery

Laparoscopic inguinal hernia repair involves less dissection of the abdominal wall and spermatic cord structures, so the risk for complications may be lower, but some kind of suture (ie, z-suture, n-suture, purse string suture, and extraperitoneal closure) must be used. Placing his sutures correctly is difficult, and there is a considerable learning curve involved, especially in premature, because of the extremely limited operative field. In contrast, deep inguinal ring does not require surgical ligation, and can be closed using injected tissue adhesive.

Laparoscopic hernia surgery continues to evolve with new polymeric products allowing surgeons multiple choices in treating their patients. In 2004 Miyano G. et al. [15], published experimental work with injection of 2-octyl-cyanoacrylate (Dermabond®) into right IHS under laparoscopic control. Herniography results showed no flow of gastrografen solution into treated inguinal hernia sac in rats. Histologic examination in the treated HIS demonstrated localized mild inflammation, and foreign body giant cells were observed around the Dermabond®. The spermatic vessels, vas deferens, and testes were normal. All testes had large numbers of normal sperm. This technique is innovative concept for the treatment of inguinal hernia because it uses tissue adhesives to close hernia sac. This approach eliminates dissection of the spermatic cord and ligation of the IHS, thus virtually completely lowering the risks of injuries. Later, in 2005, the same group of authors published paper comparing several types of tissue adhesives in the treatment of inguinal hernia [16]. This experimental work has shown

high efficiency of Dermabond® for closing IHS. Explanation of this efficiency is that this tissue agent is not absorbable. The other tissue adhesives are all absorbable, and may have become ineffective within months. Comparing different tissue adhesives Kato Y. et al. have shown that laparoscopic injection of 2-octyl-cyanoacrylate (Dermabond®) was highly effective for closing the orifice of the IHS [16]. Following study [17] demonstrates that fibrin glue and cyanoacrylate are better tolerated than sutures by patients, and that the glues lead to better results during initial follow-up and a better trend in long-term data. The glues were recommended for use in adults for mesh fixation of tension-free inguinal repair.

3. Polyacrylamides in surgery

Injectable soft tissue fillers play an important role in cosmetic and reconstructive surgery. Since the acceptance of collagen as a filler, new reabsorbable and non-absorbable implants have appeared with varying degrees of success. Today, as we know more about products and their potential complications, a more accurate treatment plan can be arranged for the patient. The ideal desired characteristics for a soft tissue filler are that they must be safe, biocompatible, easy to inject, long lasting effect, and not provoke any complications. Nonbiodegradable fillers must give a definitive correction. The advantage of these products is longevity. One of these products is polyacrylamide. The chemical properties of polyacrylamide gel with a high proportion of water cause fewer foreign body reactions. The capsule gets thicker with fibroblasts and macrophage accumulation. This product is the first choice for facial soft tissue augmentation, such a cheek, chin, or mandibular augmentation. Polyacrylamide adds volume to the subcutaneous tissue, thereby restoring of augmentic facial and body contours. It is also used for lip augmentation, nasolabial folds, perioral wrinkles, glabellar frown lines, and depressed mouth corners. This product must be injected deeply in the subcutaneous tissues. Polyacrylamide implantation is considered permanent. It cannot be reabsorbed into the body. Hydrophilic polyacrylamide gels are non-toxic, non-sensitizing, non-mutagenic, biocompatible and chemically stable. After injection the water content is absorbed by the body whilst the gel becomes encapsulated. It remains soft and pliable like the body's own tissue.

In our experimental study we proposed the laparoscopic preperitoneal injection of 3-Dimensional gel (DAM+™) on closing the orifice of the IHS in laboratory animals. This polymer is injectable hydrophilic polyacrylamide gel with 0.03% residual unpolymerized acrylamide monomer. It is manufactured by Bioform in Russia. This product is the second generation polyacrylamide gel comprised of 95% polyacrylamide and 5% water, it is also manufactured using a silver ion process to help repel bacteria. It comes in sterile syringe with a needle of 25Gx1½ (Fig.3). Prepacked and tested for microbiological cleanness the gel DAM+ is then sterilized in an autoclave chamber and tested for sterility. The 3-D polymeric gel is the most physiological and the safest implant out of the rest existing implants. Its structure and properties respond in the best way to the inner space of the human body. It contains silver, which creates unfavorable medium against bacterial invasion and development of pathogenic microbiological flora. This filling agent is inert, does not react to the previously injected gels, admits possibility of its multiple injections into the same anatomical region in the case it has

been not enough injected or applied in stage-by-stage corrections. DAM+ can be injected through thin needles, hence it causes minimal traumas. It is very important that it does not cause an inflammation, nor any allergy or non-compatibility with the tissues thanks to absence in it of initiators of immune reactions. During long-term localization within the injection zone, DAM+ does not exert any inflammatory reactions. When injected correctly, it does not migrate from the injection zone.

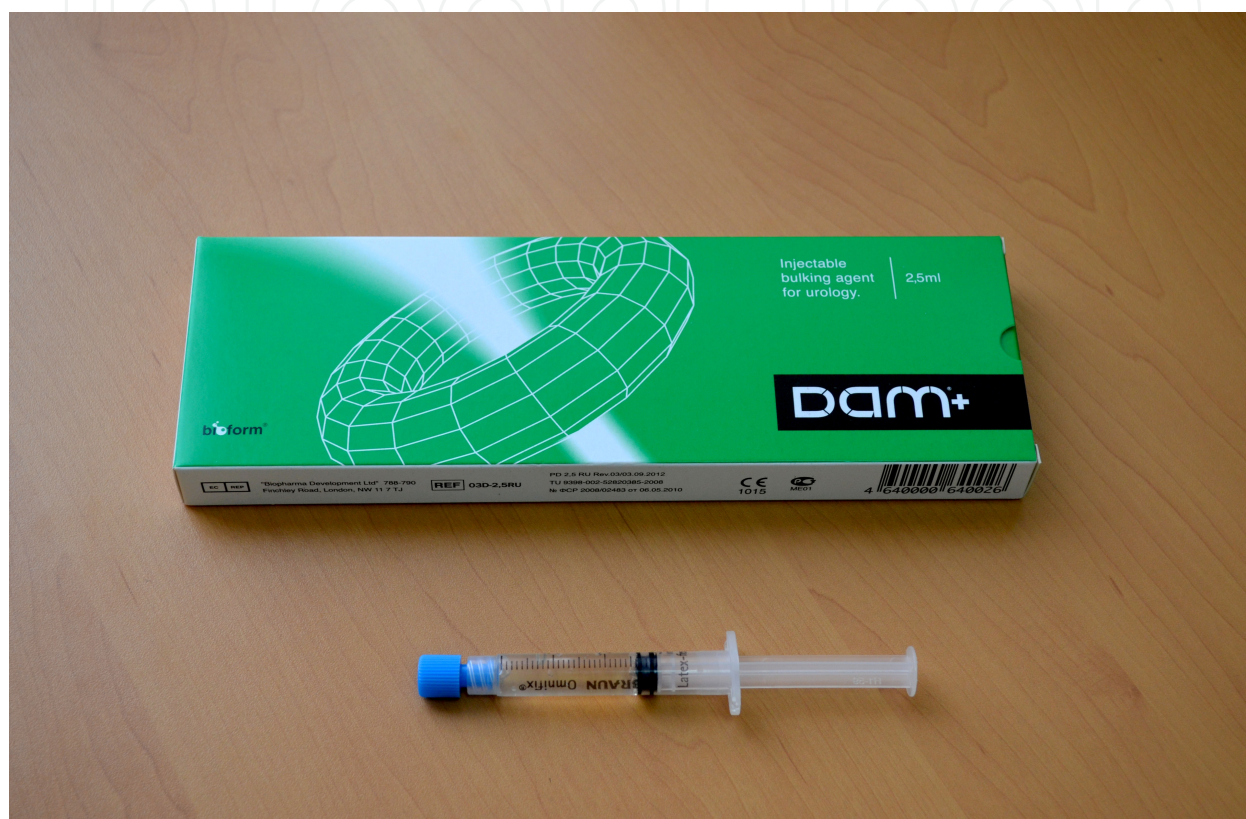

Figure 3. Polyacrylamide gel DAM+ in packing

This agent is used in clinical practice for endoprosthesis of the soft tissues by increases of their volume. Polyacrylamide in fact has been used for decades in the preparation of soft contact lenses. Besides, the toxicity of polyacrylamide has been studied for more than 30 years. Research indicates that polyacrylamide is non toxic and practically non biodegradable. DAM + is absolutely safe because of the presence of silver ions, known for their antibacterial properties. There are also no allergy issues with this gel. There are some articles with good results of using this gel in bronchial surgery for endoscopic treatment of bronchial fistulas and prophylaxis, treatment of primary insufficiency of bronchial stump after pneumonectomy [18, 19] and in endoscopic treatment of vesico-ureteral reflux in children [20]. Safety of the hydrophilic gel DAM+ has been repeatedly confirmed by its pre-clinical tests on animals, also by its experimental clinical application [21]. In this experimental study it was shown that polyacrylamide gel had low reactivity with surrounding tissue. Ions of silver contribute to this

low reactivity and reduce the risks of local inflammation. The histological examination has shown development of good capsule with macrophageal infiltration, marked vascularity and absence of any signs of local inflammation. In microscopic research 1 month after the operation, the implanted material remained located in the subcutaneous cellular tissue in the form of grid structures of fibrous character. There was a round cell reaction observed with excess of macrophage elements. Three months after the implantation, the histopathologic feature got changed. Thin polymer taenias penetrating into the tissue had developed in all directions from the main conglomerate of the implanted material. That phenomenon was explained by the fact that a conjunctive capsule began its formation. Within the connective tissue, not far from the implanted material, vessels were seen enlarged plethoric blood vessels. After six months, around the implanted material revealed a connective tissue infiltrated with macrophages and other round cell elements and marked the development of the capsule. In some areas around the implanted material observed a mature connective capsule isolating the polymer from the surrounding tissues. The main components of that capsule were collagen fibers and mature fusiform fibroblasts between them. Reaction of the blood system remained expressive, some vessels were enlarged and plethoric.

4. Experimental technique of laparoscopic inguinal preperitoneal injection (LIPI)

Minimally invasive surgery has become more frequent in children in the last decade. These techniques require special training because of the low incidence of many surgical diseases in children, and the skills needed are difficult to acquire. For this purpose, several training models have been used, including endotraining boxes, animals, and, more recently, virtual reality. The smaller size of pediatric patients requires not only adequate endoscopic instruments but also an appropriate animal model for teaching and training pediatric minimally invasive surgery.

The most commonly used animals are pigs, which are good models only for big children and adolescents; furthermore, they are expensive and hard to obtain. Rabbits are commonly used in experimental medicine, easy to obtain, very similar in weight to a newborn, and less expensive than pigs. Reports of laparoscopy performed for experimental laparoscopic surgical procedures in rabbits, including the gasless model [22], and other procedures, mainly in gynecology [23-26], prompted us to choose the adult rabbit as our training model for treatment of inguinal hernia. The naturally opened inguinal duct in rabbits resembles the human inguinal hernia with peritoneal fold. Because of inguinal canal of rabbits remains open and patent throughout life and the internal inguinal ring is also open and wide, they are chosen for laboratory study. Simple cohort of twelve male Chinchilla rabbits weighing 1200 to 1400 g was used as subjects. All animals had unrestricted access to food and water pre- and postoperatively. Experimental work was done according to the "Hospital experimental work state" and was approved by hospital ethical committee.

This work was developed at the Experimental Surgery Center of the Institute of Surgery Irkutsk, Russia. A 5-mm 30-degree endoscope without additional laparoscopic instruments

was used. All procedures were recorded on hard disk of the videohub. All animals were placed supine and laparoscopy was done under general anesthesia. Acepromazine (0,25 mg/kg), midazolam (1 mg/kg) and meperidine (5 mg/kg) were administrated intramuscularly as premedication. The induction to general anesthesia was performed with Isoflurane 5%, using a tracheal tube, and maintained with Isoflurane 3-4% under manual ventilation. The animals were positioned supine over a surgical table and kept in place with elastic bands. The abdomen had previously been shaved. All needle movements are performed from outside the body cavity under camera control. To choose the location for the needle puncture, the position of the internal inguinal ring is assessed by pressing the inguinal region from the outside with the tip of a Pean forceps (Fig.4).

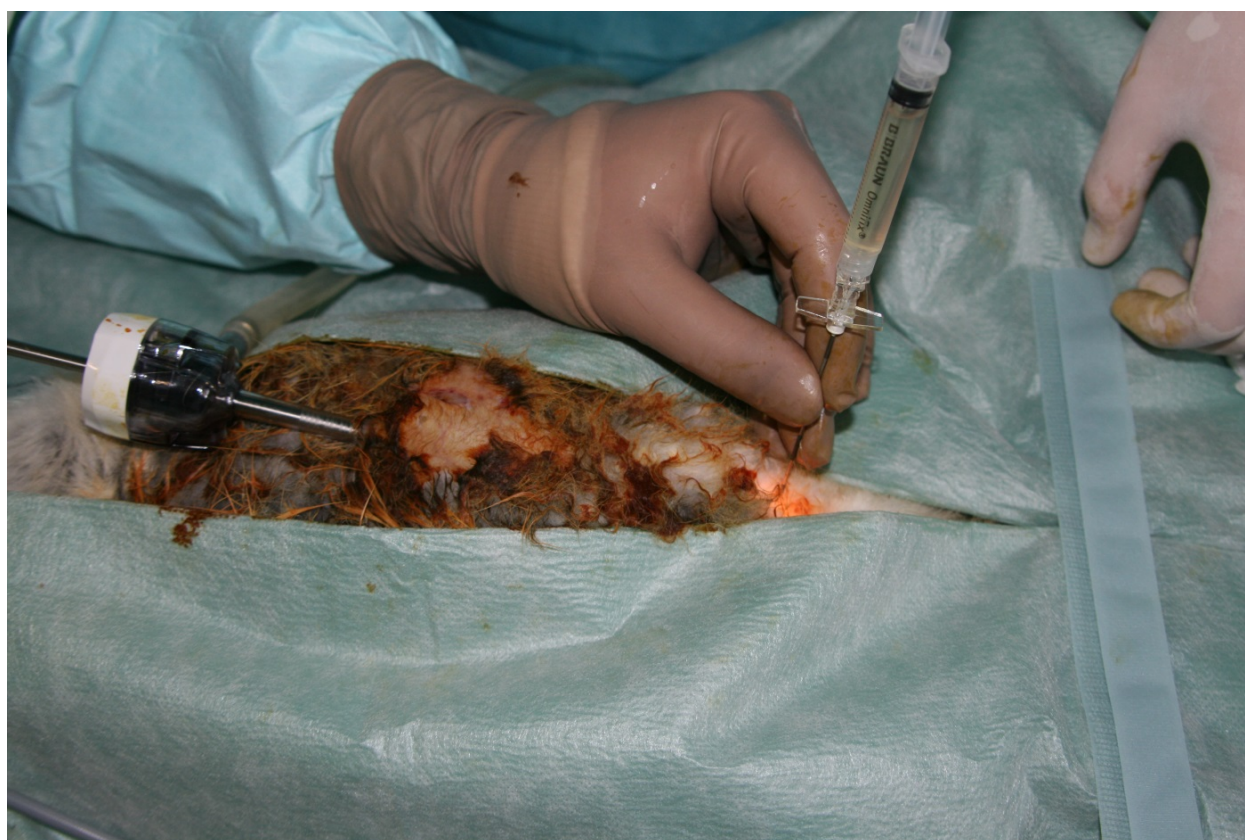

Figure 4. Position telescope and Tuohy needle during laparoscopic inguinal preperitoneal injection (LIPI)

At the beginning of procedure was performed the inspection of deep inguinal rings and cord structures (Fig.5). The Tuohy needle with injectable polymeric bulking agent DAM+™ (3-Dimensional polyacrylamide gel with ions of silver “Argiform”, Bioform®) was introduced preperitoneally (Fig.6). The 2.0 ml of implant was then injected across the entire orifice of the internal inguinal rings (Fig.7) and draped over the cord structures (Fig.8). Mean operative time ranged from 10 to 12 minutes for bilateral hernia repair. Time required to inject the DAM+™ was less than 1 minute Postoperative recovery was rapid and all animals returned to their normal activity after the procedure.

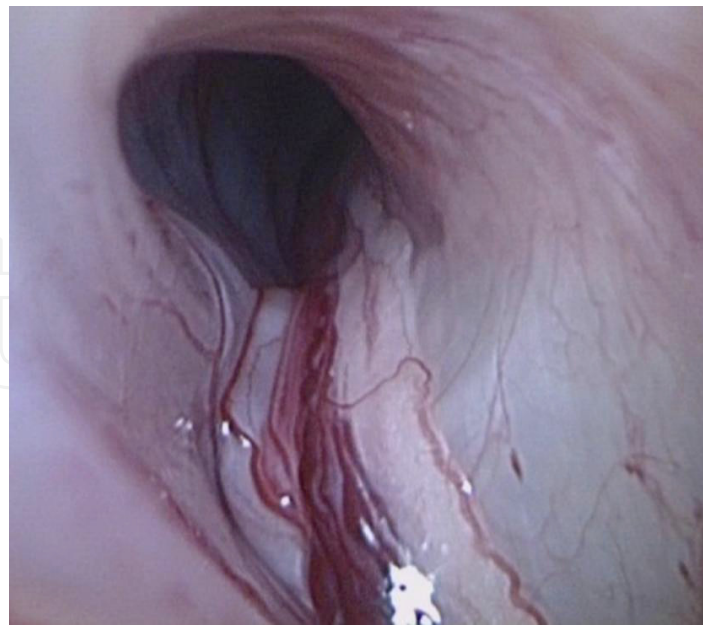


Figure 5. Laparoscopic view on the orifice of the inguinal hernia sac (IHS), the spermatic cord and vas deferens in rabbit

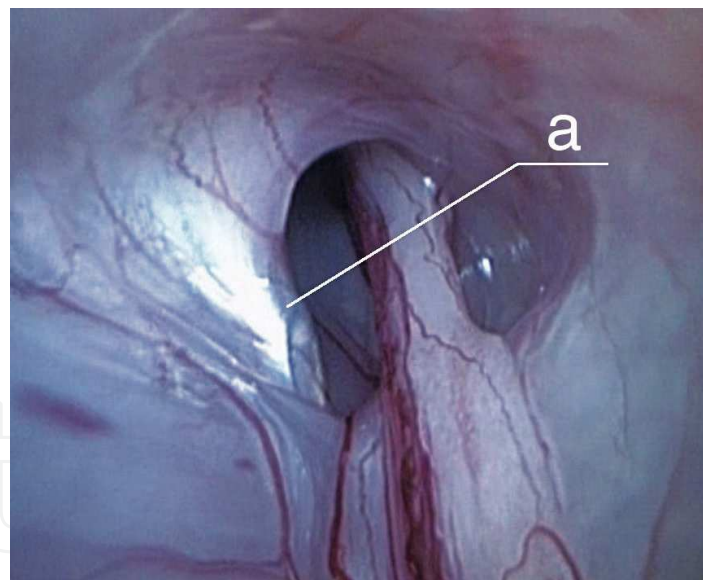


Figure 6. Tip of the Tuohy needle (a) before the gels implantation

After injection of the bulking agent and closing of the orifice of the IHS, the rabbits were extubated and observed in animal laboratory. Second laparoscopy was performed six month later using the same technique. At the second procedure the integrity of the closed internal inguinal rings and the presence of ring abscess, peritonitis and adhesions were recorded. At second laparoscopy integrity of the closed internal inguinal ring was present. No opening of the rings was observed. Accurate placement of the polymeric agent and adequate coverage of

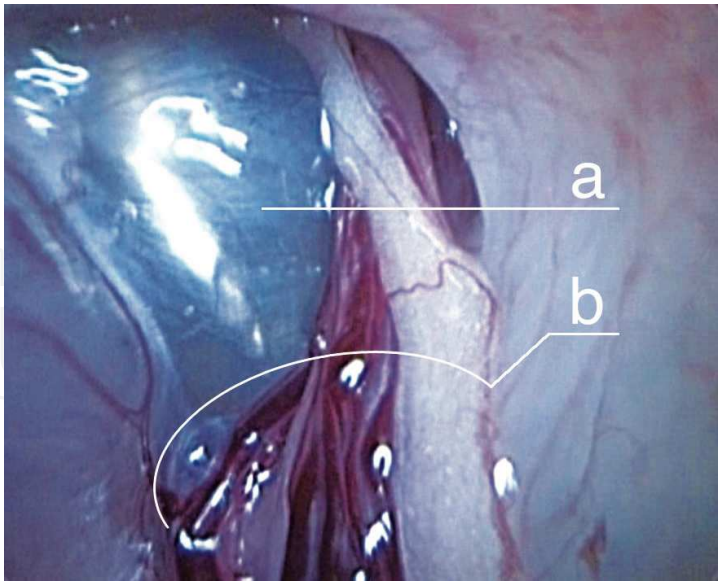


Figure 7. Tip of the Tuohy needle (a) after the gels implantation (b – spermatic cord)

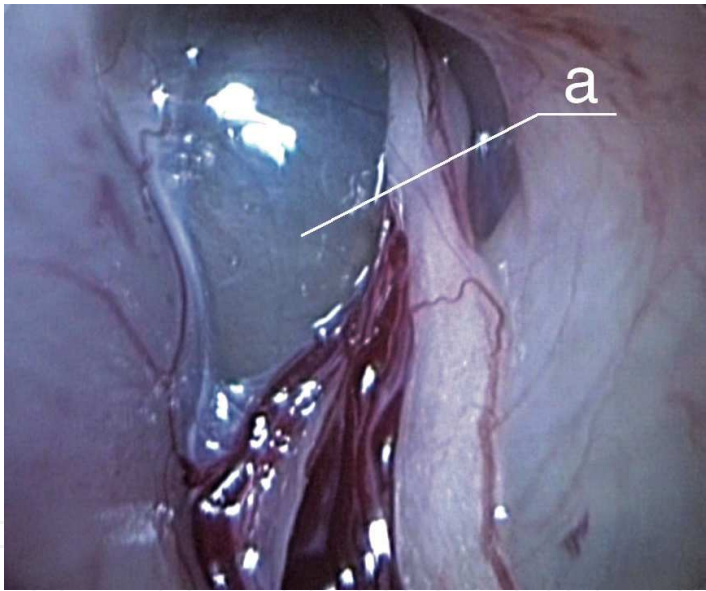


Figure 8. View of the inguinal hernia sac after LIPI procedure with preperitoneal placement of the polymeric agent (a)

the vas deferens were accomplished in all animals. Adhesions between the closed orifice of the IHS and the small bowel were absent in all rabbits. There were no signs of peritonitis and abscess formation.

In the current study, histologic examination clearly showed that mild inflammation was localized within the IHS only adjacent to the gel and there were no histopathologic changes detected around the vas deferens and spermatic vessels. Our results has shown that after six months of DAM+™ injection closing of internal inguinal ring was observed with no reopening

in all cases. This technique is simple, safe, and does not require any laparoscopic skills. Our method is highly successful, but in preparation for its use clinically, we must perform a particular studies requiring investigation local tissue reaction and long-term follow-up after the gel injection. In addition, we have concerns about hernia recurrence because polyacrylamide gel may lose its volume effect. Such research will confirm if there are any detrimental sequelae associated with this technique.

5. Application in the future

Progress in pediatric surgery and anesthesia has reduced the risk of the procedure of the hernioraphy so that in most centers it is performed as a day surgery. Further development in minimal access surgery for pediatric inguinal hernia is to decrease the number and size of skin incisions. With a trend toward increasing use of extracorporeal knotting and decreasing use of working ports and endoscopic instruments, laparoscopic inguinal preperitoneal injection (LIPI) of 3-D gel may be the attainment. We develop a modified technique of non-operative treatment of the inguinal hernia in children and we assume that gel injection in preperitoneal space can be performed under ultrasound visualization without laparoscopic control.

A technology of ultrasound guided nerve block in infants undergoing inguinal hernioraphy gained special popularity in pediatric anesthesia recently. The ilioinguinal/iliohypogastric nerve block is a popular regional anesthetic technique for postoperative pain relief after inguinal surgery in children [27, 28]. It is not easily to perform because the peritoneal cavity is just millimeters from the ilioinguinal and iliohypogastric nerves in small children. Needle placement and spread of local anesthetic is easily seen with high-resolution ultrasonography. Using ultrasound guidance, greater success can be achieved by more accurate placement of reduced volumes of local anesthetics closer to the targeted nerves.

We can transfer this technique and make similar procedure for a gel injection at pediatric patients with inguinal hernia. The idea consists in the following. Before placement of the 3-D polyacrylamide gel an initial ultrasound exploration of the area of the proposed injection site is performed by an experienced ultrasonographer using a stationary or transportable ultrasound unit and a 5–10 MHz linear probe with an active area of 20–30 mm. Inguinal masses in children must be carefully evaluated. The proposed site of injection will be then prepared with chlorhexidine.

The position of the needle tip in a particular anatomical structure (transverse abdominal muscle, internal oblique abdominal muscle, external oblique abdominal muscle; within the peritoneal cavity or subcutaneous) will be recorded. After that gel injection will be made. The injection of the gel will be performed by surgeon with experience of performing inguinal hernia repair. However this technique demands approbation on animal (rabbits) and then can be transferred on the humans.

6. Conclusion

Inguinal hernia repair is one of the most common pediatric surgical procedure worldwide. During the last 10 years, laparoscopic surgery has rapidly invaded the pediatric surgical practice. The hopes associated with introduction of a laparoscopy in treatment of pediatric inguinal hernias didn't come true. Unexpectedly, but the randomized, single-blinded, prospective repair between elective laparoscopic and open repair of unilateral inguinal hernia in children showed that recovery and surgical outcome were similar [28]. Besides, laparoscopic repair significantly increased the postoperative time and operative room time.

Injection implants can be regarded as a self-sufficient non-surgical alternative for correction of inguinal hernia in children. No doubt, materials of such kind must be safe and effective, and respond to a number of requirements: biocompatibility, non-toxicity, long-term effect, absence of antigenic properties and pyrogenic reactions. The injection method is excellent alternative to open and laparoscopic methods of treatment of inguinal hernia in children which use an anesthesia and an incision for operation performance. The advantages of this technique are that there is no dissection of the spermatic cord and there is no ligation of the IHS. The near future will show viability of this method.

Author details

Yury Kozlov^{1*}, Vladimir Novozhilov², Vitaly Kovalev³ and Pavel Krasnov²

*Address all correspondence to: yuriherz@hotmail.com

1 Department of Newborn Surgery, Pediatric Hospital Irkutsk, Irkutsk State Medical Academy of Continuing Education, Russia

2 Department of Newborn Surgery, Pediatric Hospital Irkutsk, Irkutsk State Medical Academy of Continuing Education, Russia

3 Department of Newborn Surgery, Pediatric Hospital Irkutsk, Russia

References

- [1] Sherer LR, Grosfeld JL. Inguinal hernia and umbilical anomalies. *Ped Clin North Am* 1993;40:1121–1131.
- [2] Skandalakis JE, Colborn GL, Androulakis JA, Skandalakis LJ, Pemberton LB. Embryologic and anatomic basis of inguinal herniorrhaphy. *Surg Clin North Am* 1993;73:799–836.

- [3] Shcheben'kov M.V. Laparoscopic hernioraphy. Endoscopic surgery (Mosk). 1995; 4: 7-9. [Article in Russian]
- [4] Takehara H, Yakabe S, Kameoka K. Laparoscopic percutaneous extraperitoneal closure for inguinal hernia in children: clinical outcome of 972 repairs done in 3 pediatric surgical institutions. *J Pediatr Surg*. 2006;41:1999-2003.
- [5] Ozgediz D, Roayaie K, Lee H, et al., Subcutaneous endoscopically assisted ligation (SEAL) of the internal ring for repair of inguinal hernias in children: report of a new technique and early results. *Surg Endosc*. 2007;21:1327-1331.
- [6] Steigman CK, Sotelo-Avila C, Weber TR. The incidence of spermatic cord structures in inguinal hernia sacs from male children. *Am J Surg Pathol* 1999;23:880-885.
- [7] Chen LE, Zamakhshary M, Foglia RP, et al. Impact of wait time on outcome for inguinal hernia repair in infants. *Pediatr Surg Int* 2009;25:223-227.
- [8] Schier F. Laparoscopic surgery of inguinal hernias in children: initial experience. *J Pediatr Surg* 2000;35:1331-1335.
- [9] Schier F. Laparoscopic inguinal hernia repair: a prospective personal series of 542 children. *J Pediatr Surg* 2006;41:1081-1084.
- [10] Montupet P, Esposito C. Laparoscopic treatment of congenital inguinal hernia in children. *J Pediatr Surg*. 1999;34:420-423.
- [11] Prasad R, Lovvorn HN, Wadie GM, et al. Early experience with needlescopic inguinal herniorrhaphy in children. *J Pediatr Surg*. 2003;38:1055-1058.
- [12] Endo M, Watanabe T, Nakano M, et al. Laparoscopic completely extraperitoneal repair of inguinal hernia in children: a single-institute experience with 1257 repairs compared with cut-down herniorrhaphy. *Surg Endosc*. 2009;23:1706-1712.
- [13] Shalaby R, Shams AM, Mohamed S, et al. Two-trocar needlescopic approach to incarcerated inguinal hernia in children. *J Pediatr Surg*. 2007;42:1259-1262.
- [14] Chan KL, Tam PK. Technical refinements in laparoscopic repair of childhood inguinal hernias. *Surg Endosc*. 2004;18:957-960.
- [15] Miyano G, Yamataka A, Kato Y, et al. Laparoscopic injection of Dermabond tissue adhesive for the repair of inguinal hernia: short- and long-term follow-up. *J Pediatr Surg*. 2004;39:1867-1870.
- [16] Kato Y, Yamataka A, Miyano G. Tissue adhesives for repairing inguinal hernia: a preliminary study. *J Laparoendosc Adv Surg Tech A*. 2005;15:424-428.
- [17] Testini M, Lissidini G, Poli E, et al. A single-surgeon randomized trial comparing sutures, N-butyl-2-cyanoacrylate and human fibrin glue for mesh fixation during primary inguinal hernia repair. *Can J Surg*;53:155-160.

- [18] Bisenkov L.N., Bikhodzhin R.Sh. The endoscopic treatment of bronchial fistulas by submucosal injections. *Vestn Khir Im I I Grek.* 2005;164:38-41. [Article in Russian]
- [19] Bisenkov L.N., Bikhodzhin R.Sh. Prophylaxis and treatment of primary insufficiency of bronchial stump after pneumonectomy. *Khirurgiia (Mosk).* 2007;1:59-65. [Article in Russian]
- [20] Osipov I, Lebedev D, Sosnin E, et al. Our experience in endoscopic treatment of vesico-ureteral reflux in children. *Arch Ital Urol Androl.* 2005;77:146-148.
- [21] Fedorova V.N., Dirsh A.V., Borchunova E.N. Tissue reactivity to the injection of different types of polyacrylamide gels. *Regenerative surgery.* 2004; № 2. Electronic journal: <http://www.reg-surgery.ru/home.html>. [Article in Russian].
- [22] Luks FI. Gasless laparoscopy in infants. The rabbit model. *J Pediatr Surg* 1995;30:1206–1208.
- [23] Marana R, Luciano AA, Muzii L, et al. Laparoscopy versus laparotomy for ovarian conservative surgery. A randomized trial in the rabbit model. *Am J Obstet Gynecol* 1994;171:861–864.
- [24] Hurd W. A comparison of the relative risk of vessel injury with conical versus pyramidal laparoscopic trocars in a rabbit model. *Am J Obstet Gynecol* 1995;173:1731–1733.
- [25] Ordoñez JL, Domínguez J, Evrard V, et al. The effect of training and duration of surgery on adhesion formation in the rabbit model. *Hum Reprod* 1997;12:2654–2657.
- [26] Molinas CR, Cabral CR, Koninckx PR. Effect of the diameter of the endoscope and of surgeon training on the duration and quality of laparoscopic surgery in a rabbit model. *J Am Assoc Gynecol Laparosc* 1999;6:447–452.
- [27] Willschke H, Marhofer P, Bosenberg A, Johnston S, Wanzel O, Cox SG, Sitzwohl C, Kapral S. Ultrasonography for ilioinguinal/iliohypogastric nerve blocks in children. *Br J Anaesth* 2005;95:226–30
- [28] Denny NM, Harrop-Griffith W. Location, location, location! Ultrasound in regional anaesthesia. *Br J Anaesth* 2005;95:1–2
- [29] Koivusalo AI, Korpela R, Wirtavuori K, et al. A single-blinded, randomized comparison of laparoscopic versus open hernia repair in children. *Pediatrics* 2009;123:332–337.