

# We are IntechOpen, the world's leading publisher of Open Access books Built by scientists, for scientists

6,900

Open access books available

186,000

International authors and editors

200M

Downloads

Our authors are among the

154

Countries delivered to

TOP 1%

most cited scientists

12.2%

Contributors from top 500 universities



WEB OF SCIENCE™

Selection of our books indexed in the Book Citation Index  
in Web of Science™ Core Collection (BKCI)

Interested in publishing with us?  
Contact [book.department@intechopen.com](mailto:book.department@intechopen.com)

Numbers displayed above are based on latest data collected.  
For more information visit [www.intechopen.com](http://www.intechopen.com)



---

# **Laparoscopic Approach in the Treatment of Inguinal Hernia and Associated Pathologies in Children**

---

Antonio Marte, Gianpaolo Marte and  
Pio Parmeggiani

Additional information is available at the end of the chapter

<http://dx.doi.org/10.5772/57158>

---

## **1. Introduction**

Inguinal hernia is one of the most common surgical disorders in children. Galen first, in 176 A.D, described the processus vaginalis as “The duct descending to the testicle is a small offshoot of the great peritoneal sac in the lower abdomen”. The surgical history of inguinal hernias dates back to ancient Egypt. From Bassini’s heralding of the modern era to today’s mesh-based open and laparoscopic repairs, this history closely resembles the evolution in anatomical understanding and development of the techniques of general surgery. Ferguson, in 1899, proposed hernia repair by just exposure, dissection, simple high ligation and removal of the hernia sac, and this was applied successfully to the pediatric population by Potts et al. [1-3] Fig 1-2-3

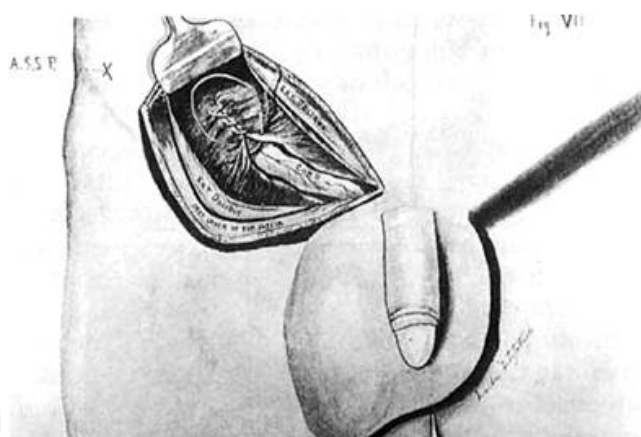
While in adult hernia repairs, the underlying principle involved reconstruction of weakened muscles and aponeurosis in multiple anatomical layers, for pediatric hernia simple dissection and high ligation of processus vaginalis at internal ring was found to be sufficient to provide a long lasting cure to repair indirect inguinal hernia. The Ferguson principle still remains the basis of all pediatric hernia repairs even in the 21st century. With advances in operating techniques, better suture materials and pediatric anesthesia, the ferguson principle remains at the basis of laparoscopic hernia repair.

The evolution reached its current level in 1990 shortly after the introduction of laparoscopic cholecystectomy, when the laparoscopic approach to inguinal hernia repair was introduced. [4]

In the last few years the use of the laparoscopic approach to inguinal hernia has increased not only for accurate diagnoses, but also for treatment.



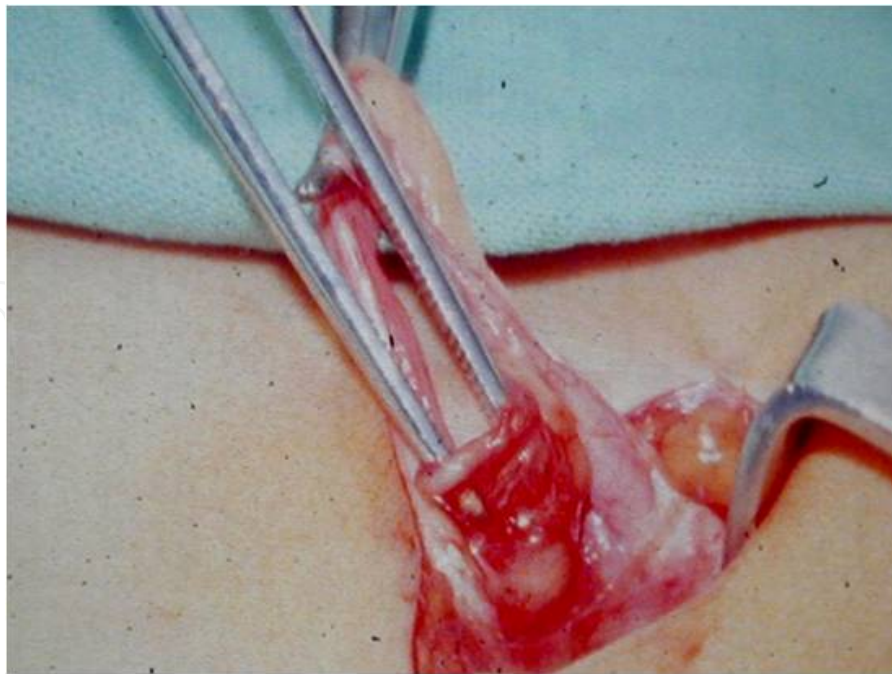
**Figure 1.** Alexander Hugh Ferguson (1853-1911).



**Figure 2.** The original drawing of Ferguson technique.

The data reported in the literature underline the safety, reproducibility and excellent cosmetic results of this technique to an extent that it can now be considered as a valid alternative to traditional surgery and a first choice technique to explore the contralateral side, in the differential diagnosis between direct and indirect hernias, and for the treatment of recurrences [5-8]. Nevertheless some perplexity still remains about the higher percentage of recurrence rate with this technique ranging from 3.4% to 4.1% compared to the open technique. [3-6]

We present here our experience with the laparoscopic inguinal hernia repair in children with the addition of the lateral incision of the sac and the suture of the inner inguinal ring. As many



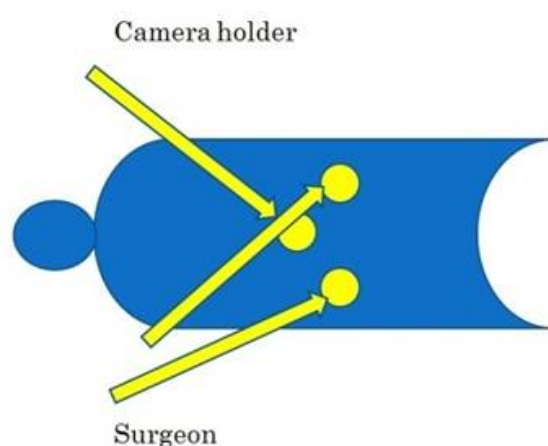
**Figure 3.** Traditional open inguinal herniotomy in children.

as 220 patients were operated on from January 2004 to June 2012. The age ranged from 2 months to 12 years (mean, 2.5 years), with a follow-up between 1 and 7 years (mean 3.5 yrs). There were 90 bilateral and 130 unilateral inguinal hernia, male/female ratio 141/79.

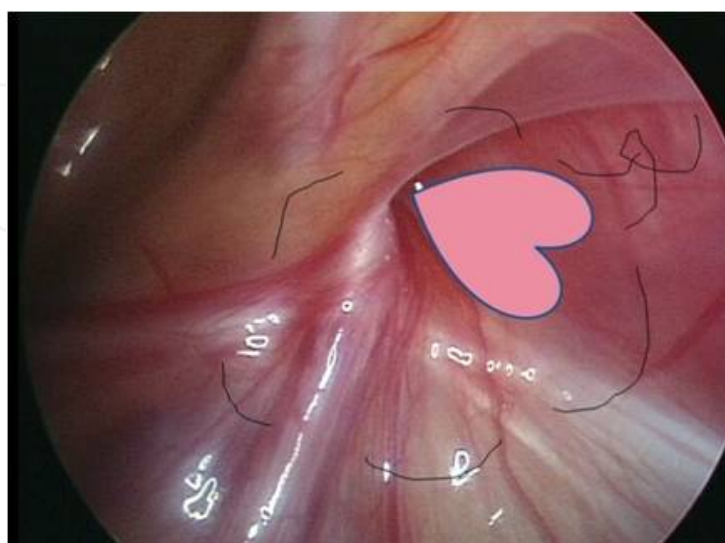
All the procedures were performed under general anaesthesia and by the same surgeon (AM). Inclusion criteria included bilateral inguinal hernia, recurrent hernia, hernia in obese children, incarcerated hernia, and ipsilateral hernia with questionable hernia on the contralateral side. Exclusion criteria included patients with undescended testicles or who have had many abdominal surgeries.

According to the age, patients were either asked to urinate before the operation or underwent manual bladder voiding after the anaesthesia. In the early experience a Veress needle was employed to induce pneumoperitoneum (12 mmHg) with carbon dioxide (CO<sub>2</sub>); the Veress was subsequently replaced by a 5 mm reusable Hasson trocar introduced by "open technique". This resulted useful not only for safety but also in case of associated umbilical hernia or previous surgical procedure, to prevent injuring the adherent bowel or omentum. The 5mm 0° or 30° laparoscope was employed first to explore the abdominal cavity, and then to ensure patency of the processus vaginalis on both sides. Thereafter, two operating 2 mm or 3 mm reusable trocars were inserted in the lower right and left quadrants of the abdominal wall, along the midclavicular line; the patient was then placed in mild Trendelenburg position. (Fig 4) The procedure usually required a needle holder, a grasper and a pair of scissors. The suture needle was introduced in the cavity through the abdominal wall, above the inguinal ring. The sac was previously incised for 1 to 2 cm laterally from the inner inguinal ring to the distal part of the sac exposing a triangular area or removing a small portion of peritoneum (IRIS Technique–Inguinal Ring Incision Suture) (fig 5), then the inner inguinal ring was closed adopting a W-shaped suture

or a purse string using non absorbable, 3/0 - 4/0 polybutester monofilament on a 17/20-mm swaged needle, starting from the lateral side, grabbing some underlying tissue, to the medial one. A return stitch was then placed near the first lateral access to obtain a tension-free knot. Four to five intracorporeal knots were always placed to ensure closure. Great care was used to close the medial margin of the inguinal ring to prevent recurrence. The vas deferens and testicular vessels in male patients were completely untouched and safeguarded. If necessary a second stitch has been applied to not put stress on the previous one with excessive tension. The needle was retrieved through the working port, and the umbilical wound was then closed with absorbable sutures while the lateral wounds were just approximated. (Fig 5 to 11)

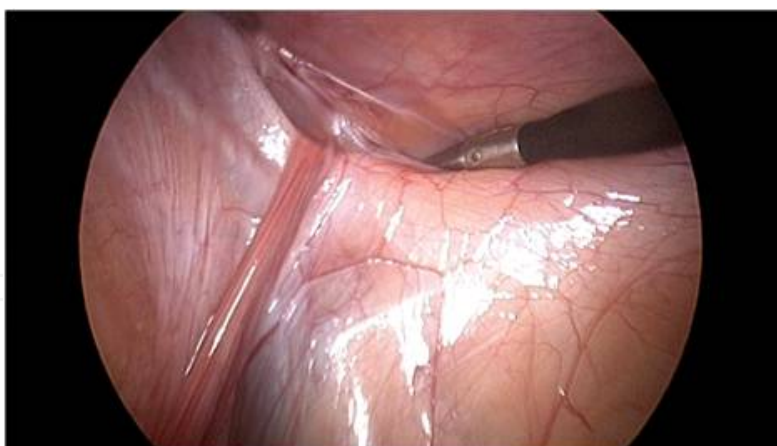

**Figure 4.** Theater layout, trocar placement.

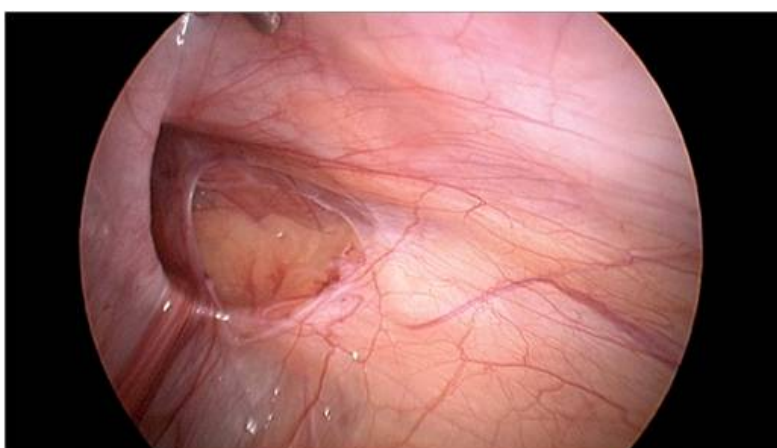


**Figure 5.** Scheme of the peritoneum incision/ purse-string suture.

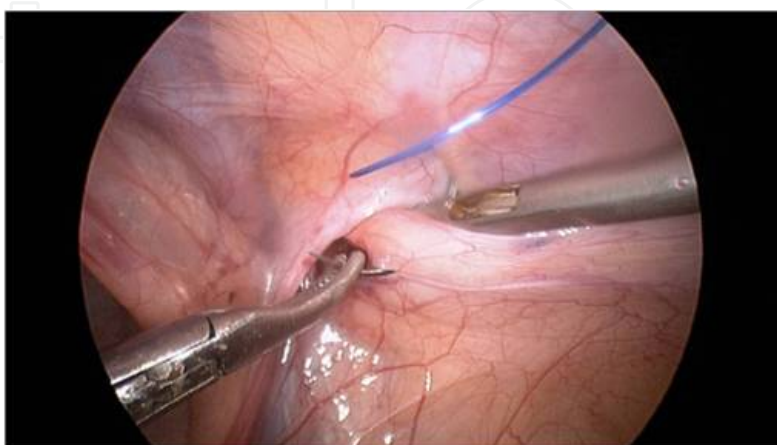




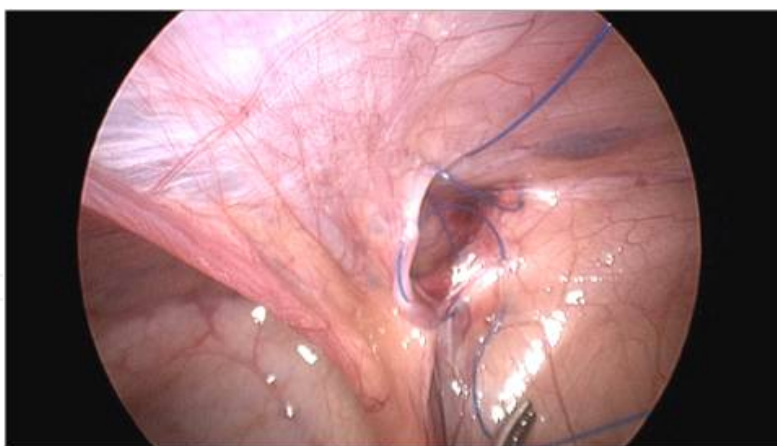
**Figure 6.** Laparoscopic step of the incision of the sac: Incision/removal of a small lateral portion of the sac.



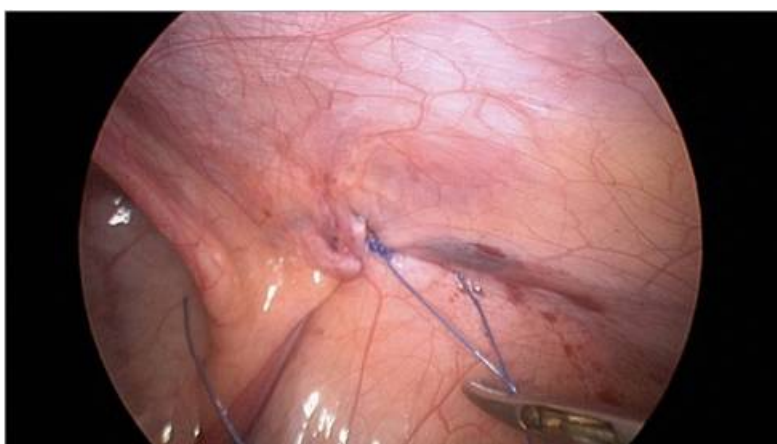**Figure 7.** Triangular area peritoneum – free.



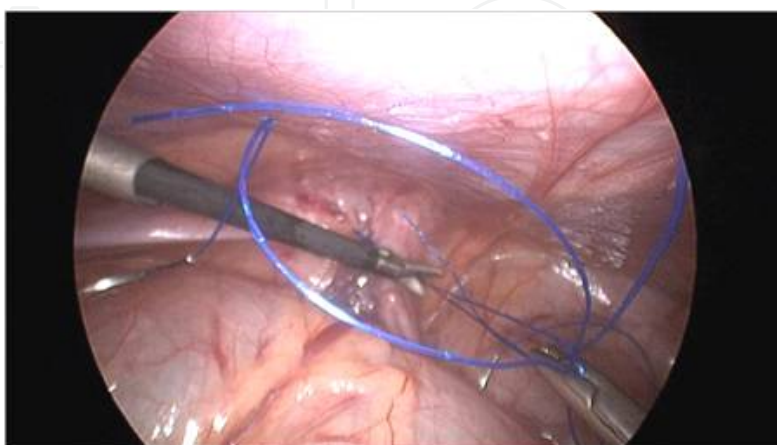
**Figure 8.** Starting suture from the lateral part of the sac.



**Figure 9.** Completion of the purse string suture.



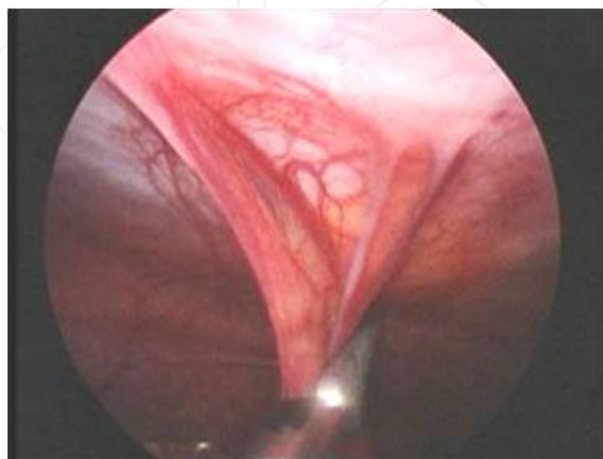
**Figure 10.** Final view of the closure of the inguinal ring.



**Figure 11.** Herniorrhaphy on the contralateral side.

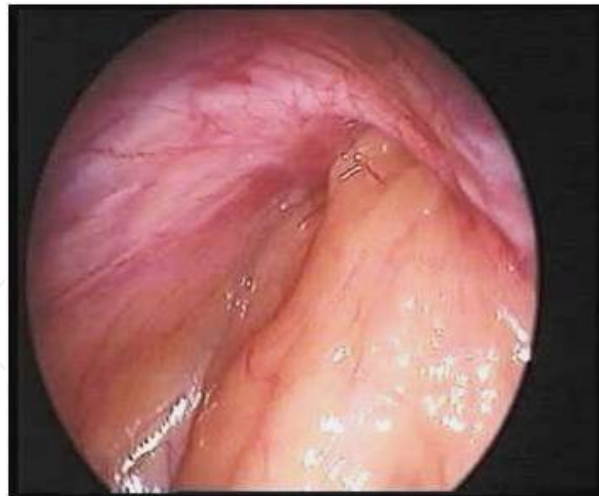
At the end of the procedure, the skin was closed with adhesive strips and the umbilical fascia was closed with polyglactin 3/0 suture at the end of the procedure. The associated umbilical hernias were treated in the usual way closing the fascial defect in a transverse direction with interrupted absorbable polyglactin suture. In some cases, there was need for only one administration of acetaminophen in the first few post operative hours.

Mean operative time was  $19 \pm 3$  m' in the monolateral hernia group and  $28 \pm 4$  m' in the bilateral hernia group. Longer time was required in cases of treatment of adhesions or associated pathologies. The majority of patients was discharged the same day or the next day scheduling the reevaluation at 1 week, 6 months and 1 year. Bilateral inguinal hernia was present in 6.5%. A contralateral patent ductus was present in 17%. No patient required an additional port or conversion to open procedure. A slight bleeding occurred in some patients at insertion port side without sequelae. In the immediate postoperative time, 20 patients presented mild emphysema on a portal site or at scrotal level, which resolved spontaneously. 2 (0.9%) patients, in the present series, after the adoption of incision/suture of the internal inguinal ring, developed recurrence after a period varying between 1 and 6 weeks, which was repaired with standard open surgery in 1 case and laparoscopically in the other. No patient presented postoperative complications including testicular atrophy, wound infection or incision site herniation. No metachronous hernia occurred during the follow-up (mean follow-up: 3,5 yrs). [9] The associated diseases treated in the same session has been as follows: umbilical hernia 31 pts. ; incarcerated hernia 18 pts; hydrocele 15 pts; incarcerated omentum 12 pts, varicocele 8 pts, incarcerated ovary 1 pt; intestinal adhesions 1 pt. (Figs. 12 to 14) The technique has undergone the following changes: passage to the open technique for the insertion of the first trocar after a period of use of the Veress. Use of incision and removal of a wedge of the parietal peritoneum at the level of the inner inguinal ring to promote healing. Use of a W-shaped or purse string suture to tie on the same side. Reinforcement, when necessary, of the suture with the overlapping of lateral ligaments. Simple interrupted stitches have been used only to reinforce the running or purse string suture.

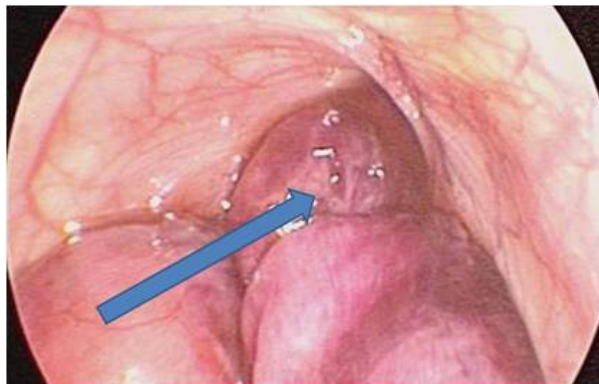


**Figure 12.** Adhesiolysis during laparoscopic herniorraphy





**Figure 13.** Laparoscopic view of the incarcerated omentum



**Figure 14.** Laparoscopic view of an incarcerated hernia

## 2. Discussion

In our experience the results of laparoscopic approach to inguinal hernia and some associated pathologies in children with IRIS technique are safe, easy and versatile and the section of the outer portion of the internal inguinal ring looks like a useful device in reducing relapses.

Different techniques has been described for tightening up the hernia opening by laparoscopy with varied results. [10] They include the following techniques:

### 1. Intracorporeal suturing and knotting technique

This has been the initial method adopted at the inception of laparoscopic inguinal hernia repair in children thanks to the reports by Schier an Montupet. The technique employs three ports and uses nonabsorbable suture materials. In this method, intraperitoneal suture of the internal inguinal ring is performed to close the processus vaginalis at its origin. The closure is achieved

by suturing in N, W or purse-string fashion and knotting tight the internal inguinal ring with 1 or 2 stitches. Sometimes simple interrupted stitches can be utilized to close the ring. This method has a certain recurrence rate (0–5.7%) and good intracorporeal laparoscopic knotting skill is required.

More recently, with refinements in technology, the single procedure is currently attracting attention. In their experience with modified single-port laparoscopic procedures in children, Rothenberg *et al.* found very encouraging outcome. This report corroborates with a study by Chang on technical refinements in single-port laparoscopic surgery of inguinal hernia in infants and children. In a comparison study by Bharathi *et al.*, single-port technique was preferred to the three port due to better outcome. Of course this technique presents technical difficulties compared to the classic three-port procedure. [11-13]

## **2. Inversion and ligation technique**

This method of laparoscopic inguinal repair is widely used in girls. This is a modification of the intracorporeal technique, using three ports and nonabsorbable sutures. It is thought that inversion and ligation of sac at the internal inguinal ring would reduce the risk of recurrence (0.8–2.5%). The problems faced in the intracorporeal technique may also apply here. In 2009, some Authors described the selective sac extraction method for inguinal hernia repair in children by minimally invasive procedure with satisfactory surgical and cosmetic outcome. In the sac extraction technique, the sac is extracted and ligated openly. In the inversion and ligation technique, the sac is isolated, inverted, and ligated laparoscopically. [14-17]

## **3. Complete resection with or without ligation technique**

This is an emerging technique and represents another modification of the intracorporeal technique, with three ports and nonabsorbable sutures employed. In this technique, the hernia sac is resected and closed with a purse-string suture at the level of the internal inguinal ring. The efficacy of this technique is attributed to the fact that in this procedure, the sac is wholly resected and this section favors the healing without leaving skip portions as happens in the intracorporeal suture. The skip portions, especially at the medial aspect of internal inguinal ring, should account for some of the recurrences in some reports. [18]

With resection and no ligation technique the hernia sac is resected at the level of the internal inguinal and allowed to close spontaneously. This technique has been reported in literature with preliminary results showing satisfactory outcome and no recurrence. The method uses three ports and no sutures are employed. [19]

## **4. Flip-flap technique**

In this procedure, a flip-flap is raised in the internal inguinal ring and used to close the defect. The hernia opening is repaired with a peritoneal flip-flap anchored with a single tension-free intracorporeal suture. The vas and testicular vessel remain completely untouched. The valve mechanism, according to these Authors, avoid scrotal collection and prevent hernia recurrence. This is a three-port technique that uses absorbable sutures. Yip *et al.* did not record any

recurrence with this technique. Satisfactory results have been noticed by Hassan *et al.* in a comparative study of this flip-flap technique with the conventional open technique. [20,21]

### 5. Extracorporeal suturing

This method is currently being adopted by increasing number of pediatric surgeons particularly because has low recurrence rates (0–2.0%), and more importantly, knotting does not require any special skill because it is done externally in the subcutaneous tissue in the conventional manner. The low recurrence rate in this technique is attributed to the fact that in this procedure the sac is wholly ligated without leaving skip portions. The limitation of this technique is that special needles and introducers are required. In the review, spinal needle, special 19-gauge needle, hook, and host of other instruments are currently being used with good outcome. [22,23,24]

### 6. Use of tissue adhesives

A useful device to reinforce the suture the internal inguinal ring can be represented by the application of tissue glue.

Initial animal experimental studies showed that tissue adhesives could be used in tissue approximation. Further, experimental animal models have continued to establish the role of tissue adhesives in inguinal hernia repair. Today tissue adhesive is being employed in a lot of laparoscopic procedures including inguinal hernia repair [25-29].

All these artifices indicate that the LH is a technique still in evolution and the near zero recurrence, if possible, is a goal not completely achieved. In our previous experience the sole W-shaped suture was associated to a 3.75% of recurrences [30-32]. The lateral incision with blunt dissection of peritoneum before suturing the inguinal ring resulted, instead, in a significant improvement of the outcome. These results, which are in line with those obtained by other Authors, could be due to a better sealing of the internal inguinal ring obtained after the incision of the peritoneum. [33] We think in fact that, at present, the real problem that all these technical changes would assume that partial or total peritoneum incision practiced at the level of internal inguinal ring can foster internal inguinal ring closure itself. But although the results are better and the comparison result favorable to this techniques there is not a clear demonstration of why and whether, on the long term, relapses are really reduced. In any case laparoscopic optic magnification allows to surgeon to dissect and handle the vas and the vessels very easily. In the open technique, the vas deferens is very vulnerable to mechanical injury, and the incidence of vas injury may be underestimated because the incidence of unilateral vas deferens obstruction was reported to be 26.7% for a subfertile patient with a history of open inguinal hernia surgery in childhood [34-36].

Moreover the possibility of recognize a contralateral patent processus vaginalis can play a role in preventing metachronous hernias. This does not mean that this condition represents a future inguinal hernia but since the adoption of this procedure the number of metachronous hernias was reduced. [37]

### 3. Conclusion

The data from our follow-up confirm that the results of the laparoscopic IRIS technique, presents an acceptable low percentage of recurrences that is comparable to those of the open technique, with the advantage of reduced post operative pain, rapid return to everyday activities, and optimal cosmetic results. Although the results of our experience seems promising we think that the follow-up is too short and the number of the patients too small for drawing definitive conclusion.

### Author details

Antonio Marte, Gianpaolo Marte and Pio Parmeggiani

\*Address all correspondence to: [antonio.marte@unina2.it](mailto:antonio.marte@unina2.it)

Second University of Naples, Pediatric Surgery, Naples, Italy

### References

- [1] Vessella A, Marte A, Parmeggiani P. (2005) Terapia dell'ernia inguinale nel bambino. Dal Papiro di Ebers alla Laparoscopia. Una storia affascinante. p. 1-87. Laruffa Editore, Reggio Calabria. ISBN: 88-7221-281-2
- [2] Ferguson AH. Oblique inguinal hernia: A typical operation for its radical cure. JAMA 1899; 33:6-14.
- [3] Potts WJ, Riker WL, Lewis JE. The treatment of inguinal hernia in infants and children. Ann Surg 1950; 132:566-576
- [4] Schier F. Laparoscopic herniorrhaphy in girls. J Pediatr Surg. 1998;33(10):1495-1497.
- [5] Mintelburg D.M., Nuchtern j.G., Jaksic t. et al: Laparoscopic evaluation of the pediatric inguinal hernia – a meta-analysis. J Pediatr Surg 1998, 33: 874 -8.
- [6] Saranga Bharathi R, Arora M, Baskaran V. Pediatric Inguinal Hernia: Laparoscopic Versus Open Surgery JSLS. 2008 Jul-Sep; 12(3): 277-281.
- [7] Gorsler C.M., Schier F.: Laparoscopic herniorrhaphy in children. Surg. Endosc 2003 17:571 -
- [8] Schier F. Laparoscopic inguinal hernia repair – a prospective personal series of 542 children. J Pediatr surg 2006;41: 1081-4

- [9] Schier F, Montoupet P, Esposito C. Laparoscopic Inguinal Herniorrhaphy in Children: A Three Center Experience With 933 Repairs. *J Pediatr Surg* 2002; 37: 395-7
- [10] Marte A, Sabatino MD, Borrelli M, Parmeggiani P. Decreased recurrence rate in the laparoscopic herniorrhaphy in children: comparison between two techniques. *J Laparoendosc Adv Surg Tech A*. 2009 Apr;19(2):259-62. doi: 10.1089/lap.2008.0292
- [11] Christopher S. Lukong CS. Surgical Techniques of Laparoscopic Inguinal Hernia Repair in Childhood: A Critical Appraisal *J Surg Tech Case Rep*. 2012 Jan-Jun; 4(1): 1-5. doi: 10.4103/2006-8808.100343
- [12] Rothenberg SS, Shipman K, Yoder S. Experience with modified single port laparoscopic procedures in children. *J Laparoendosc Adv Surg Tech*. 2009;19:695-8. 11. Chang YT. Technical refinements in single port laparoscopic surgery of inguinal hernia in infants and children. *DiagTherEndosc*. 2010;2010:392847.
- [13] Bharathi RS, Dabas AK, Arora M, Baskaran V. Laparoscopic ligation of internal ring- three port versus single port technique. Are working ports necessary? *J Laparoendosc Adv Surg Tech A*. 2008;18:891-4.
- [14] Lipskar AM, Soffer SZ, Glick RD, Rosen NG, Levitt MA, Hong AR. Laparoscopic inguinal hernia inversion and ligation in female children: A review of 173 consecutive cases at a single institution. *JPediatrSurg*. 2010;45:1370-4.
- [15] Guner YS, Emami CN, Chokshi NK, Wang K, Shin CE. Inversion herniotomy: A laparoscopic technique for female inguinal hernia repair. *J Laparoendosc Adv Surg Tech*. 2010;20:481-4.
- [16] Zallen G, Glick PL. Laparoscopic inversion and ligation inguinal hernia repair in girls. *J Laparoendosc Adv Surg Tech A*. 2007;17:143-5.
- [17] Ikeda H, Hatanaka M, Suzuki M, Fuji J, Takara K, Ishimara Y. Selective sac extraction method: Another minimally invasive procedure for inguinal hernia repair in children: A technical innovation with satisfactory surgical and cosmetic outcome. *J Pediatr Surg*. 2009;44:1666-71.
- [18] Riquelme M, Aranda A, Riquelme QM. Laparoscopic pediatric inguinal hernia repair: No ligation, just resection. *J Laparoendosc Adv Surg Tech A*. 2010;20:77-80.
- [19] Yip KF, Tam PK, Li MK. Laparoscopic flip-flap hernioplasty: An innovative technique for pediatric hernia surgery. *SurgEndosc*. 2004;18:1126-9.
- [20] Hassan ME, Mustafawi AR. Laparoscopic flip-flap technique versus conventional inguinal hernia repair in children. *JSLS*. 2007;11:90-3.
- [21] Kellnar S. Percutaneous laparoscopic hernia repair in children. *Zentralbl.Chir*. 2009;134:542-4.



- [22] Dutta S, Albanese C. Transcutaneous laparoscopic hernia repair in children: A prospective review of 275 hernia repair with minimum 2 year follow up. *Surg Endosc.* 2009; 23:103–7.
- [23] Uchida H, Kawashima H, Goto C, Sato K, Yoshida M, Takazawa S, et al. Inguinal hernia repair in children using single-incision laparoscopic-assisted percutaneous extraperitoneal closure. *J Pediatr Surg.* 2010;45:2386–9.
- [24] Harrison MR, Lee H, Albanese CT, Farmer DL. Subcutaneous endoscopically assisted ligation (SEAL) of the internal ring for repair of inguinal hernias in children: a novel technique. *J Pediatr Surg.* 2005 Jul;40(7):1177-80.
- [25] Olguner M, Aktuq T, Akqur FM, Pabuccuoglu U. Experimental study investigating the feasibility of new method for laparoscopic indirect hernia repair. *J InvestSurg.* 1997;10:189–92.
- [26] Kato Y, Yamataka A, Miyano G, Tei E, Koga H, Lane GJ, et al. Tissue adhesives for repairing inguinal hernia: A preliminary study. *J Laparoendosc Adv Surg Tech.* 2005;15:424–8
- [27] Turial S, Kreutz M, Hausser S, Enders J, Schier F. CD rats as an animal model in the experimental study of laparoscopic hernia repair. *Eur J PediatrSurg.* 2010;20:330–3.
- [28] Cushieri A. Tissue adhesives in endosurgery. *Semin Laparosc Surg.* 2001;8:63–8.
- [29] Esposito C, Damiano K, Settimi A, De Marco M, Maglio P, Centonze A. Experience with use of tissue adhesives in pediatric endoscopic surgery. *SurgEndosc.* 2004;18:290–2.
- [30] Chan K.L., Tam P.K.H.: Technical refinements in laparoscopic repair of childhood inguinal hernias. *Surg Endosc* 2004 18: 957 – 60.
- [31] Chan KL, Chan HY, Hang Tam PK. Towards a near –zero recurrence rate in laparoscopic inguinal hernia repair for pediatric patients of all age. *J Pediatr Surg* 2007 42, 1993 – 1997
- [32] Schier F. Laparoscopic repair of inguinal hernias in *Atlas of Pediatric laparoscopy and thoracoscopy*. Edited by G.W. Holcomb III, K. E. Georgeson, S. S. Rothenberg. Saunders Elsevier. 2008. Pag: 195-198
- [33] Montupet P, Esposito C. Fifteen years experience in laparoscopic inguinal hernia repair in pediatric patients. Results and considerations on a debated procedure. *Surg Endosc.* 2011 Feb;25(2):450-3. doi: 10.1007/s00464-010-1188-6. Epub 2010 Jun 2
- [34] Matsuda T. Diagnosis and treatment of post-herniorrhaphy vas deferens obstruction. *Int J Urol* 2000 May; 7 Suppl: S35-8
- [35] Matsuda T, Muguruma K, Hiura Y, Okuno H, Shichiri Y, Yoshida O. Seminal tract obstruction caused by childhood inguinal herniorrhaphy: results of microsurgical re-anastomosis. *J Urol.* 1998 Mar;159(3):837-40

- [36] Matsuda T, Horii Y, Yoshida O. Unilateral obstruction of the vas deferens caused by childhood inguinal herniorrhaphy in male infertility patients. *Fertil Steril* 1992; 58: 609-613
- [37] Choi W, Hall NJ, Garriboli M, Ron O, Curry JL, Cross K, Drake DP, Kiely EM, Eaton S, De Coppi P, Pierro A. Outcomes following laparoscopic inguinal hernia repair in infants compared with older children. *Pediatr Surg Int*. 2012 Dec;28(12):1165-9.