

# We are IntechOpen, the world's leading publisher of Open Access books Built by scientists, for scientists

6,900

Open access books available

186,000

International authors and editors

200M

Downloads

Our authors are among the

154

Countries delivered to

TOP 1%

most cited scientists

12.2%

Contributors from top 500 universities



WEB OF SCIENCE™

Selection of our books indexed in the Book Citation Index  
in Web of Science™ Core Collection (BKCI)

Interested in publishing with us?  
Contact [book.department@intechopen.com](mailto:book.department@intechopen.com)

Numbers displayed above are based on latest data collected.  
For more information visit [www.intechopen.com](http://www.intechopen.com)



---

# Telemedicine in Management of Retinoblastoma

---

Sarah MoranMichael O' Keefe

Additional information is available at the end of the chapter

<http://dx.doi.org/10.5772/57019>

---

## 1. Introduction

Retinoblastoma is a highly malignant tumor of the eye that manifests most often in the first 3 years of life. Early detection is essential to preserve visual function, and decrease mortality from retinoblastoma. Late diagnosis globally results in up to 70% mortality; where optimal therapy is accessible, more than 95% of children are cured.

Telemedicine has many possible applications in ophthalmology, from community screening to the provision of expertise in areas where it is otherwise not available. Broad-based applications of telemedicine could greatly enhance screening efforts for potentially blinding conditions such as diabetic retinopathy, macular degeneration, glaucoma, retinopathy of prematurity as well as retinoblastoma. In this chapter we discuss specifically the application of telemedicine in management of retinoblastoma. Telemedicine can help to bring subspecialty expertise to small or rural communities, as well as to the developing world.

## 2. Retinoblastoma

### 2.1. Epidemiology

Retinoblastoma is the most common intraocular malignancy of childhood.[1] It represents about 4% of all pediatric malignancies, and affects approximately 1 in 20,000 live births each year.[2] Most studies indicate that the incidence of retinoblastoma among various geographic populations is relatively constant. There is a 95% survival rate in developed countries, however the worldwide survival rate is closer to 50%. This is largely due to earlier detection in developed countries, when the tumor is still confined to the globe. This is in contrast to underdeveloped areas where retinoblastomas are often diagnosed at an advanced stage, when they have already invaded the orbit or brain.

## 2.2. Genetics

Retinoblastoma arises from malignant transformation of primitive retinal cells before final differentiation. It can be inherited as a familial tumor in which the affected child has a positive family history of retinoblastoma or as a non-familial (sporadic tumor) in which the family history is negative. Approximately 94% of newly diagnosed retinoblastoma cases are sporadic, and 6% are familial.

Retinoblastoma can be classified in 3 ways: familial or non-familial, heritable or non-heritable, unilateral or bilateral, however the 3 classifications are interrelated [3] Bilateral and familial retinoblastomas are caused by a germline tumor and are therefore heritable. Unilateral sporadic retinoblastoma is usually non-heritable, however it is estimated that 10-15% of children with unilateral sporadic retinoblastoma can have a germline mutation.

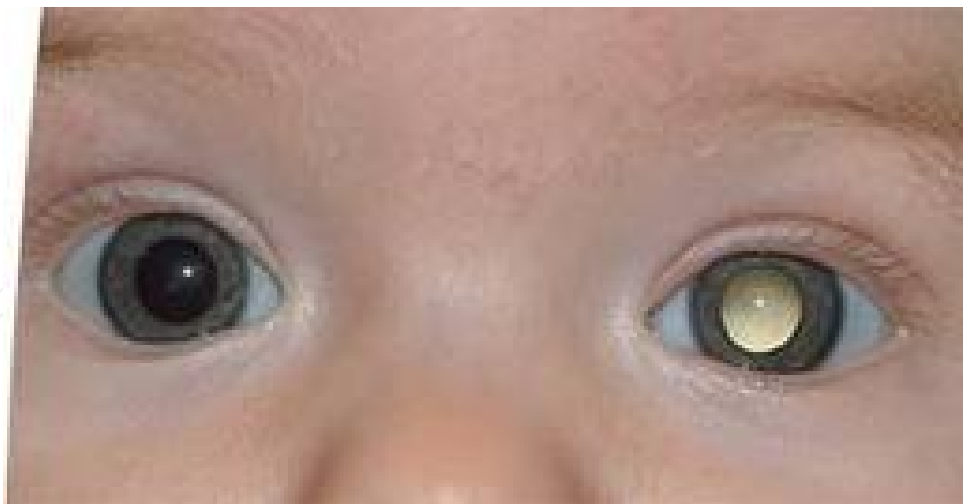The retinoblastoma gene is located on the long arm of chromosome 13 (13q14). In order for retinoblastoma to develop, both copies of the gene at the 13q14 locus must be affected. If either the maternal or paternal copy of the gene that is inherited by an individual is defective, then the individual is heterozygous for the mutant allele. Tumor formation requires both alleles to be mutant or inactive- the concept of the “two-hit” hypothesis of Knudson. In familial cases, all the retinal precursor cells contain the initial mutation, and when a second hit occurs, the cell undergoes malignant transformation. These children develop multifocal and bilateral tumors, and are at higher risk of non-ocular secondary tumors such as pinealoblastomas and osteosarcomas. In contrast, patients with unilateral sporadic retinoblastoma have normal chromosome structure elsewhere in the body and are at no higher risk of secondary tumors. In heritable retinoblastoma, the mutation is transmitted in 50%, but due to incomplete penetrance only 40% of offspring will be affected. If a child has heritable retinoblastoma, the risk to siblings is 2% if the parents are unaffected, and 40% if a parent is affected. In non-heritable cases the risk in each sibling and offspring is about 1%.

Genetic testing using DNA analysis of the patient’s tumor can help to identify those with a germline or heritable mutation. Heritable tumors account for approximately 40% of tumors with the remainder being non-hereditary.

## 2.3. Presentation and clinical features

Presentation is usually within the first year of life if the tumor is bilateral or second year of life if the tumor is unilateral. Clinical features vary according to time of presentation. Leukocoria is the most common presenting feature (60%) and may be first noticed in family photographs. (Figure 1.) Strabismus is the next most common form of presentation (20%); therefore dilated fundal examination is mandatory in all cases of childhood strabismus. Retinoblastoma may also present with chronic uveitis, orbital inflammation, secondary glaucoma, or orbital invasion in advanced cases. Metastatic disease before the detection of ocular involvement is rare.

The growth pattern of retinoblastoma can be endophytic, exophytic, and intraretinal. Exophytic tumors grow from the retina outwards into the subretinal space, whereas endophytic tumors grow inward from the retina towards the vitreous cavity. Occasionally the retinoblas-



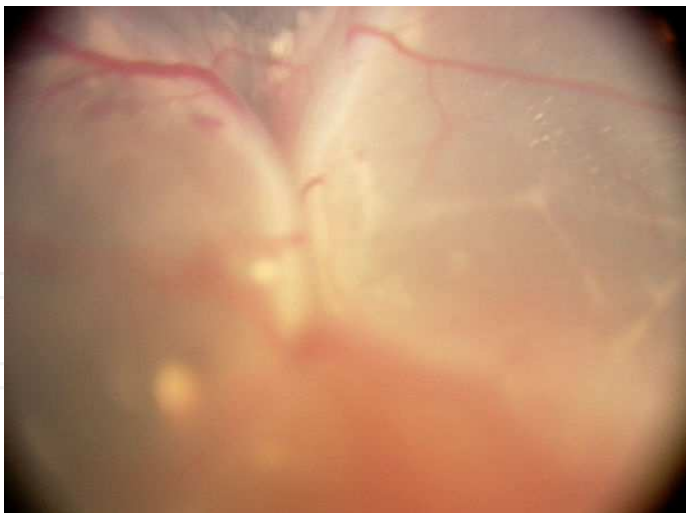
**Figure 1.** Leukocoria in a child with Retinoblastoma

toma can have a diffuse infiltration pattern, which manifests as a relatively flat infiltration of the retina without an obvious tumor mass.

<b>Group 1:</b> Very favorable for maintenance of sight
A. Solitary tumor, smaller than 4 disc diameters (DD), at or behind the equator.
B. Multiple tumors, none larger than 4 DD, all at or behind the equator.
<b>Group 2:</b> Favorable for maintenance of sight
A. Solitary tumor, 4 to 10 DD at or behind the equator
B. Multiple tumors, 4 to 10 DD behind the equator.
<b>Group 3:</b> Possible for maintenance of sight
A. Any lesion anterior to the equator.
B. Solitary tumor, larger than 10DD behind the equator.
<b>Group 4:</b> Unfavorable for maintenance of sight
A. Multiple tumors, some larger than 10 DD.
B. Any lesion extending anteriorly to the ora serrata.
<b>Group 5:</b> Very unfavorable for maintenance of sight
A. Massive tumors involving more than one half the retina.
B. Vitreous seeding.

The system was designed to predict outcome from treatment with external beam radiotherapy (EBRT), used internationally as the primary eye salvage treatment until introduction of chemotherapy in the 1980s.

**Table 1.** Reese-Ellsworth Classification



**Figure 2.** Group V Tumor Left Eye on Presentation (December 2011) The eye was subsequently enucleated.

The International Classification for Intraocular Retinoblastoma is a newer staging system. It divides intraocular retinoblastomas into 5 groups, labeled A-E, based on the chances that the eye can be saved using current treatment options.

**Group A**

Small tumors away from foveola and disc

- Tumors <3mm confined to retina
- Located at least 3mm from foveola and 1.5mm from optic disc

**Group B**

All other tumors confined to the retina.

- Subretinal fluid <3mm from base of tumor

**Group C**

Local subretinal fluid or vitreous seeding

- Subretinal fluid alone >3mm and <6mm from tumor
- Vitreous or subretinal seeding <3mm from tumor

**Group D**

Diffuse subretinal fluid or seeding

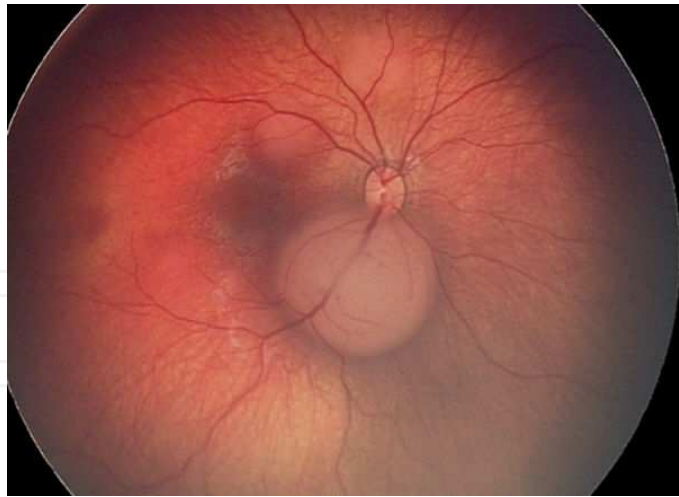
- Subretinal fluid >6mm from tumor
- Vitreous or subretinal seeding >3mm from the tumor

**Group E**

Presence of 1 or more of following poor prognostic features

- More than two-thirds of the globe filled with tumor
- Tumor in anterior segment or anterior to vitreous
- Tumor in/on ciliary body
- Iris neovascularization
- Neovascular glaucoma
- Opaque media from hemorrhage

**Table 2.** International Classification of Retinoblastoma



**Figure 3.** Fellow eye of the same patient: Multiple Tumors in Right eye at time of presentation (December 2011)

## 2.4 Differential diagnosis

Approximately 50% of patients diagnosed with possible retinoblastoma prove to have simulating conditions and not retinoblastoma. [4] Differential diagnoses include Persistent Hyperplastic Primary Vitreous, Coats disease, and ROP. It is essential to establish the diagnosis of retinoblastoma prior to commencing treatment.

## 2.5 Diagnosis

Diagnosis is established through a combination of history and physical examination, usually requiring binocular indirect fundoscopy with scleral indentation. This is generally performed under anesthesia to precisely determine the number and location of tumors. An experienced examiner can establish the diagnosis based on the clinical appearance of the tumor. Ancillary diagnostic studies can be helpful if the diagnosis is uncertain. Ultrasonography and computed tomography can demonstrate the mass and detect presence of calcium. Magnetic resonance imaging is of value for assessing the optic nerve, orbit, and brain and evaluating spread outside the globe.

## 3. Management of retinoblastoma

The primary objective in management of retinoblastoma is survival of the child, and secondly the preservation of the globe. After safety of the patient and the globe is established comes the focus on maintaining visual acuity. Treatment is tailored to each individual case, and there are several options. Intraocular retinoblastoma continues to be managed

with a wide range of treatment modalities including cryotherapy, laser photocoagulation, transpupillary thermotherapy, brachytherapy, external beam radiation, and enucleation. Newer treatment modalities include intra-vitreous and subconjunctival chemotherapy for advanced tumors, and the recently described technique of ophthalmic artery catheterization with chemotherapy infusion. [5, 6, 7]

The approach to retinoblastoma management has changed significantly over the last 10 years, with a move away from external beam radiation and increased use of focal treatment methods and chemoreduction. It has been well demonstrated that patients with germline tumors are at increased risk of developing secondary cancers if they receive external beam radiation. In recent years, eyes with unilateral retinoblastoma are generally managed with enucleation if the eye is classified as Reese-Ellsworth group V. For those eyes in group I-IV, chemoreduction or focal treatment is used. In bilateral cases, chemoreduction is used in most cases unless there is very asymmetric disease.

### **3.1. Chemoreduction**

Chemoreduction is a method of reducing tumor volume to allow for focal therapeutic measures such as cryotherapy or laser photocoagulation. This approach helps to preserve vision and avoid external beam radiotherapy. Tumors may show dramatic response in the first few months of treatment, however they will recur if treatment is not consolidated with local methods. Choice of agents as well as number and frequency of cycles varies between institutions. The main problem with chemoreduction is the recurrence of vitreous or subretinal seeds, which may respond to initial chemoreduction, but later recur.

### **3.2. Periocular chemoreduction**

Local periocular chemotherapy can be administered in the subconjunctival or subtenon space. For children with advanced retinoblastoma, systemic chemoreduction with a local periocular boost of subconjunctival or subtenon chemotherapy can be used in advanced tumors. If used alone, recurrence is inevitable, therefore, periocular chemotherapy is combined with systemic chemotherapy for best results. For small volume intraocular retinoblastomas, focal therapy may be potentially curative but can threaten vision if the tumor is adjacent to the macula or optic nerve. In these cases, periocular chemoreduction can be effective whilst avoiding systemic chemotherapy or damaging vision using focal therapies.

### **3.3. Intravitreal chemotherapy**

The use of intravitreal chemotherapy was pioneered by Ericson and Rosengren, [8] and has been studied extensively in animal models. It is widely used in Japan but has largely been avoided elsewhere due to concerns regarding tumor seeding. A recent technique has described combining the intravitreal injection with a bleb of subconjunctival chemotherapy to avoid tumor seeding.[9]

### 3.4. Intra-arterial chemotherapy

The concept of intra-arterial chemotherapy for retinoblastoma was introduced more than 50 years ago, when the alkylating agent triethylene melanamine was used via puncture sites in the carotid artery in the side of the eye to be treated.

Most recently, the technique of supraselective intraarterial chemotherapy appears to significantly improve the prognosis for eye preservation (70-80%) of group D eyes. [10, 11] Currently this treatment is employed in retinoblastoma patients as primary treatment for unilateral or bilateral retinoblastoma and as secondary treatment following failure from other treatments. This technique allows selective delivery of chemotherapy to the eye with minimal systemic absorption. The dose delivered to the eye is 10 times that achieved with systemic chemotherapy. This high dose of chemotherapy delivered to the eye accelerates regression of tumor and seeds. The chemotherapy infusion has to be repeated every 3-4 weeks for up to 3-6 injections for complete regression of tumor. Cannulation of the ophthalmic artery is difficult in children particularly in infants less than 6 months and requires surgical expertise and precision. As it is an invasive procedure the risk of neurological complications has to be considered though they are rare.

### 3.5. Focal therapy

Modalities of focal therapy include laser photocoagulation, cry therapy, thermotherapy, and plaque radiotherapy. These are mostly used for small tumors, in particular those which have been already reduced by chemo reduction.

#### 3.5.1. Laser photocoagulation

Laser photocoagulation is usually employed for small tumors posterior to the equator of the eye. It tends not to be used in conjunction with chemo reduction as its success depends on vascular coagulation and tumor ischemia, which is the opposite case for chemoreduction. It is performed using argon or diode laser, with two rows of photocoagulation surrounding the tumor base. The tumor itself is avoided as this could lead to vitreous seeding. It is repeated at approximately 1-month intervals for 3 sessions.

#### 3.5.2. Cryotherapy

Cryotherapy was first introduced by Linkoff in 1967. It causes cell death by destroying circulation during the freeze, via damage to the vascular endothelium and decreased blood flow. This is a useful treatment for equatorial and peripheral small retinoblastomas. The tumor is destroyed with one or two sessions of triple freeze-therapy. It is an important method of tumor consolidation following chemoreduction, and is especially useful for management of recurrent subretinal seeds near the ora serrate

#### 3.5.3. Thermotherapy

Thermotherapy coupled with chemoreduction is suited for tumors adjacent to the fovea and optic nerve where radiation or laser would possibly induce visual loss. It involves

heating the tumor using a diode infrared laser system, and is usually performed in conjunction with chemoreduction.

#### *3.5.4. Plaque radiotherapy*

This is a form of brachytherapy in which a radioactive implant is placed on the sclera over the base of a retinoblastoma. An average of 2 to 4 days of treatment time is required to deliver the total radiation dose to the tumor. It is useful for tumors less than 8mm thick and 16mm in base. Plaque radiotherapy can be used as a primary or secondary treatment. In the majority of cases it is used as a secondary treatment to salvage a globe after prior failed treatment. The visual outcome varies with tumor size and location as well as side effects such as radiation retinopathy and papillopathy. Overall following 1 application of plaque radiotherapy there is an approximately 80% tumor control rate at 4 years.[13]

### **3.6. External beam radiotherapy**

Retinoblastoma is generally a radiosensitive tumor. External beam radiotherapy is a method of delivering whole eye irradiation to treat advanced retinoblastoma, particularly when there is advanced vitreous seeding. Recurrence of retinoblastoma after external beam radiation is a problem that can develop in the first 1 -4 years after treatment. Radiation damage to the retina, optic nerve, and lens can be challenging to manage.

External beam radiation was once employed in a large percentage of patients but has fallen out of favor, largely because external beam radiation has the potential to increase the risk of the development of additional nonocular cancers in survivors of germline retinoblastoma. It is estimated that the risk approximates 1% per year of life.[13] Patients who develop a second cancer and then survive that cancer have an increased risk for the development of nonocular tumors of approximately 2% per year from the time of the second tumor diagnosis. The average latency period between subsequent tumor diagnoses becomes progressively less with each additional cancer that develops. Children radiated during the first year of life are between 2-8 times as likely to develop second cancers as those radiated after the age of 1 year.

Nonetheless external beam radiation remains an excellent method of preserving vision in a child with retinoblastoma, and certain clinical situation demand its use. Unlike focal therapies, external beam radiation can provide an excellent opportunity for useful vision in a macula that is not affected by tumor. It may be considered as a primary option in children with small tumors located within the macula, or for multifocal tumors where focal therapies are ineffective. External beam radiation also continues to be the salvage treatment of choice after focal treatments have failed. For children with advanced extraocular or metastatic disease, radiation can also play a role in palliation along with chemotherapy.

### **3.7. Enucleation**

Enucleation continues to be a frequently used and important method for managing retinoblastoma. If there is advanced disease with no hope for useful vision in the affected eye, or there is concern regarding tumor invasion into the optic nerve, choroid or orbit, then enuclea-

tion is appropriate. Also best considered for enucleation, are children with secondary glaucoma, pars plana seeding, or anterior chamber seeding, Over 99% of patients with unilateral retinoblastoma without microscopic or macroscopic extraocular disease are cured by enucleation. The technique of enucleation is to gently remove the eye intact without seeding any malignant cells into the orbit.

## **4. Telemedicine in management of retinoblastoma**

### **4.1. Telemedicine**

Telemedicine can be defined as the delivery of healthcare and sharing of medical knowledge over distance using telecommunication means. It is used to support health care between participants who are separated from each other.[14] It has the potential to improve the accessibility, quality, and cost of healthcare, and may also contribute to medical education and research. The concept of telemedicine was introduced about 30 years ago through the use of telephones and facsimile machines. However today, telemedicine has advanced, integrating medical and network technology, comprising remote diagnosis, expert consultation, information service, online checkups, and remote communication.

Telemedicine can be broadly divided into two categories: synchronous telemedicine uses telecommunications for real-time interactions between participants (i.e. Videoconferencing), as compared to store-and-forward telemedicine which captures patient data for subsequent interaction with a remote expert (i.e. Digital radiology)

### **4.2. Applications in ophthalmology**

The potential benefits of an effective telemedicine system in ophthalmology are many. Telemedicine has a variety of possible applications in ophthalmology, from community screening to the provision of expertise in areas where it is otherwise not available. Broad-based applications of telemedicine could greatly enhance screening efforts for potentially blinding conditions such as diabetic retinopathy, macular degeneration, glaucoma, retinopathy of prematurity and retinoblastoma to name but a few. Telemedicine can bring subspecialty expertise to small or rural communities, as well as to the developing world.

Tele-medicine applications in ophthalmology comprise both clinical and educational processes between the send and receive sites. These can include:

- screening of a disease;
- formulation of a diagnosis and clinical management plan;
- secondary advice and support in clinical management plan;
- peer supervision and support;
- professional development through group discussion, lectures, and tutorials

- research and administration activities.

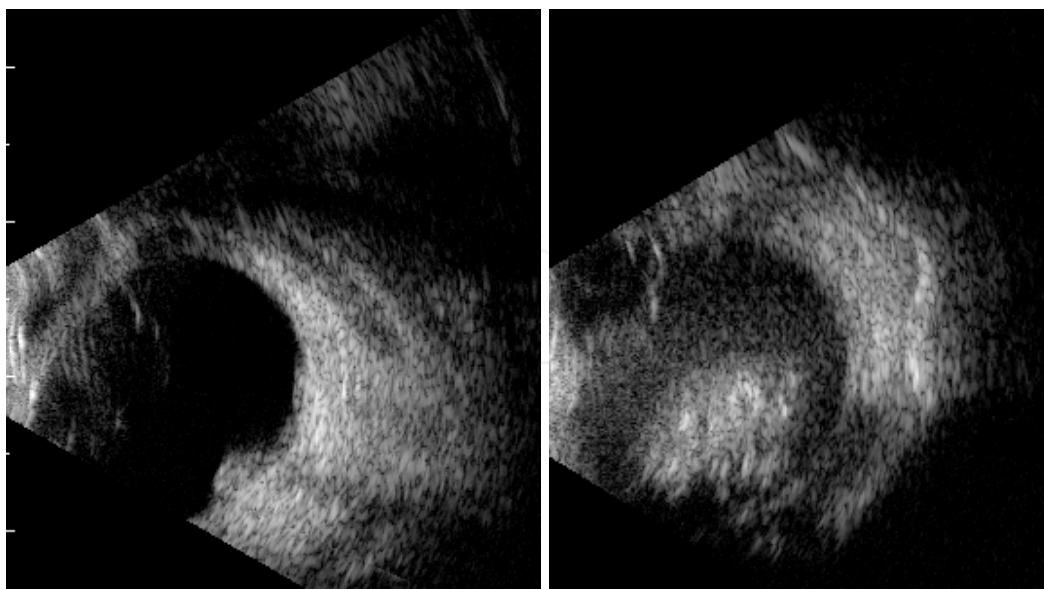
Typical telemedicine application in retinoblastoma includes the transfer of basic patient information, transfer of high resolution images such as fundal photographs, pathology images, magnetic resonance imaging pictures.

The use of telemedicine in retinoblastoma is not only useful to the specialist managing the condition, but is also of a source of confidence and comfort to parent and families of children with retinoblastoma to know that multiple experts are involved in the care of their child, and their child is receiving the best possible treatment.

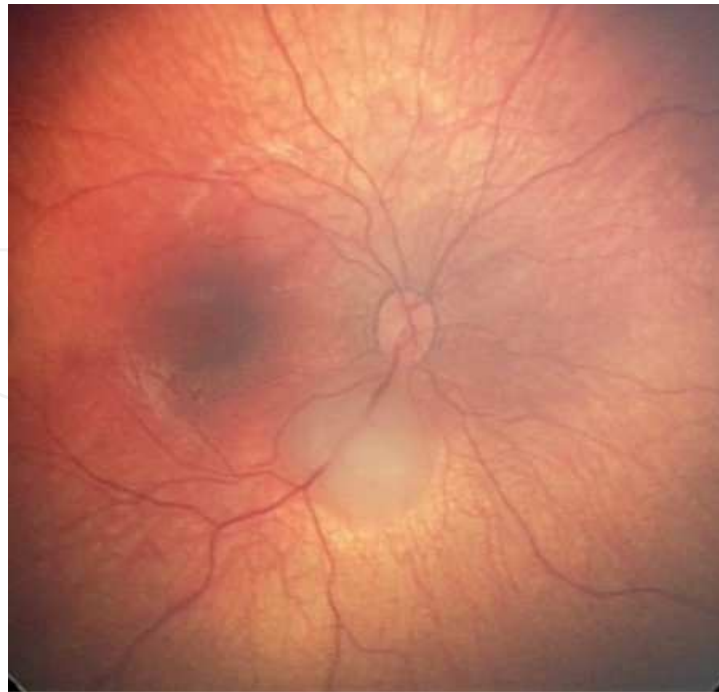
#### 4.3. Importance of imaging in management of retinoblastoma

The RetCam® wide-angle camera provides wide-field imaging of the retina and anterior segment, including the anterior chamber angle. Some small retinoblastomas, and vitreous seeds, may be better seen on RetCam® images than with indirect ophthalmoscopy. Sequential images are useful to determine if the tumors are growing or regressing. The anterior segment and anterior chamber angle can also be well visualized with the RetCam®. Fluorescein angiography using the RetCam® can assess vascularity, residual tumor activity, and recurrences within laser scars.

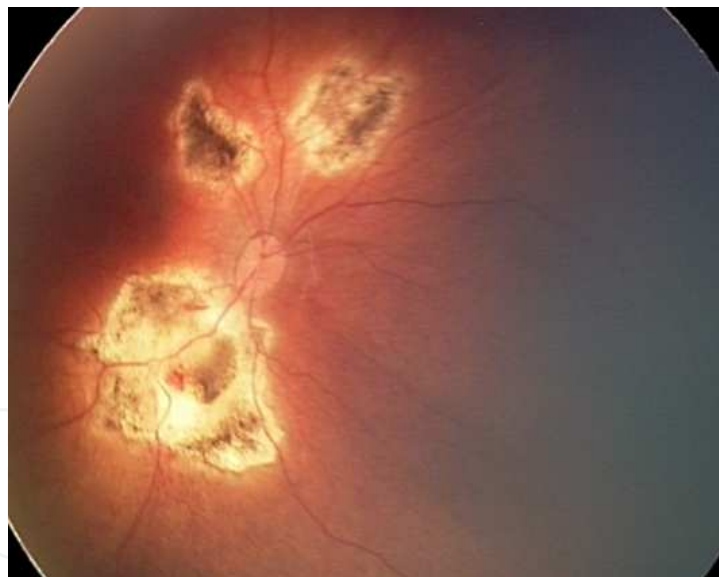
#### 4.4. Images used in telemedicine for the management of retinoblastoma



**Figure 4.** B scan ultrasonography of right and left eye of same patient at time of presentation in December 2011 showing multifocal tumors in the right eye, and the left globe filled with large tumor



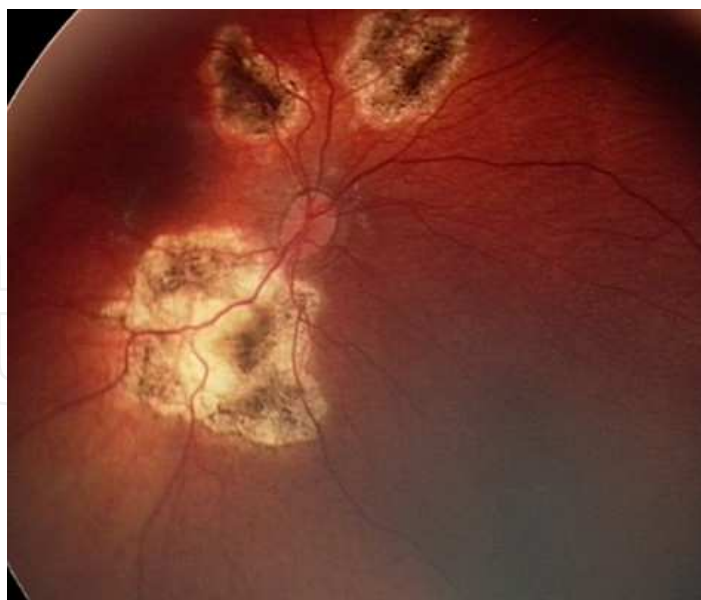
**Figure 5.** Right Fundus following chemoreduction February 2012



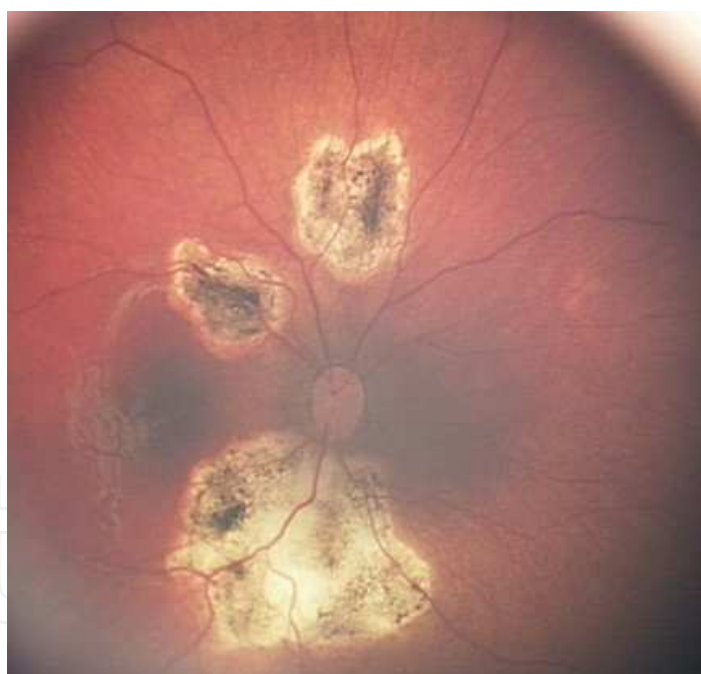
**Figure 6.** May 2012: Images of the right eye during treatment with chemoreduction and focal therapy with laser photocoagulation

#### *4.4.1. Diagnosis*

Telemedicine is invaluable when the diagnosis of retinoblastoma is in doubt. Diagnosis is generally established by the classic appearance of the retinal tumors by an experienced examiner. The sooner the diagnosis is established the sooner the appropriate treatment can be implemented and the better the prognosis.

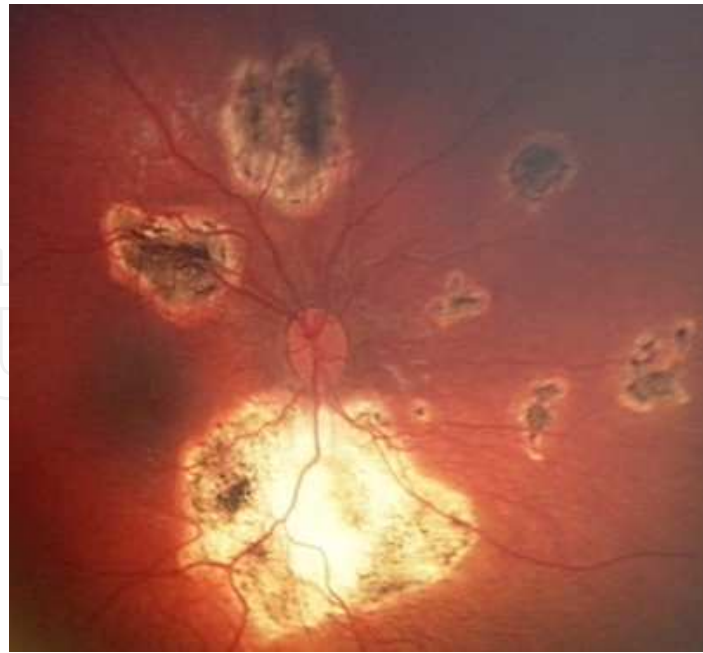

**Figure 7.** June 2012: Image from examination under anesthesia following chemoreduction and focal laser consolidation



**Figure 8.** August 2012. Fundal image from right eye following chemoreduction and focal laser photocoagulation

In our experience in the Children's University Hospital in Dublin, all new cases of retinoblastoma are discussed using an internet consultation service where fundus images, clinical history, and proposed treatment are reviewed with a leading expert in retinoblastoma in the Hospital for Sick Kids in Toronto, Canada. The diagnosis is confirmed, and a treatment plan is agreed upon. This ensures standards of retinoblastoma management are of the highest



**Figure 9.** September 2012. Fundal image from right eye taken during examination under anesthesia showing multiple treated areas and inactive tumor

quality, and the most up-to-date treatments are employed. Selected cases may be further discussed via videoconferencing and electronic mail.

#### **4.5. Treatment planning**

As discussed earlier there are multiple treatment modalities available to treat retinoblastoma. Treatment plans tailored to specific cases can be formulated between experts in different countries by sharing medical knowledge and experiences. Remote experts can closely monitor the progress of patients by sharing fundus images and other clinical information. In difficult cases, or cases requiring enucleation it is especially useful to have the second opinion of an objective expert to ensure the best possible care is delivered.

#### **4.6. Cost effectiveness**

The relatively small numbers of retinoblastoma patients worldwide means that ophthalmologists and oncologists in developing countries are unlikely to have the experience to treat without expert advice. As this is a curable disease, efforts toward early diagnosis and treatment are not only worthwhile, but cost effective. In countries with limited resources especially, telemedicine provides invaluable support and advice. For example, a telemedicine programme for retinoblastoma has been implemented in Jordan and has improved treatment and survival for children in that country. The RetCam allows for real-time teleconferencing.

There are strong arguments for tackling long term conditions to improve quality of life, while being mindful of the need to contain costs. In particular, there is considerable interest in the potential of telemedicine to generate cost effectiveness gains and even to yield cost savings,

while maintaining or improving patient outcomes. Evidence on the cost-effectiveness of telehealth is accumulating; systematic reviewers have judged it as promising for managing respiratory and cardiac disease and diabetes. Although evidence of the effect of telemedicine on retinoblastoma cost effectiveness remains scarce, it is promising.

#### 4.7. Medico-legal aspects

##### 4.7.1. *Protocols for telemedicine*

To avoid medico-legal pitfalls, comprehensive policies should be in place to ensure that patients receive the maximum benefit.

The limits of a telemedicine should be clarified. It is important to identify and outline the responsibilities of everyone in who is involved in telemedicine interactions to ensure seamless patient management. The credentials and insurance coverage of all licensed practitioners involved in telemedicine applications should be clear. Failure to verify the credentials of a consulting specialist could lead to claims of negligent referral if there is an adverse outcome.

The accepted “standard of care” for telemedicine in the relevant area should be identified. The process for assuring confidentiality of patient information should be outlined including: security and retention protections for electronic communication; protocols for identifying people at distant locations; confidentiality agreements for third-parties; compliance with confidentiality, and patient informed consent.

It is necessary also to outline standards for image acquisition, resolution bandwidth, transmission, storage resolution, method and time, retrieval, and manipulation, and to have backup procedures in place in case of equipment failure, weather interference, or other emergency.

## 5. Summary

Retinoblastoma is the most common intraocular cancer of childhood; it continues to be a challenge both diagnostically and therapeutically. Telemedicine has a large role to play in the diagnosis and management of this retinoblastoma. In our experience, telemedicine enables invaluable expert collaboration to ensure the best outcomes for patients with retinoblastoma. Telemedicine has many potential applications in retinoblastoma management, both in the developing and developed world.

## Author details

Sarah Moran Michael O' Keefe

Mater Private Hospital, Dublin, Ireland

## References

- [1] Shields JA, Shields CL. Management and prognosis of Retinoblastoma. In: *Intraocular Tumors: A text and Atlas*. Philadelphia, Pa: WB Saunders; 1992.
- [2] Devesa SS. The incidence of retinoblastoma. *Am J Ophthalmol*. 1975;80:263-265.
- [3] Shields CL, Shields JA. Genetics of Retinoblastoma. In: Tasman WS, Jaeger E, eds. *Duane's foundations of Clinical Ophthalmology*. 3<sup>rd</sup> ed. Philadelphia, Pa: Lippincott Williams and Wilkins; 2002.
- [4] Shields JA, Parsons HM, Shields CL, et al. Lesions simulating retinoblastoma. *J Pediatr Ophthalmol Strabismus*. 1991;28:338-340.
- [5] Aziz HA, Boutrid G, Murray TG, et al. Supraselective injection of intra-arterial melphalan as the primary treatment for late presentation of unilateral multifocal stage Vb retinoblastoma. *Retina* 2010;30:S63-5
- [6] Abramson DH, Dunkel IJ, Brodie SE, et al. A phase I/II study of direct intraarterial (ophthalmic artery) chemotherapy with melphalan for intraocular retinoblastoma: initial results. *Ophthalmology* 2008;115:1398-404
- [7] Shields CL, Ramasubramanian A, Rosenwasser R, et al. Supraselective catheterization of the ophthalmic artery for intrarterial chemotherapy for retinoblastoma. *Retina* 2009;29:1207-9
- [8] Ericson LA, Rosengren BH. Present therapeutic resources in retinoblastoma. *Acta Ophthalmol* 1961;39:569-76
- [9] Smith SJ, Pulido JS, Salomao DR et al. Combined intravitreal and subconjunctival carboplatin for retinoblastoma with vitreous seeds. *Br J Ophthalmol* 2012;96:1073-1077
- [10] Shields CL, Bianciotto CG, Jabbour P, et al. Intra-arterial chemotherapy for retinoblastoma: Report No. 4, Control of retinal tumors, subretinal seeds, and vitreous seeds. *Arch Ophthalmol* 2011;129:399-406
- [11] Munier FL, Beck-Popovic M, Balmer A, et al. Occurrence of sectoral choroidal occlusive vasculopathy and retinal arteriolar embolization following supraselective ophthalmic artery chemotherapy for advanced intraocular retinoblastoma. *Retina* 2011;31:566-73
- [12] Shields CL, Shields JA, Cater J et al. Plaque radiotherapy in the management of retinoblastoma: long-term tumor control and treatment complication in 208 tumors. *Ophthalmology*. 2001;108:2116-2121
- [13] Abramson DG, Ellsworth RM. The surgical management of retinoblastoma. *Ophthalmic Surg* 1980;11(8):596-8

- [14] Field MJ. Telemedicine: a guide to assessing telecommunication in healthcare. J Digit Imaging. 1997;10 (3 Supp;1):28

IntechOpen

IntechOpen