

# We are IntechOpen, the world's leading publisher of Open Access books Built by scientists, for scientists

6,900

Open access books available

186,000

International authors and editors

200M

Downloads

Our authors are among the

154

Countries delivered to

TOP 1%

most cited scientists

12.2%

Contributors from top 500 universities



WEB OF SCIENCE™

Selection of our books indexed in the Book Citation Index  
in Web of Science™ Core Collection (BKCI)

Interested in publishing with us?  
Contact [book.department@intechopen.com](mailto:book.department@intechopen.com)

Numbers displayed above are based on latest data collected.  
For more information visit [www.intechopen.com](http://www.intechopen.com)



---

# Experience in the Use of Barbed Threads and Non-Barbed Serdev Sutures in Face and Body Lift – Comparison and Combination

---

Vilma L. Padín

Additional information is available at the end of the chapter

<http://dx.doi.org/10.5772/51399>

---

## 1. Introduction

### 1.1. Barbed threads

This technique created by George Sulamanidze uses barbed non sutured monofilament polypropylene threads called APTOS (Polypropylene sutures were modified by designing many dents along their lengths. These “APTOS” threads hold tissue firmly because of the sharp edges to the dents) [1] and allows to relieve facial soft tissue ptosis when it is light or moderate. With this method is possible to lift different areas of the three thirds of the face. This is a simple technique with simple instrumentarium. We use a modification of barbed Aptos threads called Fiberlift® (Firming threads, Multifix threads, and Fiberlift threads). These threads have bidirectional cogs and multidirectional cogs to get the lifting effect of the tissue and a new collagen generation. Barbed polypropylene threads are inserted through the fat tissue with only a long and thin (21 Gx2 or 21 Gx3.5) needle as a guide. These polypropylene barbed threads may be used in face, neck and body lift. This simple and non recovery time procedure, without incisions or scars, achieves to lift and gives new volume and contour with few complications and long lasting results. They get an adequate position of the soft tissue which decreases lymphatic stasis, improves oxygenation, provides energy and stimulates the muscles recovering the normal tissue metabolism and slowing the aging process [2]

### 1.2. Serdev sutures

The use of Serdev sutures in face lift treatments allows us to lift one mobile tissue, the SMAS, and carry it to a non movable point, stable fibrotic and fascia structures, using polycaproamide Serdev sutures and a Serdev special flexible, curved and semi elastic needle. [3] These methods may be done to lift several areas of the face, neck and body. We have experience in temporal

face lift, medial face lift, brow lift, chin enhancement and buttock lift with Serdev sutures. These procedures are simple without scars and uncomplicated in the postoperative time and they get aesthetic proportions, aesthetics angles and aesthetic volumes avoiding the “operated look.”

Since the year 2000, we have been practicing with the procedures of mini-invasive lifting with Aptos barbed *threads* (George Sulamanidze) and *sutures* (Nikolay Serdev). In the past it was believed that such techniques were only fashionable in the field of cosmetic surgery. After using these methods for 12 years and seeing the positive results in our patients not only within my country but in foreign countries as well, it has come to my attention that “threads” are not something in vogue but are here to stay for good as an important feature in mini-invasive cosmetic surgery. Proof of clinic results, photo images, dermatological examinations and patients’ approval after 5 years should establish that lifting with threads and sutures are highly effective; no surgery marks or scars, natural results without undergoing an operation or post operative. It enables the patient to return to work immediately. Through the simple method of “barbed or anchorage threads” the results that are obtained show that reaching beauty may be a simple medical procedure, non invasive, responsible, ethical, in accordance with the physical and spiritual integrity of the patient. The facial softness treatment with the application of both barbed threads or Serdev sutures or their combination allows us to fulfill the requirements that nowadays the patients ask for daily in our clinic.

### 1.3. Materials

1. Polypropylene 2.0 Barbed threads are used with converging cogs called “FIRMING THREADS” (by Fiberlift®)



Source: Proesteticamed, 2003

**Figure 1.** Firming thread

- Monofilament polypropylene 2.0
- Convergent cogs
- 6cm, 8cm, 10cm long
- 4 or 6 units pack

2. Polypropylene 2.0 Barbed threads with multi-directional cogs, 2cm right section, and 2 cm left section called “MULTIFIX.” (by Fiberlift®)

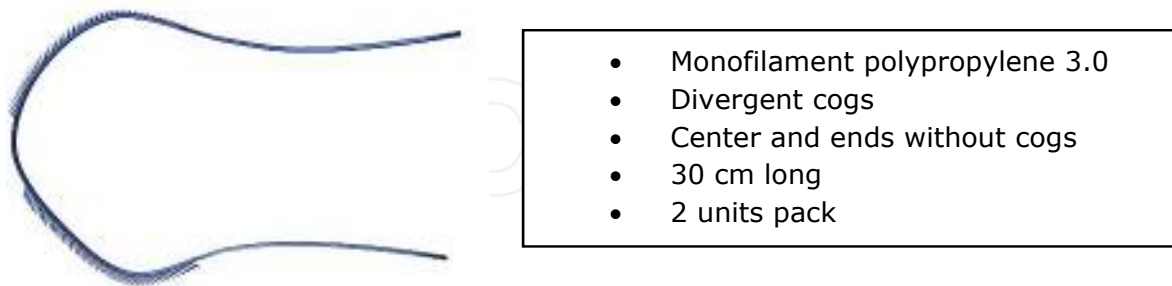


Source: Proesteticamed, 2006

**Figure 2.** Multifix thread

- Monofilament polypropylene 2.0
- Multi-directional cogs
- 12 cm long
- 4 units pack

3. Polypropylene 3.0 with diverging cogs in 2 stages, 3cm each one with one free central piece and 2 long plain ends, called “FIBERLIFT.” (by Fiberlift®)



Source: Proestheticamed, 2004

**Figure 3.** Fiberlift® thread

All these barbed threads are made in Argentina as a modification of Aptos Threads, and they are sterilized abiding by the ISO regulations.

4. Serdev Sutures (Semi elastic, braided, yellow polycapromide non barbed sutures)



Source: Ambulatory temporal SMAS lift by sutures with or without incisions IJCS 2001; 1(4):97-106

**Figure 4.** Serdev sutures

#### 1.4. Surgical instruments

- Halstead claw.
- Iris scissor.
- 21 Gx2 or 21 Gx3 needles.
- Syringe and 30 Gx½ needle for anesthesia.
- Lidocaine 2% with epinephrine.
- Special Serdev flexible needles in different sizes from a large to a mini- mini needle.



Source: Ambulatory temporal SMAS lift by sutures with or without incisions IJCS 2001; 1(4):97-106

**Figure 5.** Special Serdev elastic needles.

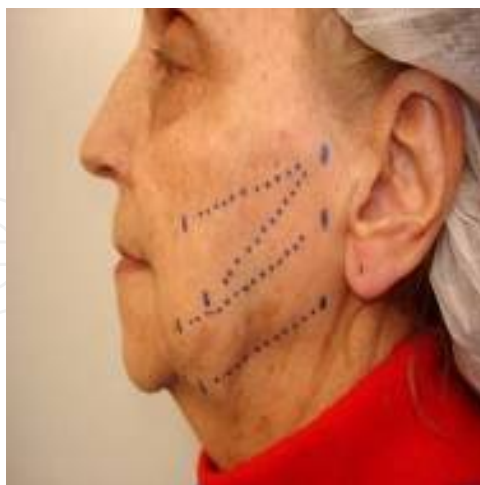## 2. Procedures

### 2.1. Barbed threads in face and body lift -

#### 2.1.1. Face lift

##### 2.1.1.1. Lower third and jawline

The aim of this technique is to lift and improve the contour of the lower third of the face and jawlines. We insert eight polypropylene barbed (4 on each side) FIBERLIFT® FIRMING THREADS between 8 to 10cm long in a simple procedure and without recovery time.[4]



Source: Personal archive

**Figure 6.** Patient's marcation for operation

##### 2.1.1.1.1. Materials

FIRMING THREADS: Polypropylene 2.0 barbed threads with convergent cogs.









Source: Proesteticamed, 2003

**Figure 7.** Firming thread with convergent cogs

2.1.1.1.2. Description of technique

<p>Step 1 First, we must take frontal and profile photographs.</p>	
<p>Step 2 Feel along the patient's face with our fingers and mark it. With this, an individual sketch is obtained.</p>	A photograph of a woman's face. A hand wearing a white glove is gently touching her cheek, likely feeling the skin texture or marking the area for the procedure.
<p>Step 3 Mark on the face of the patient the course of the thread drawing the shape of a "Z" on the lower third of the face, in the aim of inserting 2 barbed convergent parallel threads with a third one crossed in the form of an open Z.</p>	A photograph of a woman's face in profile. A black 'Z' mark is drawn on the lower third of her face, indicating the planned path for the thread insertion.
<div>A photograph of a woman's face in profile. A black 'Z' mark is drawn on the lower third of her face, indicating the planned path for the thread insertion.</div> <div><p>CORRECT "OPEN Z"</p><p>In this way we avoid deformation of the mouth</p></div>	A photograph of a woman's face in profile. A black 'Z' mark is drawn on the lower third of her face, indicating the planned path for the thread insertion.
<div>A photograph of a woman's face in profile. A black 'Z' mark is drawn on the lower third of her face, indicating the planned path for the thread insertion.</div> <div><p>INCORRECT "CLOSED Z"</p><p>In this way the mouth may be deformed</p></div>	
<p>Step 2 Paint the face with povidone.</p>	A photograph of a woman's face. A red, circular mark is visible on her cheek, indicating the application of povidone paint.



<p><b>Step 3</b> Inject the anesthesia only at the entrance and exit points. Use lidocaine 2% with epinephrine 0,5 c.c per point.</p>		
<p><b>Step 4</b> Tunnel from the external point to the internal one, with a 21 Gx2 needle. Parallel threads must be inserted 1 cm away from the nasolabial fold to preserve the natural form of the face.</p>		
<p><b>Step 5</b> Thread the barbed polypropylene thread, being careful with the cogs because they are convergent, so it's very easy to thread the first half but it is a little more complicated to pass the second half because the cogs are opposite to the sense of the needle. This situation is very easy to overcome by, with the use of a thicker needle. But using a 21 Gx2 needle we assured that the aesthetic results will be excellent and without scars.</p>		
<p><b>Step 6</b> Check that the thread is firm.</p>		
<p><b>Step 7</b> Remove the needle and the ends of the thread will be found outside the surface of the skin.</p>		
<p><b>Step 8</b> Cutting the thread. We must be very careful cutting the thread. The skin should be pushed down with the scissors. This simple switching enables us to cut the thread at a good position avoiding it getting long.</p>		

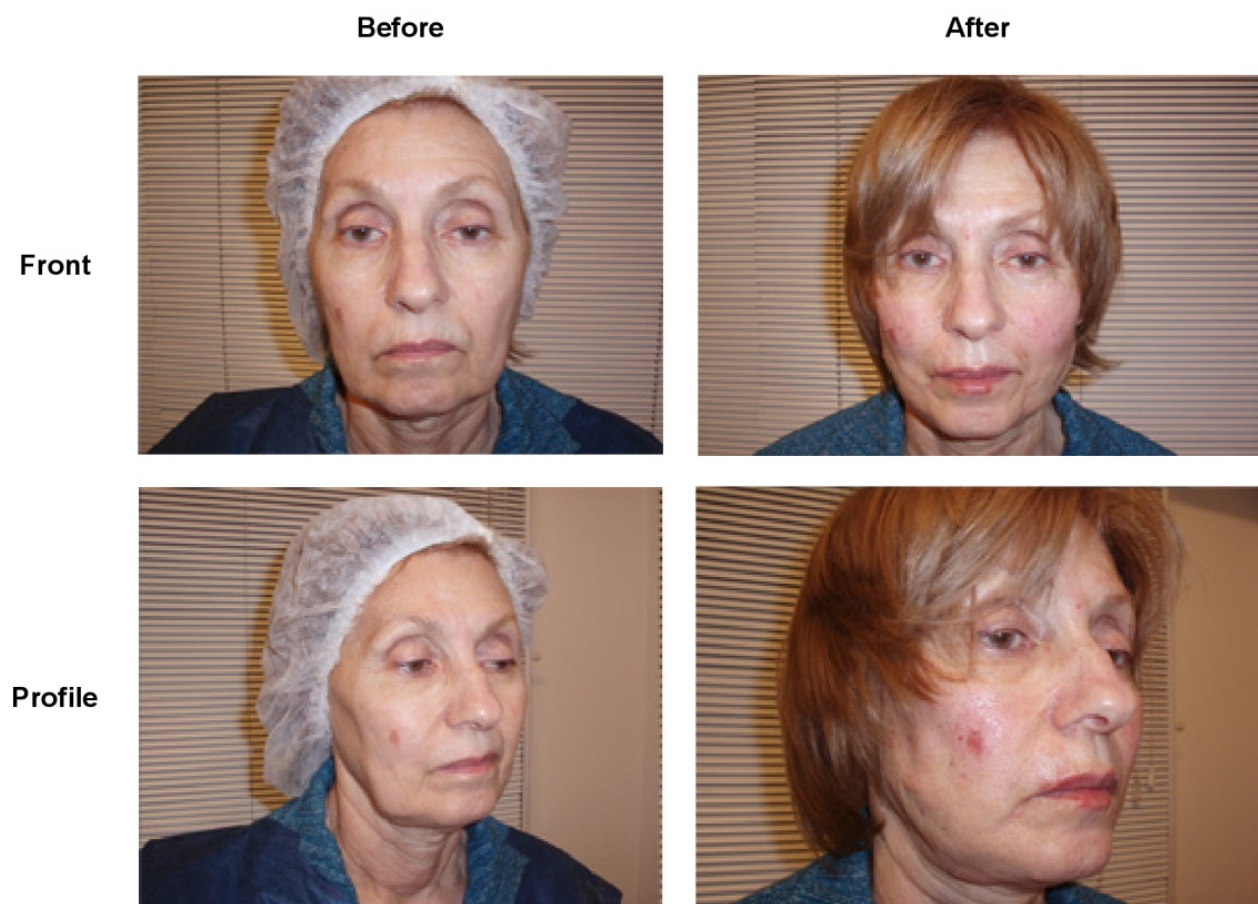Source: own elaboration using pictures of personal archive

**Scheme 1.** Lower Face Lift Technique with Barbed Threads

#### 2.1.1.1.3. Results

Barbed threads have two ways of acting. The first is the lifting effect given by the cogs. It is immediate. This effect is poor. The other action is delayed, due to the inflammatory reaction when the thread is placed, producing vas dilatation, increased capillary permeability, inflammatory exude that will be represented by leukocytes, erythrocytes, plasmatic proteins and fibrin which take us to the epitelization; that is: fibroblasts are generating collagen and elastine fibers.

So we can say that the barbed thread face lift has good results that change the angles of the face with an aesthetic expression, giving contour as well as improving the skin. Patients like this technique and ask for more threads. It is long lasting. Experienced doctors can insert more threads several times.



Source: own elaboration based on pictures from personal archive

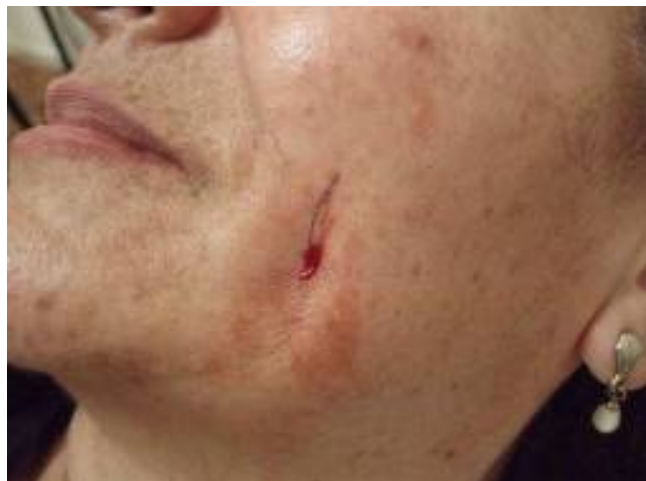**Figure 8.** Lower Face Lift Results

#### 2.1.1.1.4. Complications

This technique has few complications, one of them is cutting a long thread producing it to prick from within. This is the most common complication. Another one is the migration of the thread. We have had a 3% rate in migrations. Extrusion is unusual (1% of the cases). Another authors have found thread visibility, migration, and exposure; linear bleeding



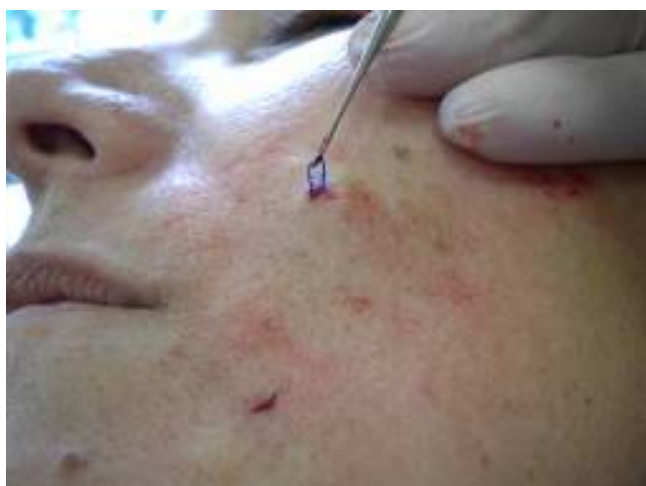along the needle course; skin dimpling; hypocorrection and hypercorrection; transient paresthesias; and a small number of cases of injury to major vessels, nerve branches, and parotid capsule/duct [5] mild asymmetry, ecchymosis, erythema, bleeding, swelling, and discomfort were the only minor. [6]



The most common complication is the thread cut long, so it pricks and we have to explore it. If the thread is anchored, we can keep it in the same place but if it is loose we have to remove and replace it.

Source: Personal archive

**Figure 9.** Thread cut long



A different way to remove a migrated thread. In this case with a crochet needle

Source: Personal archive

**Figure 10.** Removing a thread

#### 2.1.1.2. Medial third

The aim of this technique is to lift the cheek bone zone and indirectly also to improve the jawline and smoothing the folds. We insert one or two barbed multifixing thread of 12 cm. long, added to the above procedure in vertical form.

##### 2.1.1.2.1. Materials

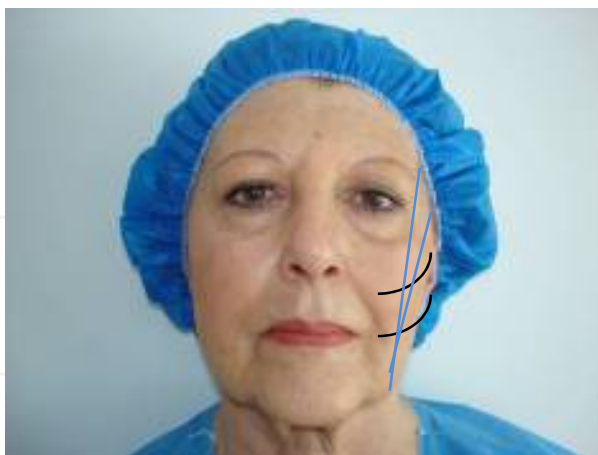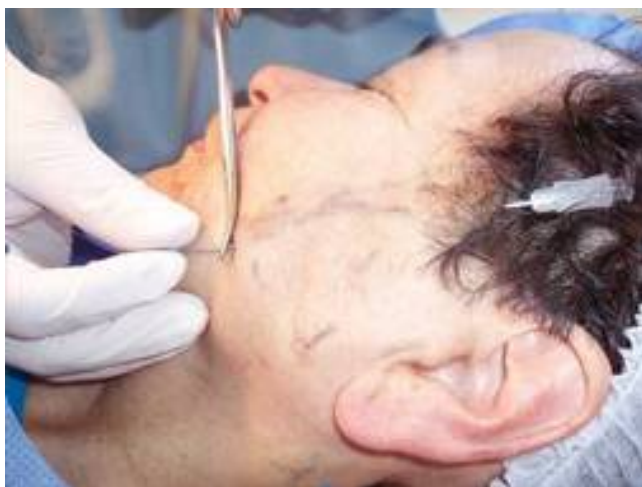FIBERLIFT® MULTIFIX THREADS: Polypropylene 2.0 barbed threads with multidirectional cogs.



Source: Proesteticamed, 2006

**Figure 11.** Multifix thread

This procedure allows us to lift the soft tissue and reshape the cheek bone too as well as smoothing the folds and commissures.



Source: Personal archive

**Figure 12.** Multifix thread located in vertical form with 21 Gx3 spinal needle

#### 2.1.1.2.2. Procedure

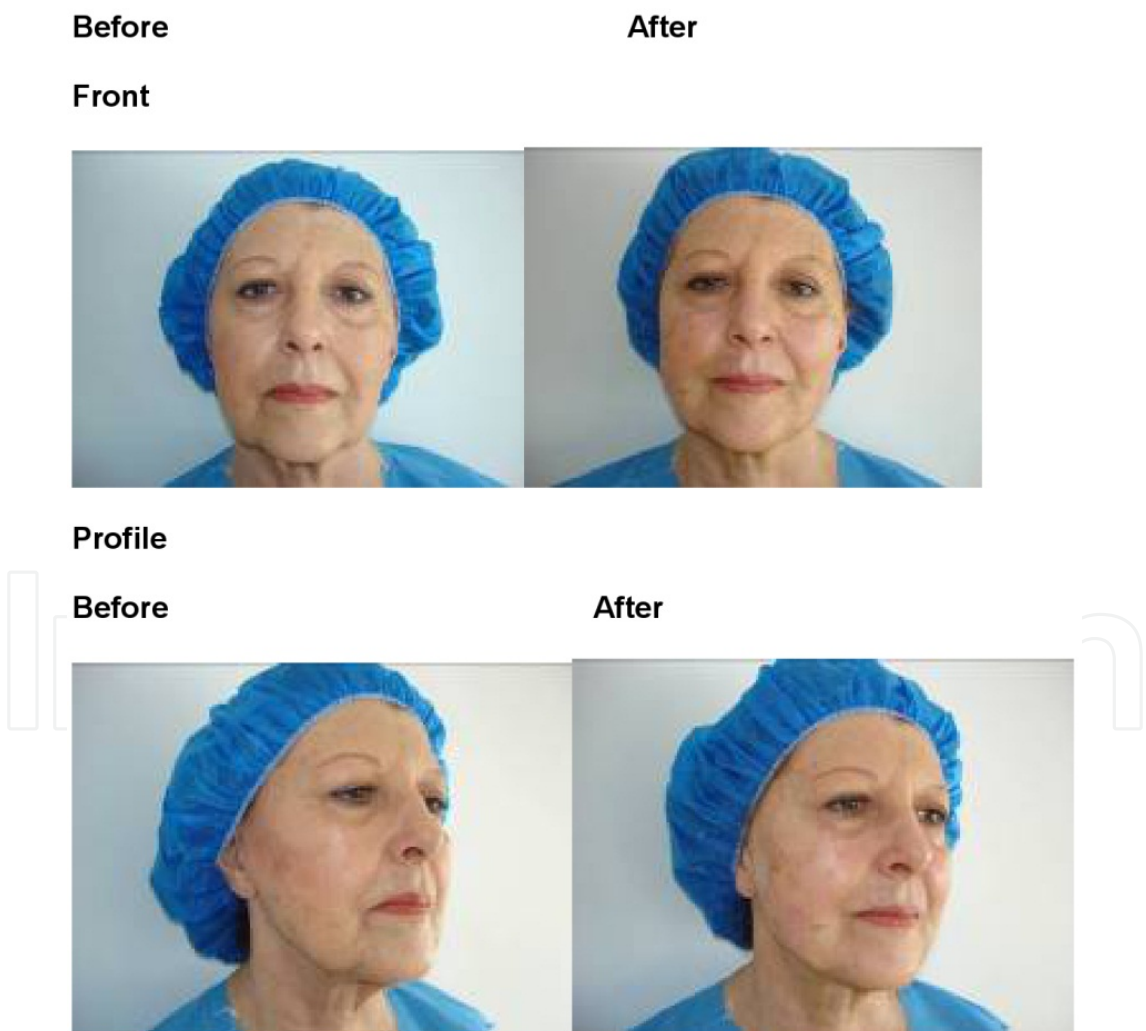One or two FIBERLIFT® MULTIFIX THREADS are placed in vertical form from the jawline to temporal zone with a 21 G x3 spinal needle, following the same procedure as in the case of Firming Threads.[7]

2.1.1.2.3. *Comparative study*

Between November 2006 and July 2007 we performed an 8-month study on 32 healthy patients of both sexes, ages ranging between 38 and 66 years old. On 16 of them, we had applied firming threads or anchorage threads as the only treatment. The other half of the patients was treated in the same form except for the extra plus combination of multifix threads. The following was observed:

The patients treated with multifix threads combined with firming threads or anchorage threads presented better results, longer lasting time span, a more important lift effect and a lower number of migrations and extrusions compared to those treated with only one technique. We think due to the multi-directional cogs because they do a more important anchorage surface.[5]

2.1.1.2.4. *Results*



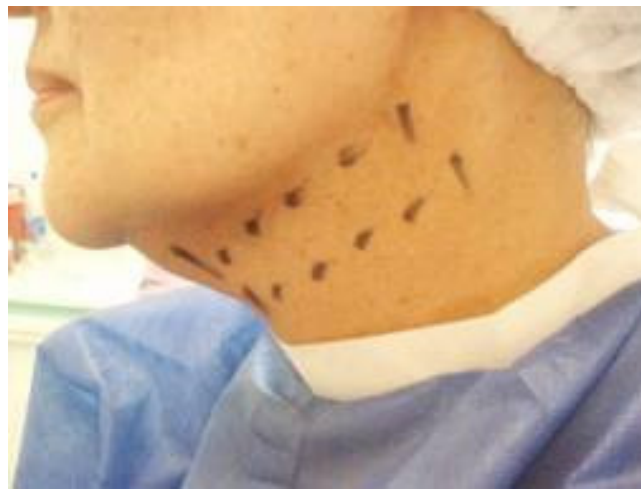Source: own elaboration based on pictures from personal archive

**Figure 13.** Multifix threads plus Firming threads. Results

### 2.1.1.3. Neck lift and double chin

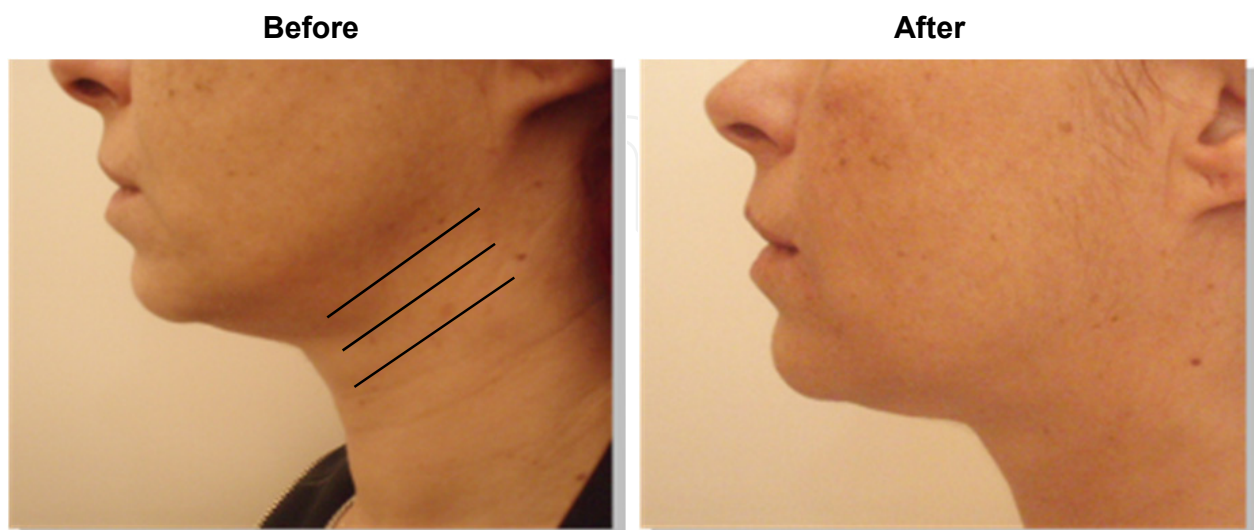
#### 2.1.1.3.1. With firming threads

We can improve the aging neck by using 2 or 3 barbed Firming Threads 10cm's long on both sides of neck. We prefer to place them 2cm away from the midline because we have seen a lot of extruded threads when placed from the midline to the sides. This treatment is good for the neck and double chin. It is simple and only local anesthesia is used, therefore improving 35% of the contour. It is ideal for those patients who elude operations and for those who are knowledgeable on the results attained by this technique. Firming threads are inserted with a 21 Gx2 needle. Entering at point two fingers below the edge of the mandible and below the earlobe, above the sternocleidomastoid muscle to a point located in the same line, 1 or 2cm outside the outer border of the central band of platysma.



Source: Personal archive

**Figure 14.** Marcation on the patient's neck




Source: Own elaboration based on pictures from personal archive

**Figure 15.** Neck Lift and Double Chin with barbed threads Results

### 2.1.1.3.2. With fiberlift®

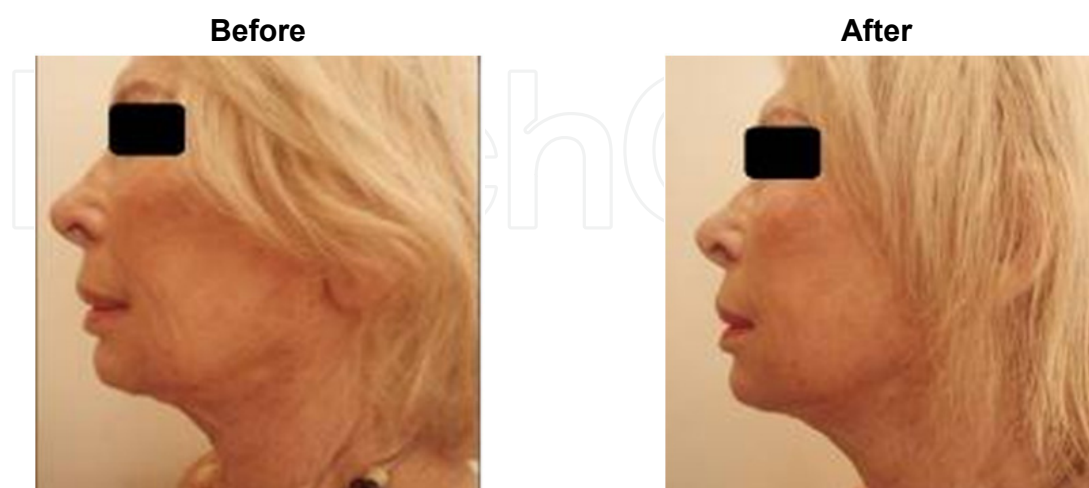FIBERLIFT THREAD (By Fiberlift®) is a barbed polypropylene 3.0, with divergent cogs. It is not an autosustentation thread but an anchorage one, 30cm long, with two parts each consisting of 3cm with divergent cogs separated by a smooth area and two smooth ends.



Source: Proestheticamed, 2004

**Figure 16.** Fiberlift® thread

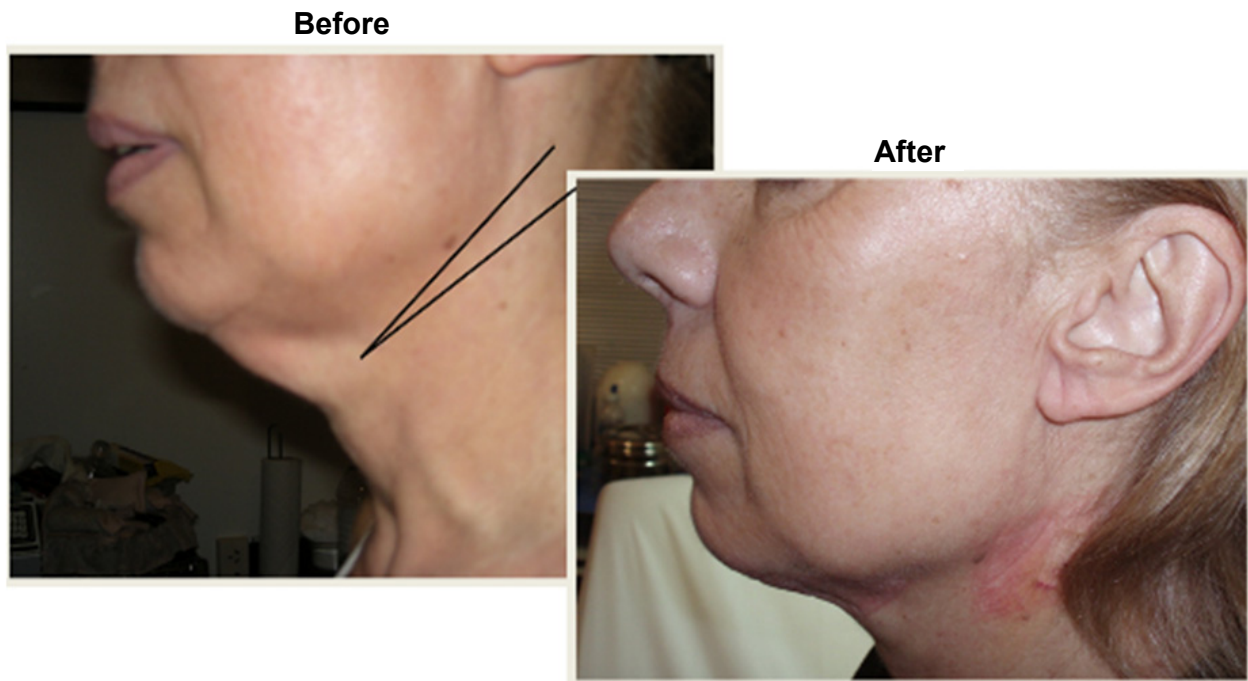This method is simple and allows us to lift the neck in a better way than in the FIRMING LIFT. The procedure is done with local anesthesia, using the 21 Gx2 needle, by entering the mastoid zone making a small incision of 1cm. The aim is to introduce the thread in the shape of a “V.” Firstly, we enter through one side of the incision and exit on the internal point out of the platysma band, once more holding the needle and entering again on the other side of the incision, secondly, exiting at the same anterior point and out through the platysma band. The results are very good, on the other hand some complications have arisen such as persistent folds and pain. Only one case has been registered of a torn thread.



Source: Own elaboration based on pictures from personal archive

**Figure 17.** Neck Lift and Double Chin with Fiberlift® Results ( The patient also has Firming Threads at the lower and medium third)





Source: Own elaboration based on pictures from personal archive

**Figure 18.** Neck Lift and Double Chin with Fiberlift® Results

#### *2.1.1.4. Upper third*

##### *2.1.1.4.1. With firming threads*

Brow lift may be done with one or two 6cm convergent barbed threads being very careful with the blood vessels. Work on frontal zone is made easier with a curved needle. This is a very good procedure with highly satisfied patients, who do not want an invasive technique and this one is performed in a few minutes.

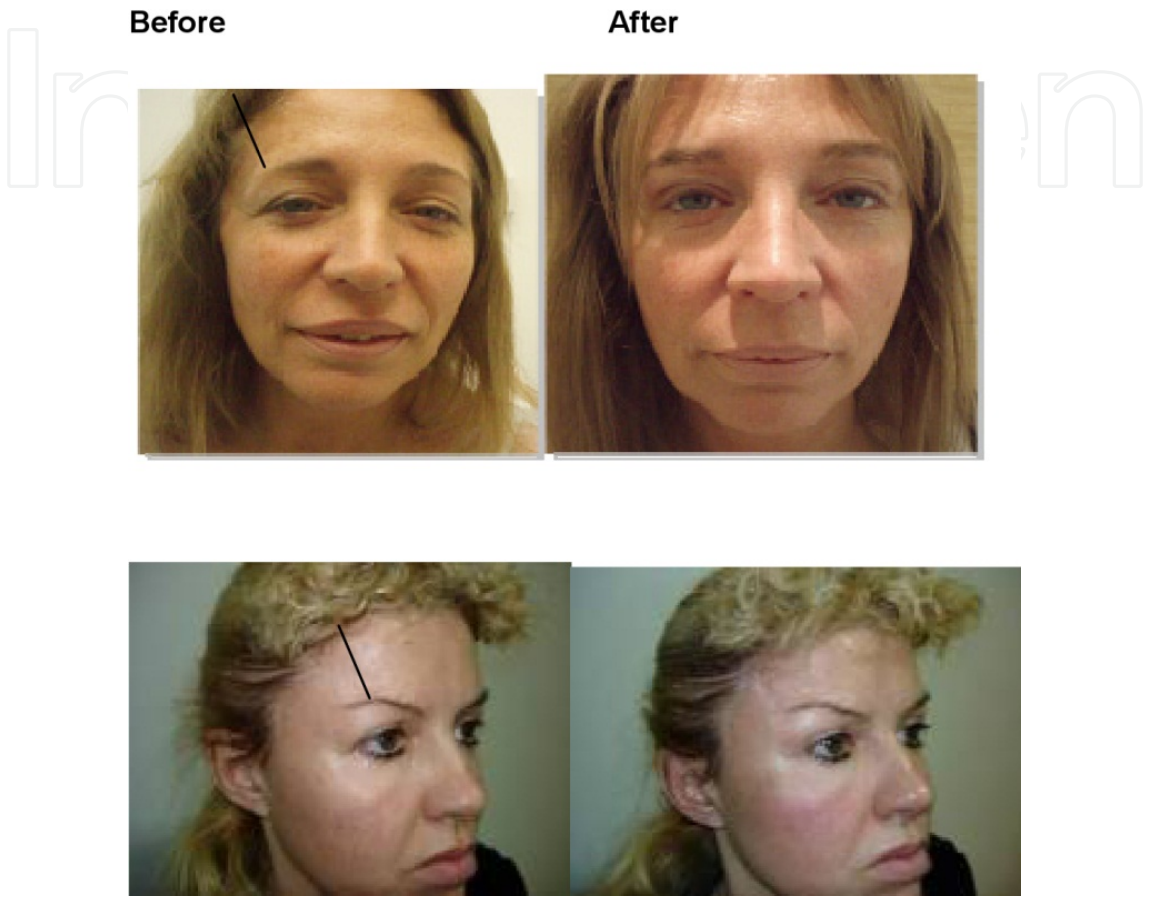**COMPLICATIONS:** only hematomas.

**RESULTS** are good and long lasting. Patients are very happy.

##### *2.1.1.4.2. With fiberlift®*

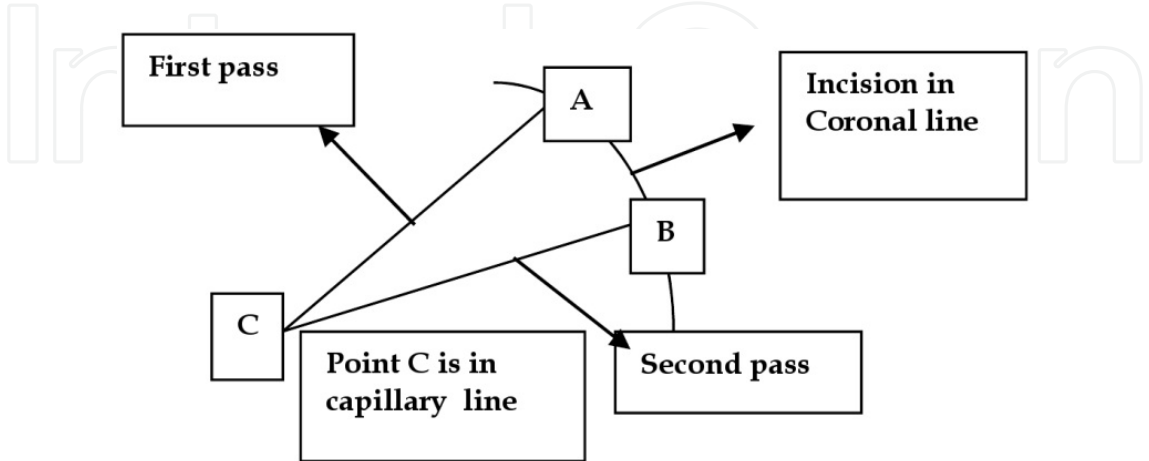
Fiberlift® is a triple anchorage polypropylene 3.0 30cm divergent barbed thread that is used to lift the eye brow tail. The technique is very simple with only a small incision of 0.5 to 1 cm. at the coronal line. Fiberlift is a procedure of double entrance and triple anchorage. We use a 21 G x2 needle and enter twice. The first entrance of the needle is AC and the second is BC. We put the divergent barbed thread from C to A in the first step and from C to B in the second step. In this way the thread has the first anchorage in C point. The divergent cogs picture the second anchorage and the last one is given by a sub-galea knot in the temporal

zone. This method is very good to lift the eye brow, opening the eyes and smoothing the periorbital lines. Patients like it very much. Initially, we have seen few complications. Pain and persistent folds are improving with practice.



Source: Own elaboration based on pictures from personal archive

**Figure 19.** Direction of the Firming thread to lift the eye brow. Results

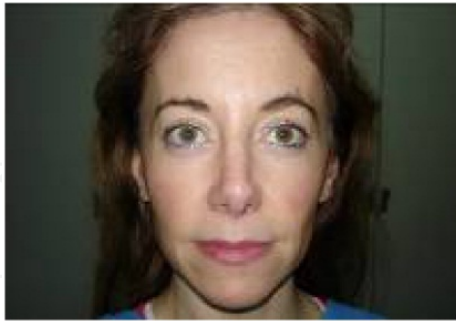

Source: Own elaboration

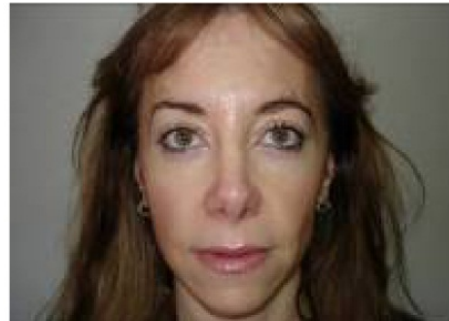
**Scheme 2.** Placement of Fiberlift®

**Front**

**Before**

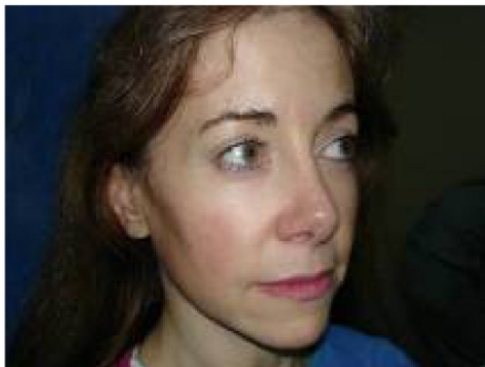


**After**

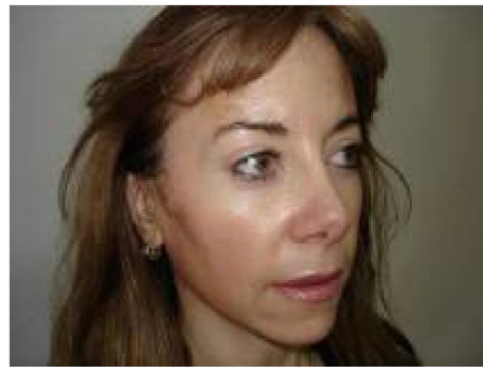

**Profile**

**Before**



**After**

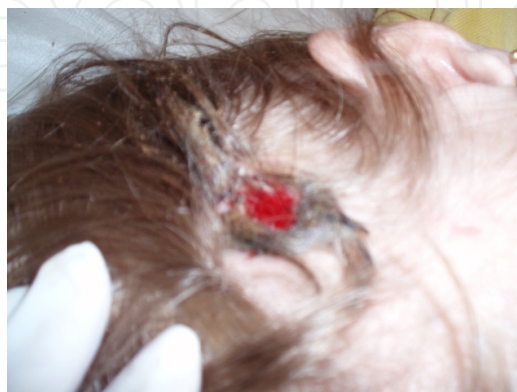

Source: Own elaboration based on pictures from personal archive

**Figure 20.** Upper Face Lift with Fiberlift® Results

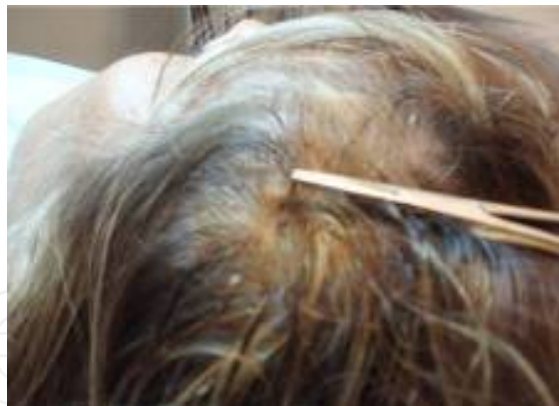*2.1.1.4.3. Complications*

In two cases we found a decubitus ulcer that needed surgical treatment.



Source: Personal archive

**Figure 21.** Decubitus ulcer



Source: Personal archive

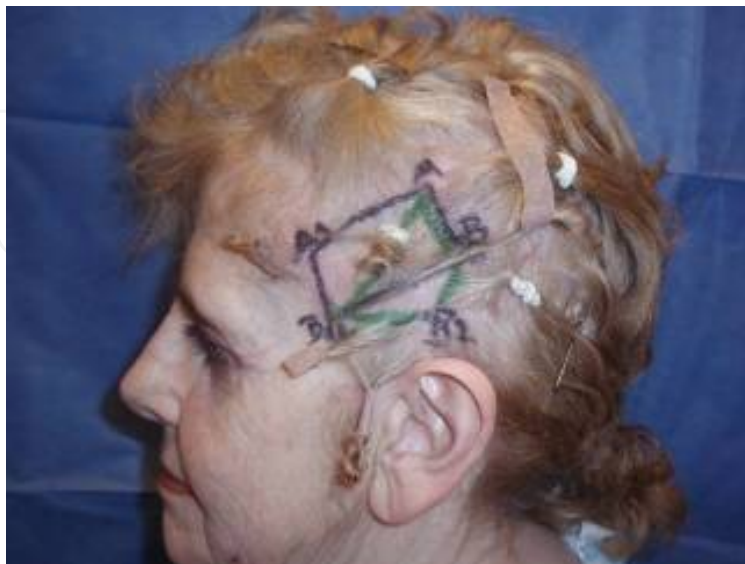**Figure 22.** Extrusion of Fiberlift® thread

## **2.2. Serdev sutures – Serdev methods: Temporal face lift, eye brow lift, medial face lift and chin enhancement**

These techniques, created by Nikolay Serdev use semi-elastic polycaproamide, long term absorbable (2-3 years), braided, antimicrobial, Bulgarian materials, called Serdev Sutures. With Serdev's methods we can lift one mobile tissue and carry it to a non movable point.

### *2.2.1. Temporal face lift without incisions*

The Temporal face lift with Serdev sutures not only lifts the soft tissue of the upper face and the zygomatic zone but it also reflects a lifting of the lower face. The results cover in a complete way 'lifting' without an incision. It is significant to know the location of the temporal zone to prevent damage to the temporal branch of the facial nerve. It is very important for us to outline the temporal zone.[8]



Source: Personal archive

**Figure 23.** Marcation for temporal face lift



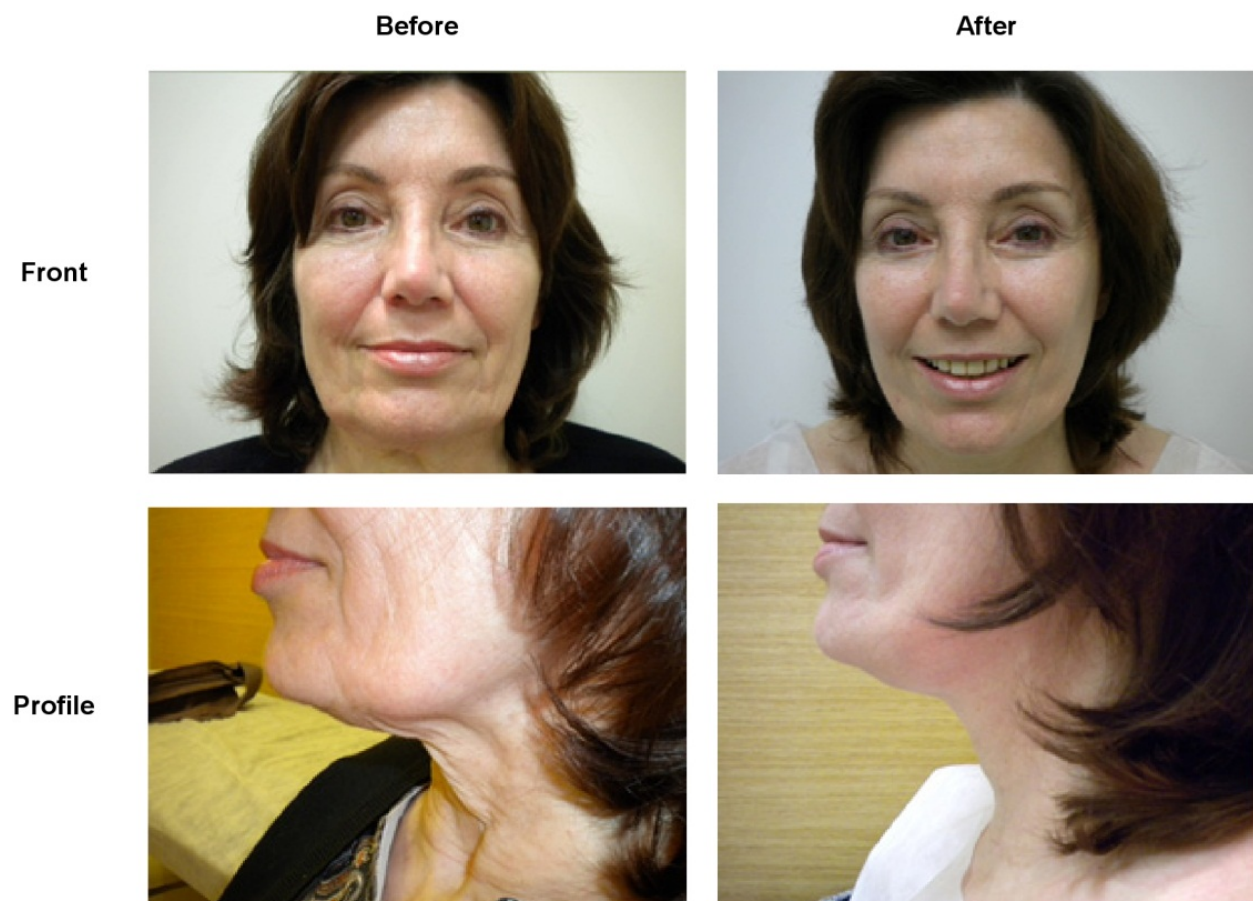In this outline we have marked with green a second lift treatment, in the same temporal zone to optimize the result. In this case there were another four passes (AB1, B1B2, B2B and B2B)

#### 2.2.1.1. Technique

Insert the suture with a special, curved, semielastic, small or mini Serdev's needle with a tip hole. The passes are A-A1, thread the suture and leave. Go B1A1, thread the suture and leave, then BB1 thread the suture and leave and finally AB, thread the suture, knot it and cut. The passes AA1 and BB1 are sub-galea, the pass A1B1 is sub-dermic, and the last AB is sub-fascia. In this way the SMAS is lifted and fixed to the temporalis fascia.

#### 2.2.1.2. Results

We can see an improvement in the aspect of the face: the eye brows, the skin and the eyes with a change in the tired expression of the face with no traces of an operation. The results of this technique are immediate and the patient's satisfaction is high.



Source: Own elaboration based on pictures from personal archive

**Figure 24.** Temporal Face Lift with Serdev Sutures Results

#### 2.2.1.3. Complications

Initially, we have seen skin dimpling, pain, edema of the upper face, hematoma below the eye. Skin dimpling is treated with one branch of the "mosquito" claw (Serdev). Pain is

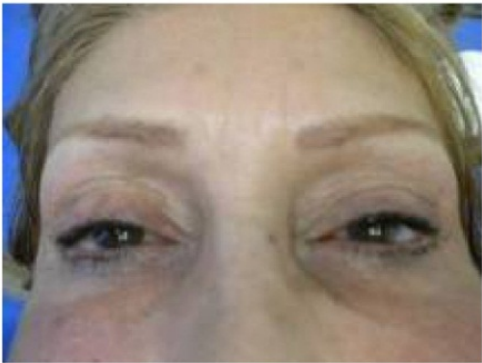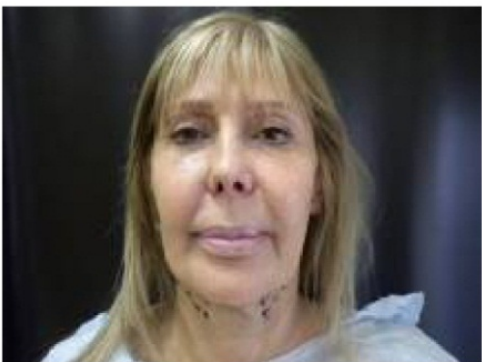


tolerable and patients can take analgesics. The edema and hematomas were produced by mistake in the surgical plane of needle puncture and suture insertion. Today, with the experience of 6 years of daily practice with this technique, complications are not significant.

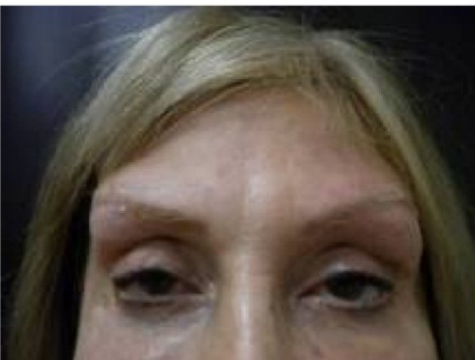
2.2.2. *Eye brow lift with Serdev sutures and Serdev method*

This method is very simple and fast. It was described by Nikolay Serdev in 1994, [9] without incisions, only a needle perforation between the eye brow hairs. Thus, it is possible to carry

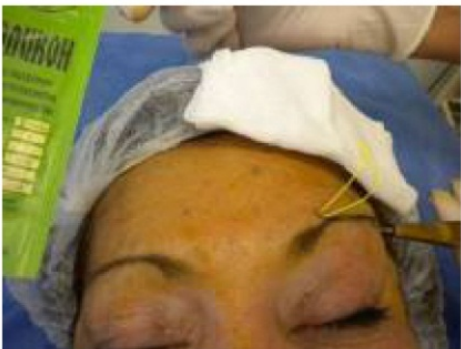**Before**



**After**



**During the procedure** (See the needle leaving through the frontal muscle and skin. It must become fixed)



Source: own elaboration based on pictures from personal archive

**Figure 25.** Eye brow lift with Serdev Sutures and Serdev Method Results

the subdermal tissue to the bone periosteum and fix it, using a Serdev suture and a special semi elastic small (mini-mini) needle with a tip hole. The secret for success is not to be afraid of being aggressive in fixing the subdermal tissue to the bone periosteum (Serdev's 2007 Course in Sophia on Serdev Techniques.)

The procedure consists of two steps; using lidocaine 2% with epinephrine in each of the two points that we'll use (positioning previously 1cm above of the orbital rim).

#### *2.2.2.1. First step*

Enter in point A with semi elastic, mini Serdev needle. The incision is made with the tip of a N° 11 scalpel. Get the bone periosteum with the needle tip down and leave through the frontal muscle and skin with the tip up; needle must become fixed, if it is not fixed it could be improperly located in a wrong plane. Thread the suture and remove the needle.

#### *2.2.2.2. Second step*

The 2nd needle pass is superficial, it goes through the lower dermis from point A to point B. Then a knot is made with medium tension. The dimpling is removed with a branch of the mosquito claw.

It is a very interesting method with very good and long lasting results. Initially I didn't have good results due to the incorrect position of the needle. It is very important to take the periosteum with the tip down and then turn the needle with the tip up. In 5 years I have only had one complication with a knot extrusion. In that case the suture used was a N°2 instead of a N°0. It was removed and replaced by the correct one.

### *2.2.3. Medial face lift with Serdev sutures*

I use only one of the several alternatives that Serdev describes for this method. It is to lift loose medial SMAS and to fix it to the stable zygomatic periosteum. Point A (entrance and fixation) is located in the zygoma 1 cm below the lateral cantus of the eye so the zygomatic periosteum is caught. In this method a Serdev semi elastic, curved needle size small and Serdev elastic braided antimicrobial polycaproamide are used.[10]

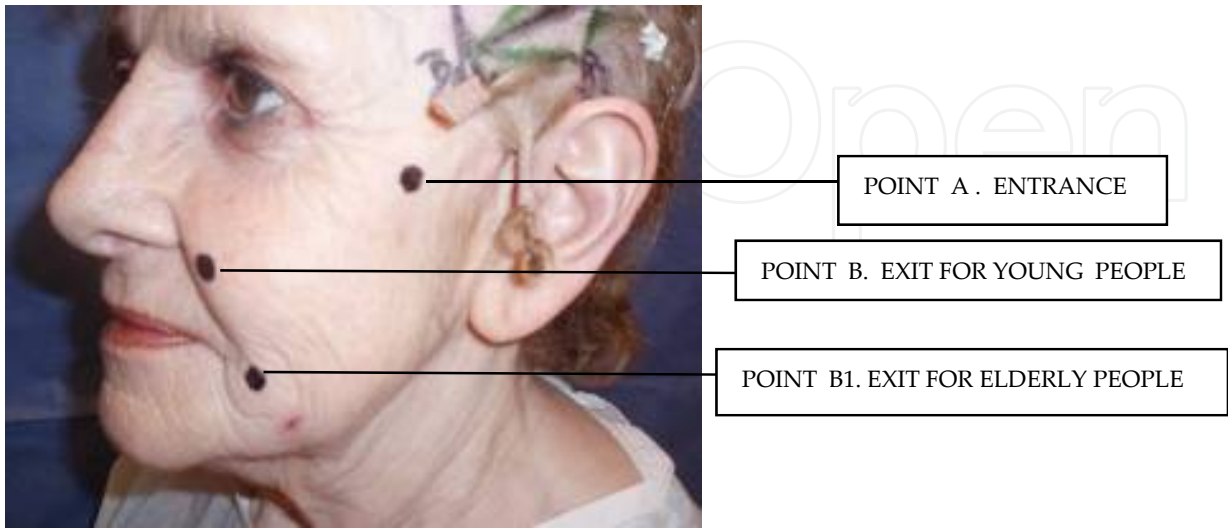
#### *2.2.3.1. First step*

The needle enters in point A through the bone periosteum and exits in a parallel line beside the nasolabial fold in one of three points that Serdev describes according to the age of the patient.

#### *2.2.3.2. Second step*

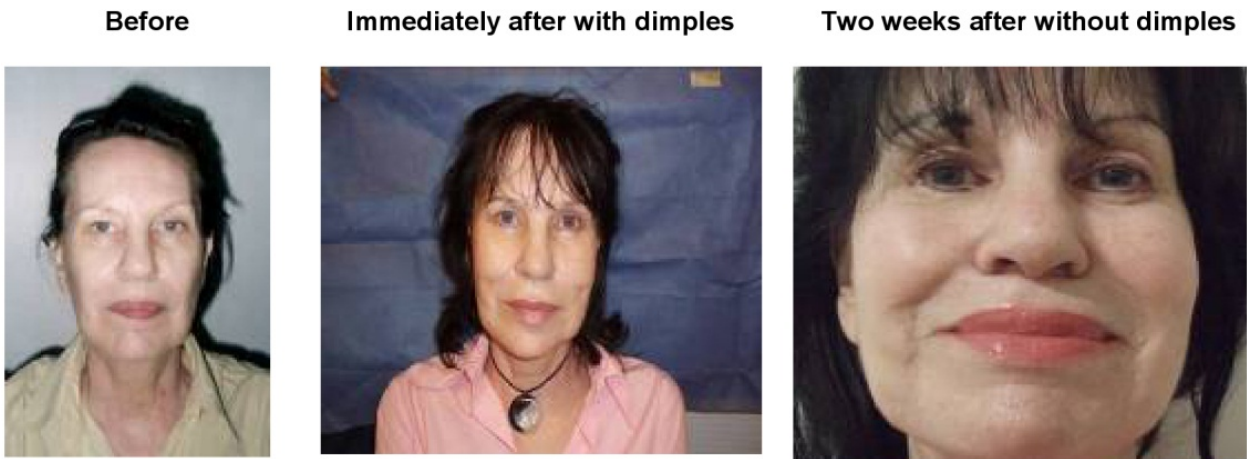The needle enters in point A and passes superficially through the soft tissue and exits in point B describing a circle around the zygoma and zygomatic SMAS extension. Then, a knot is made with medium tension. In this way it gives new volume to the cheek bone. It is a good ambulatory method, with good results but at first patients sometimes don't accept it

due to the formation of dimples. I haven't seen complications except for some dimples that patients didn't like and there has been only one case of asymmetry. The dimples disappeared in two weeks and the asymmetry, caused by exaggerated tension, was corrected by removing and replacing the suture.



Source: Personal archive

**Figure 26.** Medial Face Lift Technique with Serdev Sutures

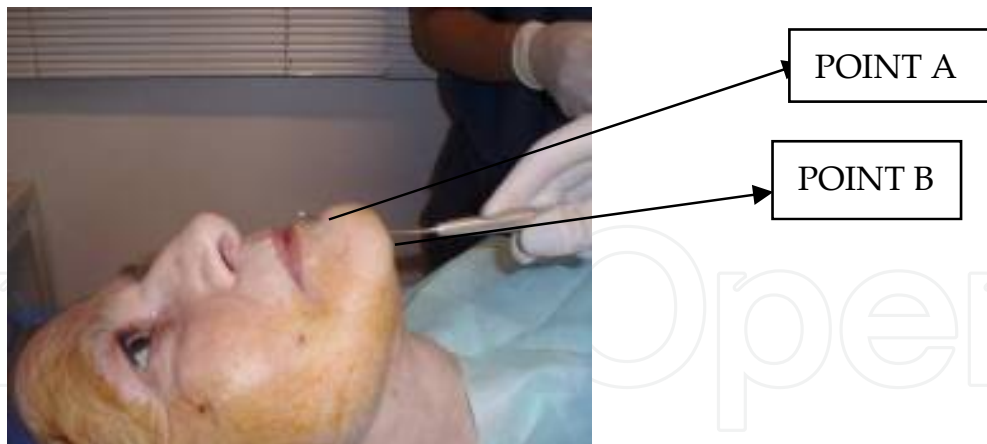


Source: Own elaboration based on pictures from personal archive

**Figure 27.** Medial Face Lift with Serdev Sutures Results

2.2.4. *Chin augmentation using Serdev sutures*

The form and position of the chin is very important in the correct and harmonic face proportions and beauty features. It is common to see chin disproportions such as micrognathia aging, asymmetries, etc. Nikolay Serdev proposes a simple technique using non barbed suture to correct these chin disharmonies. The procedure is simple using a small semi-elastic, curve needle with a tip hole and a thin Serdev suture. The entrance may be in point A or B and the exit in the other.



Source: Personal archive

**Figure 28.** Chin augmentation technique with Serdev Sutures

The aim is to create a circle around the chin's soft tissue, there are two steps to follow. The first pass is depth, entering in point A, going along the mandibular line, exiting in point B, threading the suture and removing the needle.[11] The second pass is done by entering point A but in a more superficial way by going under the skin and leaving through point B in the skin. The knot is done here. If there is dimpling in the skin, it is corrected with the mosquito branch (Serdev). The results are excellent and fast. The patients are satisfied. No complications.

## 2.3. Threads and sutures in body lift

### 2.3.1. Barbed threads in body lift

The objective of these techniques are to give a lift effect to the soft tissue of the arms, inner thigh, abdominal zone and outer thigh when there have been sequelae with liposuction effects. They are good for treating flaccid or aging areas. All methods are performed without incisions and without scars. They are simple and fast, obtaining good results, with medium and long term duration due to the new collagen fibers that are generated around each thread and each cog of them.

#### 2.3.1.1. Arm lift

##### 2.3.1.1.1. Materials

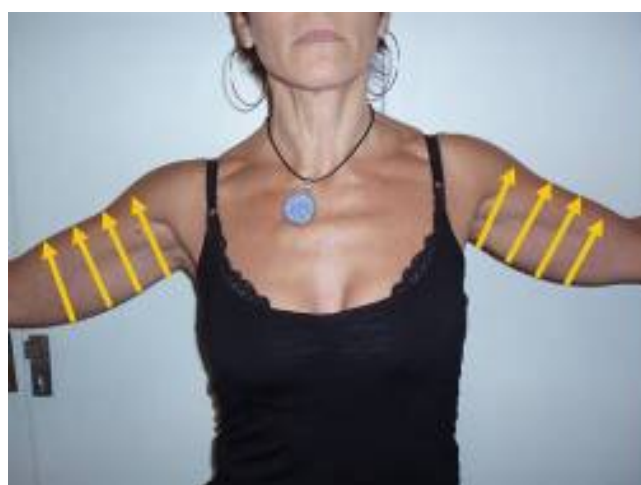We use MULTIFIX THREADS, multifix 12 cm nonabsorbable 2.0 polypropylene with multidirectional cogs. We insert them under the skin in the fat tissue. 4 threads or more can be inserted depending on the size of the arm.

##### 2.3.1.1.2. Procedure

Begin with the marcation three fingers below the axilla. Prior to procedure inject lidocaine 2% with epinephrine in the skin, just 0.5cc in each point is enough.

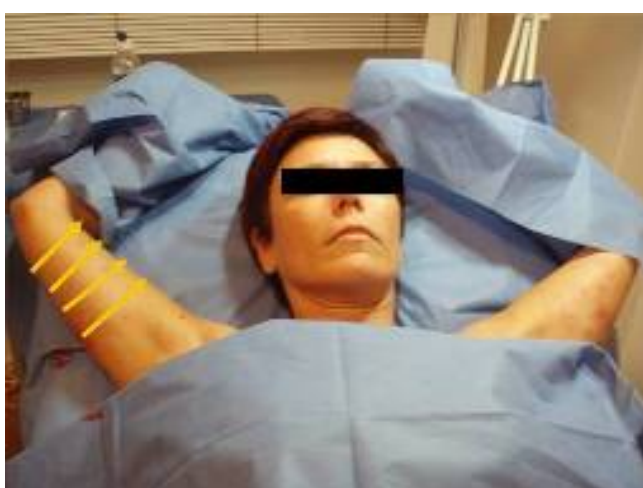Do the insertion with a 21 Gx3 needle (spinal needle) beginning from the external point to the internal one, repeating the same procedure many times as necessary. The thread is





Source: Personal archive

**Figure 29.** Arms lift



Beware of the humeral artery

Source: Personal archive

**Figure 30.** Arms lift – Procedure

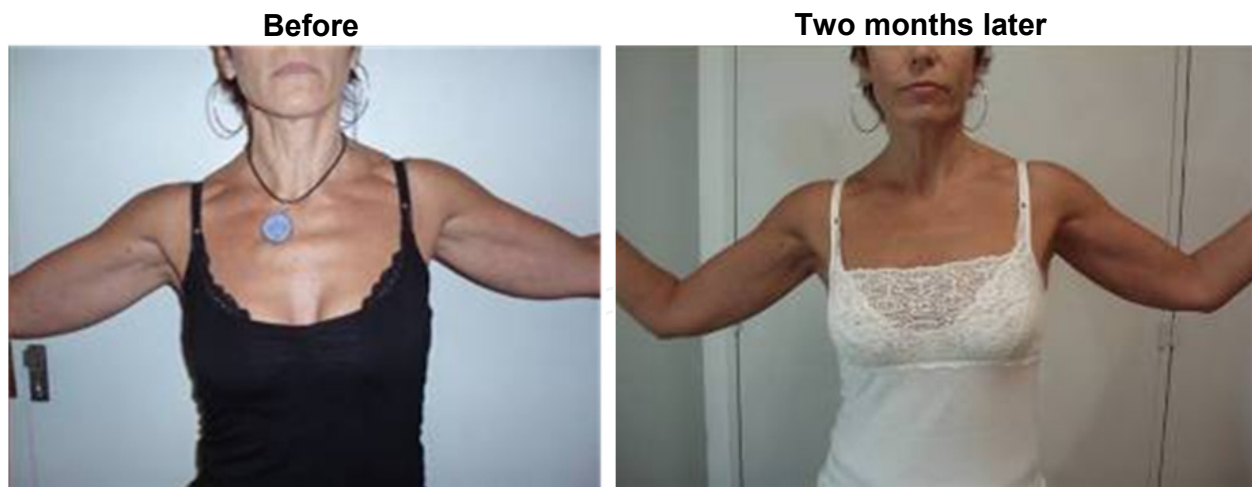positioned and anchored with a simple and delicate movement with the hand using a Halsted claw and pulling gently in both directions. Then we cut the ends of the thread by pushing the skin down to uncover the thread's end, avoiding a long thread. We use bandages or tight sleeves for 10 days. Nsaids and analgesics are indicated for three days.

**RESULTS** are good, it is a fast and long lasting procedure.

#### 2.3.1.1.3. *Complications*

Pain and edema, have been seen. Sometimes a bump under the skin because of the length of the thread. We have had some extrusions in three patients. Bumps under the skin are the most common complications and are corrected by cutting the end of the thread. If it is in the correct position (fix and anchorage), it's not necessary to remove it, if that is the case only cut the end. If the thread is loose it would be convenient to remove it.





Source: Own elaboration based on pictures from personal archive

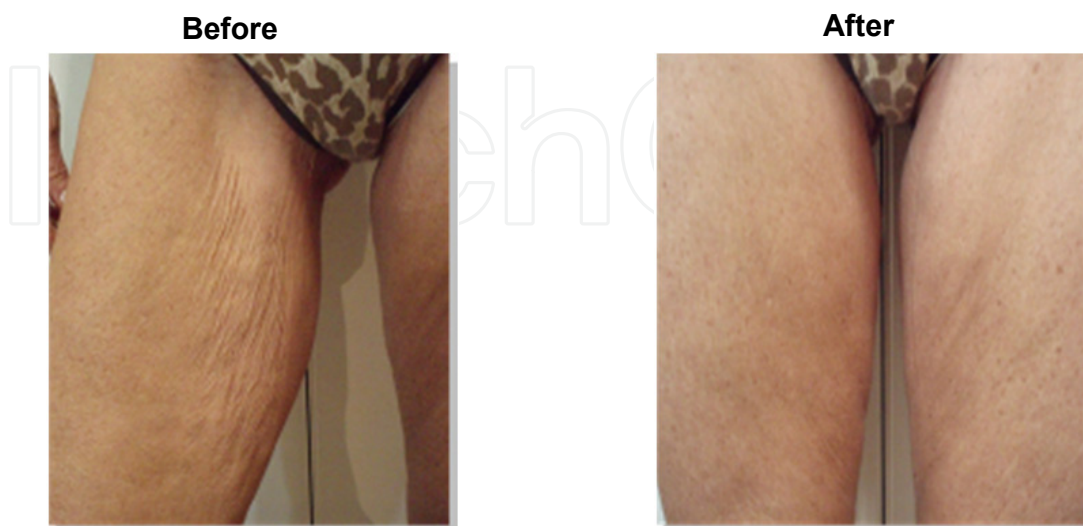**Figure 31.** Arm Lift with Barbed Threads Results

#### 2.3.1.2. *Inner thigh*

The inner thigh is a flaccid and aging area that may be improved with 2.0 polypropylene multifix barbed threads with multidirectional cogs. It is a simple application done with a long 21Gx3.5 needle in the fat tissue thickness. We must be careful with the femoral artery and vein as well as with the saphen intern vein. The femoral artery can often be palpated through the skin in the inner thigh at the mid-inguinal-point, halfway between the pubic symphysis and anterior superior iliac spine. [12]

##### 2.3.1.2.1. *Procedure*

Application of at least 4 threads for each side, from external (A) to internal (B) point using a 21Gx3.5 needle (spinal), being careful when cutting the ends and using an elastic compression for a week.



Source: Own elaboration based on pictures from personal archive

**Figure 32.** Inner Thigh Lift with Barbed Threads Results

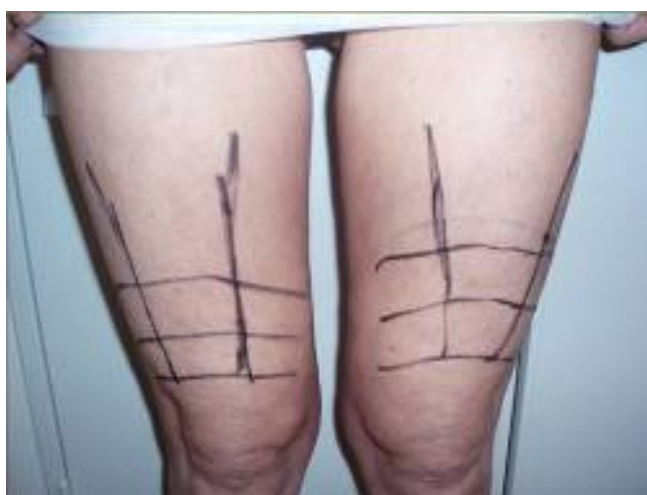### 2.3.1.2.2. Results

Results are very interesting, patients accept this technique. It allows them to see themselves better as well as returning immediately to their social activities. It is very important to see the changes in the general physiognomy of the skin, produced by the stimulation of collagen formation. This method is easy, fast and with a long lasting time span. In accordance with my experience, I believe the inner thigh is the best place to insert barbed multifix threads in body lift treatment.

### 2.3.1.3. Front and upper face of the knee

#### 2.3.1.3.1. Materials

The upper and anterior face of the knee share with the inner thigh as the best places to lift with barbed threads. I usually use 2.0 polypropylene antimicrobial multifix barbed threads with multidirectional cogs, 12 cm length and 2.0 polypropylene antimicrobial Firming barbed threads with bidirectional cogs, 8 or 10 cm length. Multifix are inserted in a vertical form and Firming (bidirectional cogs) is used on a horizontal line.



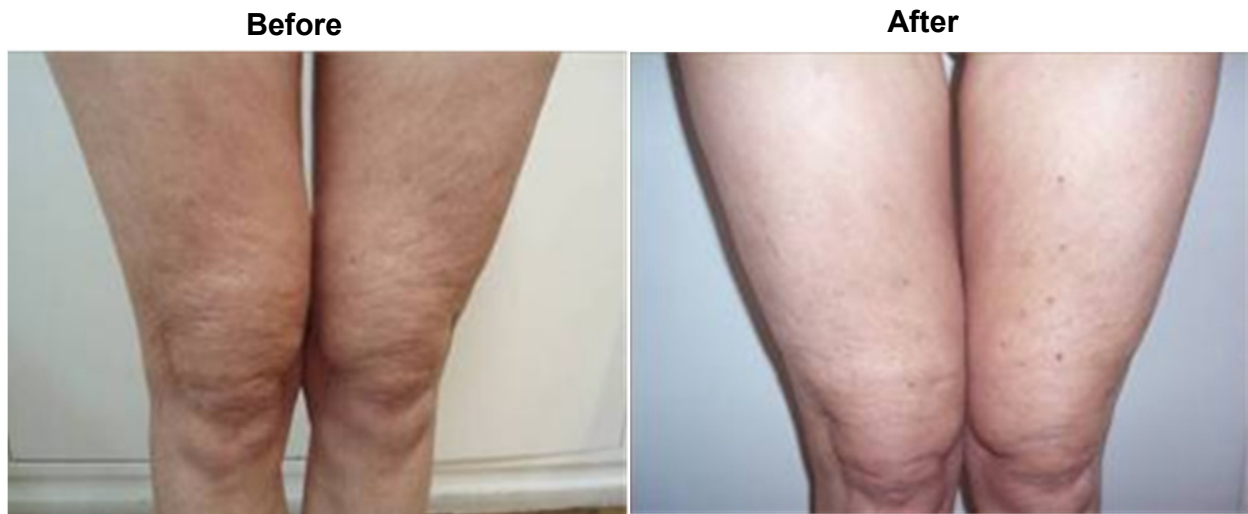Source: Personal archive

**Figure 33.** Marcation for front and upper face of the knee lift

#### 2.3.1.3.2. Procedure

It's a simple procedure, using only local anesthesia (lidocaine 2% with epinephrine) at the entrance and exit points; 0.5cc in each one. The insertion is carried out with two kinds of needles a 21 Gx2 is used to insert Firming threads and a 21 Gx3.5 is used to insert Multifix threads. This technique consists of two steps. In the first step insert Firming threads in parallel lines and in a horizontal position place the fat tissue of the anterior thigh 3 or 4 fingers above the knee. In the second step Multifix threads are inserted in diagonal form crossing over the Firming threads. As we finish we have to be careful cutting the threads in order to avoid long threads pricking from within. The use of an elastic compression or tight panties is suggested for a week.

**RESULTS** are very good. Patients are satisfied with the change in the skin and the improvement of irregularities in the tissue caused by flaccidity.



Source: Own elaboration based on pictures from personal archive

**Figure 34.** Front and upper face of the knee lift with Barbed Threads and Multifix Results

### *2.3.2. Serdev sutures in body lift*

#### *2.3.2.1. Buttock lift*

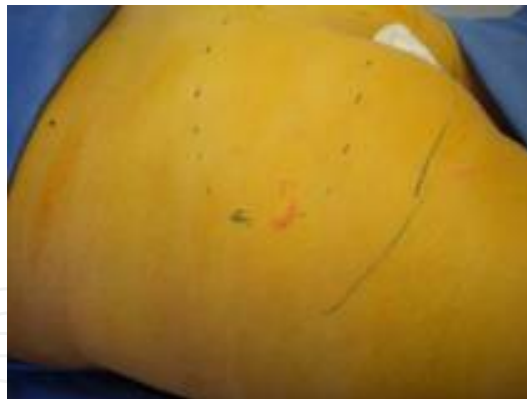
I have experience in buttock lift with Serdev sutures and Serdev's technique. It is a very interesting method to lift buttocks that are flaccid. This is a mini invasive procedure without scars and with a short postoperative. A description of the subject was made by Nikolay Serdev in 2003, in Sophia, Bulgaria. It is an ambulatory procedure and it achieves the reposition of the buttock's subdermal fat tissue by lifting it and increasing its volume and anteroposterior diameter using only a suture that grasps the deep fibrous tissue and fixes it to the upper zone in the gluteus maximus fascia in its sacrum insertion. [13]

We prefer to use the Argentine modified Serdev technique (J. Ferreira, Buenos Aires 2004) due to the gluteus shape of Argentine women. [14] This technique has 3 steps as in the original Serdev's method:

First step: with the patient in a sitting position I mark the lower limit.

Second step: with the patient in ventral decubitus I draw the internal and lower points some centimeters above the inferior limit and 2 or 3 cm from the anus. There is another lateral point, the same as in liposuction. The higher point or sacrum point is in the middle line at the beginning of the gluteal fold.

Third step: we then proceed to measure and to check the symmetries, drawing a print line between the three points to give the rounded desired form. It's important for me to draw the inferior limit so as to avoid a long term post-operative pain.



Source: Personal archive

**Figure 35.** Buttock lift. Marcation

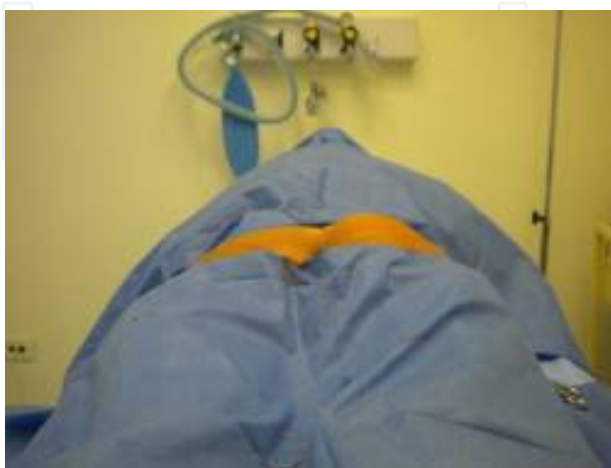#### 2.3.2.1.1. Procedure

Antisepsis is done, the perianal zone is covered by a sterile gauze. Anesthesia with lidocaine 2% with epinephrine in each point where small incisions between 3 to 4mm will be performed with a number 11 scalpel blade. Klein solution is injected with a 2mm cannula into the deep fat tissue which lies on the superficial surface from the maximus gluteus fascia. A way is marked where the path of the Serdev needle will proceed.

We work with a hollow protector in lateral and inferior incision points to avoid taking superficial skin with the needle thus producing a “dimple” on the surface.

The procedure is carried out with a special needle developed by Nikolay Serdev. It is 20 cm, flexible and semi-curved with a top orifice, it is also a polycapromide, elastic, antimicrobial Bulgarian suture. A liposuction is previously performed on the outer thigh to reduce the volume and weight of the gluteus.

First pass: from external incision to medial or a sacrum one in the shape of an arch with a Serdev needle. We thread the suture and remove the needle leaving out the ends of the suture. Second pass: from inferior perianal incision to the lateral one. Thread the suture and remove the needle.



Source: Personal archive

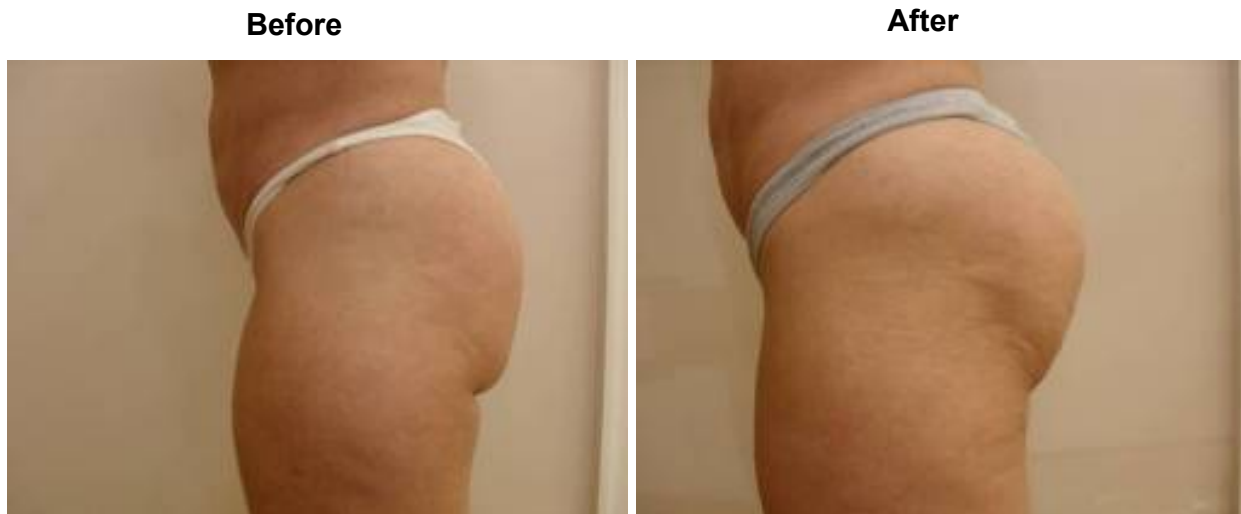**Figure 36.** Buttock lift only one side done

Buttock lift of only one side done

Finally we go from the sacrum incision to the inferior internal point and thread the suture, then we remove the needle and we can observe both ends of the suture in the sacrum incision. Adjust the suture to give it the desired form and height and make some surgical knots. Finish by closing the skin with a nylon 5.0 and a micropore.

#### 2.3.2.1.2. Results

The results are very interesting and patients are satisfied. I have performed 104 procedures; 103 were women and only 1 man. The patients were between 20 and 65 years old. A 40% of these were combined with liposuction of the outer thigh. All patients were satisfied with the results.



Source: Own elaboration based on pictures from personal archive

**Figure 37.** Buttock Lift Results

#### 2.3.2.1.3. Complications

There are few complications; such as skin dimples or asymmetries due to different tensions found in both gluteus. Pain was the most frequent undesired effect. It had a duration of 15 days and it was treated with NSAIDs and analgesics. Every patient had been prescribed with antibiotics. There were neither infections nor hematomas.

#### 2.3.2.1.4. Comparison of both methods, barbed threads and non barbed Serdev sutures

Both methods, barbed threads and non barbed Serdev sutures, are excellent for mini invasive techniques. Patients are satisfied with both of them. Complications are rare and the lifting effect range from good to excellent.

We have found –after 10 years of barbed thread experience and 6 years of Serdev sutures–, that lifting effect is higher with Serdev sutures, patients recover forms, angles and the tissue is repositioned without “operated look.” They also improve adding a higher volume and contour. The collagen and elastic fibers generation are very important with barbed threads, improving the skin of the face, giving it light and a glow.



In an experimental study of the morphological changes in tissue with barbed threads carried out by Sulamanidze and co-writers (2002) in order to clarify the mechanism of tissue ptosis correction, it was seen in rats when polyprpropylene barbed threads were inserted subdermally and were compared with non barbed polypropylene in control rats with serial skin biopsies. It was noted that the barbed threads had elicited an earlier inflammatory response followed by a vascular proliferation and fibroblastic reaction thus creating a new collagen generation along the threads and along each barbs. In the case of non-barbed threads in rats it was found (Truswell 2008)[15] that there was neither found a collagen generation nor a vascular proliferation nor an inflammatory response nor a fibroblastic reaction.

Volume and contour were seen with Serdev suture and barbed threads in a less degree. “Z” insertion of Firming and Multifix threads has generated a new and better cheek bone.

The improvement in 1 year is important for both methods as well as the patient’s satisfaction. Both methods have no post-operative recovery time. Pain is minimum in both procedures. In the field of complications we can mention that with barbed threads we’ve seen some cases of migration and some extrusions of the end of the thread. With Serdev sutures we have sometimes seen pain in the temporal zone.

	BARBED THREADS	SERDEV SUTURES
LIFTING EFFECT	++	++++
COLLAGEN GENERATION	+++	+
VOLUME	+	+++
CONTOUR	++	+++
IMPROVE IN ONE YEAR	+++	+++
PATIENT SATISFACTION	+++	+++
POSTOPERATIVE RECOVERY TIME	—	—
PAIN	+	+
COMPLICATIONS	+	+

Source: Own elaboration

**Table 1.** Comparative chart Barbed Threads vs. Serdev Sutures

2.3.2.1.5. *Combined techniques*

It is very interesting to combine both methods using barbed threads in the lower third and temporal face lift with Serdev sutures. With this combination we can get fantastic results of the lifting effect and collagen generation. To optimize the contour with temporal face lift with sutures and barbed threads in the neck zone, improving the smoothing effect too. In my daily practice I usually perform a combined formula with temporal face lift and barbed threads insertion in the medium and in the lower third and neck. I can also add one barbed thread in each eyebrow tail.

#### 2.3.2.1.6. *Complementary methods*

The combination of these methods is very important, with the use of barbed threads and non barbed sutures, and other rejuvenation and beautification techniques as BOTOX, Fillers, IPL, Peelings, Laser, Oxygenesis and Mesotherapy. It's specially interesting Botox application treatment in the lower third as complement of threads. We inject the botulinum toxin in both platysm bands and jawline. Also may be injected into the orbicularis angle depressor muscle to elevate the commissures [16].

### 3. Discussion

Since the beginning of mankind men and women have always seeked ways to preserve beauty and the fountain of youth. Beauty has always been portrayed through art where you will find the most beautiful features which are in harmony with perfect proportions. In such natural and beautiful forms, why should harmony be altered? There are numerous methods to treat the aging face. Surgical techniques with cuts, pain, edema, scars, long postoperative time, often are used as a matter of surgeons satisfaction who do not even consider the genuine needs of their patients. Already in 1970 R Guillemain published on Curl Lift [17] but at the time the lift with cuts was well regarded by the patients who happily wore their scars. Today the patient ask for mini invasive procedures without scars nor pain and they want to return immediately to their activities. Aging treatments with threads and sutures are chosen for our patients, because they provide a natural effect.

### 4. Conclusion

In spite of having seen some extrusions, some migrations, some cases of pain or edema, whereas the simplicity of these procedures, the good and natural results that may be seen, the long lasting, the no post-operative time, the few complications and the high satisfaction of the patients we think that threads and sutures are a great answer to our patient's modern life exigencies and their wish: "don't cut". Patient's understanding of these techniques is very important. We are convinced that these procedures are a very good way path in the current cosmetic surgery and the most requested among our patients.

### Author details

Vilma L. Padín

*CEMEC (Center of Aesthetic Medicine and Surgery), Buenos Aires, Argentine Republic*

*AIMERA (International Association of Aesthetic Medicine), Argentine Republic*

### Acknowledgement

I would very much like to thank Professor Nikolay Serdev for allowing me to write this chapter. Dr. Serdev introduced me and opened the way to the fascinating field of the mini-invasive techniques of facial and body lifting.

## 5. References

- [1] Sulamanidze, M. et al., "Removal of facial tissue ptosis with special threads", *Dermatological Surgery* 28 (2002):367-371.
- [2] Bacci, P., *Cirugía Estética Mínimamente Invasiva con Hilos Tensores* (Caracas; Amolca, 2008).
- [3] SERDEV, N., "Scarless 'APTOS' & 'SERDEV SUTURE' Lifting Methods", *International Journal of Cosmetic Surgery* 4 (2004); 1-10.
- [4] Sulamanidze M., Sulamanidze G., "Avoiding Complications with Aptos Sutures" *Aesthetic Surgery*,...,2011
- [5] Lycka B. et al., "The emerging technique of the antiptosis subdermal suspension thread", *Dermatological Surgery* 30 (2004): 41-44.
- [6] Padin, V., "Tratamiento de la Flaccidez Facial con Aplicación de Hilos", *Revista Argentina de Rinología y Cirugía Facial* 1 (2005): 35-44.
- [7] Serdev, N., "Ambulatory Temporal SMAS Lift by Sutures with or without Incisions", *International Journal of Cosmetic Surgery* 1 (2001); 97-106.
- [8] Serdev, N., "A Suture Method for Scarless Brow Lift", *International Journal of Cosmetic Surgery* 1 (2001); 1-15.
- [9] Serdev, N., "Serdev Suture Method for Ambulatory Medial SMAS Face Lift", *International Journal of Cosmetic Surgery* 2 (2002); 1-13.
- [10] Serdev, N., "Chin enhancement and form correction using a suture of the soft tissue", *International Journal of Cosmetic Surgery* 2 (2002);16-25.
- [11] Padin, V., "Dermosustentación con hilos en miembros inferiores" (presented at the II International Symposium of mini invasive procedures in Flebology, Buenos Aires, Argentina, October 2009, Medicine Faculty, Buenos Aires University).
- [12] Serdev, N., "Buttock Lifts. Part I: Ambulatory Buttock Lift Using a Suture Without Incision Scars", *International Journal of Cosmetic Surgery* 2 (2002); 1-7.
- [13] Ferreira, J. and Padin, V., "Lifting Glúteo con Tensores Naturales. Hilos Reafirmantes: La Gran Solución No Quirúrgica", *Portal Medestética*, 2005, accessed April 16<sup>th</sup> 2012 <http://www.medestetica.com.ar/informes/informehilos.pdf>
- [14] Truswell, W. Surgical facial Rejuvenation: A Roadmap to Safe and Reliable Outcomes, October 25, 2008 | ISBN-10: 1588904911 | ISBN-13: 978-1588904911 | Edition: 1
- [15] Padin, V. and Lopez Mecle, V., "Mejores Prácticas mínimamente invasivas para el tratamiento del tercio medio e inferior del rostro y el cuello", in *Mejores Prácticas en Rejuvenecimiento Facial*, ed. Allergan Academy (Buenos Aires: Allergan Press, 2011), 88-113.
- [16] Guillemain, R. Le "Curl Lift" :, le Profession Medical, chirr. Plast.E Recon ;Mars 1970