

# We are IntechOpen, the world's leading publisher of Open Access books Built by scientists, for scientists

6,900

Open access books available

185,000

International authors and editors

200M

Downloads

Our authors are among the

154

Countries delivered to

TOP 1%

most cited scientists

12.2%

Contributors from top 500 universities



WEB OF SCIENCE™

Selection of our books indexed in the Book Citation Index  
in Web of Science™ Core Collection (BKCI)

Interested in publishing with us?  
Contact [book.department@intechopen.com](mailto:book.department@intechopen.com)

Numbers displayed above are based on latest data collected.  
For more information visit [www.intechopen.com](http://www.intechopen.com)



---

# Serdev Sutures® in Lower Face and Neck

---

Nikolay Serdev

Additional information is available at the end of the chapter

<http://dx.doi.org/10.5772/55675>

---

## 1. Introduction

The concept of lower face SMAS lift via sutures, through skin punctures alone (or by hidden incisions in the retro-lobular fold), explains how to re-structure and re-position the lower face, associated facial elements and neck, without visible pre- and retro-auricular scars. The author uses the specially designed, curved elastic Serdev® needles with lengths of 60 mm, 100 mm and 140 mm and prefers the Bulgarian semi-elastic, polycapromide (Polycon) surgical suture USP 2, with long delayed absorption durability.

## 2. Lower face and neck lift by sutures, with skin perforations only or by using a hidden 2.5 cm retro-lobular incision

The first method is a closed approach suture method of lower SMAS face and neck lift. The author uses skin punctures alone to introduce the needle and suture, in order to capture, lift and fix loose lower face and neck SMAS to stable structures like periosteum, without tissue undermining. Colli fascia, mastoid or occipital periosteum are used as anchor points to fix and elevate the lower SMAS, enabling lower face and neck lifting.

In the second method, the author uses limited undermining of 3-4 cm in front of the tragus, via retro-lobular incision. The fold behind the earlobe is the only place to hide the incision and at the same time obtain the optimal approach to cheek SMAS and platysma in front of the tragus. Usually, the retrolobular fold permits a 1.5-2.5 cm long incision. Thus, lifting the SMAS restores aesthetic angles, shape and proportions, which is the basis for beautification and rejuvenation.

### 2.1. The concept

Ptosis and laxity of the “subdermal facial mask” - the SMAS - in lower face and neck reflects the signs and appearance of lower face aging. The concept of using the closed approach

semi-elastic sutures with delayed absorption, is to tighten and elevate the lower face and neck, without unnecessary incisions. It is a fact that soft tissue and skin are attached to the SMAS. Accordingly, lifting and fixing the SMAS into a more favourable position enables repositioning of soft tissue facial structures as well. Loose SMAS and skin laxity imparts a heavy, hanging, sad and tired facial expression. In young patients without genuine ptosis, heavy facial features, poorly expressed cheekbones and jaw lines, flawed proportions and angles, as well as sad appearance should be corrected. In many patients heavy subdermal fat and fat pad should be removed simultaneously.

Classic face lifts can not avoid some visible scars or an "operated-on" appearance, secondary to skin and SMAS rotation and pull. The concept of the suture lift of lower face and neck SMAS is to achieve immediate results and to avoid trauma, visible pre- and retro-auricular incisions, excisions and scars.

As subdermal and submental fat in the lower face is superficial to SMAS, it cannot be lifted with the SMAS lift. If necessary, it should be reduced concurrently or prior to lifting. The author uses ultrasound assisted liposculpturing in the lower face and neck since 1994 (SMEI Sculpture and later - VASER) as a best option for atraumatic fat removal and tightening of skin.

### *2.1.1. Definition*

The two methods, described by the author, represent lower face and neck SMAS suspension, tightening or duplication, using elastic sutures durable through extended absorption delay, via needle perforations alone or via hidden retro-lobular incision, where SMAS-platysma is lifted and fixed to the mastoid, and in some selected cases - to occipital periosteum.

### *2.1.2. Objective*

The primary goal in lower face and neck closed approach suture lifting technique is the straightening and repositioning of the subdermal facial mask - the SMAS/platysma - with the perspective of refreshing the facial appearance and obtaining rejuvenation and beautification, corresponding to aesthetic angles, proportions and anatomic position, typical for youth. It is used for sculpturing the jaw line, softening the nasolabial fold and beautification, mostly in minor and medium jowling, submental laxity. It is ideal in cases of beautification, associated with early or medium facial ptosis. In cosmetic surgery it is very important to respond to patient's requirements for immediate beautification, to avoid visible scars, as well as to give patients the chance to promptly resume work and social activities, without long recovery period.

For this objective, the author's methods were created to be minimally invasive, without trauma and scars.

### 2.1.3. Anatomy

Face droops with age, due to gravity, atrophy and loosening of the facial ligaments. Jowling is caused by displacement of the SMAS and skin aging. The neck is a face related area. The sagging neck is an important part of the aging face.

The SMAS is a fibro-muscular layer that connects platysma and galea and acts as a suspension for the overlying facial skin. The continuity between the facial SMAS and the platysma is an anatomical fact, useful in performing facelift surgery.

Subdermal plexus of vessels is superficial to SMAS. Motor nerves and facial muscles lie deep to SMAS. SMAS provides a suspensory sheet, which distributes the forces of facial expression. The concept that lifting this layer leads to better long-term suspension of overlying skin has become universally accepted.

SMAS continues inferiorly towards the platysma and represents aponeurotic connections between mimetic musculature and the overlying skin.

SMAS overlies the parotid gland in mandibular angle and tends to be substantial and easy to handle, because the parotid gland, zygomaticus major and minor muscles protect underlying facial nerve branches. With regard to protecting the facial nerve structures, we can accept that lower SMAS-platysma face-lift “by sutures only” or “with a retro-lobular incision” is done in a fairly secure area. The suture lift should protect the parotid gland and for this reason is performed only in the mobile superficial layers to capture the facial SMAS and platysma.

## 2.2. Surgical technique

The scarless lower face and neck SMAS-platysma lift by sutures takes about 10 minutes per side and is done under local anaesthesia and i.v. sedation.

### 2.2.1. METHOD I: using skin perforations only

#### 1. Lower face SMAS lift by suture (A-C)

##### First Pass A-C

a) Perforate points A, B, and C with a No. 11 scalpel blade, only skin deep. Position the blade in direction of Langer's lines.

**NB!** Stay away from deep mastoid penetration (at point A), stay away from parotid gland (located deeper at point C), and submandibular gland (located more medially, could be near point B).

b) Enter the needle perpendicularly through the skin perforation at point A (without fixation of any dermal tissue), then **tangentially** through the mastoid periosteum at the anterior mastoid border.

**NB!** Do not push needle perpendicularly into mastoid - it is very soft and can be easily perforated (be aware of mastoid and inner ear anatomy). Do not push the needle - twist it gently forwards or backwards.

c) Proceed through fascia colli and superficial subcutaneous tissue from A to C. Proceed parallel to the skin - place the needle tip laterally. The handpiece concavity shows the needle tip position in the tissue. The pass should be superficial and below the skin. However, if too superficial - dimpling will appear above the needle. Avoid this by twisting the needle backwards and then forwards again, a little deeper (but still in a superficial plane). A deeper pass will produce a bulging effect.

**NB!** Stay superficial. Never introduce the needle into or below the sternocleidomastoid muscle (vascular nerve bundle, a. and v. jugularis interna). Stay away from external jugular vein as well.

d) Just before exiting at point C, SMAS (platysma) is captured. To capture SMAS, turn needle tip downwards, progress a bit and twist needle tip upwards.

**NB!** Stay in superficial mobile layer, away from the parotid gland (just below mobile SMAS).

e) Pass through perforation point C.

Do not push through skin perforation point C. Place skin perpendicular to needle tip, twist the needle softly and progress gently and easily. The tip should appear at perforation point C, without resistance in front. Perforation or resistance indicates engagement of dermis, resulting in a dimple that is difficult to remove. Free the needle tip and repeat the movement until the tip appears without the feeling of resistance.

f) The needle tip is threaded and is pulled out through the needle pass in line C-A.

### **Second Pass A-C**

The second parallel needle pass goes through the same skin perforations and tissue plane, 2-3 mm away from the first one. Platysma has to be engaged again. Appearing in perforation point C, the needle is threaded with the second end of the suture that is withdrawn through the second needle pass C-A. The suture loop dives in the subdermis at point C. The knot is made under medium elastic tension. Possible skin dimples should be managed by pulling the skin away from the suture, using a mosquito instrument. Thus, the first suture of lower face SMAS fixation to mastoid (or to occipital periosteum – rare and mostly in men to hide the swelling bulging) is fulfilled (Fig. 1, 2).

### **PROCEDURE Video**

<http://www.youtube.com/watch?v=zpDvCxC9hDg>

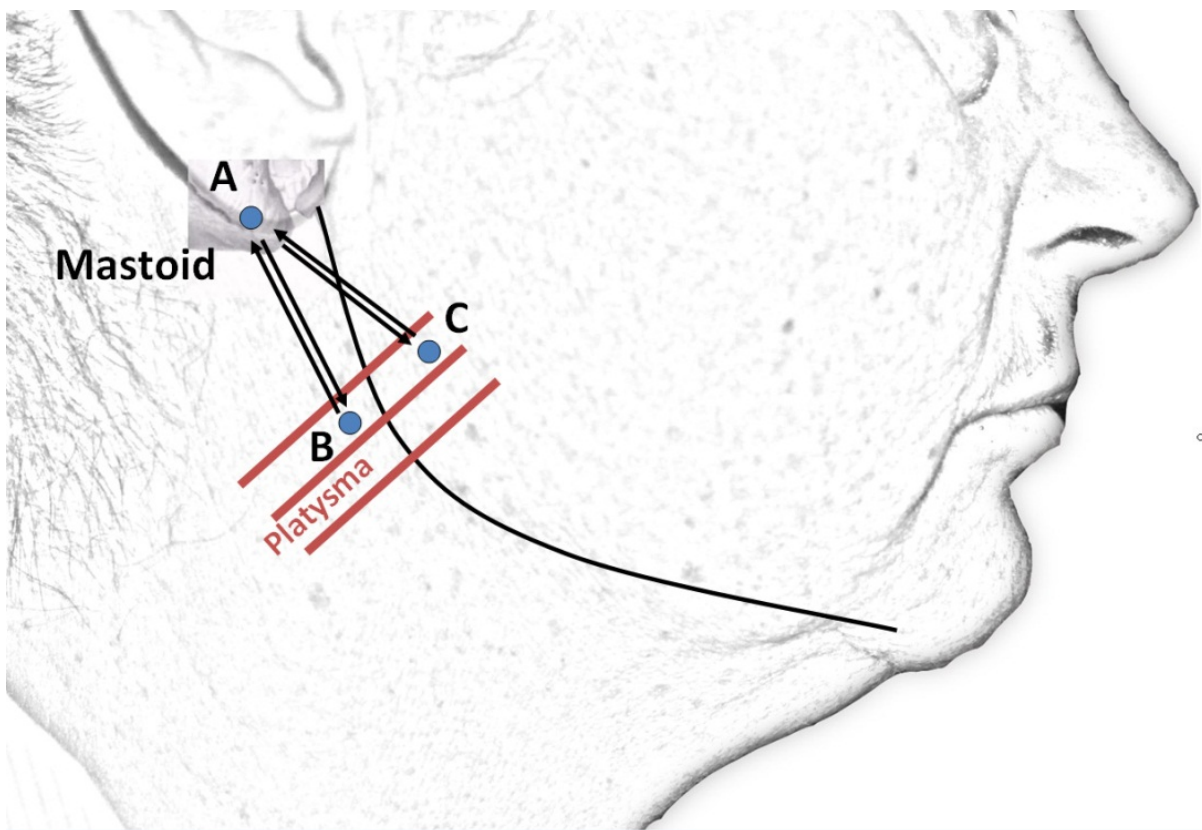
Inject local anesthesia into points A, B, and C and also into the tissue corridor to be used for the needle passes.

The points of skin perforations should be planned in advance:

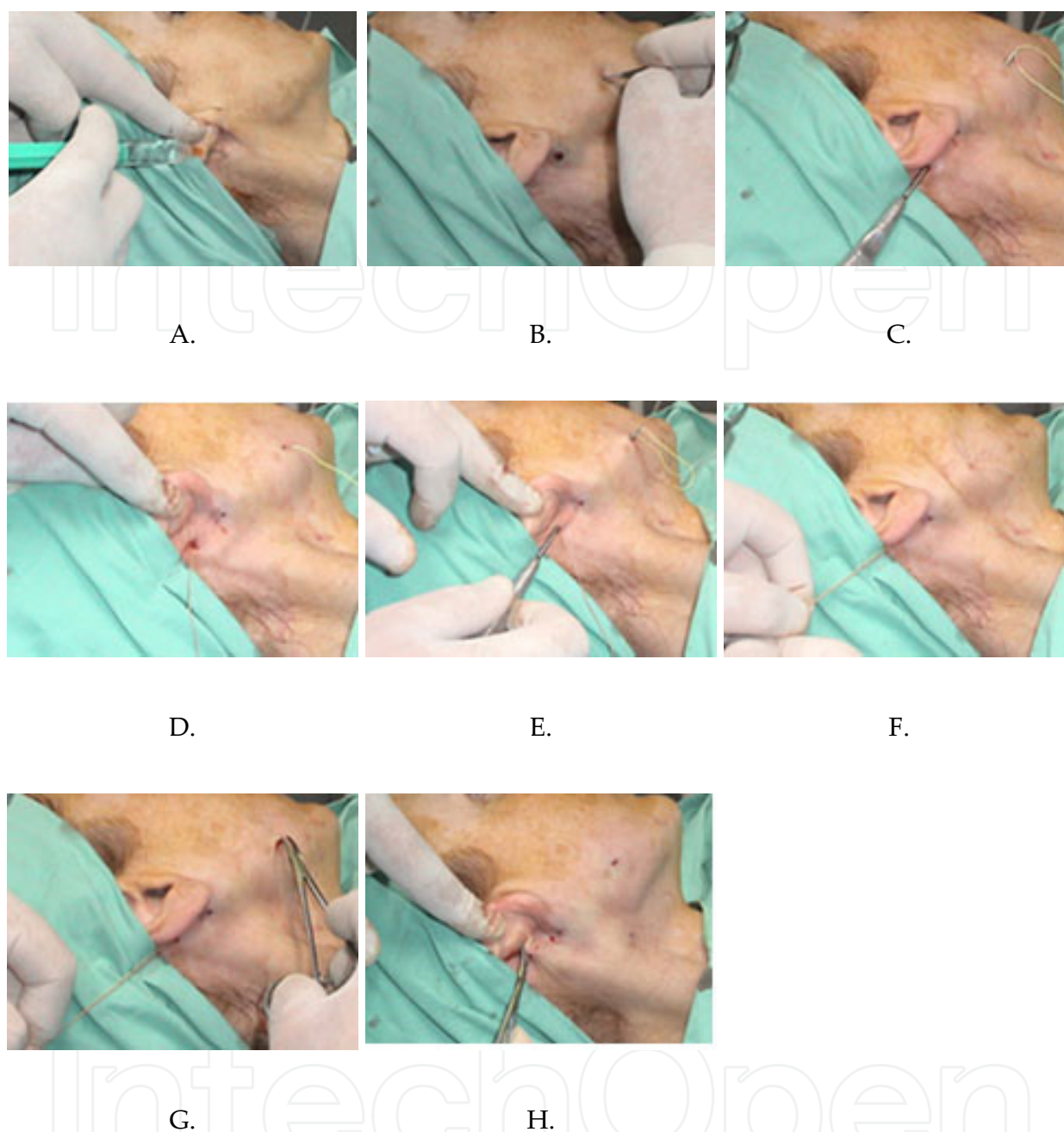
**Point A** - fixation at mastoid periosteum

**Point B** - fixation of lateral border of platysma to be lifted to A. A-B direction is to cervico-mandibular angle.

**Point C** - fixation of cheek SMAS and lateral border of platysma to be lifted to A. A-C direction is to the chin.



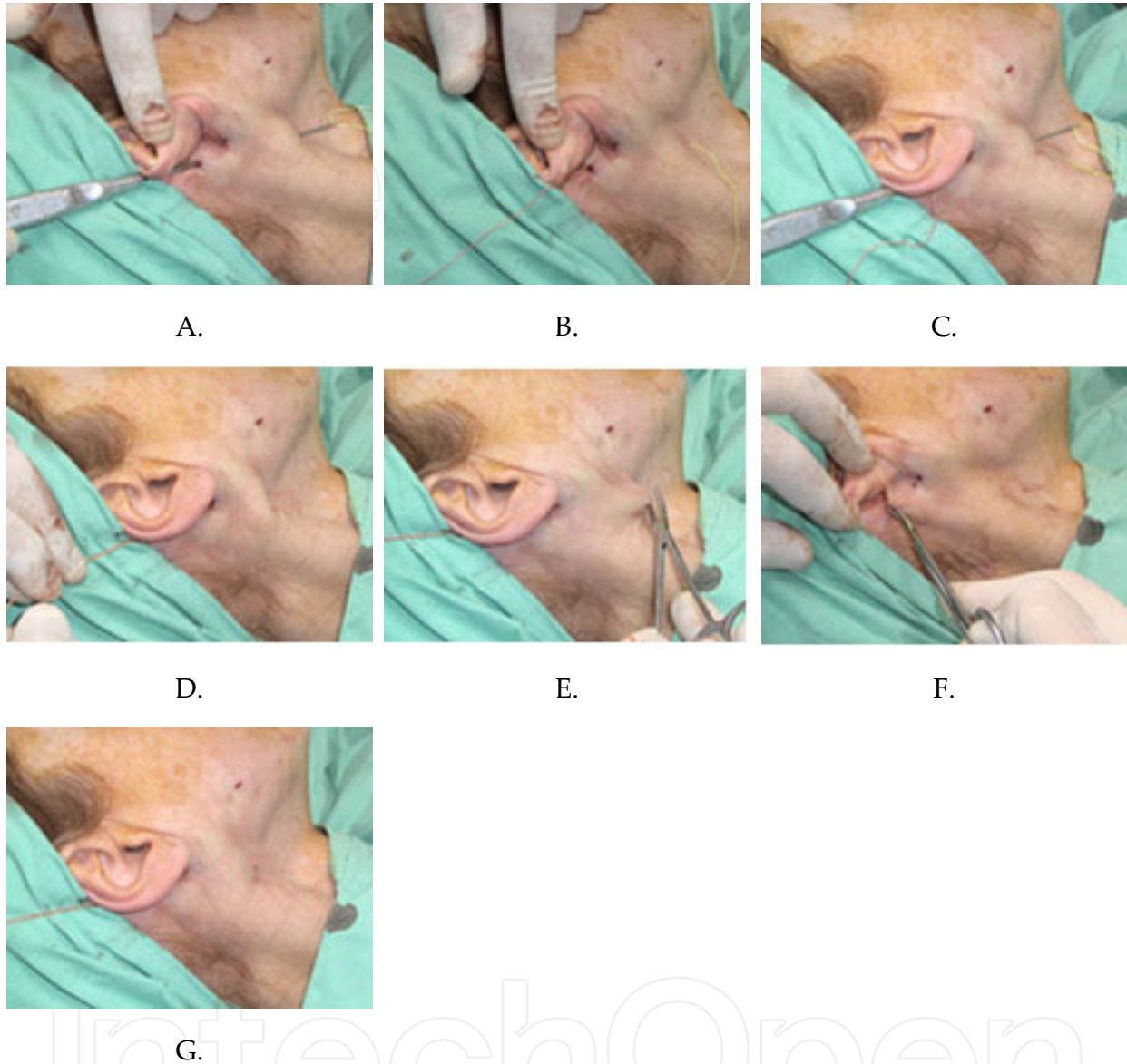
**Figure 1.** Lower face and neck SMAS lift, using Serdev Suture®



**Figure 2.** **A.** Lidocaine infiltration of the mastoid periosteum, colli fascia and SMAS at perforation points A, C, and along the line A-C, **B.** Scalpel blade No 11 skin perforation in the selected points, **C.** The needle is introduced through skin perforation A, then **tangentially** through the mastoid, superficial subdermal through colli fascia, SMAS/platysma and perforation point C. No dimpling should be visible above the needle., **D.** The suture is introduced through the needle pass C-A, **E.** Second pass of the needle following the same plan 2-3 mm away from the first pass, the needle eye is threaded, no dimpling is visible above the needle, **F.** The second end of the suture is introduced through the second needle pass C-A. The suture circle is fulfilled. The pull on the suture lifts the cheek SMAS, **G.** Skin dimpling has been removed by releasing the skin from attachments using a mosquito instrument, **H.** Skin is released at point A. Nice jaw line is visible.

## 2. Neck lift (A-B)

The second suture is done in the same manner, from point A to point B.



**Figure 3.** A. The needle is introduced through the skin perforation point A, then **tangentially** through the mastoid, **superficial** subdermal through colli fascia, **above the sternocleidomastoid muscle**, through platysma and perforation point B in the direction of the cervico-mandibular angle, B. The suture is introduced through the needle pass B-A, C. Second pass of the needle following the same plan, 2-3 mm away from the first one, D. The second end of the suture is introduced through the second needle pass, suture loop dives into the skin perforation point B and the suture circle is fulfilled. The pull on the suture lifts the platysma, E. Skin dimpling at skin perforation point B is removed by releasing the skin from attachments, using a mosquito clamp, F. Skin dimpling at skin perforation point A is removed by releasing the skin from attachments using a mosquito clamp, G. The knot is made and the result of neck lift and cervico-mandibular angle is immediately visible.

At the other side, lifting is performed by suture in the same fashion.

### 2.2.2. METHOD II: using a 2.5 cm retro-lobular incision

The author has found that the only place to hide the incisions and at the same time have a very good approach to cheek, lower face and neck SMAS in a distance of 3-4 cm in front of the tragus, is the fold behind the ear lobule. It usually permits a 1.5 to 2.5 cm long incision, which is enough to elevate pre-auricular SMAS and retromandibular platysma into the skin incision line and to suture them to the colli fascia and mastoid.

Infiltration is done in the retro-lobular fold and 3-4 cm in front of tragus. 1.5 to 2.5 cm incision in the fold is done and a blunt subcutaneous undermining is performed through the retro-lobular opening in a radius of 3-4 cm from the earlobe in direction to: 1. oral commissure, 2. chin, and 3. cervico-mandibular angle.

After undermining there are **2 options**:

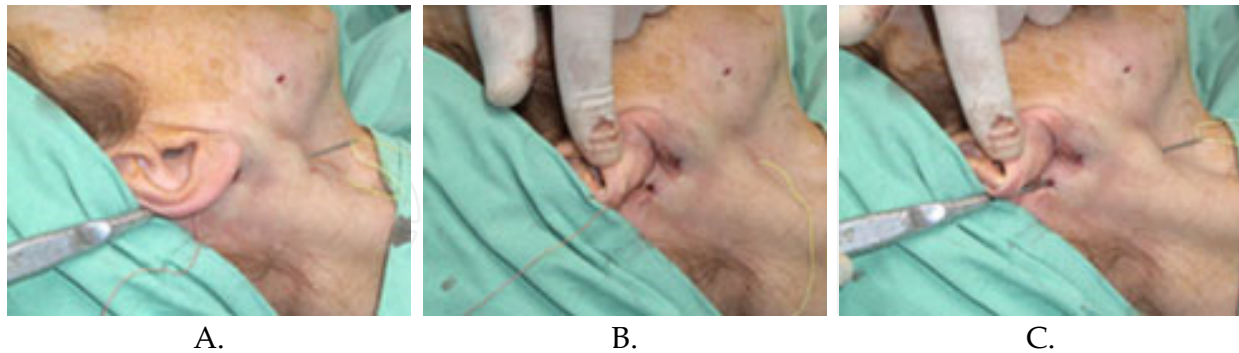**Option 1.** Cheek SMAS and platysma are captured with a mosquito instrument, pulled out into the wound opening and sutured to colli fascia and mastoid. In this manner the lower face and neck SMAS lift is developed from the preauricular SMAS (at the level of the earlobule) and platysma (at the mandibular angle), and attached posteriorly to the mastoid process. Medium elastic tension is applied, providing a lower face SMAS backward & upward lift and platysma upward lift (Fig. 1). Skin is closed in one layer. Gauze dressings are not obligatory but can be used overnight or for some hours. Sutures are removed after 7 days.

**Option 2.** After the retrolobular incision and undermining is done, a 60 mm Serdev® needle is introduced in the undermined subdermal space and biting SMAS, arrives in perforation point C in lower face (or B in neck). After threading the needle, the surgical suture is introduced into the incision. Then, from skin perforation point A, **tangentially** through the mastoid, the needle arrives in the retrolobular incision and takes the suture end, introducing it at skin perforation point A. The suture is located in the line A-C in the lower face (or A-B in the neck area) fixing mobile SMAS (platysma) and immobile mastoid periosteum. Second pass is subdermal again taking the second suture end at point C (or B) and introducing it into skin perforation point A. Thus, the circle of the suture is fulfilled and the suture loop dives in point C (or B in neck). The knot is tied at Point A. Skin dimpling at points C and B is removed by traction of the skin perforation points C or B and the suture in opposite directions. One or two stiches are placed, in order to close the wound.

Both Serdev Suture® techniques of lower face and neck SMAS lift are quicker and safer than classic invasive face lift techniques. Mobile SMAS is lifted behind the ear lobule and sewn down to stable bone and periosteal structures. This technique gives an aesthetic and normal “non-operated on” appearance to the face, without scars and totally covers patient’s expectation.

It is also possible to combine lower SMAS lift with other procedures such as fat pad removal, ultrasonic assisted liposculpturing of lower face and neck, medial platysma suturing, skin resurfacing, rhinoplasty, etc. Only a small number of patients need additional platysma sewing at the midline. In double chin cases, most important is to remove the fat

collection. In authors hands, ultrasonic assisted liposuction is the best method to obtain a good cervico-mandibular angle of the neck and to tighten the skin in such cases.



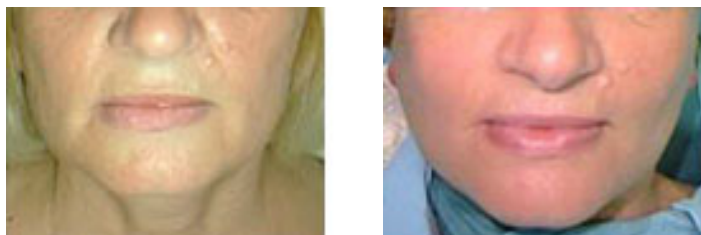
**Figure 4.** **A.** After Lidocaine infiltration, retrolobular incision and about 3 cm blunt dissection of the preauricular and subauricular zones, the platysma is fixed with the needle in point B and the needle is threaded, **B.** The suture is introduced from the skin perforation point B into the opening of the retrolobular incision. A tangential bite of the mastoid from point A and suture end is introduced from the incision to point A. **C.** The needle is introduced again from skin perforation point A subdermally to perforation point B and the needle is threaded. Introduction of the suture in line B-A follows, the suture loop will dive in perforation point B and the suture circle will be finalized. The suture will be knotted, dimples removed. Closure of the retroauricular incision follows.

### 2.3. Results

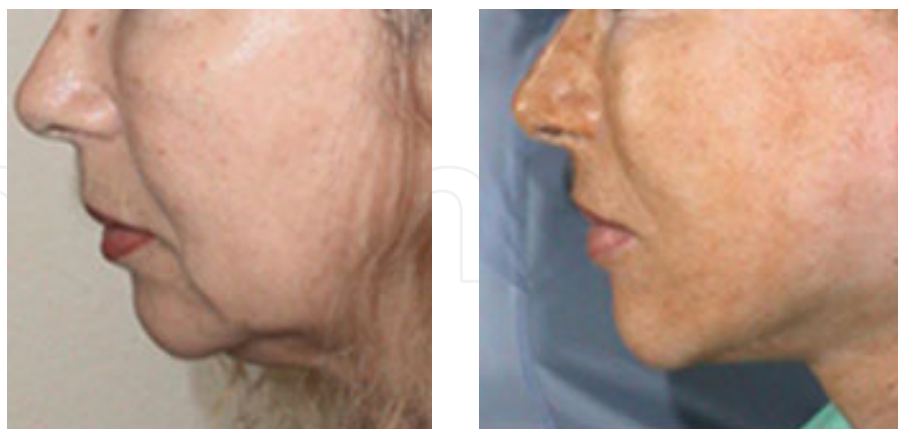530 patients have been operated with Method I during the period 1994-2011. Method II was performed in 386 patients. The result in these cases was immediate and optimal: there are no limitations to postoperative activities; no "operated-on" appearance, no visible scars and no real signs of operative intervention. The moderate facial tension generally imparts a pleasant sensation for the patient. Neither haematomas, nor infections have been observed. Bruising is rare.

In method I, in very loose skin cases, it is possible to obtain some swelling (bulging) effect at the sternocleidomastoid site that adapts and disappears in 2-3 weeks and could be easily covered by hair in female patients. In method II, skin undermining prevents from bulging or folding.

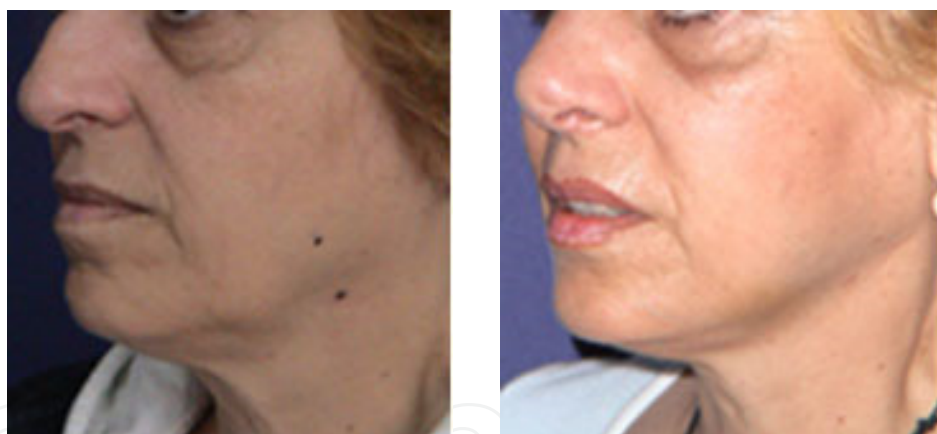In method I, the skin punctures disappear in 2-3 days. In method II, the skin scar in the retrolobular fold is invisible and, additionally, there is no skin tension.



**Figure 5.** Visible change in the lower face appearance after lower SMAS lift by sutures with skin punctures only.



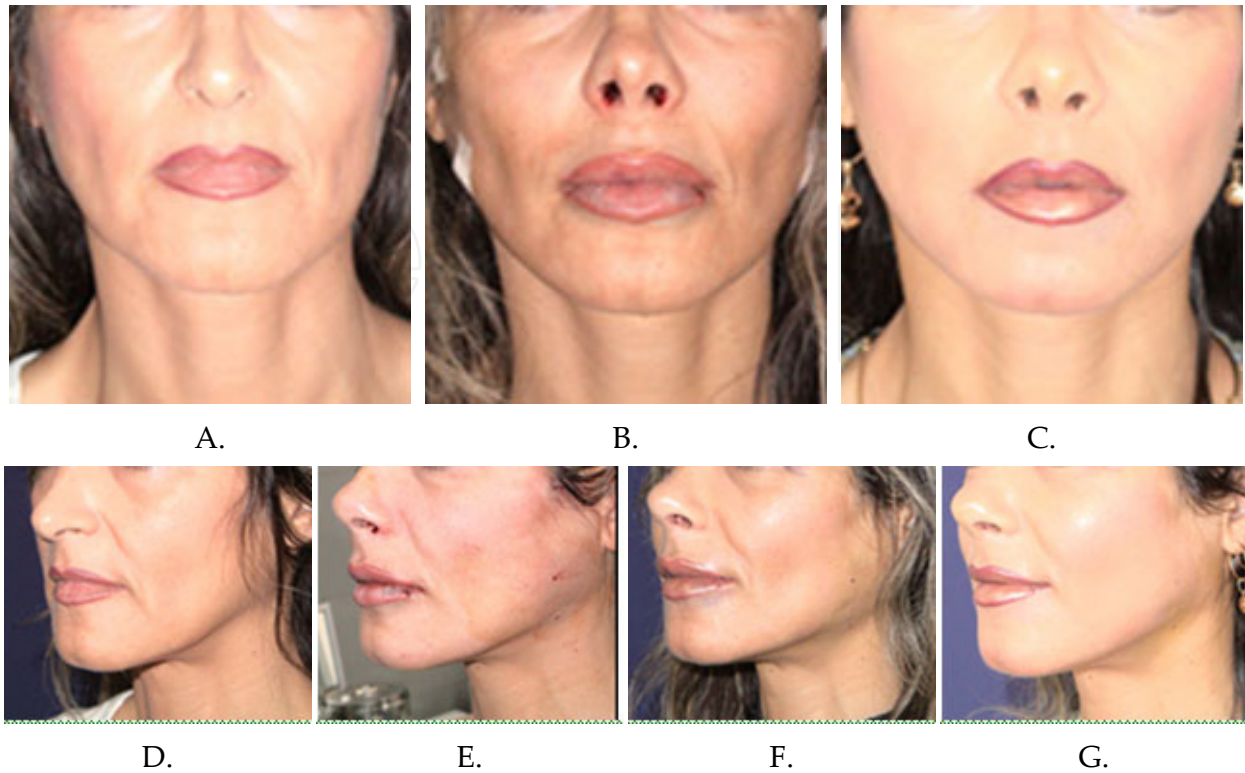
**Figure 6.** Result, immediately after surgery in the OP theatre. Immediate total change in the lower face after temporal, brow lift and a lower SMAS lift, using sutures with skin punctures alone.



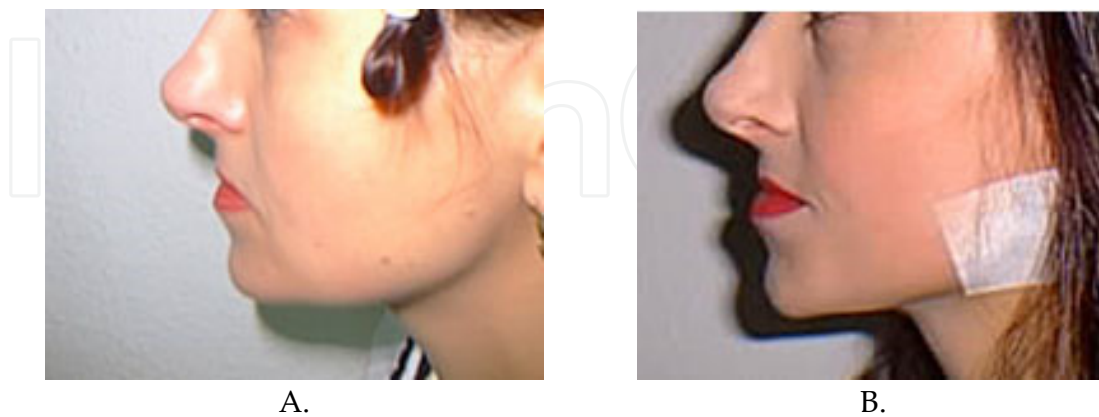
**Figure 7.** Before and after temporal SMAS, brow, and lower SMAS lift using sutures with skin punctures alone, combined with rhinoplasty. The change pleases the patient. Rejuvenation of the face.

In one case, when method II, option one was used, upper lid ptosis occurred during fixation of the pre-auricular SMAS. Immediate release of the suture solved this “complication” on the spot and another suture was performed without further complication. In one 63 year old patient, in line with her aesthetic requirements, an additional pre-auricular skin excision (S-lift) was performed 3 years after the suture lift. Due to the previous SMAS lift using method II, it was not possible to excise more than 2 to 3 mm skin in front of the ear.

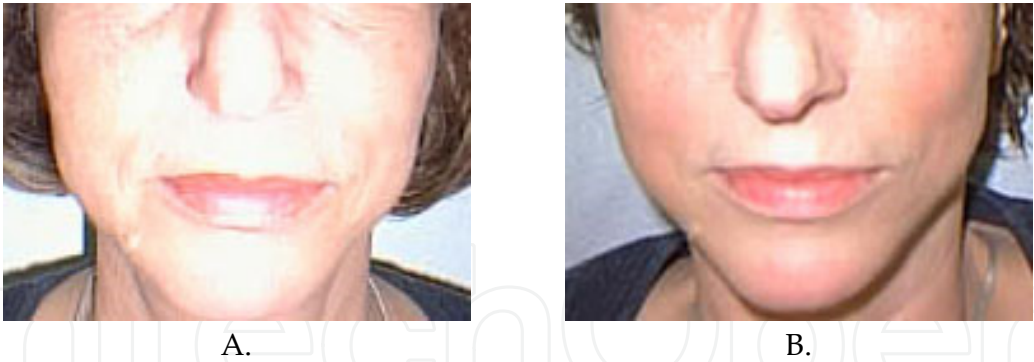
No other complications or complaints have been observed in this period.



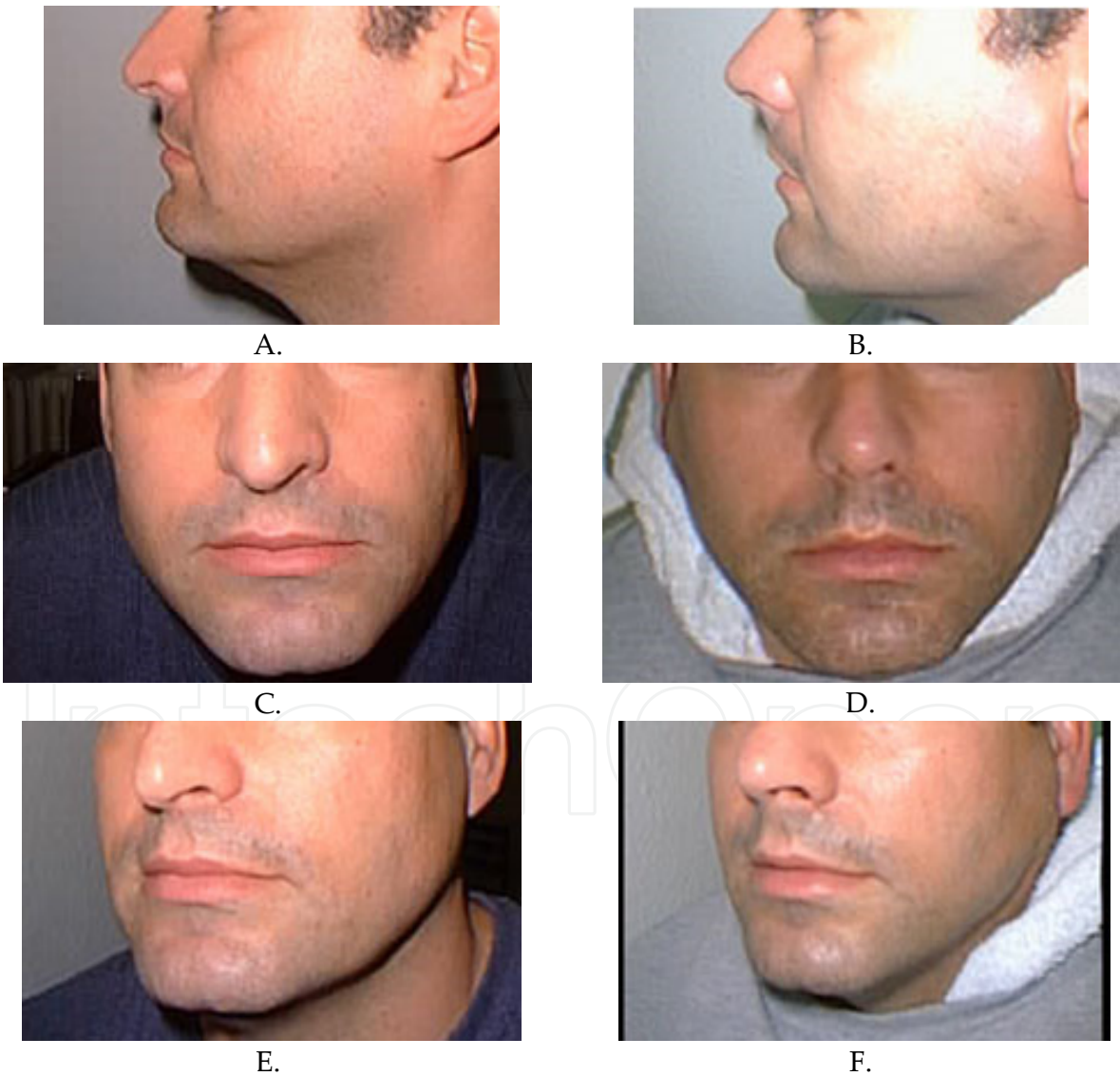**Figure 8.** A, D. Before, B, E. Immediately after simultaneous temporal, medial and lower SMAS face lift by sutures using skin punctures only, brow lift by sutures, rhinoplasty, and lip augmentation. The skin punctures for the lower SMAS lift by sutures are visible (E), F. the day after surgery. C, G. After 3 days with make-up.




**Figure 9.** A. Before and B. immediately after surgery in an 37 years old patient. A pleasant result in the lower face and jaw line. The bandage covering the skin punctures stays for overnight only. Patients usually return to work in a day or two.



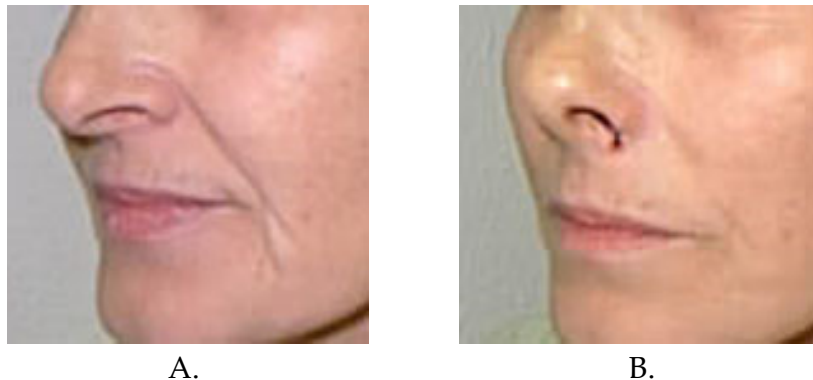**Figure 10.** Rejuvenation in an elderly patient. **A.** Before and **B.** after lower face and neck SMAS lift with retro-lobular incisions. Very good result with skin beautification. The SMAS and skin attached to it is tightened.



**Figure 11.** **A, C, E.** Before. **B, D, F.** After lower face SMAS lift with retro-lobular incisions in a 40 years old man, plus T-excision and columella sliding rhinoplasty. No signs of an operated-on appearance. Defined cervico-mandibular angle post op.



**Figure 12.** **A.** Before. Thin and loose skin in the lower face. Gravity effect on the soft tissue and skin is visible in different positions. **B.** After lower SMAS-platysma lift with retro-lobular incisions in a 37 years old female patient. The SMAS, attached soft tissue and skin are tightened. No signs of gravity on the soft tissue and skin are visible in any position after surgery. Lovely tightened youthful “hungry cheeks”, pleasing the patient.



**Figure 13.** **A.** Before, **B.** Effect on the nasolabial and marionette folds in a 53 years old patient after lower SMAS lift, rhinoplasty and allar base narrowing.

## 2.4. Complications

Minimal and very rare problems have occurred with the suture technique in some patients. As described above, one case of taking a facial nerve branch in the suture during performing method II led to ptosis of the upper lid and was solved immediately by removing of the suture. It is a rare complication, because the facial nerve runs a little higher, just below the tragus and immediately after that penetrates deep into the parotid gland. Sutures can be easily removed and placed again at any time with nearly no downtime.

In method I, the needle penetrates the tissue much lower and we have had no cases of facial nerve insertion in the suture. Three patients described some loss of sensation in the ear lobe for a couple of weeks. The trauma of involving the great auricular nerve in the suture, provoked by a lateral traction, adapts in some weeks. Swelling and bruising are rare.

## 2.5. Discussion

Beautification and immediate social activity are the first and most important aspect of patients' requirements. The author's experience indicates that his specific methods of lower

SMAS lift can be performed safely with minimum complications and maximum patient satisfaction.

Solely stretching the skin is an obsolete concept. Excision SMAS lifts, extended SMAS lift, deep plane, and sub-periostial face-lifts are associated with a number of complications, including haematoma, pixie ear, nerve injury, and skin sloughing. Deep-plane and composite techniques achieve a deeper suspension, but the risk of facial nerve injury is higher. Post-operative care is longer and pre- and retro-auricular incisions are not the patient's best contemporary option.

The author's suture methods are performed to obtain and preserve a youthful lower face and neck through fixing lower face and neck SMAS to mastoid (or very rarely to occipital periosteum). These techniques of "scarless lower SMAS face and neck lift" provide a safe alternative to other face lifts using preauricular skin incisions and elevation, platysmal and subplatysmal flaps, SMAS dissections, submental surgery, deep plane or composite face lifts. Injury to the facial nerve in rhytidectomy has been described in less than one percent of the cases, and a spontaneous return of function results within 6 months in more than 80 percent of these injuries.

With the introduction of the author's technique, performed without aggressive platysmal and subplatysmal flaps and SMAS dissections, the risk of injury to facial nerve branches has decreased significantly. Nevertheless, the operating surgeon must follow up the patient's reactions carefully for signs of facial palsy during operation.

The scarless lower face and neck SMAS lift by sutures, using skin needle perforations only or hidden retro-lobular incision, provides a safe and effective ambulatory method for beautification and rejuvenation of early and medium sagging face. It is an effective method that addresses problems of jowling or submental laxity. A nice and youthful shaped jaw, acute cervicomandibular angle and straightened cervical skin are the most desirable effects. The results fully correspond to patients' desires. The effect is immediate and without visible scars.

The lower SMAS lift is a bidirectional lower face and neck lift that gives a harmonious, strong lifting effect on the sub-zygomatic area and jaw and creates an acute cervicomandibular angle. It achieves partial correction of the nasolabial folds and submental area laxity.

In author's patients, the lower SMAS-platysma lift is very often combined with temporal, mid-face SMAS lift and brow lift by sutures, in order to obtain a "total SMAS lift". Generally, SMAS lifts by sutures are nice and easy ambulatory weekend procedures.

### **3. Chin enhancement and form correction**

The primary goal of facial aesthetic (cosmetic) surgery is beautification, achieving balance and harmony. The mental area must be addressed to the complete synthesis of the face. The concept of augmenting, correcting and adjusting the chin position has evolved so

significantly that it is now an important procedure in face beautification. Various autogenous implants for chin augmentation have been in use for over 100 years. The advent of synthetic materials has given rise to various types of alloplastic implants with their advantages, disadvantages and complications.

The author's technique of chin soft tissue suspension, using a simple durable suture with extended absorption delay, is indicated to correct microgenia, to obtain the necessary projection and to adjust chin symmetry. It is ideally suited for correction of most chin disproportions, such as: profile deficiencies, aging (witch) chin, asymmetries, disharmonies, and is used for beautification and rejuvenation of the entire face as a single or combined operation, with very satisfying cosmetic results.

### 3.1. Introduction

The importance of the chin in face beautification is determined by the fact that the chin is a part of the lower third of the face. Aesthetically it has to fit to the straight line of the noble profile, to the "beauty triangle" of the lower face, and the facial golden section rule of 3 proportionally equal parts. Chin prominence gives the essence of visage character.

Profile deficiencies are due to congenital, traumatic and aging factors with different degrees of deformity. Loss of volume or a genetically small mandible affect the aesthetics and expression of the face, mouth, chin, and neck. Disharmony between the skeletal support and the soft tissue envelope is a common cause of aesthetic concerns.

Although standards of beauty evolve over time, classical facial features such as symmetry, straight profile, good chin projection and proportions remain as rules. A comprehensive beautification (including rejuvenation of the chin) depends on accurate analysis of the lower face with attention to the contours and underlying structures.

Many surgical options are available to restore the definition of the chin region. A large variety of materials are used by surgeons for augmentation purposes, although the search for the perfect implant continues.

The author's surgical suspensory procedure, using a simple suture, has the aim to return the chin's soft tissue to a more aesthetic and youthful position and to meet patients' demands for immediate result, fast recovery and beautification without implanting foreign materials.

#### 3.1.1. Anatomy

Although the process of facial aging is predictable, the rate of changes varies from person to person. With aging, laxity develops in the skin and subcutaneous tissues, the result of which is an aesthetically incorrect projection and contour of the anterior mandible. The soft tissues are subject to gravity and undergo progressive atrophy. Aging (Witch) chin is an unpleasant aesthetic defect, characterized by ptosis of the premental tissue and a deep submental fold. Bone resorption and soft tissue atrophy are the most important components. Loss of bone volume leads to loss of support for the soft tissues of the face.

Aesthetic cosmetic rejuvenation of the face and neck involves repositioning of poorly supported soft tissues. The effect of surgery in these cases aims to improve and restore a youthful appearance. This depends on the bone structure, amount and distribution of subcutaneous fat, as well as the interconnectedness of the superficial muscles to the overlying skin.

*3.1.2. The objective* of the author's specific technique is to suspend the loose and hanging soft tissue of the chin, to give natural height of the chin projection and to advance the submental skin in order to obtain a youthful jaw line. Avoidance of common problems associated with implantation of foreign materials is an additional goal.

### *3.1.3. Definition*

Suturing and suspending the loose chin soft tissue in front of the immobile menton in order to obtain volume, projection and a straight profile. Using the suture method, the chin could be positioned forward, up or down, left or right, thus obtaining proper aesthetic proportions and facial symmetry.

### *3.1.4. Surgical approach*

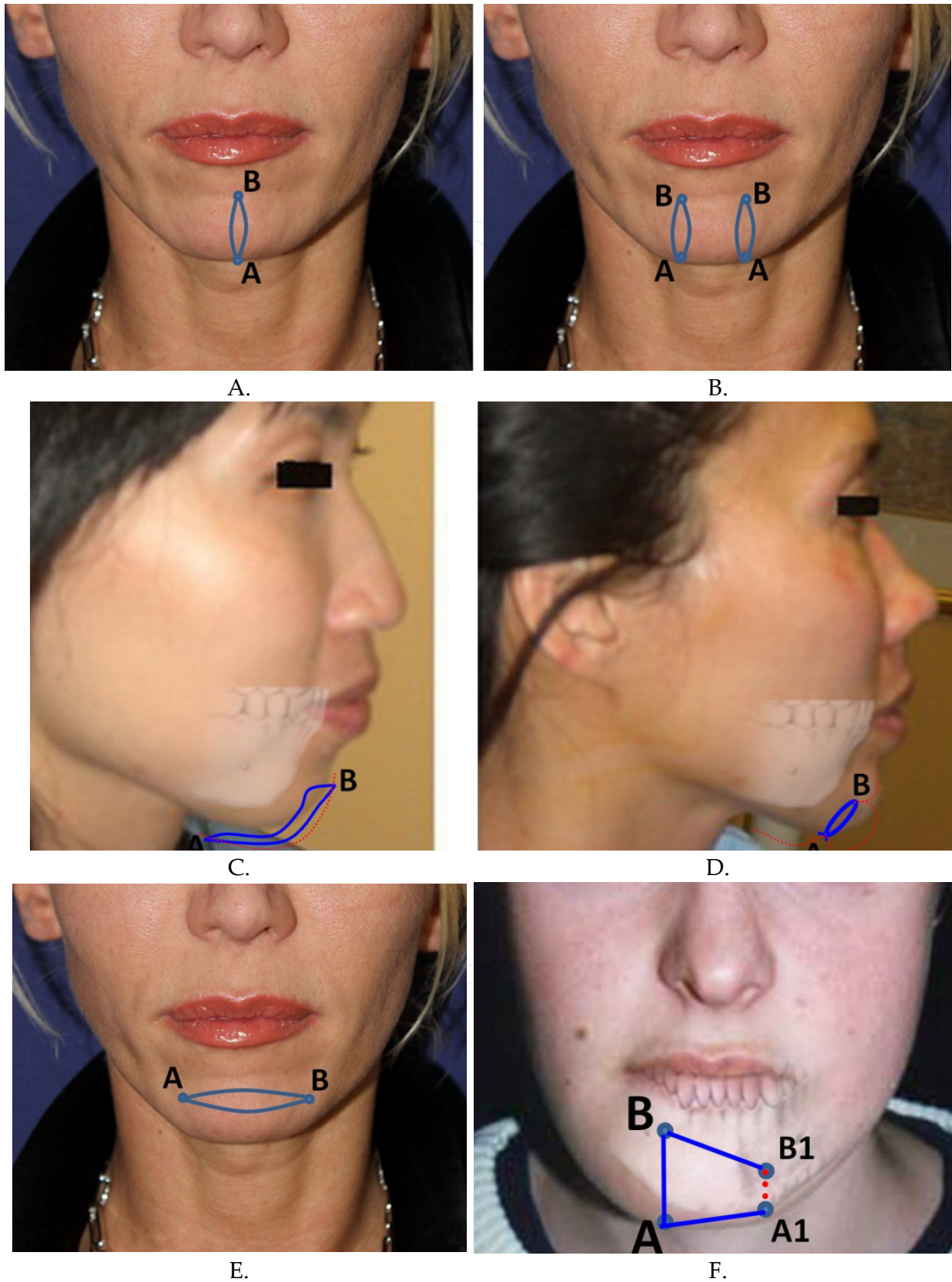
Two skin punctures to insert the needle.

## **3.2. Author's surgical technique**

One or more Serdev Sutures® of the chin soft tissue could be used to obtain roundness and projection of the chin, where desired. The author uses only two skin perforation points (A and B) in the sub- and supra- mental folds to insert the needle and perform a suture, which, bulging the sutured fibrotic soft tissue, creates volume in front of the immobile menton. An additional option is the horizontal suture with 2 lateral skin perforation points.

Using different angles of needle positioning, the author has introduced the Serdev Suture® method for total or partial enhancement, augmentation and positioning of the chin up or down (to adapt facial aesthetic proportions), or left or right (to obtain symmetry). I.e. chin lift is created tridimensionally: up or down, forward, left or right. Creation of a dimple is another option with author's techniques.

The author prefers to start from the submental skin perforation point A. **Video:** <http://www.youtube.com/watch?v=oqJreY-JsCM>. If more tissue is necessary, the perforation point A is located in the submental fold. When positioning the needle in the skin perforation point, the submental perforation has to be moved forward anteriorly to the menton. **NB!** Do not perforate the muscles dorsal to the menton. If a "Witch" chin has to be lifted, the submental skin perforation point should be positioned much more anteriorly, so the projection will be higher. If the chin has to be projected downwards, the second perforation point B can be lower than the supramental fold and first point A should be maximally dorsal at the submental fold. The suture can be placed more lateral to project one side of the chin only (to equalize symmetry), or the central chin tissue can be fixed to the mental periosteum more laterally with the same result.



**Figure 14.** A, B, C, D, E, F. Different variations of fixation of the fibrotic soft tissue, with or without fixation to menton

### 3.3. Vertical chin suture

A 50 mm or 60 mm Serdev® needle enters through the submental skin puncture, then in front of the menton, slips along the anterior surface of the bone and exits through the other skin puncture at the supramental fold. After threading the needle with surgical suture USP 0, the suture is positioned in the deep first needle pass. Performing the second pass, the needle re-enters through point A, then medium deep through the soft tissue, and exits through point B to take the second suture end and introduce it in the second pass. **NB!** When performing the medium deep pass it should not be superficial. If skin dimpling appears above the needle, the pass is too superficial and should be repositioned deeper.

Thus, the suture circle is finalized and when pulling the suture, the suture loop dives in perforation point B. After it is tied, the knot dives into perforation point A. Chin projection is immediately visible. Then, any dimpling and skin attachment to the suture should be removed using a mosquito clamp. **NB!** If the needle pass does not engage dermis, removal of dimpling at the skin perforation points is easy. If dermis is caught, dimple removal is impossible and the suture procedure should be repeated. Twist the needle softly forward or backward to find its way through the skin perforation openings without fixation of dermis.

Performing such a suture, the available chin soft tissue is projected in front of the immobile menton and enhancement/augmentation is obtained. The angle of needle position gives direction of the enhancement - up, down, left or right. In cases of persistent deep chin dimple, 2 sutures are possible both sides.

If the projection is not sufficient, an additional horizontal suture can be added. The horizontal suture has 2 perforation points laterally and 2 passes should be done – the first one deep near the menton and the second - middle deep.

The number of sutures could be more than two, in order to obtain the necessary projection.

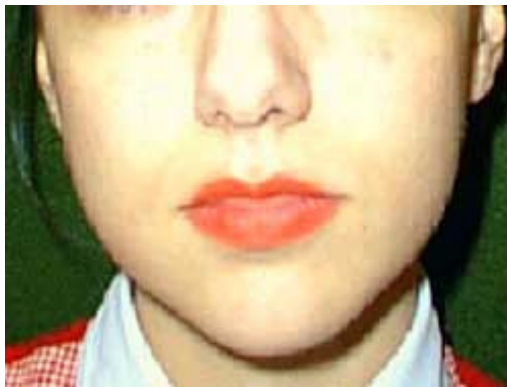This ambulatory procedure takes only a few minutes. No dermal closure and no bandages are used. Facial wash should be done on the following day. The skin puncture in the supramental fold could be visible for 2-3 days and patients may use make up. The early post-operative period swelling is almost invisible and patients can return to their social life as soon as they wish.

### 3.4. Results

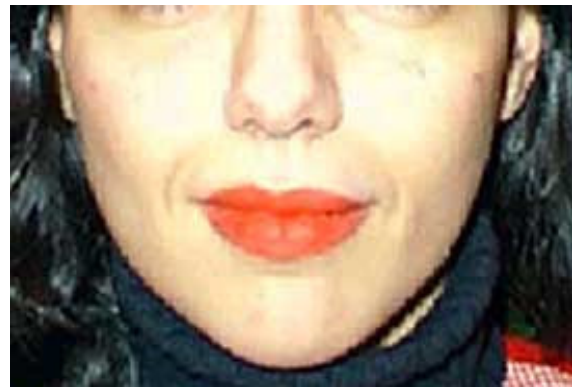1095 patients underwent the above-described procedures for ambulatory suture chin augmentation in the author's clinic and abroad, between 1993 and 2012. Patients were followed up between 2 and 11 years and have reported excellent clinical success. No complications have been observed. There has been no aesthetic disappointment, no seromas, no haematomas and no infection. The soft tissue enhancement has been observed to be an average of 8.0 mm (range 4.1 to 11.8 mm). No asymmetry has been observed. On the contrary, this particular technique has been used to solve problems with asymmetry of the face. The author frequently leaves a bit of dimpling at the lower submental perforation area

that defines the lower chin line better and enhances the Caucasian appearance that is very much appreciated by patients. Straight line of the profile has been obtained satisfactorily. Sometimes, additional 2-3 mm of chin prominence are required. In order to reach a straight profile line, a second suture enhancement has been done in 21 cases and in one case of pronounced retrogenia and small amount of soft tissue, the enhancement was done in 3 steps.

The obtained chin projection enhances the "beauty triangle" of the "chin and cheekbone complex". The neckline becomes more slender and youthful. These visual criteria measure the degree of success in fashioning of chin aesthetics. We now believe that by using this soft tissue suture technique, with the exception of extreme cases, it is possible to satisfy the above-mentioned criteria in most patients.

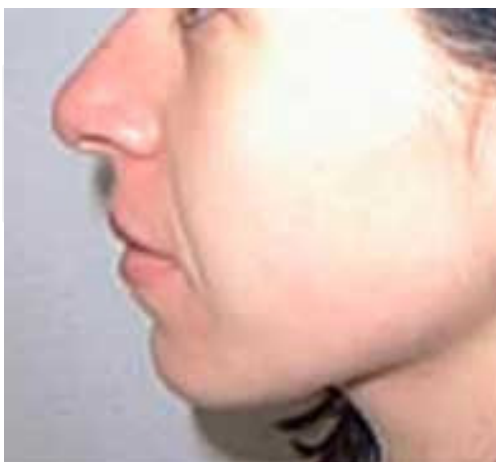

A.

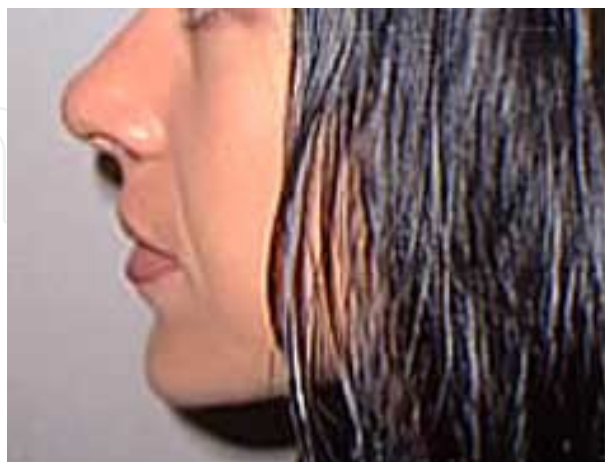

B.

**Figure 15.** A. Before and B. after chin correction and enhancement along with lower face ultrasonic liposculpture to obtain the beauty triangle of chin and cheekbones. The additional upper lip augmentation is a part of the face proportion adjustment and beautification.

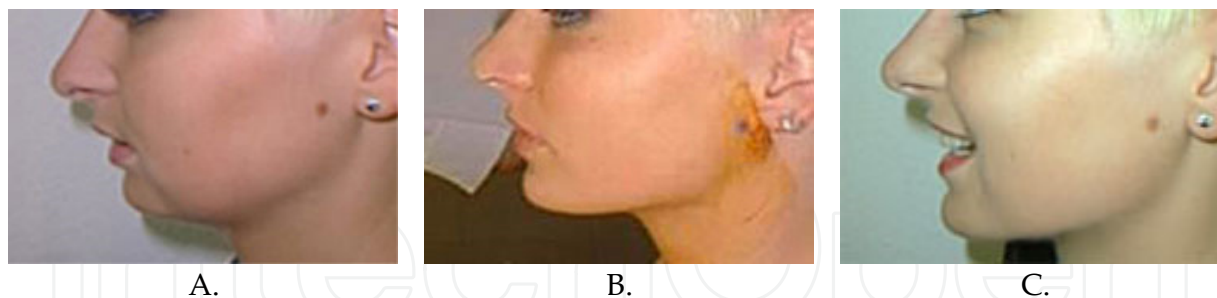


A.

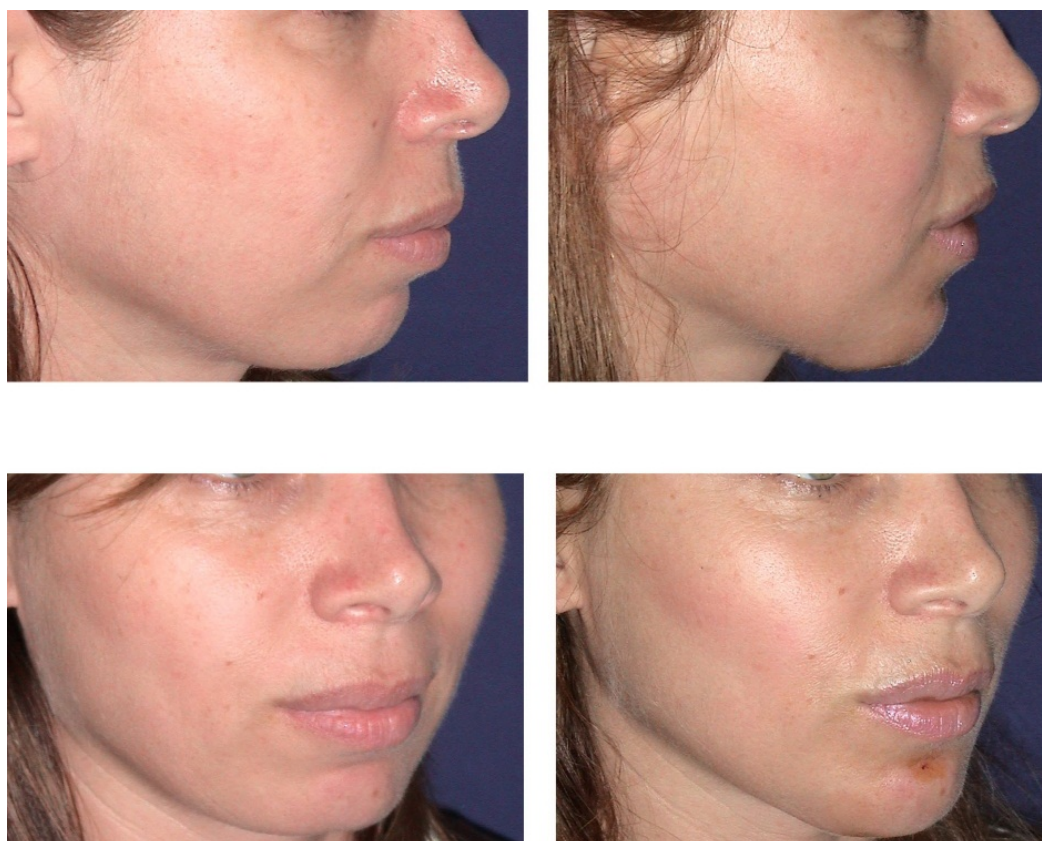

B.

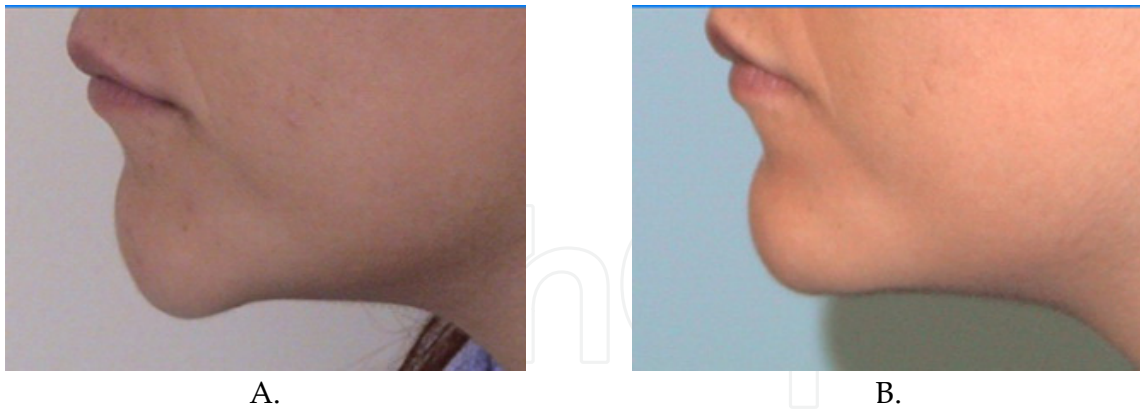
**Figure 16.** A. Before and B. after chin enhancement to obtain straight line of the profile and define the jaw line, and good proportions with 3 equal parts of the face. Simultaneous rhinoplasty – T-excision and columella sliding for nasal tip rotation and projection.



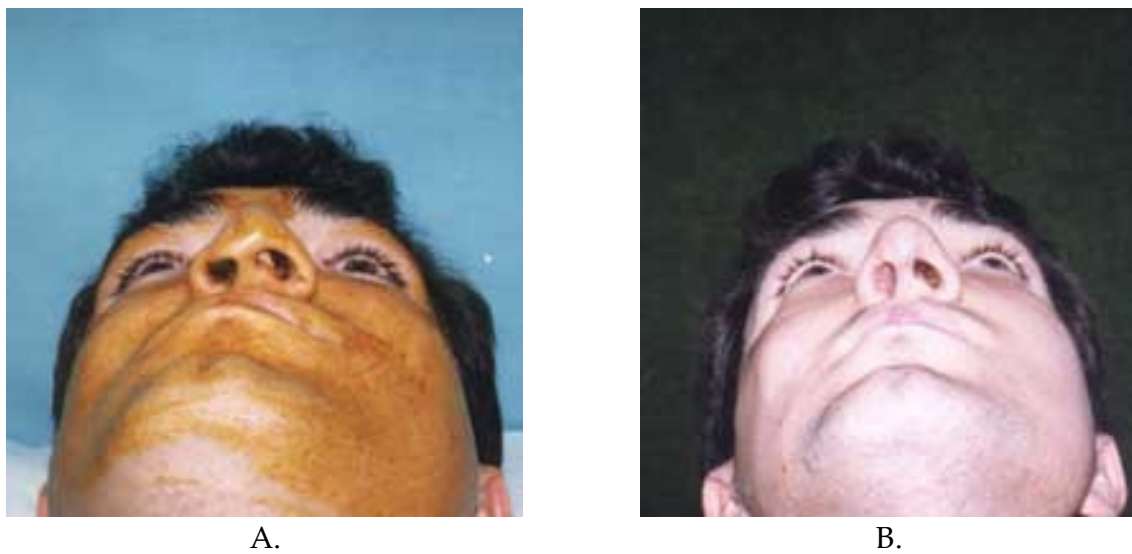**Figure 17.** A. Before, B. immediately after chin enhancement and tip rhinoplasty (T-excision and columella sliding) to obtain a straight profile and aesthetic proportions of the face (intra-op Betadine disinfection still not washed off). A slender neckline, due to skin lift forward (when moving the submental skin perforation point A in front of the menton) is obtained and is recognized as an attractive feature of youth with this method. C. 5 years later. It is difficult to find any change in the operated chin position during the 5 year follow up.



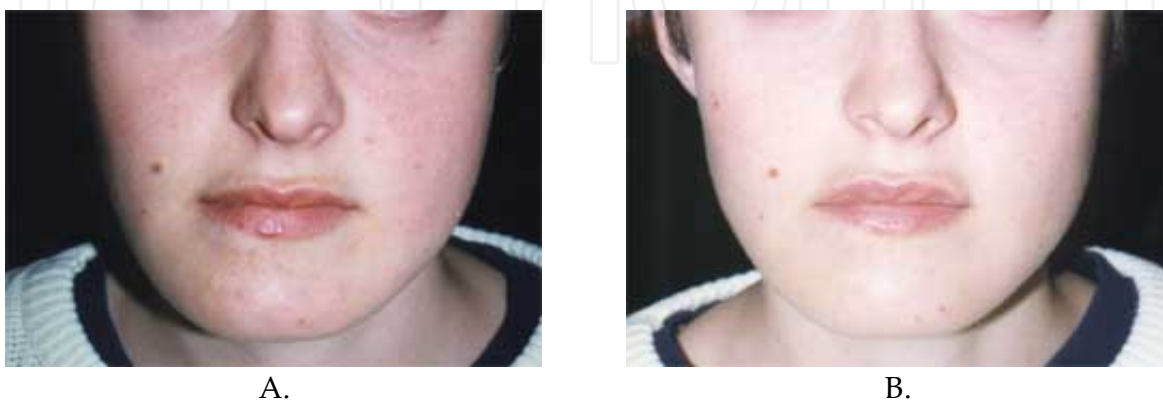**Figure 18.** Better chin position is visible from all angles



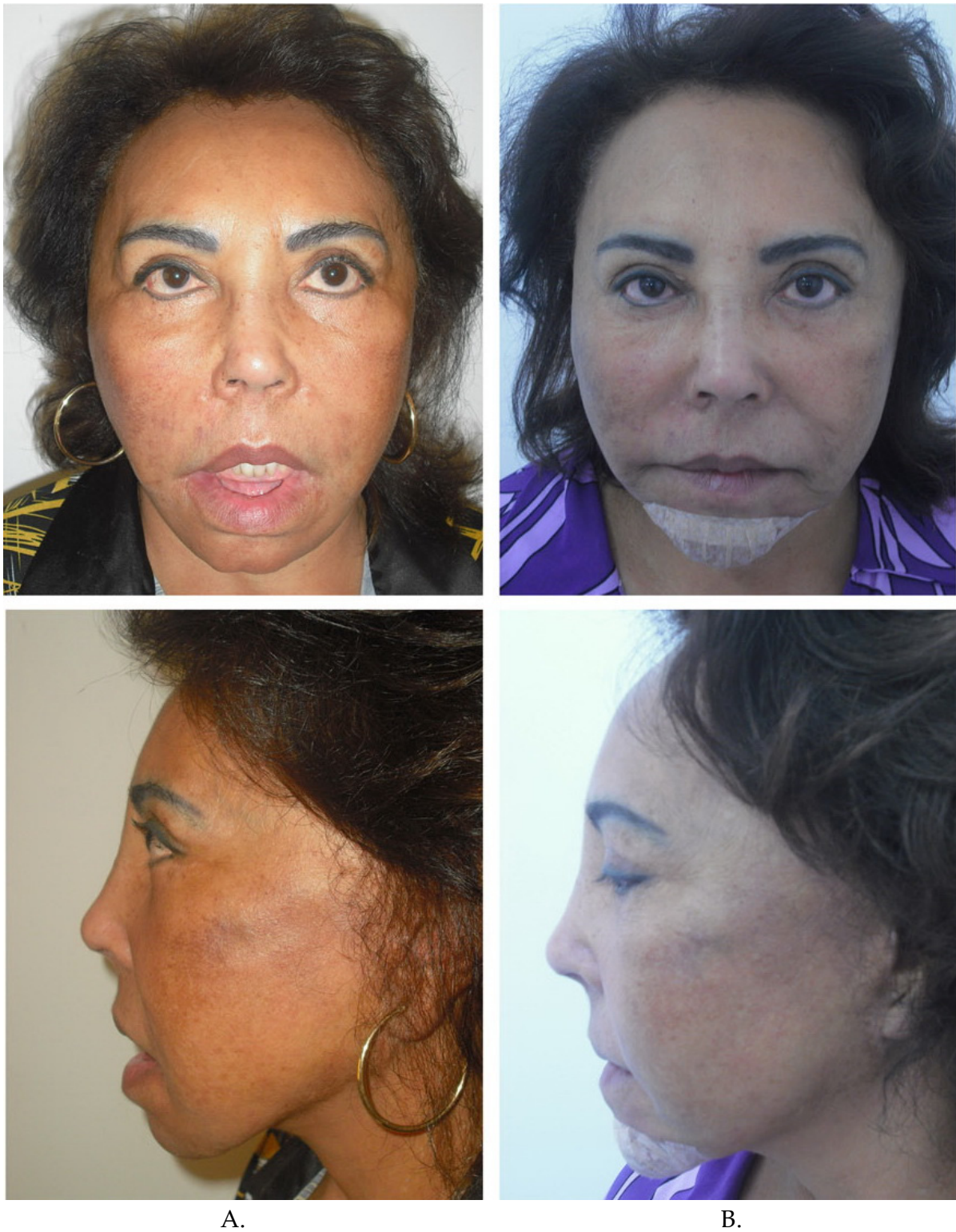**Figure 19.** **A.** Before – A witch chin in a young patient. **B.** After chin enhancement in front, suturing the tissue higher.



**Figure 20.** **A.** Before (Betadine disinfected) and **B.** After correction of the chin position and nose deformity in one session. The chin is sutured to the left.



**Figure 21.** **A** Before, **B.** After chin suture to the left to correct the deformity of the face.



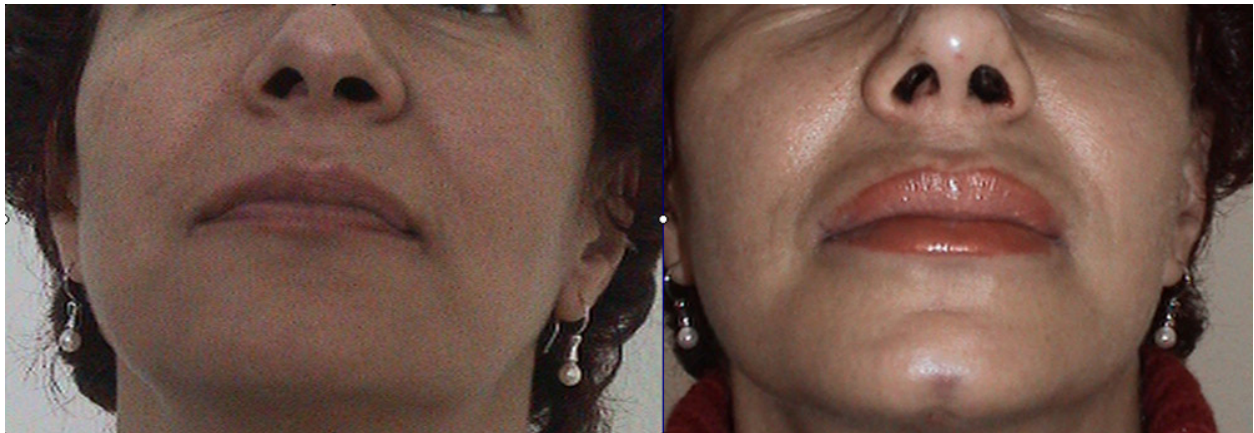**Figure 22.** A. Too much plastic surgery. Hanging chin/lower lip complex after removal of infected chin implant. B. Immediately after fixation of the chin fibrotic tissue to periosteum by suture.

The longevity of any technique depends on the stage and progression of aging, i.e. atrophy of the soft tissue and skeleton. The author has had a satisfactory longevity of results in his patients and secondary chin enhancement after years was necessary only in 5 cases. Using serial photography during the follow up period he has not noticed remarkable changes in the result.

The chin soft tissue suture technique for anterior adjustment and form correction provides a soft, natural facial appearance and it continues to be the method of choice for form correction, augmentation and beautification of the chin. All patients have rejected implantation techniques.

### 3.5. Chin dimple

Dimple formation is easy and consists of dermis fixation to periosteum by Serdev Suture® scarless closed approach. In such case, 2 points at the 2 ends of the dimple are used to capture the dermis between them. For this reason, the author may or may not use additional perforation points. It depends on what the patient wants – a dimple solely or with additional chin enhancement, and/or chin form correction.



A.

B.

**Figure 23.** Immediate result after scarless chin dimple formation by suture.

### 3.6. Discussion

For the past several decades, various materials have been developed to improve the appearance of the chin as one of the important subunits of the face. Initially, autogenous tissue grafts, such as: removed nasal hump, described by Aufricht in 1934, autogenous skeletal and cartilage transplants, ear cartilage grafts, rib cartilage grafts, fat, fascia, tendon, bone and dermal fat grafts have been used. Additional options became available with the development of a variety of alloplastic materials for augmentation genioplasty. Polymers are used primarily for bone deficiency substitution. Mersilene mesh introduced in 1950, silicone and silicone bag-gel implants, Gore-Tex, Medpor, Supramid, Silastic, injectable collagen, expanded polytetrafluoroethylene (e-PTFE), high-density polyethylene (HDPE), polydimethylsiloxane (PDMS), Proplast I (PI), Proplast II (PII), porous block hydroxyapatite (PBHA) are available for correction of microgenia. Placed through an anterior oral sulcus incision or a submental incision with a screw fixation, many of these implants have good organotrophic characteristics, allowing tissue ingrowth. Available in a variety of block, sheet, and preformed shapes, they can be easily modeled and maintained. Antibiotics, irrigation, and closure of the incisions are performed. A lot of absorbable injectable materials came into the market in the last decade. Reviews of biomaterials used for mandibular implantation prove that although today's armamentarium of implant materials is vast, the search for the perfect implant continues.

Risks and complications with foreign materials: We address general considerations of toxicity relevant to all biomaterials. Investigations and overviews present data from a large number of clinical series on incidence of complications for materials used in this specific application. Although few, there are results that show infection, displacement, temporary paresthesias, incidences of absorption, rejection, or extrusion, implant migration, etc. Complications are manageable: these include implant displacement, infection has been treated with irrigation, closed system suction, etc. Most often infection requires a re-operation to remove the implant. Other complications such as internal and external soft tissue erosion, indentation, slippage, asymmetry and late bone resorption under the implant have been seen. Wound repair around implants is achieved through capsule formation. Fibrous capsule formation can be interrupted by infection, immune reaction, implant migration, or extrusion. No implant can be perfect for every face.

Due to the search of simpler techniques and based on his own experience, the author proposes an operation without implants, using only a suture of the chin soft tissue, suitable for chin enhancement, beautification and form correction. The author followed up 527 patients with chin augmentation and chin form correction for 2 and more years of whom no one had a complication. 398 of them had combined face beautification operations done.

As a single procedure or simultaneously with other facial rejuvenation operations, the chin suture of the soft tissue is ideally suited for correction of most chin aesthetic disharmonies in patients with a congenitally small mandible, patients requesting facial beautification and

rejuvenation as well as correction of asymmetry. Simplicity and immediate return to social life are the major benefits of this procedure. It provides a natural, "non-operated-on" look that is largely sought after by patients today.

As implants are foreign bodies with some limits of longevity, they are mostly not accepted in the author's selection of patients and his technique became a method of choice, minimizing the tissue trauma. It appears to be an attractive alternative to other chin augmentation techniques.

#### 4. Total face beautification using Serdev Sutures®

Beautification is the main goal in cosmetic surgery. Both words "cosmetic" in Latin and "aesthetic" in Greek language mean "beautification". Cosmetic and aesthetic surgery are wrongly understood as rejuvenation, anti aging, restoration, reconstruction etc., if no beautification is obtained.

It has been found that certain points in a face composition automatically attract the observer's attention. Many objects and scenes with certain proportions please us automatically.

##### 4.1. Aesthetic proportions


Aesthetics as a science has been first established in ancient Greece and is based on aesthetic proportions, angles and volumes. Those aesthetic rules are intransient and are a persistent base for the understanding of beauty in all ethnic groups and cultures. It is studied in "History of Art".

In face aesthetics, the main proportion guidelines are given by **the Golden Section Rule** – the face is divided into 3 equal parts. Ancient Greeks have found that distance between columns has to be equal, to give an aesthetic perspective from different points of view. Leonardo da Vinci investigated the principle that underlies our notions of beauty and harmony and called it the Golden Section. Long before Leonardo, Babylonian, Egyptian, and ancient Greek masters also applied the Golden Section proportion in architecture and art.

Another golden rule is **the Golden Ratio** of 1.6 (1.6180339887...) that is an important rule in human body and extremity proportions. It is attracting our attention so much that credit cards have been created using the golden ratio.

##### 4.1.1. Aesthetic angles

As face ptosis affects the lateral face, angles should be positioned higher (laterally) to create the beauty of youth, corresponding to the mask of comedy in ancient theatre, unlike the mask of tragedy. So, the lifting effect on face should be lateral.



**Figure 24.** The Golden Section Rule permits precise examination of the face and its proportions

#### 4.1.2. Aesthetic volumes

In the face, the “beauty triangle” visualizes apparent chin and cheekbones. Higher cheekbones represent youth.

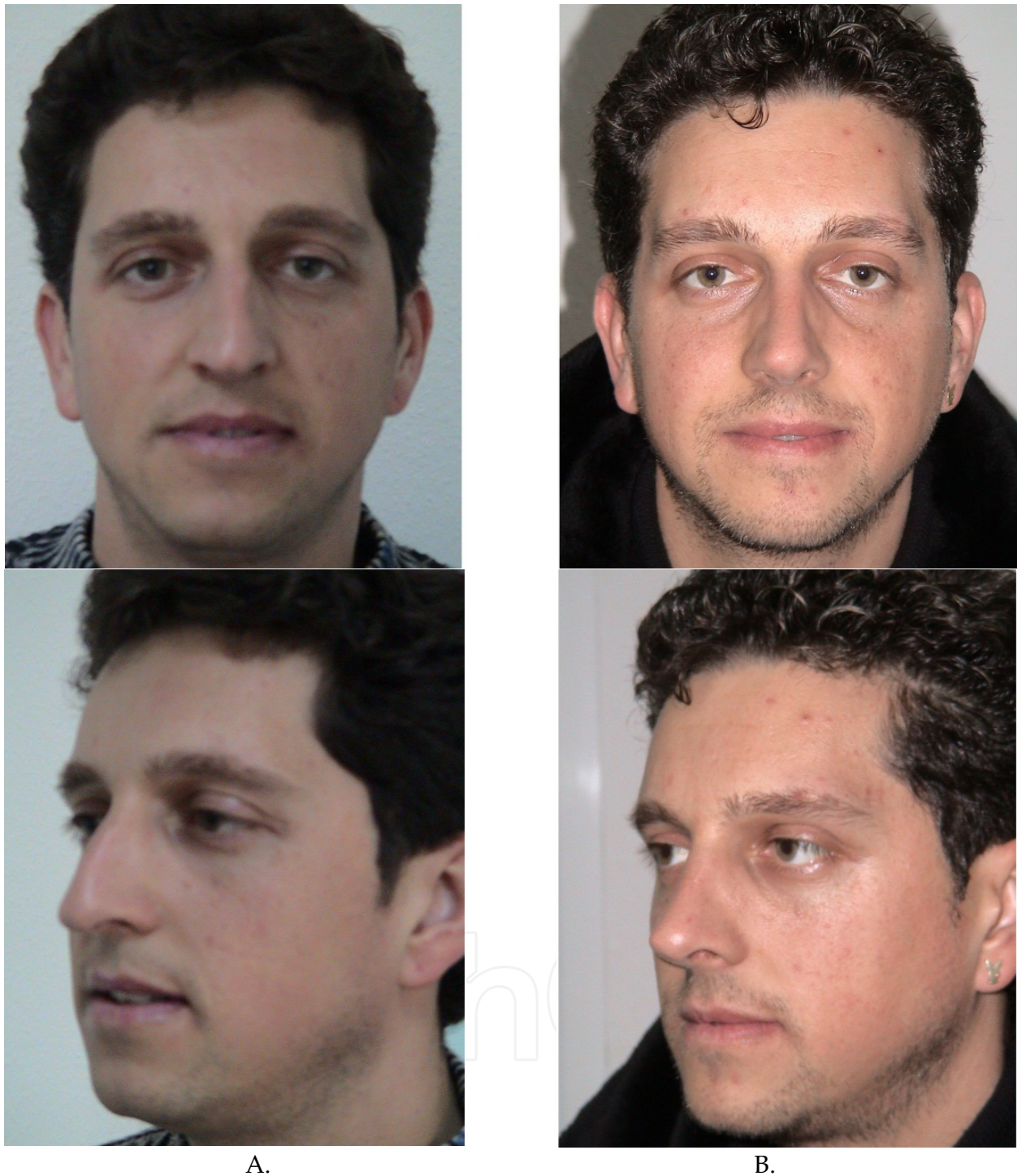The straight profile line is a noble sign.

As people look each other in the eyes when communicating, our first goal is to open and give light to the eyes and never modify them into an "operated-on" appearance.

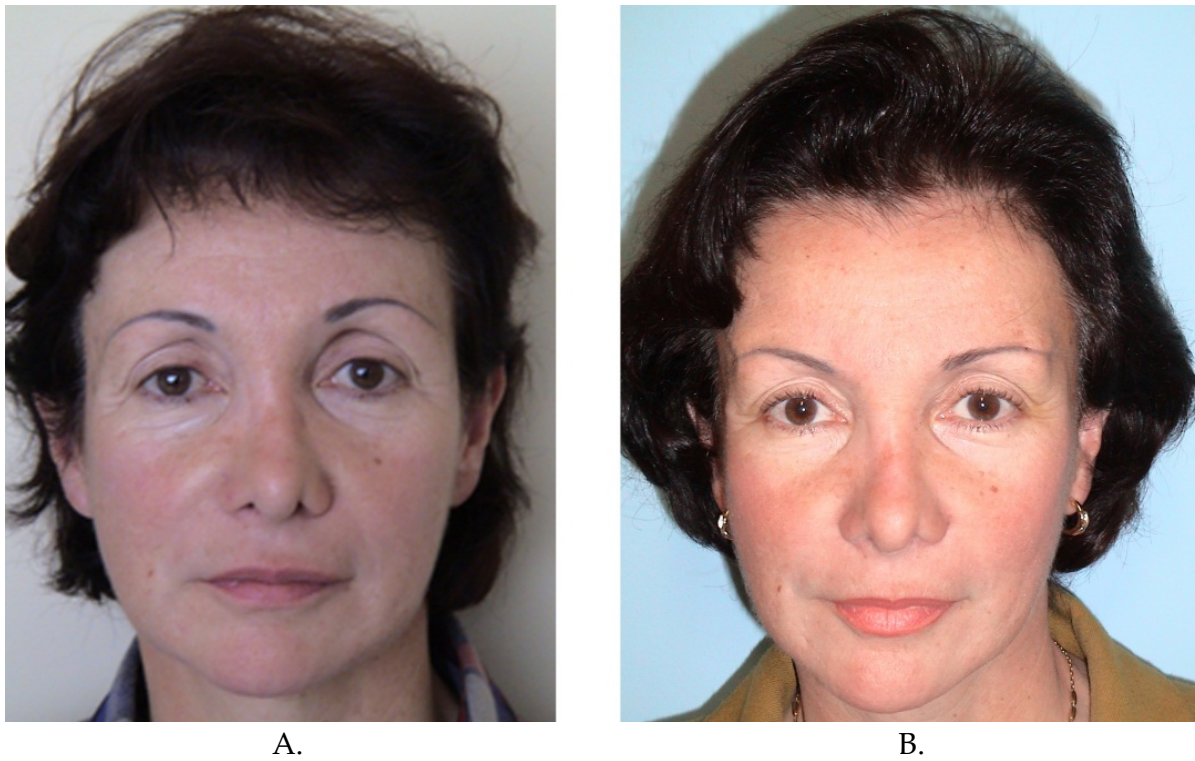Considering patient faces we can recognize unaesthetic signs. Following aesthetic rules, regardless of age, we can add beauty to a face.

The main goal of Serdev Sutures® is to create the appropriate aesthetic proportions, volumes and angles in face and body.

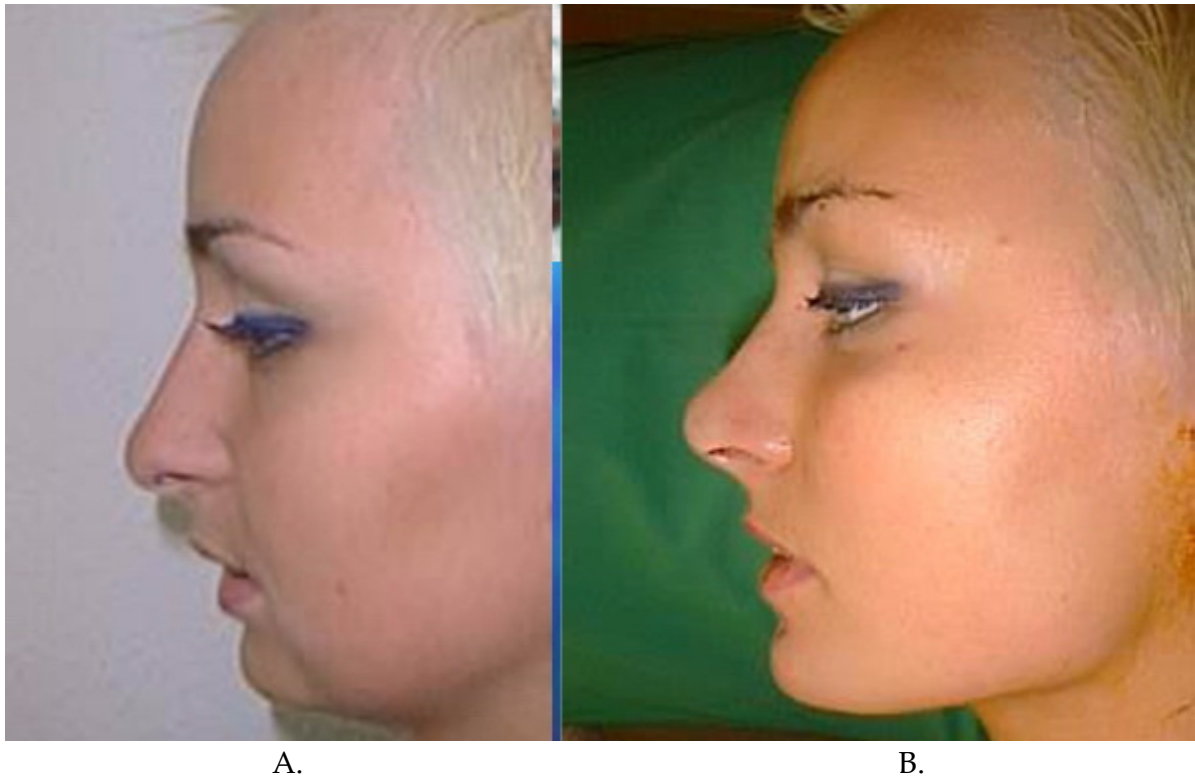#### 4.2. Some clinical cases



**Figure 25. A.** Before: Low eyebrows give darkness to the eyes; unaesthetic proportions – the Golden Section Rule of the face is not present; nobleness is not present - retrograde chin, profile line is not straight. The proportion ratio in the lower third of the face is 1:3 instead of 1:2. **B.** After: Brow lift to open the eyes. Their color is finally visible; Rhinoplasty to create the 3 equal thirds (golden section rule), chin enhancement to create more visible beauty triangle (in men, the cheekbones should not look “sweet”), straight profile and proper lower face third ratio of 1:2. The result is **total face beautification**. “Playboy” ear pendant serves to demonstrate patient’s self-confidence after surgery.

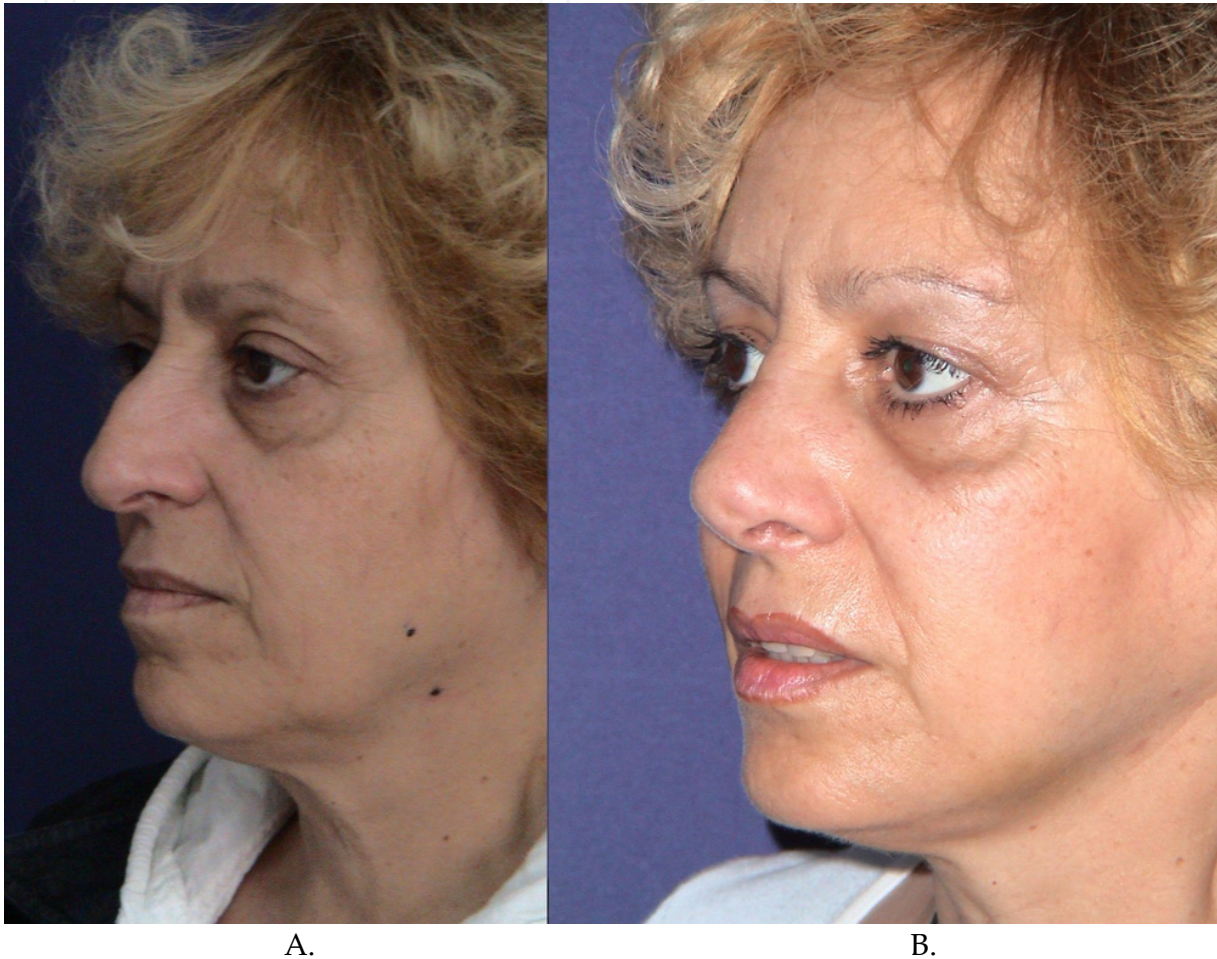

**Figure 26.** **A.** Before: Brow ptosis, hollow eyes, gradual facial ptosis. Sad appearance. **B.** After Temporal and Brow Serdev Suture® lifts: eyes and face are full of light. See the color of the eyes. The Golden Section Rule is apparent. The lower face is changed from heavy and square into fresh and oval.



**Figure 27.** **A.** Before. Nice young lady, but with longer nose, small chin; disrupted golden section rule, lower face proportion and the line of straight profile. **B.** Immediate beautification results in the

operating theater after temporal lift by suture to lift the facial angles laterally and repositioning the cheekbone soft tissue; rhinoplasty to obtain the 3 equal parts of the face (golden section rule) - author's T-excision for tip rotation and columella sliding for tip projection, and chin enhancement to obtain the straight profile, beauty triangle and proper proportion ratio 1:2 in the lower third of the face. Suturing the chin in front has defined the jaw line. Skin still not cleaned from the Braunol. No operated-on appearance, immediately after 3 operations (including 2 suture lifts).



**Figure 28.** **A.** Before: aging face, disproportions and lack of aesthetics in all proportions, volumes and angles. **B.** After scarless closed approach suture Brow, Temporal, Mid-face, Lower face and neck lift, Chin enhancement and Rhinoplasty. Fresh No operated-on appearance and open eye look, sparkling radiation, proper proportions are present, straight profile, angles lifted laterally, volumes, beauty triangle, defined jaw line and cervico-mandibular angle are present. Better skin texture. Blepharoplasty and cheekbone lift could be added, if and when patient decides.

## 5. Conclusion

In a way, cosmetic surgery as a multidisciplinary science is a fine art, inherently combining knowledge of architecture, sculpture, painting, design, fashion and even poetry. Scarless closed approach Serdev Suture® lifts, suspensions and tissue volumizing serve to create beauty on the basis of a proper understanding of anatomy, aesthetics as a science, ideal proportions, angles and volumes.

## Author details

Nikolay Serdev

*New Bulgarian University, Sofia, Bulgaria*

## 6. References

- [1] Serdev, N.P. Year 1994, Suture Suspensions For Lifting Or Volume Augmentation In Face And Body (English version), presented at the 2nd Annual Meeting of the National Bulgarian Society for Aesthetic Surgery and Aesthetic Medicine, Sofia, 18 March 1994, *Int J Aesth Cosm*, 2001,1:1, 2561-2568
- [2] Serdev NP. Serdev Suture Techniques Lower SMAS Face Lift, Original Papers, *Int J Cosm Surg*, 2009, 9:4, 1 - 2
- [3] Serdev NP. Ambulatory temporal SMAS lift using minimal hidden incisions. *IJACBS*, 1(2):17-24, 2001.
- [4] Serdev NP. Serdev Suture Techniques Lower SMAS Face Lift (Bulgarian), Original Papers, *Int J Cosm Surg*, 2009, 9:4, 1-12
- [5] Serdev NP. SERDEV SUTURE TECHNIQUES - Lower SMAS Face LIFT, Original Papers, *Int J Cosm Surg*, 2010, 10:1, 1-2
- [6] Mitz V, Peyronie M. The superficial musculo-aponeurotic system (SMAS) in the parotid and cheek area. *Plast Reconstr Surg* 58: 80-88, 1976.
- [7] Jost G, Lamouche G. SMAS in rhytidectomy. *Aesthetic Plast Surg* 2: 69-74, 1982
- [8] Larabee WF, Makielski KH, Cupp C. Facelift anatomy. *Facial Plastic Surgery Clinics of North America* 1(2): 135-52, 1993.
- [9] Brennan HG. Rhytidectomy: Mandibular and submandibular contouring. *Facial Plastic Surgery Clinics of North America* 1(2): 181-96, 1993.
- [10] Kridell RWH, Covello LV. The aging face (rhytidectomy). In BJ Bailey (ed.): *Head & Neck Surgery – Otolaryngology*, 2nd edition. Lippincott – Raven, 1998, pp. 2693-716.
- [11] Berman WE. Rhytidectomy. In CJ Krause (ed.) *Aesthetic Facial Surgery*. Lippincott, 1991, pp 513-31.
- [12] Dedo DD. The aging neck. In BJ Bailey (ed.): *Head & Neck Surgery – Otolaryngology*, 2nd edition. Lippincott – Raven, 1998, pp. 2717-32.
- [13] Baker DC, Conley J. Avoiding facial nerve injuries in rhytidectomy. *Anatomical variations and pitfalls. Plast Reconstr Surg* 6: 781-95, 1979
- [14] Seckel BR. *Facial Danger Zones: Avoiding Nerve Injury in Facial Plastic Surgery*. Quality Medical Publishing, St. Louis, 1994.
- [15] Webster RC, Smith RC, Papsidero MJ, et al. Comparison of SMAS plication with SMAS imbrication in face lifting. *Laryngoscope* 92: 901-12, 1982.
- [16] Lewis JR. Multiple-tiered deep support of cheeks in meloplasty and rhytidectomy. *Aesthetic Plast Surg* 1: 21-5, 1983
- [17] Owsley JQ. SMAS-platysma facelift. A bidirectional cervicofacial rhytidectomy. *Clin Plast Surg* 3: 429-401, 1983

- [18] Randall P, Skiles MS. The "SMAS sling": an additional fixation in face lift surgery. *Ann Plast Surg* 1:5-9, 1984
- [19] Webster RC, Smith RC, Smith KF. Face lift, Part 4: Use of superficial musculoaponeurotic system suspending sutures. *Head Neck Surg* 3: 780-91, 1984
- [20] McCoullough EG, Perkins SW, Langsdon PR. SASMAS suspension rhytidectomy. *Arch Otolaryngol Head Neck Surg* 115: 228-34, 1989.
- [21] Hamra ST. The deep-plane rhytidectomy. *Plast Reconstr Surg* 86: 53-61, 1990.
- [22] Hamra ST. Composite rhytidectomy. *Plast Reconstr Surg* 90:1-13, 1992.
- [23] Ramirez OM. The subperiosteal rhytidectomy: The third-generation facelift. *Ann Plast Surg* 28: 218-232, 1992.
- [24] Beeson WH. Extended posterior rhytidectomy. *Facial Plastic Surgery Clinics of North America* 1(2): 197-216, 1993.
- [25] Serdev, N.P. Chin form correction and augmentation using simple suture. *Int J Aesth Cosm Beauty Surg IJACBS* 2001, 3 (1), 42-66
- [26] Serdev, N.P. Chin Form Correction And Augmentation Using A Simple Suture, Presentations, *Int J Cosm Surg*, 2003, 3:3, 1-36
- [27] Serdev, N.P. Chin Enhancement And Form Correction Using A Suture Of The Soft Tissue, Original Papers, *Int J Cosm Surg*, 2002, 2:1, 1-10
- [28] Serdev, N.P. Chin augmentation using simple suture. *Int J Cosm Surg* 2001, 2 (1) 42-66
- [29] Mottura AA. Chin augmentation with nasal osteocartilaginous graft. *Plast Reconstr Surg* 2002 Feb;109(2):783-7
- [30] Karras SC, Wolford LM. Augmentation genioplasty with hard tissue replacement implants. *J Oral Maxillofac Surg*. 1998 May;56(5):549-52
- [31] Cox AJ 3rd, Wang TD. Skeletal implants in aesthetic facial surgery. *Facial Plast Surg* 1999;15(1):3-12
- [32] Hwang K. Chin augmentation with a bone graft from the mandibular region. *J Craniofac Surg* 2000 Nov;11(6):543-6
- [33] Ramirez OM. Mandibular matrix implant system: a method to restore skeletal support to the lower face. *Plast Reconstr Surg* 2000 Jul;106(1):176-89
- [34] Gubisch W, Kotzur A. Our experience with silicone in rhinomentoplasty. *Aesthetic Plast Surg* 1998 Jul-Aug;22(4):237-44
- [35] Snyder GB, Courtiss EH, Kaye BM, Gradinger GP. A new chin implant for microgenia. *Plast Reconstr Surg* 1978 Jun;61(6):854-61
- [36] Schoenrock LD, Chernoff WG. Subcutaneous implantation of Gore-Tex for facial reconstruction. *Otolaryngol Clin North Am* 1995 Apr;28(2):325-40
- [37] Lewis RP, Schweitzer J, Odum BC, Lara WC, Edlich RF, Gampper TJ. Sheets, 3-D strands, trimensional (3-D) shapes, and sutures of either reinforced or nonreinforced expanded polytetrafluoroethylene for facial soft-tissue suspension, augmentation, and reconstruction. *J Long Term Eff Med Implants* 1998;8(1):19-42
- [38] Singh S, Baker JL Jr. Use of expanded polytetrafluoroethylene in aesthetic surgery of the face. *Clin Plast Surg* 2000 Oct;27(4):579-93
- [39] Gross EJ, Hamilton MM, Ackermann K, Perkins SW. Mersilene mesh chin augmentation. A 14-year experience. *Arch Facial Plast Surg* 1999 Jul-Sep;1(3):183-9

- [40] Sclaroff A, Williams C. Augmentation genioplasty: when bone is not enough. *Am J Otolaryngol* 1992 Mar-Apr;13(2):105-8
- [41] Kheir JN, Leslie LF, Fulmer NL, Edlich RF, Gampper TJ. Polydimethylsiloxane for augmentation of the chin, malar, and nasal bones. *J Long Term Eff Med Implants* 1998;8(1):55-67
- [42] Yaremchuk MJ. Mandibular augmentation. *Plast Reconstr Surg* 2000 Sep;106(3):697-706
- [43] Odum BC, Bussard GM, Lewis RP, Lara WC, Edlich RF, Gampper TJ. High-density porous polyethylene for facial bone augmentation. *J Long Term Eff Med Implants* 1998;8(1):3-17
- [44] Dann JJ, Epker BN. Proplast genioplasty: a retrospective study with treatment recommendations. *Angle Orthod* 1977 Jul;47(3):173-85
- [45] Qian Y, Fan Z, Yang Q. Application of MEDPOR surgical implant in the craniofacial reconstruction *Zhongguo Xiu Fu Chong Jian Wai Ke Za Zhi* 1998 Mar;12(2):71-3
- [46] Jafar M, Younger RA. Screw fixation mentoplasty. *J Otolaryngol* 2000 Oct;29(5):274-8
- [47] Rubin JP, Yaremchuk MJ. Complications and toxicities of implantable biomaterials used in facial reconstructive and aesthetic surgery: a comprehensive review of the literature. *Plast Reconstr Surg* 1997 Oct;100(5):1336-53
- [48] Robinson M, Shuken R. Bone resorption under plastic chin implants. *J Oral Surg* 1969 Feb;27(2):116-8
- [49] Maas CS, Merwin GE, Wilson J, Frey MD, Maves MD. Comparison of biomaterials for facial bone augmentation. 1: *Arch Otolaryngol Head Neck Surg* 1990 May;116(5):551-6
- [50] Sclafani AP, Romo T 3rd. Collagen, human collagen, and fat: the search for a three-dimensional soft tissue filler. *Facial Plast Surg* 2001 Feb;17(1):79-85
- [51] Constantinides MS, Galli SK, Miller PJ, Adamson PA. Malar, submalar, and midfacial implants. *Facial Plast Surg* 2000;16(1):35-44
- [52] Moenning JE, Wolford LM. Chin augmentation with various alloplastic materials: a comparative study. *Int J Adult Orthodon Orthognath Surg* 1989;4(3):175-87
- [53] Romo T 3rd, Baskin JZ, Sclafani AP. Augmentation of the cheeks, chin and pre-jowl sulcus, and nasolabial folds. *Facial Plast Surg* 2001 Feb;17(1):67-78
- [54] Jones RH. The effects of zygomatic and chin augmentation on facial aesthetics. *Ann R Australas Coll Dent Surg* 1998 Oct; 14:114-8