

We are IntechOpen, the world's leading publisher of Open Access books Built by scientists, for scientists

6,900

Open access books available

186,000

International authors and editors

200M

Downloads

Our authors are among the

154

Countries delivered to

TOP 1%

most cited scientists

12.2%

Contributors from top 500 universities



WEB OF SCIENCE™

Selection of our books indexed in the Book Citation Index
in Web of Science™ Core Collection (BKCI)

Interested in publishing with us?
Contact book.department@intechopen.com

Numbers displayed above are based on latest data collected.
For more information visit www.intechopen.com



Serdev Sutures® Lifts in Body Areas

Nikolay Serdev

Additional information is available at the end of the chapter

<http://dx.doi.org/10.5772/55672>

1. Introduction

Excisional body lift operations are traumatic surgical procedures that result in significant scarring.

The scarless transcutaneous closed approach Serdev Suture® method in buttock lift, breast lift, abdominal flaccidity lift was first presented in 1994 as a scarless alternative to the classic excision lifts, such as circumscisional body lifts, mammoplasty, abdominoplasty (tummy tuck) and others as part of the total understanding for the scarless closed approach suture lifting method. The concept is to lift stable mobile fascias to immobile tissues such as periosteum, immobile fascia, or tendons. This is achieved by a closed approach suture lift, using special instruments – curved semi-elastic Serdev® needles and semi-elastic surgical sutures, distinguished by an extended period of delayed absorption (2-3 years).

The Serdev Suture® buttock lift presents a scarless surgical procedure for the treatment of the flaccid, flat and "unhappy buttock" form by a closed approach, without any requirement for incision and excision scars. The outcome is a visual change in buttock projection, roundness, tightness and elevation into a higher position. The buttock lift elongates the lower limbs and changes the proportions of the body. The aim is to obtain a beautification of the buttock form by creating a circumferential lifting effect on the buttock's subcutaneous tissue without scars. This is obtained by the use of a suture that takes hold of the inferiorly positioned deep fibrous tissue, elevating and fixing it to the "sacro-cutaneous" fascia (discovered by the author). This fascia fixes the overlying skin to the lateral lines of the sacrum and suspends the weight of the buttocks.

In scarless suture breast lift, the mobile breast glandular tissue and its fascia are lifted and fixed to the stable immobile anterior clavicle periosteum, or to the insertion of the pectoralis major tendon to humerus.

The Serdev Suture® method allows for an atraumatic and scarless lift of the inner thigh dermis to the tendon insertion of the gracilis muscle.

The Serdev Suture® lift can be used in selected cases of thin patients to obtain a scarless and atraumatic tightening of the abdominal skin. This suture method for abdominal flaccidity lift is achieved by a closed approach suture as well, with skin perforations alone in the abdominal skin to capture, suture and lift the mobile superficial fascias supporting the abdominal skin. To obtain outcome longevity it is important to lift and stretch the firm mobile fascias, fixing them to immobile firm tissue, such as costal periosteum and/or perichondrium, periosteum of spina iliaca superior anterior.

A stable improvement was observed in all patients. In the post-operative period, the complication rate was minimal and below 0.1%. All early complications were resolved in the first 4-5 post-operative days. All other professional duties, social activities or obligations were possible in the next one or two days. These outpatient procedures are effective in the correction of laxity and ptosis. They also create a new form, along with improved body proportions that has been universally accepted as beautification beside rejuvenation.

2. Buttock lift

As more people seek body contour surgery, we should use our expanding knowledge and surgical experience to create new, non-scarring surgical procedures for beautification in areas like the buttocks. Former results of body contour surgery have been less than satisfying. A very small number of techniques are available for correction of the form and aesthetics of the buttocks. This is especially so for lax, ptotic and non-projected buttocks. Scarless methods are preferred and demanded by virtually all patients.

Classic methods are combinations of liposuction, lipoinjections, implants for augmentation and lipectomy. The outpatient buttock lift procedure by suture can satisfy patients' requirements for beautification of the buttock form and position without scars and foreign bodies. The post-operative period is both rapid and easily tolerated, while the outcome is durable and long lasting.

2.1. Anatomy

The well accepted gluteal position is the location of the gluteus maximus muscle. The muscle-skeletal framework is usually well formed. Unfortunately, female structure usually includes an inferiorly positioned fatty tissue deposit, elongating the female buttocks in the inferior perspective. Long and hanging buttocks are visible even from a frontal view (Fig. 1) and shorten the length of female lower limbs. The hanging buttocks soft tissue is well recognised as "unhappy buttocks" as distinct from the high gluteal position, known as "happy buttocks".

2.2. FIXATION of mobile to immobile tissue

The only useful mobile tissue for suture lift is the very fibrotic buttocks soft tissue. **NB!** Gluteus muscles and gluteus fascia cannot be lifted.

The only immobile structure to which the suture can be fixed, in order to produce buttock lifting and secure the buttock weight, is the Serdev “sacro-cutaneous” fascia (discovered by the author) which fixes the skin to the lateral edges of the sacrum, located between the “dimples of Venus” at the sacro-iliac points and the upper point of the intra-gluteal fold, located at the sacro-coccygeal point. **NB!** Sacro-coccygeal fascia is not useful for fixation. Any attempt to attach the buttocks weight to the sacro-coccygeal fascia can provoke an “ischadic” pain.

The gluteal fatty tissue is very fibrotic. The fibrotic tissue represents a flexible support for the soft framework of the body. It forms a stable network for subdermal and deep fat layers. We use this stable fibrotic buttock soft tissue structure in order to elevate it securely by fixation to the Serdev fascia on each side.

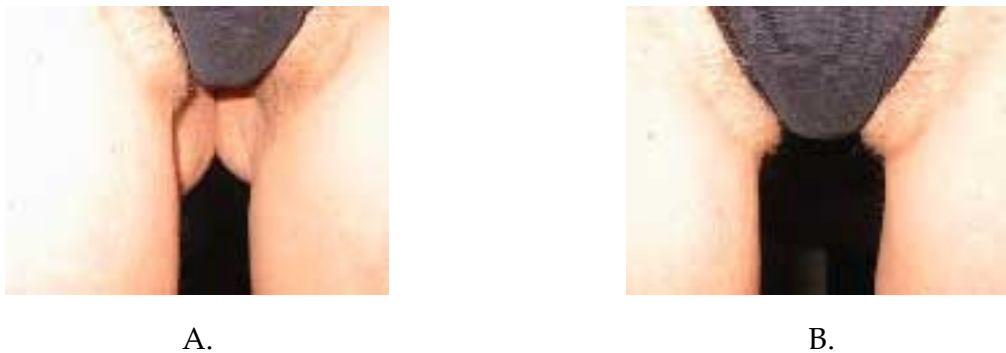

Figure 1. **A.** “Unhappy”, sagging, loose buttock soft tissue, drooping between the thighs, engenders disappointment in women, inclining them to request buttock lifting. **B.** “Happy buttocks” - the outcomes of lifting the hanging buttocks are visually elongated legs and more aesthetic body proportions.

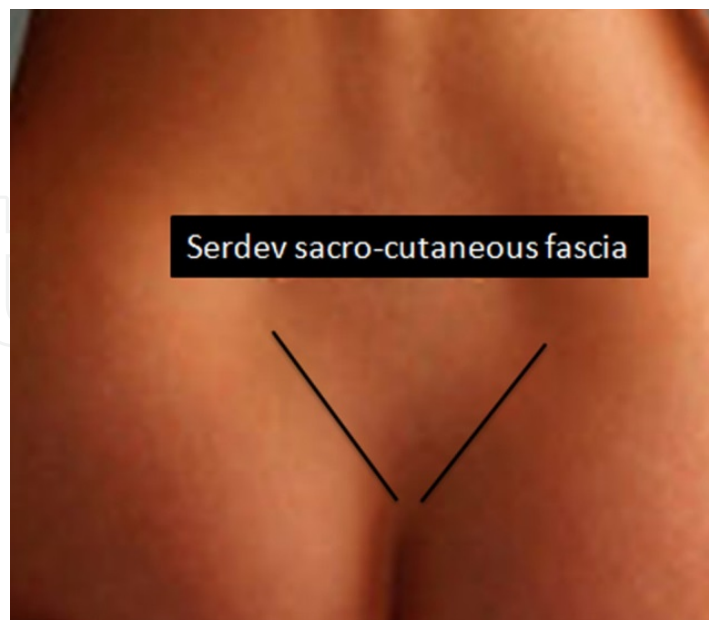

Figure 2. The Serdev “sacro-cutaneous” fascia fixes the skin to lateral edges of the sacrum in the lower part of the “rhombus of Michaelis”. It is located on each side, between the “dimples of Venus” and the upper point of the intra-gluteal fold, i.e. between the sacro-iliac points and the sacro-coccygeal point.

2.3. Method

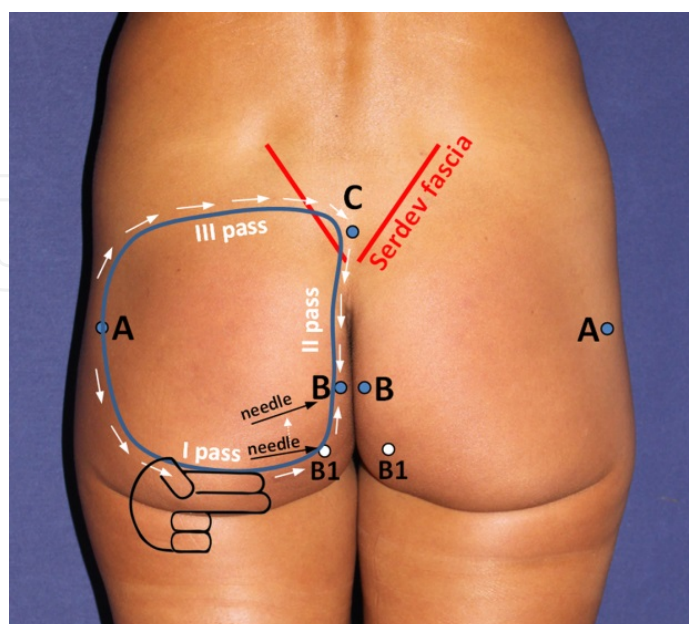
Indications: Beautification, aesthetic proportions, lifting of ptosis, elongation of the lower limbs, shortening of the body length in proportion to the legs.

The primary indication for buttock lift surgery by suture is the moderate to severe soft-tissue laxity in the lower trunk, with minimal or mild residual fat deposits. In patients with significant fat deposits, the author initially treats with UAL/VASER to reduce the volume and heaviness of the buttock fat tissue. Then, the reduced weight of the buttocks soft tissue can be lifted and fixed to the Serdev fascia in order to ensure a safe post-operative healing process.

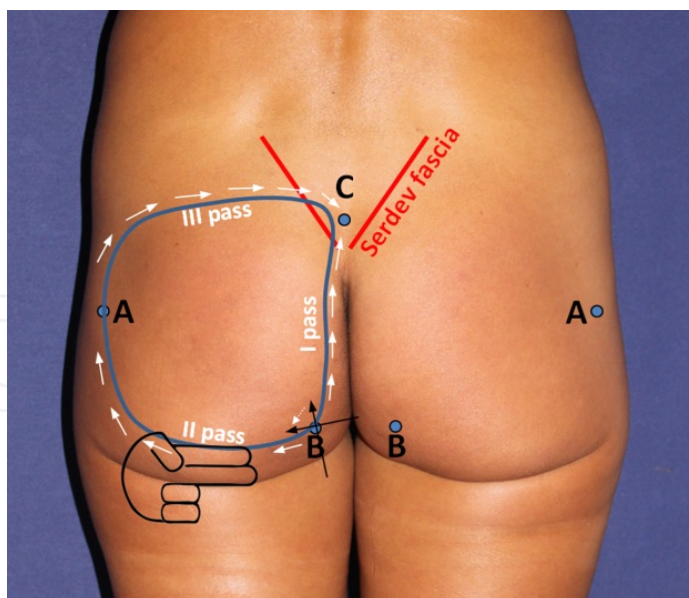
The buttock lift by suture was created for aesthetic purposes, with the intention of creating a higher and more attractively rounded and projected buttocks, while at the same time creating a visible elongation of the legs and a change of the correlation between the body and the length of the lower limbs. True buttock sculpting demands a three-dimensional artistic appreciation of the anatomic and surgical adipose layers of the central trunk. This is essential in preventing complications from the buttock lifting, where the fixation is done without damaging neurovascular structures.

2.4. The technique

Author's surgical technique consists of a fixation of the complete buttock soft tissue fibrotic system to the Serdev sacro-cutaneous fascia on each side. The suture technique uses the specially designed Serdev® needles from 170 mm to 250 mm, and Polycon USP 4, 6 or 8, depending on the degree of tissue volume and heaviness.



A.



B.

Figure 3. “Serdev fascia” is marked in red color. It is perpendicular to skin and sacrum and the suture with buttocks’ heaviness will hang on it. Arrows show the direction of needle passes. A minimum of three passes is necessary to complete the fixation of the buttock fibrotic soft tissue system to Serdev fascia, which realizes a lift, roundness, projection and stable fixation of the mobile lower buttock to the immobile Serdev fascia. 2 methods are presented:

A. The first pass is from A to B1, then the direction of the needle is changed toward B, but higher than the anus (B1 is only an orientation, not a skin perforation point). The suture is introduced into A-B. Then, the needle is introduced in the second pass (C-B), in order to be threaded at B. Next, the second end of the suture is taken at A and fulfills the circle of the suture at C (third pass – C-A) to be tightened and knotted on Serdev fascia. If no dermis is attached to the suture, all dimples at the perforation points are easy to remove.

B. Sometimes it is easier for beginners to perform 2 passes at once - to start from B to C and introduce the suture from C in direction to B, then change the direction of the needle tip towards A, without exiting the superficial fascia at B. This maneuver prevents beginners from dimpling at point B. After introducing the suture in lines C-B-A, the third pass C-A introduces the thread in line A-C and fulfills the suture circle at point C. The suture will be tightened and knotted at C. Dimpling at a perforation point has to be removed.

The author prefers the first step for fixation of the subdermal fibrotic tissue to be initiated from the lateral aspect of the buttock. Selection of the type of surgical suture is the surgeon’s responsibility. However, the elastic tightening of the Polycon suture provides a stable support with a short elasticity, when lifting the buttock into a higher position and fixing it to the stable sacro-cutaneous fascia. The suture collects the buttock’s fibroic tissue and its trabecular system into a superficially convex “bouquet”. This roundness is moved superiorly and fixed to the Serdev sacro-cutaneous fascia. The fixation of the suture to the stable inelastic fascia maximally ensures the longevity of the aesthetic effect. The semi-elastic quality of the antimicrobial polycaproatamide suture Polycon (as preferred by the author) reduces the possibility of trauma and decubiti of the fibrotic tissue and reduces complications.

The buttock lift by suture requires 10 to 15 minutes of operating time per side, no blood transfusions, no stay at the clinic, no nursing care and no more than a day or two absence from work.

2.5. Directions

Mark skin perforation points A, B and C (B1 should be only marked, not perforated, it is an orientation point). Point A should be located laterally, at the midpoint of each buttock, near the place where the trochanter can be palpated. This ensures equal distance to points B and C.

2.6. Tips and tricks

- Perforation point B could be located above the anus (preferable because of hygienic reasons) or below, and somewhat lateral from anus, in order to secure point B from contamination.
- If skin perforation point B is planned higher than the anus, an imaginary point B1 should be taken into consideration and when arriving from point A, deep under point B1, the needle direction should be changed to B as shown in Fig. 3.A.
- If perforation point B is planned below the anus, the superficial fascia at that point B should be perforated very well and the perforation must be widened to avoid fixation with the needle and introduction into the suture. Otherwise, its attachment to the suture will produce dimpling.
- Point C should be between both Serdev fascias, inside of the triangle of the sacral region. This will ensure that the passes C-B and C-A on both sides will cross the Serdev fascia from below and above, and the suture will be fixed to the Serdev fascia. Serdev fascia is perpendicular to the skin and sacral edges and the weight of the suture will be suspended on it.
- Perforation of sacrococcygeal fascia and fixation of the suture on it produces ischiadic pain and should be avoided!
- Do not fix the gluteus fascia or gluteus muscle to the suture. Both are immobile and will not permit lifting.
- Perform an oval, circular suture, in order to place equal tension to all points. Do not perform triangles or Z sutures. Higher tension in the angles will cut through the tissue and will not permit longevity of the lift.

After anesthetic infiltration intradermally and deep in points A, (B1), B and C, and deep in the soft tissue along the marked suture circle, make small perforation at points A, B and C. Then, open the perforations and deep subdermal fat in perpendicular fashion with a mosquito clamp. Take sterile needle caps from 18-gauge needle, cut part of the closed needle cap tip. Insert these plastic cannulas in twisting perpendicular fashion, maximum deep into perforation points A, B and C, in order for the suture to stay deep in the fat fibrotic tissue (near but above the gluteus fascia) and away from dermis and subdermal fibrotic tissue. This maneuver prevents dimpling.

2.7. Technique

Video: <http://www.youtube.com/watch?v=mn0O2bNkG7o>

First Pass - A-B: It should be deep in the soft tissue, 2 fingers higher than the infragluteal fold (see Fig. 3) in order to stretch and flatten it when the buttock is lifted:

Variant A (Fig. 3. A)

- **First pass - A-B:** Introduce a long Serdev® needle 170mm or 230mm from point A to point B1, deep in the soft fibrotic fat tissue. **NB!** The Serdev Suture® circle should be located deep, just above the gluteus maximus fascia. Be sure not to be too superficial as it will cause skin/tissue dimpling on the path of the needle. If so, twist the needle backwards to free the superficial tissue and proceed deeper. Stay near, but above the gluteus fascia, which will block your needle if perforated. Arriving deep at B1, turn the needle toward B, as shown in Fig. 3A. Find the deeply positioned opening of the plastic cannula and go out through the plastic hub. Load the needle at point B with a thread USP 4, 6 or 8 (depending on buttocks size) and pull through. The surgical sutures will be located deep in the soft tissue, in the mobile line B-A. **NB!** The deeply introduced plastic cannulas prevent from engaging dermis and fibrotic tissue in the suture (prevent from dimple formation).
- **Second pass - C-B:** Proceed from point C to B, deep in the fat tissue, 1-2cm away from the intra-gluteal fold (without superficial skin/tissue dimpling). **NB!** If dimpling appears, the needle is too superficially located. Proceed deeper, without perforating the sacrococcygeal fascia (pain!). Find and exit through the plastic hub at point B and load the needle. Pull through from B to C. In this way, the suture has crossed the Serdev fascia medially.
- **Third pass has two options: A-C or C-A:**
 - **Pass A-C:** Load the needle at point A. From A, proceed to C - deep subdermally (without superficial dimpling), and cross laterally through the upper part of Serdev fascia. Perforate the Serdev fascia near the upper pole and exit at point C through the plastic hub. Unload the needle at C and pull back the empty needle through point A. The suture circle is finalized and both ends of the suture are located at C. Remove cannulae, tighten and knot. Remove dimpling at perforation points. **NB!** If you want to tie the knot at point A, proceed with empty needle from A to C and load needle at C. Introduce the suture at C-A. Then you will have both ends at A. Tightening and knotting the suture at A is somehow difficult for beginners. Most doctors prefer to knot at C.
 - **If pass C-A is selected:** From C, proceed to A, load the needle at A and unload it at C. Both ends of the suture will be located at C. Remove cannulas, tighten and knot at C. Remove dimpling.

Tie the suture as closely as possible to medium tension. In this way, the whole buttock tissue will be collected and projected like a “bouquet” by the suture and fixed higher to the Serdev fascia. Pull out all dimpling at points A, B and C, using a mosquito clamp.

NB! Do not perform suture triangles ABC. The higher pressure in the angles will cut the tissue and the suture will become loose. The circle of the suture should be round to apply equal pressure at each point and minimize trauma of the tissue.

The close proximity of the wounds to the anus area makes antibiotic prophylaxis and strict hygiene obligatory.

2.8. Warnings

1. Do not perforate gluteal fascia or muscle. They cannot be lifted.
2. Do not perforate the sacrococcygeal fascia or periosteum at point C – this causes ischiadic pain.
3. Make a circular suture to obtain equal pressure around all points. Do not perform triangle sutures - tension on the angles will cut the tissue and produce pain.

2.9. Author's experience

More than a thousand buttock lifts have been performed by the author in the last 19 years, both in his clinic and during live surgery workshops around the world. Patients ranged in age from 18 to 62 years. The author reports his experience with patients followed up for up to 10 years.

2.10. Combined methods

63% of the patients had moderate lower trunk and lower limb cellulite and fat deposits, which required additional ultrasonic liposculpture of the lower body and limbs. In patients who have had buttock lift in combination with ultrasonic assisted liposculpture, UAL was performed to reduce the volume and to sculpture the buttocks and other areas for total leg or body beautification. Additional positive qualities of UAL are skin tightening and weight loss. When using UAL for buttock sculpturing, the goal is to minimize fat deposits, buttock's weight and to obtain a nicely rounded and higher positioned buttocks (over the gluteus maximus muscle).

2.11. Results

The buttock lift by suture requires 10 to 15 minutes of operating time per side, there is no blood loss or transfusions, no stay at the clinic, no nursing care and not more than a day or two absence from work.

The cosmetic results were evaluated with pre-operative and post-operative photographs and by patient satisfaction. No patient was dissatisfied with the results and all of them considered their results as excellent or very good.

2.12. Risks and complications

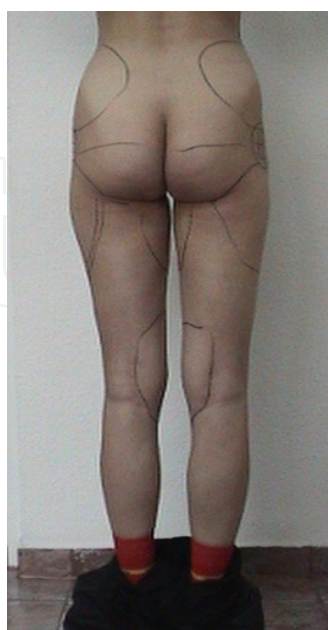Risks are: higher pressure on one tissue being different from the tension in other areas and points; contamination - skin perforation point B near the anus area.

- Higher pressure should be prevented, by performing a circle – a round form suture that equalizes pressure in all points and prevents from tension and trauma of the tissue.
- Infection can be prevented with better selection of point B and antibiotic prophylaxis. The Bulgarian surgical sutures are antimicrobial, semi-elastic and are preferred by the author.

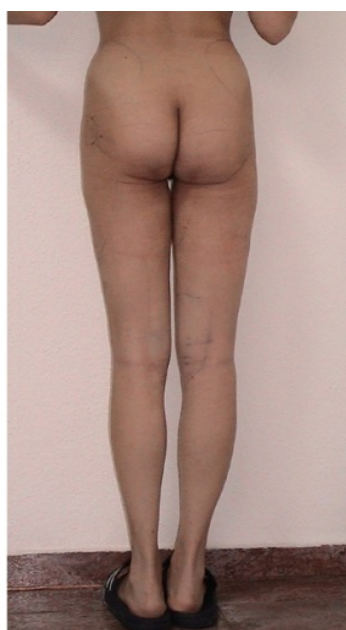In all his cases, the author has observed only one patient with a painful hardness in point B, near the infra-gluteal fold and four other cases with a local infection in one of the wounds. The cause for the first complication was the rigid nylon suture that was used in this first patient. Rigidity, hardness and inelasticity caused a tissue decubitus in the point of tension on the soft tissue. This complication has since then been avoided by changing the suture material to the semi-elastic Bulgarian antimicrobial Polycon suture. In all other cases, the local infection was easily treated in a matter of days. Infections are very rare, occurring mainly at the skin perforation points and are easily treated. No hematoma or nerve damage have been observed. Pain is limited to the first 1-2 weeks in sitting position. In limited cases, when the pain goes away, patients forget the advices to gradually commence physical activities. In these few cases, abnormal friction and trauma can cause pain that is usually on one side. Palpation along the suture gives information about presence or absence of infiltration and location of the pain. It is usually near a perforation point.

In very rare cases, the skin perforation point was opened and some seroma or blood drops have been evacuated with the disappearance of the pain. If there is no infiltration around the suture, slowing down activities, non-steroid anti-inflammatory drugs and pain killers are enough. Antibiotic can be added if considered necessary.

2.13. Clinical cases



A.



B.

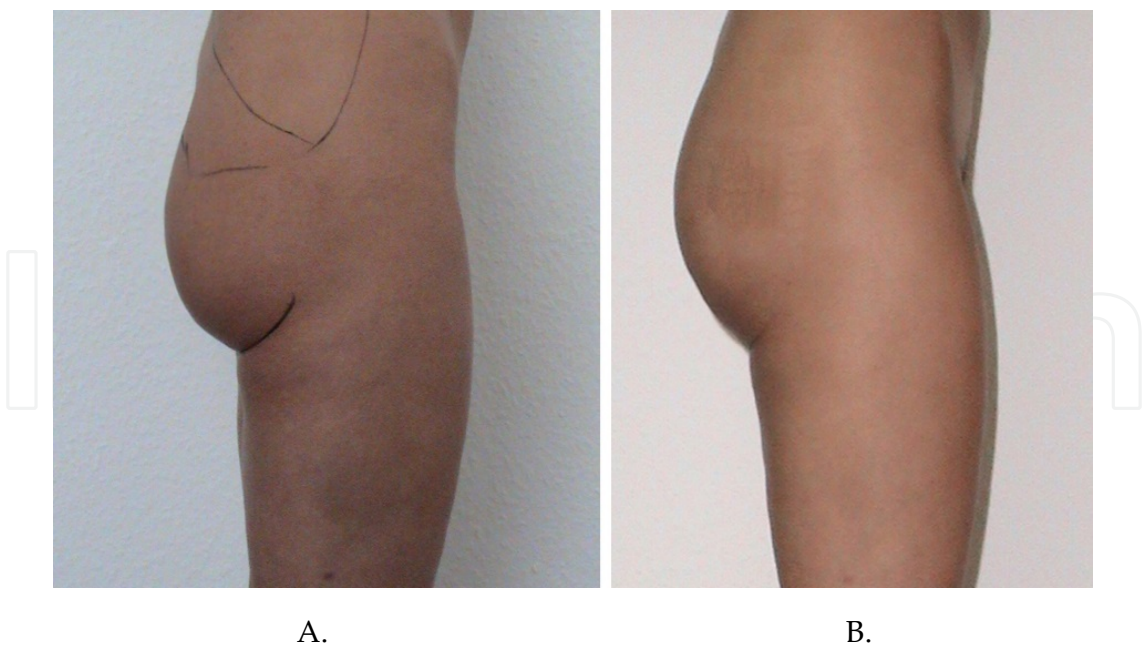


Figure 6. A. Before, B. Result after a buttock lift by suture. Elongation of the legs. Better projection and higher buttocks.

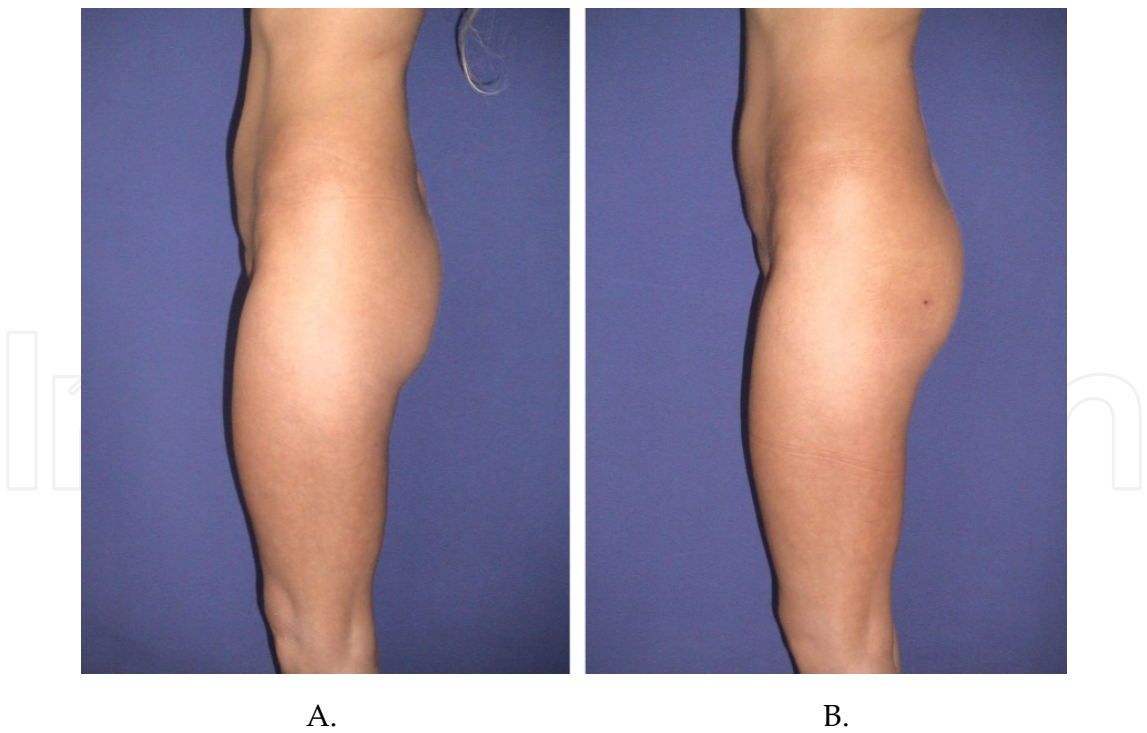


Figure 7. A. Before and B. After buttock lift by Serdev Suture®. Visible elongation of the lower extremities and shortening of the trunk after buttock lift.

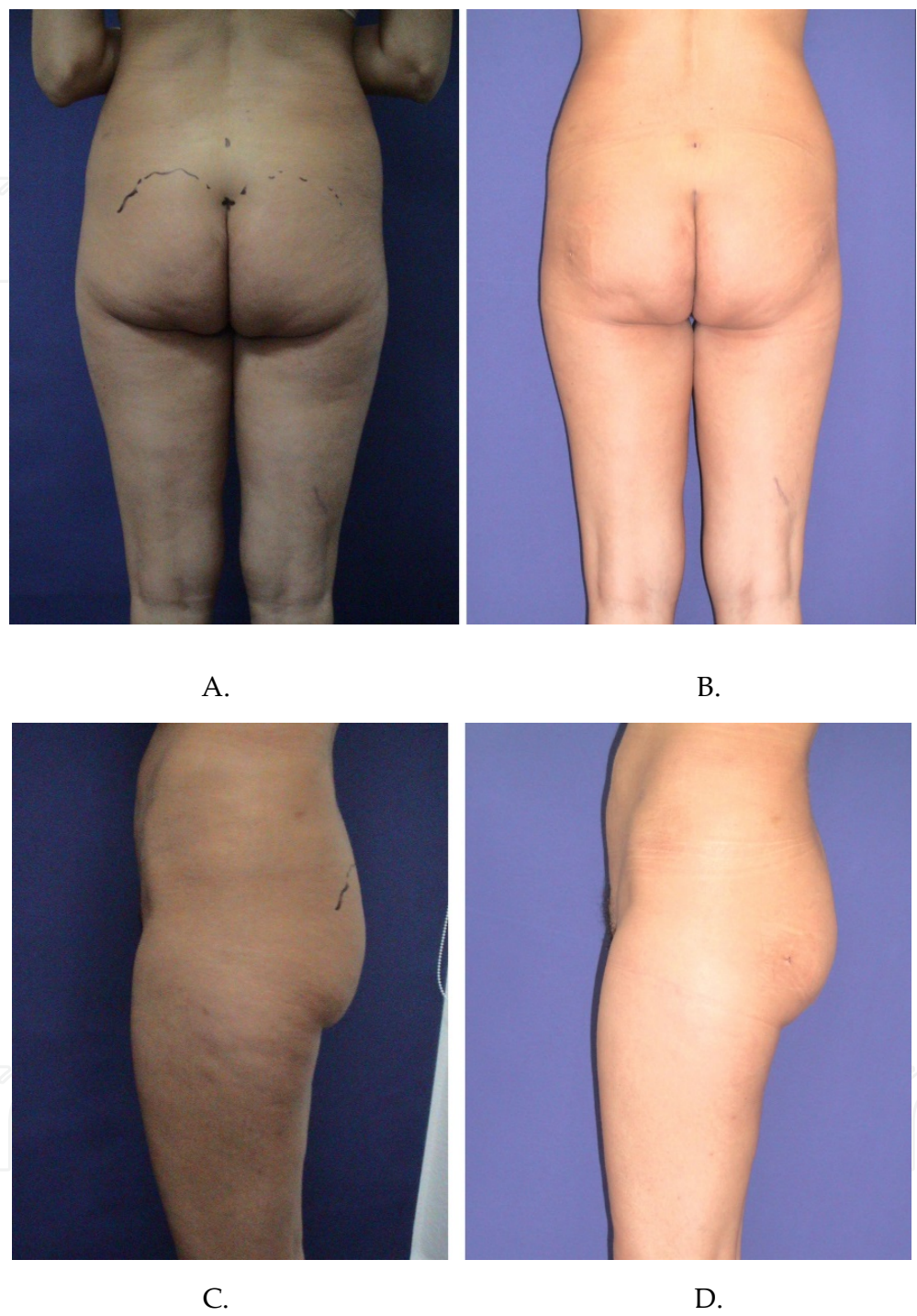


Figure 8. A., C. Before, B., D. Result after buttock lift by suture in a 62 y.o. patient. The buttocks are visibly lifted and a better-rounded form is obtained. There is improvement of the whole body shape.

2.14. Discussion

There is an increasing demand for surgical correction of the body contour in modern society. There is a limited number of operations that aim to correct non-aesthetic buttocks form as part of the total body contouring and proportions. The hips, thighs and the lower back frame the buttock contours. Ethnic differences in the shape and proportions of the buttocks create a variety of aesthetic perceptions in size and shape. However, high positioned “happy” buttocks and elongated legs have always been fashionable.

Flat and sagging buttocks are a common clinical condition. However, before the introduction of the suture butt lift, there was no proven aesthetic and effective therapeutic option at hand. Sole excision of skin cannot obtain a true lift of the heavy buttocks. Subcision is a surgical technique that has been used in treating advanced degree of cellulite. To treat excesses of fat and skin tissue in that area, liposuction and/or dermolipectomy have been mostly used. The indication for liposuction has been restricted to the conditions in which the overlying skin is capable to retract and adapt itself to the new contour. If excess skin is the cause of the deformity, a dermolipectomy has been mostly indicated.

2.15. Buttock augmentation, wrongly named “lifting”

Liposuction of the buttock area is infrequently mentioned in the literature and for some authors it is a forbidden zone. Two additional approaches in suction lipectomy of the buttock region are described: liposuction of the “banana” and liposuction of the “sensuous triangle”. A common complication of liposuction of this area is ptosis of the buttocks. To improve buttock roundness, fat transplantation and different implants, including mammary ones, have been introduced. These procedures do not lift, but only augment buttocks. Free fat graft has been used to avoid the most common complications of doing a buttock augmentation with silicone prostheses and to find a better surgical procedure that is simpler, complementary with liposuction while better able to deal with body irregularities. Lately, excessive augmentations can be observed in Brazil and Latin America, which are not acceptable in Caucasian communities, where aesthetic proportions are important.

Furthermore, the suture lift is the best option for Afro-Americans and Asians, where there is a tendency to hypertrophic scarring.

3. Breast lift

3.1. Clavicular fixation

Video: <http://www.youtube.com/watch?v=bHKA5HaiZs0>

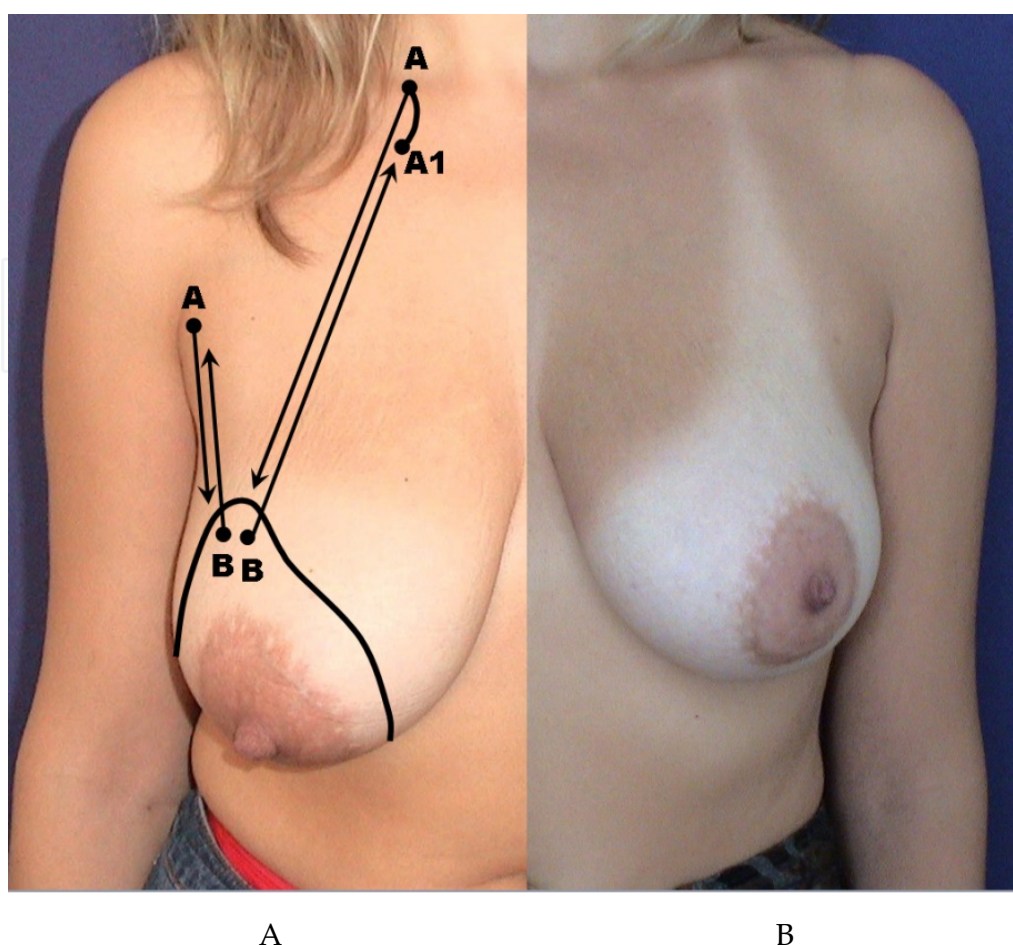


Figure 9. A. Before breast lift to clavicle and to pectoralis tendon. B. Result – 14 cm lift of the nipple

NOTES:

- The circular line indicates the glandular tissue edges,
- Points A and A1 in clavicular fixation are at the upper and lower borders of the clavicle. Take anterior clavicular periosteum and never posterior.
- Arrows show the direction of the needle pass.
- In larger breasts a longer needle could be necessary and 2 sutures may be required.
- Using “Clavicular fixation”, nipples can be raised as much as 14 cm or more. Due to the shorter distance between the pectoralis tendon A point and the upper glandular breast tissue B point, “Pectoralis tendon fixation” can be used for small lifts (suspensions) or for additional support to clavicular fixation in larger breasts.

DIRECTIONS:

- a) Mark the borders of the breast glandular tissue. Select the breast fixation point B depending on the breast heaviness in the upper part of the glandular tissue.
- b) Select the position for the clavicular fixation. It could be:

Central position

Place a plastic tape measure around the neck directed to the nipples and mark the lines. Measure and mark the distance “nipple to clavicle” on both sides.

Medial or Lateral – for medial or lateral nipple position

If requirements for more central or more lateral nipple position, select a more central or more lateral clavicular fixation point.

c) Local anesthesia in points A, A1, subperiosteally in A-A1, intradermally in point B and perpendicularly into the breast fascia, upper breast tissue and below, on the A-B line in deep subdermal fat layer.

d) Perforate points A, A1 and B using a No. 11 scalpel blade. Perforate the blunt subdermal fascia in points A, A1 and the breast glandular tissue fascia in point B using mosquito clamp.

Warning: If not perforated, the superficial fascias will be engaged in the suture, forming a dimpling effect on the surface

e) Clavicular Fixation A-A1:

Pass an unloaded “mini mini” (50 mm) or “mini” (60 mm) Serdev® needle from point A to A1 under the anterior clavicle periosteum. Load the needle with a USP 4 or 6 surgical suture (depending on breast size) and introduce it under the anterior clavicle periosteum A-A1.

Warning: Do not pass dorsal to the clavicle (danger: subclavian a. and v., brachial plexus)

f) Take the upper breast glandular fascia and tissue at point B, using “medium” (140 mm) Serdev® needle. Proceed to point A1 in the deep subdermal fat. Feed the suture end into the Serdev® needle at point A1 and introduce it toward B.

Warning: Unwanted superficial needle pass forms dimpling on the skin surface. Try again a deeper pass to obtain a smooth surface over the needle.

Stay above the pectoralis fascia. If engaged, the pectoralis fascia will block the needle and the suture and then it will produce immobility of the suture.

g) Proceed with the needle from point A in deep subdermal tissue and then over the breast tissue to point B. Feed the second suture end into the needle from point B passing it into point A to accomplish the circle of the suture.

Warning: Do not perforate through dermis at the skin perforations, as this will result in a dimple. In the skin perforation points, pass the needle perpendicularly to the skin surface, without catching dermis (without resistance in front), by gently twisting the needle. Do not push - twist the needle gently forwards or backwards.

h) Tie at point A. Check for equality. After securing the knot, release any dimpling at points A, A1 and B with a hemostat.

Warning: Serdev Sutures® should not engage skin. Skin cannot hold or support the suspended tissue.

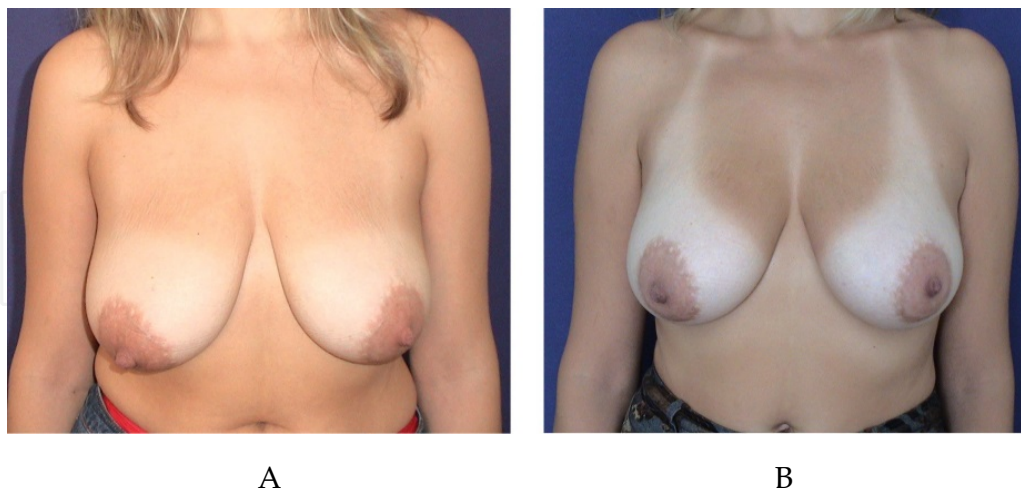


Figure 10. A. Before, B. After a 14 cm breast lift by clavicular suture in large ptotic breasts. A second “step-by-step” breast lift by suture can be performed after months.

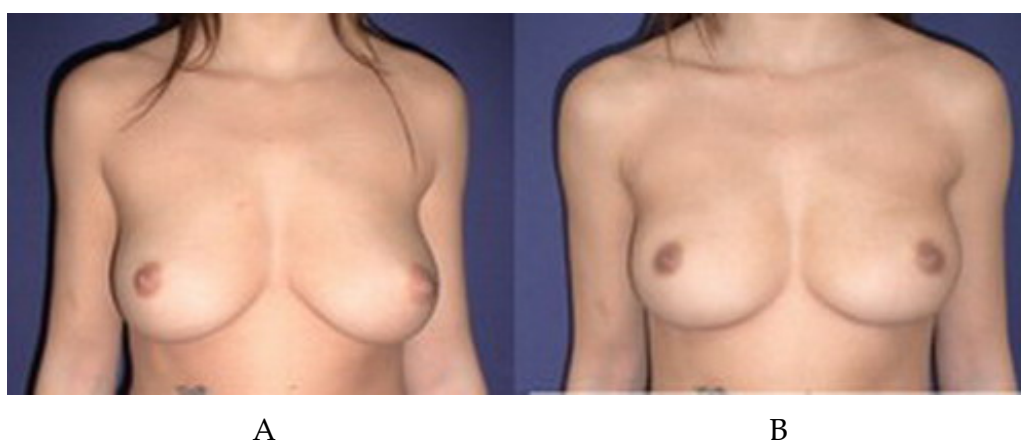


Figure 11. Breast lift by suture to the clavicle in a young patient.

3.2. Pectoralis tendon fixation

DIRECTIONS:

a) Select the place of fixation to the pectoralis major tendon at its insertion to the axilla - Point A.

Note: In point A, the needle pass through the tendon should start from the dorsal side of the tendon to the front of it - Point A1. In other words - Point A should be posterior to the pectoralis tendon, near its insertion to the brachium.

b) Local anesthesia in point A1, through the tendon to Point A, intradermally in point B and perpendicularly into the breast fascia, upper breast tissue and below, and in the deep subdermal fat layer on the A-A1-B line.

c) Perforate points A and B, using a No. 11 scalpel blade. Perforate the subdermal fascia and breast fascia bluntly in point B, using a mosquito clamp.

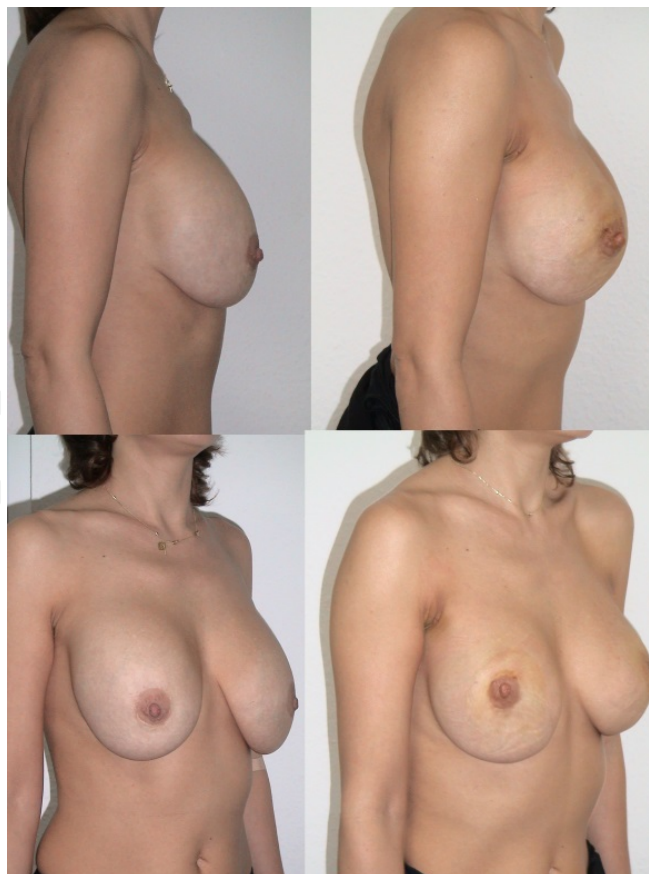
Warning: If not perforated, the fascias will be engaged in the suture, forming a dimpling effect on the surface.

d) Using an unloaded “medium” (140 mm) Serdev® needle, pass from point A, through pectoralis major tendon to A1. Point A1 can be a skin perforation or not. If no skin perforation point A1 is selected, change the needle direction, passing deep in the subdermal fat layer. then under the upper breast tissue, then perpendicular up through breast tissue and skin perforation at point B. Thread needle with USP 4, or 6 suture. Pull through point A.

Note: If easier, perforate A1 and introduce a threaded “mini” or “mini mini” Serdev® needle in line A-A1. Then, using an unloaded “medium” needle proceed from point B through the upper breast fascia, upper breast tissue, and in the deep subdermal fat to point A1. Next, thread the needle at A1 and pull it through at point B.

e) With the unloaded needle, take a different plane in the subdermal fat in line A-B, exiting at point B (**do not grab the tendon and the glandular breast fascia with the second pass, but stay in deep subdermal fat tissue**) Load needle at point B and pull through at point A.

f) While pulling both suture ends at point A, release any dimpling seen at point A1 and B. Tie with medium tension at point A. After tying and securing the knot, release any dimpling with a hemostat at **point A, A1 and B.**



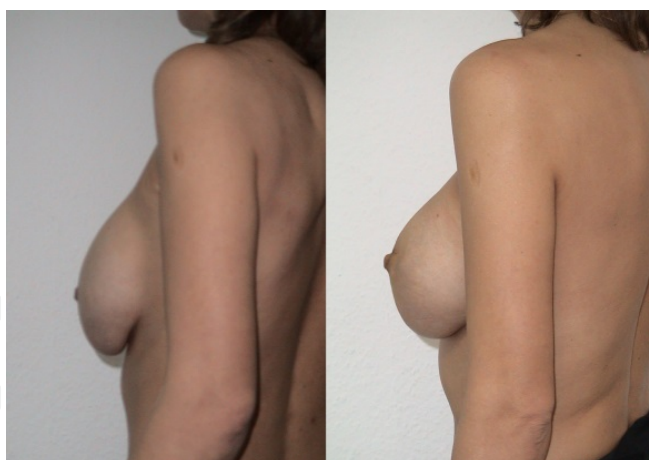


Figure 12. Before and after a breast lift with fixation to the pectoralis tendon. After subpectoral implants placement, the patient has given two births and after breast-feeding the breasts have dropped. Breast lift by suture solves the problem without additional surgery for bigger implant placement or excisional mastopexy.

4. Inner thigh lift

4.1. Introduction

Excisional thigh and buttock operations are traumatic surgical procedures that result in significant scarring. The Serdev Suture® method allows for an atraumatic and scarless lift of the inner thigh.

4.2. Anatomy

Inner thigh fat is attached to skin that loosens with time and descends with age, obesity and weight loss.

Between the major labia and the inner thigh fat deposit, there is about 3-5 cm skin that is free from any attached fat. The length of the fat-free skin depends on age, fat weight and skin laxity.

4.3. Surgical concept

The Serdev Suture® method is a stable suture fixation of movable to non-movable fibrous structures. The use of semi-elastic, absorbable surgical sutures is crucial, as they do not cut the target mobile tissue and when fibrosis is finalized (6 to 18 months) the sutures will be absorbed (in 2-3 years).

4.4. The procedure

The Dermis layer, precisely adjacent to the fat deposit, has to be sutured to the Gracilis tendon, near its insertion point at the Pubis (Fig. 13).

Position the patient so that the upper inner thigh is exposed (leg externally rotated). In this position the Gracilis muscle is the only visibly prominent muscle and tendon under the skin of the upper inner thigh. To identify the Gracilis tendon, palpate along the Gracilis muscle. The Gracilis tendon will be located immediately below the Pubic Tubercle.

Administer local anaesthetic injection to the dermis to be sutured (exactly over the upper fat border), surrounding soft tissues and in the proximal Gracilis tendon.

Make a stab incision with a No. 11 blade into the free-from-fat skin (in the lowest point possible) on both sides of the Gracilis Tendon. Incisions will be 1-1.5cm apart.

Perforate skin opening **A** with the Serdev® needle (mini-mini, or mini), elevate the skin with the needle to the Gracilis tendon insertion and securely pass through the tendon insertion. Lift the skin perforation on the other side to the level of the needle tip (needle is fixed in the tendon). Pass the needle through opening **B**. Load a USP 2 Bulgarian (Polycon) suture into the needle eye at point B and retrogradely withdraw the needle through point **A**. With this pass, the suture is fixed to the immobile Gracilis Tendon insertion. Allow the skin to relax back to its original position. Now make the second pass precisely through the firm dermis from **A** to **B** (very difficult – gently twisting forward (not pushing) the Serdev® needle) and passing through the skin opening at point **B**. Now load the free end of the suture into the eye of the needle. Retrogradely withdraw the needle from point **B** through the dermis pass and point **A**. With this pass, the movable firm dermis is attached to the suture and the circle of the suture is finalized with the 2 free suture ends at point **A**.

Tie a secure surgical knot under medium elastic tension. Cut the suture just short of the knot and let it dive into the opening. At this point is very important to release the skin at points **A** and **B** with a mosquito clamp to remove any dimpling of the skin.

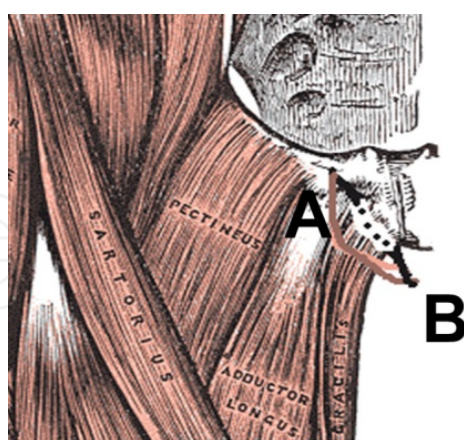


Figure 13. Inner thigh lift by suture is fixed to the incertion of the gracilis tendon

The medial thigh will now be lifted and the inner thigh skin will be stretched.

Skin folding will be placed high in the fold, laterally from the major labia. The initial skin folding due to skin lifting, anesthesia and swelling will adapt to the very wrinkled skin in this area and will disappear in 2-4 weeks.

5. Abdominal flaccidity lift

5.1. Introduction

This suture method for abdominal flaccidity was first presented in 1994 as a scarless alternative to the classic abdominoplasty (tummy tuck) and a part of the total understanding for the scarless closed approach suture lifting method all over face and body. The concept is the lift of abdominal skin without engaging it in the suture. This is achieved by a closed approach suture lift, using special instruments – curved semi-elastic needles and semi-elastic surgical sutures, distinguished by an extended period of delayed absorption (2-3 years).

The author uses skin perforations alone in the abdominal skin to capture, suture and lift the superficial fascias and linea alba supporting the abdominal skin. To obtain outcome longevity, it is important to lift and stretch these firm mobile fascias, fixing them to immobile firm tissue, such as xiphoid periosteum, costal and spina iliaca anterior superior periosteum.

The Serdev Suture® lift can be used in selected cases of thin patients to obtain a scarless and atraumatic tightening of the abdominal skin.

5.2. Anatomy

Anatomy landmarks are linea alba, superficial fascia, bone periosteum around the abdomen.

Firm mobile fascias fixing the abdominal skin are linea alba and superficial fascia. Firm immobile structures utilized in turn for fixation of the mobile fascias are the xiphoid process, the costal line, spina iliaca anterior superior.

Linea alba runs from the xiphoid process to the pubic symphysis and is mostly composed of collagen connective tissue. It fixes the abdominal skin longitudinally to the mid-line and consisting only of connective tissue, does not contain important nerves or blood vessels.

The superficial fascia of the abdomen fixes the anterior abdominal skin by a trabecular system. The superficial fascia consists of one thicker fatty superficial layer (Camper's fascia). There is also a membranous deep layer (Scarpa's fascia). The superficial vessels and nerves run between these two layers. It is important to preserve the a. and v. epigastrica inf.

The Procedure – see video http://youtu.be/oXU_80OqtOg

“sad navel”, “sad abdomen” = flaccidity

The aim of the transcutaneous, scarless, closed approach Serdev Sutures® for abdominal flaccidity lift is:

1. Cephalic lift - to produce a “happy navel” when shortening the length of linea alba.

Two skin perforation points are used: Point A at the xiphoid and point B at a selected length of the linea alba in the upper abdomen. After anesthetic infiltration in the points A and B

and along the length of linea alba, introduce the “medium” 140 mm Serdev® needle into point A, without capturing the dermis. In abdomen lifts the author uses a set of Serdev® needles with different lengths.

Take periosteum of the xiphoid and, by gently twisting the needle forward through the linea alba, exit at B. Load the needle and pull through. Second pass A-B is without catching periosteum. Load the second end of the suture and pull it through line B-A. The circle of the suture is fulfilled. Tie at A using medium elastic tension to lift the mobile linea alba in the direction of the xiphoid periosteum fixation. **NB!** Shortening of the linea alba length can be produced as well, without fixation to the periosteum, but only by shortening the lengths between 2 selected points of the linea alba, above the navel.

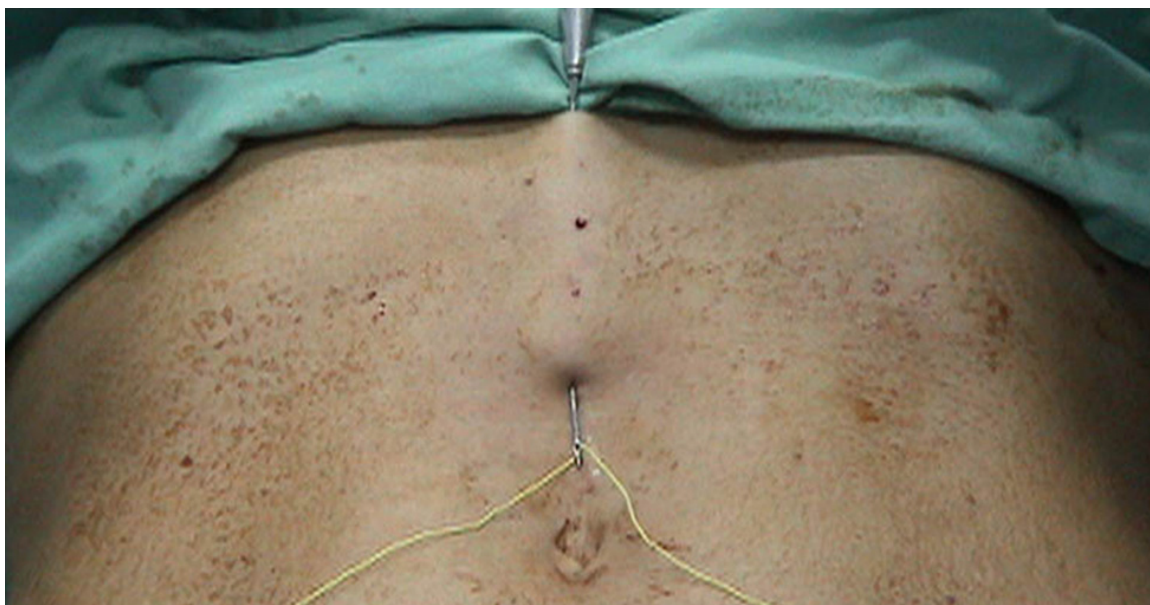

Figure 14. The needle is fixed to the xiphoid periosteum at A. Then, with soft, twisting zigzag motions through the length of linea alba it exits through point B, without catching dermis. The tip is loaded and the thread will be pulled through the line B-A. The second A-B pass will be more superficial, without producing dimpling on the surface (dimpling indicates an overly superficial pass), in order to load the second suture end and pull it through. The knot will be tied at A. Both passes could be located at both sides of the linea alba.

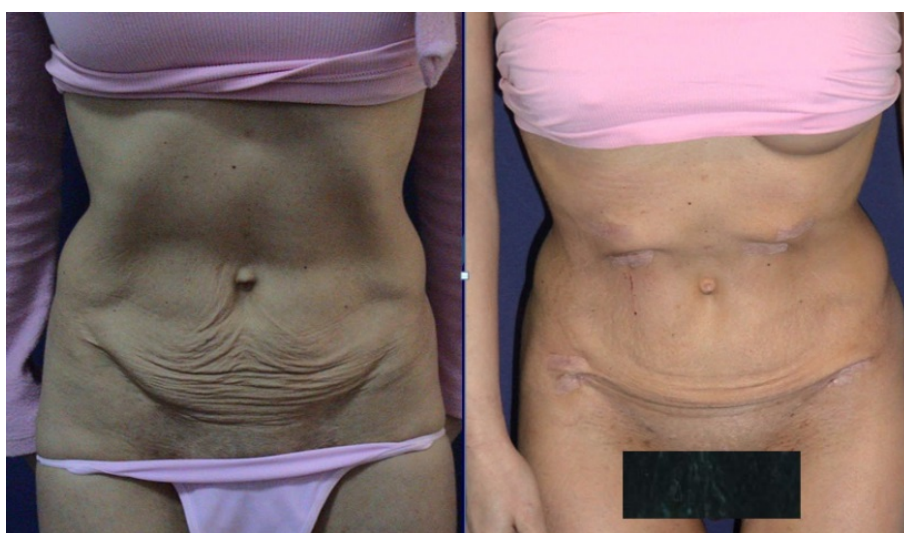2. Cephalic, lateral and distal lifting - to stretch the flaccid abdominal skin in cephalic, lateral and distal direction is performed by a fixation of the mobile superficial fascia to immobile structures, such as:

- a) the costal line periosteum/perichondrium,
- b) the spina iliaca anterior superior

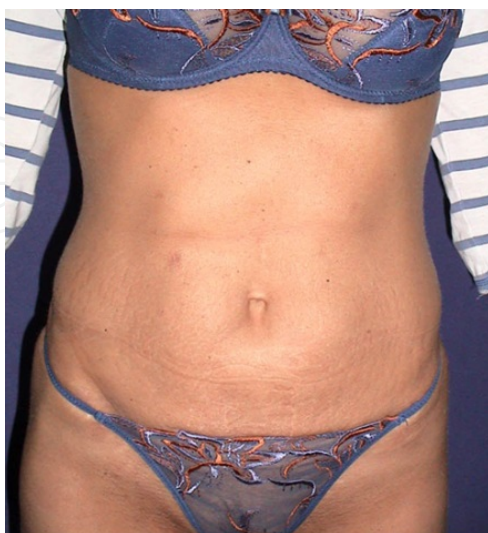5.3. Surgical procedure

Mark point A at costal periosteum/perichondrium level, or at spina iliaca anterior superior. Check the flaccidity level and mark point B (medial to A) at a selected distance. After

anesthetic infiltration in points A and B and along the length of line A-B, introduce “medium” (140 mm), “small” (100 mm) or “mini” (60 mm) Serdev® needle into point A, without capturing the dermis. Take periosteum and proceed a little deeper to capture the superficial fascia and exit at B. **NB!** Be careful not to perforate through the anterior abdominal wall. Superficial fascia is just below the abdominal skin. Move the needle laterally to check fascia fixation. Load the needle and pull it through. The second pass A-B is more superficial, without catching superficial fascia or periosteum. Load the second end of the surgical suture and pull it through line B-A. The circle of the suture is fulfilled. Tie at point A, using medium elastic tension, to stretch the mobile superficial fascia in direction to the immobile periosteum, perichondrium or linea alba at A, which reflects in stretching of the attached abdominal skin.



A



B

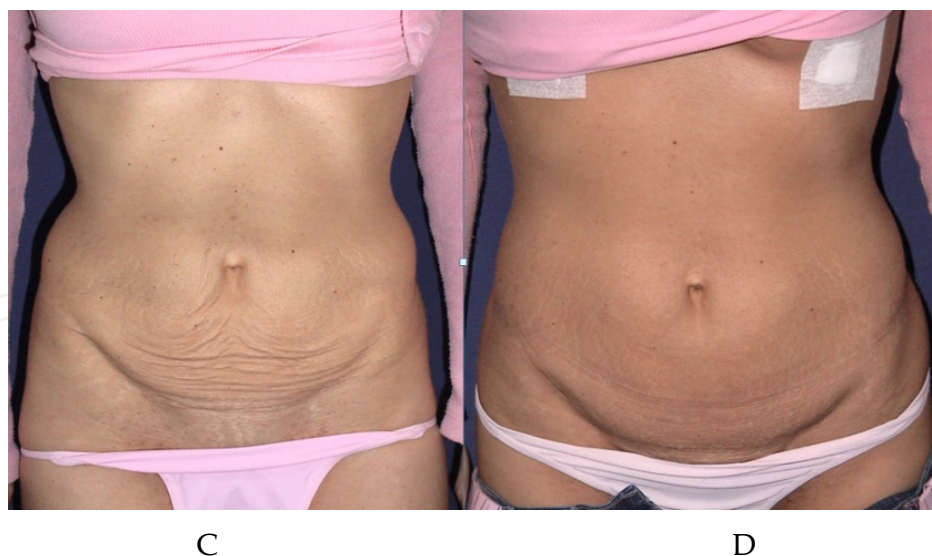


Figure 15. A. Before and immediately after linea alba lift, superficial fascia lift to costal periosteum and to spina iliaca anterior superior, B. Edema absorption after 20 days, C. before and D. final result. Bandages in the thorax area are connected with early post op secondary breast augmentation period.

Edema absorption in the fixation locations takes about a month.

Results are more than satisfactory. Selection of patients is important.

5.4. Conclusion

Buttock lifts: Redundant tissue in sagging buttocks can be corrected by excision lifts. However, these are seldom used procedures because of post-operative problems, such as unacceptable inferiorly displacement, wide scars, early recurrence of ptosis, large trauma, blood loss and a prolonged post-operative period.

In order to limit these complications in flat and sagging buttocks without remarkable fat deposits, the author has developed a surgical technique, using a circumferential suture of the soft tissue to the sacro-cutaneous fascia discovered by the author. The circumferential suspension gives strong vertical support with minimal tension in each point and reduces the complications, which are traditionally associated with other procedures. The author's suture lift offers fewer complications than any others described. It is an efficient and safe procedure to correct or enhance buttock contour. It has virtually eliminated most complications of liposuction and dermolipectomies under general anaesthesia.

In patients, whose problem was excessive fat in conjunction with flabbiness, UAL of the buttocks combined with the buttock suture lifting method completed the main goals of the procedure in one or more different stages. The combination of UAL and buttock lift by the suture technique described in this chapter is a minimally invasive procedure that can be used to reduce and lift the buttocks at the same time.

The Serdev Suture® buttock lifting technique is simple and low in cost, with minimal morbidity and very good results. It is important to note that a good result does not depend

on great surgery but rather on more simple and acceptable procedures for the patients. Outcomes incorporate harmonious structuring and positioning of the form, lifting of the lower portion of the buttocks, augmentation in the upper gluteus part and better projection. Complications with suture lift of the buttocks are few and patient satisfaction is high. The result is a visual change in the buttock projection, roundness, tightness and higher positioning. The buttock lift elongates the lower limbs and visibly changes the proportions of the body. Patients of regular weight seeking higher, rounded and projected buttocks with better proportions are indicated. Heavy buttocks and obesity are contraindicated.

Breast Lifts: Redundant tissue in ptotic and giant breasts can be corrected by excision lifts. However, these are procedures with wide scars, early recurrence of ptosis, large trauma, blood loss and a prolonged post-operative period, post-operative problems, such as unacceptable displacement etc.

The Serdev Suture® breast lifting technique is simple, with minimal morbidity and very good results. Complications with suture lift are few and patient satisfaction is high. The result is a visual change in the projection, tightness and higher positioning, as well as position of the nipple at the middle of the humerus. Heavy breasts and large ptosis are contraindicated.

Inner Thigh lift by suture is indicated mostly in skinny patients.

Abdominal Flaccidity: Serdev Suture® for abdominal flaccidity lift is a satisfactory procedure that can be done in several steps. It is scarless and atraumatic. No complications have been observed. Selection of patients and their acceptance of a time interval for the adaptation of some bulging/edema in areas of fixation to the costal periosteum is crucial for patients' satisfaction. It is a good alternative to abdominoplasty in thin and selected patients.

Author details

Nikolay Serdev

New Bulgarian University, Sofia, Bulgaria

6. References

- [1] Serdev, N.P. Year 1994, Suture Suspensions For Lifting Or Volume Augmentation In Face And Body (English version), presented at the 2nd Annual Meeting of the National Bulgarian Society for Aesthetic Surgery and Aesthetic Medicine, Sofia, 18 March 1994, *Int J Aesth Cosm*, 2001,1:1, 2561-2568
- [2] Serdev, NP. Buttock lift. Two own methods. 3rd International Congress of the South-American Academy of Cosmetic Surgery, Buenos Aires, Argentina, October 19-21, 2001
- [3] Serdev, NP. Buttocks lift by ultrasonic assisted liposuction - My technique *International Journal of Aesthetic Cosmetic Beauty Surgery* Volume 1, Number 3, 1991, 130-54

- [4] Serdev, NP. Buttocks lifting without implants - Serdev technique no visible scars" Aesthetic Surgery Course In Sofia, Bulgaria, Medical Center "Aesthetic Surgery, Aesthetic Medicine, November 26, 2001
- [5] Anikina TI. Soft framework of the human body, Arkh Anat Gistol Embriol 1980 Mar;78(3):5-15
- [6] Hexsel DM, Mazzuco R., Subcision: a treatment for cellulite. Int J Dermatol 2000 Jul;39(7):539-44
- [7] Gargan TJ, Courtiss EH., The risks of suction lipectomy. Their prevention and treatment. Clin Plast Surg 1984 Jul;11(3):457-63
- [8] Schlesinger SL. Two arcane areas in liposuction: the banana and the sensuous triangle. Aesthetic Plast Surg 1991 Spring;15(2):175-80
- [9] Gasparotti M. Superficial liposuction: a new application of the technique for aged and flaccid skin. Aesthetic Plast Surg 1992 Spring;16(2):141-53
- [10] Pitanguy I. Surgical reduction of the abdomen, thigh, and buttocks. Surg Clin North Am 1971 Apr;51(2):479-89
- [11] Delerm A, Cirotteau Y. Cruro-femoro-gluteal or circumgluteal plasty. Ann Chir Plast 1973;18(1):31-6
- [12] Agris J. Use of dermal-fat suspension flaps for thigh and buttock lifts. Plast Reconstr Surg 1977 Jun;59(6):817- 22
- [13] Gasperoni C, Salgarello M. MALL liposuction: the natural evolution of subdermal superficial liposuction. Aesthetic Plast Surg 1994 Summer;18(3):253-7
- [14] Shaer WD. Gluteal and thigh reduction: reclassification, critical review, and improved technique for primary correction. Aesthetic Plast Surg 1984;8(3):165-72
- [15] Chajchir A., Fat injection: long-term follow-Up. Aesthetic Plast Surg 1996 Jul-Aug;20(4):291-6
- [16] Cardenas-Camarena L, Lacouture AM, Tobar-Losada A., Combined gluteoplasty: liposuction and lipoinjection. Plast Reconstr Surg 1999 Oct;104(5):1524-31;
- [17] Lack EB. Contouring the female buttocks. Liposculpting the buttocks. Dermatol Clin 1999 Oct;17(4):815-22
- [18] Lewis JR Jr. Body contouring. South Med J 1980 Aug;73(8):1006-11
- [19] Pereira LH, Radwanski HN., Fat grafting of the buttocks and lower limbs. Aesthetic Plast Surg 1996 Sep-Oct;20(5):409-16
- [20] Hanke CW, Bullock S, Bernstein G., Current status of tumescent liposuction in the United States. National survey results. Dermatol Surg 1996 Jul;22(7):595-8
- [21] De Pedroza LV., Fat transplantation to the buttocks and legs for aesthetic enhancement or correction of deformities: long-term results of large volumes of fat transplant. Dermatol Surg 2000 Dec;26(12):1145-9
- [22] Teimourian B, Adham MN. Anterior periosteal dermal suspension with suction curettage for lateral thigh lipectomy. Aesthetic Plast Surg 1982;6(4):207-9
- [23] Guerrerosantos J. Secondary hip-buttock-thigh plasty. Clin Plast Surg 1984 Jul;11(3):491-503
- [24] Lewis JR Jr. Body contouring. South Med J 1980 Aug;73(8):1006-11
- [24] Lockwood T. Lower body lift with superficial fascial system suspension. Plast Reconstr Surg 1993 Nov;92(6):1112-22

- [25] Regnault P, Daniel R. Secondary thigh-buttock deformities after classical techniques. Prevention and treatment. *Clin Plast Surg* 1984 Jul;11(3):505-16
- [26] Gonzalez M, Guerrerosantos J. Deep planed torso-abdominoplasty combined with buttocks pexy. *Aesthetic Plast Surg* 1997 Jul-Aug;21(4):245-53
- [27] Carwell GR, Horton CE Sr. Circumferential torsioplasty. *Ann Plast Surg* 1997 Mar;38(3):213-6
- [28] Heddens CJ. Belt lipectomy: procedure and outcomes. *Plast Surg Nurs* 2001 Winter;21(4):185-9, 199
- [29] Pascal JF, Le Louarn C. Remodeling bodylift with high lateral tension. *Aesthetic Plast Surg* 2002 May-Jun;26(3):223-30
- [30] Lavigne P, Lorient de Rouvray TH. The superior gluteal nerve. Anatomical study of its extrapelvic portion and surgical resolution by trans-gluteal approach *Rev Chir Orthop Reparatrice Appar Mot* 1994;80(3):188-95
- [31] Karnes J, Salisbury M, Schaeferle M, Beckham P, Ersek RA. Hip lift. *Aesthetic Plast Surg* 2002 Mar-Apr;26(2):126-9
- [32] Hagen K, Sorhagen O, Harms-Ringdahl K., Influence of weight and frequency on thigh and lower-trunk motion during repetitive lifting employing stoop and squat techniques. *Clin Biomech (Bristol, Avon)* 1995 Apr;10(3):122-127
- [33] Niechajev I, Sevcuk O., Long-term results of fat transplantation: clinical and histologic studies. *Plast Reconstr Surg* 1994 Sep;94(3):496-506
- [34] Guerrerosantos J., Autologous fat grafting for body contouring. *Clin Plast Surg* 1996 Oct;23(4):619-31
- [35] Peren PA, Gomez JB, Guerrerosantos J, Salazar CA. Gluteus augmentation with fat grafting. *Aesthetic Plast Surg* 2000 Nov-Dec;24(6):412-7
- [36] Ichida M, Kamiishi H, Shioya N., Aesthetic surgery of the trunk and extremities in the Japanese. *Ann Plast Surg* 1980 Jul;5(1):31-9
- [37] Lawrence N, Coleman WP 3rd., The biologic basis of ultrasonic liposuction. *Dermatol Surg* 1997 Dec;23(12):1197-200
- [38] Serdev, N.P. Breast Lift: My Methods Presentations from the Congress "VI Sharing with the Experts" - San Salvador, *Int J Cosm Surg* 2009, 9, 2, 1 – 39
- [39] Serdev, N.P. Serdev Suture Techniques Breast Lift Original Papers, *Int J Cosm Surg*, 2009, 9, 4, 1 – 3
- [40] Serdev, N.P. Minimally Invasive Author Technique For Breast Lift Without Scars Using Sutures Abstracts - The First World Multidisciplinary Congress on Cosmetic Surgery and Medicine *Int J Cosm Surg*, 2010, 10, 3, 1 – 1
- [41] Serdev, N.P. Tratamento De Flacidez Cutanea Abdominal Com Filos Elásticos Serdev / Scarless Serdev Suture Methods For Abdominal Skin Flaccidity, 12 Congresso Brasileiro Medicina Estetica - 15 - 18 June 2005, Salvador, *Int J Cosm Surg*, 2006, 6, 1, 1 - 25