

# We are IntechOpen, the world's leading publisher of Open Access books Built by scientists, for scientists

6,900

Open access books available

186,000

International authors and editors

200M

Downloads

Our authors are among the

154

Countries delivered to

TOP 1%

most cited scientists

12.2%

Contributors from top 500 universities



WEB OF SCIENCE™

Selection of our books indexed in the Book Citation Index  
in Web of Science™ Core Collection (BKCI)

Interested in publishing with us?  
Contact [book.department@intechopen.com](mailto:book.department@intechopen.com)

Numbers displayed above are based on latest data collected.  
For more information visit [www.intechopen.com](http://www.intechopen.com)



---

# Acute Thromboembolic Pulmonary Hypertension

---

Jean M. Elwing and Ralph J. Panos

Additional information is available at the end of the chapter

<http://dx.doi.org/10.5772/56719>

---

## 1. Introduction

Acute pulmonary thromboembolism is a common and life-threatening condition that requires prompt evaluation and management to improve outcomes. In severe cases, acute pulmonary thromboembolism causes a rapid rise in pulmonary pressures precipitating compromised right ventricular (RV) function. Acute elevation in pulmonary pressures with RV failure is associated with poor outcome. When pulmonary thromboembolic disease is detected, further assessment of its impact on cardiac function is required for risk stratification and to determine appropriate therapy. This evaluation requires appropriate diagnosis of pulmonary thromboembolic disease as well as assessment of hemodynamics and RV function with electrocardiograms (ECG), echocardiography and commonly available biomarkers (Tapson 2012).

## 2. Epidemiology and prevalence

Venous thromboembolism is the third most common acute cardiovascular disease after myocardial infarction and stroke (Giuntini 1995). The incidence of venous thromboembolism is estimated to be 100-300 per 100,000 individuals but is age dependent increasing from 5 per 100,000 in childhood to 500-600 per 100,000 in those over 75 years of age (Douma 2010). Based upon the International Cooperative Pulmonary Embolism Registry (ICOPER), 4.2% of PE are classified as massive and are associated with systemic hypotension and cardiogenic shock (Stein 2003). In the Emergency Medicine Pulmonary Embolism in the Real World Registry (EMPEROR), 58 of 1875 patients (3.1%) presented with massive PE and their 30-day mortality was 14% (Lin 2012). The mortality rate for individuals with hemodynamically stable acute PE is 2-8% (Goldhaber 1999, Nijkeuter 2007) and the main cause of death is RV failure (Schoefp 2004, Kasper 1997, Wood 2002). However, in the first 3 months after acute PE, the case fatality rate increases to 15-18% (Goldhaber 1999).

## 2.1. Clinical presentation

Risk factors for PE are summarized in table 1 (Stein and Matta Curr Probl Cardiol 2010). Conditions predisposing to the development of deep venous thrombosis (DVT) include malignancy (especially pancreatic and brain cancers), chronic obstructive pulmonary disease, stroke, pregnancy, obesity, and immobilization, especially after lower extremity trauma or after surgery (hip and knee replacement). Hypercoagulable states may be acquired or inherited. Deficiencies in antithrombin, protein C, or protein S, factor V Leiden mutation, prothrombin gene 20210 mutation, and antiphospholipid antibodies predispose individuals to the development of venous thrombosis and subsequent PE.

Condition	Prevalence (%)
Immobilization	44
Surgery $\leq$ 3 month	35
Malignancy	18
Thrombophlebitis	16
Myocardial infarction	13
Trauma $\leq$ 3 months	11
Lower extremity	
Heart failure	9
Asthma	9
COPD	8
Stroke, paresis, or paralysis	8
Prior PE	5
Travel	
>4 hr in past month	4
Collagen vascular disease	4
Pneumonia (current)	1

**Table 1.** Predisposing conditions in patients with PE (based upon data from PIOPED I and II; (adapted from Stein and Matta 2010)

## 2.2. Clinical manifestations

The clinical manifestations and presentation of acute PE are not specific and range from mild breathlessness to hemodynamic collapse. Dyspnea either at rest or with exertion occurs in approximately three quarters of patients diagnosed with PE (Stein 2010). Pleuritic or non-pleuritic chest discomfort occurs less frequently. Hemoptysis occurs in 5-15% of patients with PE. Approximately one third of patients with DVT have clinically asymptomatic PE (Stein 2010). The clinical presentation of PE has been classified recently into three categories: 1)

syndrome of pulmonary hemorrhage or infarction with pleuritic chest pain or hemoptysis; 2) syndrome of isolated dyspnea, breathlessness with no accompanying chest discomfort, hemoptysis, or hemodynamic alteration; and 3) syndrome of circulatory collapse with loss of consciousness, hypotension, or cardiogenic shock (Ouellette 2012).

Alterations in vital signs occur frequently in patients with PE. Respiratory and heart rates are often increased; elevated temperatures occur less frequently. Blood pressure is reduced in hemodynamically significant PE. Physical examination findings are often not specific and are usually detected in only a minority of patients. Cardiac examination may reveal tachycardia, elevated jugular venous pressure, right ventricular lift, and increased sound of pulmonic valve closure. Pulmonary auscultation may identify crackles, rales, wheezes, diminished breath sounds, or rarely a pleural friction rub. Lower extremity swelling, edema, or tenderness is detected infrequently.

### 3. Diagnostic studies

Because the clinical presentation and manifestations of PE are not specific, further diagnostic testing is required to establish the diagnosis definitively. Patients are usually categorized by the clinical probability, either high or intermediate/low, based upon the clinician's suspicion for the presence of PE. Several evaluation systems have been developed to assess the clinical probability for the presence of PE and the most widely used algorithms are the Wells score and the revised Geneva score (Wells 2000, LeGal 2006). If the suspicion for PE is intermediate or low, a D-dimer assay is performed. D-dimer is formed during the degradation of cross-linked fibrin and its presence is very sensitive for intravascular thrombosis due to either venous thrombosis or PE. The threshold value for D-dimer testing depends upon the assay but a value below the threshold indicates a very low risk for the presence of thrombosis. However, a value above the threshold is not specific for thrombosis and further evaluation is required. Compression ultrasonography is the currently preferred evaluation for suspected DVT and chest computed tomographic pulmonary angiography (CTPA) is used to diagnose PE.

#### 3.1. Laboratory abnormalities

Troponin I and T and brain natriuretic peptide (BNP) are cardiac biomarkers that are released into the circulation when cardiac myocytes are stretched or injured as may occur during right ventricular dysfunction after an acute pulmonary embolism (Samama 2006). Elevation of these biomarkers identifies patients who are normotensive but have an increased risk of mortality (Pruszczyk 2003). Neither biomarker is a sensitive assay for the diagnosis of pulmonary embolism (Meyer 2003).

Measurement of  $P_aO_2$  and  $P_aCO_2$  are routinely performed in patients presenting with breathlessness or pleurisy. In patients suspected to have PE, the sensitivity and specificity of a  $P_aCO_2 < 36$  mmHg are 45% and 60%, respectively, and a  $P_aO_2 < 80$  mmHg are 57% and 53%, respectively (Rodger 2000).

### 3.2. Electrocardiogram

The electrocardiographic manifestations of pulmonary embolism vary greatly from sinus tachycardia to conduction delays to patterns of RV strain (Panos 1988). Up to one quarter of patients with acute PE have normal electrocardiograms. Rhythm disturbances include tachycardia which is most common, atrial fibrillation, and atrial flutter. Conduction abnormalities include first degree AV block, and left and right bundle branch block. The S1Q3T3 pattern may occur in 25-50% of patients.

## 4. Imaging studies

Multi-detector computed tomography pulmonary angiography (CTPA) is the current best imaging study for the diagnosis of acute PE (Mos 2012, Klok 2011). Image acquisition is timed to occur during opacification of the pulmonary arterial bed after an intravenous injection of contrast. This technique has both high sensitivity, 96-100%, and specificity, 97-98% (Remy-Jardin 2007). The use of intravenous contrast may be contraindicated in patients with allergies to iodinated contrast and those with renal insufficiency or who are at risk for contrast-induced nephropathy. A prospective study showed that 14 of 174 patients (8%) developed contrast-induced nephropathy after CTPA which significantly contributed to the adverse outcomes of patients suspected of having an acute PE (Mitchell 2012). The radiation exposure during a CTPA has been estimated to cause 150 excess cancer deaths per million scans (Remy-Jardin 2007). RV function can also be assessed during multi-detector CTPA and abnormal position of the interventricular septum, inferior vena cava contrast reflux, RV diameter to left ventricle (LV) diameter ratio  $> 1.0$  and RV volume to LV volume ratio  $> 1.0$  are predictive of poor outcomes and RV diameter to LV diameter ratio  $> 1.0$  and RV volume to LV volume ratio  $> 1.0$  are also predictive of 30 day mortality after acute PE (Kang 2011).

In patients who are unable to undergo CTPA, ventilation perfusion scintigraphy (V/Q scan) is the next best imaging procedure for acute PE (Mos 2012). A normal V/Q scan effectively identifies patients who do not need anticoagulation treatment whereas a high probability V/Q scan has a positive predictive value  $> 90\%$  (PIOPED 1990). However, up to half of patients with suspected PE may have intermediate scans and require further testing to exclude or establish a diagnosis of PE (Anderson 2007). Intermediate scans occur less often in patients with a normal chest x-ray and no prior cardiopulmonary disease (Calvo-Romero 2005).

### 4.1. Echocardiography

Transthoracic and transesophageal echocardiography (ECHO) can be used to image cardiac structure and function in patients with suspected PE. Rarely, intravascular thrombus can be visualized if the clot is large and located within the proximal pulmonary artery (Goldhaber 2002). Studies correlating perfusion lung scans with ECHO findings suggest that approximately 92% of patients with PE and occlusion of greater than one third of the pulmonary vasculature demonstrate right ventricular hypokinesis (Wolfe 1994, McConnell 1996). Other echocardiographic findings in acute PE include right ventricular dilation, septal flattening and

paradoxical septal motion, pulmonary arterial hypertension, and patent foramen ovale (Goldhaber 2002).

ECHO may be used to risk stratify hemodynamically stable patients with acute PE. In a meta-analysis, Sanchez and colleagues found the unadjusted relative risk of RV dysfunction for predicting death in patients with acute PE and normal hemodynamics was 2.4 (95% CI 1.3-4.4) (Sanchez 2008). In a prospective study of patients with acute PE, RV dysfunction determined by ECHO had an odds ratio of 1.2 (95% CI 1.1-1.4) for adverse events including death, cardiogenic shock, and recurrent venous thromboembolism (Sanchez 2010).

## **5. Hemodynamic consequences of acute pulmonary embolism**

### **5.1. RV response to Acute PE**

The response of the RV to acute PE depends upon its pre-existing level of function and hemodynamic relationship with the LV, the extent of pulmonary artery bed occlusion, and the degree of pulmonary arterial vasoconstriction caused by hypoxemia, release of vasoactive and bronchoactive mediators from platelets and vascular endothelial cells, and neural responses.

### **5.2. Baseline cardiopulmonary status**

Approximately half of patients with acute PE have RV dysfunction at presentation and 14-17% have persistently reduced RV function six months later (Klok 2011, Stevinson 2007). Serial echocardiograms show that the PA pressure declines and RV dysfunction improves rapidly over the 30 days after presentation in approximately 90% of patients with acute PE and that age greater than 70 years and PAP greater than 50 mmHg are associated with persistent PH and RV dysfunction (Ribeiro 1999).

### **5.3. Extent of pulmonary vascular occlusion**

In a series of 690 patients diagnosed with PE, the number of occluded pulmonary artery segments ranged from 1 to 17 and was normally distributed with a mean of 9.2 segments representing 51.2% of the pulmonary arterial bed (Guintini 1995). Because the pulmonary vasculature is a high capacitance system, earlier studies suggested that occlusion of 70% or more of the pulmonary vasculature is required for the elevation of pulmonary pressures (Sabiston 1965, Wagenvort 1995). Subsequent studies using measures of pulmonary vascular bed occlusion such as the Miller index, the Walsh score, or the Qanadli index suggested that obstruction of at least 30-40% identifies greater than 90% of patients with RV dilation (Qanadli 2001). However, further studies have shown that the RV ejection fraction determined with or without electrocardiographic synchronization and the RV/LV ratio are better predictors of clinical outcome than the pulmonary artery obstruction index (van der Bijl 2011)

## 5.4. Effects of vasoactive and broncho-active mediators

### 5.4.1. Vasoactive mediators

In experimental animal models of occlusive pulmonary embolism, blockage of vasoconstricting mediators such as thromboxane  $A_2$  ( $TxA_2$ ), serotonin, endothelin-1, and prostaglandin  $F_{2\alpha}$  decreases pulmonary vascular resistance (Smulders 2000, Jones 2003, Reeves 1976, Reeves 1983, Todd 1981, Todd 1983, Breuer 1985, Battistini 2003, Kapsch 1981) suggesting that these factors play a significant role in increased pulmonary vascular resistance and elevated pulmonary pressures after acute PE.

Platelets produce  $TxA_2$  after activation; other less significant sources of  $TxA_2$  are endothelial cells and monocytes (Smulders 2000).  $TxA_2$  production occurs quickly after PE and the level of production correlates with mortality in animal models (Reeves 1983). Reduction of  $TxA_2$  production by COX inhibitors diminishes the increase in pulmonary artery pressure by 40-60% in various models of PE (Weidner 1979, Konstam 1987).

Within the lung, serotonin is produced by activated platelets and is a potent vasoconstrictor. Serotonin levels increase in the pulmonary circulation after PE and infusion of serotonin can produce hemodynamic changes similar to PE (Thompson 1986, Breuer 1985). Inhibition of monoamine oxidase which degrades serotonin accentuates the vascular response to PE and reduction of platelet serotonin by reserpine diminishes the hemodynamic effect of PE (Rosoff 1971, Miczoch 1978, Gurewich 1968). Serotonin inhibitors markedly reduce pulmonary vascular resistance in various animal models of PE and a combination of  $TxA_2$  and serotonin inhibitors completely prevents mortality due to massive PE in rabbits (Todd 1981, Todd 1983).

Prostacyclin ( $PGI_2$ ) is a vasodilator produced by endothelial cells that antagonizes many of the effects of  $TxA_2$  and serotonin. Blocking  $PGI_2$  production or its effects augments the deleterious hemodynamic effects of PE (Smulders 2000).

Endothelins are potent vasoconstrictors produced by various pulmonary cells including endothelial cells, epithelial cells, monocytes, and macrophages. These mediators are potent vascular and bronchial constrictors and induce increases in pulmonary vascular resistance, decreases in pulmonary compliance and hypoxemia due to deranged ventilation-perfusion relationships. The effect of endothelin receptor antagonists on the hemodynamic consequences of PE are complex and vary depending upon the PE model and animal species (Battistini 2003).

Intravascular hemolysis may also occur during acute PE releasing free hemoglobin that may decrease pulmonary nitric oxide which may promote pulmonary vasoconstriction (Kline 2009).

### 5.4.2. Neural factors

In the resting state, the pulmonary arterial tree is nearly maximally dilated with little or no resting tone (Stratmann 2003). Vasodilating innervation is variable throughout most of the pulmonary arterial system but is consistently present in arteries >700 micrometers in diameter. In contrast, noradrenergic vasoconstrictive innervation is present throughout the entire

pulmonary bed. The effect of acetylcholine and sympathomimetics on pulmonary artery pressure is dependent upon the resting pressure and the same mediator may have constricting or dilating effects depending upon whether the baseline pressure is normal or increased (Stratmann 2003). Acute PE may also trigger the short lived von Bezold-Jarisch reflex which is manifest by apnea, bradycardia, and hypotension and may contribute to sudden death associated with PE (Stratmann 2003). This reflex may be mediated by J receptors, pulmonary irritant receptors, and pulmonary C-fibers.

#### *5.4.3. RV response to changes in the pulmonary vasculature*

The obstructive and vasoconstricting effects of acute PE on the pulmonary vasculature cause a sudden increase in the RV afterload that elevates RV wall tension dilating the RV, reducing its contractility, and impairing systolic and diastolic function. Right ventricular dilation distorts the anatomic configuration of the heart. Acute tricuspid valve insufficiency may be precipitated by elevated pulmonary arterial pressures coupled with physical dilation of the valvular annulus that causes misalignment of the leaflets. In addition, as the RV dilates, the interventricular septum flattens or bows toward the LV impairing its filling. LV preload is thus reduced by decreased RV output, tricuspid insufficiency, and diminished left ventricular filling. As preload falls, left ventricular output decreases and systemic hypotension ensues. Right ventricular ischemia or infarction may be caused by reduced myocardial perfusion, increased right ventricular wall tension, and compression of the right coronary artery reducing blood flow. (Piazza 2005, 2013) Figure 1.

#### *5.4.4. Myocardial inflammation*

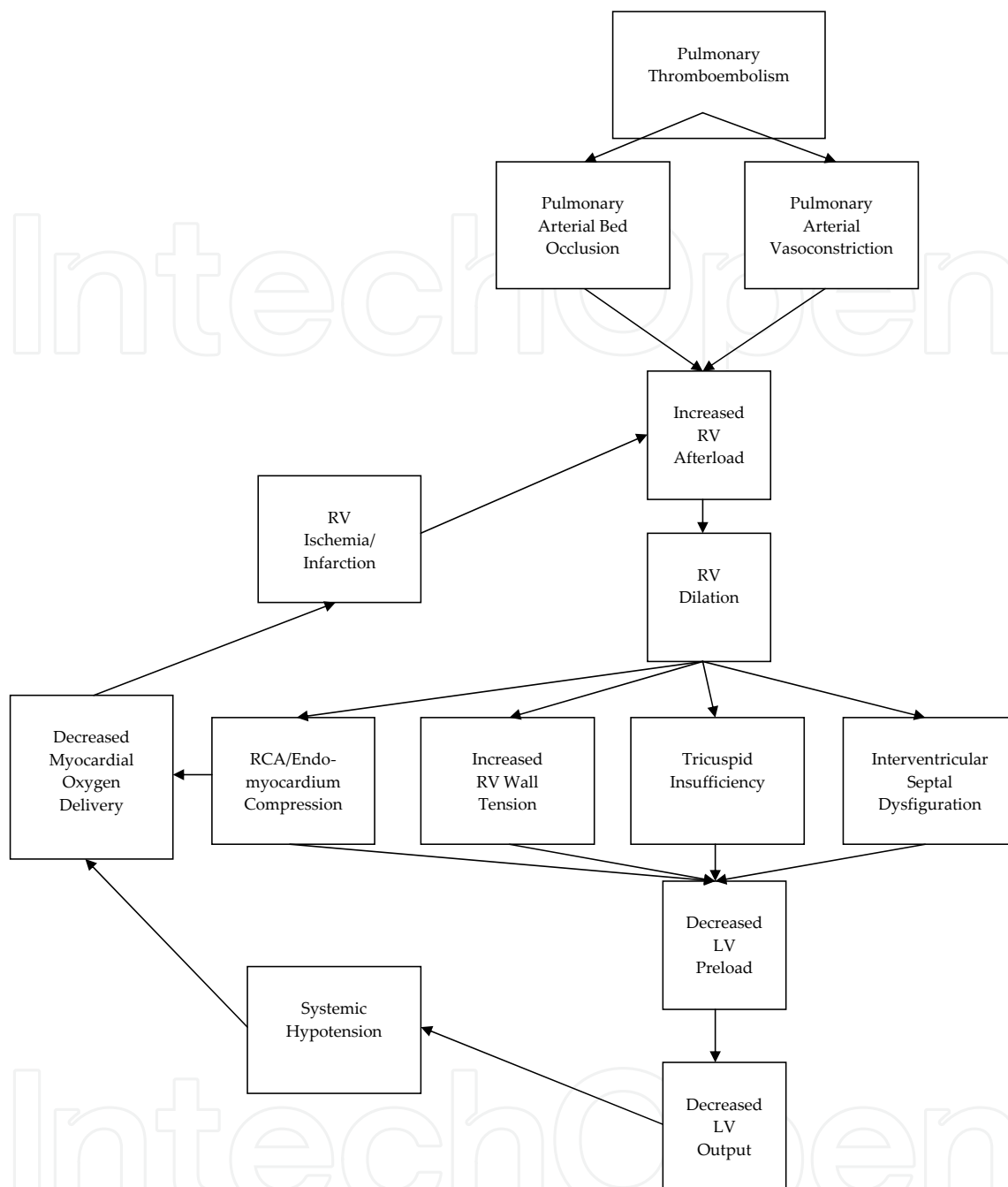
After acute PE, neutrophilic infiltration of the right ventricular outflow tract occurs within 6 hours and subsequently resolves over the ensuing week (Watts 2008). Histopathologically, there is evidence of myocyte lysis and necrosis (Begieneman 2008) Monocytes are also present during the acute period and persist for at least 6 weeks; however, their phenotype transforms from inflammatory to healing over this period (Watts 2008).

### **5.5. Diagnosis of acute pulmonary embolism**

The diagnostic evaluation of PE often is a multistep process which includes clinical evaluation, examination, laboratory assessment, and both noninvasive as well as invasive testing. Pulmonary angiography remains the gold standard to prove the presence of PE. However, this invasive test is not always readily available and does carry procedural risk. Other diagnostic modalities such as CTPA and V/Q scanning are used routinely in the assessment of possible PE (Tapson 2012).

## **6. Clinical prediction rules**

PE is suspected in many patients presenting with acute worsening of dyspnea or chest pain. When evaluating patients for the possibility of PE, the use of a validated tool to predict pretest



**Figure 1.** Acute pathophysiologic responses of the right ventricle to pulmonary thromboembolism (Adapted from Piazza and Goldhaber 2005)

extensively validated rules were the three-level Wells, two-level Wells, Geneva score, revised Geneva score, and the Charlotte rule (Ceriani 2010). The available CPRs incorporate patient's symptoms and the likelihood of alternative etiologies to determine the probability of PE as the cause of symptoms. These tools serve as valuable guides to assess the likelihood of PE as the cause of symptoms and often are used to determine the extent of testing performed during evaluation of suspected pulmonary thromboembolism. (Table 2)

Pulmonary Embolism Wells Score	
Symptoms of DVT	3 points
No alternative diagnosis better explains the illness	3 points
Tachycardia with pulse >100	1.5 points
Immobilization (≥3 days) or surgery in the previous four weeks	1.5 points
Prior history of DVT or pulmonary embolism	1.5 points
Presence of hemoptysis	1 point
Presence of malignancy	1 point
Total Criteria Point Count:	
Pulmonary Embolism Score Interpretation	
Score > 6:High probability	
Score > 2 and < 6:Moderate probability	
Score < 2:Low Probability	

**Table 2.** Wells Score to predict pulmonary embolism (adapted from Wells 2000)

7. D-dimer

The D-dimer antigen is a marker of fibrin degradation. It is formed by the sequential action of thrombin, Factor XIIIa and plasmin. D-dimer antigen can exist on fibrin degradation products derived from soluble fibrin before its incorporation into a fibrin gel or after the fibrin clot has been degraded by plasmin (Adam 2009). D-dimer has been found to be useful in evaluating outpatients for the presence of venous thromboembolism (VTE) (Wells 2001). D-dimer levels >500 ng/mL are considered elevated (Stein 2004). 95% of patients with proven PE will have an elevated D-dimer by ELISA assay (Stein 2004). Unfortunately, only 40-68% of patients without VTE have a negative D-dimer (Stein 2004). D-dimer elevation occurs in multiple other conditions besides PE including renal failure, surgery, cancer, sepsis, and pregnancy (Rathbun 2004). Thus, the use of d-dimer to evaluate VTE in hospitalized or otherwise chronically ill patients is limited. D-dimer is best used to exclude VTE in outpatients with low or moderate clinical suspicion for a thromboembolic event (Rathbun 2004, Wells 2000, Wells 2001, Stein 2006, Stein 2007).

8. Computed tomography pulmonary angiography (CTPA)

Over the last several decades, CTPA has become the first-line imaging modality for the assessment of PE. When compared with V/Q scanning in a randomized, single-blinded noninferiority clinical trial involving 1417 patients, CTPA was found to be non-inferior to V/Q scanning (Anderson 2007). CTPA is readily available and offers a high level of sensitivity and specificity for acute PE (Huisman 2013). PIOPED II found CTPA to be 83% sensitive and 96% specific for PE (Stein 2006). The newer generation multi-detector CTPA sensitivity is over 95% for segmental, lobar and centrally located PE (Huisman 2013) and is an extremely useful test to exclude PE (van Beek 2001). As with all other imaging modalities for pulmonary thromboembolism, CTPA should be used as part of an integrated approach in the evaluation of PE (Rathbun 2000, Van Strijen 2005) utilizing risk assessment tools to determine the appropriateness of proceeding to CTPA as this test does expose patients to radiation (Remy-Jardin 2007) and IV contrast.

9. Ventilation/perfusion scanning (V/Q scan)

An alternative diagnostic study to CTPA is V/Q scanning. V/Q scanning involves imaging of pulmonary perfusion and ventilation to evaluate for areas of mismatch that suggest the presence of PE. The average radiation exposure for a V/Q scan is 1.2 mSv. PIOPED evaluated the accuracy of V/Q scanning in the assessment of pulmonary embolism compared with the gold standard pulmonary angiogram (PIOPED 1990). Patients with a high clinical probability of PE and a high probability V/Q had a 95% likelihood of truly having a PE. Patients with a low clinical probability of PE and a low probability VQ scan had a 4% likelihood of having a PE (Gottschalk 2007). A normal V/Q scan virtually excluded PE (PIOPED 1990). Unfortunately, in patients with other combinations of clinical risk and V/Q results, the diagnostic accuracy of V/Q ranged from 15-86%. Therefore, additional diagnostic testing is required to determine the presence of PE in this group (Calvo-Romero 2005). (Table 3)

V/Q Scan Probability	Clinical Probability of Pulmonary Embolism		
	High	Intermediate	Low
High	96	88	56
Intermediate	66	28	16
Low	40	16	4
Normal or near normal	0	6	2

**Table 3.** Likelihood of pulmonary embolism according to scan category and clinical probability (based on PIOPED study 1990)

## **10. Pulmonary angiography**

Pulmonary angiography is an invasive test that requires catheter placement in the pulmonary artery and directed IV contrast infusion to detect intraluminal vascular filling defects that might be caused by PE. This test requires performance and interpretation expertise and carries a risk of intracardiac catheter placement, radiation, and contrast exposure. In 1992, Stein et al (Stein 1992) reported 0.5% mortality, 1% nonfatal complications and 5% minor complications associated with this test in the 1,111 patients who underwent angiography in PIOPED. In most centers, pulmonary angiography has been replaced by CTPA as the standard for the diagnosis of PE (Hogg 2006). Currently, pulmonary angiography is only employed when other less invasive attempts at diagnosis are inconclusive.

## **11. Cardiac magnetic resonance imaging**

Cardiac magnetic resonant imaging (MRI) is not a widely utilized tool in the evaluation of patients with PE. Magnetic resonance angiography (MRA) is often limited by motion artifact with resultant suboptimal resolution (Tapson 1997). When MRA was evaluated prospectively in 118 patients with dyspnea, MRA was positive in only 77% of patients with confirmed pulmonary embolism by conventional pulmonary angiography. Furthermore, in that study, MRA was positive in 100% of lobar PE, 84% of segmental PE and 40% of subsegmental PE (Oudkerk 2002). MRA may have promise in the future but requires further optimization of this imaging strategy prior to its routine use.

## **12. Assessment of right ventricle and pulmonary vasculature derangements**

### **12.1. Electrocardiography**

Electrocardiography (ECG) is an easily obtainable initial study in the evaluation of dyspnea and chest pain. It is often helpful in evaluating for acute coronary syndrome. Unfortunately, ECG has limited diagnostic value for acute PE (Rodger 2000). However, in the setting of known pulmonary thromboembolism, ECG is oftentimes abnormal and may be of some benefit in risk stratification. In 1997, Ferrari et al (Ferrari 1997) reported the results of 80 consecutive ECGs in hospitalized patients with documented pulmonary embolism. T-wave inversion in the precordial leads was shown to be the most common abnormality (68%) and correlated with PE severity. Anterior T wave inversions had a sensitivity of 90% and specificity of 81% for massive PE. The classic finding of acute RV failure with S1Q3 T3 was seen in 50% of ECGs in the setting of confirmed acute PE (Ferrari 1997) which is more frequent than previously reported, 12% (Stein 1975) to 28% (Cutforth 1958).

## 12.2. Cardiac echocardiography

Cardiac echocardiography (ECHO) is a useful tool in evaluation of a patient presenting with dyspnea and/or chest pain. Cardiac ECHO should not be used in the evaluation to confirm the diagnosis of acute PE as only 30-40% of all acute pulmonary thromboembolic events are associated with echocardiographic abnormalities (Gibson 2005). However, cardiac ECHO may be used in a supportive role in the diagnostic evaluation and for risk stratification. Several echocardiographic parameters should be assessed in the setting of presumed or confirmed PE including RV size, RV function, presence of RV thrombus, presence of McConnell's sign (mid-free wall akinesis but normal apical motion), and estimation of pulmonary artery pressures measured from tricuspid regurgitant jet velocity. RV dilation and dysfunction are associated with poor outcomes in PE accompanied by either normotension or hypotension. In 2005, Gibson et al (Gibson 2005) reported that RV dysfunction occurs in 30-40% of all normotensive patients with acute PE and is a positive predictor for short-term mortality (5%). This finding was also supported by Kucher et al (Kucher 2005) in 2005 who found decreased 30 day survival in patients with RV dysfunction in the setting of normotension (univariate hazard ratio of RV hypokinesis for predicting 30-day mortality of 2.11 (95% CI, 1.41-3.16;  $P < .001$ ). In the setting of hypotension, RV dysfunction is a strong marker of poor outcome. In a retrospective assessment of 180 patients with acute PE, 70 were found to be hemodynamically stable without RV dysfunction, 74 hemodynamically stable with RV dysfunction and 36 hemodynamically unstable with RV dysfunction. The patients with hemodynamic instability and RV dysfunction had the highest mortality (27.8%,  $p < 0.05$ ) and PE related deaths (16.7%,  $p < 0.05$ ) (Yoo 2012). McConnell's sign is a distinct pattern of regional RV dysfunction that may be seen in the setting of acute PE. McConnell's sign is characterized by akinesis of the mid-free wall but normal motion at the apex and is 77% sensitive and 94% specific for the diagnosis of acute PE with a positive predictive value of 71% and a negative predictive value of 96% (McConnell 1996).

## 12.3. Computed tomography pulmonary angiography (CTPA)

CTPA is a sensitive and specific diagnostic tool for PE (Huisman 2013). More recently, it has also been deemed an important study to assess thrombus burden and functions as a valuable indicator of RV decompensation. Thrombus burden can be assessed utilizing a modified Miller score (MMS) in which thrombus load is evaluated by the number of occluded segmental pulmonary arteries (9 on the right, 7 on the left) (Bankier 1997). In a retrospective analysis of 504 consecutive CTPA proven PE, higher MMS correlated with greater right ventricular (RV) to left ventricular (LV) ratio (RV:LV) indicating RV strain (Wong 2012). Furthermore, CTPA findings of high thrombus burden and RV strain are associated with increased PE mortality. In 81 consecutive patients with CTPA proven PE, RV:LV ratio, the shape of the interventricular septum, and the obstruction index were shown to be significant predictors of mortality ( $p < 0.001$ ,  $p = 0.04$ ,  $p < 0.001$  respectively). The negative predictive value for mortality with an RV:LV ratio  $\leq 1.0$  and the obstruction index of  $< 40\%$  were 100% (Chaosuwannakit 2012).

### 13. Biomarkers

D-dimer, troponin I, troponin T, brain natriuretic peptide (BNP) are commonly available biomarkers that are used to evaluate patients with PE. A recent meta-analysis evaluating D-dimer elevation and PE revealed that elevations greater than a defined threshold were associated with significantly increased short-term (3 months) mortality and the degree of pulmonary artery obstruction (Becattini 2012). Elevation in the cardiac biomarker, troponin I, when used in combination with CTPA predicts echocardiographically proven RV dysfunction associated with PE (Meyer 2012). Elevated high-sensitivity troponin T (hsTnT) has also been shown to be associated with poor outcomes in acute PE. hsTnT > 14 pg/ml is a predictor of early death and complications of venous thromboembolic disease. Furthermore, hsTnT, < 14 pg/ml is associated with a low risk of mortality in individuals with PE (Lankeit 2011). Various brain natriuretic peptide assays are available for routine use to assess dyspnea. In a multicenter study including 570 patients with acute PE, ProBNP, BNP, and NT-proBNP values were significantly increased in patients with adverse outcomes after acute pulmonary embolism. However, the prognostic performance of proBNP for predicting adverse outcomes was lower than that of the other natriuretic peptides (Verschuren 2013).

### 14. Management of acute pulmonary embolism

Optimal management of the dyspneic patient includes rapid assessment for etiologies including PE. Complete history, physical examination and use of clinical prediction rules (CPRs) are essential to the initial evaluation. If the index of suspicion for PE is significant, radiologic imaging with CTPA or V/Q is often employed. If these noninvasive tests are inconclusive, pulmonary angiography is occasionally necessary to obtain a definitive diagnosis. Once PE is confirmed, additional risk assessment with hemodynamic assessment, echocardiography, CT determination of RV configuration, ECG, and biomarkers should be performed (Tapson 2008, Tapson 2012). Individual patient characteristics, level of hemodynamic compromise, and risk assessment should be used to determine optimal management. The 2011 Scientific Statement from the American Heart Association defined acute pulmonary thromboembolism as massive, sub-massive or low risk PE using these criteria: 1. Massive PE: Acute PE with sustained hypotension defined as a systolic blood pressure < 90 mmHg for at least 15 minutes or requiring inotropic support without other etiology; 2. Sub-massive PE: Acute PE without systemic hypotension but at risk of poor outcome based on evidence of either RV dysfunction or myocardial necrosis; 3. Low risk PE: Acute PE without the clinical markers defined in massive or submassive PE that portend a poor prognosis (Jaff 2011). (Table 4)

Massive	Sub-massive	Low-Risk
Acute PE with sustained hypotension	Acute PE without systemic hypotension	Low-risk PE
Systolic blood pressure < 90 mm Hg for at least 15 minutes or requiring inotropic support	Systolic blood pressure > 90 mm Hg but with either RV dysfunction or myocardial necrosis	Acute PE and the absence of the clinical markers of adverse prognosis that define massive or submassive PE
Hypotension not due to a cause other than PE	RV dysfunction defined as the presence of at least 1 of the following:	
<ul style="list-style-type: none"><li>•Including but not limited to arrhythmia, hypovolemia, sepsis, or LV dysfunction, pulselessness, or persistent profound bradycardia</li><li>◦Heart rate 40 bpm with signs or symptoms of shock.</li></ul>	<ul style="list-style-type: none"><li>•RV dilation (apical 4-chamber RV diameter divided by LV diameter 0.9) or RV systolic dysfunction on echocardiography</li><li>•RV dilation (4-chamber RV diameter divided by LV diameter 0.9) on CT</li><li>•Elevation of BNP ( 90 pg/mL)</li><li>•Elevation of N-terminal pro-BNP ( 500 pg/mL); or</li><li>•Electrocardiographic changes (new complete or incomplete right bundle-branch block, anteroseptal ST elevation or depression, or anteroseptal T-wave inversion)</li></ul>	
	Myocardial necrosis is defined as either of the following:	
	<ul style="list-style-type: none"><li>•Elevation of troponin I (0.4 ng/mL)</li><li>•Elevation of troponin T ( 0.1 ng/mL)</li></ul>	

**Table 4.** Definitions of massive, submassive and low risk of pulmonary embolism (based on 2011 American Heart Association Scientific Statement)

15. Low risk pulmonary embolism

The mainstay of treatment for low risk PE is prompt initiation of anticoagulation. Importantly, if there is a high clinical suspicion for PE, anticoagulation should be initiated prior to confirmation of the diagnosis (Tapson 2012). The 2012 American College of Chest Physicians Evidence-Based Clinical Practice Guidelines (Kearon 2012) for Venous Thromboembolism

(VTE) recommend parenteral anticoagulants or oral factor Xa inhibition with rivaroxaban as the initial therapy for PE. Low-molecular-weight heparin (LMWH) or fondaparinux is endorsed over IV unfractionated heparin or subcutaneous unfractionated heparin. If there are no contraindications to anticoagulation, treatment is recommended for at least 3 months after acute PE with a more prolonged course when indicated (Kearon 2012).

## 16. Submassive pulmonary embolism

The treatment of submassive PE remains controversial. Patients with submassive PE carry an increased risk of adverse outcomes and early mortality (Piazza 2013); however, there is no clear evidence that thrombolysis in addition to heparin in this subset of patients improves mortality. In 2002, Konstantinides et al (Konstantinides 2002) evaluated 256 patients with submassive PE who were randomly assigned to receive heparin plus alteplase versus heparin plus placebo. Treatment with heparin plus placebo was associated with more frequent clinical deterioration requiring an escalation of treatment (11% versus 25%); however, no change in mortality was detected (Konstantinides 2002). Further study is required to determine appropriate management of this patient population. Currently, comprehensive evaluation weighing risks and benefits of anticoagulation with heparin versus thrombolysis is the usual approach.

## 17. Massive pulmonary embolism

The management of massive PE requires a multifaceted approach to resolve pulmonary vascular obstruction, reverse hemodynamic instability, and support respiratory insufficiency (Tapson 2008). Supportive measures often require volume resuscitation, vasopressors, supplemental oxygen, and occasionally mechanical ventilation (Tapson 2012). Current American College of Chest Physicians (ACCP) (Kearon 2012) and American Heart Association (AHA) (Jaff 2011) guidelines support the use of thrombolytic therapy in patients with acute massive PE and no contraindications. A 2004 meta-analysis revealed that thrombolysis significantly reduced recurrent PE and mortality (9.4% versus 19.0%; OR 0.45, 95% CI 0.22 to 0.92; number needed to treat=10) in patients with hemodynamically unstable PE (Wan 2004). There are limited clinical trial data to provide guidance on the best management of massive PE. A small prospective randomized clinical trial evaluating 8 patients with massive PE showed that streptokinase plus heparin improved hemodynamics within the first hour after treatment and survival at 2 years compared with heparin alone (Jerjes-Sanchez 1995). The heparin treated group had 100% mortality 1-3 hours after initial presentation. Autopsy studies in the heparin treated group revealed massive pulmonary emboli with RV infarction and no coronary artery obstruction (Jerjes-Sanchez 1995). Additional studies are required to determine the optimal management of patients with massive PE.

## 18. Embolectomy

Several interventional techniques including mechanical fragmentation, thrombus aspiration, and direct thrombolytic therapy are currently available for the treatment of acute PE. No clear guidelines can be provided regarding the use of interventional techniques for PE as there are no randomized controlled trials to assess these treatments. ACCP guidelines advise consideration of these interventions in the setting of massive PE with contraindications to systemic thrombolysis, failed thrombolysis, or likelihood of death before thrombolysis (Kearon 2012). Surgical embolectomy is infrequently required for management of acute PE. There are limited data guiding surgical interventions in this setting. Leacche et al (Leacche 2005) reported surgical outcomes in 47 consecutive patients with acute massive PE treated surgically. Indications for surgery included contraindications to thrombolysis (45%), failed medical treatment (10%) and right ventricular dysfunction (32%). Operative mortality and late mortality were 6% and 12% with the majority (83%) of the late mortality related to metastatic cancer. 86% and 83% of patients were alive 1 and 3 years after surgery, respectively (Leacche 2005). Specific instances when surgical intervention may be indicated are the presence of right atrial thrombus, paradoxical arterial embolism, or closure of a patent foramen ovale (Kearon 2012).

## 19. Late consequences of pulmonary embolism

Unresolved pulmonary thromboembolic disease can result in significant morbidity and mortality after acute PE and may lead to chronic thromboembolic pulmonary hypertension (CTEPH). The incidence of this condition is not well-documented. In 2012 Korkmaz et al (Korkmaz 2012) evaluated 325 consecutive patients after acute PE for residual thrombus and CTEPH. Residual chronic thrombus was detected in 48%, 27% and 18% of patients at 3, 6 and 12 months respectively. CTEPH (defined echocardiographically as estimated PAP  $\geq 50$  mmHg) was detected in 4.6% of follow-up echocardiograms. It is unclear if specific interventions at the time of PE could improve the rapidity or extent of thrombus resolution or decrease the likelihood of CTEPH development.

Recently, Kline et al (Kline 2009) reported baseline and 6 month follow-up echocardiography at a single center after acute PE. Elevated pulmonary pressures were defined as an RV systolic pressure (RVSP)  $\geq 40$  mmHg on echocardiogram. 200 normotensive patients with CTPA proven PE were enrolled. 21 received thrombolytic therapy with alteplase because of subsequent hemodynamic destabilization or respiratory failure. 180 (90%) survived to 6 months. 162 returned for a 6 month reevaluation after PE. In the heparin treated group, 35% had elevated pulmonary pressures initially and 7% were elevated at 6 months. 27% had increased estimated RVSP on subsequent echocardiograms. In the alteplase plus heparin group, 61% had elevated pulmonary pressures initially and 11% on follow-up echocardiogram without any increase in RVSP at follow-up (Kline 2009). These data suggest that thrombolytic therapy is associated with better reduction of RVSP than heparin alone; however, more detailed evaluation is necessary.

## 20. Summary

Acute pulmonary thromboembolism is the third most common acute cardiovascular disease (Giuntini 1995) and is associated with significant morbidity and mortality. Thromboembolic obstruction of the pulmonary vasculature frequently causes dyspnea, hypoxia, and chest pain. In severe cases, PE can cause an acute rise in pulmonary pressures precipitating RV dysfunction and hemodynamic instability. The increase in hemodynamic pressures is due to both mechanical obstruction of the pulmonary vascular bed as well as the release of vasoconstricting mediators and derangement of neural regulation of vasomotor tone. Hypotension, RV dysfunction, elevated biomarkers (BNP, troponin I, troponin T) and ECG abnormalities with T-wave inversions are markers of poor prognosis. Rapid evaluation and risk stratification are necessary for effective treatment. Hemodynamically stable PE, i.e. low risk PE, is routinely managed with heparin therapy and clinical monitoring. Hemodynamically unstable PE, i.e. massive PE, is frequently managed with thrombolysis. Optimal management of hemodynamically stable PE with high risk features, i.e. submassive PE, is unclear at this time. Further study to determine best practice in this group is ongoing. Unfortunately, acute PE has both short-term and long-term consequences. Additional evaluation and characterization of patients at risk to develop long term complications of pulmonary emboli are needed.

## Author details

Jean M. Elwing<sup>1,2\*</sup> and Ralph J. Panos<sup>1,2</sup>

\*Address all correspondence to: [jean.elwing@uc.edu](mailto:jean.elwing@uc.edu)

1 Pulmonary, Critical Care, and Sleep Medicine Division, Cincinnati Veterans Affairs Medical Center, Cincinnati, USA

2 Pulmonary, Critical Care, and Sleep Medicine Division, University of Cincinnati College of Medicine, Cincinnati, USA

## References

- [1] Adam SS, Key NS, Greenberg CS. D-dimer antigen: current concepts and future prospects. *Blood*. 2009 Mar 26;113(13):2878-87.
- [2] Anderson DR, Kahn SR, Rodger MA, Kovacs MJ, Morris T, Hirsch A, Lang E, Stiell I, Kovacs G, Dreyer J, Dennie C, Cartier Y, Barnes D, Burton E, Pleasance S, Skedgel C, O'Rourke K, Wells PS. Computed tomographic pulmonary angiography vs ventilation-perfusion lung scanning in patients with suspected pulmonary embolism: a randomized controlled trial. *JAMA*. 2007 Dec 19;298(23):2743-53.

- [3] Bahia A, Albert RK. The modified Wells score accurately excludes pulmonary embolus in hospitalized patients receiving heparin prophylaxis. *J Hosp Med*. 2011 Apr; 6(4):190-4.
- [4] Bankier AA, Janata K, Fleischmann D, Kreuzer S, Mallek R, Frossard M, Domanovits H, Herold CJ. Severity assessment of acute pulmonary embolism with spiral CT: evaluation of two modified angiographic scores and comparison with clinical data. *J Thorac Imaging*. 1997 Apr; 12(2):150-8.
- [5] Battistini B. Modulation and roles of the endothelins in the pathophysiology of pulmonary embolism. *Can J Physiol Pharmacol*. 2003 Jun; 81(6):555-569.
- [6] Becattini C, Lignani A, Masotti L, Forte MB, Agnelli G. D-dimer for risk stratification in patients with acute pulmonary embolism. *J Thromb Thrombolysis*. 2012 Jan; 33(1): 48-57.
- [7] Begieneman MP, van de Goot FR, van dB I, Noordegraaf AV, Spreeuwenberg MD, Paulus WJ, et al. Pulmonary embolism causes endomyocarditis in the human heart. *Heart* 2008; 94:450-456.
- [8] Breuer J, Meshcig R, Breuer HWM, Arnold G. Effects of serotonin on the cardiopulmonary circulatory system with and without 5-HT<sub>2</sub>-receptor blockade by ketanserin. *J Cardiovasc Pharmacol* 1985; 7(suppl.7):S64-S66.
- [9] Calvo-Romero JM, Lima-Rodríguez EM, Bureo-Dacal P, Páez-Miranda M. Predictors of an intermediate ventilation/perfusion lung scan in patients with suspected acute pulmonary embolism. *Eur J Emerg Med*. 2005 Jun; 12(3): 129-31.
- [10] Ceriani E, Combescure C, Le Gal G, Nendaz M, Perneger T, Bounameaux H, Perrier A, Righini M. Clinical prediction rules for pulmonary embolism: a systematic review and meta-analysis. *J Thromb Haemost*. 2010 May; 8(5):957-70.
- [11] Chaosuwannakit N, Makarawate P. Prognostic value of right ventricular dysfunction and pulmonary obstruction index by computed tomographic pulmonary angiography in patients with acute pulmonary embolism. *J Med Assoc Thai*. 2012 Nov; 95(11): 1457-65.
- [12] Cutforth RH, Oram S. The electrocardiogram in pulmonary embolism. *Br Heart J*. 1958 Jan; 20(1):41-60.
- [13] Douma RA, Kamphuisen PW, Büller HR. Acute pulmonary embolism. Part 1: epidemiology and diagnosis. *Nat Rev Cardiol*. 2010 Oct; 7(10):585-596.
- [14] Ferrari E, Imbert A, Chevalier T, Mihoubi A, Morand P, Baudouy M. The ECG in pulmonary embolism. Predictive value of negative T waves in precordial leads--80 case reports. *Chest*. 1997 Mar; 111(3):537-43.

- [15] Gibson NS, Sohne M, Buller HR. Prognostic value of echocardiography and spiral computed tomography in patients with pulmonary embolism. *Curr Opin Pulm Med*. 2005 Sep;11(5):380-4.
- [16] Giuntini C, Di Ricco G, Marini C, Melillo E, Palla A. Pulmonary embolism: epidemiology. *Chest*. 1995 Jan; 107(1 Suppl):3S-9S.
- [17] Goldhaber SZ, Visani L, De Rosa M. Acute pulmonary embolism: clinical outcomes in the International Cooperative Pulmonary Embolism Registry (ICOPER). *Lancet* 1999; 353:1386-9.
- [18] Goldhaber SZ. Echocardiography in the management of pulmonary embolism. *Ann Intern Med*. 2002; 136(9):691-700.
- [19] Gottschalk A, Stein PD, Sostman HD, Matta F, Beemath A. Very low probability interpretation of V/Q lung scans in combination with low probability objective clinical assessment reliably excludes pulmonary embolism: data from PIOPED II. *J Nucl Med*. 2007 Sep; 48(9):1411-5.
- [20] Gurewich V, Cohen ML, Thomas DP. Humoral factors in massive pulmonary embolism: an experimental study. *Am Heart J* 1968; 76:784-794.
- [21] Hogg K, Brown G, Dunning J, Wright J, Carley S, Foex B, Mackway-Jones K. Diagnosis of pulmonary embolism with CT pulmonary angiography: a systematic review. *Emerg Med J*. 2006 Mar;23(3):172-8.
- [22] Huisman MV, Klok FA. How I diagnose acute pulmonary embolism. *Blood*. 2013; 121(22):4443-4448.
- [23] Jaff MR, McMurry MS, Archer SL, Cushman M, Goldenberg N, Goldhaber SZ, Jenkins JS, Kline JA, Michaels AD, Thistlethwaite P, Vedantham S, White RJ, Zierler BK, American Heart Association Council on Cardiopulmonary, Critical Care, Perioperative and Resuscitation, American Heart Association Council on Peripheral Vascular Disease, American Heart Association Council on Arteriosclerosis, Thrombosis and Vascular Biology. Management of massive and submassive pulmonary embolism, iliofemoral deep vein thrombosis, and chronic thromboembolic pulmonary hypertension: a scientific statement from the American Heart Association. *Circulation*. 2011 Apr 26; 123(16):1788-830.
- [24] Jerjes-Sanchez C, Ramírez-Rivera A, de Lourdes García M, Arriaga-Nava R, Valencia S, Rosado-Buzzo A, Pierzo JA, Rosas E. Streptokinase and Heparin versus Heparin Alone in Massive Pulmonary Embolism: A Randomized Controlled Trial. *J Thromb Thrombolysis*. 1995; 2(3):227-229.
- [25] Jones AE, Watts JA, Debelak JP, Thornton LR, Younger JG, Kline JA. Inhibition of prostaglandin synthesis during polystyrene microsphere-induced pulmonary embolism in the rat. *Am J Physiol Lung Cell Molec Physiol* 2003; 284:L1072-1081.
- [26] Kang DK, Thilo C, Schoepf UJ, Barraza JM Jr, Nance JW Jr, Bastarrika G, Abro JA, Ravenel JG, Costello P, Goldhaber SZ. CT signs of right ventricular dysfunction:

- prognostic role in acute pulmonary embolism. *JACC Cardiovasc Imaging*. 2011; 4(8): 841-9.
- [27] Kapsch DN, Metzler M, Silver D. Contributions of prostaglandin F<sub>2</sub>alpha and thromboxane A<sub>2</sub> to the acute cardiopulmonary changes of pulmonary embolism. *J Surg Res* 1981; 30:522-529.
  - [28] Kasper W , Konstantinides S , Geibel A , Tiede N , Krause T , Just H . Prognostic significance of right ventricular afterload stress detected by echocardiography in patients with clinically suspected pulmonary embolism. *Heart*. 1997; 77(4):346-349 .
  - [29] Kearon C, Akl EA, Comerota AJ, Prandoni P, Bounameaux H, Goldhaber SZ, Nelson ME, Wells PS, Gould MK, Dentali F, Crowther M, Kahn SR, American College of Chest Physicians. Antithrombotic therapy for VTE disease: Antithrombotic Therapy and Prevention of Thrombosis, 9th ed: American College of Chest Physicians Evidence-Based Clinical Practice Guidelines. *Chest*. 2012 Feb; 141(2 Suppl):e419S-94S.
  - [30] Kline JA, Marchick MR, Hogg MM. Reduction in plasma haptoglobin in humans with acute pulmonary embolism causing tricuspid regurgitation. *J Thromb Haemostasis* 2009; 7:1597-9.
  - [31] Kline JA, Steuerwald MT, Marchick MR, Hernandez-Nino J, Rose GA. Prospective evaluation of right ventricular function and functional status 6 months after acute submassive pulmonary embolism: frequency of persistent or subsequent elevation in estimated pulmonary artery pressure. *Chest*. 2009 Nov; 136(5):1202-10.
  - [32] Klok FA, Mos IC, Kroft LJ, de Roos A, Huisman MV. Computed tomography pulmonary angiography as a single imaging test to rule out pulmonary embolism. *Curr Opin Pulm Med*. 2011; 17(5):380-6.
  - [33] Klok FA, S Romeih, LJM. Kroft, JJMWestenberg, MV Huisman, A de Roos Recovery of right and left ventricular function after acute pulmonary embolism *Clinical Radiology* 2011; 66: 1203-1207.
  - [34] Konstam MA, Hill NS, Bonin JD, Isner JM. Prostaglandin mediation of hemodynamic responses to pulmonary microembolism in rabbits: effects of ibuprofen and meclofenamate. *Exp Lung Res* 1987; 12:331-345.
  - [35] Konstantinides S, Geibel A, Heusel G, Heinrich F, Kasper W, Management Strategies and Prognosis of Pulmonary Embolism-3 Trial Investigators. Heparin plus alteplase compared with heparin alone in patients with submassive pulmonary embolism. *N Engl J Med*. 2002 Oct 10; 347(15):1143-50.
  - [36] Korkmaz A, Ozlu T, Ozsu S, Kazaz Z, Bulbul Y. Long-term outcomes in acute pulmonary thromboembolism: the incidence of chronic thromboembolic pulmonary hypertension and associated risk factors. *Clin Appl Thromb Hemost*. 2012 Jun; 18(3):281-8

- [37] Kucher N, Rossi E, De Rosa M, Goldhaber SZ. Prognostic role of echocardiography among patients with acute pulmonary embolism and a systolic arterial pressure of 90 mm Hg or higher. *Arch Intern Med*. 2005; Aug 8-22; 165(15):1777-1781.
- [38] Lankeit M, Jiménez D, Kostrubiec M, Dellas C, Hasenfuss G, Pruszczyk P, Konstantinides S. Predictive value of the high-sensitivity troponin T assay and the simplified Pulmonary Embolism Severity Index in hemodynamically stable patients with acute pulmonary embolism: a prospective validation study. *Circulation*. 2011 Dec 13; 124(24):2716-24.
- [39] LeGal G, Righini M, Roy PM, et al. Prediction of pulmonary embolism in the emergency department: the revised Geneva score. *Ann Intern Med* 2006; 144: 165–71.
- [40] Leacche M, Unic D, Goldhaber SZ, Rawn JD, Aranki SF, Couper GS, Mihaljevic T, Rizzo RJ, Cohn LH, Aklog L, Byrne JG. Modern surgical treatment of massive pulmonary embolism: results in 47 consecutive patients after rapid diagnosis and aggressive surgical approach. *J Thorac Cardiovasc Surg*. 2005 May; 129(5):1018-23.
- [41] Lin BW, Schreiber DH, Liu G, Briese B, Hiestand B, Slattery D, Kline JA, Goldhaber SZ, Pollack CV Jr. Therapy and outcomes in massive pulmonary embolism from the Emergency Medicine Pulmonary Embolism in the Real World Registry. *Am J Emerg Med*. 2012; 30(9):1774-1781.
- [42] McConnell MV, Solomon SD, Rayan ME, Come PC, Goldhaber SZ, Lee RT. Regional right ventricular dysfunction detected by echocardiography in acute pulmonary embolism. *Am J Cardiol*. 1996 Aug 15; 78(4):469-73.
- [43] Meyer G, Roy PM, Sors H, Sanchez O. Laboratory tests in the diagnosis of pulmonary embolism. *Respiration*. 2003; 70(2):125-32.
- [44] Meyer M, Fink C, Roeger S, Apfalter P, Haghi D, Kaminski WE, Neumaier M, Schoenberg SO, Henzler T. Benefit of combining quantitative cardiac CT parameters with troponin I for predicting right ventricular dysfunction and adverse clinical events in patients with acute pulmonary embolism. *Eur J Radiol*. 2012 Nov; 81(11): 3294-9.
- [45] Miczoch J, Tucker A, Weir EK, Reeves JT, Grover RF. Platelet mediated pulmonary hypertension and hypoxia during pulmonary microembolism. Reduction by platelet inhibition. *Chest* 1978; 74:648–653.
- [46] Mitchell AM, Jones AE, Tumlin JA, Kline JA. Prospective study of the incidence of contrast induced nephropathy among patients evaluated for pulmonary embolism by contrast-enhanced computed tomography. *Acad Emerg Med*. 2012; 19(6):618-25.
- [47] Mos IC, Klok FA, Kroft LJ, de Roos A, Huisman MV. Imaging tests in the diagnosis of pulmonary embolism. *Semin Respir Crit Care Med*. 2012; 33(2):138-43

- [48] Nijkeuter M, Söhne M, Tick LW, et al; Christopher Study Investigators. The natural course of hemodynamically stable pulmonary embolism: clinical outcome and risk factors in a large prospective cohort study. *Chest*. 2007; 131(2):517-523.
- [49] Oudkerk M, van Beek EJ, Wielopolski P, van Ooijen PM, Brouwers-Kuyper EM, Bongaerts AH, Berghout A. Comparison of contrast-enhanced magnetic resonance angiography and conventional pulmonary angiography for the diagnosis of pulmonary embolism: a prospective study. *Lancet*. 2002 May 11; 359(9318):1643-7.
- [50] Ouellette DW, Patocka C. Pulmonary embolism. *Emerg Med Clin North Am*. 2012 May; 30(2):329-75.
- [51] Panos RJ, Barish RA, Whye DW Jr, Groleau G. The electrocardiographic manifestations of pulmonary embolism. *J Emerg Med*. 1988 Jul-Aug; 6(4):301-7.
- [52] Piazza G, Goldhaber SZ. The acutely decompensated right ventricle: pathways for diagnosis and management. *Chest*. 2005 Sep; 128(3):1836-1852.
- [53] Piazza G. Submassive pulmonary embolism. *JAMA*. 2013 Jan 9; 309(2):171-80.
- [54] PIOPED. Value of the ventilation/perfusion scan in acute pulmonary embolism. Results of the prospective investigation of pulmonary embolism diagnosis (PIOPED). The PIOPED Investigators. *JAMA*. 1990 May 23-30; 263(20):2753-9.
- [55] Pruszyk P, Bochowicz A, Torbicki A, Szulc M, Kurzyna M, Fijalkowska A, Kuch-Wocial A. Cardiac troponin T monitoring identifies high-risk group of normotensive patients with acute pulmonary embolism. *Chest* 2003; 123(6):1947-1952.
- [56] Qanadli SD, El Hajjam M, Vieillard-Baron A, Joseph T, Mesurolle B, Oliva VL, Barré O, Bruckert F, Dubourg O, Lacombe P. New CT index to quantify arterial obstruction in pulmonary embolism: comparison with angiographic index and echocardiography. *AJR Am J Roentgenol*. 2001 Jun; 176(6):1415-1420.
- [57] Rathbun SW, Raskob GE, Whitsett TL. Sensitivity and specificity of helical computed tomography in the diagnosis of pulmonary embolism: a systematic review. *Ann Intern Med*. 2000 Feb 1; 132(3):227-32.
- [58] Rathbun SW, Whitsett TL, Raskob GE. Negative D-dimer result to exclude recurrent deep venous thrombosis: a management trial. *Ann Intern Med*. 2004 Dec 7; 141(11): 839-45.
- [59] Rathbun SW, Whitsett TL, Vesely SK, Raskob GE. Clinical utility of D-dimer in patients with suspected pulmonary embolism and nondiagnostic lung scans or negative CT findings. *Chest*. 2004 Mar; 125(3):851-5.
- [60] Reeves WC, Demers LM, Wood MA et al. The release of 168. thromboxane A and prostacyclin following experimental acute Pulmonary microembolism: attenuated pulmonary vasoconstriction with prostaglandin inhibitors and antihistamines. *Prostaglandins* 1976; 11:31– 41.

- [61] Reeves WC, Demers LM, Wood MA, Skarlatos S, Copenhaver G, Whitesell L, et al. The release of thromboxane A<sub>2</sub> and prostacyclin following experimental acute pulmonary embolism. *Prostaglandin Leukotrienes Med* 1983; 11:1-10.
- [62] Remy-Jardin M, Pistolesi M, Goodman LR, et al. Management of suspected acute pulmonary embolism in the era of CT angiography: a statement from the Fleischner Society. *Radiology* 2007; 245(2):315-329
- [63] Remy-Jardin M, Pistolesi M, Goodman LR, Geftter WB, Gottschalk A, Mayo JR, Sostman HD. Management of suspected acute pulmonary embolism in the era of CT angiography: a statement from the Fleischner Society. *Radiology*. 2007 Nov; 245(2): 315-29.
- [64] Ribeiro A, Lindmarker P, Johnsson H, et al. Pulmonary embolism: one year follow-up with echocardiography Doppler and five-year survival analysis. *Circulation* 1999; 99:1325-1330.
- [65] Rodger M, Makropoulos D, Turek M, Quevillon J, Raymond F, Rasuli P, Wells PS. Diagnostic value of the electrocardiogram in suspected pulmonary embolism. *Am J Cardiol*. 2000 Oct 1; 86(7):807-9.
- [66] Rodger MA, Carrier M, Jones GN, Rasuli P, Raymond F, Djunaedi H, Wells PS: Diagnostic value of arterial blood gas measurement in suspected pulmonary embolism. *Am J Respir Crit Care Med* 2000; 162:2105-2108.
- [67] Rosoff CB, Salzman EW, Gurewich V. Reduction of platelet serotonin and the response to pulmonary emboli. *Surgery* 1971; 70:12-19.
- [68] Sabiston DC, Wagner HN. The pathophysiology of pulmonary embolism: relationships to accurate diagnosis and choice of therapy. *J Thorac Cardiovasc Surg*. 1965 Sep; 50:339-56.
- [69] Samama MM. Pulmonary embolism: controversies in laboratory studies. *Pathophysiol Haemost Thromb*. 2006; 35(1-2):157-161.
- [70] Sanchez, O., Trinquart, L., Caille, V., Couturaud, F., Pacouret, G., Meneveau, N., Verschuren, F., Roy, P.M., Parent, F., Righini, M., Perrier, A., Lorut, C., Tardy, B., Benoit, M.O., Chatellier, G., Meyer, G. Prognostic factors for pulmonary embolism: the PREP study, a prospective multicenter cohort study. *American Journal of Respiratory and Critical Care Medicine*, 2010; 181:168-173.
- [71] Sanchez, O., Trinquart, L., Colombet, I., Durieux, P., Huisman, M.V., Chatellier, G. & Meyer, G. Prognostic value of right ventricular dysfunction in patients with haemodynamically stable pulmonary embolism: a systematic review. *European Heart Journal*, 2008; 29:1569-1577.
- [72] Schoepf UJ, Kucher N, Kipfmüller F, Quiroz R, Costello P, Goldhaber SZ. Right ventricular enlargement on chest computed tomography: a predictor of early death in acute pulmonary embolism. *Circulation*. 2004; 110 (20): 3276-3280.

- [73] Smulders YM. Pathophysiology and treatment of haemodynamic instability in acute pulmonary, embolism: the pivotal role of pulmonary vasoconstriction. *Cardiovasc Res.* 2000 Oct; 48(1):23-33.
- [74] Stein PD, Athanasoulis C, Alavi A, Greenspan RH, Hales CA, Saltzman HA, Vreim CE, Terrin ML, Weg JG. Complications and validity of pulmonary angiography in acute pulmonary embolism. *Circulation.* 1992 Feb; 85(2):462-8.
- [75] Stein PD, Dalen JE, McIntyre KM, Sasahara AA, Wenger NK, Willis PW 3rd. The electrocardiogram in acute pulmonary embolism. *Prog Cardiovasc Dis.* 1975 Jan-Feb; 17(4):247-57.
- [76] Stein PD, Fowler SE, Goodman LR, Gottschalk A, Hales CA, Hull RD, Leeper KV Jr, Popovich J Jr, Quinn DA, Sos TA, Sostman HD, Tapson VF, Wakefield TW, Weg JG, Woodard PK; PIOPED II Investigators. Multidetector computed tomography for acute pulmonary embolism. *N Engl J Med.* 2006 Jun 1; 354(22):2317-27.
- [77] Stein PD, Hull RD, Ghali WA, Patel KC, Olson RE, Meyers FA, Kalra NK. Tracking the uptake of evidence: two decades of hospital practice trends for diagnosing deep vein thrombosis and pulmonary embolism. *Arch Intern Med.* 2003; 163: 1213–1219.
- [78] Stein PD, Hull RD, Patel KC, Olson RE, Ghali WA, Brant R, Biel RK, Bharadia V, Kalra NK. D-dimer for the exclusion of acute venous thrombosis and pulmonary embolism: a systematic review. *Ann Intern Med.* 2004 Apr 20; 140(8):589-602.
- [79] Stein PD, Matta F, Musani M, et al. Silent pulmonary embolism in patients with deep venous thrombosis: a systematic review. *Am J Med* 2010; 123:426-431.
- [80] Stein PD, Matta F. Acute pulmonary embolism. *Curr Probl Cardiol.* 2010 Jul; 35(7): 314-76. Giuntini C, DiRicco G, Marini C, Melillo E, Palla A. Pulmonary embolism: epidemiology. *Chest* 1995; 107(suppl):3S-9S.
- [81] Stein PD, Woodard PK, Weg JG, Wakefield TW, Tapson VF, Sostman HD, Sos TA, Quinn DA, Leeper KV Jr, Hull RD, Hales CA, Gottschalk A, Goodman LR, Fowler SE, Buckley JD; PIOPED II investigators. Diagnostic pathways in acute pulmonary embolism: recommendations of the PIOPED II investigators. *Am J Med.* 2006 Dec; 119(12):1048-55.
- [82] Stein PD, Woodard PK, Weg JG, Wakefield TW, Tapson VF, Sostman HD, Sos TA, Quinn DA, Leeper KV Jr, Hull RD, Hales CA, Gottschalk A, Goodman LR, Fowler SE, Buckley JD; PIOPED II Investigators. Diagnostic pathways in acute pulmonary embolism: recommendations of the PIOPED II Investigators. *Radiology.* 2007 Jan; 242(1):15-21.
- [83] Stevinson BG, Hernandez-Nino J, Rose G, et al. Echocardiographic and functional cardiopulmonary problems 6 months after first-time pulmonary embolism in previously healthy patients. *Eur Heart J* 2007; 28:2517-24.

- [84] Stratmann G, Gregory GA. Neurogenic and humoral vasoconstriction in acute pulmonary thromboembolism. *Anesth Analg*. 2003 Aug; 97(2):341-54.
- [85] Tapson VF. Acute pulmonary embolism. *N Engl J Med*. 2008 Mar 6; 358(10):1037-52.
- [86] Tapson VF. Advances in the diagnosis and treatment of acute pulmonary embolism. *F1000 Med Rep*. 2012; 4:9.
- [87] Tapson VF. Pulmonary embolism--new diagnostic approaches. *N Engl J Med*. 1997 May 15; 336(20):1449-51.
- [88] Thompson JA, Millen JE, Glauser FL, Hess ML. Role of 5-HT<sub>2</sub> receptor inhibition in pulmonary embolization. *Circ Shock* 1986; 20:299-309.
- [89] Todd MH, Forrest JB, Cragg DB. The effects of aspirin and methysergide, singly and in combination, on systemic haemodynamic responses to pulmonary embolism. *Can Anaesth Soc J* 1981; 28:373-380.
- [90] Todd MH, Forrest JB, Cragg DBJ. The effects of aspirin and methysergide on responses to clot induced pulmonary embolism. *Am Heart J* 1983; 105:769-776.
- [91] van Beek EJ, Brouwerst EM, Song B, Stein PD, Oudkerk M. Clinical validity of a normal pulmonary angiogram in patients with suspected pulmonary embolism—a critical review. *Clin Radiol*. 2001 Oct; 56(10):838-42.
- [92] van der Bijl N, Klok FA, Huisman MV, van Rooden JK, Mertens BJ, de Roos A, Kroft LJ. Measurement of right and left ventricular function by ECG-synchronized CT scanning in patients with acute pulmonary embolism: usefulness for predicting short-term outcome. *Chest*. 2011 Oct; 140(4):1008-15.
- [93] Van Strijen MJ, De Monye W, Kieft GJ, Pattynama PM, Prins MH, Huisman MV. Accuracy of single-detector spiral CT in the diagnosis of pulmonary embolism: a prospective multicenter cohort study of consecutive patients with abnormal perfusion scintigraphy. *J Thromb Haemost*. 2005 Jan; 3(1):17-25. Erratum in: *J Thromb Haemost*. 2005 Mar; 3(3):622.
- [94] Verschuren F, Bonnet M, Benoit MO, Gruson D, Zech F, Couturaud F, Meneveau N, Roy PM, Righini M, Meyer G, et al. The prognostic value of pro-B-Type natriuretic peptide in acute pulmonary embolism. *Thromb Res*. 2013 Apr 4. [Epub ahead of print]
- [95] Wagenvort CA. Pathology of pulmonary thromboembolism. *Chst* 1995; 107(1 Suppl): 10S-17S.
- [96] Wan S, Quinlan DJ, Agnelli G, Eikelboom JW. Thrombolysis compared with heparin for the initial treatment of pulmonary embolism: a meta-analysis of the randomized controlled trials. *Circulation*. 2004 Aug 10; 110(6):744-9.

- [97] Watts JA, Gellar MA, Obraztsova M, Kline JA, Zagorski J. Role of inflammation in right ventricular damage and repair following experimental pulmonary embolism in rats. *Int J Exp Pathol* 2008; 89:389-399.
- [98] Weidner WJ. Effects of indomethacin on pulmonary hemodynamics and extravascular lung water in sheep after pulmonary microembolism. *Prostagl Med* 1979; 3:71-80.
- [99] Wells PS, Anderson DR, Rodger M, et al. Derivation of a simple clinical model to categorize patients probability of pulmonary embolism: increasing the models utility with the SimpliRED D dimer. *Thromb Haemost* 2000; 83: 416-20.
- [100] Wells PS, Anderson DR, Rodger M, Ginsberg JS, Kearon C, Gent M, Turpie AG, Bormanis J, Weitz J, Chamberlain M, Bowie D, Barnes D, Hirsh J. Derivation of a simple clinical model to categorize patients probability of pulmonary embolism: increasing the models utility with the SimpliRED D-dimer. *Thromb Haemost*. 2000 Mar; 83(3): 416-20.
- [101] Wells PS, Anderson DR, Rodger M, Stiell I, Dreyer JF, Barnes D, Forgie M, Kovacs G, Ward J, Kovacs MJ. Excluding pulmonary embolism at the bedside without diagnostic imaging: management of patients with suspected pulmonary embolism presenting to the emergency department by using a simple clinical model and d-dimer. *Ann Intern Med*. 2001 Jul 17; 135(2):98-107.
- [102] Wells PS, Ginsberg JS, Anderson DR, Kearon C, Gent M, Turpie AG, Bormanis J, Weitz J, Chamberlain M, Bowie D, Barnes D, Hirsh J. Use of a clinical model for safe management of patients with suspected pulmonary embolism. *Ann Intern Med*. 1998 Dec 15; 129(12):997-1005.
- [103] Wolfe MW, Lee RT, Feldstein ML, Parker JA, Come PC, Goldhaber SZ. Prognostic significance of right ventricular hypokinesis and perfusion lung scan defects in pulmonary embolism. *Am Heart J*. 1994; 127:1371-5.
- [104] Wong LF, Akram AR, McGurk S, Van Beek EJ, Reid JH, Murchison JT. Thrombus load and acute right ventricular failure in pulmonary embolism: correlation and demonstration of a "tipping point" on CT pulmonary angiography. *Br J Radiol*. 2012 Nov; 85(1019):1471-6.
- [105] Wood KE. Major pulmonary embolism: review of a pathophysiologic approach to the golden hour of hemodynamically significant pulmonary embolism. *Chest*. 2002; 121(3):87-905.
- [106] Yoo JW, Hong SB, Lim CM, Koh Y. Clinical implications of right ventricular dysfunction in patients with acute symptomatic pulmonary embolism: short- and long-term clinical outcomes. *J Crit Care*. 2012 Jun; 27(3):325.e1-6.