

We are IntechOpen, the world's leading publisher of Open Access books Built by scientists, for scientists

6,900

Open access books available

185,000

International authors and editors

200M

Downloads

Our authors are among the

154

Countries delivered to

TOP 1%

most cited scientists

12.2%

Contributors from top 500 universities



WEB OF SCIENCE™

Selection of our books indexed in the Book Citation Index
in Web of Science™ Core Collection (BKCI)

Interested in publishing with us?
Contact book.department@intechopen.com

Numbers displayed above are based on latest data collected.
For more information visit www.intechopen.com



Surgical Treatment

Giuliano Cerulli, Enrico Sebastiani, Giacomo Placella,
Matteo Maria Tei, Andrea Speziali and
Pierluigi Antinolfi

Additional information is available at the end of the chapter

<http://dx.doi.org/10.5772/56736>

1. Introduction

Muscular tissue has a good ability to regenerate that promotes the healing of lesions also extended, caused by strains, contusions and muscle lacerations. This characteristic is guaranteed by myogenic precursor cells (satellite cells) that proliferate and fill the structure of the extracellular matrix produced by fibroblasts becoming myoblasts.

Several factors make difficult the healing of the lesion: hematoma, granulation tissue, scar tissue and lesions of nerve bundles. In '84 Garret et al. [1] have shown that the tissue recovery was obstructed by a large percentage of denervated myocytes distal to the lesion.

A well-executed suture could allow early rehabilitation with a lower risk of re-rupture and stitch pullout. The main problem is figuring out which is the best surgical technique, but especially when a surgical repair is necessary and if the benefits outweigh the disadvantages.

In the choice of surgical technique are many points still debated. The surgical indication is very limited and, in most of the muscle injury, conservative treatment is certainly indicated. Location and extent of the lesion are the criteria most examined in the literature.

Some of the few in vivo studies on animals have shown that a surgical suture of the wound can accelerate healing. The myorrhaphy prevents the formation of excess scar tissue, limits the hematoma formation, decreases the infiltration of mononuclear cells, increases the number of regenerating myofibers, decreases the inflammatory response favoring the healing.

For example, lesions of the pectoralis major muscle have wider surgical indication and conservative treatment is recommended only in cases of injury at the sternoclavicular origin, in some partial tears, in older or sedentary individuals.

Some authors tend to wide the indication for surgical treatment to lesions greater than 50% of the thickness of the muscle belly and the debate is still open because of the few tests to date available, but certainly the indication is strengthened by the absence of synergistic muscles that can decrease the workload to the muscle and therefore aid healing.

The aim of this chapter is to perform a review of the literature in order to identify the muscle injury which indicate surgical treatment and its results.

2. Muscle healing

Muscle injuries are debilitating injuries, especially for athletes who risk setbacks in their career. A subcutaneous muscle tear can be caused by direct trauma, such as a contusion from a blunt object or strains, or by indirect trauma such as ischemia or a neurological dysfunction [2]. In any case these injuries are difficult to treat and unfortunately there are no clear and defined guidelines to help the physician [3].

From a biological point of view muscles have been shown to be particularly active and capable of excellent tissue regeneration. The gap between the muscle fibers is filled thanks to the myocyte cell reactivity, the presence of replicative phase cells and the production of connective tissue scar.

The healing process of muscle injury consists of three phases: the degeneration-inflammation phase, the reparative phase and the remodeling-fibrosis phase (Figure 1).

The first phase (first few days post-injury) is characterized by inflammatory stimulation caused by the cellular debris and the pro-inflammatory molecules that are released as a result of necrosis of the injured tissue; also the severed blood vessels release blood within the tissue forming hematoma, which in turn stimulates the inflammatory response. This cascade of events results in the release of cytokines, interleukins, adhesion molecules (e.g., P-selectin, L-selectin, E-selectin), Tumor Necrosis Factor alpha and growth factors (e.g. insulin-like growth factor 1 IGF-1, hepatocyte growth factor HGF, EGF, epidermal growth factor, transforming growth factor alpha and TGF beta, platelet-derived growth factor PDGF) that promote inflammation, cell migration and stimulate progress to the next stage [2 - 3]

The reparation phase (from day 7-10 to week three-four post-injury) begins with the cleaning of the tissue formed in the acute phase by macrophages that engulf the injured tissue and allow the regeneration of tissue within the lesion: it stimulates the proliferation of striated muscle tissue, the neo-angiogenesis within the neo-tissue and stimulates the production of connective scar tissue. The cells that are more active from the point of view of replication (myogenic precursor cells, or satellite cells) are located between the basal lamina and the plasma membranes of each individual myofiber; once they are released by the lesion of the basal lamina and activated by growth factors, they differentiate into myoblast and replicate forming multinucleated myotubes and possibly myofibers.

The final phase, the remodeling-fibrosis, involves the maturation of the neo-muscle tissue and the reorganization of the scar tissue, and is strongly driven by mechanical stress and the stress

of the surrounding tissue that drive the neo-tissue to organize in the most functional way possible for contraction. The connective tissue produced is partly demolished, gradually leaving more space for the connections between the myofibers [4].

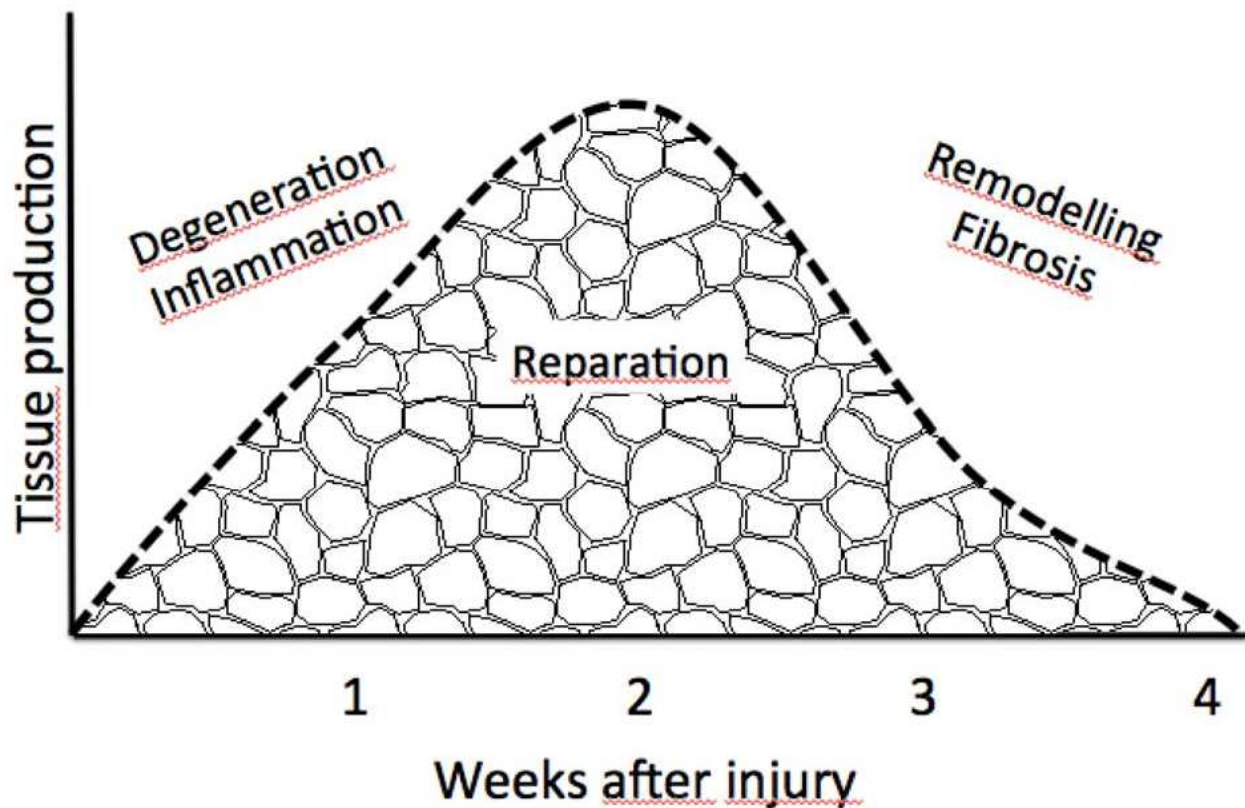


Figure 1. The diagram summarizes the three phases of muscle laceration healing. Note that reparation has a peak around the second week and concludes by the third- fourth week [2].

Fibroblasts that colonize the lesion and produce extracellular matrix play a key role in lesion healing. The connective tissue that is formed fills the gap created by the lesion with a three-dimensional plot that not only guides the proliferation of muscle cells and blood, but allows the transmission and the distribution of mechanical stresses thus acting as a sort of brace and allowing the functional use of the muscle before the lesion is completely healed. It was observed that animal muscles, thanks to this connective tissue, already after 14 days the scar that had formed in complete tears was mechanically more resistant than the surrounding muscle [4]. It should be kept in mind that in human tissue healing times are longer and recovery is less complete but the sequence and function of the repair steps are the same [5].

This scar tissue is extremely important but it can also be an obstacle to proper healing: in fact, if there is too much of it, instead of promoting, it may prevent tissue proliferation leading to incomplete recovery [3]. A proper healing of muscle tissue is centered on the correct balance between fibroblastic proliferation and myoblast proliferation: the first promote the connective

tissue that must act as a scaffold for the repopulation of the lesion by the myoblasts. When the lesion is too large, however, the gap between the proximal and the distal stump is filled with granulation tissue which results in connective tissue scar [6, 7] leaving little room for myoblast proliferation. It is possible that in the final phase (remodeling) structural improvements of the scar may occur but they are only minor [5].

The healing of the lesion depends not only on cell reactivity and the amount of scar tissue, but is closely linked to many other factors. The innervation of the tissue remaining promotes tissue viability: an excessive presence of denervated myocytes downstream of the lesion impairs proper healing [1]. Other aspects to be considered are the supply of oxygen from the surrounding tissue, the vascular proliferation and neo-angiogenesis within the lesion in the post-trauma stage, the percentage and the pattern with which the myoblasts go to form the myotubes and the collagen crosslinking [8].

3. Indication for surgery

Unfortunately very few studies are available in literature that scientifically demonstrate the benefits of one treatment rather than another.

Traditionally muscle injuries are treated conservatively and surgery is frowned upon by many surgeons for this type of lesions of the musculoskeletal system. It is common belief that surgical treatment gives results similar to, or even worse than conservative treatment [9]. Therefore it is not recommended for the fear of causing damage which would lead to further complications. The presence of hematoma and a palpable gap in the muscle belly make surgical suture difficult to perform because it is often impossible to get the fascial ends to close and the muscle fibers are hard to draw back together [5].

However, animal studies have shown that surgically sutured muscle heals more quickly and more functionally. The suture in fact decreases the distance between the muscle stumps allowing a more rapid recovery [10], decreasing major defects in scarring [11], improved healing and a decrease in deep superabundant scar tissue [3].

Obviously, surgery can lead to numerous, although fortunately infrequent, complications; therefore it is a viable option only when it guarantees clear and obvious improvements for the patient or when the lesion cannot heal if treated with the conservative approach.

Generally, surgical treatment is indicated for severe muscle tears [1, 12], in grade 4 lesions on the Ryan classification [13, 14] or when over 50% of the muscle fibers are involved. Grade 1 refers to injuries of a few muscle fibers; grade 2 - injury of a moderate number of muscle fibers; grade 3 - rupture of a moderate number of fibers associated with partial lesion of the fascia; grade 4 - those that involve injury through the full thickness muscle and the fascia (Figure 2).

From the clinical point of view, a massive rupture of the muscle leads to a loss of its strength which may be acceptable in patients with a low functional demand. However, athletes or people with high functional demands need the full recovery of muscle strength which

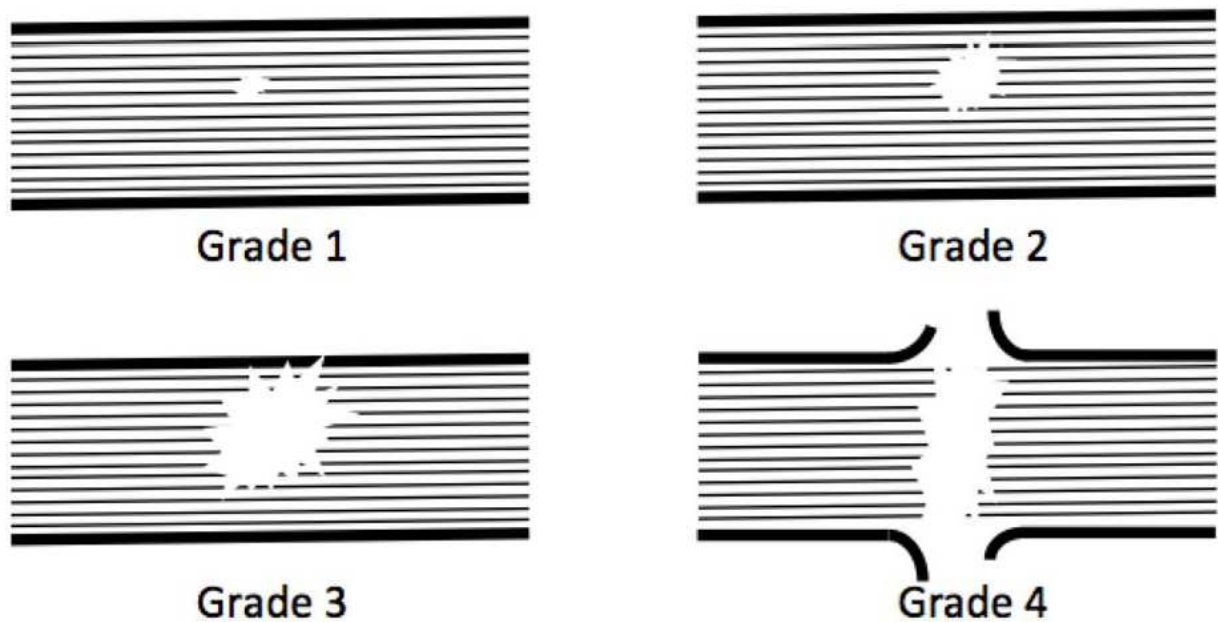


Figure 2. Ryan's Classification for muscle damage. The thin lines represent the muscle fibers, the thick lines represent the fascia.

conservative treatment in some areas and in some types of injury cannot guarantee. In literature, little has been written on myorrhaphy of the skeletal muscle and almost all of the reports focus on injuries of the biceps brachii and pectoralis majors. If these two muscles are severely damaged, a major deficit in strength and the cosmetic damage is not to be underestimated in the case of professional body-builders. The suture of muscle damage is in fact taken into consideration if the action of the muscle is not compensated for by other synergistic muscles or if the hematoma is so large that it compresses the main vessels and determines ischemia of the tissue or overlying skin [15].

The timing of the intervention is not clearly defined in the literature, Kragh et al. [16] recommend to do it the day after the traumatic event because delay it causes the suffering of muscle tissue and of the epimysium.

4. Pectoralis major

A complete lesion of the pectoralis major still allows a normal active mobilization of the shoulder, but will cause an important decrease in strength in adduction and internal rotation of the arm [17] so an early surgical reconstruction is indicated in athletes. In fact, with conservative treatment a significant loss of torque, measured using the isokinetic strength test, has been observed [18, 19] while following surgical treatment a significant increase in isokinetic torque of the muscle has been reported [20, 21]. In addition, the aesthetic damage caused by the gap following injury can cause the end of the career for body-builders and similar professionals for whom the aesthetics of the muscle is essential. Conservative treatment is recom-

mended only in cases of injury at the sternoclavicular origin, in some partial tears, in older or sedentary individuals.

This lesion was classified and reported in literature for the first time by Patissier in 1822 and since then over 200 cases have been reported [22]. The number of these lesions has increased and the increase in the last 30 years is due to the increased participation in heavy physical activity such as weight lifting, weight training, wrestling, rugby and waterskiing. Attributable almost solely to males, these lesions occur in an age range from 16 to 91 years with a peak in athletes aged between 20 and 40 years [22]. The most common mechanism is indirect trauma during bench pressing or other weight lifting movements; less frequent injuries are those following abduction-external rotation, extension-adduction and direct trauma [23].

The lesion of this muscle may occur in different zones. Tietjen [24] used a classification divided into 3 groups: type I consists of muscle contusions and sprains; type II partial tears and type III complete lesions. Each of these groups has a subclassification based on the location of the lesion: A - muscle origin; B - belly muscle; C - myotendinous junction; D - tendon. Statistically, insertion tendon injuries are the most frequent (55%), lesions to the belly or muscular-tendon insertion cover about 35% of these injuries [23].

According to the most recent meta-analysis [23] early surgical treatment achieves significantly better results than conservative treatment with an excellent-good result in 90% of cases, compared with 17% of conservative treatment ($P = 0.00000001$). When surgery is delayed slightly worse results are obtained, especially after 13 weeks from injury.

While for partial lesions treatment with conservative immobilization for 2-3 weeks is indicated, where surgery is required immobilization should be 4-6 weeks and subsequently a gradual lengthening of the muscle must be performed and only after 6-12 weeks strength training can begin.

5. Biceps brachii

The lesion of the biceps usually involves the tendon portion, more often the long proximal head and to a lesser extent the distal end that inserts into the radial tuberosity. Sometimes biceps muscle tears occur in the belly, especially when the arm remains entangled in ropes during some sports such as skydiving and wakeboarding [25, 26]. Less frequently, the muscle belly can break following direct trauma in a car accident [27].

Complete laceration of the muscle belly of the biceps brachii leads to a loss of muscle strength and unfortunately, few data are available in literature regarding the right choice of treatment. One of the few studies to have compared the effects of a surgical muscle suture with conservative treatment is the one by Kragh and Basamania in 2002 [25]. In a military base in North Carolina with 25,000 paratroopers, the authors performed nine surgeries in a year and compared the results to those of three patients treated conservatively in previous years. The paratroopers treated surgically achieved significantly better results for strength (measured in supination torque) and appearance. Those who had been treated conservatively had a worse

appearance, suffered easy fatigue in repetitive movements of pronation and supination (e.g. use of screwdriver), avoided weight-lifting and in two cases the musculocutaneous nerve was in contact with the skin and not covered by muscle tissue thus easily irritated even by the cuffs on the uniform.

The mechanism of injury is important for the occurrence of lacerations. In parachutists, the entrapment of the arm in the static-line during the launch determines a subcutaneous transverse lesion and an almost total one of the muscle belly with the proximal and distal stumps retracted; in this case muscle suture is indicated. In the case of water sports such as water skiing or wakeboarders, the mechanism of injury is similar with the entrapment of the arm in a tow-line that pulls the athlete at great speed. What differs between the two sports is that the lesion usually reported in water sports causes a tearing injury in the proximal-distal direction of the biceps and is not as clear cut as the paratroopers; this sometimes may preclude the muscle suture and require muscle resection [26].

The injury of the muscle belly of the biceps brachii is rare and closely related to particular sports; the indication for surgery is clear as it prevents functional and aesthetic deficits.

Kragh et al. in [25] with regard to the lesions of the biceps brachii recommend the intervention in the case in which the lesion extend more than 95% of the muscle belly.

6. Quadriceps femoris

No cases of suturing subcutaneous belly lacerations of the quadriceps femoris are described in literature. The only description is in a surgical case report by Straw [28]. The tear had occurred at the proximal musculotendinous junction. With surgery muscular performance improved 151% to concentric power after 6 months compared to preoperative levels.

7. Hamstring muscle

The hamstring is one of the muscle groups most affected by injuries in athletes. They often suffer strains localized in the muscle-tendon junction due to an eccentric contraction. The lesions may occur in different areas: proximal or distal muscle-tendon junction, muscle belly, the proximal and distal tendon insertion [29].

Usually hamstring injuries are treated conservatively with rest, ice, physical therapy, NSAIDs and a gradual return to sport. Rarely a lesion in this anatomical site requires surgical treatment.

One of the rare occasions when the patient may have to undergo surgery is when the hamstring is detached from the ischial tuberosity. This injury is rare but its incidence is increasing, especially in middle-aged patients who continue to be physically active [30]. The triggering mechanism of injury is a sudden flexion of the hip and extension of the knee that causes a contraction of the hamstring. The patient reports feeling a shot in the rear thigh and walks with his leg straight (stiff-legged gait) avoiding flexing hip and knee in order to relieve the pain.

The hamstring avulsion from the ischial tuberosity is not always treated surgically. Presently there is no commonly accepted classification, or any guidelines to be followed for treatment [29]. The current literature recommends conservative treatment if the injury affects only one tendon and the retraction does not exceed 1 - 2 cm. The single damaged tendon tends to heal by adhering to intact neighboring tendons and even professional athletes will be able to return to competitive activity within about 6 weeks from injury.

The rupture of three tendons usually causes a major retraction of the stumps (greater than 5 cm) and in this case surgical treatment is recommended.

When two tendons are completely damaged, the regimen is not clear and depends on the physician's personal experience. Surgery is generally recommended if the patient is less than 50 years old, active and participating in athletic activities. Furthermore, the retraction of the stumps for more than 2 cm may be the indirect sign of injury to the third muscle at the muscle-tendon junction or in the muscle belly; that has gone unseen at diagnosis, making surgery absolutely necessary [30]. It should be remembered that the MRI is difficult to interpret with certainty when multiple tendons are damaged in this region.

Conservative treatment lead to a reduction of strength in the knee flexion and extension of the hip; also a superabundant scar could entrap the sciatic nerve, which runs nearby, giving rise to a "hamstring syndrome". The cause of neurological symptoms in the sciatic nerve is not well defined and remains ambiguous: it is possible that the fibrotic scar tissue generated from the lesion could lead to adhesions with the nerve, it is possible that the detached bone of the tuberosity forms a callus which compresses the nerve, or that the hamstrings during retraction cause the sciatic nerve or one of its branches to stretch [31].

Surgical treatment provides for an incision (longitudinal or transverse) on the posterior side of the proximal thigh, once tendons are isolated, the surface of the ischial tuberosity is debrided, the injured tendons are reinserted with bone anchors and if necessary, the neurolysis of the sciatic nerve is performed to free it from any adhesions.

There is no "one and only" postoperative care in literature; some authors recommend to avoiding using a cast; at least one suggests keeping the knee flexed at 30 ° [29], others recommend a splint at 90 ° for 2 weeks followed by a gradual lengthening of the knee [31], others advise protecting the affected hip with a cast to be worn for 6 weeks that allows only movements between 15 ° and 30 ° of flexion [30]. This is followed by a gradual recovery of the joint's ROM and muscle strength during which time it is important to avoid too much tension on the insertion of the proximal hamstring in the first post-operative period. In particular, passive aggressive stretching should be avoided in the first 3 months post-op [29]. The return to sports-specific conditioning is expected between 6-9 months after surgery. It should be kept in mind that the full recovery of muscle strength requires a long time; often more than a year is needed to obtain an equal force in both legs. Residual muscle atrophy is common, especially in the long head of the biceps which results in a compensatory hypertrophy of the short head [32].

In the preoperative period hamstring stretching exercises should be avoided to prevent further distancing of the ends of the lesion; instead isometric contractions of the quadriceps and gluteal

muscles should be encouraged to reduce muscle atrophy as well as ankle pumps to prevent deep vein thrombosis [30].

The results of surgical treatment reported in literature appear to be satisfactory with 62 -90% of patients satisfied with return to sporting activity levels the same as before the injury [33, 34, 35, 36]. A recent review of the literature [37] shows that early surgical treatment guarantees a better performance in terms of rate of return to sports, patient subjective satisfaction, recovery of strength and performance compared to conservative treatment. Unfortunately the results presented in literature are not easy to interpret because the techniques used are varied and, being a rather rare lesion, the cases analyzed are few.

The results of the operation depend on many factors. The timing of surgery seems crucial as after 14 days from injury there is a higher risk of adhesions between the lesion and the sciatic nerve [38] so surgery should be performed before this limit. If surgery is performed after five weeks, the post-operative cast must be worn for a longer period of time [39]. It is not clear how the retraction of the tendon influences the treatment decisions : while in children retraction is an important factor in avulsion fractures, in skeletally mature subjects the importance of retraction has not yet been demonstrated. It has been shown how the level of retraction changes if observed on MRI or intra-operatively and it is closely related to hip and knee flexion and muscle activation [29].

Another rare lesion that can take place to the hamstring is a lesion to the distal insertion. In literature this injury is briefly described and the need for surgery is indicated although no more than 10 case reports and one case series with only a few patients enrolled, have been published.

The most common in the distal region is the avulsion of the biceps femoris associated with a multiligamentous lesion of the knee with a trauma in varus and hyperextension [40]. This muscle is an important and strong flexor and an active stabilizer of the knee and its injury can cause weakness and instability of the knee, especially in athletes [41]. Moreover, in the case of partial tears, the haphazard rearrangement of scar tissue and the formation of adhesions may jeopardize competitive sport activity because it causes pain. From an analysis of the 19 cases present in literature [41], it can be concluded that this type of injury, both complete and incomplete, allows the return to competition and that sometimes conservative treatment of partial tears may eventually require surgery to stop the painful symptoms.

The semimembranosus muscle has a role in flexion and internal rotation of the tibia. An injury to its distal portion determines a worse prognosis for players than the biceps femoris. There are fewer reports in literature (6 cases) [41], and it seems that the early reconstruction of total lesions lead to good results (2 cases). However, in the case of partial lesions, despite late reconstruction (4 cases), the subjects were unable to return to the same level of sporting activity as performed before previous to the injury. Biopsies performed on the unhealed muscles showed a severe denervation of muscle fibers. We can therefore suppose that a partial tear of the distal myotendinous junction of this muscle can cause serious nerve damage and determine a worse prognosis [41].

The semitendinosus muscle contributes to flexion strength at high degrees of knee flexion and intrarotation of the tibia. The tendon of this muscle is often harvested for use as a graft for

reconstruction of the anterior cruciate ligament, so in theory it is an "expendable" tendon. Indeed it has been shown that athletes who have had removed their semitendinosus tendon were able to return to the previous level of activity without the harvest causing an important deficit in the competitive performance [42]. A traumatic injury of this region, however, can result in a partial or total lesion that causes pain, and interferes with the physical activity of the patient. Also in this case few articles are available in literature and it is not clear when it is advisable to choose conservative treatment and when to opt for surgical treatment. From our literature search we found 25 cases described [40, 41, 43, 44], 14 patients had been treated conservatively and 11 surgically. The surgery in all cases was a tenotomy with eventual release of adhesions, in no case was a suture performed to restore the damaged anatomical structure. In 5 of the 14 cases (35%) treated conservatively there was a treatment failure and the patient needed surgery that subsequently gave good results. Of the 11 patients treated surgically all returned to their previous level of athletic activities.

The study with the largest case series [40] emphasized that early surgical treatment (within 4 weeks from injury) leads to a much earlier return to sports: with conservative treatment (7 cases) return to sport occurs at an average of 18.4 weeks, with surgery (5 cases) at 6.8 weeks, while if conservative treatment fails and surgery is needed (5 cases), return to the field is much later, at 29.6 weeks on average. Unfortunately, however, the results are not statistically significant because of the small sample number.

8. Adductor muscle

A lesion at the proximal end of the adductor complex is not a common injury. There are few articles in literature about it, and those few are of a low level of evidence and with a few selected cases. An eccentric contraction during a movement of forced abduction of the lower limb may cause this type of acute injury. The most common mechanism is bilateral abduction of the lower limbs with a hip flexion and internal rotation of the other hip [45]. Usually the acute injury is preceded by painful symptoms previous to the accident that express an acute injury on a chronic disease in the area. In fact, histological studies [46, 47] have shown that in the area near the lesion there are degenerative tissue alterations. For this reason the first therapeutic approach to acute injuries of proximal adductor insertion was based on the results of treatment of the chronic lesion. Tenotomy, often used for chronic pain resistant to conservative therapies, had not guaranteed excellent results: 40% of patients were unable to return to competitive activity after surgery and the strength of the adductors reported a significant decrease at the isokinetic test [48]. These results led to the surgical reconstruction of the injured tendon / muscle to prevent the loss of strength and try to increase the percentage of athletes who could return to their previous level of competitive activity [46].

It was later shown that about 60% of the athletes complained of an aspecific symptom, especially abdominal or inguinal pain in the period prior to the injury [49]. However, the importance of the integrity of these anatomical structures has decreased. Studies on the conservative treatment of these lesions have shown that the anatomical continuity of these

structures is not essential for a high athletic performance and electromyographical studies support the idea that the abductor muscles do not play a key role in sprinting and cutting movements [50, 51].

The most recent study with the largest series includes 19 players of the American National Football League (NFL) [49], 14 were treated conservatively and 5 surgically. The authors conclude that although all the players returned to play in the top league, those who received conservative treatment returned to the field sooner (6.1 ± 3.1 weeks) than those treated surgically (12.0 ± 2.5 weeks). Moreover, besides the risk of complications with surgery, the operation is not easy to perform if the lesion is at the level of the muscle-tendon junction [45].

The information available in the literature on this subject is scarce, with a low level of evidence and often conflicting. Some authors recommend surgery to suture / reinsert in the case of acute injuries occurring in athletes and excision / tenotomy in the case of inveterate injuries; other authors do not recommend surgery because it extends recovery time and does not guarantee better results than conservative treatment, considering also the non fundamental function of this muscle group in sport activities. Much still needs to be understood in this regards and future studies should be conducted with better methods and possibly with a larger number of patients.

9. Suture versus immobilization

Few studies in the literature have compared muscle suture and immobilization. Animal studies, usually in the Sprague-Dawley rat, have shown that lesions performed for experimental purposes heal better if sutured. Almekinders [52] has shown that the benefits obtained by suturing muscles are significant at one week after injury, while at two weeks surgical treatment or treatment with simple immobilization bring the same results in terms of maximum failure load, active force generation as well as from the histological point of view. Menetrey [3] instead found significant improvements with suturing muscle in respect to not suturing and immobilization; in fact one month after the injury the sutured muscle produced 81% of the tetanus strength measured in the intact muscle, while the non sutured muscle produced 35% and the immobilized muscle 18%. It is evident how the overabundance of connective tissue in the scar tissue inhibits the formation of myofibers at 12 weeks [1] whereas the suture prevents the formation of scar tissue in depth; it restricts the formation of hematoma by decreasing the gap of the lesion and the infiltration of mononuclear cells is limited to the surface region only. Desmin's detection has proved that the greatest number of regenerating myofibers is in the sutured muscle already at 2 days after injury, this is not because it limits the inflammatory phase or cellular necrosis (that occurs anyway) but probably because it produces a microenvironment favorable to repair, keeping the muscle stumps together [3].

Clearly the results of the animal tests should be interpreted with caution for several reasons: the lesion that is created is a surgical one, metabolism and healing of the lesion are different between humans and rats. In humans, the only studies comparing surgery and conservative treatment are about lesions of the biceps brachii [25, 53] where the best results are had in

patients treated with the myorrhaphy. However, these articles have a poor methodology and take into account only a small number of patients; obviously future larger and better conducted studies are required in order to determine more specifically which type of treatment is most suitable in humans. It remains clear, however, that surgical treatment is rarely necessary, only for certain types of injuries, and only with a specific indication. We perform surgery only when strictly necessary.

10. Types of sutures

Once you choose a surgical approach it is important to decide the surgical technique and how to suture the muscle.

The suture of a muscle belly is easier in its proximal third and distal third, whereas only in some muscles in the middle third; this is because the tendon fibers flatten and extend into the muscle belly giving the stitches a greater support [54].

Literature describes many types of knots and sutures, such as the conventional Kessler, the modified Kessler and the figure-eight horizontal mattress and more complex ones, such as the Mason-Allen, the Modified Mason-Allen and suturing the perimeter of the lesion.

The integrity and viability of the remaining muscle tissue is important and indicative for a good prognosis; furthermore the preservation of the epimysium and the possibility of suturing it to the muscle makes the suture more resistant. From an *in vitro* study on pig muscles [55], it has been shown that suturing the epimysium gives the suture greater resistance to tensile stress compared to sutures made only on the muscle tissue and perimysium. This is because the epimysium consists of more connective tissue and is composed of two layers, hence much more resistant to tension compared to the perimysium [56].

The Kessler stitch would seem to be more resistant to pull-out suturing than simple stitch or simple suturing with a tendon graft [57].

Kragh [16] compared the Kessler stitch and a stitch combinations (Mason-Allen stitch and stitch around perimeter) in pig muscle. These two types of sutures were considered the strongest in a pilot study carried out before the main study where 9 different types of suturing were compared: simple stitch, running simple (epimysium based, non-core) stitch, the figure of eight stitch, the modified Kessler stitch, a vertical mattress stitch, a horizontal mattress stitch (core), a horizontal mattress stitch (inverted, epimysium based, non-core), a double right angle stitch, a combination (Modified Mason-Allen and perimeter) stitch. At the tensile tests carried out, the Kessler stitch achieved a maximum load of 35 N, whereas the combined suture achieved 74 N. Not only did the combined suture achieve a greater tensile load, but also the Kessler stitch failed because the sutures were pulled away from the muscle tissue, whereas in the combined suturing, the better distribution of the forces induced a gradual lengthening of the muscle fibers and the stitches were not torn away from the tissue at the 35 mm lengthening.

Similar results were obtained on fresh frozen cadaveric human tissue [58]. Comparing Kessler, figure eight, mattress, Mason-Allen, perimeter and perimeter-Mason-Allen on different

muscles of human cadaver, Kessler stitch was the least resistant and tore the muscle with an average load of 1.65 kg; the strongest suture, as was observed in other studies, was the combined suture, Mason-Allen plus perimeter stitch, that withstood a weight of 6.4 kg on average. It was also observed that the simple sutures tend to tear the tissue and the epimysium longitudinally, whereas the more complex sutures failure involves more the transversal tissue. In fact, the epimysium is the key to a robust suture, it is more robust in the tissue where the suture can adhere firmly, the complex sutures involve a greater surface area than the simple ones.

It should also be noted that the simple sutures close the epimysium flaps but in the deep layers, fibers are free and when subsequent contraction of the muscle flaps occur, although held together at the extremity by the suture, deep below the surface tend to form a gap that favors the formation of hematomas, prolong the period of healing and promote excessive fibrosis which may in turn lead to exuberant scar tissue. Hence, the complex suture allows the surgeon to pull together the edges of the tear both at the extremes and deep in the muscle enhancing a greater biological performance [58].

The muscle tissue, due to its physical characteristics, does not offer a solid anchor for sutures which, if positioned improperly, tend to tear the fibers and are pulled from the muscle. When the suturing encompasses multiple points on the injured muscle and the correct technique is used, it can sustain heavy loads and prevent further injuries and ineffective sutures. In theory a stronger suture and one that is less damaging to the muscle tissue should allow earlier mobilization without the risk of failure; therefore improving the healing, shortening the period of immobility and in turn decreasing muscle atrophy.

These in vitro tests demonstrate how to make the most of myorrhaphy. In vivo, however, there are no significant differences between the stitches used. Even when comparing a Kessler stitch with a simple suture in a tendon graft, Chien et al. [57] found no difference in terms of muscle healing in rabbits.

Some authors have proposed the use of grafts to reinforce the suture, but It is still unclear whether the use of an augmentation graft suture, as performed by Botte et al. [59] on a case series of 58 patients, is useful to make improvements in clinical and functional outcomes.

11. Conclusions

The indication for surgical treatment applies to a small number of muscle lacerations. The tearing of the muscle belly is a common occurrence in athletes and nowadays are difficult to predict or prevent. There is no clear indication for surgical suture for these lesions and there is no real guide line to follow. The majority of the authors in literature consider performing surgery when the lesion affects more than 50% of the total of muscle fibers. Such an extensive injury would provoke a massive scar reaction making it difficult to achieve efficient and functional tissue leading to an excess of collagen and fibrotic tissue which would change the muscle mechanics and facilitate the onset of new lesions. It has also been evaluated and

demonstrated that large lesions also present decreased strength, especially in those cases where the affected muscle is not assisted by other agonist muscles. The best results were obtained in patients treated with surgery compared to those treated conservatively with splinting.

In addition, such an extensive lesion would also be very disfiguring in appearance for those who make fitness and muscle shape their job such as body builders. These lacerations leave the muscle anatomy altered, and conservative treatment fails to restore the geometric lines and shapes of the muscle.

The muscles most affected by these injuries in sports are the pectoralis major (in lifters), the biceps brachii (in the paratroopers and water sportsmen who are pulled by ropes) and the rectus femoris.

Surgery brings the margins of the lesion together thus decreasing the hematoma and reducing the reactive fibrous reaction which in turn leads to smaller scars. The approach also enhances a faster return to mobilization of the affected segment and an earlier recovery of muscle tone.

The muscle belly tissue is not a robust structure for anchoring the stitches to, therefore the choice of method, anchor points and suture type must be made carefully.

It is evident how few publications there are in literature that deal with the management of massive muscle injuries; only a few studies comparing the therapeutic options have been conducted and the majority of articles available concern in vitro studies or animal studies. It is necessary that further studies are conducted in order to obtain enough scientific evidence to guide the treatment and management of these patients.

Author details

Giuliano Cerulli^{1,2,3,4}, Enrico Sebastiani⁵, Giacomo Placella⁵, Matteo Maria Tei⁵, Andrea Speziali⁵ and Pierluigi Antinolfi⁶

1 University of Perugia, Perugia, Italy

2 Nicola's Foundation ONLUS Arezzo, Italy

3 Let People Move Research Institute Arezzo, Perugia, Italy

4 International Orthopedic and Traumatologic Institute Arezzo, Italy

5 Residency program in Orthopedics and Traumatology, University of Perugia, Perugia, Italy

6 "Santa Maria della Misericordia" Hospital, Orthopedic and traumatology department, Perugia, Italy

References

- [1] Garret WE Jr, Seaber AV, Boswick J, Recovery of a skeletal muscle after laceration and repair. *J Hand Surg* 1984;9A: 683-692
- [2] Huard J, Li Y, Fu FH, Muscle injuries and repair: current trends in research. *Journal of Bone and Joint Surgery*. 2002;84A(5):822-832
- [3] Menetrey J, Kasemkijwattana C, Fu FH, Moreland MS, Huard J, Suturing versus immobilization of a muscle laceration, *Am j Sports Med* 1999;27(2): 222-229
- [4] Kaariainen M, Kaariainen J, Jarvinen TLN, Sievanen H, Kalimo H, Jarvinen M. *Journal of Orthopaedic Research*. 1998;16:197-206
- [5] Beiner JM, Jokl P. Muscle contusion injuries: current treatment options. *Journal of American Academy of Orthopedic Surgeon*. 2011;9:227-237
- [6] Jarvinen M, Healing of a crush injury in rat striated muscle: 2. A histological study of the effect of early mobilization and immobilization on the repair processes. *Acta Pathologica et Microbiologica Scandinavica*. 1975;83:269-282
- [7] Lehto M, Duance VC, Restall D. Collagen and fibronectin in a healing skeletal muscle injury: An immunohistological study of the effects of physical activity on the repair of injured gastrocnemius muscle in the rat. *Journal of Bone and Joint Surgery*. 1985;67:820-828
- [8] Lehto MUK, Jarvinen MJ, Muscle injuries, their healing process and treatment. *Ann Chir Gynaecol*. 1991;80:102-108
- [9] Noonan TJ, Garrett WE Jr. Muscle strain injury: diagnosis and treatment. *Journal of American Academy of Orthopaedic Surgeon*. 1999;7:262-269
- [10] Aspelin P, Ekberg O, Thorsson O, Wilhelmsson M, Westlin N. Ultrasound examination of soft tissue injury of the lower limb in athletes. *American Journal of Sport Medicine*. 1992;20:601-603
- [11] Mellerowicz H, Lubash A, Dulce MC, Dulce K, Wagner S, Wolf KJ. Diagnosis and follow-up of muscle injuries by means of plain and contrast-enhanced MRI: Experimental and clinical studies. *Rofo Fortshr Geb Rontgenstr Neuen Bildgeb Verfahr*. 1997;166:437-445
- [12] Jarvinen TAH, Kaarianen M. Muscle strain injuries. *Curr Opin Rheum*. 2000;12:155-161
- [13] Ryan AJ. Quadriceps strain, rupture and charlie horse. *Med Sci Sports* 1969;1:106-111
- [14] Miller WA, Rupture of the musculotendinosus juncture of the medialhead of the gastrocnemius muscle. *American Journal of Sport Medicine* 1977;5:191-193

- [15] Ferrario A, Monti GB, Jelmoni GP. Traumatologia dello sport, clinica e terapia. Ediz. Ermes. 2005
- [16] Kragh JF Jr, Svoboda SJ, Wenke JC, Ward JA, Walters TJ. Suturing of lacerations of skeletal muscle. *J Bone Joint Surg Br.* 2005;87B:1303-5
- [17] Kretzler HH Jr, Richardson AB. Rupture of the pectoralis muscle. *American Journal of Sports Medicine.* 1989;17:453-458
- [18] McEntire JE, Hess WE, Coleman SS. Rupture of the pectoralis major muscle. *Journal of Bone and Joint Surgery.* 1972;54:1040-1045
- [19] Scott BW, Wallace WA, Barton MAJ. Diagnosis and assessment of pectoralis major rupture by dynamometry. *Journal of Bone and Joint Surgery.* 1992;74:111-113
- [20] Liu J, Wu JJ, Chang CY, Chou YH, Lo WH. Avulsion of the pectoralis major tendon. *Journal of American Sports Medicine.* 1992;20:366-367
- [21] Pavlik A, Csepai D, Berkes I. Surgical treatment of pectoralis major rupture in athletes. *Knee Surgery Sports and Traumatology Arthroscopy.* 1998;6:129-133
- [22] Petilon J, Carr DR, Sekiya JK, Unger DV. Pectoralis major muscle injuries: evaluation and management
- [23] Bak K, Cameron EA, Henderson IJP. Rupture of the pectoralis major: a meta-analysis of 112 cases. *Knee Surgery Sports and Traumatology Arthroscopy.* 2000;8:113-119
- [24] Titjen R. Closed injuries of the pectoralis major muscle. *J Trauma.* 1980;20:262-264
- [25] Kragh JF, Basamania CJ. Surgical repair of acute traumatic closed transection of the biceps brachii. *Journal of Bone and Joint Surgery.* 2002;84(6):992-998
- [26] Pascual-Garrido C, Swanson BL, Bannar SM. Closed proximal muscle rupture of the biceps brachii in wakeboarders. *Knee Surgery Sports Traumatology Arthroscopy.* 2012;20:1019-1021
- [27] Shah AK, Pruzansky ME. Ruptured biceps brachii short head muscle belly: a case report. *Journal of Shoulder and Elbow Surgery.* 2004;13(5):362-365
- [28] Straw R, Colclough K, Geutjens. Surgical repair of a chronic rupture of the rectus femoris muscle at the proximal musculotendinous junction in a soccer player. *Br J Sports Medicine.* 2003;37:182-184
- [29] Askling CM, Koulouris G, Saartok T, Werner S, Best TM. Total proximal hamstring ruptures: clinical and MRI aspects including guidelines for postoperative rehabilitation. *Knee Surg Sports Traumatol Arthrosc.* 21:515-533. 2013
- [30] Cohen S, Bradley J. Acute proximal hamstring rupture. *J Am Acad Orthop Surg.* 15:350-355, 2007

- [31] Chakravarthy J, Ramisetty N, Pimpalnerkar A, Mohtadi N. Surgical repair of complete proximal hamstring tendon ruptures in water skiers and bull riders: a report of four cases and review of the literature. *Br J Sports Med.* 39:569-572. 2005
- [32] Silder A, Heiderscheit BC, Thelen DG, Enright T, Tuite MJ. MR observations of long term musculotendon remodeling following a hamstring strain injury. *Skeletal Radiol.* 37:1101-1109. 2008
- [33] Klingele KE, Sallay PI. Surgical repair of complete proximal hamstring tendon rupture. *Am J Sports Med.* 30:742-747, 2002
- [34] Chakravarthy J, Ramisetty N, Pimpalnerkar A, Mohtadi N. Surgical repair of complete proximal hamstring ruptures in water skiers and bull riders: a report of four cases and review of the literature. *Br J Sports Med.* 39:569-572. 2005
- [35] Brucker PU, Imhoff AB. Functional assessment after acute and chronic complete ruptures of the proximal hamstring tendons. *Knee Surg Sports Traumatol Arthrosc.* 13:411-418. 2005
- [36] Orava S, Kujala UM. Rupture of the ischial origin of the hamstring muscles. *Am J Sports Med.* 23:702-705. 1995
- [37] Harris JD, Griesser MJ, Best TM, Ellis TJ. Treatment of proximal hamstring ruptures – a systematic review. *Int J Sports Med.* 32:490-495. 2011
- [38] Konan S, Haddad F. Successful return to high level sports following early surgical repair of complete tears of the proximal hamstring tendons. *Int Orthop.* 34:119-123. 2010
- [39] Chamichael J, Packham I, Trikha SP. Avulsion of the proximal hamstring origin: surgical technique. *J Bone Joint Surg Am.* 15:350-355. 2007
- [40] Cooper DE, Conway JE. Distal semitendinosus ruptures in elite-level athletes: low success rates of nonoperative treatment. *Am Journal Sports Med.* 38(6):1174-8. 2010
- [41] Lempainen L, Sarimo J, Kimmo M, Heikkila J, Orava S. Distal tears of the hamstring muscles: review of the literature and our results of surgical treatment. *Br J Sports Med.* 41:80-83. 2007
- [42] Smith FW, Rousenlund EA, Aune AK. Subjective functional assessments and the return to competitive sport after anterior cruciate ligament reconstruction. *Br J Sports Med.* 38:279-284. 2004
- [43] Schilders E, Bismil Q, Sidham S. Partial rupture of the distal semitendinosus tendon treated by tenotomy - a previously underscribed entity. *Knee.* 13:45-7. 2006
- [44] Adejuwon A, McCourt P, Hamilton B, Haddad F. Distal semitendinosus tendon rupture: is there any benefit of surgical intervention?. *Clin J Sports Med.* 19:502-504. 2009

- [45] Campbell. Canale ST. *Chirurgia ortopedica*. X edizione. Verducci Editore. 2005
- [46] Rizio L, Salvo JP, Schurhoff MR, Uribe JW. Adductor longus rupture in professional football players: acute repair with suture anchors - a report of two cases. *Am J Sports Med*. 32(1):243-245. 2004
- [47] Ippolito E, Postacchini F. Rupture and disinsertion of the proximal attachment of the adductor longus tendon: case report with histochemical and ultrastructural study. *Ital J Orthop Traumatol*. 7:79-85. 1981
- [48] Akerman C, Johansson C. Tenotomy of the adductor longus tendon in the treatment of chronic groin pain in athletes. *Am J Sports Med*. 20:640-643. 1992
- [49] Schlegel TF, Bushnell BD, Godfrey J, Boublik M. Success of nonoperative management of adductor longus tendon ruptures in national football league athletes. *Am J Sports Med*. 37(7):1394-1399. 2009
- [50] Mann RR, Moran GT, Dougherty SE. Comparative electromyography of the lower extremity in jogging, running, and sprinting. *Am J Sports Med*. 14(6):501-510. 1986
- [51] Neptune RR, Wright IA, Van Den Bogert AJ. Muscle coordination and function during cutting movements. *Med Sci Sports Exerc*. 31(2):294-302. 1999
- [52] Almekinders LC. Results of surgical repair versus splinting of experimentally transected muscle. *Journal of Orthopaedic Trauma*. 1991;5(2):173-176
- [53] Heckman JD, Levine MI. Traumatic closed transection of the biceps brachii in the military parachutist. *Journal of Bone and Joint Surgery*. 1978;60-A:369-72
- [54] Chammout MO, Skinner HB. The clinical anatomy of commonly injured muscle bellies. *J Trauma*. 1986;26:549-552
- [55] Kragh JF, Svoboda SJ, Wenke JC, Ward JA, Walters TJ. Epimysium and perimysium in suturing in skeletal muscle lacerations. *The Journal of Trauma Injury, Infection, and Clinical Care*. 2005;59(1):209-212
- [56] Nishimura T, Hattori A, Takahashi K. Ultrastructure of the intramuscular connective tissue in bovine skeletal muscle: a demonstration using cell-maceration/scanning electron microscope method. *Acta Anatomica*. 1994;151:250-257
- [57] Chien SH, Chen SK, Lin SY, Chen SS, Wu HS. Repair method and healing of skeletal muscle injury. *The Kaohsiung Journal of Medical Sciences*. 1991;7(9):481-488
- [58] Chance JR, Kragh JF, Agrawal M, Basamania CJ. Pullout forces of sutures in muscle lacerations. *Orthopedics*. 2005;28(10):1187-90
- [59] Botte MJ, Gelberman RH, Smith DG, Silver MA, Gellman H. Repair of severe muscle belly lacerations using a tendon graft. *J Hand Surg Am*. 12(3):406-412, 1987