

We are IntechOpen, the world's leading publisher of Open Access books Built by scientists, for scientists

6,900

Open access books available

185,000

International authors and editors

200M

Downloads

Our authors are among the

154

Countries delivered to

TOP 1%

most cited scientists

12.2%

Contributors from top 500 universities



WEB OF SCIENCE™

Selection of our books indexed in the Book Citation Index
in Web of Science™ Core Collection (BKCI)

Interested in publishing with us?
Contact book.department@intechopen.com

Numbers displayed above are based on latest data collected.
For more information visit www.intechopen.com



Reduction Mammoplasty and Intra-Operative Radiotherapy (IORT) in Conservative Surgery

Simonetta Franchelli, Paolo Meszaros, Michela Massa, Marina Guenzi, Renzo Corvò, Davide Pertile, Giorgia Timon, Ferdinando Cafiero and Pierluigi Santi

Additional information is available at the end of the chapter

<http://dx.doi.org/10.5772/55939>

1. Introduction

1.1. Conservative surgery

Conservative surgery (lumpectomy, quadrantectomy) associated with radiation therapy is widely applied worldwide instead of mastectomy in early-stage breast cancer, since clinical trials reported similar survival rate [1,2].

These surgical procedures are the first choice for small primary tumours (diameter on physical examination up to 3 cm) with no palpable nodes (N0); the choice of procedure adopted depending upon the relation between tumour size and breast volume (small tumour in voluminous breast).

Contraindications to a conservative surgery are: serious co-morbidities, multifocal tumour or wide microcalcifications, clinically palpable lymph nodes and all contraindications to radiotherapy.

The conservative surgery may expose to the patient to a higher risk of local recurrence, that could be reduced applying wider excision with microscopic clear margins. Although there are controversies with regard to a safe margin, it is generally accepted that there is lower risk of recurrence with clear margin more than 10 mm, while margins less than 2 mm are considered inadequate [3]. Excision with clear margins is important for local control and consequently for overall survival.

In our experience sentinel node biopsy represents another step of conservative surgery because it is important for tumour staging.

1.2. Radiotherapy and IORT

The standard adjuvant therapy in early breast carcinoma includes whole breast irradiation (WBI) after conservative surgery to minimize the risk of local failure and improve disease-specific survival. The standard schedules for WBI is 1.8- to 2-Gy daily fractions given 5 times a week to a total dose of 45 to 50 Gy over 5 weeks with optional addition of a boost to the primary site of 10 to 16 Gy in 5 to 8 daily fractions over 1 to 1.5 weeks. The irradiation takes almost 6 weeks. Recent randomized trials have shown that use of modest hypo-fractionation for adjuvant WBI in women with early breast cancer can reduce the number of weeks of treatment (3 or 4 depending on the schemes used) to obtain [4].

Another aspect is whether whole mammary gland needs to be irradiated to destroy microscopic tumour foci. Few studies have systematically addressed the extent of foci of premalignant and malignant disease in the breast after lumpectomy [5,6]. It has been shown that around 40% of the cases had no other foci in the breast of pre-malignancy/malignancy, thus 60% of the cases had residual foci. Moreover at a distance of >2cms from the primary carcinoma only 14–16% had invasive tumor foci in the breast.

Nevertheless it has been uniformly demonstrated that local recurrence rate is significantly lowered by adjuvant radiotherapy [2] and that the majority of local recurrences (LRs) occurs in proximity to the tumour bed, while less than 20% of LR appear “elsewhere” in the breast. [7,8]

On the basis of these considerations, there has been a growing interest in the use of accelerated partial-breast irradiation (APBI) as an alternative to WBI in the last decade. This technique irradiates a limited volume of the mammary gland to a high dose in 1 to 10 fractions to be delivered in 1 to 5 days. The advantages of APBI are: a decreased overall treatment time and decreased radiation dose delivered to uninvolved portions of the breast and adjacent organs.

It is important to recognize that APBI is unlikely to replace WBI for all patients treated with breast-conserving surgery and that the key to long-term success for partial breast irradiation is proper selection to identify low risk patients.

The American Society for Radiation Oncology (ASTRO) and the Groupe Européen de Curiethérapie-European Society for Therapeutic Radiology and Oncology (GEC-ESTRO) [9,10] breast cancer working groups developed a consensus statement regarding patient selection criteria for the use of APBI outside the context of a clinical trial. The recommendations were based on the results of a systematic literature review and were supplemented by the expert opinions of both Task Force members.

The inclusion/exclusion criteria of partial breast irradiation after conservative surgery are shown in tab.1-2.

Similar prognostic factors are applied in both the documents developed by two groups: patients factors (young age and BRCA mutations), pathologic factors (tumor size, lobular carcinoma, positive margins of resections, lymph-vascular space invasion, multicentricity,

multifocality, pure ductal carcinoma in situ, extensive intraductal component), nodal factors (axillary dissection not performed or pN1, pN2, pN3) and treatment factors as neoadjuvant chemo-therapy. Analyzing the prognostic factors, different categories of risk for local relapse were drawn to exclude patients at high risk from APBI.

Inclusion criteria*	<ul style="list-style-type: none">• Non lobular carcinoma in histological specimen after standard lumpectomy;• Age ≥ 45 and < 85 years• Lump diameter ≤ 2 cm (pT1-T2 according to TNM-UICC 2002);• Safe resection margin ≥ 5 mm in the surgical specimen;• Patient availability to out-patient follow-up;• Patient availability for following medical examinations such as MNR, mammography, ultrasound;• Agreement to informed consent;• pN0.
---------------------	---

Table 1.

Exclusion criteria	<ul style="list-style-type: none">• Extensive intraductal component in the histological specimen (> 3 cm of diameter);• Pure ductal carcinoma or lobular carcinoma;• Multifocality;• Neoadjuvant therapy• Serious diseases;• Pregnancy or breast feeding;• Psychiatric illness;• Connective tissue diseases
--------------------	--

Table 2.

Several technique may be used for partial breast irradiation: interstitial brachytherapy, brachytherapy using MammoSite device, 3D conformal external radiotherapy (3D CRT) and Intraoperative Radiotherapy (IORT). The above mentioned methods for APBI have different characteristics and they are very difficult to compare [11].

IORT is the only APBI technique that offers surgery and radiotherapy simultaneously with great comfort for patients. It can be implemented using low energy photons (50 kV) provided by an Intra-beam device [12] or using accelerated electrons produced by mobile linear accelerators installed in the operating room (fig.1).

Some centers use beams of electrons produced by linear accelerators located outside the operating room; although this process is feasible, having a dedicated accelerator in the operating room facilitates the procedures and reduces discomfort and complications.



Figure 1. Mobile linear accelerator in our operative room

IORT with electrons is a method for adjuvant radiotherapy developed in 1999 at European Institute of Oncology (IEO) in Milan: Intra-operative Radiotherapy with Electrons (ELIOT) delivers a single dose of radiation equivalent to the total dosage with external fractionated radiotherapy directly to the tumour bed after lumpectomy or quadrantectomy using a mobile linear accelerator located in the operating theatre.

This technique has the advantage to do radiation treatment when breast tissue is having a rich vascular supply; thereby making it more sensitive to the action of the radiation (oxygen effect), immediately after surgery, before tumour cells have a chance to proliferate.

Moreover, the precise application of one single high dose of irradiation directly to the tumour bed with complete skin sparing has the great advantage of shortening radiotherapy time from 6 weeks to one single fraction.

The biological equivalent dose (BED) for IORT needs to be discussed as for a 20–21 Gy dose given in one fraction there are no radiobiological models that can describe what is happening during such high doses. The tool, most commonly used for determining iso-effective doses is the linear-quadratic (LQ) model, and it is unclear if it is applicable for single fractions >10 Gy. Within this limit, the single dose of 21 Gy is equivalent to a fractionated dose of 65 Gy hence, an increased incidence of severe fibrosis can be expected, nevertheless clinical experiences, reported to date, does not support this hypothesis. [13]

Preliminary results are encouraging, but some questions are still unclear, such as the effect of high single doses on late morbidity and aesthetic result. All experts are waiting for the results of prospective randomized ELIOT trial carried on by IEO, comparing the delivery of 21 Gy intraoperatively versus Whole Breast Irradiation (50Gy/25 fraction) plus additional 10 Gy boost irradiation. In the meantime, Veronesi et al have published the results of a retrospective analysis on 1822 patient, treated from January 2000 to December 2008 at the IEO, after a mean follow up of 36.1 months [14].

Forty-two women (2.3%) developed local recurrence, 24 (1.3%) new primary ipsilateral carcinomas and 26 (1.4%) distant metastases as first event. Local side effects were mainly liponecrosis (4.2%) and fibrosis (1.8%). Forty-six women died (2.5%), 28 with breast carcinoma and 18 with other causes. Five- and ten-year survivals were, respectively, 97.4 and 89.7%. Based on these data, ELIOT seems to be promising technology. Moreover, the authors showed that age, tumor size, numbers of positive nodes, molecular subtype, tumour grade and peritumoural invasion are statistically significant predictors of local relapse [14].

A further study has confirmed the importance of patient selection as indicated by the international documents mentioned above. [9,15].

IORT is a method of radiation treatment that requires close collaboration between all components of a multidisciplinary team: oncologic and plastic surgeons, radiation oncologists and medical physicists.

2. Oncoplastic techniques

Several techniques of reduction mammoplasty have been carried out over the years to correct macromastia [16].

In aesthetic field the choice between different mammoplasty techniques depending upon degree of macromastia; patients who require mild resections of 500 gr per breast can be treated by superior pedicle techniques such as Pitanguy reduction mammoplasty with T-shaped inverted scar (Fig.2) or other superior pedicle techniques such as Marchac, Peixoto and Lassus Techniques that have different extension of residual scars [17].

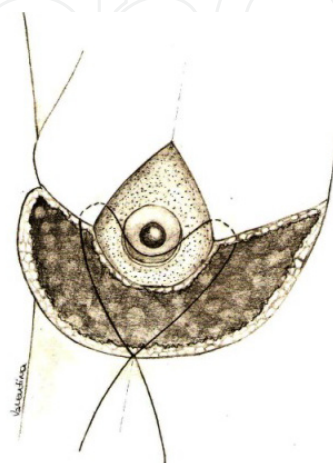


Figure 2. Superior pedicle mammoplasty: gland resection concerns the inferior quadrants

However, patients who require greater resection (1000 gr per breast and more) can be treated more effectively by inferior pedicle techniques or free nipple grafting technique (Fig 3, 4).

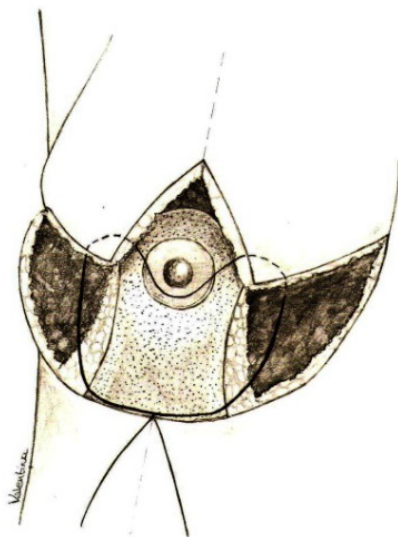


Figure 3. Inferior pedicle mammaplasty: in this case gland resection concerns the superior quadrants. The technique suites better to great reduction.

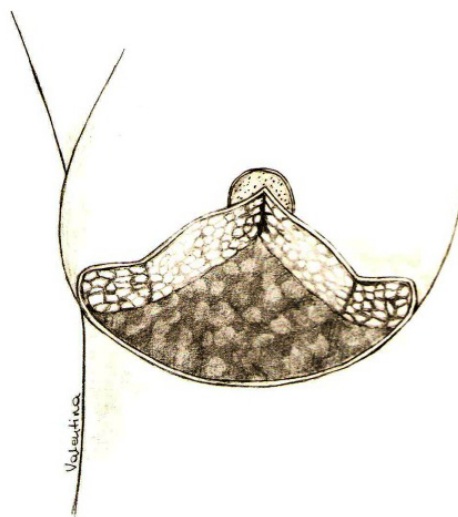


Figure 4. Mammaplasty with free nipple grafting technique: in this case resection concerns the inferior and the central part of the gland

However, in oncologic field the choice between the different options depends primarily on cancer position; for example, the inferior pedicle mammaplasty is chosen, if lump is located in the superior part of the gland; while superior pedicle mammaplasty is applied if lump is located in inferior part of the breast.

This practice minimizes the reshaping and displacement of residual glandular flaps, that may be very important if external radiotherapy is applied.

3. Technique

At our Institute, since 2004 a protocol has been applied to patients with medium/large-sized and ptotic breast (from II to IV degree ptosis) and the patients that needed breast tissue removal of more than 10% of total volume for small breast and more than 20% of total volume for large breast. Different techniques of reduction mammoplasty were carried out in these cases instead of classic conservative surgery (lumpectomy, quadrantectomy).

Oncoplastic techniques have been always applied, regardless of volume/ptosis of breast, if lump is located behind nipple-areola complex.

The introduction of IORT has greatly modified the approach to all features of conservative treatment, both traditional or oncoplastic. Since 2010 we have started to apply oncoplastic techniques of reduction mammoplasty in association with IORT.

The inclusion criteria include criteria of oncoplastic techniques (medium / large breast with/or ptosis III-IV degree) together with the ones of IORT (pts aged >45, T1, T2 < 2.5 cm, intraductal component < 25%, negative lymphatic metastasis, single lump) applied in our Department after approval of Institute Ethical Board.

All the patients underwent oncoplastic procedures and IORT including a multidisciplinary team (oncologic surgeon, plastic surgeon and radiotherapist) during the same surgical time.

A comprehensive preoperative consultation with plastic and oncologic surgeon including a discussion with the patient about her physical peculiarity, psychological status, expectations and choice between unilateral or bilateral procedure, precedes the operation; the choice between unilateral or bilateral mammoplasty is made by the patient and is motivated exclusively by psychological reasons.

A specific informed consent that explains the extent of the undermined tissues and scars and the effect of IORT are discussed with each patient; it explains the different phases of surgery and the possible alternatives (classic conservative surgery), the cutaneous incisions, the extent of the undermined tissues and residual scars.

The possible complications are discussed with the patient, such as: cutaneous and subcutaneous necrosis, seroma, haematoma, numbness and local anesthesia, surgical site infection (SSI), possible asymmetry; moreover some preoperative conditions are evaluated such as smoking that may extend the healing process or may influence the quality of residual scars.

A specific informed consent is administered by radiotherapist that discusses with the patient all different treatment opportunities, the extent of the disease and the agreement to the procedure; this consent includes the explanation of the procedure and the possible complications of IORT, such as mammary oedema, infection, fat necrosis, seroma, late fibrosis.

The markings on the breast are made with patient in standing position and are discussed with the oncologic surgeon clearly showing the position of the lump and the extension of tissues that have to be removed. The patient is consulted with regard to the amount of breast reduction.

Usually the residual scars are T-inverted shaped; although in small reduction mammoplasty, the scar may be only vertical.

4. Surgical and radiotherapy time

The tumour is removed, according to the preoperative drawings, with at least 1 cm of macroscopic margin and submitted to immediate pathological analysis that ensures an adherence to inclusion criteria of IORT ($T < 2.5$, intraductal component $< 25\%$, negative margins > 5 mm). This is followed by a sentinel node biopsy to exclude positive biopsies. If sentinel node biopsy is positive, a complete axillary dissection is performed and IORT is not applied: such a patient is candidate for traditional radiotherapy.

After tumour resection a mobilization of the mammary gland, from the pectoralis fascia and from the skin, is carried out to obtain a good exposure to the radiation beam. A shielding disk (available in various diameter from 4 to 10 cm) is positioned between gland and pectoralis muscle, in line with the collimator to protect thoracic wall, heart and lung (Fig.5)

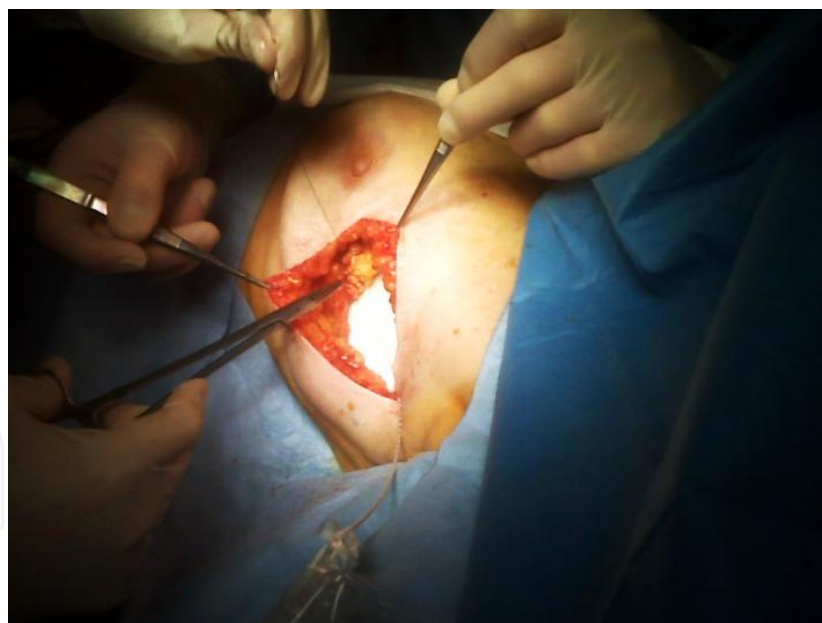


Figure 5. The disk is positioned under the pectoralis fascia and the gland is replaced on it

The disk must be equal or greater in diameter than the collimator which will be used, to realize the best protection of the thoracic wall. The lead disk and collimator diameters are chosen keeping in consideration the ratio of tumour size and breast volume.

The gland is replaced over the disk with temporary and separated stitches so that breast is homogeneous as regard the thickness and receives irradiation in the best way (Fig.6).

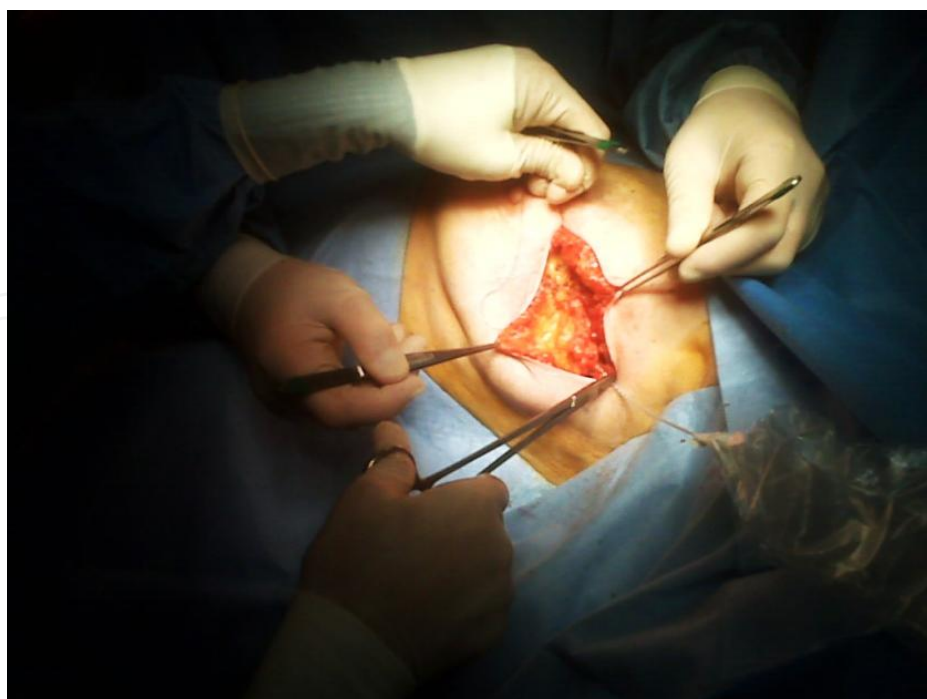

Figure 6. Breast tissues sutured on the disk with temporary stitches

The breast thickness is subsequently measured by graduated needle (perpendicularly inserted through the breast target until the hard surface of the disk can be felt), and the effective electron energy is chosen (Fig. 7).

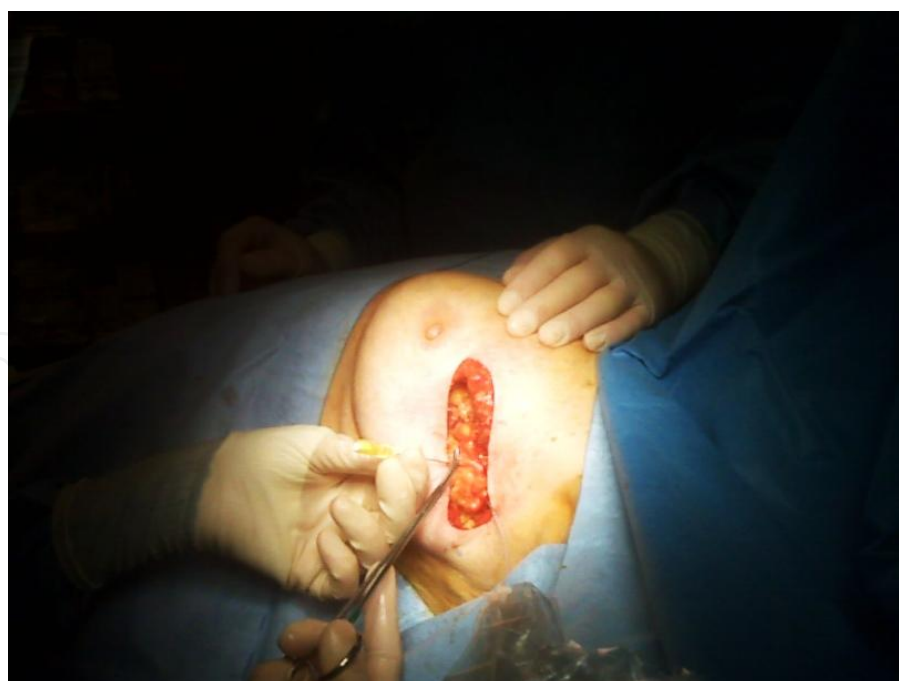

Figure 7. A graduated needle measures gland thickness

A total dose of 18 Gy or 21 Gy is delivered directly to the mammary gland depending on tumour volume according to the pilot study that is ongoing in our Institute.

In-vivo dosimetry may be useful for the optimization of the dose delivered in IORT. This optimization can help to reduce unnecessary large over-dosage regions and allows introducing reliable action levels for in-vivo dosimetry [18].

The sterile polymethyl methacrylate (Perspex; Hitesys SpA, Aprilia, Italy) collimator of the linear accelerator (LINAC) is introduced through the skin incision and placed directly over the breast target, on the tumor bed (Fig.8).

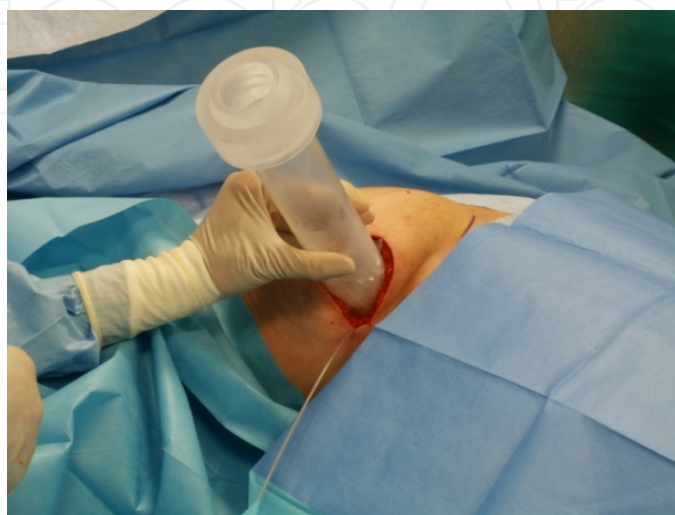

Figure 8. The collimator placed on the gland

The diameter of the collimator must be chosen according to tumor size and breast volume. As an area of 4-5 cm around the tumour has to be irradiated, the most useful collimators are 5 and 6 cm in diameter. An involuntary herniation of the gland into the collimator must be avoided, as it could result in an increased delivered dose to the superficial part of the target. The radiation technologist leads the LINAC into the surgical room; then the connection to the distal part of the applicator is performed to start the dose delivery (Fig. 9).

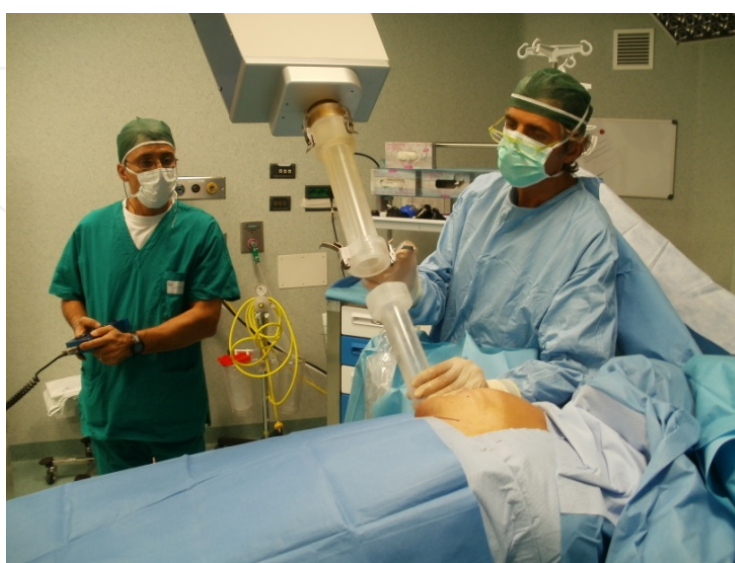

Figure 9. The radiation technologist and the surgeon lead the LINAC to connect to collimator

After collimator positioning, a series of mobile barriers are positioned around the operating table to provide a good shielding of X-rays scattered by the patient; the team then leaves operative room and the irradiation starts (Fig.10).

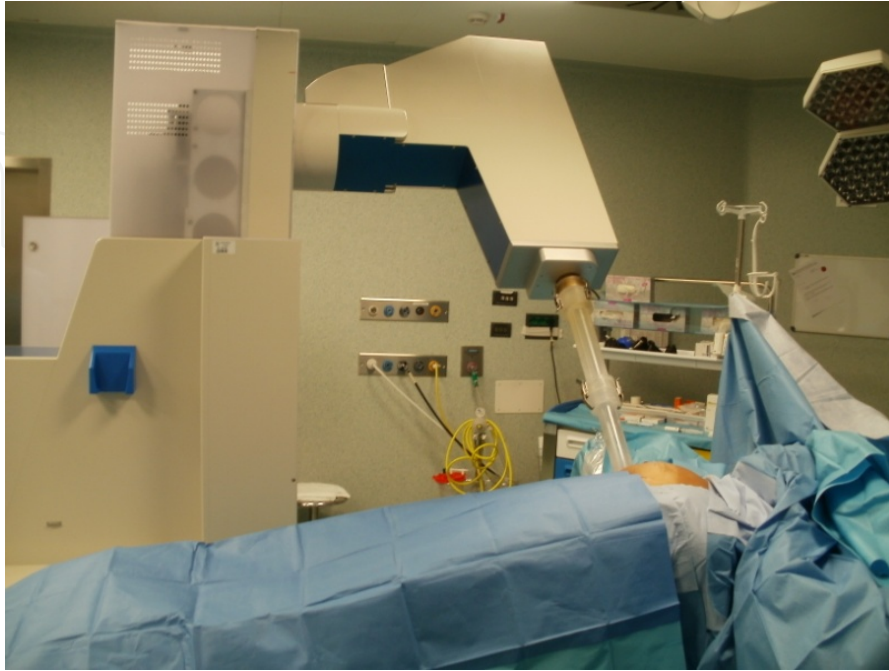


Figure 10. Operative room during radiation therapy

The prescribed dose is given in two steps; by reading the dose delivered during the first step, medical physicist and radiation oncologist can correct the second dose for giving the prescribed dose. The duration of radiation procedure is 2-4 minutes.

The applicator is immediately removed from the surgical field and the LINAC is placed far from the operating table. The shielding disc is removed and mammoplasty proceeds as the preoperative design. A contra-lateral similar reduction technique is concomitantly performed when required.

After three months a simple scale is administered to the patient and to the surgeon, separately, to evaluate post-operative aesthetic result through 4 different values: poor, sufficient, good, excellent. The surgeon's assess about aesthetic outcome results from various aspects: good proportion between size / shape of the gland and chest wall; position of areola-nipple complex on the breast meridian; distance between areola-nipple complex and infra-mammary fold [17]

Our experience as regards: age of patients (mean 61.4; median 63), TNM, amount of removed tissue, type and side of mammoplasty and aesthetic final result, is shown in Table 3.

In 9 patients mammoplasty has been performed on one side, while in the remaining 7 the surgical procedure has been bilateral (Fig. 11, 12, 13, 14, 15, 16); the choice, discussed with the patient during the preoperative consultation, has been usually motivated by psychological reasons.

Age	pTNM	Removed Tissue	Side	Mastoplasty	Patient judgment	Surgeon judgment
50	pT1c/G2-pN0-pMx	50 g	Bilateral	inf-med pedicle	excellent	excellent
61	pT1a/G2-pNx-pMx	55 g	Monolateral	inf-med pedicle	excellent	good
48	pT1c/G1-pN0-pMx	55 g	Monolateral	amputation-graft	excellent	good
49	pT1c/G2-pN0-pMx	27 g	Monolateral	inf pedicle	excellent	good
78	pT1c/G2-pN0-pMx	122 g	Monolateral	inf pedicle	good	good
67	pT1c/G3-pN0-pMx	58 g	Bilateral	inf pedicle	excellent	excellent
68	pT1b/G2-pN0-pMx	60 g	Bilateral	inf pedicle	good	good
53	pT0/G0-pN0-pMx	35 g	Monolateral	inf pedicle	excellent	good
52	pT1c/G2-pN0-pMx	41 g	Monolateral	inf pedicle	good	good
70	pT1c/G2-pN0-pMx	40 g	Monolateral	inf pedicle	excellent	good
72	pT2/G2-pN0-pMx	105 g	Monolateral	superior pedicle	excellent	good
65	pT1a/G2-pN0-pMx	23 g	Monolateral	inf pedicle	excellent	excellent
60	pT1c/G2-pN0-pMx	32 g	Bilateral	inf pedicle	excellent	excellent
49	pT1b/G1-pN0-pMx	44 g	Bilateral	inf pedicle	excellent	excellent
72	pT1b/G3-pN0-pMx	40 g	Bilateral	Inf pedicle	excellent	excellent
69	pT1c/G3-pN0-pMx	320 g	Bilateral	superior pedicle	good	good

Table 3.

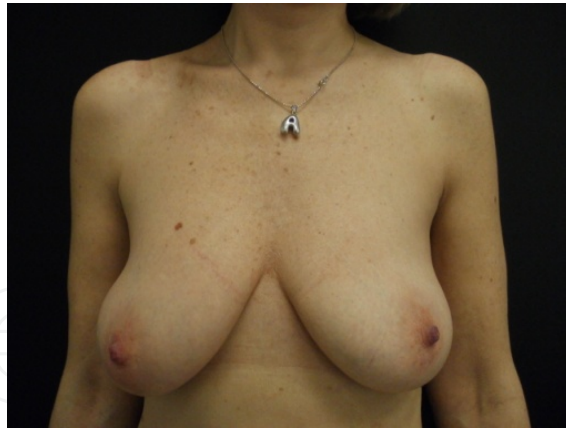

Figure 11.

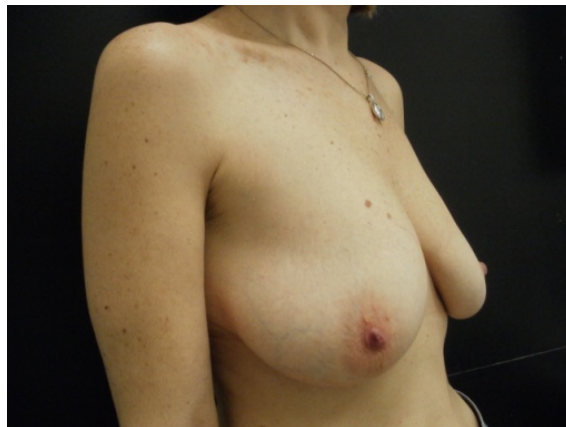

Figure 12.

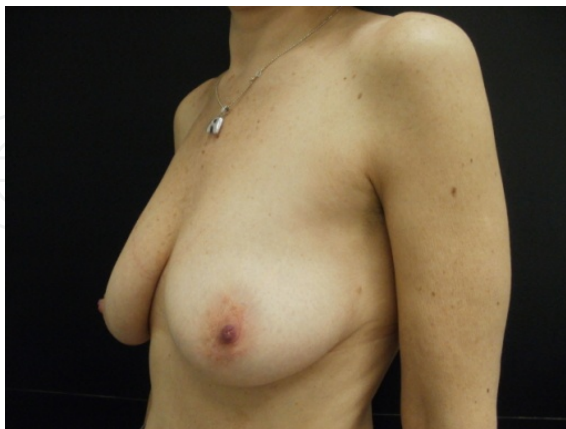

Figure 13. Preoperative view of 50-year old patient pT1c/G2-pN0-pMx ductal carcinoma on the left side; a bilateral inferior pedicle mammoplasty was performed and 50 grams of glandular tissues was removed from each breast

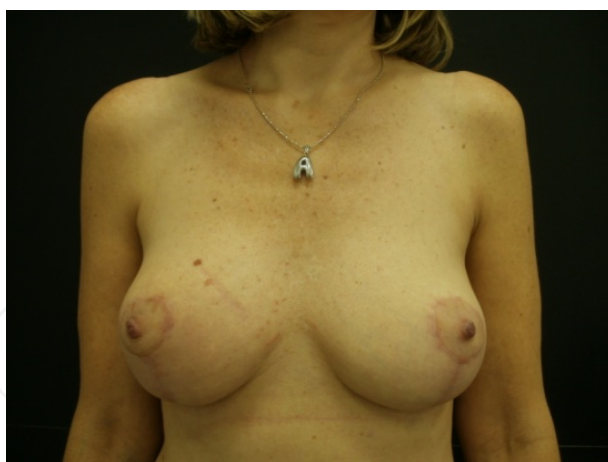

Figure 14.

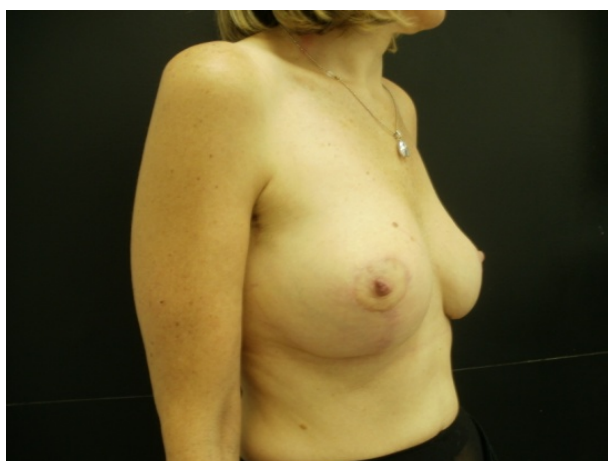

Figure 15.

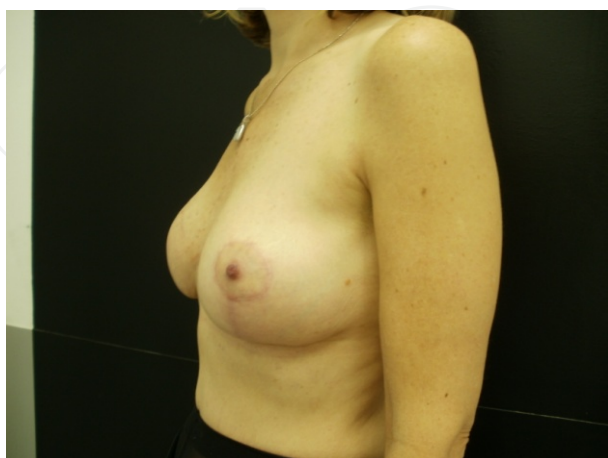


Figure 16. 6-month postoperative view of the same patient

5 of 9 patients with unilateral mammoplasty have required the contra-lateral procedure afterwards (Fig. 17, 18, 19).

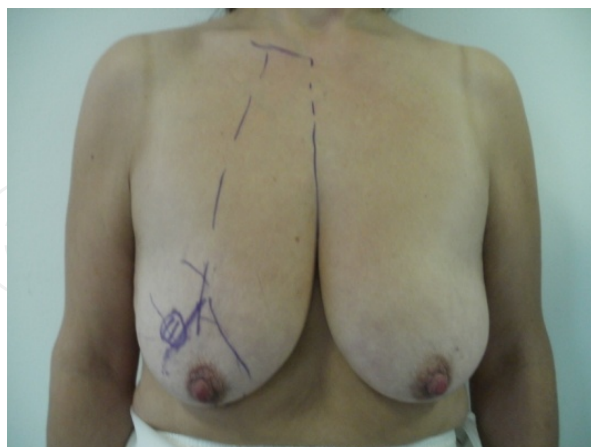

Figure 17. Preoperative view of 49-year old patient with pT1c/G2-pN0-pMx ductal carcinoma on the right side. An inferior pedicle mammoplasty was performed and 27 gram of glandular tissue was removed from right breast.

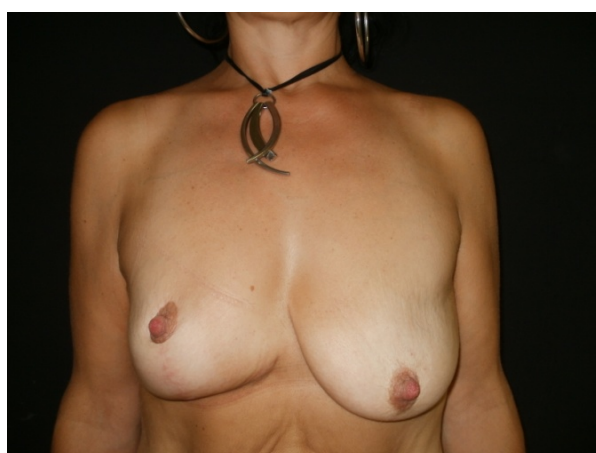


Figure 18. 6-month postoperative view of the same patient

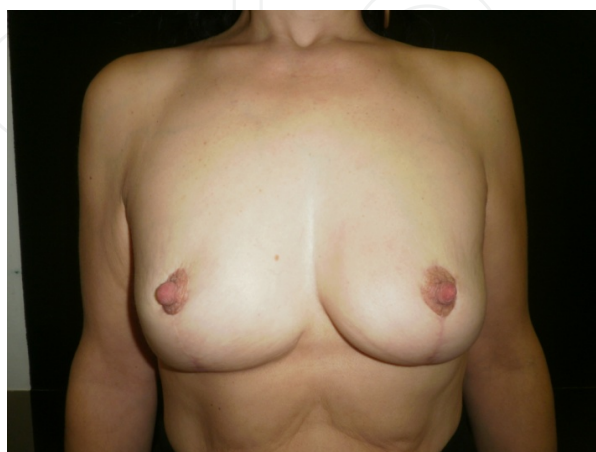

Figure 19. The same patient required reduction mammoplasty on the left side. The same procedure was applied. Final result at 3 months.

The complications observed were: areola-nipple partial loss <25% (1 case) (Fig. 20), liponecrosis (3 cases), partial vertical scar dehiscence (2 cases).

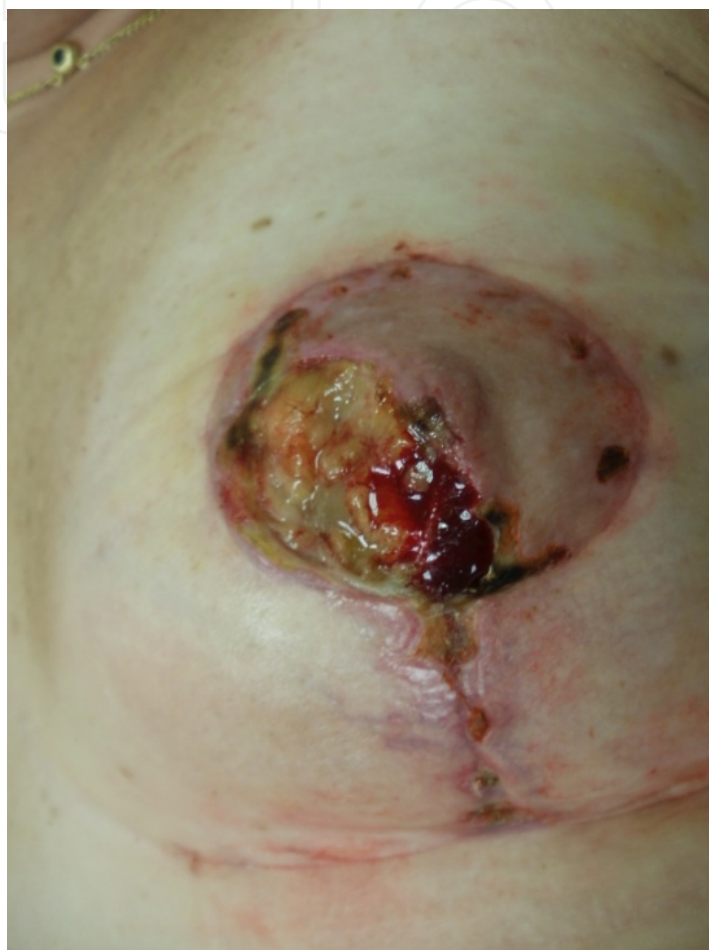

Figure 20. Skin necrosis with partial loss of areola in a 60-year old patient.

Liponecrosis caused discomfort to one patient with local oedema and erythema, but resolved spontaneously without breast deformity, while in 2 patients liponecrosis required surgical debridement in local anaesthesia. Partial areola-nipple loss is made up in local anaesthesia with skin graft from internal part of thigh and the vertical scar dehiscence improved with a revision in local anaesthesia. So far there is no evidence of local recurrence after 9 month medium follow-up (range 6-22 months). The weight of specimen is variable from 23 g to 320 g (mean g 71.13; median g 50). The postoperative result is good for 4

patients and excellent for 12, while the surgeon judged the result good in 10 and excellent in 6. No poor result has been observed.

5. Conclusion

Oncoplastic surgery represents an established new alternative in conservative breast surgery.

Several advantages of mammoplasty plus IORT have been elaborated along with the cautions to be administered during the surgery, as already discussed in our previous preliminary report [19].

The combination between glandular flaps resulting in minimal displacement and IORT, applied on cancer site immediately after lumpectomy and before mobilizing flaps, allows the optimization of irradiation effects and makes unnecessary the use of metal clips, used previously to detect the tumour bed.

The preoperative planning between oncologic surgeon and plastic surgeon is important to understand how much tissue has to be removed and which glandular pedicles can be spared, including the undermining of glandular flaps due to the positioning of a 6-8 cm diameter disk for radiation-therapy. All these aspects must be carefully discussed before projecting reduction mammoplasty in order to reduce postoperative complication such as liponecrosis and areola-nipple necrosis. If the lump is very close to nipple-areola complex, it appears safer, for oncologic and aesthetic reason, to remove it and address a contra-lateral graft.

Postoperative breast shape is evaluated by the patients and the surgeons as good/excellent. The aesthetic results have been, on an average, less satisfactory for the surgeons, especially in cases where unilateral procedure was performed.

It is maybe noteworthy to recognize that a greater number of patients over 68 found the result good, while younger patients found it excellent.

On oncologic viewpoint, we believe that the technique is reliable as long as various principles are respected: the very rigorous criteria of inclusion and the width of margin applied (> 1 cm around the tumour).

On this subject, many other Authors published data about the weight of histological specimen in oncoplastic surgery that are on average greater than those obtained after lumpectomy [20, 21].

Actually, we could verify that in another similar series of patients who were subjected to lumpectomy at the our Department the medium weight of specimen was 24.5 (median 19).

Finally, the wider extension of cutaneous access in comparison with classic lumpectomy plus IORT, permits to use easily larger disks and to apply radiation-therapy on wider extension of residual glandular flaps so as to optimize the procedure.

The technique described is reliable as long as very strict criteria of inclusion is applied. Close collaboration between surgical oncologist, plastic surgeon and radiotherapist is essential in preoperative planning and during surgery in order to obtain adequate tumour resection and good aesthetic result and to minimize postoperative complications.

The excellent cosmetic results and patients satisfaction encourage us to continue on this way, particularly in younger patients.

Author details

Simonetta Franchelli, Michela Massa and Pierluigi Santi

Chirurgia Plastica, IRCCS San Martino- IST, Istituto Nazionale per la Ricerca sul Cancro, Genova - Italy

Marina Guenzi, Renzo Corvò and Giorgia Timon

Oncologia Radioterapica, IRCCS San Martino- IST, Istituto Nazionale per la Ricerca sul Cancro, Genova - Italy

Paolo Meszaros, Davide Pertile and Ferdinando Cafiero

Chirurgia Oncologica, IRCCS San Martino- IST, Istituto Nazionale per la Ricerca sul Cancro, Genova - Italy

Acknowledgement

We thank Valentina Roberto for the drawings and Simone Callegari, MD for technical support during manuscript preparation. A special acknowledgment goes to all staff of the operative room, anesthesiologists and nurses, that supported us in all moments.

6. References

- [1] Veronesi U, Cascinelli N, Mariani L et al. (2002) Twenty-year follow-up of a randomized study comparing breast-conserving surgery with radical mastectomy for early breast cancer. *N Engl J Med* 347(16): 1227–1232.
- [2] Darby S, McGale P, Correa C et al Early Breast Cancer Trialists' Collaborative Group (EBCTCG) (2011) Effect of radiotherapy after breast-conserving surgery on 10-year recurrence and 15-year breast cancer death: meta-analysis of individual patient data for 10,801 women in 17 randomised trials. *Lancet* 378(9804):1707-16
- [3] Law TT, Kwong A. (2009) Surgical margins in breast conservation therapy: how much should we excise? *South Med J*. 102(12): 1234-7.
- [4] Yarnold J, Bentzen S, Coles C and al (2011) Hypofractionated whole-breast radiotherapy for women with early breast cancer: myths and realities. *Int J Radiat Oncol Biol Phys*. 79(1): 1-9
- [5] Rosen PP, Fracchia AA, Urban JA. (1975) Residual mammary carcinoma following simulated partial mastectomy. *Cancer* 35: 739–47

- [6] Holland R, Veling SHJ, Mravunac M, Hendriks JHCL. (1985) Histologic multifocality of Tis, T1-2 breast carcinomas: implications for clinical trials of breast conserving surgery. *Cancer* 56:979-90
- [7] Clarke DH, Lé MG, Sarrazin D, et al. (1985) Analysis of local regional relapses in patients with early breast cancers treated by excision and radiotherapy. Experience of the Institute Gustave Roussy. *Int J Radiat Oncol Biol Phys* 11: 137-45
- [8] Vicini FA, Arthur DW. (2005) Breast brachytherapy: North American experience. *Semin Radiat Oncol* 15: 108-15
- [9] Smith DB, Arthur DW, Buchholz TA, et al. (2009) Accelerated partial breast irradiation consensus statement from the American Society for Radiation Oncology (ASTRO). *Int J Radiat Oncol Biol Phys* 74: 987-1001
- [10] Polgár C, Van Limbergen E, Pötter R et al (2010) Patient selection for accelerated partial-breast irradiation (APBI) after breast-conserving surgery: Recommendations of the Groupe Européen de Curiethérapie-European Society for Therapeutic Radiology and Oncology (GEC-ESTRO) breast cancer working group based on clinical evidence. *Radiother Oncol.* 94(3): 264-73
- [11] Offersen BV, Overgaard M, Kroman N et al (2009) Accelerated partial breast irradiation as part of breast conserving therapy of early breast carcinoma: A systematic review. *Radiother Oncol.* 90(1): 1-13
- [12] Vaidya JS, Joseph DJ, Tobias JS et al (2010) Targeted intraoperative radiotherapy versus whole breast radiotherapy for breast cancer (TARGIT-A trial): an international, prospective, randomised, non-inferiority phase 3 trial. *Lancet* 376(9735): 91-102
- [13] Orecchia R, Leonardi MC (2011) Intraoperative radiation therapy: is it a standard now? *The Breast* 20 S3, 111-115
- [14] Veronesi U, Orecchia R, Luini A et al (2010) Intraoperative radiotherapy during breast conserving surgery: a study on 1,822 cases treated with electrons *Breast Cancer Res Treat* 124: 141-151
- [15] Leonardi MC, Maisonneuve P, Mastropasqua MG et al (2012) How do the ASTRO Consensus Statement Guidelines for the Application of Accelerated Partial Breast Irradiation Fit Intraoperative Radiotherapy? A Retrospective Analysis of Patients Treated at the European Institute of Oncology. *Int J Radiat Oncol Biol Phys.* 13
- [16] Rees and La Trenta (1992) *Aesthetic Plastic Surgery*, W.B. Saunders Company pp. 926-987
- [17] Robert Goldwyn, (1990) *Reduction Mammoplasty*, Little, Brown Company
- [18] Agostinelli S, Gusinu M, Cavagnetto F et al (2012) On-line optimization of intraoperative electron beam radiotherapy of the breast *Radiother Oncol.* 17
- [19] Franchelli S, Meszaros P, Guenzi M, Corvó R, Pertile D, Massa M, Belgioia L, D'Alonzo A, Cafiero F, Santi P. (2011) Preliminary experience using oncoplastic techniques of reduction mammoplasty and intraoperative radiotherapy: report of 2 cases. *Aesthetic Plast Surg.* 35(6): 1180-3.
- [20] Masetti R, Di Leone A, Franceschini G, et al (2006) Oncoplastic techniques in the conservative surgical treatment of breast cancer: an overview. *Breast J* 12:174-80

- [21] Clough KB, Lewis JS, Couturaud B, Fitoussi A, Nos C, Falcou MC. (2003) Oncoplastic techniques allow extensive resections for breast-conserving therapy of breast carcinomas *Ann Surg.* 237(1): 26-34.

IntechOpen

IntechOpen