

# We are IntechOpen, the world's leading publisher of Open Access books Built by scientists, for scientists

6,900

Open access books available

186,000

International authors and editors

200M

Downloads

Our authors are among the

154

Countries delivered to

TOP 1%

most cited scientists

12.2%

Contributors from top 500 universities



WEB OF SCIENCE™

Selection of our books indexed in the Book Citation Index  
in Web of Science™ Core Collection (BKCI)

Interested in publishing with us?  
Contact [book.department@intechopen.com](mailto:book.department@intechopen.com)

Numbers displayed above are based on latest data collected.  
For more information visit [www.intechopen.com](http://www.intechopen.com)



---

# **Percutaneous Transvenous Embolization of Intracranial Dural Arteriovenous Fistulas with Detachable Coils and/or in Combination with Onyx**

---

Xianli Lv, Youxiang Li and Chuhan Jiang

Additional information is available at the end of the chapter

<http://dx.doi.org/10.5772/56732>

---

## **1. Introduction**

Intracranial dural arteriovenous fistulas (DAVFs) represent 10 to 15% of intracranial arteriovenous malformation. [1-3] Published classifications of DAVFs (e.g., Cognard's classification) are based on the pattern of drainage, for estimation of bleeding risks. [4] Venous drainage patterns allow classification of DAVFs into five types as follows: Type I, located in the main sinus, with antegrade flow; Type II, located in the main sinus, with reflux into the sinus (Type IIa), cortical veins (Type IIb), or both (Type IIa+b); Type III, with direct cortical venous drainage without venous ectasia; Type IV, with direct cortical venous drainage with venous ectasia; Type V, with spinal venous drainage (Table1). Depending on the DAVFs location and the venous drainage, clinical presentations range from asymptomatic to symptomatic [5-11], with pulse-synchronous bruit, headaches, neurological deficits, venous hypertensive encephalopathy with dementia, or intracranial hemorrhage resulting from venous hypertension.

The decision to treat is based on the venous drainage pattern, the natural history of the lesion, the severity of presenting symptoms, the patient's general condition, angiographic features, the location of the DAVF, and the morbidity and mortality rates of the procedure being considered. The goals of treatment are the prevention of risks and the elimination of symptoms caused by the arteriovenous shunt. Because of the bleeding risk, intracranial DAVFs with retrograde cortical drainage often require an anatomic cure. They can be treated with different modalities, such as endovascular procedures with transve-

nous and transarterial [2, 3, 5, 11-36], surgery [6-8, 35, 37-43], gamma knife surgery [31, 44-47], or combinations of the three [7, 24, 48-50]; in selected cases, the lesions can be treated conservatively [20].

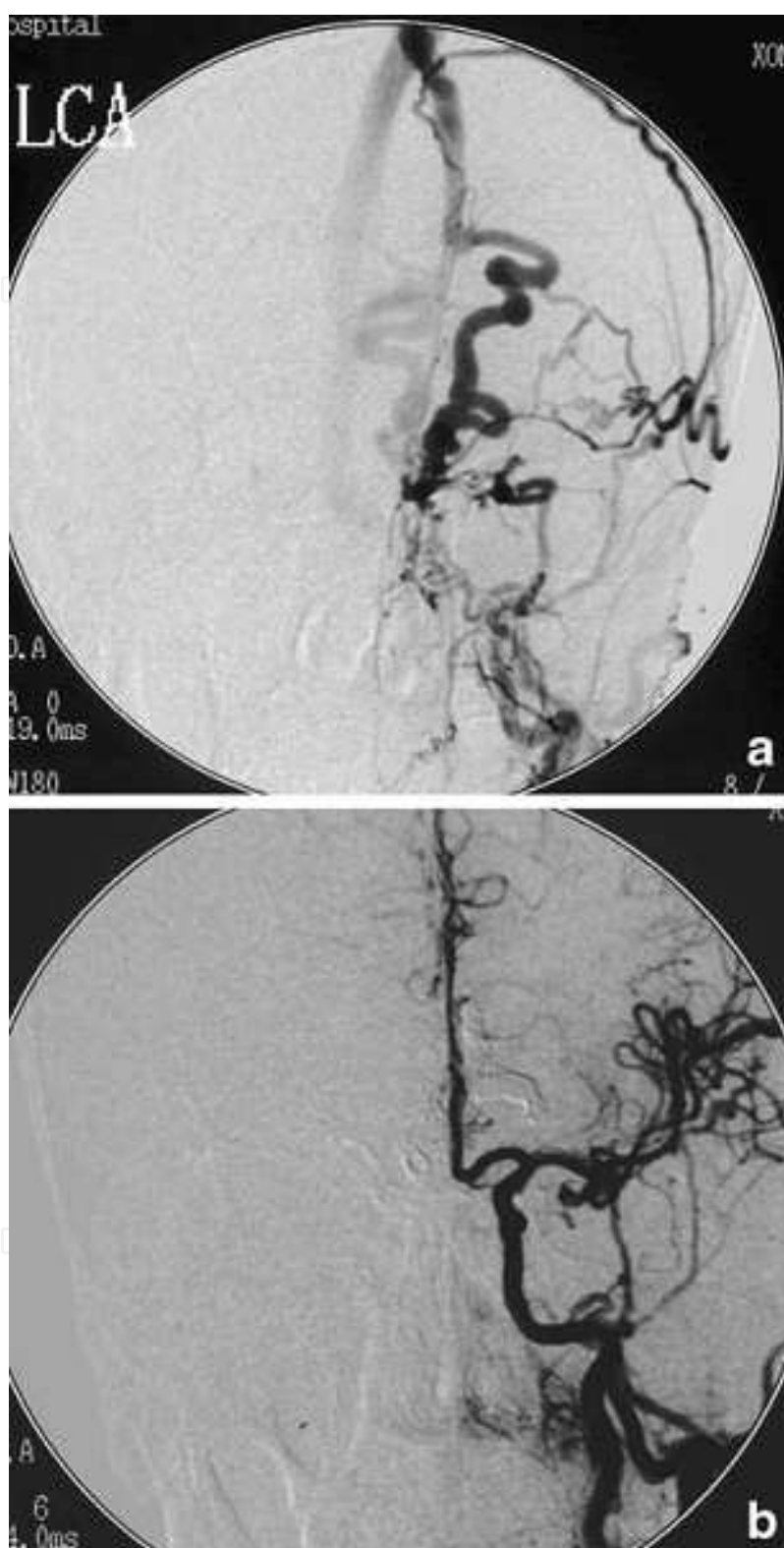
## 2. Transvenous technique

The embolization of DAVFs is performed under general anesthesia, preferably under supervision of an experienced neuroanesthesiologist. Transvenous catheterizations and embolizations are often lengthy procedures (2–4 h), during which the typically elderly patients would have difficulties remaining still on an angiographic table. General anesthesia with endotracheal intubation is therefore widely used in most centers in the world, as it also allows for safer monitoring and easier management in cases of intraprocedural complications such as rupture and hemorrhage. Bilateral selective internal carotid artery (ICA) and external carotid artery (ECA) angiography and vertebral artery (VA) angiography were performed for all patients, for assessment of the feeding arteries, the fistula sites and the venous drainage. The arteriovenous shunts were approached via the venous route. We first placed 6-French sheaths in the femoral artery and vein. A 5-French catheter in the carotid artery allowed observation of the shunt, acquisition of roadmaps, and angiographic monitoring of the procedure. A second 5-French catheter was placed in the jugular vein. A microcatheter (Marathon/Echelon, MTI-EV3, Irvine, CA, USA) was navigated coaxially via different venous approaches. The microguidewire (Mirage/Silverspeed10, MTI-EV3, Irvine, CA, USA; Transend0.014, Boston Scientific, USA) was then carefully introduced and advanced to the fistula portion, followed by the microcatheter. Subsequently, the draining vein or sinus was packed using detachable platinum coils or a combination with Onyx, using real-time digital subtraction fluoroscopic mapping.

## 3. Case reports (Figs.1-8)

### 3.1. Case report I: Ethmoidal DAVF (Fig.1)

A 48-year-old man with a DAVF of the anterior rianal fossa supplied by branches of the anterior ethmoidal arteries, the septal branches of the sphenopalatine and the middle meningeal arteries with venous drainage via dilated frontopolar veins to the superior sagittal sinus. A guide catheter was inserted into the jugular vein transfemorally and a microcatheter (Echelon10, MTI-ev3, Irvine, CA) was navigated over a guidewire (Silver-speed, MTI-EV3, Irvine, CA, USA) to the frontal part of the superior sagittal sinus. The microcatheter was gently advanced into the primary draining vein. Once the tip of the microcatheter had reached the fistula point, embolization was performed with detachable platinum coils until transarterial angiography showed occlusion of the DAVF (Fig. 1).



**Figure 1.** a, Left ECA angiogram shows the fistula fed by the left sphenopalatine artery and the left middle meningeal artery. b, Frontal angiogram following injection of the left common carotid artery (CCA) with coils placed in bilateral dilated frontopolar veins shows occlusion of the fistula.



### 3.2. Case report II:Cavernous DAVF (IPS) (Fig.2)

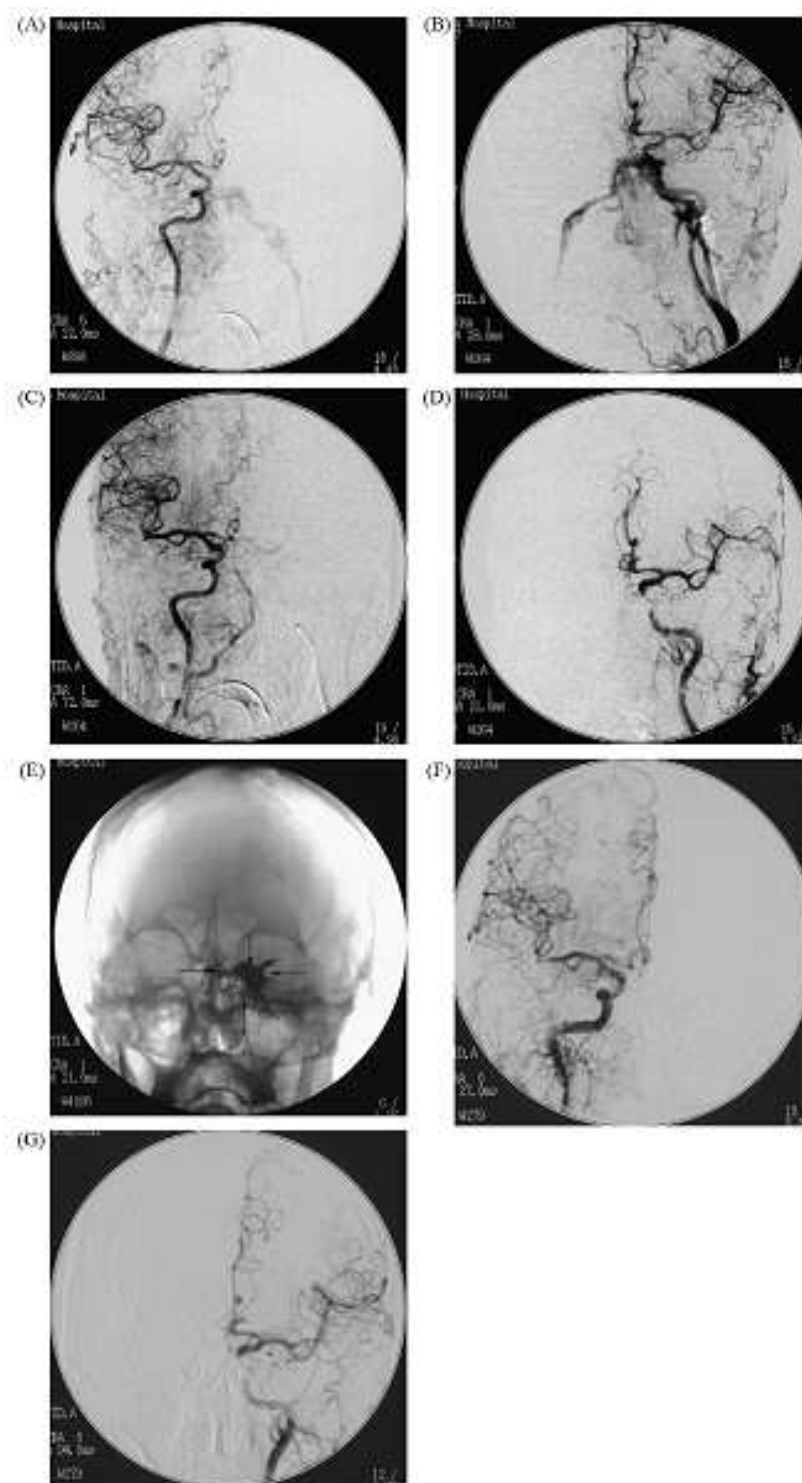
A 54-year-old man presented with blepharoptosis, diplopia and chemosis for 2 months. Cerebral angiograms were obtained and showed a DAVF principally fed by the left meningohypophyseal trunk with additional small branches of the right ICA. Venous outflow emptied into the left inferior petrosal sinus (IPS) and the left superior ophthalmic vein (SOV). Recommendation was made for transvenous embolization of this lesion. Under general anesthesia, catheterization was performed via transfemoral approach using standard coaxial techniques. Systemic heparinization was achieved during the procedures with heparin 3000U bolus followed by 1000U of heparin every hour. A 5-French diagnostic catheter with continuous heparinized flush was positioned in the left ICA for selective control angiograms. The late venous phase of the left ICA angiogram revealed the IPS on this side. Therefore, this IPS was chosen for endovascular approach. A 5-F guiding catheter was placed and, using road mapping technique and fluoroscopic guidance, a microcatheter (Echelon14, MTI-EV3, Irvine, CA, USA) was advanced over a guidewire (Transend0.014, Boston Scientific) into the left IPS up to the left cavernous sinus (CS). Three hydrocoils (two 5×12, one 6×15; MicroPlex) were packed first to reduce the venous outflow towards the SOV. Then, under biplane roadmapping, the catheter was slowly flushed with 0.25ml of DMSO over 40 seconds and this was followed by injection of Onyx (MTI-EV3, Irvine, CA, USA). After 2.3ml of Onyx-34 was injected into the cavernous sinus, we attempted to inject Onyx-18. In the meantime caution was exerted to avoid inadvertent embolization of the left ICA during the slow injection of Onyx. Patency of the left ICA was checked frequently during the intermittent injection of the embolic material. The amount of injected Onyx-18 was 2.6ml. The procedure was completed as soon as a control angiogram revealed complete occlusion of the DAVF. The patient's chemosis improved within the next day, but blepharoptosis and diplopia were not improved. The patient was discharged on the postprocedure day 3.

### 3.3. Case report III :Cavernous DAVF (Cross-over approach via IPS) (Fig.3)

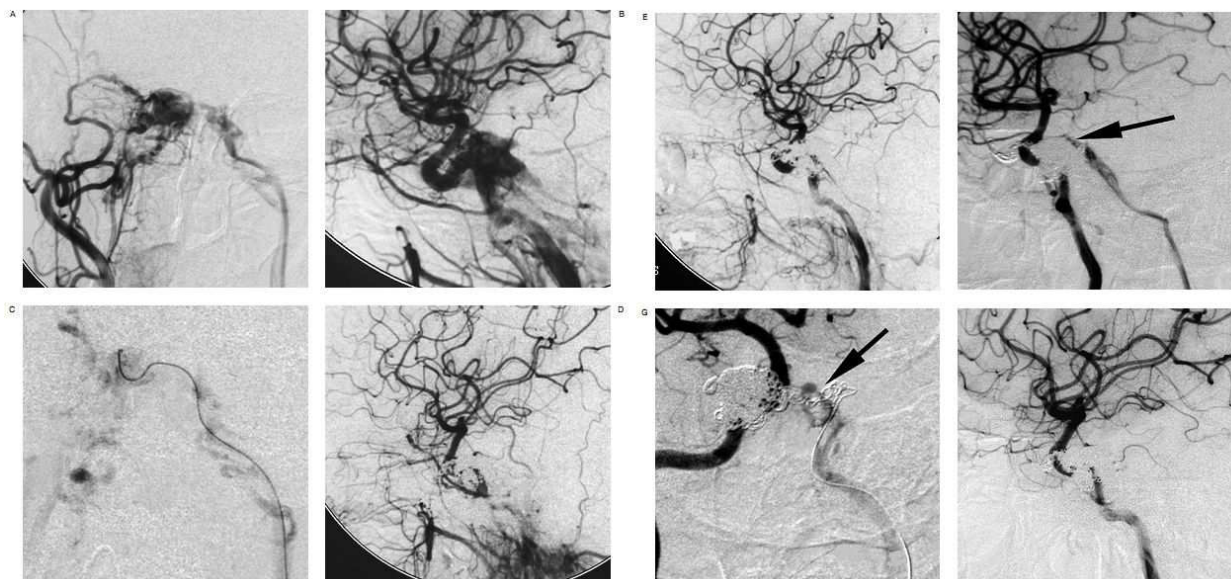
A 44-year-old woman demonstrated right proptosis and VIth cranial nerve palsy and excessive pulsatile bruits. Cerebral angiography revealed a DAVF of the right CS. Angiography of the right CCA demonstrated persistent filling of the left IPS (Figure 1A). Therefore, a transvenous approach was chosen. The microcatheter was navigated through the left IPS and the intercavernous sinus to the right CS (Figure 1C). The right CS was occluded with 28 standard coils (Figure 1D, E). However, the pulsatile tinnitus was still persistent at six-month follow-up study. Control angiography demonstrated recurrence of the fistula (Figure 1F) and the same procedure was performed (Figure 1G). The residual fistula was occluded completely by another six standard coils (Figure 1H).

### 3.4. Case report IV:Cavernous DAVF (FV-SOV) (Fig.4)

A 36-year-old female was referred to our hospital again after incomplete transarterial embolization of a cavernous DAVF. On admission, she suffered from slight exophthalmos and chemosis of her right eye. A cerebral angiogram demonstrated a residual arteriovenous shunt of the right CS supplied by the right meningohypophyseal trunk draining to the right SOV.



**Figure 2.** Right ICA angiogram, anteroposterior projection (A), left ICA angiogram, anteroposterior projection (B), show fed by both ICAs, mainly drained to left IPS and left SOV. Right ICA angiogram, anteroposterior projection (C) and left ECA angiogram, anteroposterior projection (D), after embolization showing the DAVF is completely occluded. (E) Skull X-ray film after embolization, anteroposterior projection, showing the Onyx cast (arrows). The follow-up angiographic study after 7 months, right CCA (F) and left CCA angiogram (G), demonstrated no recanalization of the fistula.

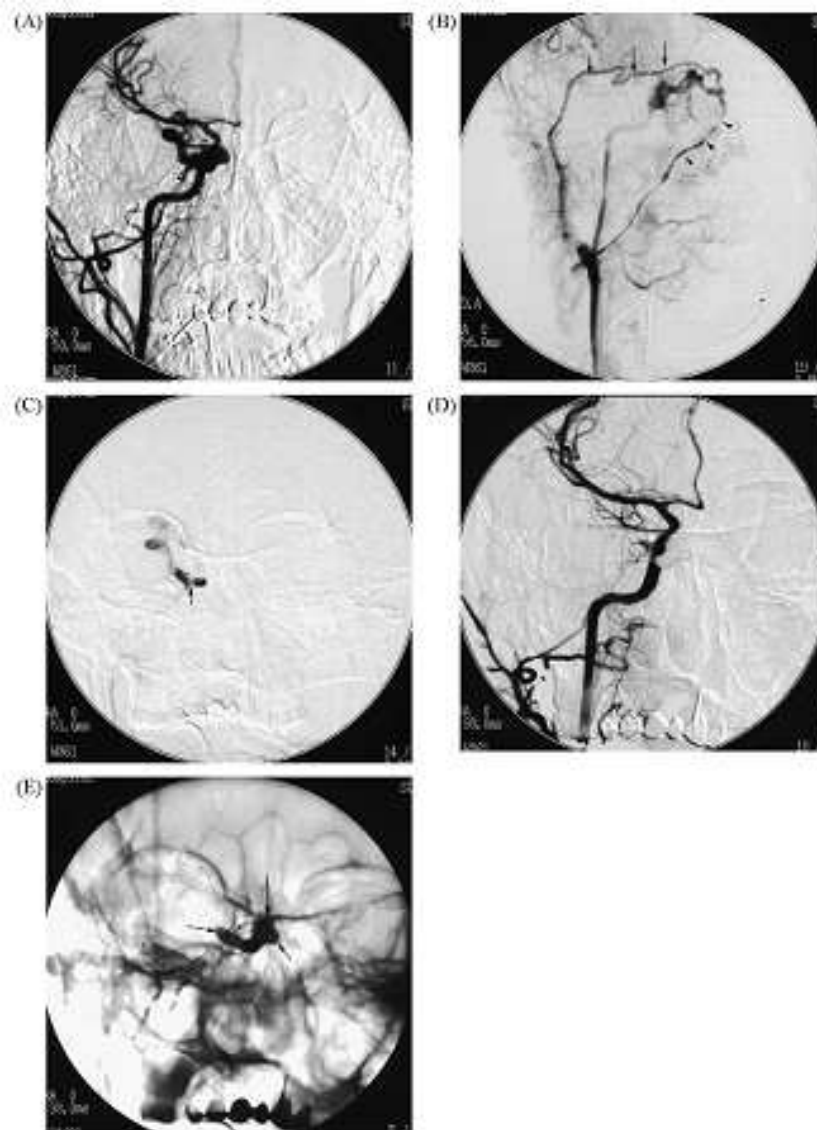


**Figure 3.** Right CCA angiogram, anteroposterior projection (A), left CCA angiogram, lateral projection (B), showing a CDAVF fed by both internal and external carotid arteries, mainly drained to the left IPS and the right SOV. Frontal superselective angiogram of the right CS (C), showing the microcatheter positioned close to the fistula site. After embolization, anterograms of the right common carotid artery (lateral view) (D) and left common carotid artery (lateral view) (E), demonstrating complete occlusion of the fistula. F, six months later, lateral angiogram of the right ICA, showing persistent filling of the residual fistula (arrow). G, occlusion of the intercavernous sinus (arrow), with several standard coils. H, angiogram of the right ICA (lateral view) after complete embolization of the right-side fistula.

The right facial vein and the right superficial temporal vein were demonstrated angiographically draining the fistula. Because the approach of superficial temporal vein was longer and tortuous, we decided to approach the right CS through the right facial vein. A 5-French guiding catheter (Envoy; Cordis Endovascular System) was advanced through the right internal jugular vein into the right common trunk of facial and retromandibular veins. A diagnostic catheter was placed in the right ICA via the left common femoral artery. A Marathon microcatheter was advanced through the guiding catheter and through the right facial vein into the right SOV. After traversing the SOV, we gain access to the right CS. Occlusion of the fistula was accomplished by filling the right CS with 1.5ml Onyx-34. In the meantime caution was exerted to avoid inadvertent embolization of the ICA during the slow injection of Onyx. Patency of the right ICA was checked frequently during the intermittent injection of the embolic material. There were no complications during the procedure. She was discharged 3 days after the procedure with symptoms improved.

### 3.5. Case report V: Cavernous DAVF (Direct puncture of SOV) (Fig.5)

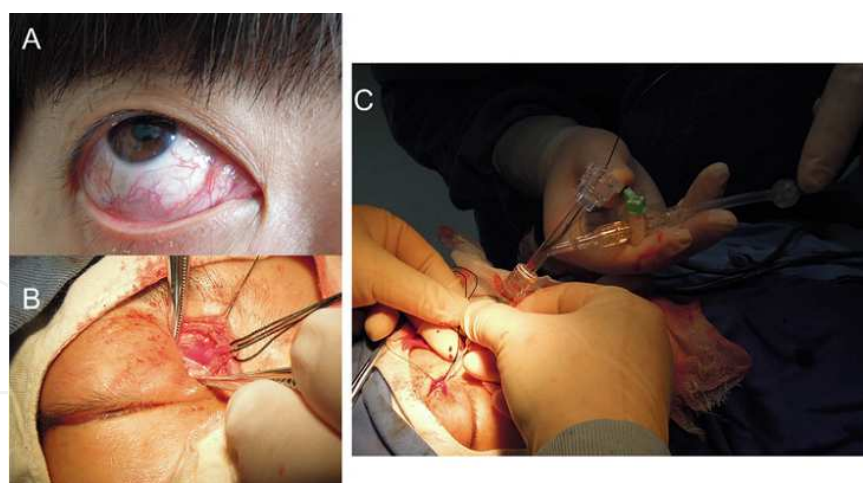
A 43-year-old woman had a 2 month history of intracranial bruits, proptosis and chemosis of the right eye. Her vision was normal. An angiogram revealed a CS DAVF draining anteriorly into the enlarged right SOV. The fistula was fed by the meningeal branches of the right ECA and ICA, making it a Barrow type D DAVF. Because of progressive ocular symptoms and intracranial bruits, transvenous embolization was indicated. No IPS was opacified from either



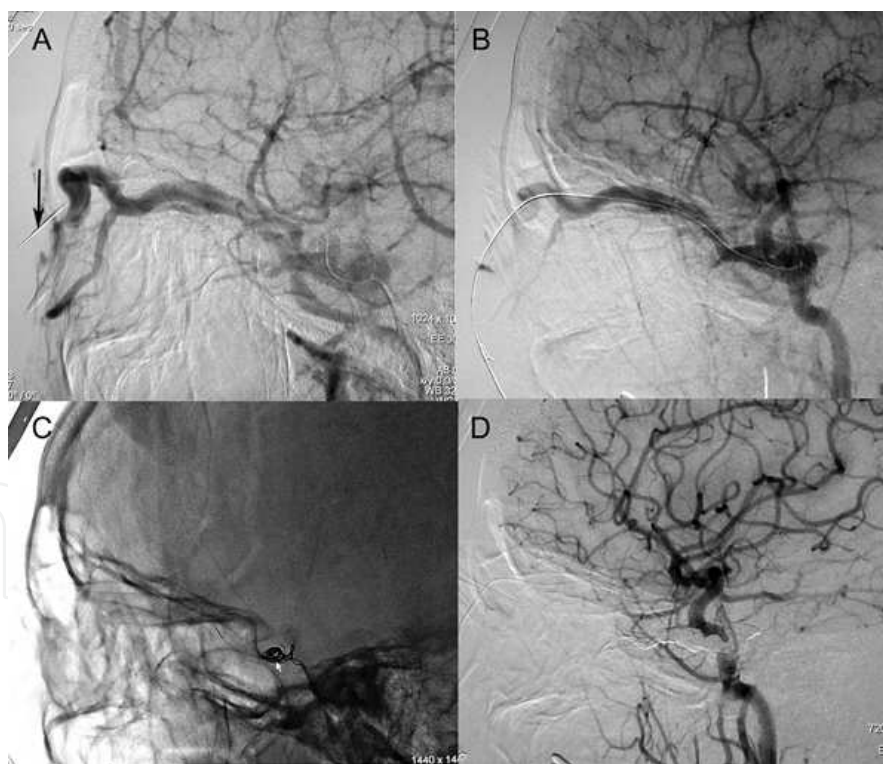
**Figure 4.** Right CCA angiogram, frontal projection (A), showing a DAVF involving the right CS fed by the left meningo-hypophyseal trunk and the right internal maxillary artery. Venous phase of the right CCA (B) demonstrated the venous drainage via the right IPS, the superficial temporal vein and the facial vein. Superselective angiography (C) showed the microcatheter in the right CS. Right CCA angiogram, frontal projection (D), showing the right CS completely packed. Skull X-ray film, frontal projection (E) showing the deposited Onyx in the right CS.

side, and cannulation of either IPS or the facial vein was not successful. Therefore, we recommended surgical exposure and direct cannulation of the right SOV, which was performed in the angiographic suite, as detailed above. A microcatheter was introduced through the trocar sheath, and several platinum coils were deployed into the CS to reduce the flow volume of the fistula. Then, Onyx was used to obliterate the CS until there was no filling of the CS. Final follow-up angiograms showed complete obliteration of the fistula. Postoperatively, her vision remained normal and the proptosis and chemosis improved within 5 days, and the patient's intracranial bruits also resolved. A 3 month follow-up angiogram showed durable complete occlusion of the CSDF. The eyelid incision healed well with excellent cosmesis.





**Figure 5.** A) The patient presented with proptosis, chemosis and intracranial bruits caused by a cavernous sinus dural fistula. (B) A 2 cm subbrow incision was made in the upper medial eyelid crease on the affected side. A 10-15 mm segment of the SOV was isolated and controlled with 3-0 silk sutures and an intraoperative angiogram was performed to confirm the SOV. (C) An 18 size trocar was used to acupuncture the SOV, then moving the needle core, the trocar sheath was connected to a Y shaped valve. An Echelon-10 microcatheter was introduced through the tube.



**Figure 6.** A) Later cerebral angiogram showing a CS dural fistula (Barrow type D) with anterior venous drainage in an enlarged right SOV. Note a metal landmark (arrow) was used to confirm the exposed SOV by transfemoral angiography. (B) The affected cavernous sinus was catheterized with an Echelon-10 microcatheter. Multiple coils (C) and Onyx (D) were deployed through the microcatheter to obliterate the cavernous sinus and proximal portion of the right SOV. The fistula was cured.

3.6. Case report VI:Transverse sigmoid sinus DAVF (Fig.7)

A 56-year-old man with headaches and pulsatile tinnitus demonstrated a left TSS Cognard Type IIa DAVF (Table1). An ophthalmological examination revealed bilateral papilledema. Cerebral angiography demonstrated multiple feeders arising from the left ECA and ICA and basal artery system with a parallel venous channel. One transarterial and one transvenous embolization of the TSS DAVF were performed. These procedures and occlusion of the ECA feeders significantly reduced the size of the fistula. After transvenous embolization of the left TSS, control angiography demonstrated obliteration of the parallel channel, with preservation of the patent parent sinus (Cognard Type I). During the subsequent months the patient’s tinnitus was in stable condition and no further neurological symptoms were noted, ophthalmological examination was not available.

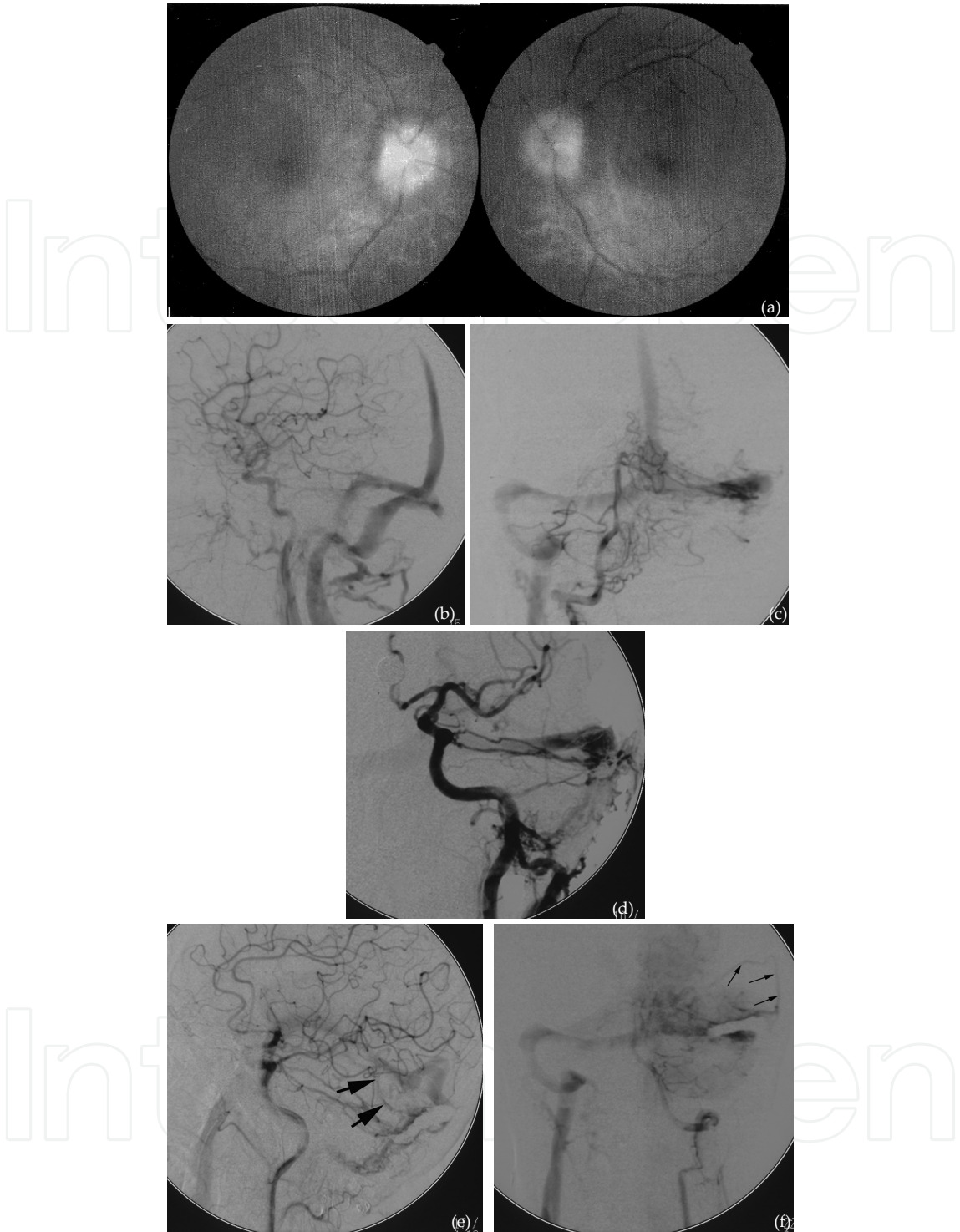I Venous drainage into dural venous sinus with antegrade flow
IIa Venous drainage into dural venous sinus with retrograde flow
IIb Venous drainage into dural venous sinus with antegrade flow and CVR
IIa+b Venous drainage into dural venous sinus with retrograde flow and CVR
III Venous drainage directly into subarachnoid veins (CVR only)
IV Type III with venous ectasias of the draining subarachnoid veins

Table 1. Cognard classification of dural AVS (1995)

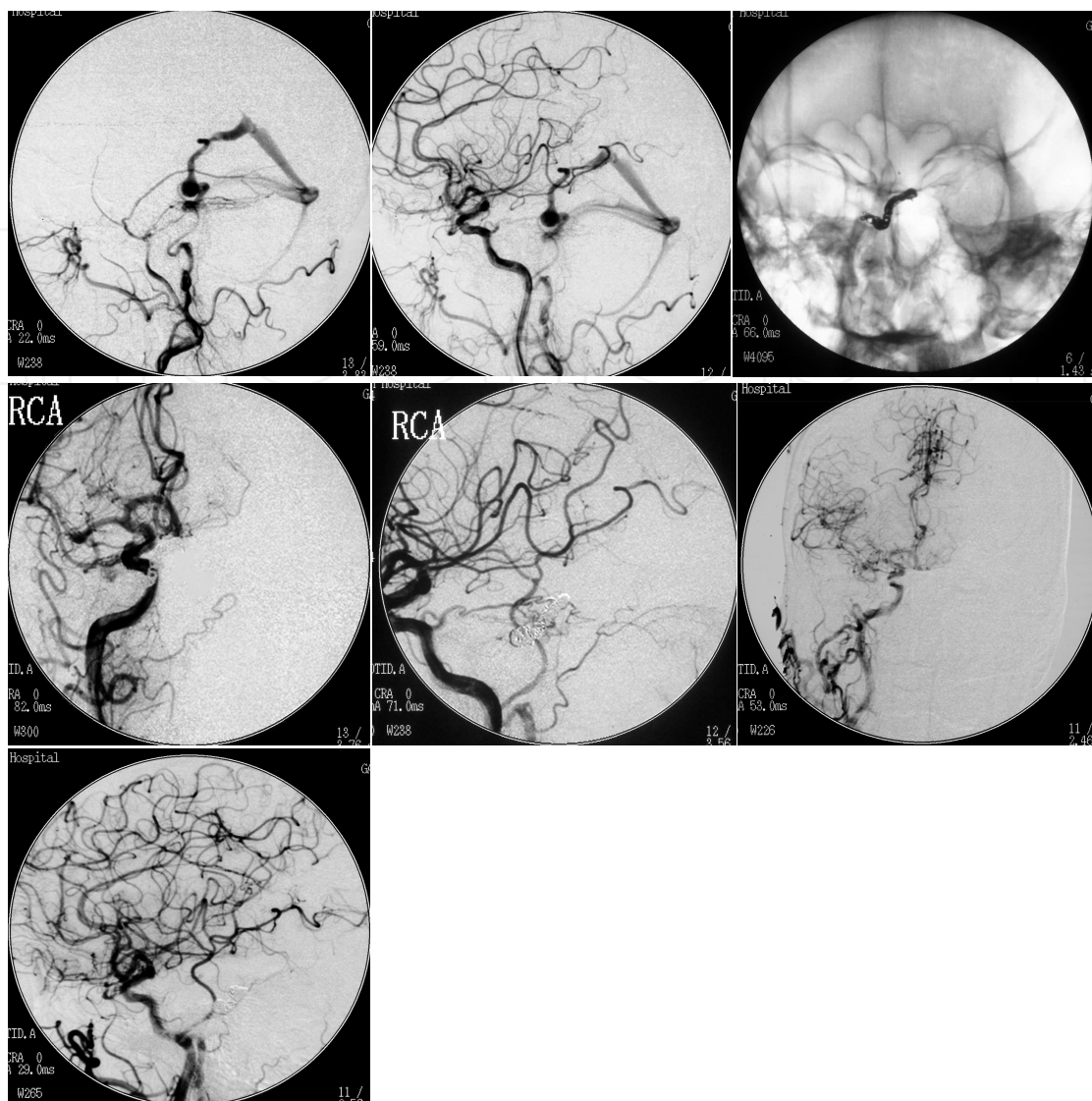
3.7. Case report VII:Tentorial DAVF (Fig.8)

A 70-year-old man presented with a headache of sudden onset and vomiting. Computed tomography demonstrated diffuse subarachnoid hemorrhage and a venous aneurysm at the right petrous apex. Selective right ECA and ICA angiography revealed a dural fistula supplied by branches of the right middle meningeal artery, ascending pharyngeal artery and tentorial branches of the right ICA. The fistula drained in the region of the right petrosal venous complex and thence into the basal vein to the straight sinus. There was a venous aneurysm appropriately 1 cm in diameter on the basal vein. We initially attempted ECA embolization. A microcatheter was placed in the posterior branch of the right middle meningeal artery and embolizing with 5-0 (1.0-1.5cm long) sutures. The ECA suppliers were occluded. But the fistula was still persistent and fed by the branches of the right asending pharyngeal artery and right ICA. We therefore decided on endovascular treatment using a transvenous approach. A microcatheter was placed in the right jugular vein was catheterized and a microcatheter was directed through the straight sinus into the basal vein. The venous varix was crossed with care and the tip of the microcatheter was placed at the site of the fistula in the petrosal venous complex. Using the venous catheter, five EDCs were then placed at the site of the fistula via the transvenous microcatheter. Angiography revealed complete occlusion of the fistula on both the ECA and ICA injections. The patient made an uneventful recovery. After 4 months, the follow-up angiograms of bilateral CCAs confirmed the complete obliteration and the patient demonstrated no symptoms.





**Figure 7.** A, an ophthalmological examination revealed bilateral papilledema. B, arteriogram of the left CCA (arterial phase, lateral view), showing multiple feeders arising from the ICA and ECA. C, arteriogram of the right vertebral artery (arterial phase, frontal view), showing multiple feeders arising from the vertebral artery. D, the microcatheter was navigated into the left TSS via the right IJV-TSS. E-F, arteriograms (lateral view) of the left CCA (E) and left VA. The residual fistula was Cognard Type I with parallel venous channel was coiled and the parent sinus was patent, with preservation of the venous outflow (arrows) of the temporal lobe through the vein of Labbe.



**Figure 8.** A, Lateral DSA of right ECA shows the fistula supplied by branches of the right middle meningeal artery and ascending pharyngeal artery. B, Lateral DSA of the right CCA shows the meningo-hypophyseal trunk supplying the DAVF and the suppliers from the right meningeal artery were occluded. C, During procedure, the skull X-ray film shows the delivery of the detachable coils. Postprocedure angiograms of right CCA, frontal (D) and lateral (E), demonstrated complete obliteration of the fistula. Four-month after endovascular treatment, lateral DSAs of right CCA (F) and left CCA (G) show permanent occlusion of DAVF.

## 4. Discussion

Depending on their venous drainage patterns, intracranial DAVFs can cause headaches, dementia, chemosis, proptosis, bruit, and, rarely, infarction or hemorrhage. The data of our patients confirmed previous studies. [3, 6, 11, 37, 45, 51, 52] The clinical presentation is closely related to the degree of shunting, cerebral venous hypertension, and the pattern of venous drainage, with or without impaired cortical function. [1] Despite spontaneous remission,

which occurs in 9.4 to 50% of cases, according to the literature, [20] treatment is indicated in cases with cortical drainage (Cognard Type IIb or greater), hemorrhage, progressive neurological deficits, or intractable headaches or tinnitus. Although cure rate of DAVFs of transarterial embolization has been promoted by Onyx, it is limited in smaller arteriovenous fistula DAVFs. [33] Transvenous embolization is still a good option for DAVFs with multiple feeding arteries, especially for transarterial embolization cannot be cured. [17-19] When transvenous catheterization is possible, transvenous embolization is associated with a high rate of permanent long-term occlusion. Occlusion can be achieved with placement of coils, via a transvenous route. Isobutyl-2-cyanoacrylate embolization, particles of polyvinyl alcohol or a detachable balloon have been used to pack the cavernous sinus before advancement of GDC.

## 5. Transvenous embolization of CS

There are different transvenous route to the CS, i.e., by way of the IPS, contralateral IPS, basilar plexus, or circular sinus, through the facial vein, angular vein, and SOV, or through the pterygoid plexus. [10, 12-14, 17, 23-28, 32, 50-54] To achieve complete occlusion, the cavernous sinus was tightly packed with GDC. This tight packing may have accounted for the intense nausea and vomiting. Transient VIth or IIIrd nerve palsy following coil embolization for cavernous DAVF are well-known events. [52] The complex nature of the fistula, the unexpected hardship in the placement of detachable coils, and our previous experience with Onyx in the treatment of DAVFs promoted us to use Onyx in the treatment of our patient. [11, 17, 18]

## 6. Transvenous embolization of DAVFs in other locations

For DAVFs in the ACF, we prefer transvenous procedure with softest EDC and free coils to fit the draining frontal veins and to minimize the risk of damage and rupture of the frontal veins, appreciating the risk of visual compromise from embolic occlusion of the central retinal artery. Although venous approach through the elongated, ectatic, and potentially fragile pial veins is considered difficult and risky, several cases of tentorial DAVF have been treated by transvenous embolization. [14, 19, 21]

If the affected TSS is isolated or exhibits prominent retrograde drainage to the cortical veins and is not a functional part of the venous circulation, then sinus occlusion via an endovascular. If there was anterograde flow in the vein of Labbe in a case of a lateral sinus fistula, the vein of Labbe should be spared after transvenous embolization of the TSS.

Kubo et al. [48] concluded, on the basis of their three cases and a review of the literature, that second fistulae can occur after complete embolization, with latency periods of more than one year and this finding was confirmed by Kiyosue et al. [9] For this reason, we occluded all main feeding arteries prior to obliteration of the affected sinus in our cases with DAVFs of tentorium and TSS to prevent development of cortical venous reflux and intracranial hemorrhage. In one

patient with a TSS DAVF with a parallel venous channel of the transverse/sigmoid sinus was converted a Cognard Type IIa DAVF into a Cognard Type I DAVF with patent parent sinus.

## 7. Conclusion

Transvenous treatment of intracranial DAVFs can be a highly effective method if various transvenous approaches are attempted. Onyx is a promising embolic agent for the transvenous treatment of DAVFs, and its physical properties warrant further appraisal in larger series of patients. The advantages make this an attractive alternative to already described various platinum coils.

## Author details

Xianli Lv, Youxiang Li and Chuhan Jiang\*

\*Address all correspondence to: [lvxianli000@163.com](mailto:lvxianli000@163.com)

Beijing Neurosurgical Institute and Beijing Tiantan Hospital, Capital Medical University, Beijing, P R China

## References

- [1] Paula-Lucas C, Pereica-Caldas J-G-M, Prandini MN (2006) Do leptomeningeal venous drainage and dysplastic venous dilation predict hemorrhage in dural arteriovenous fistula? *Surg Neurol* 66:S3:2-S3:6
- [2] Roy D, Raymond J (1997) The role of transvenous embolization in the treatment of intracranial dural arteriovenous fistulas. *Neurosurgery* 40 (6):1133-1144
- [3] Urtasun F, Biondi A, Casaco A, Houdart E, Caputo N, Aymard A, Merland JJ (1996) Cerebral dural arteriovenous fistulas: percutaneous transvenous embolization. *Radiology* 199:209-217
- [4] Cognard C, Gobin YP, Pierot L, Bailly AL, Houdart E, Casasco A, Chiras J, Merland JJ (1995) Cerebral dural arteriovenous fistulas: clinical and angiographic correlation with a revised classification of venous drainage. *Radiology* 194:671-680
- [5] Abrahams JM, Begley LJ, Flamm ES, Hurst RW, Sinson GP (2002) Alternative management considerations for ethmoidal dural arteriovenous fistula. *Surgical Neurology* 58 (6):410-417



- [6] Benndorf G, Schmidt S, Sollman WP, Kroppenstedt SN (2003) Tentorial dural arteriovenous fistula presenting with various visual symptoms related to anterior and posterior visual pathway dysfunction: case report. *Neurosurgery* 53:222-227
- [7] Halbach VV, Higashida RT, Hieshima GR, Wilson CB, Barnwell SL, Dowd CF (1990) Dural arteriovenous fistulas supplied by ethmoidal arteries. *Neurosurgery* 26:816-823
- [8] Iwamuro Y, Nakahara I, Higashi T, Iwaasa M, Watanabe Y, Hirata E, Tsunetoshi K, Taha M (2006) Tentorial dural arteriovenous fistula presenting symptoms due to mass effect on the dilated draining vein: case report. *Surg Neurol* 65:511-515
- [9] Kim MS, Han DH, Han MH, Oh C-W (2003) Posterior fossa hemorrhage caused by dural arteriovenous fistula: case reports. *Surg Neurol* 59:512-517
- [10] Leonard F, Jeffrey B, Nicholas JV (2003) Cavernous sinus fistulas: carotid cavernous fistulas and dural arteriovenous malformations. *Current Neurology & Neuroscience Reports* 3:415-420
- [11] Lv X, Li Y, Wu Z (2008) Endovascular treatment of the anterior cranial fossa dural arteriovenous fistulas. *Neuroradiology* 50:433-437
- [12] Arat A, Cekirge S, Saatci I, Ozgen B (2004) Transvenous injection of Onyx for casting of the cavernous sinus for the treatment of a carotid-cavernous fistula. *Neuroradiology* 46:1012-1015
- [13] Benndorf G, Bender A, Lehmann R, Lanksch W (2000) Transvenous occlusion of dural cavernous sinus fistulas through the thrombosed inferior petrosal sinus: report of four cases and review of the literature. *Surg Neurol* 54:42-54
- [14] Deasy NP, Gholkar AR, Cox TCS, Jeffree MA (1999) Tentorial dural arteriovenous fistulas: endovascular treatment with transvenous coil embolization. *Neuroradiology* 41:308-312
- [15] Defreyne L, Vanlangenhove P, Vandekerckhove T, Deschrijver I, Sieben G, Klaes R, Kunnen M (2000) Transvenous embolization of a dural arteriovenous fistula of the anterior cranial fossa: preliminary results. *AJNR Am J Neuroradiol* 21:761-765
- [16] Jahan R, Gobin YP, Glenn B, Duckwiler GR, Vinuela F (1998) Transvenous embolization of a dural arteriovenous fistula of the cavernous sinus through the contralateral pterygoid plexus. *Neuroradiology* 40:189-193.
- [17] Jiang C, Lv X, Li Y, Liu A, Lv M, Jiang P, Wu Z (2007) Transvenous Embolization of Cavernous Sinus Dural Arteriovenous Fistula with Onyx-18 and Platinium coils: Technical Note. *NRJ-Neuroradiol J.* 20:47-52
- [18] Jiang C, Lv X, Li Y, Liu A, Wu Z (2007) Transvenous embolization with Onyx for dural arteriovenous fistula of cavernous sinus: a report of two case reports. *NRJ-Neuroradiol J.* 20:718-725

- [19] Jiang C, Lv X, Li Y, Wu Z (2007) Transarterial and transvenous embolization for tentorial dural arteriovenous fistula: case report. *NRJ-Neuroradiol J* 20:726-729
- [20] Kai Y, Hamada J, Morioka M, Yano S, Kuratsu J (2007) Treatment of cavernous sinus dural arteriovenous fistulas by external manual carotid compression. *Neurosurgery* 60:253-258
- [21] Kajita Y, Miyachi S, Wakabayashi T, Inao S, Yoshida J (1999) A dural arteriovenous fistula of the tentorium successfully treated by intravascular embolization. *Surg Neurol* 52:294-298
- [22] Kallmes DF, Jensen ME, Kassell NF, Dion JE (1997) Percutaneous transvenous coil embolization of a Djindjian type 4 tentorial dural arteriovenous malformation. *AJNR Am J Neuroradiol* 18:673-676.
- [23] Kazekawa K, Iko M, Sakamoto S, Aikawa H, Tsutsumi M, Kodama T, Go Y, Tanaka A (2003) Dural AVFs of the cavernous sinus: transvenous embolization using a direct superficial temporal vein approach. *Radiation Medicine* 21:138-141
- [24] Kuwayama N, Endo S, Kitabayashi M, Nishijima M, Takaku A (1998) Surgical transvenous embolization of a cortically draining carotid cavernous fistula via a vein of the sylvian fissure. *AJNR Am J Neuroradiol* 19 (7):1329-1332.
- [25] Lefkowitz M, Giannotta SL, Hieshima G, Higashida R, Halbach V, Dowd C, Teitelbaum GP (1998) Embolization of neurosurgical lesions involving the ophthalmic artery. *Neurosurgery* 43:1298-1303
- [26] Liu HM, Huang YC, Wang YH, Tu YK (2000) Transarterial embolization of complex cavernous sinus dural arteriovenous fistulas with low-concentration cyanoacrylate. *Neuroradiology* 42:766-770.
- [27] Nakamura M, Tamaki N, Kawaguchi T, Fujita S (1998) Selective transvenous embolization of dural carotid-cavernous sinus fistulas with preservation of sylvian venous outflow. Report of three cases. *J. Neurosurg* 89:825-829
- [28] Oishi H, Arai H, Sato K, Iizuka Y (1999) Complications associated with transvenous embolization of cavernous dural arteriovenous fistula. *Acta Neurochir* 141:1265-1271
- [29] Satomci J, Satoh K, Matsubara S, Nakajima N, Nagahiro S (2005) Angiographic changes in venous drainage of cavernous sinus dural arteriovenous fistulas after palliative transarterial embolization or observational management: a proposed stage classification. *Neurosurgery* 56:494-502.
- [30] Siekmann R, Weber W, Kis B, Kuhne D (2005) Transvenous treatment of a dural arteriovenous fistula of the transverse sinus by embolization with platinum coils and Onyx HD 500+. *Inter Neuroradiol* 11:281-286



- [31] So-Hyang I, Chang WO, Dae HH (2004)Surgical management of an unruptured dural arteriovenous fistula of the anterior cranial fossa: natural history for 7 year. *Surg Neurol* 62:72-75.
- [32] Suzuki S, Lee DW, Jahan R, Duckwiler GR, Vinuela F (2006)Transvenous treatment of spontaneous dural carotid-cavernous fistulas using a combination of detachable coils and Onyx. *AJNR Am J Neuroradiol* 27:1346-1349
- [33] Toulgoat F, Mounayer C, Tulio Salles Rezende M, Piotin M, Spelle L, Lazzarotti G, Desal H, Moret J (2006)Transarterial embolization of intracranial dural arteriovenous malformations with ethylene vinyl alcohol copolymer (Onyx-18). *J Neuroradiol* 33:105-114
- [34] Troffkin NA, Graham CB, Berkman T, Wakhloo AK (2003)Combined transvenous and transarterial embolization of a tentorial-incisural dural arteriovenous malformation followed by primary stent placement in the associated stenotic straight sinus. Case report. *J. Neurosurg* 99 (3):579-583.
- [35] Tu YK, Liu HM, Hu SC (1997)Direct surgery of carotid cavernous fistulas and dural arteriovenous malformations of the cavernous sinus. *Neurosurgery* 41 (4):798-806.
- [36] Watanabe T, Matsumaru Y, Sonobe M, Asahi T, Onitsuka K, Sugita K, Takahashi S, Nose T (2000)Multiple dural arteriovenous fistulas involving the cavernous and sphenoparietal sinuses. *Neuroradiology* 42:771-774.
- [37] Deshmukh VR, Maughan PH, Spetzler RF (2006)Resolution of hemifacial spasm after surgical obliteration of a tentorial arteriovenous fistula: case report. *Neurosurgery* 58 (1):E202
- [38] Deshmukh VR, Maughan PH, Spetzler RF (2006)Resolution of hemifacial spasm after surgical obliteration of a tentorial arteriovenous fistula: case report. *Neurosurgery* 58 (1):E202
- [39] Fujita A, Tamaki N, Nakamura M, Yosuo K, Morikawa M (2001)A tentorial dural arteriovenous fistula successfully treated with interruption of leptomeningeal venous drainage using microvascular Doppler sonography: case report. *Surg Neurol* 56:56-61.
- [40] Jesus OD, Rosado JE (1999)Tentorial dural arteriovenous fistula obliteration using the petrosal approach. *Surg Neurol* 51:164-167.
- [41] Komotar RJ (2007)Clinicoradiological review: bilateral ethmoidal artery dural arteriovenous fistulas. *Neurosurgery* 60 (1):131-136
- [42] Mayfrank L, Reul J, Huffmann B, BertalanHy H, Spetzger U, Gilsbach JM (1996)Microsurgical interhemispheric approach to dural arteriovenous fistulas of the floor of the anterior cranial fossa. *Minimally Invasive Neurosurgery* 39 (3):74-77.

- [43] White DV, Sincoff EH, Abdulrauf SI (2005)Anterior ethmoidal artery: microsurgical anatomy and ethmoidal considerations. *Neurosurgery* 56 (4)ONS (2):406-410.
- [44] Masahiro S, Hiroki K, Masao T, Takaaki K (2000)Stereotactic radiosurgery for tentorial dural arteriovenous fistulas draining into the vein of Galen: reports of two cases. *Neurosurgery* 46 (3):730
- [45] Matsushige T, Nakaoka M, Ohta K, Yahara K, Okamoto H, Kurisu K (2006)Tentorial dural arteriovenous malformation manifesting as trigeminal neuralgia treated by stereotactic radiosurgery: a case report. *Surg Neurol* 66:519-523
- [46] Pannu Y, Shownkeen H, Nockels RP, Oritano TC (2004)Obliteration of a tentorial dural arteriovenous fistula causing spinal cord myelopathy using the cranio-orbital zygomatic approach. *Surg Neurol* 62:463-467.
- [47] Patrik RT, Harry JC, Akihiko K, Micheal CC, Jacques D, Daniel LB (2003)Evolution of the management of tentorial dural arteriovenous malformations. *Neurosurgery* 52 (4):750-762.
- [48] Kong DS, Kwon KH, Kim JS, Hong SC, Jeon P (2007)Combined surgical approach with intraoperative endovascular embolization for inaccessible dural arteriovenous fistulas. *Surg Neurol* 68:72-78
- [49] Krisht AF, Burson T (1999)Combined pretemporal and endovascular approach to the cavernous sinus for the treatment of carotid-cavernous dural fistulas: technical case report. *Neurosurgery* 44 (2):415-418.
- [50] Quinones D, Duckwiler G, Gobin PY, Goldberg RA, Vinuela F (1997)Embolization of dural cavernous fistulas via superior ophthalmic vein approach. *AJNR Am J Neuroradiol* 18:921-928
- [51] Kim DJ, Kim DI, Suh SH, Kim J, Lee SK, Kim EY, Chung TS (2006)Results of transvenous embolization of cavernous dural arteriovenous fistula: A single-center experience with emphasis on complications and management. *AJNR Am J Neuroradiol* 27 (10):2078-2082
- [52] Aihara N, Mase M, Yamada K, Barno T, Watanake K, Kamiya K, Takagi T (1999)Deterioration of ocular motor dysfunction after transvenous embolization of dural arteriovenous fistula involving the cavernous sinus. *Acta Neurochir* 141:707-710.
- [53] Benndorf G, Bender A, Campi A, Menneking H, Lanksch WR (2001)Treatment of a cavernous sinus dural arteriovenous fistula by deep orbital puncture of the superior ophthalmic vein. *Neuroradiology* 43:499-502
- [54] Goldberg RA, Goldey SH, Duckwiler G, Vineula F (1997)Management of cavernous sinus-dural fistulas. Indications and techniques for primary embolization via the superior ophthalmic vein. *Arch Ophthamol* 115:823-824

