

We are IntechOpen, the world's leading publisher of Open Access books Built by scientists, for scientists

6,900

Open access books available

186,000

International authors and editors

200M

Downloads

Our authors are among the

154

Countries delivered to

TOP 1%

most cited scientists

12.2%

Contributors from top 500 universities



WEB OF SCIENCE™

Selection of our books indexed in the Book Citation Index
in Web of Science™ Core Collection (BKCI)

Interested in publishing with us?
Contact book.department@intechopen.com

Numbers displayed above are based on latest data collected.
For more information visit www.intechopen.com



Diagnostic Imaging in Muscle Injury

Massimo Manara, Danilo Manari and Giulio Pasta

Additional information is available at the end of the chapter

<http://dx.doi.org/10.5772/56472>

1. Introduction

It might be strange to begin a chapter on diagnostics in the 21st century by highlighting doubts. Yet, the structure and physiology of muscles still escape our full understanding as the muscular system is a heterogeneous structure able to adapt to numerous functional demands, linked to physiological needs or pathologies. Indeed, the muscle is a complex mechanism, in which the phenotypical and morphological profile of the fibres varies between the double insertions and from surface to depth, and it adapts depending on stressors and stimuli which, independently of age, gender and physical activity, give rise to different responses within the same muscle. For these reasons the muscle appears to be a complex and not fully explored world.

This aspect is mainly concerned with physiopathology, and diagnostics nowadays has reached levels which perhaps were unimaginable 20 years ago. The development of electronic engineering has led to the construction of diagnostic machinery able to identify the finest details of the muscle. As history has proved, the continuous development of Ultrasound and MRI equipment, not to mention TAC, has changed the doctors' modus operandi over a period starting from the first musculoskeletal ultrasound image in 1972 by Leopold and McDonald to current 3D images, or from the first MRI image developed in the '70s to the current 3 Tesla MRI equipment.

The use of these devices in muscular injury diagnostics has acquired fundamental importance in Sports Medicine as regards diagnosis, prognosis and rehabilitation. The choice of using either Ultrasound or MRI is still subject to debate as it is influenced by several factors, such as type of injury, availability of the devices, the Radiologist's knowledge of Sport injuries, and the cost-benefit ratio, all of which the Sports Physician must evaluate carefully.

As the clinical cases shown prove, the difference in quality and accuracy of the images is well defined in favour of the MRI, but the decision still remains subject to a multifaceted vision.

2. Current uses of Ultrasound and MRI

Acute muscular strain injuries are frequently found in sports, at both amateur and competitive level, so much so that diagnostic imaging has acquired primary importance in identifying the trauma, assessing the damage, estimating possible complications and predicting recovery. Ultrasound and MRI play an important role in the study of muscle injuries owing to their ability to identify lesions effectively, which is closely related to the presence of oedema in the damaged muscle. [1]

The aim of our work is to analyse and compare the diagnostic value of ultrasound and MRI in terms of sensitivity, and recommend the best route to follow when studying muscular injuries.

First and foremost, advances in technology have dramatically improved image quality and nowadays a physician can easily prescribe either an MRI or an echography.

Although ultrasound has been used to evaluate the musculoskeletal system for approximately 25 years and despite the increasingly frequent use of MRI, there has been a renewed interest in Ultrasound for several reasons. The spatial resolution of Ultrasound exceeds the resolution obtainable with magnetic resonance (MR) imaging without the use of small surface coils and specific imaging parameters. For example, commercially available transducers with frequencies of 9 MHz to 15 MHz produce in-plane resolutions of 200 μ m to 450 μ m and section thicknesses of 0.5 mm to 1 mm. The resolution of sonographic imaging with standard high-frequency transducers allows visualization of individual neuronal fascicles in peripheral nerves.

Another reason for the increased interest in musculoskeletal Ultrasound is an understanding of its role in connection with MR imaging. MR imaging is valuable when the global assessment of a joint requires evaluation of the muscles, tendons, cartilage, and bone marrow. Ultrasound, however, can produce similar results when a focused evaluation of muscle, tendon, and joint recesses is needed. Frequently this can be performed at a lower cost and with less delay when compared with MR imaging.

More importantly, however, there are several applications where Ultrasound outperforms MR imaging. One deserving emphasis is the use of dynamic imaging with musculoskeletal Ultrasound.

Dynamic imaging is very helpful when differentiating full-thickness from partial-thickness tendon tears because tendon retraction indicates full-thickness tear. Additionally, there are several conditions where muscle, tendon, and nerve subluxation or dislocation only occur with specific extremity positions or movements. These abnormal subluxations or dislocations reduce in neutral position and remain undetected with routine MR imaging.

One last advantage of Ultrasound over MR imaging is the ability to focus the examination precisely at the region of symptoms and obtain imaging which is directly correlated to the patient's complaints. This correspondence is invaluable for a physician from a diagnostic perspective. [2]

US and MRI play an important role in the study of muscle injuries owing to their ability to identify lesions effectively, which is closely related to the presence of oedema in the damaged muscle. [1]

MRI is regarded as the gold standard. [3]

Literature contains no generally accepted classification of muscle traumas, and classification of minor traumas, in which imaging patterns are often identical, is even more complex.

In our experience, only a combination of imaging and accurate clinical examination makes it possible to achieve a correct diagnosis.

In our study, we observed only 26 minor traumas out of a total of 81 traumas (32%). The small number of minor traumas observed reflects the vagueness of their clinical symptoms rather than their rarity. Ultrasound sensitivity to minor traumas is much lower than that obtained for major traumas (76.92% vs. 92.72%). This is because Ultrasound findings in minor traumas are vague and indistinct if the oedema is small. In our study, the lowest Ultrasound sensitivity values were recorded for DOMS. [4]

Studying 40 patients with DOMS, Dierking et al. observed that ultrasound had low sensitivity in detecting the complaint. [5]

Although MRI correctly detected the muscle oedema in seven of our patients with DOMS, the pattern was non-specific and the correct diagnosis required integration with laboratory findings such as creatine-kinase assay.

De Smet states that MRI is reliable only if it is preceded by a thorough clinical assessment that enables selection of the most appropriate sequences and scan planes, and observed specificity and sensitivity values of 80% and 83%, respectively, for diagnosis of contractures and lengthening. This may also be correlated to the presence of considerable muscle oedema, which facilitates lesion identification. In such cases, Ultrasound demonstrates diffuse hypoechogenicity with displacement of the tertiary bundles. [6]

Hashimoto et al. suggest the use of very-high-frequency transducers to detect minor lesions. Ultrasound sensitivity increases slightly in mild contusions. In these cases, as the trauma has an external origin, the sonographer is guided by knowledge of the site of impact.

In our experience, the Ultrasound imaging pattern of small contusions does not differ much from that of other minor traumas; in all cases, it shows muscle oedema without interruption of the continuity of muscle fibres. Differentiation was only possible on the basis of the patient's history.

As regards major traumas, Ultrasound had 84% sensitivity in identifying muscle strain. The extent of tissue alterations affects the Ultrasound pattern.

Significant differences were observed between third-degree muscle strains (which are readily detected) and first-degree muscle strains. In two cases of false

negative results, Ultrasound underestimated lesions subsequently classified as second-degree injuries by MRI. The reason for such underestimation was that both lesions were located deep in the femoral quadriceps and therefore less amenable to Ultrasound.

Ultrasound examination enables identification of typical lesions of muscle strains: discontinuity of tertiary bundles, reactive oedema and haematoma. In first-degree strains, the involvement of a small number of myofibrils can make it difficult to recognise the lesion with Ultrasound so the use of MRI is necessary. More-severe lesions (second and third degree) with involvement of a larger number of myofibrils, will exhibit a hypoechoic or anechoic haematoma, which can remain localised or extend along the bundles. Immediately after a trauma, the true extent of a lesion may be masked by a hyperechoic haemorrhage whereas Ultrasound done after 48–72 hours will reveal the evolution of the haematoma and the extent of the area affected. [7]

In cases of complete tears of the muscle belly, the retracted muscle bundles have the typical Ultrasound appearance of a bell clapper surrounded by a hypoechoic haematoma. In cases of complete tears of the muscle belly, the retracted muscle bundles have the typical Ultrasound appearance of a bell clapper surrounded by a hypoechoic haematoma. As previously emphasised, a dynamic examination is fundamental in all cases and particularly in first-degree strains, as it enables detection of the separation and dislocation of tertiary bundles and evaluation of the effective extent of the lesion. [8]

Muscle strains are recognisable at MRI due to changes in muscle volume and composition, variations in signal intensity and pathological alterations of surrounding tissues. [9]

Axial scans allow for comparative examination to detect changes in muscle volume and signal intensity. Coronal or sagittal images along the muscle belly axis make it possible to define the extent of the lesion. [6]

An important finding by Megliola et al. was that in all patients with severe contusion, the haematoma was detected with both Ultrasound and MRI, leading to a sensitivity of 100% for Ultrasound. According to Peetrons, a sonographic classification of major muscle lesions into four different types may be made on the basis of the percentage of muscle involved, but it is essential to distinguish lesions giving rise to haematomas from those causing tearing of muscle fibres only.

Megliola et al. studied 29 patients with severe contusion, and Ultrasound was able not only to locate the haematoma but also to evaluate its extent in total agreement with MRI. Ultrasound has far higher sensitivity for major traumas than for minor traumas.

This is because the ability of Ultrasound to evaluate minor traumas is related to the presence of severe muscle oedema. In major traumas, it can accurately evaluate the extent of the lesion, the percentage of muscle affected, the size of the scar and possible complications. [4]

Bianchi et al. examined 17 patients with acute injury of the rectus femoris with both MRI and Ultrasound. There was concordance between the two techniques in identifying the lesions and evaluating lesion extent. The authors therefore concluded that for lesions of the rectus femoris, a very superficial muscle, Ultrasound should be considered the first-line technique. [10]

In contrast, in the study of deeper muscles, Kolouris and Connell identified a discrepancy between Ultrasound and MRI in the evaluation of hamstring injuries and observed that MRI is more accurate in assessing the extent of injury. These studies confirm that Ultrasound is limited in the study of muscle injury in that its resolution is limited to the tertiary bundle, it is unable to identify pathological alterations to the secondary and primary bundles and myofibrils, and cannot evaluate deep muscle planes. [11]

But Ultrasound (US) technologies are rapidly advancing, offering several refined transducer technologies as well as soft and hardware facilities to improve the potential clinical impact in the field of musculoskeletal (MSK) imaging.

Nowadays when using B-mode ultrasound, compound imaging and beam-steering are of help in decreasing anisotropy in tendons and ligaments, which are less well depicted due to their oblique course.

Doppler imaging has become sensitive in the detection of flow in small vessels and the use of US micro bubble contrast agents (Contrast-enhanced ultrasound –CEUS) improves detection of low-volume blood flow in smaller vessels, by increasing the signal-to-noise ratio and thereby facilitating detection of angiogenetic vessels in inflammatory conditions as for muscular lesion.

The use of US blood pool contrast agents enables molecular imaging in real-time, and thus the diagnostic potential of US is expanded, opening up a new field of US applications. Objective quantification of altered tissue (e.g., synovial proliferation) needs further development and might be improved by the use of three-dimensional imaging and software tools such as parametric evaluation.

Real-time sonoelastography (EUS) is a new development for visualization of tissue elasticity by measurement of tissue displacement in terms of stiffness changes, promising new insights into tendon disorders.

Image fusion is an exciting development that enables superimposition of CT/MRI data sets on real-time US scanning.

This technique might be helpful in guiding injections under real-time conditions even in regions less easily accessible by US as, for instance, the axial skeleton, and can additionally provide an interesting tool for teaching MSK imaging and ways to guide interventions. [12]

But, as described, MRI has very good sensitivity for the depiction of muscle lesions. Various MRI patterns of muscle injury have been described, usually including oedema-like signal alterations within torn muscle bundles. [1]

The importance of the STIR technique in detection of muscle injuries has been stressed by Greco et al., who recognized that subtle abnormalities, not easily seen on long echo T2-weighted images, are highlighted with the STIR technique as the short T1 induces suppression of fat signal and makes the effects of prolonged T1 and T2 on signal intensity additive. [13]

Imaging of muscular lesions has been greatly improved with the use of the contrast medium (Gadolinium), which grants a better definition of the muscular strain. A proof of this was provided by El-Noueam KI, Schweitzer ME, Bhatia, who described how muscle strain injury

was demonstrated only in the post contrast MR scans, a pattern that we believe was not previously reported.

This pattern may be explained on the basis of the clinical spectrum of muscle strain injury described by O'Donoghue, as well as by considering the histological changes occurring at the myotendon junction in cases of muscle strain. O'Donoghue classified muscle strain injury as being mild, moderate, and severe. In the mild (first degree) strain, there is no appreciable tissue disruption, with neither discernible loss of strength nor any restriction of motion; the pathological changes observed at this stage are confined to low grade inflammatory process. In a moderate (second degree) strain, there is actual tissue damage that compromises the strength of the muscle tendon unit.

A severe (third degree) strain denotes complete disruption of some portion of the unit. A possible correlation is that the mild (first degree) muscle strain injury is the one detectable only on the post contrast MR scans and that the moderate and severe strain muscle injuries are readily recognized in the non contrast T2 and STIR MR sequences. However, these injuries limited the athletes' competitive participation for significant periods of time, suggesting that they were not minor injuries; so a perhaps more plausible explanation for this phenomenon is that the proliferation of MRI sites as well as the high level of medical care required by professional athletes usually mandate rapid imaging after injury. Therefore, if a longer delay in imaging had occurred, more oedema might have been present, allowing depiction of the muscle injury in the non enhanced MR study. Thus, the possibility of false negative non enhanced early MR images should be considered. A number of limitations are associated with this study but despite these limitations, they suggest the consideration of intravenous gadolinium in the setting of clinically suspected muscle injuries not visualized on T2 or STIR sequences. [14]

However, MRI remains the gold standard for detecting changes in muscle tissue. In some cases, MRI examinations can take the place of muscle biopsy for diagnosis. New advances in MRI include diffusion-weighted imaging, which permits assessment of fluid motion in muscles, and blood-oxygen-level-dependent imaging to evaluate tissue oxygenation. [15]

3. Images

In this paragraph we have used several images in order to emphasise the characteristics of muscular lesion diagnosed over the years in professional athletes.

We do not wish to provide a new classification but rather definitions which may help better understand the type of injury and choose the best diagnostic tool.

3.1. Indirect muscular injuries

3.1.1. D.O.M.S.

D.O.M.S. stands for DELAYED ONSET of MUSCULAR SORENESS. This refers to the pain felt several hours or even days after hard training and is caused by structural damage to the

microscopic contracting functional units present in muscular fibres, with metabolic changes which lead to an alteration of the muscular tone, but does not reveal macroscopic damage to the fibres.

All that appears with Ultrasound, despite inconsistently is greater echogenicity of the whole muscle and a slight enlargement of the muscle due to oedema.

MRI instead reveals slight diffuse signal hyperintensity with undefined edges due to interstitial and perifascial oedema.

This proves MRI to be the gold standard in diagnosing D.O.M.S..

Indeed several articles have shown that the small number of minor injuries observed in clinical practice is not due to their frequency but rather to ill-defined symptoms and to the fact that Ultrasound appears to be unreliable in identifying such small alterations.

Actually Ultrasound sensitivity in identifying minor injuries is much lower compared to greater ones (70% vs 90%), as previously highlighted. MRI instead accurately identifies even minimal muscular oedemas such as D.O.M.S. thanks to adequate sequences which grant approximately 90% sensitivity.

Case 1

Example of a professional runner

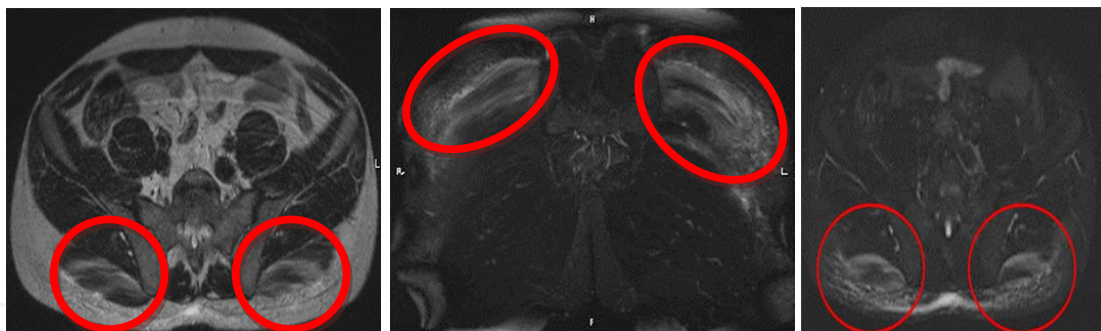


Figure 1. Example of RMN with DOMS in a professional runner

D.O.M.S. of glutei maximi of a runner who had carried out long training for the New York marathon a few days. Diffused oedema is shown by signal hyperintensity (Fig.1)

3.2. Contracture

No macroscopic anatomical injury of the fibres is shown by Ultrasound, but rather alteration of the muscular tone due to fatigue with metabolic changes, revealed by greater echogenicity of the muscle

MRI shows minimal inconsistent increase in the size of the muscle due to diffused oedema and slight signal hyperintensity with ill-defined edges because of interstitial and perifascial oedema

Case 1

Example of a professional footballer

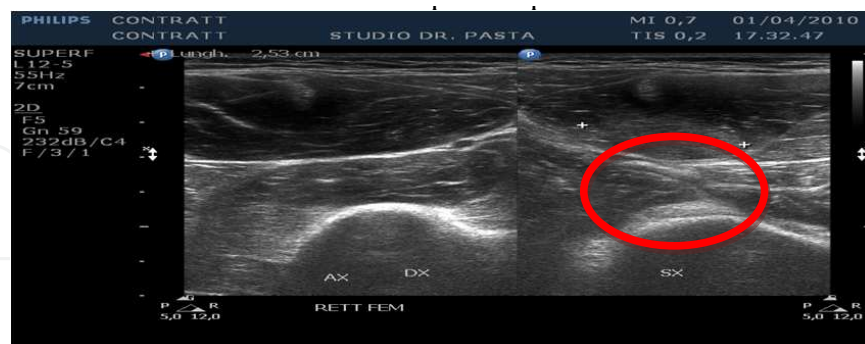


Figure 2. US image of Contracture in a professional footballer

This athlete had no problem finishing the match but the following day complained of slight undefined pain in his quadriceps femoris involving a large area of the muscle. Two days after the match Ultrasound showed slight hyperechogenicity in an area with ill-defined edges in the rectus femoris. (Fig.2)

3.3. Strain (Elongation)

No macroscopic anatomical injury of the fibres is shown by Ultrasound, rather microscopic alteration which in the acute stage are revealed by slight hyperechogenicity due to oedema and affected muscle and by a hypoechoic blurred area in the sub acutestage. MRI reveals slight focal signal hyperintensity

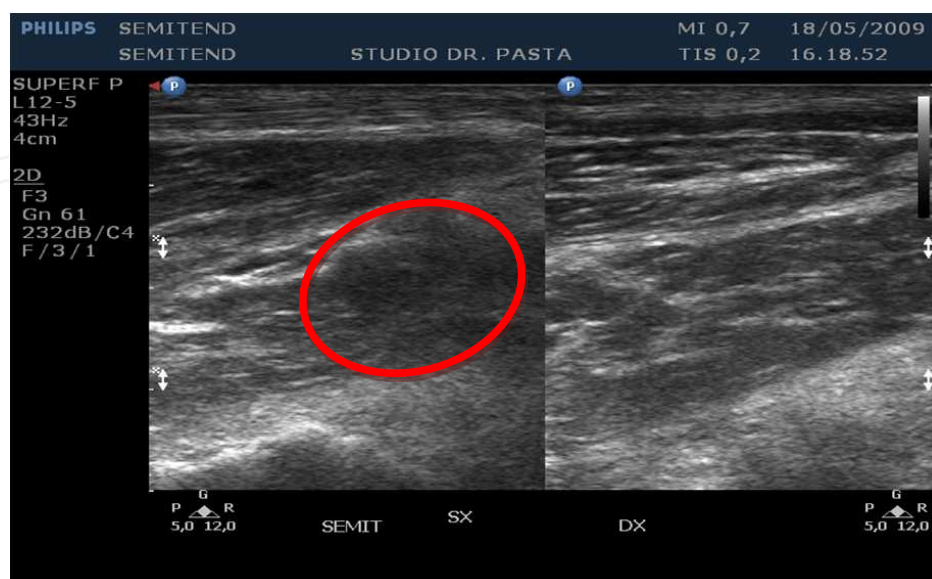


Figure 3. US image of Elongation in a professional footballer

Case 1

Example of a professional footballer

This athlete had no problem finishing the match but the following day complained of undefined pain and slight functional impotence in his Hamstrings involving a large area. Two days after the match Ultrasound showed slight hypoechogenicity, due to slight oedema, in an area with ill-defined edges in the Semitendinosus. (Fig.3)

Case 2

Example of a professional footballer

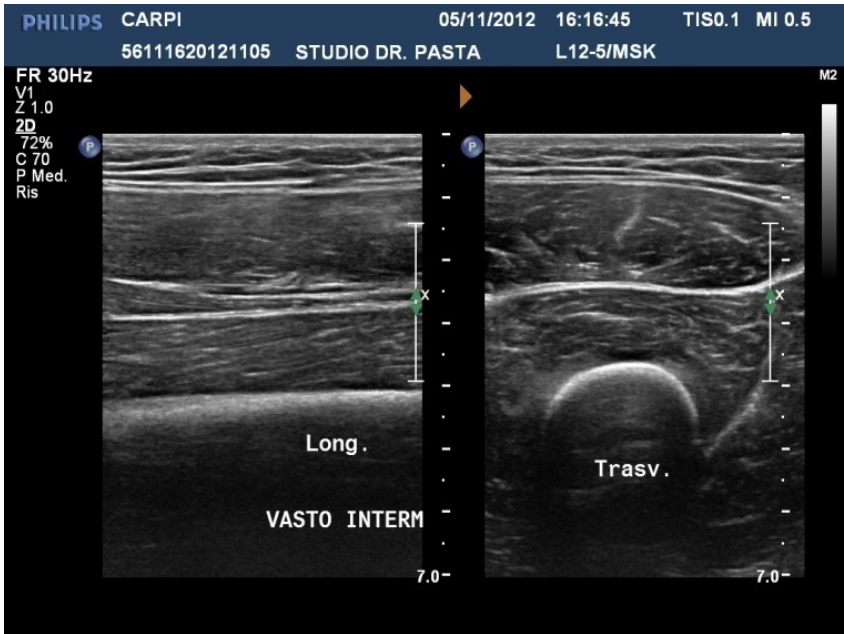


Figure 4. US image of Elongation in a professional footballer

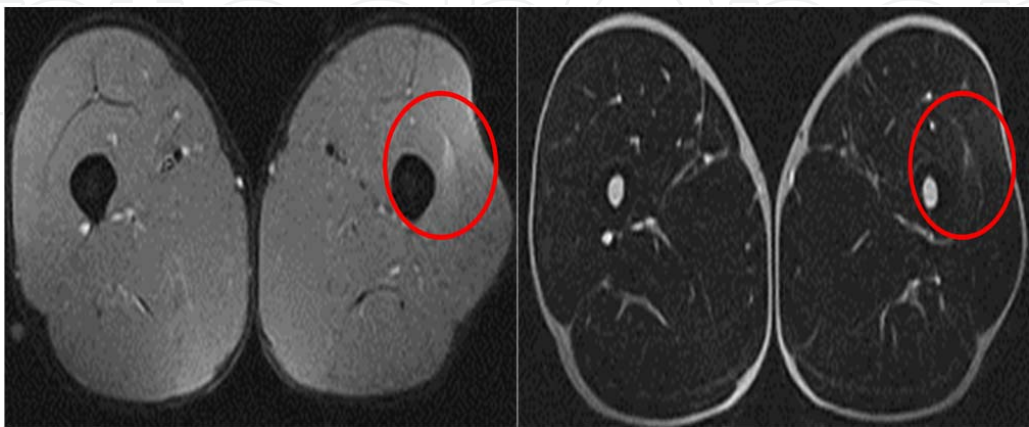


Figure 5. Example of Elongation in an RMN of a professional footballer

The ultrasound of this athlete was negative (Fig.4), yet the MRI carried out because of the symptoms highlighted an oedema of VastusIntermedius, shown by a minimal area of hyperintensity due to minimal myofascial elongation (Fig.5)

3.4. First degree injuries

First degree injuries are characterized by the tear of fibres in the muscle (<5%) with oedema and small haemorrhage because of the vascularisation of connective tissue.

In the acute stage the Ultrasound highlighted a slightly hypoechoic area whilst in the sub-acute phase a dishomogeneous hypoechoic focal area was revealed with initial modification showing a small anechoic inter or intramuscular area (usually <1cm) depending of the size of the muscle.

MRI instead showed an increase in muscle size due to oedema with slight dishomogeneous signal hyperintensity due to interstitial and perifascial oedema together with small focal signal hyperintensity due to small haemorrhage

Case 1

Example of a professional rugby player

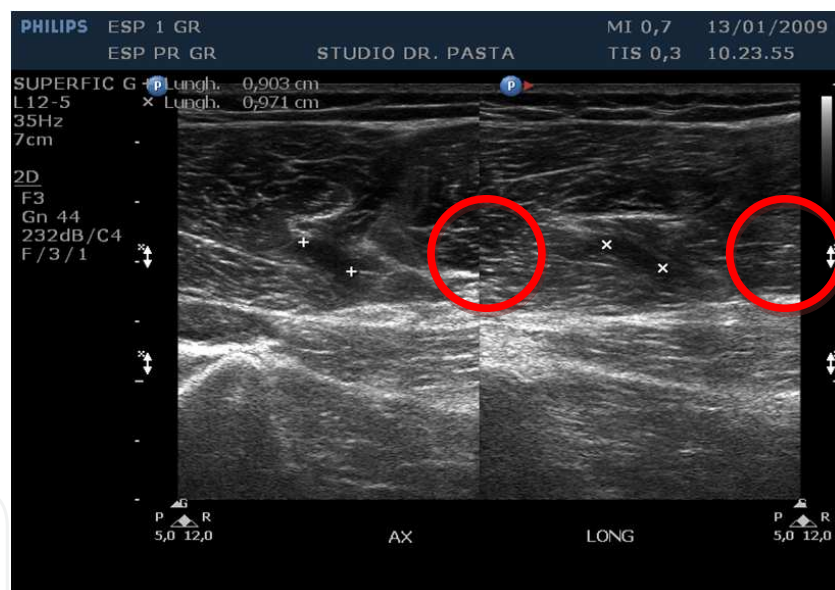


Figure 6. US image of First degree lesion in a professional rugby player

The player came for a check two days after a match when after a sharp movement in a tackle he started feeling pain in a precise point of his thigh.

Ultrasound highlighted an anechoic area due to haemorrhage as from first degree injury of the Hamstrings (Fig.6)

Case 2

Example of a professional rugby player

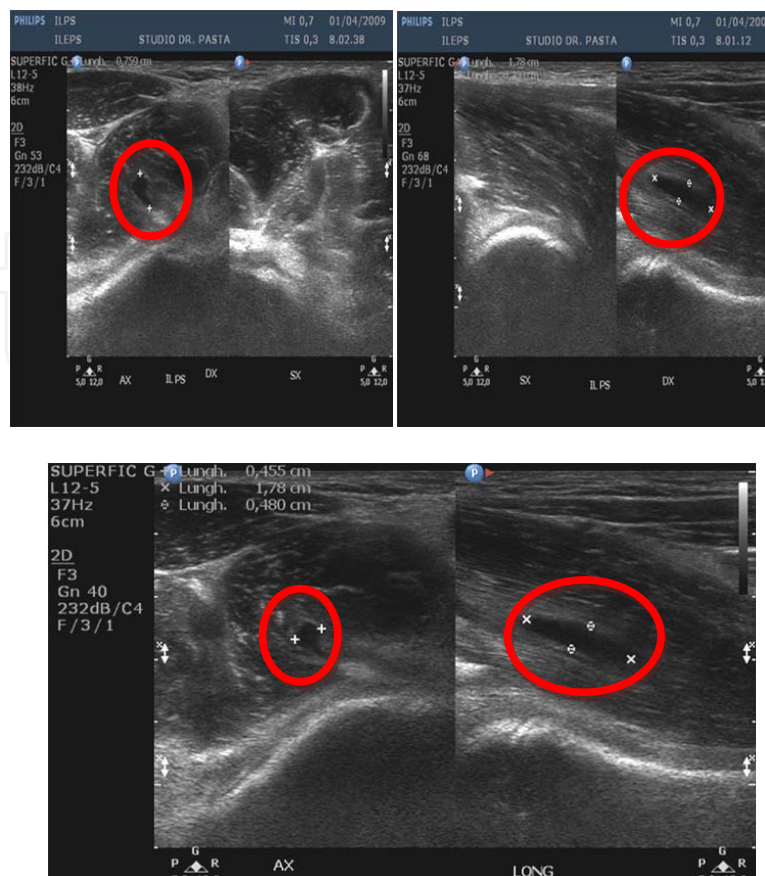


Figure 7. US images of First degree lesion in a professional rugby player

The player came for a check three days after a match when after a sharp movement in a tackle he complained of hyperextension of the pelvis followed by sharp pain in the lower abdomen.

Ultrasound highlighted an anaechoic area due to haemorrhage as from first degree injury of the Abdominal external obliquemuscle. (Fig.7)

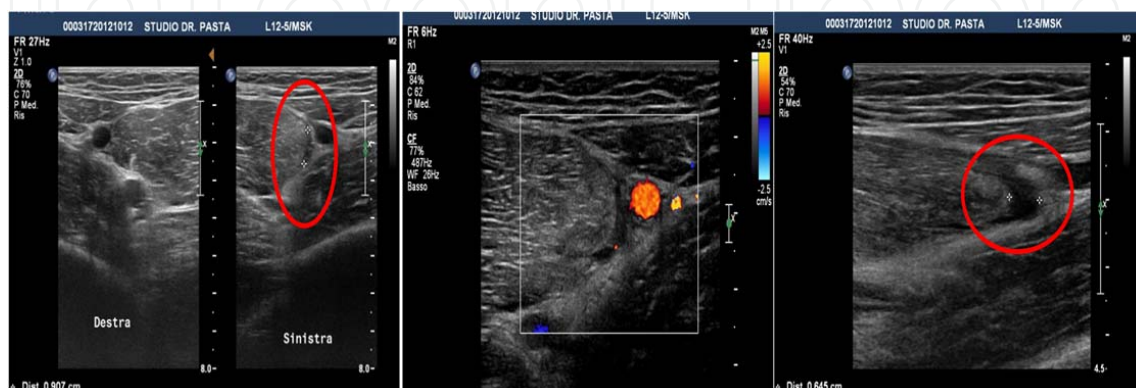


Figure 8. US images of First degree lesion in a professional footballer

Case 3

Example of a professional footballer (Fig.8-Fig.9)

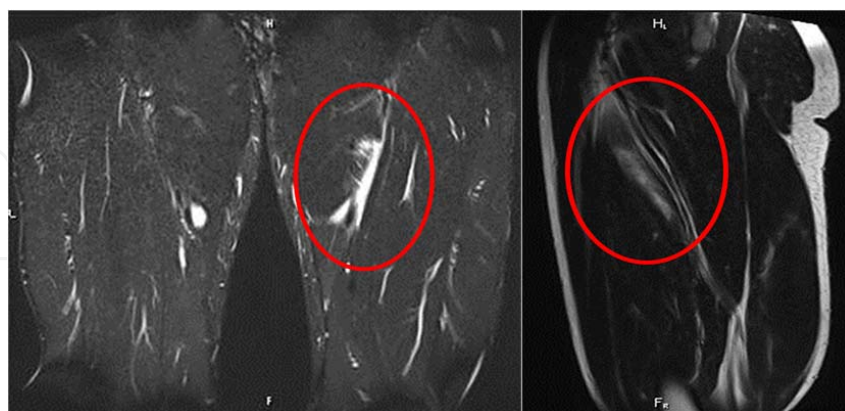


Figure 9. RMN images of First degree lesion in a professional footballer

A professional footballer felt a slight pain in the distal section of the adductor muscle while playing a match but felt no further symptoms.

He therefore started a rehabilitation program but when he started more intense activity he complained of the same pain.

The ultrasound showed an anechoic area due to haemorrhage. (Fig.8)

The MRI was therefore essential to assess the real extension of the injury and highlight mio tendon retraction. (Fig.9)

The analysis was carried out the following day and showed changes in muscle volume and structure and signal hyperintensity when using axial imaging in comparative assessment for volume and variations, whilst coronal and sagittal images defined the extension of the injury, i.e. a first degree myofascial injury of longus adductor.

Case 4

Example of a professional swimmer

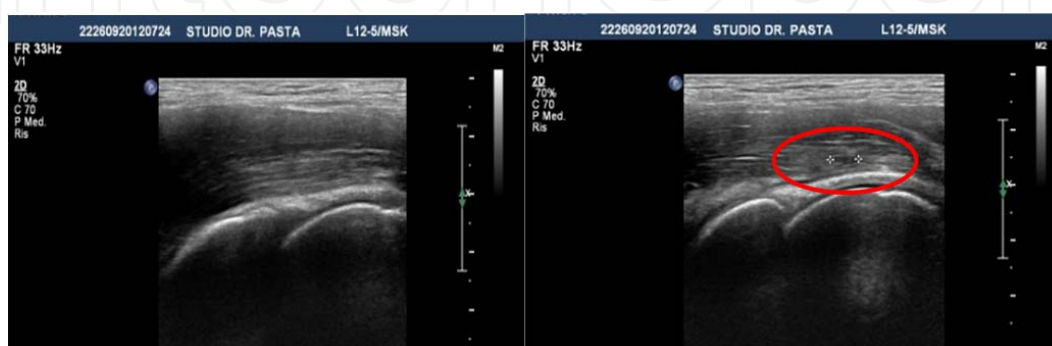

Figure 10. US images of First degree lesion in a professional swimmer

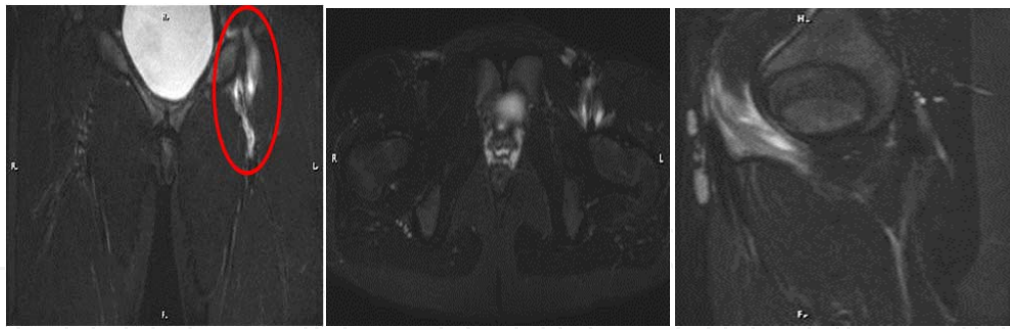


Figure 11. RMN images of First degree lesion in a professional swimmer

This is the case of a professional swimmer who complained of left groin pain for two days after diving but was able to compete.

Ultrasound highlighted a small thin hypoechoic area due to oedema along the ileo-psoas. (Fig. 10)

Due to the mismatch between the symptoms and diagnostics an MRI was carried out

This showed changes in muscle volume and structure and signal hyperintensity when using axial imaging in comparative assessment for volume and variations as for oedema and haemorrhage from ileo-psoas injury linked to tendon partial tear. (Fig.11)

Case 5

Example of a professional runner

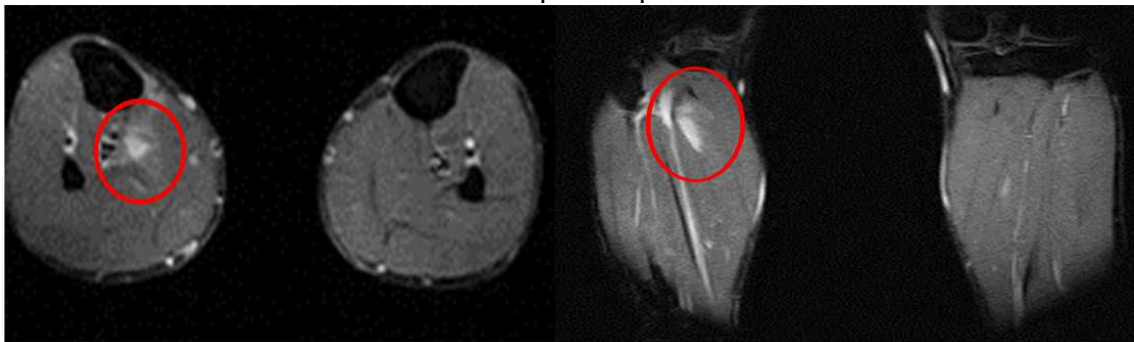

Figure 12. RMN images of First degree lesion in a professional runner

Example of a runner complaining of a sharp pain in the calf

The Ultrasound showed a small thin oedema along the flexor hallucis longus muscle. Due to the mismatch between the symptoms and diagnostics an MRI was carried out.

This showed changes in muscle volume and structure and signal hyperintensity when using axial imaging in comparative assessment for volume and variations as for oedema and haemorrhage from first degree injury of the flexor hallucis longus muscle. (Fig.12)

Case 6

Example of a professional footballer

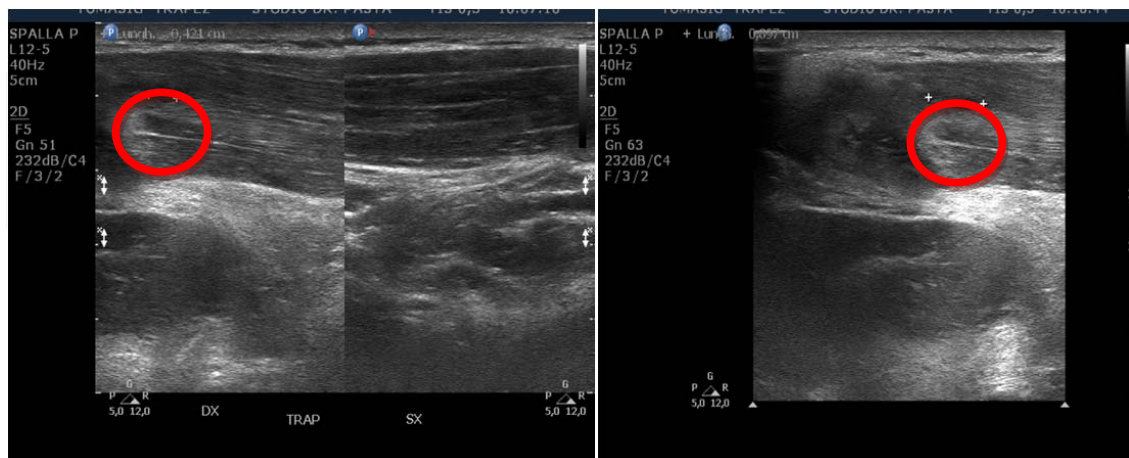


Figure 13. US image of First degree lesion in a professional footballer

This is the case of a goalkeeper who felt a slight pain in his shoulder during a save. The Ultrasound showed a small thin hypoechoic area due to oedema along the Trapezius muscle as for first degree injury. (Fig.13)

3.5. Second degree injury

Second degree injuries are characterized by the tear of a higher number of fibres in the muscle (<70%, < 2/3 of the muscle) with greater oedema and haemorrhage due to the wider involvement of the connective tissue.

Because of the wide range they are divided into initial and advanced second degree injuries.

It is sometimes difficult to define the injury degree precisely as the muscles affected can be very long, so injuries which are first degree should be classified as second degree and this leads to a simple description without a real classification.

In the acute stage the Ultrasound highlighted an iso-hyperechoic area whilst in the sub-acute phase a large, clearly dishomogeneous anechoic area was revealed with structural change showing a large anechoic inter or intramuscular area (usually <3cm) depending of the size of the muscle.

MRI instead showed an increase in muscle size due to oedema with dishomogeneous signal hyperintensity due to interstitial and perifascial oedema together with a mass of fluid with focal signal hyperintensity due to haemorrhage

Case 1

Example of a professional footballer

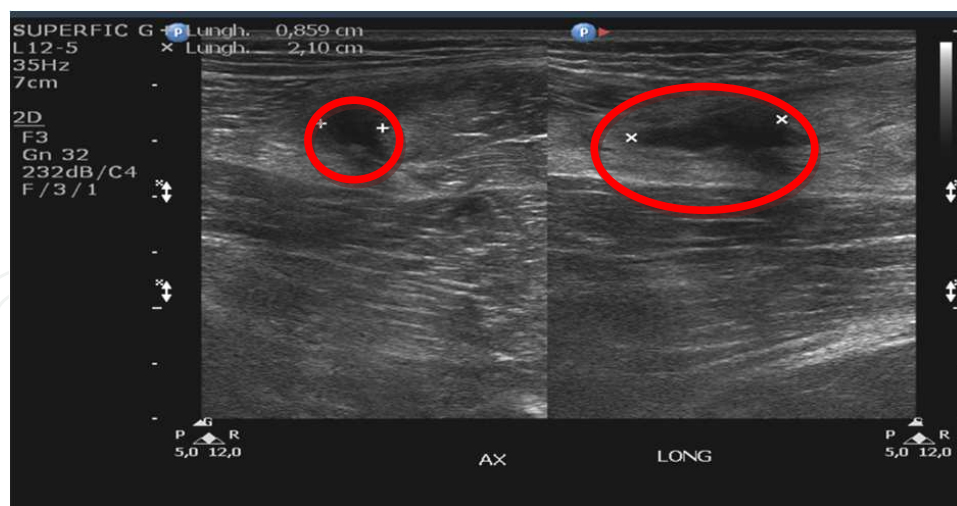


Figure 14. US image of Second degree lesion in a professional footballer

Major League footballer who on the previous day felt a very sharp pain in a sprint and left the match

Ultrasound highlighted a clearly dishomogeneous area with marked structural change showing a large intramuscular anechoic area (<3cm), as from second degree injury of the Biceps Femoris. (Fig.14)

Case 2

Example of a professional volleyball player

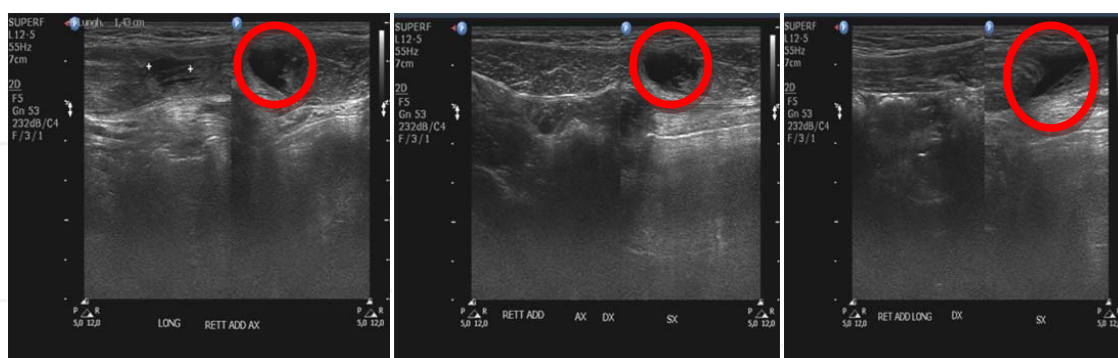


Figure 15. US image of First degree lesion in a professional volleyball player

Example of a volleyball player who, following the movement of the arm in spiking during a match, felt a sharp pain in the abdomen

Ultrasound highlighted a clearly dishomogeneous area with marked structural change showing a large intramuscular anechoic area (>3cm), as from second degree injury of the Rectus Abdominis. (Fig.15)

Case 3

Example of a professional footballer

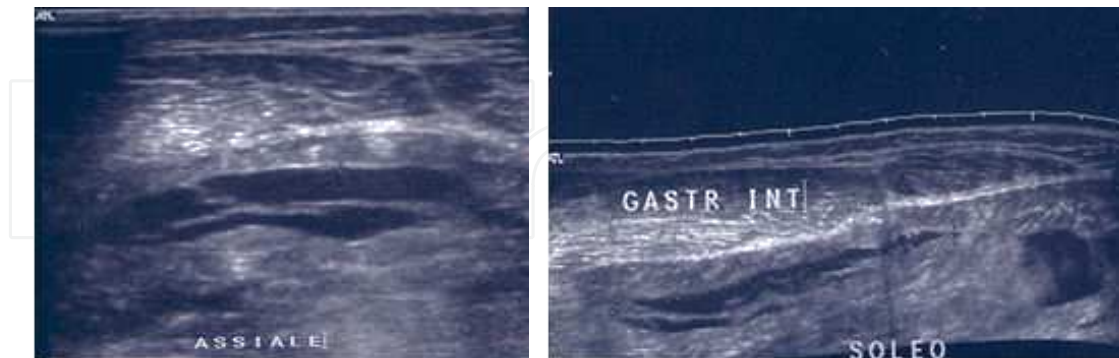


Figure 16. US images of Second degree lesion in a professional footballer

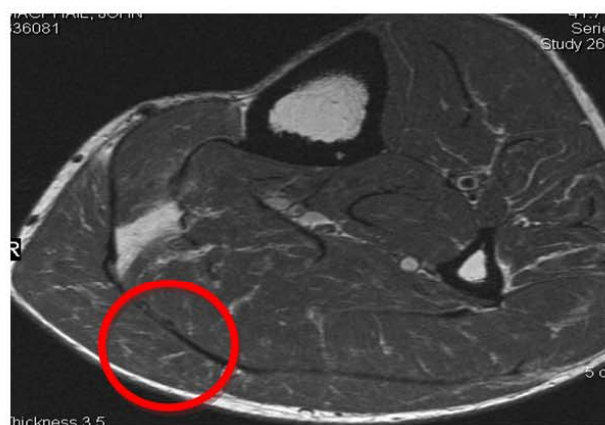

Figure 17. RMN images of Second degree lesion in a professional footballer

Example of a footballer who during pre-match warm-up felt a sharp pain in the calf which did not prevent him from playing up to the second half

Ultrasound highlighted a clearly dishomogeneous area with marked structural change showing a large intramuscular anechoic area (>5 cm) with large haemorrhage, as from second degree injury. (Fig.16)

MRI instead showed an increase in muscle size due to oedema with dishomogeneous signal hyperintensity due to interstitial and perifascial oedema together with a mass of fluid with focal signal hyperintensity due to haemorrhage. (Fig.17)

These images are typical of a second degree injury of Soleus muscle

Case 4

Example of a professional footballer

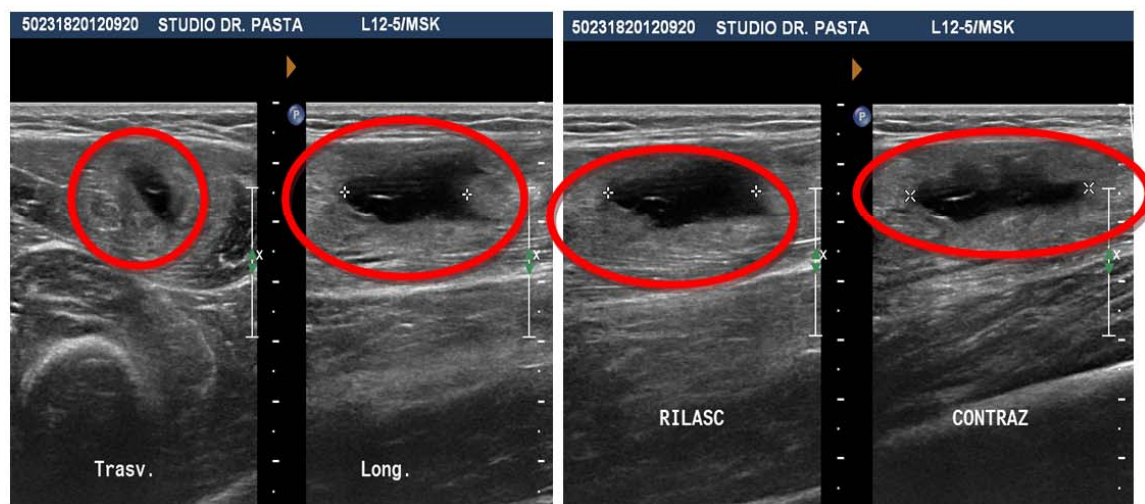


Figure 18. US images of Second degree lesion in a professional footballer

Example of a goalkeeper who during a kick felt a very sharp pain in the quadriceps

Ultrasound highlighted a clearly dishomogeneous area with marked structural change showing a large intramuscular anechoic area (>5 cm) with large haemorrhage.

MRI instead showed an increase in muscle size due to oedema with dishomogeneous signal hyperintensity due to interstitial and perifascial oedema together with a mass of fluid with focal signal hyperintensity due to haemorrhage.

These images are typical of a second degree injury of Rectus Femoris

Case 5

Example of a professional footballer

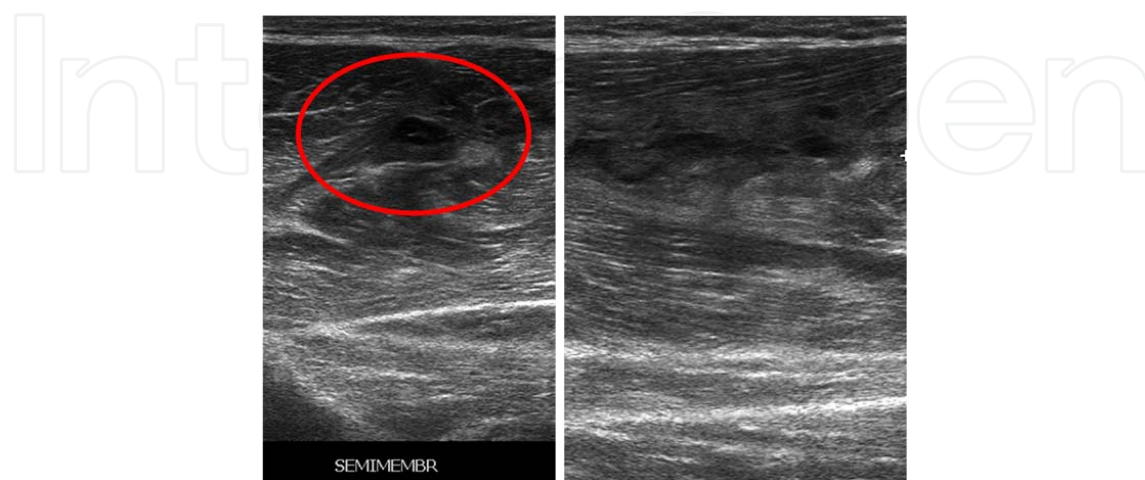


Figure 19. US images of Second degree lesion in a professional footballer

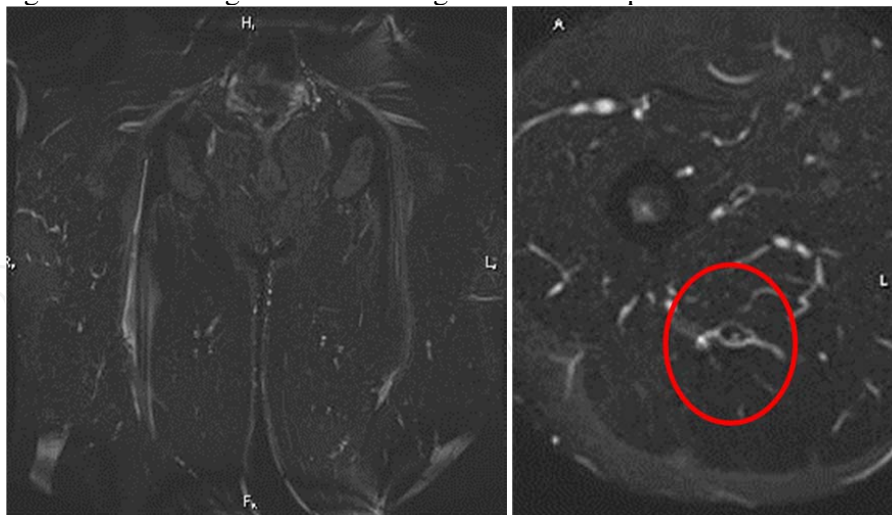


Figure 20. RMN images of Second degree lesion in a professional footballer

Major League footballer who felt a very sharp pain in a sprint on 29 September.

The first Ultrasound on 1 October highlighted a large anechoic area as from second degree miotendon injury of the Semimembranosus. (Fig.19)

MRI on 15 October highlighted a wide area with signal hyperintensity confirming the miotendon injury and intratendon tear too. (Fig.20)

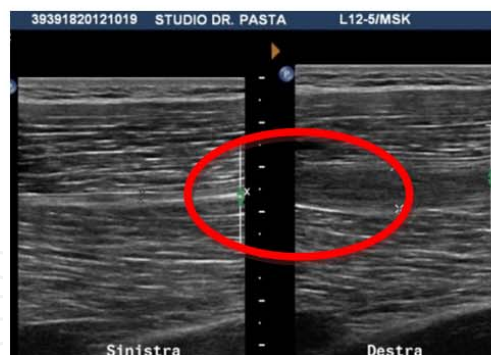

Figure 21. US image of Second degree lesion in a professional footballer

Follow-up analyses, i.e. Ultrasound on 19 October (Fig.21), MRI on 24 October and MRI on 2 November show the development of the pathology up to the disappearance of the modified signal in MRI as from recovery. (Fig.22)

Case 6

Example of a professional footballer

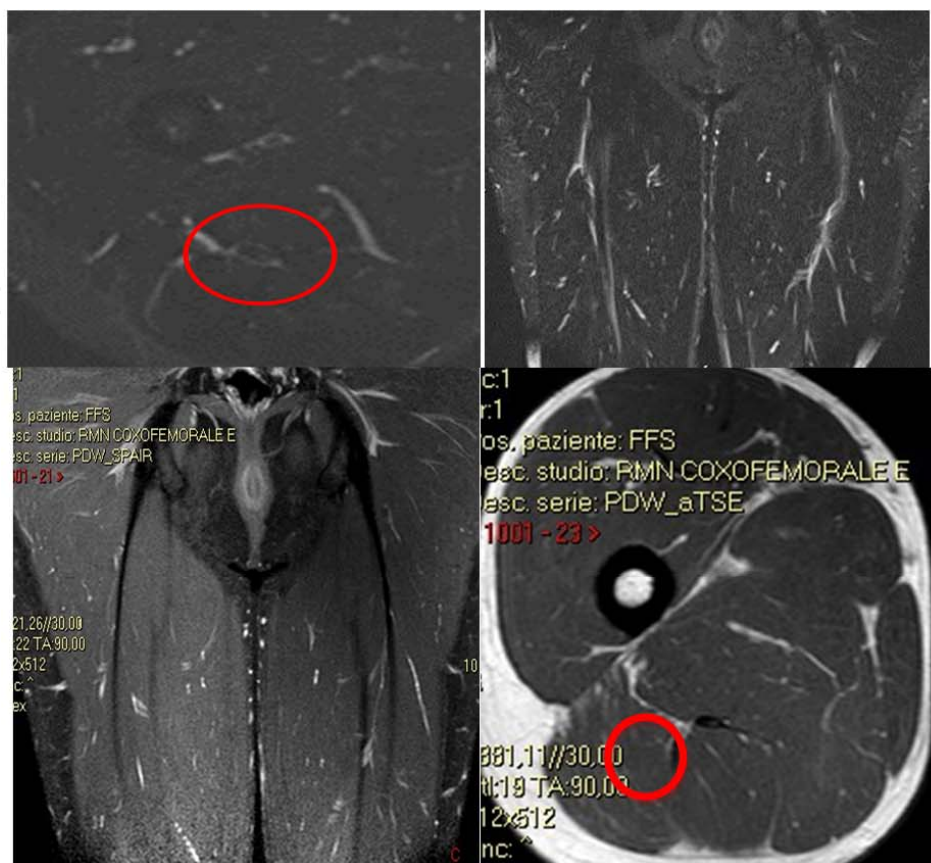

Figure 22. RMN images of Second degree lesion in a professional footballer

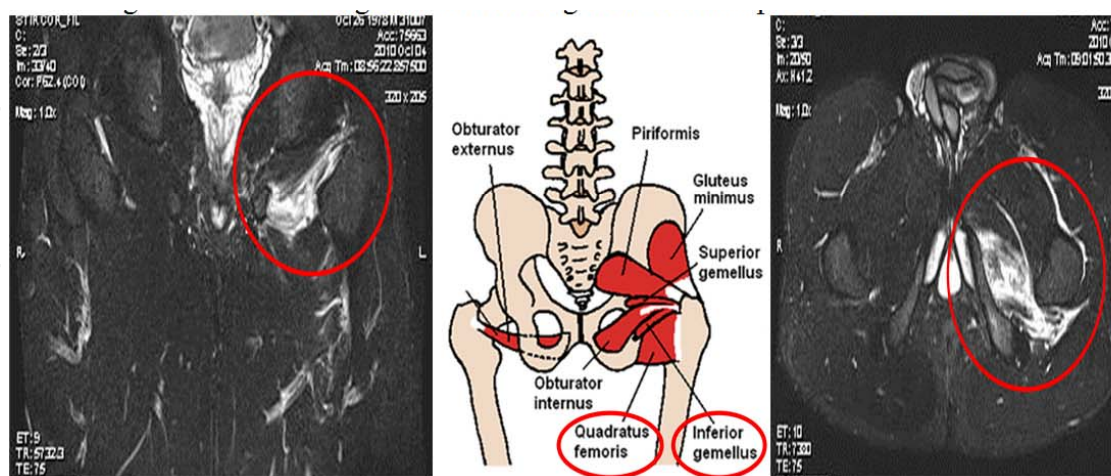


Figure 23. RMN images of Second degree lesion in a professional footballer

Professional footballer who felt a harp pain in the groin after a match but was able despite the pain to carry out differentiated training for four-five days.

The pain persisted so after a negative Ultrasound MRI was carried

This highlighted a large serum-haemorrhagic area characterized by clear signal hyperintensity as from second degree injury of the QuadratusFemoris and of the Inferior Gemellus. (Fig.23)

Case 7

Example of a professional footballer

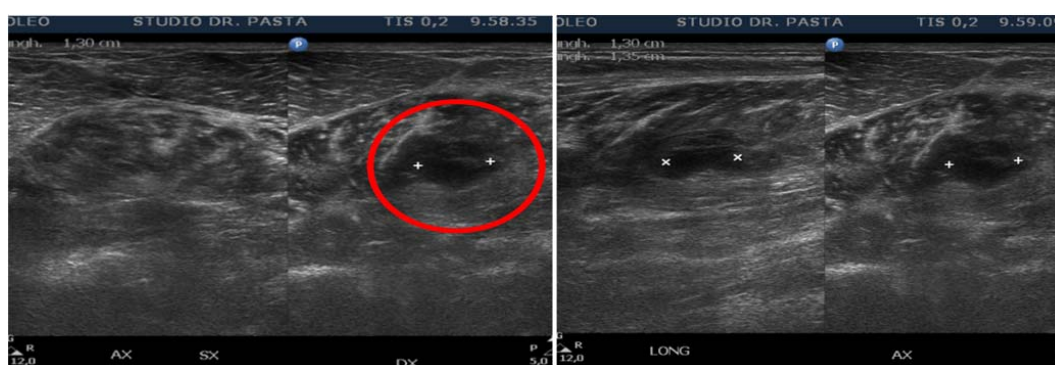


Figure 24. US images of Second degree lesion in a professional footballer

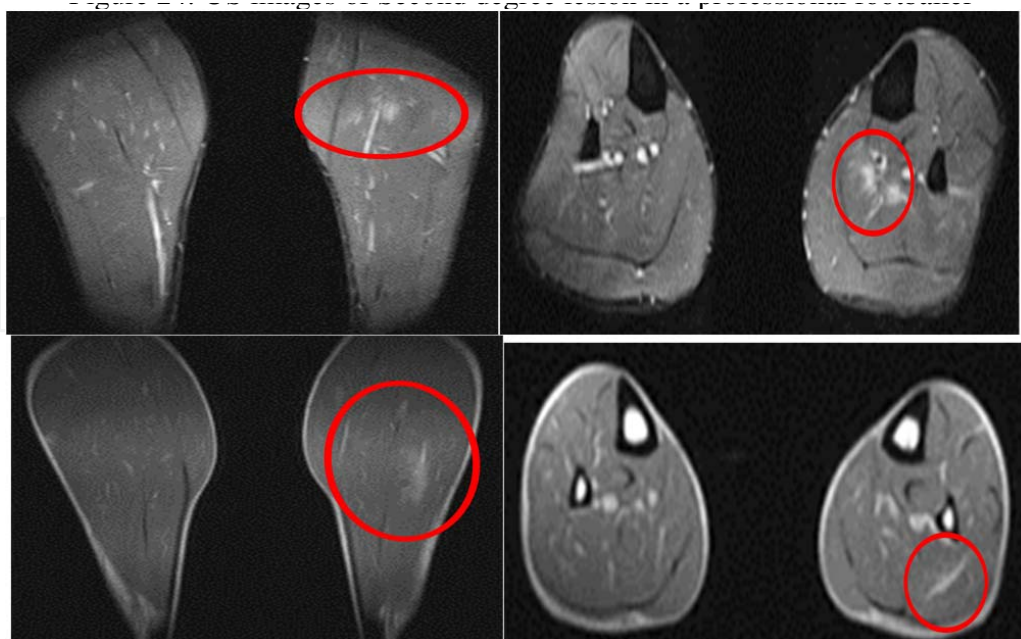


Figure 25. RMN images of Second degree lesion in a professional footballer

Example of a professional footballer who felt sharp pain in the calf during pre-match warm up.

Ultrasound highlighted a single intramuscular anechoic area (>5 cm) with large haemorrhage as from isolated second degree injury of the Soleus muscle. (Fig.24)

Because of an unclear diagnosis MRI was carried out which showed a double area with dishomogeneous signal hyperintensity due to interstitial and perifascial oedema together with haemorrhage as from a double second degree injury of the Soleus muscle. (Fig.25)

These images are typical of a complex second degree injury

Case 8

Example of a professional football player

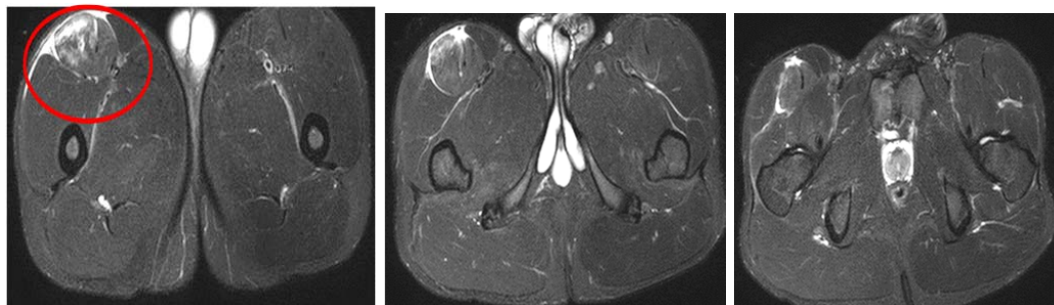


Figure 26. RMN images of Second degree lesion in a professional footballer

Professional footballer who felt a sharp pain during pre-season camp.

An initial Ultrasound (not published here) highlighted a large anechoic area (>5 cm) as from myotendon second degree injury of the Rectus Femoris muscle.

MRI showed relevant signal hyperintensity due to oedema together with haemorrhage as from second degree injury of the Anterior or Straight Tendon of Rectus Femoris muscle. (Fig.26)

Follow-up MRIs show the development of the pathology up to the disappearance of the modified signal in MRI as from recovery. (Fig.27)

Caso 9

Example of a professional footballer

Professional footballer who came for Ultrasound a few days after kicking a goal and feeling a sharp pain in the quadriceps.

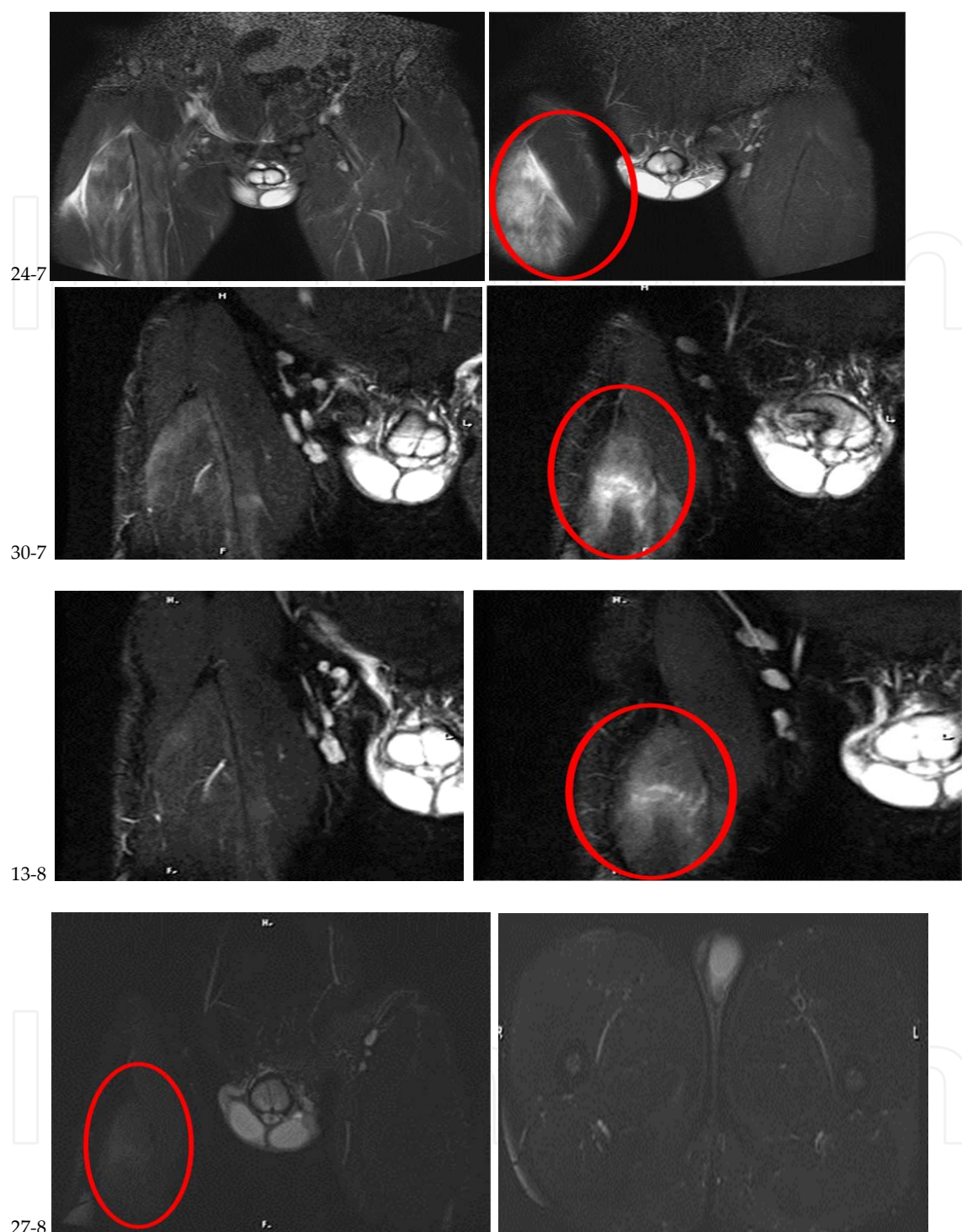


Figure 27. RMN images of Second degree lesion in a professional footballer

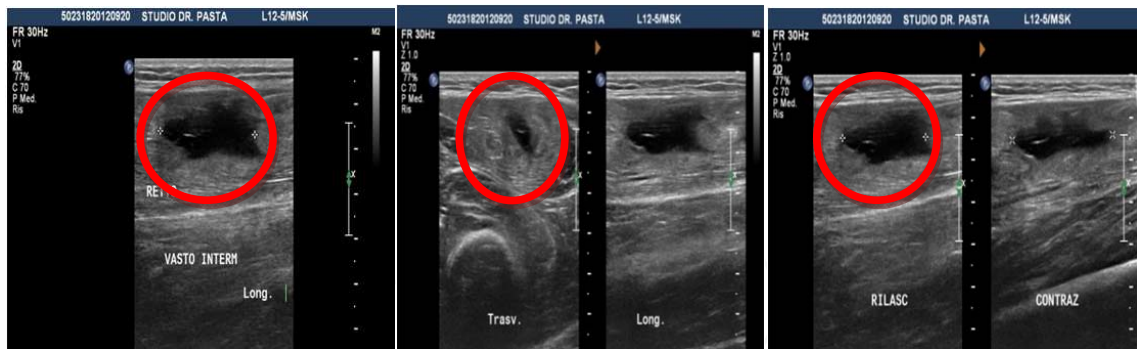

Figure 28. US images of Second degree lesion in a professional footballer

Ultrasound showed a large anechoic area of structural alteration due to haemorrhage with distancing of muscular extremities as from second degree injury of Posterior or Reflected Tendon. (Fig.28)

Subsequent MRI (Fig.29-30-31) and Ultrasound (Fig.32) show the development of the pathology up to disappearance of the modified signal in MRI as from recovery.

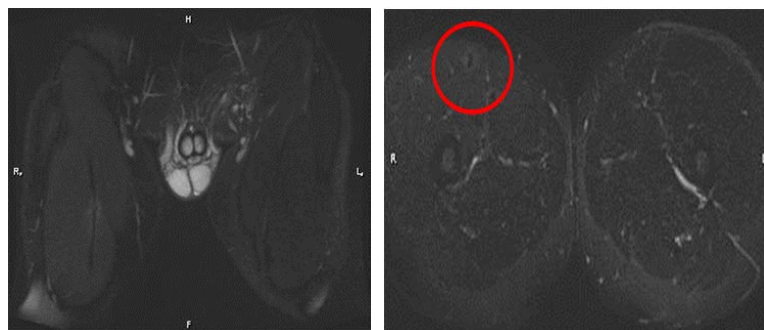


Figure 29. Rmn 11-11 in stir without Gadolinium

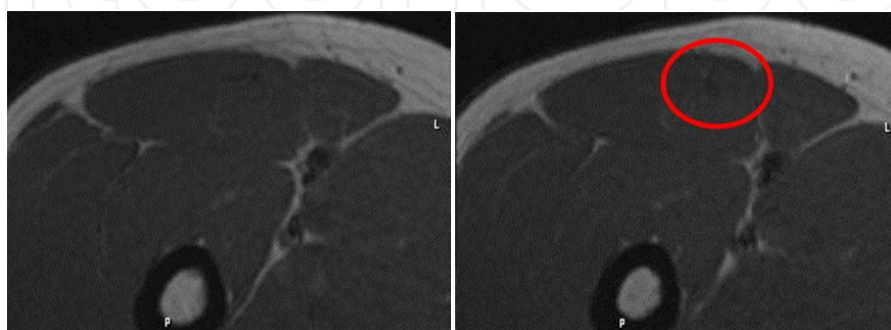


Figure 30. Rmn 11-11 in T1 without Gadolinium

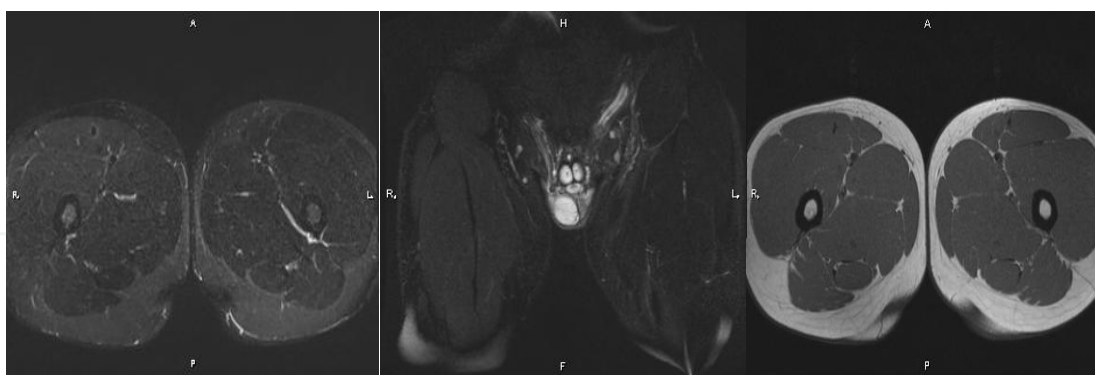


Figure 31. Rmn 3-12

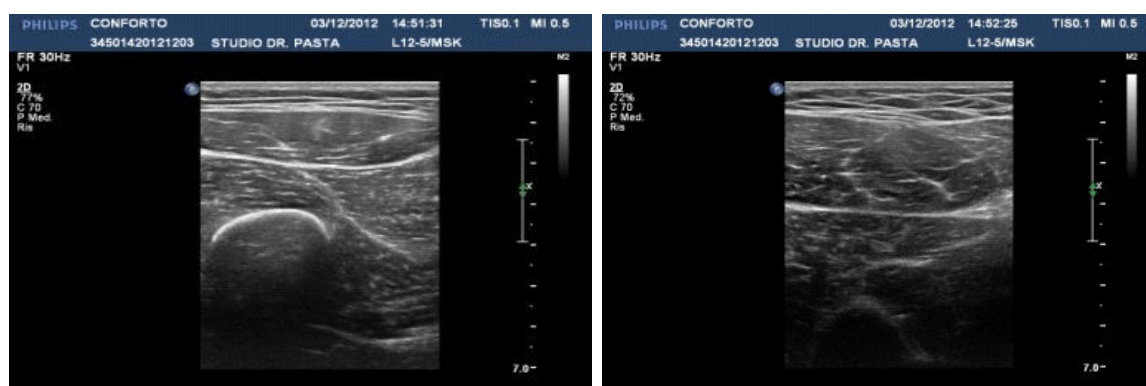


Figure 32. US 3-12

3.6. Third degree injury

Third degree injuries are defined as Subtotal with a tear of a higher number of fibres in the muscle ($>70\%$, $> 2/3$ of the muscle belly) or Total with a tear of the whole muscle belly.

In the acute stage the Ultrasound highlighted a clearly dishomogeneous and disorganized iso-hyperechoic area, whilst in the sub-acute stage a clearly dishomogeneous area with marked structural change was revealed together with retraction of the stumps and a large anechoic inter or intramuscular area (usually $>3\text{cm}$) depending of the size of the muscle.

MRI instead revealed a retraction of the stumps which showed irregular, wavy edges and hyperintense mass of fluid due to the haemorrhage between the two stumps.

Case 1

Example of a professional rugby player

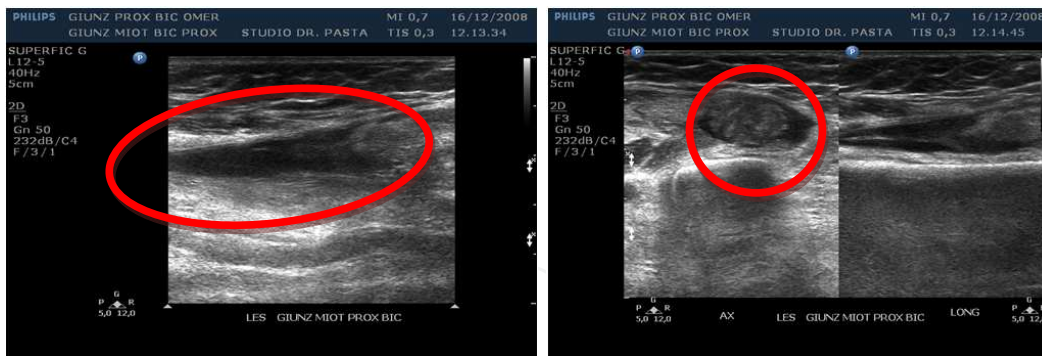

Figure 33. US images of Third degree lesion in a professional rugby player

Example of a professional rugby player who came for Ultrasound to his arm after prolonged tackle. A large anechoic area was revealed due to haematoma associated to retraction of the muscle head as from a complete tear of the Proximal Biceps Brachii. (Fig.33)

Case 2

Example of a professional footballer

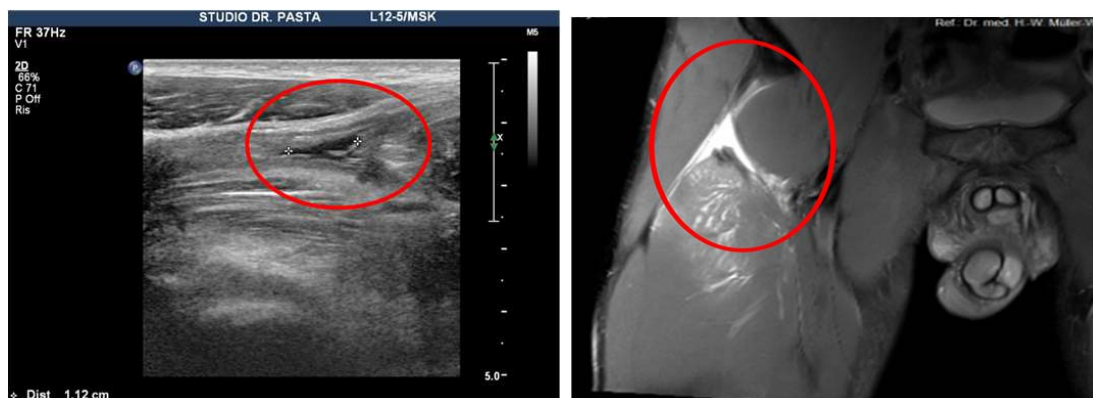

Figure 34. US images of Third degree lesion in a professional footballer

Example of a young goalkeeper who after a kick felt a sharp pain in the upper thigh as if from hip dislocation.

Ultrasound showed a small haemorrhage as from miotend injury.

However symptoms led to a more severe injury.

MRI highlighted a haematoma shown by a hyperintense area associated to miotendon retraction as from sub-total tear of the Rectus Femoris Tendon. (Fig.34)

Case 3

Example of a professional footballer

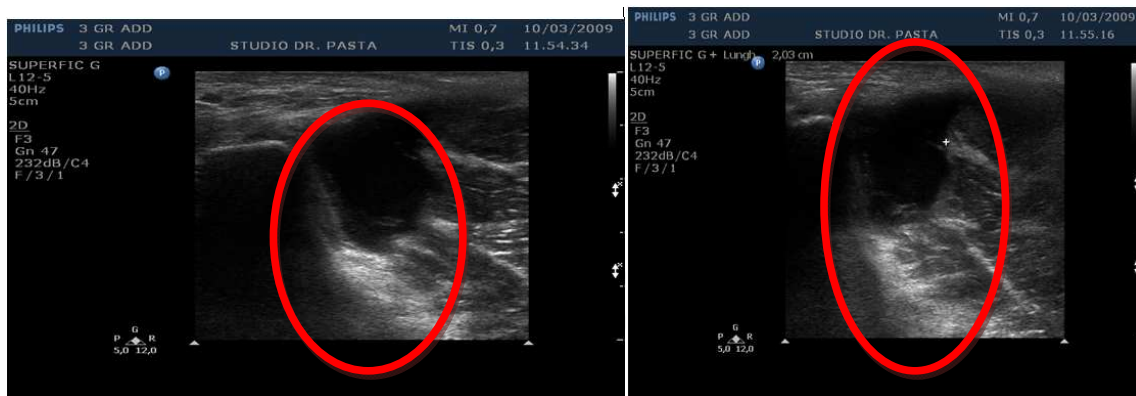


Figure 35. US images of Third degree lesion in a professional footballer

Example of a footballer who after a kick felt a very sharp pain in the groin.

Ultrasound showed a large anechoic area due to haematoma with retraction of the muscle head as from complete third degree tear of the Adductor Longus muscle. (Fig.35)

Case 4

Example of a professional footballer

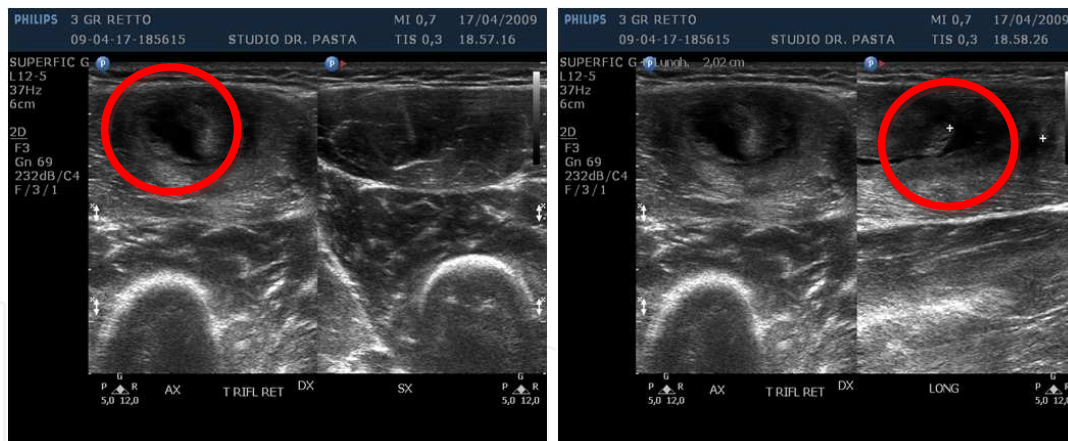


Figure 36. US images of Third degree lesion in a professional footballer

Example of a footballer who after a kick felt a very sharp pain in the upper thigh.

Ultrasound showed a large haematoma with retraction of the muscle head as from complete third degree tear of the Rectus Femoris. (Fig.36)

Case 5

Example of a professional rugby player

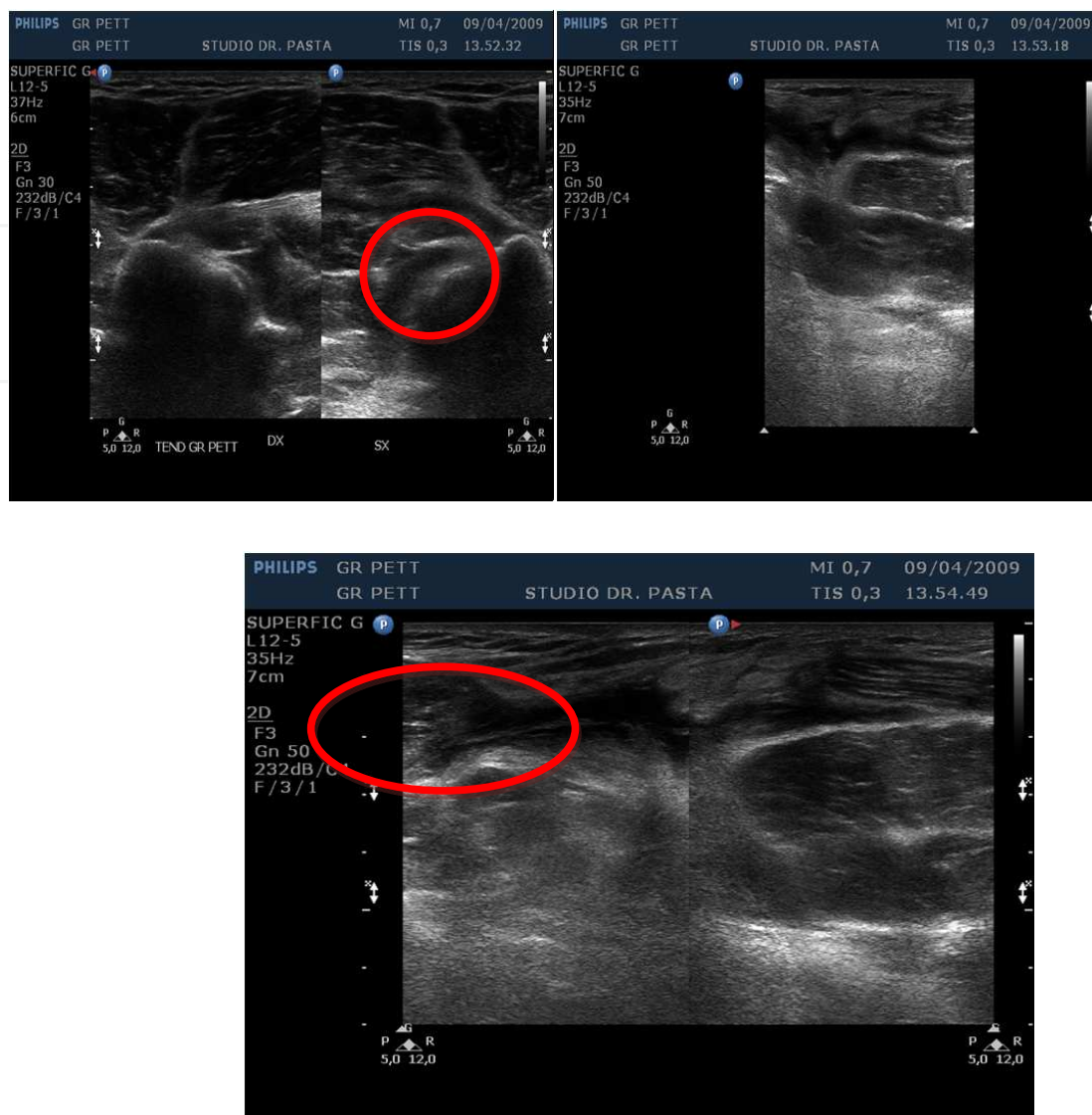


Figure 37. US images of Third degree lesion in a professional rugby player

Example of a professional rugby player who came for Ultrasound to his arm after prolonged tackle.

A large anechoic area was revealed due to haematoma associated to retraction of the muscle head as from a complete tear of the Tendon of the Pectorali Major muscle. (Fig.37)

3.7. Direct muscular injuries

This typically are injuries by contusion followed by hoematoma which by ultrasound revealed no difference from intrinsic hoematoma

Only a correct history of the injury can help in understanding the stages in the level of the fluid.

Case 1

Example of a professional footballer

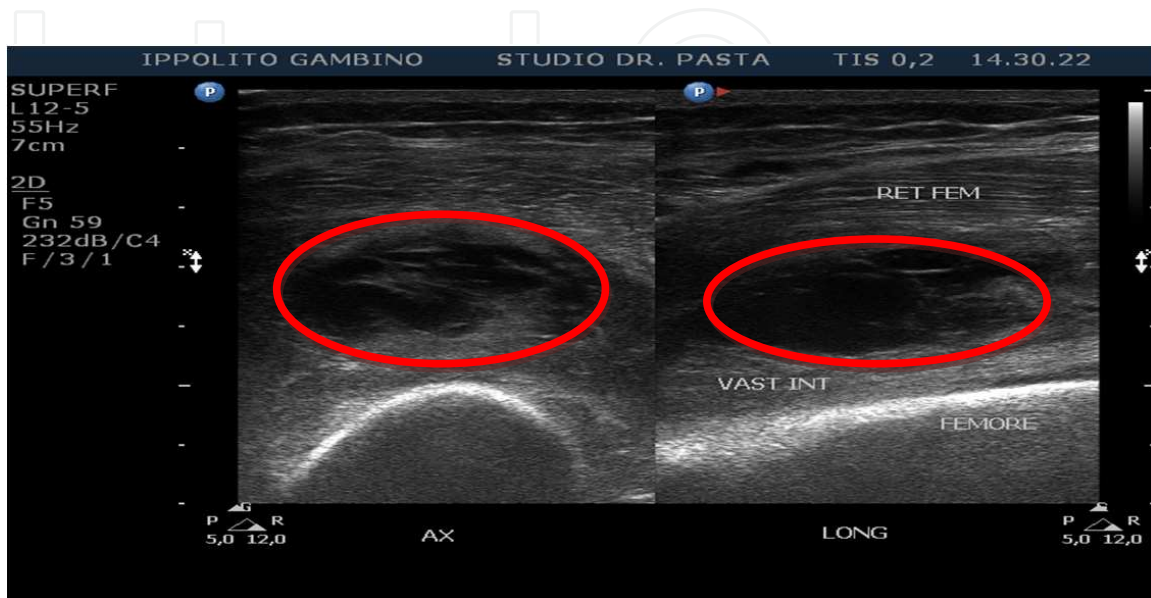


Figure 38. US image of lesion due to a contusion in a professional footballer

Example of a goalkeeper who during jump was hit with a knee on his thigh receiving a contusion and subsequent injury of the VastusIntermedius muscle

The Ultrasound revealed a large anechoic area. (Fig.38)

Case 2

Example of a professional footballer

Example of a goalkeeper who during jump was kicked in the side of his abdomen receiving a contusion and subsequent injury of the ObliquusAbdominis Muscle

The Ultrasound revealed a large anechoic area of the ObliquusAbdominis Muscle. (Fig.39)

4. Chronic lesions in muscle injuries

When a muscle is subject to a trauma (either direct or indirect) the subsequent inflammation is meant to repair the damage tissue in order to allow its complete recovery.

Sometimes, however, the complete recovery does not take place giving raise to complication and conditions which for an athlete can be a serious problem as the performance can be severely limited.

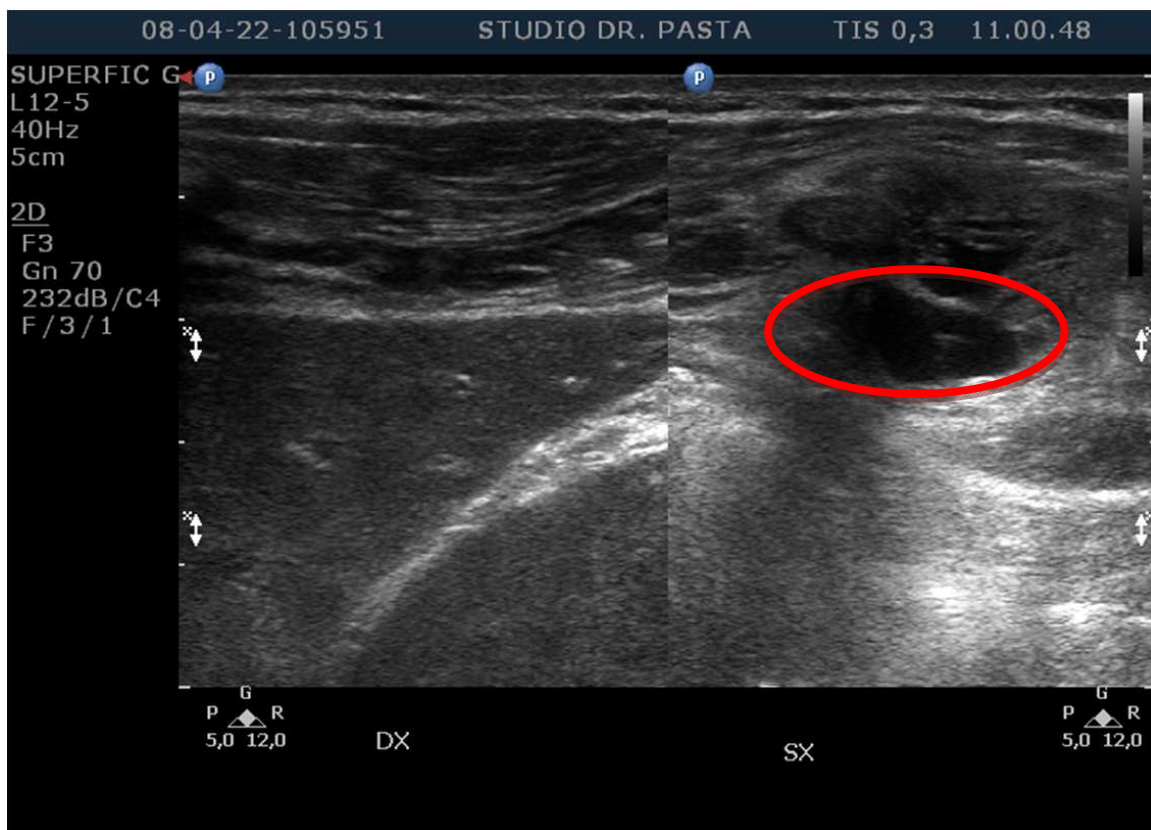


Figure 39. US image of lesion due to a contusion in a professional footballer

Differently from the classification above a definition of muscle injury complication appears to be universally recognized and more simple.

These include:

- Fibrosis
- Intermuscular fluid collection
- Cyst sero-sanguineus
- Ossific myositis
- Muscular atrophie

4.1. Fibrosis

It is the most frequent complication.

It reduces the muscle elastic and functional capacities (the capacity to develop strength) as it replaces the normal tissue.

It is usually caused by early mobilisation or prolonged immobilisation with excessive formation of abnormal, hypertrophic retracting fibrous tissue which affect the functionality of the muscular area involved.

The Ultrasound reveals a hyperechoic area which represents fibrous tissue in the injured muscle

Case 1

Example of a professional footballer

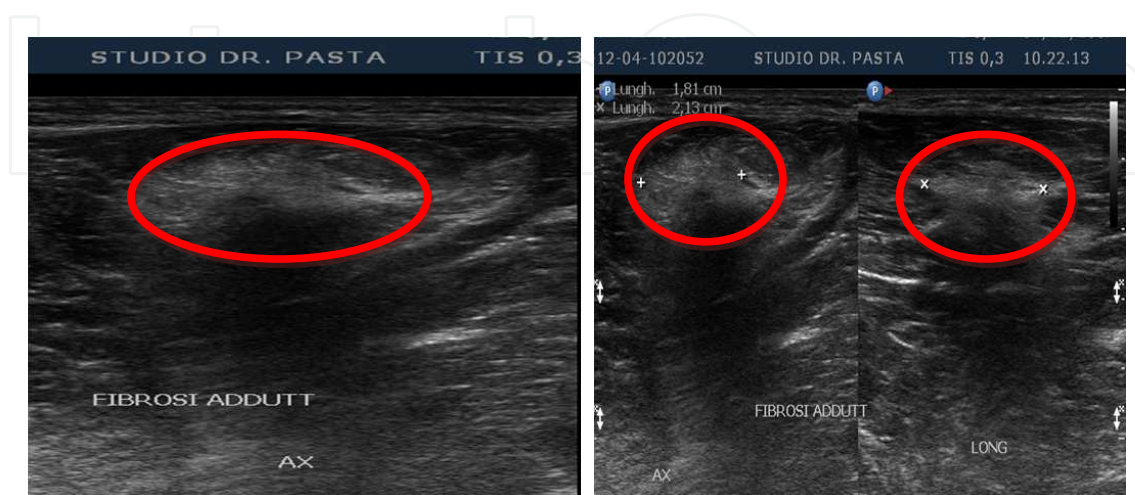


Figure 40. US images of Fibrosis in a professional footballer

Example of a professional footballer with a fibrosis of the Adductor muscle approximately two months after a severe injury

Ultrasound reveals a large hyperechoic area in the previously injured muscle from reparation of the muscular injury with formation of abnormal, hypertrophic retracting fibrous tissue which affect the functionality of the muscular area involved. (Fig.40)

Case 2

Example of a professional footballer

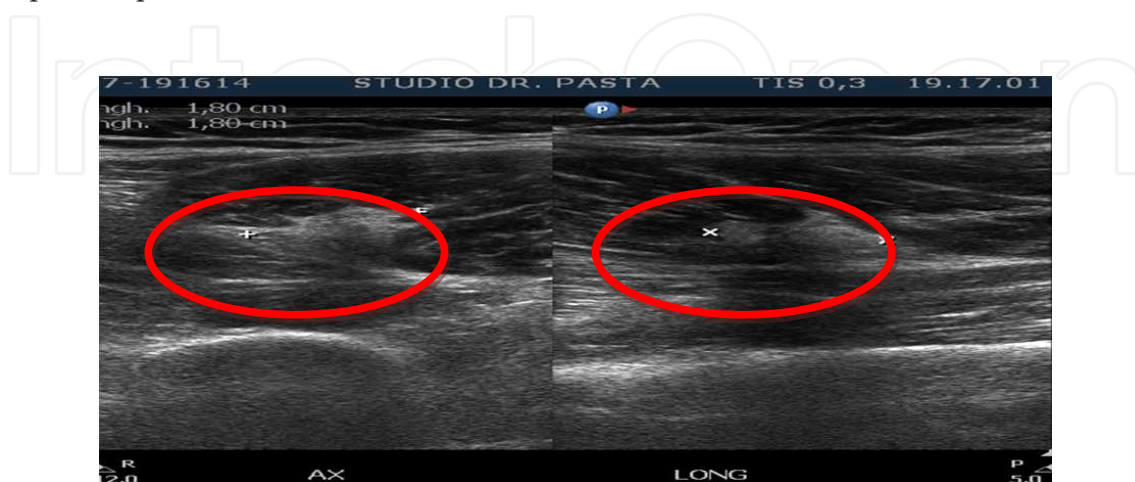


Figure 41. US images of Fibrosis in a professional footballer

Example of a professional footballer with a fibrosis of the Rectus Femoris muscle approximately two months after a severe injury

Ultrasound reveals a large hyperechoic area in the previously injured muscle from reparation of the muscular injury with formation of abnormal, hypertrophic retracting fibrous tissue which affect the functionality of the muscular area involved. (Fig.41)

4.2. Intermuscular fluid collection

It is a reaction process with formation of sero-sanguineus fluid between two muscular fasciae detectable by Ultrasound as a long plate with totally anechoic or hypoechoic or echoic structure.

Case 1

Example of a professional footballer

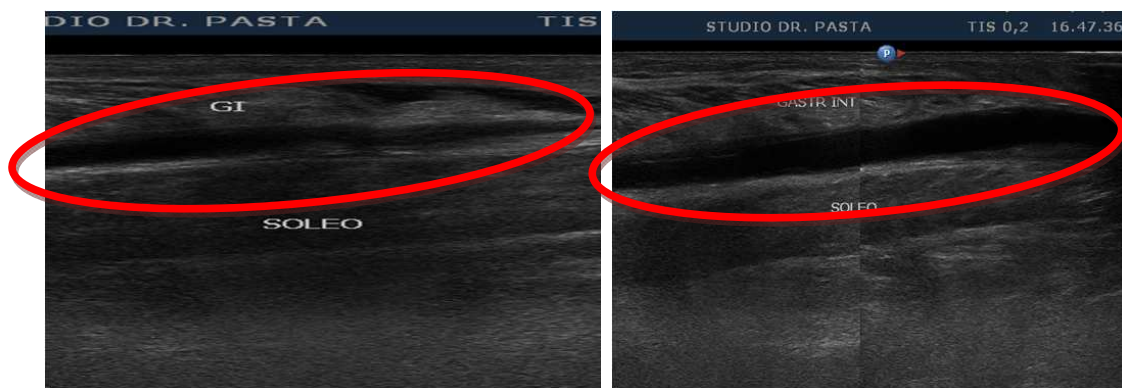


Figure 42. US images of a Fluid Collection in a professional footballer

Example of a footballer with residual and totally colliquative fluid collection between Gastrocnemius and Soleus muscles detectable by Ultrasound as a completely anechoic long plate. (Fig.42)

Case 2

Example of a professional footballer

Example of a footballer with residual fluid collection partially colliquative and partially structured detectable by Ultrasound as a completely hypoechoic long plate. (Fig.43)

Case 3

Example of a professional footballer

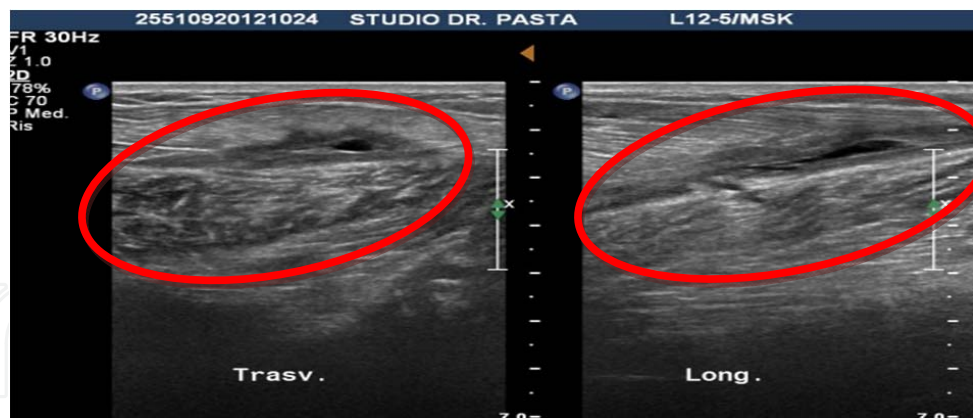


Figure 43. US images of a Fluid Collection in a professional footballer

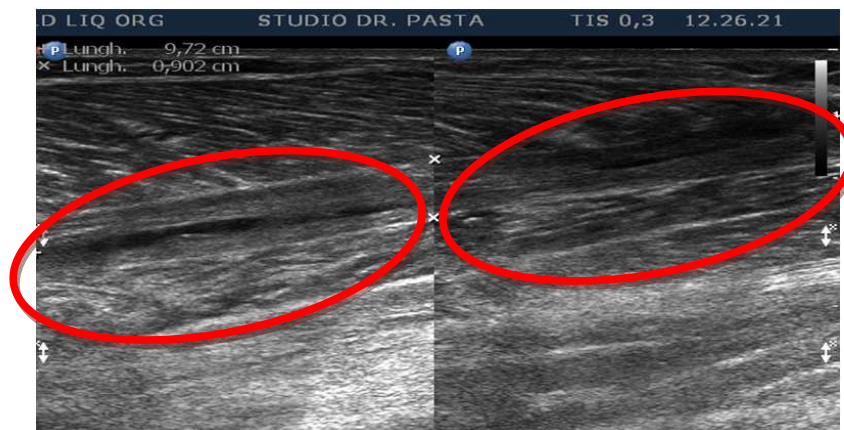


Figure 44. images of a Fluid Collection in a professional footballer

Example of a footballer with totally structured fluid collection between Gastrocnemius and Soleus muscles detectable by Ultrasound as a completely anechoic long plate. (Fig.44)

4.3. Cyst sero-sanguineus

It is the consequence of a badly treated hoematoma which is not completely absorbed and which is encapsuled by newly formed fibrous tissue which separates it from the surrounding muscular tissue.

It originates from reaction process of the badly treated hoematoma which leads to the formation of sero-sanguineus fluid structured as a cyst capsuled in newly formed fibrous tissue.

Ultrasound reveals a completely anechoic round shaped structure with posterior acoustic enhancement.

Case 1

Example of professional footballer

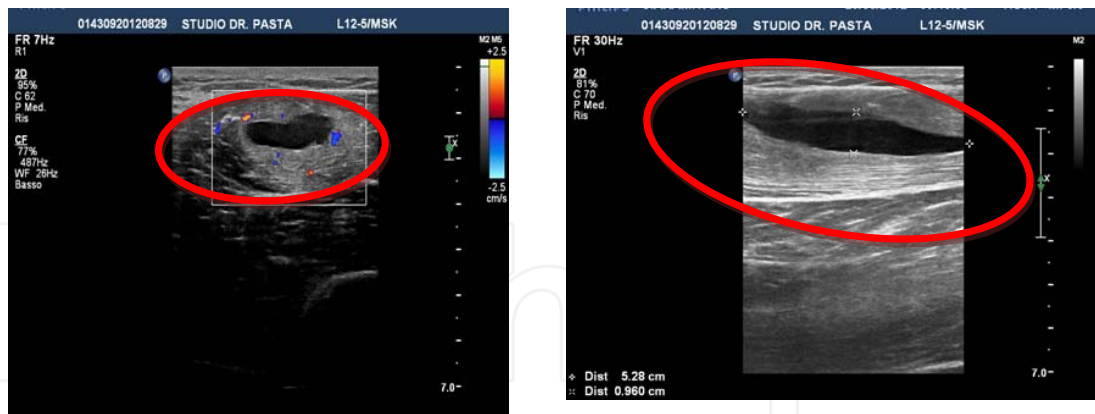


Figure 45. US images of a Sero-sanguineus cyst in a professional footballer

Example of a professional footballer with sero-sanguineus cyst of the Rectus Femoris Muscle approximately three weeks after muscular injury.

Ultrasound reveals a completely anechoic round shaped structure with posterior acoustic enhancement. (Fig.45)

4.4. Ossific myositis

Badly treated inflammatory process of the injured muscle usually after contusion of large limb muscles close to the bones which leads to calcium deposit.

Two stages can be identified, a pre-calcific stage which is revealed as a pseudo solid mass in Ultrasound with Doppler signal along the edges and a calcific stage represented by a heterogeneous mass with linear hyperechoic imaging showing posterior acoustic shadows and both central and peripheral vessels

Case 1

Example of a professional rugby player

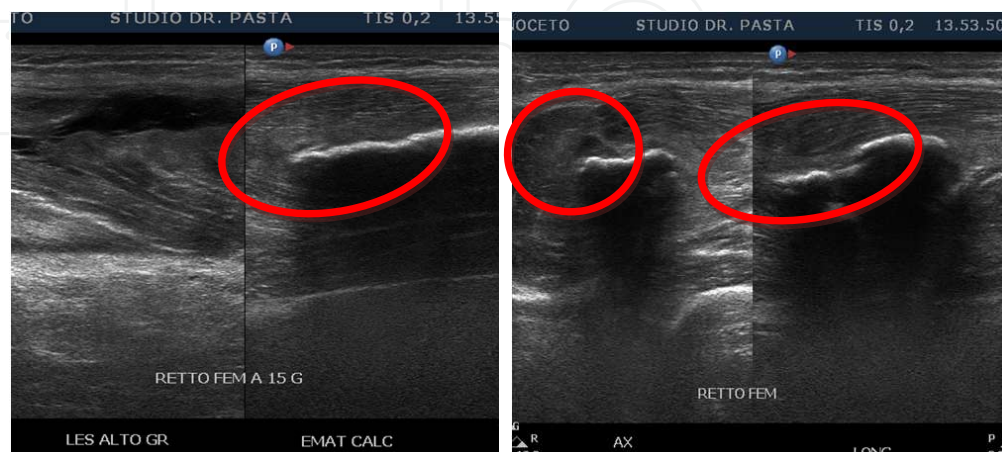


Figure 46. US images of a calcification in a professional rugby player

Post contusion injury of the Rectus Femoris muscle approximately two weeks after the injury with hoematoma linked to calcification easily detectable by Ultrasound as a heterogeneous mass with linear hyperechoic imaging showing posterior acoustic shadows. (Fig.46)

Case 2

Example of a professional rugby player

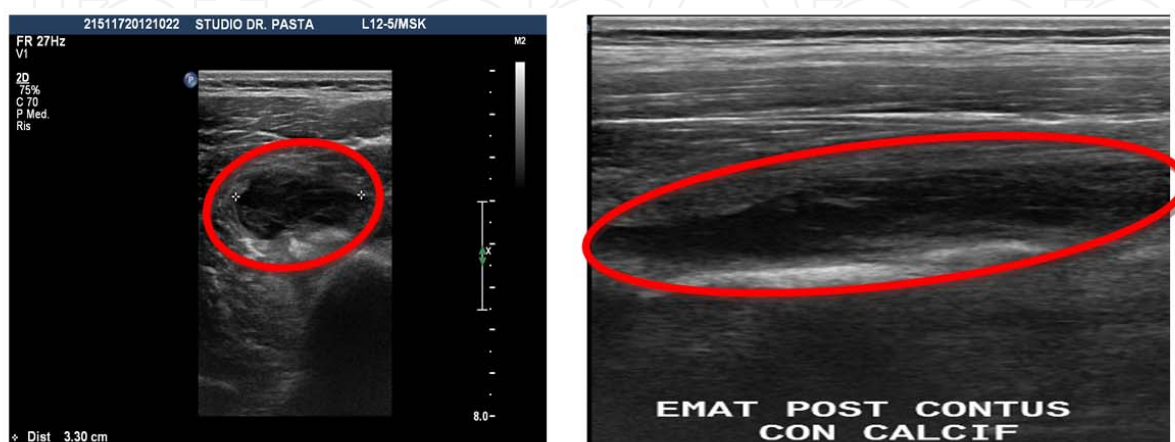


Figure 47. US images of a calcification in a professional rugby player

Example of a post contusion injury approximately seven days after the trauma which shows a pseudo solid mass in Ultrasound. (Fig.47)

4.5. Muscular atrofia

This complication originates from a chronic tendon tear or nerve implication with subsequent muscular adipose infiltration linked to reduction of the muscle volume.

Ultrasound shows a reduced hyperechoic muscle

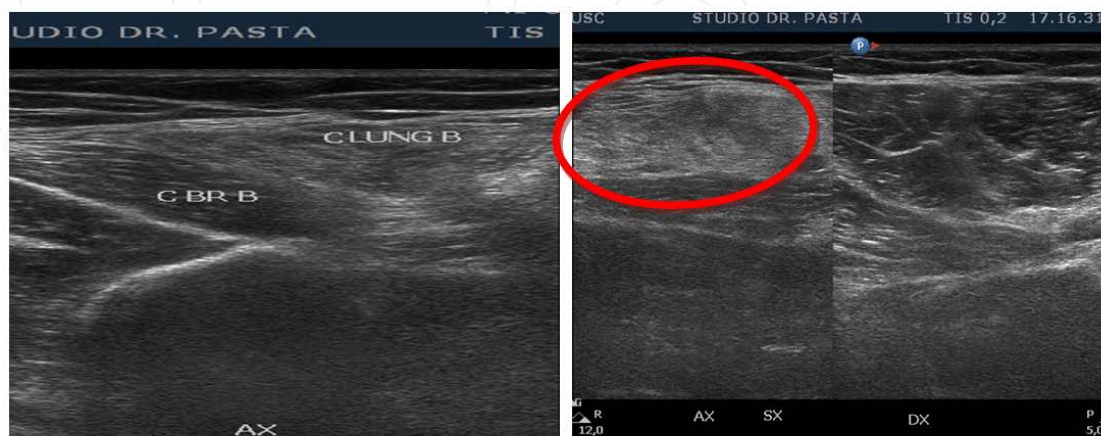

Figure 48. US images of reduced hyperechoic muscle in a professional volleyball player

Case 1

Example of a professional volleyball player (Fig.48)

Example of volleyball player after a severe myotendon injury of the long head of the Biceps Femoris muscle

Ultrasound shows a reduced hyperechoic muscle. (Fig.48)

5. Conclusions

Ultrasound is the first-line technique in the study of muscle traumas, as it is readily available, has a good cost-benefit profile, enables assessment of muscle dynamics and provides reliable assessment of the extent of damage. Musculoskeletal Ultrasound has been shown to be effective for many applications related to sports medicine and has proved itself as one of several imaging methods invaluable to the diagnosis of sport medicine-related abnormalities. Some advantages of Ultrasound over MR imaging include portability, accessibility, high resolution, and relative lower cost. More importantly, dynamic imaging under Ultrasound visualization allows diagnoses that cannot be made with routine MR imaging. Additionally, direct imaging correlation with patient symptoms provides important information to the referring clinicians.

There however some disadvantages.

Among these is the fact that its resolution is limited to the tertiary bundle, it is unable to identify alterations to secondary and primary bundles and myofibrils, and cannot visualise deep muscle planes. For these reasons, Ultrasound may yield negative results in lesions with only slight muscle alterations, such as contracture, lengthening and DOMS. [4]

Other disadvantages of Ultrasound include operator dependence and long learning curve. This can be minimized, however, with proper training and standardized technique.

Musculoskeletal Ultrasound has recently experienced an increase in popularity for several reasons. Advances in technology including the advent of high-frequency transducers have markedly improved image resolution. [2]

Additionally, the relative low expense of Ultrasound compared with MR imaging has made this an attractive alternative imaging method for many indications. Ultrasound does have several potential advantages over MR imaging. Evaluation of a soft tissue process near metal orthopaedic hardware is possible with Ultrasound without the artefact that limits MR imaging. Additionally, Ultrasound can immediately guide percutaneous procedures when an abnormality, such as a joint effusion, is identified. Ultrasound also allows a dynamic evaluation of joints detecting abnormalities that may not be present during MR imaging positioning. Lastly, the improved resolution of superficial structures demonstrates subtle abnormalities that may be difficult to visualize with MR imaging. Current ultrasound technology produces in-plane resolutions of 200 to 450 μm and section thicknesses of 0.5 to 1 mm. For these reasons muscu-

loskeletal Ultrasound has proved to be one of the most valuable imaging methods in the diagnosis of anomalies in sports medicine.

Before it gains universal acceptance in evaluation of the musculoskeletal system, however, Ultrasound must be able to produce results similar to those of MR imaging.

MR imaging is essentially the standard of care for the evaluation of the musculoskeletal system at most centres worldwide.

There exist several advantages of MR imaging over Ultrasound.

The primary advantage is relative lack of operator dependence. This is achieved through the use of standardized MR imaging protocols.

Other advantages include multiplanar capabilities, panoramic views, ability to evaluate deep muscle planes and to detect lesions missed by Ultrasound.

Another advantage is the ability of MR imaging to evaluate globally and thoroughly an anatomic area including deep soft tissues, bone marrow, and joint cartilage with high sensitivity.

Advanced technology has resulted in improved image resolution and shortened imaging times. Images may be acquired at all times of the day at various physical sites. Interpretation of images can also be accomplished promptly with data transfer to computer workstations.

Controversy exists when Ultrasound and MR imaging are compared. Unlike the research results using MR imaging, those pertaining to Ultrasound are usually more variable. Although this can be partially explained by the inherent operator dependence of this imaging method.

Additionally, there are relatively few blinded research studies that directly compare Ultrasound with MR imaging. Many sonographic studies are limited to small subject groups without a gold standard. Additional research is needed to determine Ultrasound's true effectiveness in evaluating the musculoskeletal system relative to MR imaging.

Clinical studies, however, are demonstrating the potential of Ultrasound for several indications and interest in this imaging method continues to grow.

It is obvious that MR imaging will remain the most common advanced imaging method of the musculoskeletal system until research demonstrates that Ultrasound can produce similar results. It is clear, however, that there are several areas where musculoskeletal Ultrasound has been proved effective. Each of these points has allowed MR imaging to become widely accepted for evaluating the musculoskeletal system in sports medicine. [14]

As the images of the cases presented have shown, we too believe that MRI is to be considered the Gold Standard in muscular injuries, but we still consider Ultrasound the first choice because of its specific characteristics.

Further developments will extend applications of Ultrasound and MRI within muscular-skeletal diagnostics, granting many more advantages in real-time performance, high tissue resolution and cost-benefit ratio.

Author details

Massimo Manara¹, Danilo Manari² and Giulio Pasta³

¹ Association of Parma, Italy

² FC Parma, Italy

³ Pasta Associate Clinic for Imaging Diagnostics, Italy

References

- [1] Rubin, S. J, Feldman, F, Staron, R. B, et al. (1995). Magnetic resonance of muscle injury. *Clin Imaging* , 19, 263-269.
- [2] Ultrasound in sports medicineJon AJacobson, MD*RadiolClin N Am* (2002). , 40(2002), 363-386.
- [3] Takebayashi, S, & Takasawa, H. Banzai Yet al ((1995). Sonographic findings in muscle strain injury: clinical and MR imaging correlation. *J Ultrasound Med*, 14, 899-905.
- [4] A. Megliola, F. Eutropi, A. Scorzelli, D. Gambacorta, A. De Marchi, M. De Filippo, C. Faletti & F.S. Ferrari. Ultrasound and magnetic resonance imaging in sports-related muscle injuries. *Ruolo dell'ecografia e della risonanza magnetica nello studio delle lesioni muscolari. Radiol med* (2006) 111; DOI 10.1007/s11547-006-0077-5
- [5] Dierking, J. K, & Bemben, M. G. Bemben DA et al ((2000). Validity of diagnostic ultrasound as a measure of delayed onset muscle soreness. *J Orthop Sports Phys Ther* , 30, 116-122.
- [6] De Smet, A. A. (1993). Magnetic resonance findings in skeletal muscle tears. *Skeletal Radiol* , 22, 479-484.
- [7] Hashimoto, B. E, Kramer, D. J, & Wiitala, L. (1999). Applications of musculoskeletal Ultrasound. *J Clin Ultrasound*, 27, 293-318.
- [8] Fornage, B. D. (1995). Muscular trauma. *Clin Diagn Ultrasound* , 30, 1-10.
- [9] Garrett WE Jr ((1996). Muscle strain injuries *Am J Sports Med* 24: SS8, 2.
- [10] Bianchi, S, Martinoli, C, Waser, N. P, et al. (2002). Central aponeurosis tears of the rectus femoris: sonographic findings. *Skeletal Radiol* , 31, 581-586.
- [11] Kolouris, G, & Connell, D. (2003). Evaluation of the hamstring muscle complex following acute injury. *Skeletal Radiol* , 32, 582-589.

- [12] Developments in musculoskeletal ultrasound and clinical applicationsKlauser AS, Peetrons P. Skeletal Radiol. (2009). Sep 3.
- [13] Greco, A, Mcnamara, M. T, Escher, M. B, et al. (1991). Spin-Echo and STIR MRImaging of sports-related muscleinjuries at 1.5 T. J Comput AssistTomogr , 15, 994-999.
- [14] El-Noueam, KI, Schweitzer, ME, & Bhatia, . (1997) The utility of contrastenhancedMRI in diagnosis of muscleinjures occult to conventional MRI.J Comput Assist Tomogr 21:965-968
- [15] Imaging and skeletal muscle diseaseNancy J Olsen MD, Jing Qi MD, Jane H. Park PhDCurrent Rheumatology Reports (2005). , 7(2), 106-114.