We are IntechOpen, the world's leading publisher of Open Access books
Built by scientists, for scientists

6,900
Open access books available

186,000
International authors and editors

200M
Downloads

Our authors are among the

154
Countries delivered to

TOP 1%
most cited scientists

12.2%
Contributors from top 500 universities

CLARIVATE ANALYTICS
BOOK CITATION INDEX
INDEXED

WEB OF SCIENCE™

Selection of our books indexed in the Book Citation Index in Web of Science™ Core Collection (BKCI)

Interested in publishing with us?
Contact book.department@intechopen.com

Numbers displayed above are based on latest data collected.
For more information visit www.intechopen.com

Chapter 6

Robotic Harvest of the Latissimus Dorsi Muscle for Breast Reconstruction

Jesse Selber

Additional information is available at the end of the chapter

http://dx.doi.org/10.5772/55040

1. Introduction

Robotic technology has assumed a prominent position in minimally invasive surgery throughout the surgical subspecialties1234. Enhanced precision, tremor elimination, motion scaling, high resolution, 3-D optics and an intuitive interface have permitted wide adoption of robotic surgical techniques across a range of intra-corporeal procedures.

As experience with robotics has grown and permeated main stream surgery, applications in plastic surgery have emerged. Trans-oral robotic reconstruction of oropharyngeal defects has gained momentum, and is now performed in select academic centers in the United States.56789 Robotic microsurgery is a burgeoning field that has great potential for growth as robotic technology and instrumentation improves.101112

Because plastic surgeons are infrequently involved with intracorporeal procedures, there is not a rich history of minimally invasive training in the specialty. Muscle flaps are one of the few reconstructive procedures in which plastic surgeons bypass the skin entirely to gain access to deeper tissue planes. For that reason, there exists the opportunity for a minimally invasive approach to muscle flap harvest.

The latissimus dorsi muscle has been a workhorse of reconstructive surgery since its original description by Iginio Tansini in 1906.13 Its diverse applications range from breast reconstruction with implants, partial breast reconstruction, chest wall and intra-thoracic reconstruction, scalp and extremity coverage, and functional muscle transfer.14,15,16,17,18,19,20 Traditional harvest technique requires a posterior donor-site incision that can be between 15 cm and 45 cm in length, in addition to an axillary incision for pedicle harvest or transfer (Figure 1). The reason for this length is that the incision must accommodate access to the thoracodorsal pedicle in the axilla, as well as the origin of the muscle along the thoracolumbar fascia.

INTECH
open science | open minds

© 2013 Selber; licensee InTech. This is an open access article distributed under the terms of the Creative Commons Attribution License (http://creativecommons.org/licenses/by/3.0), which permits unrestricted use, distribution, and reproduction in any medium, provided the original work is properly cited.

Minimally invasive harvest of the latissimus flap has long been a desirable goal. Endoscopic harvest has been attempted by multiple groups, and is still practiced in certain centers.21,22,23 But because of technical challenges such as line of sight around the curvature of the back, limitations of endoscopic instrumentation, and difficulty maintaining an optical window, all but a few centers have abandoned this technique.24,25

The robotic platform has specific advantages that make it superior to traditional endoscopy. One is the high resolution, three-dimensional optics. The incredible picture clarity and magnification at the point of surgery allow for better identification and control of perforating blood vessels, which has been a problem for the endoscopic approach, evidenced by a high rate of conversion to the open procedure. Another advantage is instrumentation. The robotic instruments have motion in 7 degrees of freedom at the very tips. Not only does this allow for incredible precision in controlling small vessels and maintaining a consistent plane, but it allows negotiation around the curvature of the back. This feature is absent in "straight-stick" endoscopy, which has no real versatility at the tips of the instruments. Finally, surgeon comfort and positioning removes much of the awkwardness of the endoscopic approach to muscle harvest, where the surgeon can find herself struggling in a mechanical disadvantage.

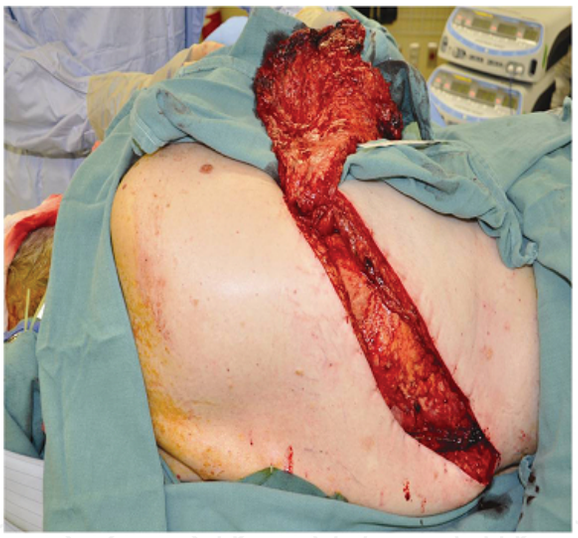

Figure 1. Traditional incision for harvest of the latissimus dorsi muscle can be very long, to access both the pedicle and the muscle origin

2. Operative procedure

2.1. Positioning and defining landmarks

The muscle harvest is performed, like a standard latissimus dorsi harvest, with the patient in the decubitus position with the ipsilateral arm prepped and placed on a sterile Mayo stand. An axillary roll is used to prevent contralateral, brachial plexopathy. The borders of the LD

http://dx.doi.org/10.5772/55040

muscle are marked on the patient: the anterior border is palpated preoperatively during active muscle contraction, the superior border is marked from the tendinous insertion, along the tip of the scapula to the posterior border, and the posterior border is marked about 4 cm lateral to the spine.

The bed can be retroflexed in the middle to help open the space between the iliac crest and the lower border of the ribcage. This is important because at the extremes of dissection, as the arms line up with one another, they will frequently bump into the hip or shoulder. Retroflexion obviates some of this problem.

2.2. Incision and port locations

Figure 2 demonstrates the markings for the axillary incision and port placement. When the harvest is performed for breast reconstruction, the sentinel lymph node or axillary node dissection incision is used, without the need for an additional incision. If a new axillary incision is required, then it is designed to facilitate pedicle dissection, dissection of the subcutaneous space anterior to the muscle, and placement of a port at the inferior end of the incision. In such cases, a 5-8 cm incision is oriented along a line between the posterior axilla and the nipple areolar complex. This vector accomplishes two things: 1) it allows the incision to be oblique to the plane of dissection anterior to the muscle, affording a broader initial dissection view 2) it allows a port to be placed in the distal end of the axillary incision, because it is an adequate distance from both the muscle edge and pedicle.

The first port is placed at the end of the axillary incision, which is later closed temporarily with a running stitch to maintain insufflation. The second and third ports are then placed approximately 8 cm apart from each other and from the 1st port, and 8 cm anterior to the anterior border of the muscle. This places the central port at the infra-mammary fold in women, concealing this 12 mm port site. The distal, 8 mm port remains the only visible scar with the arm in repose. The port in the axillary incision can be double cannulated with an 8 mm port inside a 12 mm port. This has two benefits: 1) the inner port can be removed and a laporacopic instrument such as a grasper, a clip applier or a suction irriagator can be placed by the bedside assistant, and 2) and a smoke evacuator can be attached to the insufflations port which helps with visualization. Isufflation can be tolerated at up to 15 mm Hg.

2.3. Initial dissection and port placement

The axillary incision is opened, and the thoracodorsal pedicle is identified, isolated and marked with a vessel loop for identification under endoscopic vision. This is important because when in the console, although detail is very good, orientation can be challenging. Having the pedicle marked helps avoid it at the proximal extent of the dissection and prevents inadvertent pedicle damage. The subcutaneous space anterior to the anterior border of the muscle is then dissected using a long-tip electrocautery and a lighted retractor, in order to place additional ports. The axillary incision, the two additional ports and the anterior border of the muscle must form a hemi-octagon (as shown in Figure 2) that must be completely dissected through the axillary incision to create the confluent subcutaneous space to facilitate placement of instruments and initiation of the dissection.

Figure 2. Port placement and axillary incision design for robotic harvest of the LD is shown in relation to the anterior border of the muscle. A hemioctagonal, subcutaneous area is dissected for optimal exposure and ergonomics.

The open dissection through the axillary incision is optimized in the following two ways to ensure a smooth transition to the initial robotic dissection: 1) the deep muscular plane is dissected under direct vision through the axilla as far as technically feasible. This dissection is easily performed under direct vision, and requires less precision, cutting down on unnecessary robotic time. 2) Approximately 4 cm of the superficial plane over the muscle is dissected through the axilla, releasing the anterior border of the muscle so that it is suspended loosely enough that the initial robotic subcutaneous dissection is facilitated, but not released to an extent that obscures the robotic view of the sub-muscular plane of dissection. This is a very helpful technical point. If the muscle is not released at all, then it is very difficult to do robotically, because the machine has to look almost straight up at the muscle. If the edge hangs down, the dissection can be brought into a better orientation for the angle of the arms. If the muscle is released too much, it makes it hard to get in and out of the submuscular space during this part of the dissection.

http://dx.doi.org/10.5772/55040

A 1 cm incision is then made for the second port. A digit is introduced through the axillary incision to palpate the port as it enters the subcutaneous space and a 12 mm camera port is introduced. An small incision is then made over the other port site. A zero-degree endoscope is placed in the 12 mm port and an 8 mm port is placed at the third port site under endoscopic vision. The axillary incision is then temporarily closed using a running suture around 12 mm port to maintain insufflation.

2.4. Robotic docking and dissection

Following port placement, the robotic side cart (Da Vinci, Intuitive Surgical, Sunnyvale, CA) is positioned posterior to the patient with the two robotic arms and the endoscope extending over the patient in proximity to the ports. The distance from the bed is determined by the camera arm being flexed at more or less 90 degrees at the elbow. The other arms can then be brought into position, opening the elbows as much as possible to avoid conflicts during dissection. The robot is then docked to the cannulas, bringing the arms into a position that is nearly parallel to the floor.

Figure 3. The robot is docked with the Patient-Side Cart behind the patient and the arms nearly parallel with the floor.

Once the patient side cart is docked to the cannulas, insufflation is applied at 10 mm Hg. Dissection begins along the under surface of the muscle.[1] Monopolar scissors and Cadière grasping forceps (Intuitive Surgical, Sunnyvale, California) are used for the dissection. Blood

vessels can be clipped using a laparoscopic clip applier through one of the ports, or using a robotic clip applier. When the curvature of the back is encountered, the horizon will get too low for appropriate visualization. At that point, I recommend switching to a 30 degree down scope to better view this portion. Allow your bedside assistant to guide the extent of your dissection by comparing the space created with the preoperative markings. After the under-surface of the muscle is dissected to the borders, the 0 degree scope is replaced and the grasper is used to direct the anterior edge of the muscle towards the chest wall. Dissection then proceeds over the superficial surface of the muscle. The same process of switching to the 30 degree down scope is repeated when the curvature of the back becomes difficult to negotiate. Ideally, the deep and superficial dissection reach the same borders to that at the end, all that is left is the attachment to the thoracolumbar fascia inferiorly and posteriorly.

It is extremely helpful to have an assistant at the bedside familiar with the mechanics of robotic surgery. At the inferior and superior extremes of the dissection, the robotic arms and camera are nearly parallel, and may conflict with one another or the prominences of the patient's hip or shoulder. These undesirable interactions need to be monitored, and subtle modifications of arm positioning over the course of the case will be necessary to prevent them. In addition, as the dissection moves posteriorly, arm position will have to be adjusted to account for the curvature of the back. Specifically, the skin will need to be tented up by lifting the arms straight up. This is called "bumping" the arms. It's important to have the bed all the way to the floor for these adjustments, or the robotic arms will run out of room in the vertical dimension. These adjustments can be made without undocking the robot, but require experience.

Once dissection is complete in both the deep and superficial planes, the monopolar scissors is used to release the muscle at the infero-posterior border. A 30 degree-down scope is useful at this juncture to "look over" the curvature of the back. As the muscle is divided, it is continually "gathered" towards the axilla in order to maintain an optical window and tension at the point of dissection. Once the muscle has been liberated beyond the tip of the scapula, it will be easily accessible through the axillary incision. It is critical to visualize directly the thoracodorsal pedicle and insure that it is not in danger as the dissection approaches the axilla. Identification is made easier by the presence of a vessel loop.

2.5. Undocking and extraction of the muscle

At this stage, the robot can be undocked, and pushed back from the bed. The robotic portion of the procedure is now over. The axillary incision is then re-opened, and the muscle is delivered. An endoscope is reintroduced to confirm adequate hemostasis. Drains are placed though the two lower port sites, positioned in the donor site, and sutured into place.

The tendinous insertion can be released further through the axillary incision under direct visualization. Any remaining attachments are divided postero-superiorly. Usually there is some attachment to the teres major in this area that can be addressed open. If the muscle is being transferred as a pedicled flap for breast reconstruction, the majority of the posterior

1 If dissection began along the subcutaneous plane, it would be impossible to maintain the optical window beneath the muscle because insufflation would press the muscle down against the chest wall.

http://dx.doi.org/10.5772/55040

insertion is divided, and the muscle is delivered through the axillary incision, and then into the mastectomy space in preparation for a change to the supine position (Figure 4).

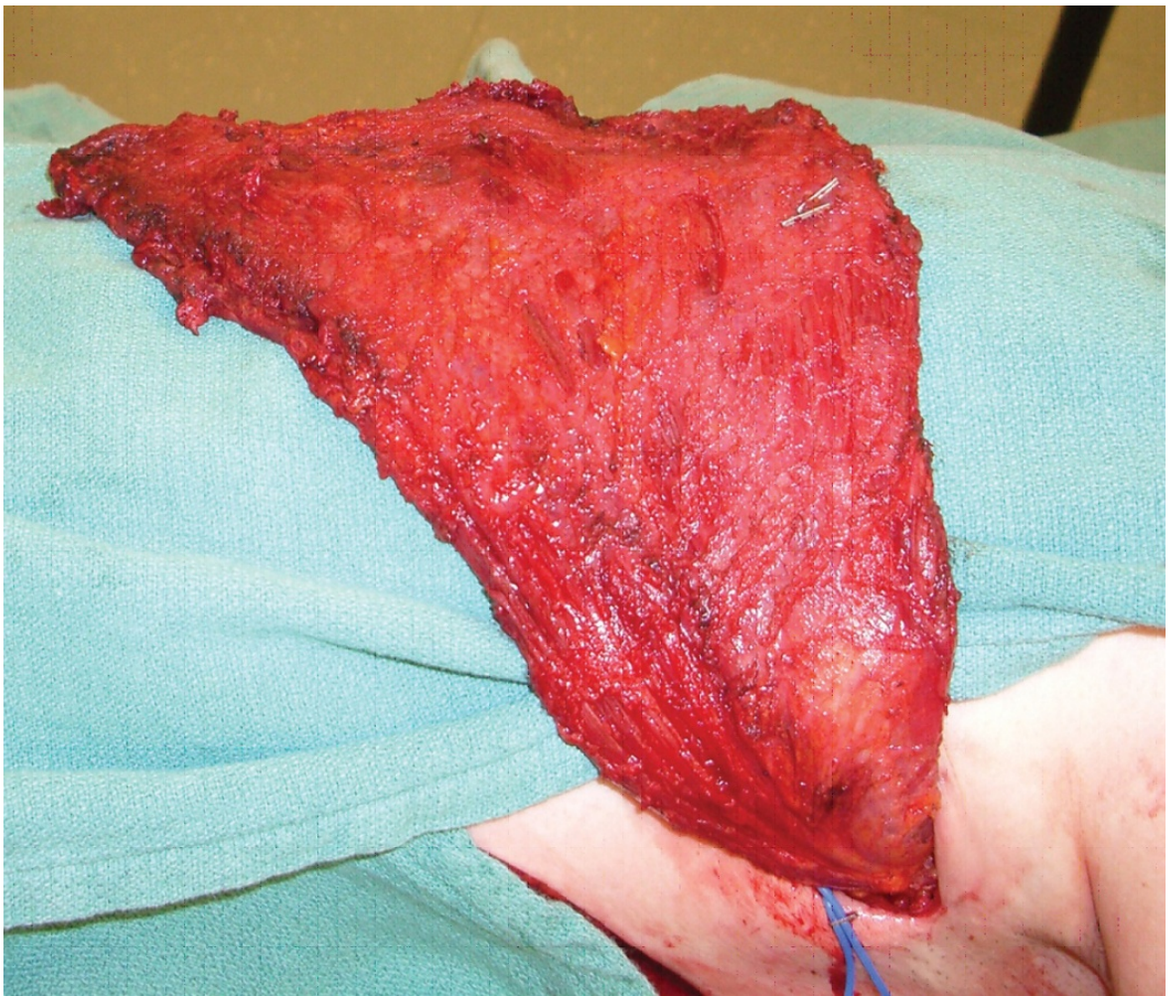

Figure 4. The muscle is delivered following the robotic harvest through the short axillary incision

2.6. Uses of the robotic LD for breast reconstruction

For use as a pedicled flap, the advantages of a muscle only LD with a barely visible donor site are tremendous. Breast reconstruction is more like cosmetic surgery than many other areas of reconstructive surgery in the sense that patients are very sensitive to esthetic outcomes and much more discriminating and informed about how advances in the field apply to their individual treatment plan. Partial breast reconstruction and nipple-areolar-complex (NAC) sparing mastectomy represent two advances in the field that reflect this reality. Robotic assisted LD harvest can enhance and expand the indications of both these procedures.

In the case of lateral lumpectomy defects, if no contralateral procedure is required or desired, then the optimal option for the index breast is volume replacement. If a latissi-

mus muscle can be introduced using the sentinel lymph node biopsy site and two additional ports, this volume replacement can be achieved with minimal donor cost to the patient and without additional breast incisions, incisions on the contralateral breast, or altering the tumor bed. If a patient who is concerned with donor esthetics is presented with the option of a LD flap where a back incision is necessary, her decision might more easily swing away from the LD flap volume replacement procedure and towards local tissue rearrangement based on reduction mammoplasty principles and a contralateral balancing procedure. This potentially compromises her goal of breast volume preservation and commits the patient to a bilateral procedure increasing the potential for complications in the contralateral breast and overall post-radiation asymmetry. Robotic assisted LD harvest has changed the clinical algorithm for partial breast reconstruction in my practice for patients with large, lateral lumpectomy defects.

For NAC sparing mastectomies, implant based results that rival breast augmentations can be achieved; however, the challenge to the reconstructive surgeon is considerable, because the breast mound needs to be centered perfectly under the NAC for a good result. This requires release of the pectoralis major so the expander or implant can descend to the natural position of the breast, which subsequently requires some lower pole support, usually in the form of a serratus flap or bioprosthetic. The serratus is small for this purpose and bioprosthetic is expensive and prone to complication. 26,27 The esthetic benefits related to contour of having muscle under the lower pole instead of allograft or xenograft are substantial (Figure 5 and 6).

In addition, since the NAC complex is present in such cases (in distinction to a skin sparing mastectomy), the need for a skin island is completely mitigated, adding an additional rational for a muscle only LD in this setting. Introducing an LD into the lower pole without a back incision allows for direct to implant single stage reconstruction without the need for bioprosthetic mesh. This technique maximizes the esthetic outcomes in both the breast and back, reduces complications and the cost associated with bioprosthetics and optimizes the outcomes in NAC sparing mastectomy reconstructions (Figure 7).

Another use for the muscle only latissimus is in the second stage of a two-stage implant based breast reconstruction in which the patient received radiation unexpectedly, but had a complete re-expansion with a preservation of the breast skin envelope. In these patients, the risk of exposure and short and long term complications following the exchange is high. A muscle, placed between the permanent implant and the skin at the time of the exchange is protective in these situations. I have a number of colleagues who have requested robotic muscle harvests for their patients in these clinical scenarios.

Regarding tumor staging, it is important to identify patients who will not require adjuvant radiation therapy for the immediate robotic assisted LD flap. In these patients the LD should be preserved for use in a delayed reconstruction setting. If a patient with a T2 tumor is found to have a positive sentinel lymph node on frozen section then a one stage robotic assisted LD with implant reconstruction is deferred pending final pathology. It is critical to preserve the LD as a salvage option for breast reconstruction in these difficult to predict clinical scenarios involving radiation therapy.

http://dx.doi.org/10.5772/55040

Figure 5. Two stage reconstruction with TE and muscle only LD - For NAC sparing mastectomies, a muscle only LD can be used for lower support with results that rival the contralateral breast augmentation.

3. Results

I have performed 14 robotic latissimus dorsi harvests for breast reconstruction over the past year. The average set up time, which includes the initial axillary incision, port placement, and docking of the robot is about 30 minutes. The actual harvest itself takes a little over an hour. There have been no conversions to the open technique for any of the flaps, and all flaps were harvested and transferred in their entirety. One patient was explanted due to a fungal infection while she was on chemotherapy, months following her procedure. This was considered unrelated to the method of surgery. There have been no other recipient site or donor site complications, including seroma, hematoma or overlying skin injury. One port site was revised to improve esthetics.

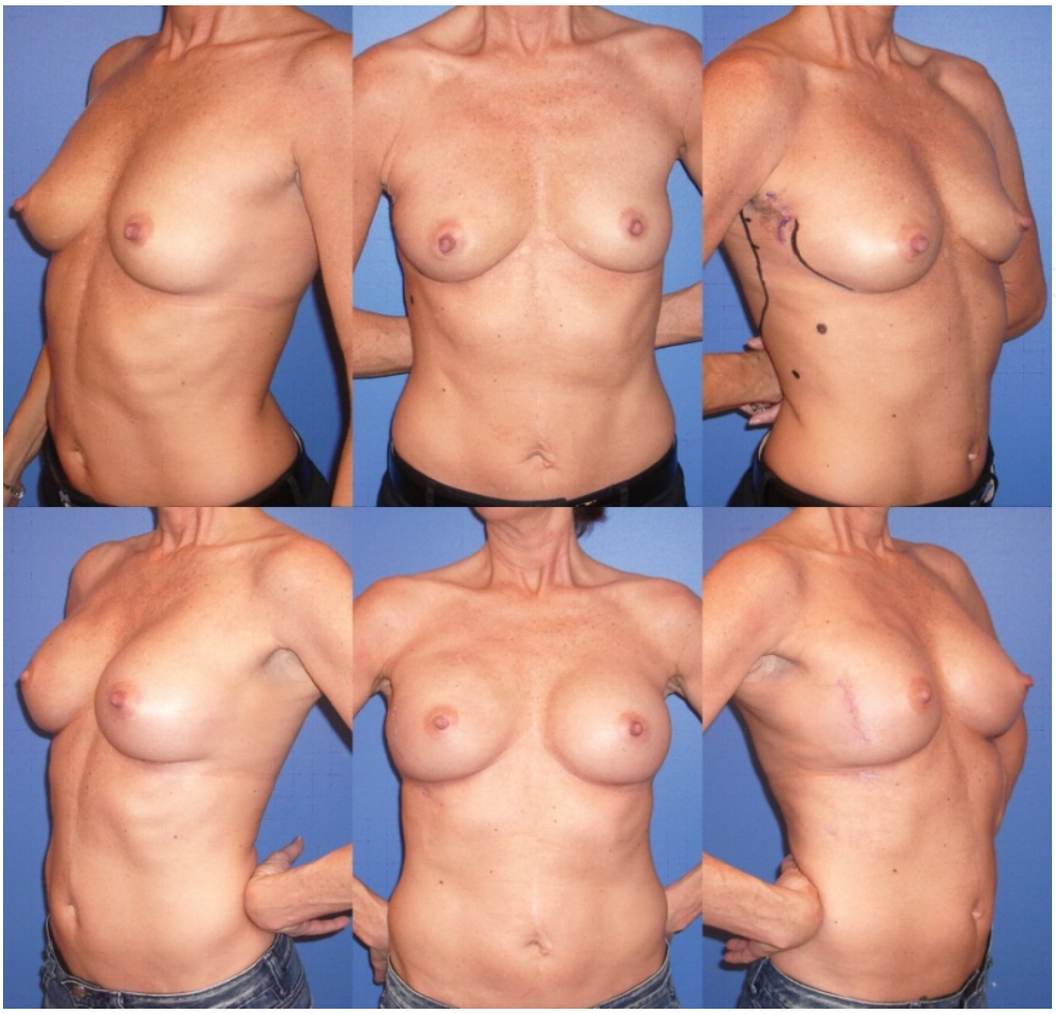

Figure 6. Single stage reconstruction with muscle only LD - For NAC sparing mastectomies, a muscle only LD can be used for lower support with results that rival the contralateral breast augmentation.

Figure 7. The donor site from a muscle only LD is functionally and esthetically difficult to distinguish from the normal side.

http://dx.doi.org/10.5772/55040

4. Discussion

The goal of minimally invasive surgery is to reduce the esthetic and functional morbidity of open procedures. Robotic technology has many advantages to standard minimally invasive approaches - high resolution, three dimensional optics, intuitive motion and greatly enhanced precision have combined to catapult robotic surgery into minimally invasive surgical mainstream. Plastic surgeons are late adopters of this technology, partly because we frequently operate on the skin itself, and partly because we lack the training and thought process from which to develop minimally invasive robotic concepts and techniques.

The latissimus dorsi muscle flap is one of our most reliable reconstructive options for a variety of indications, and I have demonstrated that this muscle can be reproducibly harvested using a surgical robot. The main advantage of the robotic technique is in sparing the patient a visible incision on the back. Instead, the patient has a short incision hidden in the axilla, with two additional port sites, one of which is obscured in the inframammary fold. Eliminating the "cost" of the donor site incision increases the versatility of an already versatile flap. In my practice, the muscle only LD has, in select cases, replaced bioprosthetic mesh in supporting the lower pole in implant-based breast reconstruction, replaced local tissue rearrangement for partial breast, and lowered the threshold for adding muscle coverage in radiated implant reconstructions.

As we move forward with this and other robotic procedures, our specialty must face the practical considerations of disseminating robotic techniques to a broader population of surgoens. One important concern is cost. A new, dual console, DaVinci SI costs approximately 2.2 million dollars. This is a major capital cost, but it is important to understand that the robotic platform is being purchased by hospitals in order to attract high volumes of patients undergoing established robotic procedures such as prostatectomy. The marginal cost of using the robot for a plastic surgery procedure is only the additional OR time, and the cost of the instruments, which is distributed over 10 uses (the life of the DaVinci instruments). In our setting, a robotic LD harvest costs an additional $800 to $900 compared to an open LD flap harvest. This is about the same cost as a CT scan, which many surgeons routinely get for free flap breast reconstruction. This is not intended as a formal or comprehensive cost-benefit analysis, but only to provide an estimate of the "cost" of eliminating the back incision in an LD harvest.

The other important question impacting dissemination of this technique is its "teachability." There are important barriers to teaching this technique to a wider audience. One is that plastic surgeons need to have a training pathway to learn how to use the surgical robot, separate from any specific technique. Operating the surgical robot has many nuances associated with it, and the surgeon must be comfortable, not only with its basic functionality, but how to manage the machine itself if the procedure is not proceeding optimally. This requires an initial investment of personal time and energy on the part of the learner. The second barrier is that the robotic LD harvest has a multitude of small technical nuances, which if well considered can make for a smooth operative experience, but if poorly accounted for can make it nearly impossible. Moving forward, the success of the operation will rely on standardizing the operative sequence

and robotic technique so that it can be taught in an advanced training module and the knowledge can be transferred to other surgeons.

5. Conclusions

Robotic applications now dominate many areas of minimally invasive surgery. The harvest of muscle flaps represents a novel plastic surgery application for this technology. Because of the esthetic sensitivity of breast reconstruction patients in general, eliminating an incision on the back for this very versatile flap has real benefit to patients. The robotic LD mitigates many of the challenges posed by endoscopic harvest by providing a platform with precise instrumentation and high resolution, three-dimensional optics. The technique itself is not simple, but with some experience, is both reliable and reproducible. The most practical applications are for partial breast reconstruction of lateral lumpectomy defects, implant based reconstruction in the context of NAC sparing mastectomies, and in patients with expanders who receive radiation.

Author details

Jesse Selber M.D., M.P.H.

Assistant Professor and Adjunct Director of Clinical Research, Department of Plastic Surgery, The University of Texas, M.D. Anderson Cancer Center, Houston, TexasUSA

References

[1] Yuh, B. E, Hussain, A, Chandrasekhar, R, et al. Comparative Analysis of Global Practice in Urologic Robot-Assisted Surgery. J Endourol. (2010). Sep

[2] Meehan, J. J, Elliott, S & Sandler, A. The Robotic Approach to Complex Hepatobiliary Analies in Children: Preliminary Report. J Pediatr Surg. (2007) Dec;42(12)2110-4.

[3] Jacobsen, G, Berger, R, & Horgan, S. The role of robotic surgery in morbid obesity. J Laparoendosc Adv Surg Tech A (2003), 13:279-83.

[4] Zacharopoulou, C, Sananes, N, Baulon, E, Garbin, O, & Wattiez, A. J Robotic Gynecologic SurgeryL State of the Art.Review of the Literature. Gynecol Obstet Biol Reprod. (2010) Aug 6

[5] Selber JC. Transoral Robotic Reconstruction of Oropharyngeal Defects: A Case Series. Plast Reconstr Surg 126(6):1978-1987, 12/2010). 126(6), 1978-1987.

[6] Genden, E. M, Kotz, T, Tong, C. C, et al. Transoral robotic resection and reconstruction for head and neck cancer. J Laryngoscope (2011). Aug;121(8), 1668-74.

[7] Garfein, E. S. Greaney PJ Jr, Easterlin B, et al. Transoral robotic reconstructive surgery reconstruction of a tongue base defect with a radial forearm flap. Plast Reconstr Surg (2011) Jun;127(6), 2352-4.

[8] Ghanem, T. A. Transoral robotic-assisted microvascular reconstruction of the oropharynx. J Laryngoscope (2011) Mar;121(3), 580-2.

[9] Genden, E. M, Park, R, Smith, C, & Kotz, T. The role of reconstruction for transoral robotic pharyngectomy and concomitant neck dissection. Arch Otolaryngol Head Neck Surg (2011).Feb;137(2), 151-6.

[10] Parekattil, S. J, & Brahmbhatt, J. V. Robotic approaches for male infertility and chronic orchialgia microsurgery. Curr Opin Urol (2011) Nov;21(6), 493-9. Review

[11] Mantovani, G, Liverneaux, P, Garcia, J. C, et al. Endoscopic exploration and repair of brachial plexus with telerobotic manipulation: a cadaver trial. J Neurosurg (2011) Sep;115(3), 659-64. Epub 2011 Apr 8.

[12] Harada, K, Minakawa, Y, Baek, Y, et al. Microsurgical skill assessment: Toward skill-based surgical robotic control. Conf Proc IEEE Eng Med Biol Soc (2011). Aug;2011, 6700-3.

[13] Tansini I Sopra il mio muovo processo di amputazione della mammilla. Gazetta MedicaI Italiana. (1906), 67:141-142.

[14] McCraw, J. B, Dibbell, D. G, & Carraway, J. H. Clinical definition of independent myocutaneous vascular territories. Plast Reconstr Surg (1977) Sep;60(3), 341-52.

[15] Schneider, W. J. Hill HL Jr, Brown RG. Latissimus dorsi myocutaneous flap for breast reconstruction. Br J Plast Surg (1977) Oct ;30(4), 277-81.

[16] Bostwick, J. 3rd, Vasconez LO, Jurkiewicz MJ. Breast reconstruction after a radical mastectomy. Plast Reconstr Surg (1978) May;61(5), 682-93.

[17] Bartlett, S. P. May JW Jr, Yaremchuk MJ. The latissimus dorsi muscle: a fresh cadaver study of the primary neurovascular pedicle. Plast Reconstr Surg (1981) May;67(5), 631-6.

[18] Maxwell, G. P, Mcgibbon, B. M, & Hoopes, J. E. Vascular considerations in the use of a latissimus dorsi myocutaneous flap after a mastectomy with an axillary dissection. Plast Reconstr Surg (1979) Dec;64(6), 771-80.

[19] Germann, G, Waag, K. L, Selle, B, & Jester, A. Extremity salvage with a free musculocutaneous latissimus dorsi flap and free tendon transfer after resection of a large congenital fibro sarcoma in a 15-week-old infant. A case report. Microsurgery (2006), 26(6), 429-31.

[20] Seitz, I. A, Adler, N, Odessey, E, Reid, R. R, & Gottlieb, L. J. Latissimus dorsi/rib intercostal perforator myoosseocutaneous free flap reconstruction in composite defects of the scalp: case series and review of literature. J Reconstr Microsurg. (2009). Nov; 25(9), 559-67.

[21] Pomel, C, Missana, M. C, & Lasser, P. Endoscopic harvesting of the latissimus dorsi flap in breast reconstructive surgery. Feasibility study and review of the literature Ann Chir. (2002) May;127(5), 337-42. French

[22] Lin, C. H, Wei, F. C, Levin, L. S, & Chen, M. C. Donor-site morbidity comparison between endoscopically assisted and traditional harvest of free latissimus dorsi muscle flap Plast Reconstr Surg (1999) Sep; 104(4), 1070-7; quiz 1078. Review. Erratum in: Plast Reconstr Surg (2000) Feb;105(2):823.

[23] Miller, M. J. Robb GL Endoscopic technique for free flap harvesting. Clin Plast Surg (1995) Oct;22(4), 755-73. Review

[24] Fine, N. A, Orgill, D. P, & Pribaz, J. J. Early clinical experience in endoscopic-assisted muscle flap harvest. Ann Plast Surg (1994). Nov;469-72, 33(5), 465-9. Discussion

[25] Ramakrishnan, V. V, Southern, S, & Villafane, O. Endoscopic harvest of the latissimus dorsi muscle using the balloon dissection technique. Plast Reconstr Surg (1997) Mar;99(3), 899-903; discussion 904-5.

[26] Liu, A. S, Kao, H. K, Reish, R. G, et al. Postoperative complications in prosthesis based breast reconstruction using acellular dermal matrix. Plast Reconstr Surg (2011) May;127(5), 1755-62.

[27] Lanier, S. T, Wang, E. D, Chen, J. J, et al. The effect of acellular dermal matrix use on complication rates in tissue expander/implant breast reconstruction. Ann Plast Surg (2010) May;64(5), 674-8.

IntechOpen