

# We are IntechOpen, the world's leading publisher of Open Access books Built by scientists, for scientists

6,900

Open access books available

185,000

International authors and editors

200M

Downloads

Our authors are among the

154

Countries delivered to

TOP 1%

most cited scientists

12.2%

Contributors from top 500 universities



WEB OF SCIENCE™

Selection of our books indexed in the Book Citation Index  
in Web of Science™ Core Collection (BKCI)

Interested in publishing with us?  
Contact [book.department@intechopen.com](mailto:book.department@intechopen.com)

Numbers displayed above are based on latest data collected.  
For more information visit [www.intechopen.com](http://www.intechopen.com)



---

# **Double Venous System Drainage in Deep Inferior Epigastric Artery Perforator Flap Breast Reconstruction**

---

Scott Reis, Jules Walters, Jason Hall and  
Sean Boutros

Additional information is available at the end of the chapter

<http://dx.doi.org/10.5772/55296>

---

## **1. Introduction**

The field of breast reconstruction has evolved rapidly since the advent of the first silicone gel-filled prosthesis by Cronin and Gerowin in 1963. [1] Over the past decades, we have seen remarkable advances in the field with microsurgical techniques becoming the gold standard for breast reconstruction. The deep inferior epigastric artery perforator (DIEP) flap has many advantages when compared to other methods of autologous breast reconstruction, namely reliability, malleability of soft tissue, and limited donor site morbidity. It is primarily for these reasons that the DIEP flap has become the preferred autologous option of many microsurgeons.

The main disadvantage of the DIEP flap is the technical difficulty, especially during the early experience of the microsurgeon. Even in experienced hands, there is a small yet significant incidence of flap compromise and loss. Gill et al. reported a partial flap loss rate of 2.5% and total flap loss rate of < 1% in their 10-year review of 758 DIEP flaps. They also reported a 5.8% flap re-exploration rate. [2] Other large series have reported similar results with respect to major complications. [2-7,13,16]

With regards to vascular problems, venous congestion tends to be the primary concern for microsurgeons who perform DIEP flap breast reconstruction. Complications due to the venous drainage or venous anastomosis have been shown to be eight times more common than issues arising from arterial insufficiency or arterial anastomotic complications. [2] These problems can lead not only to the rare total flap failure but more commonly to the need to return to the operating room in the immediate postoperative period to correct venous insufficiency and even partial flap failure and fat necrosis in the long-term. [3-7] Anatomic studies have shown

that the deep inferior epigastric vein (DIEV) connects with the superficial inferior epigastric vein (SIEV) through a system of choke vessels within the flap. [8] In numerous studies, the superficial venous system has been used to adequately decongest the flap in cases where venous congestion was clinically observed [9-13]. We have found that routinely anastomosing both the superficial and deep venous systems has resulted in significantly fewer operative take-backs and decreased venous complications with use of the DIEP flap.

## 2. Surgical technique

We begin the harvest of the DIEP flap with the inferior incision in a central to lateral direction. Our focus is first to identify a usable superficial vein. All reasonable superficial veins are preserved and compared to one another. The largest superficial vein is chosen, with preference given to veins more central in the flap. There is a consistent superficial vein which is present in unoperated abdominal wall flaps that is located approximately 5-10cm from the midline and a few millimeters deep to the dermis. In patients with prior low transverse incisions, this vein usually lies just lateral to the incision and most likely represents a smaller vein that has dilated over time. At the inferior portion of the flap, these veins are typically 1 to 2 mm in diameter. Dissection continues caudally for approximately 5 to 8 cm, or until a large side branch joins this more central vein. A venae comitans of the superficial inferior epigastric artery (SIEA) is typically not our vein of choice as it usually has more branches, thus requiring a longer time of dissection. In unilateral cases, the superficial veins are dissected bilaterally, and their location is typically consistent from one side to the other.

We typically do not obtain preoperative imaging to localize the DIEA perforators, unless the patient has had prior abdominal or pelvic surgery that would affect the patency of the perforating vessels. Upon dissection of the flaps, we choose the largest perforator on which to harvest the flap, and typically take any other reasonable perforators that require minimal extra rectus dissection. Typically 1-3 perforators are taken. In bilateral cases, we give slight preference to the lateral row perforators, as they are more central in the flaps. In unilateral cases, we give stronger preference to the medial row perforators.

In immediate reconstruction cases, the breast surgeon is advised to use hemoclips to control any medial bleeding rather than electrocautery. This bleeding is typically from internal mammary venous perforators (IMVPs). Once the mastectomy is completed, we identify any sizable transected IMVPs. If no usable transected vein is identified in the mastectomy dissection field, the mastectomy skin flap is further dissected superiorly and medially to search for an IMVP. These IMVPs are dissected through the pectoralis muscle down to the intercostal level. In our experience, after communication with the oncologic surgeon, adequate caliber venous perforators are routinely identified and spared during the initial mastectomy procedure. These veins tend to be very large and thin walled, thus making them ideal for venous coupling.

In cases of delayed reconstruction, we elevate the mastectomy skin flaps and search for IMVPs. If a large IMVP is found in the second or third interspace, it is dissected a short distance through the pectoralis muscle to the intercostal level. If no usable IMVP is identified, the lowest

interspace which is wide enough to allow dissection without removing a portion of rib is chosen. This technique allows a greater chance of finding two internal mammary venae comitantes since there is more often both a medial and lateral venae comitantes in the lower interspaces. Selecting the lowest interspace also decreases the likelihood of causing an upper inner quadrant soft tissue depression due to division of the pectoralis muscle. The intercostal muscles are elevated from the rib directly over the internal mammary artery (IMA) and vein (IMV). Each vessel is dissected well below the inferior rib margin to gain as much pedicle length as possible. It is also advantageous to include any side branches, as even small side branches afford the option of opening the vein through the branch to make the vein larger and thus allow a larger coupler to be used.

Once the flap is harvested, it is taken to the back table. The artery is cannulated with a 24 gauge angiocatheter, and the flap then irrigated with heparinized saline. Typically 60-80cc is flushed through the flap divided between three syringes. With the first flush, the pedicle is inspected for any obvious leaks and controlled accordingly. With the second and third, the veins are closely observed. With both veins left free to drain, the amount draining will typically be similar through both systems. However, occasionally we will note a deep or superficial dominance where the drainage is predominantly through one of the systems.

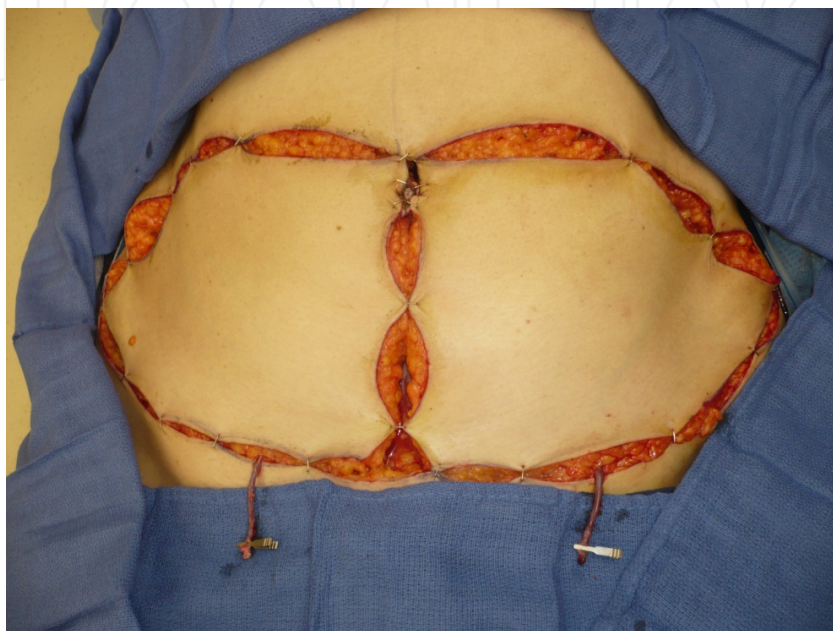
In the vast majority of DIEP reconstructions, a good caliber IMVP is present. In these cases, the IMA to DIEPA and IMV to DIEPV anastomoses are performed first. The superficial vein is then allowed to dilate after being controlled with a microvascular clamp. With the vein dilated, the second venous anastomosis is then performed. If the second venae comitant of the IMA is to be used for superficial system drainage, the DIEPV is anastomosed to the more lateral IMV, and the superficial vein is anastomosed to the more medial IMV. If there is no IMVP, only one IMV, and the flap is superficially dominant, we will anastomose the secondary vein to one of the DIEPVs. Before performing this superficial to deep vein anastomosis, we irrigate through one of the DIEPVs in retrograde fashion to verify antegrade flow in other, in order to ensure that there are no problematic venous valves. All venous anastomoses are performed with the Synovis microvascular anastomotic coupler.

Finally, the DIEP flap is inset. It is sutured to the chest wall at the inframammary fold and lateral breast margin with incorporation of pectoralis fascia in the lateral chest wall stitch. Medially, we tack the flap to both the undersurface of the mastectomy skin flap and superiorly to the highest point within the pocket. We do not use any implantable monitoring devices for the DIEP flaps. Monitoring of the flap is by means of a small skin paddle and bedside doppler exam. In patients who do not require a skin paddle, we make a cruciate incision in the mastectomy skin flap over an audible Doppler signal and then suture the four edges down to a deepithelialized portion of the DIEP flap creating a small patch of exposed dermis to monitor for signs of venous congestion. Our patients are placed on bed rest for four days and are usually discharged on postoperative day four. While in the hospital, patients are given low molecular weight heparin and sequential compression devices for DVT prophylaxis. Intraoperatively, 1500 units of heparin is given intravenously one hour into surgery, also for DVT prophylaxis.

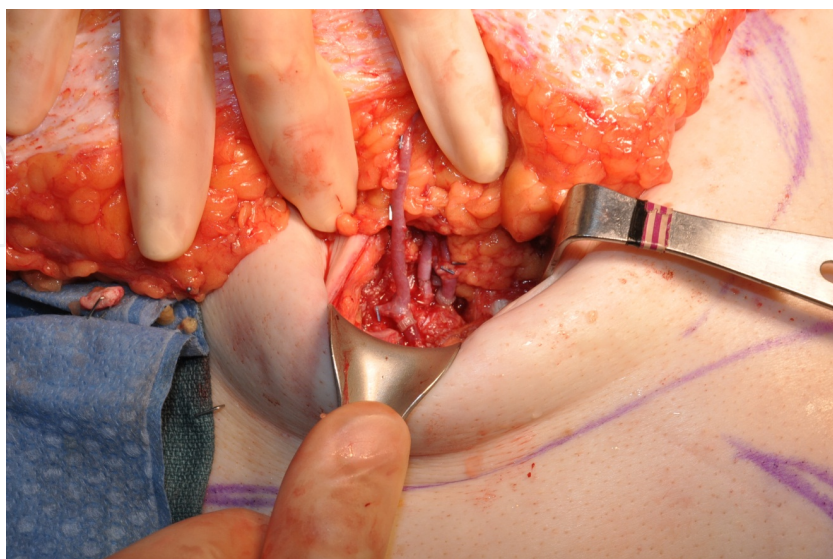
A recent study published in *Plastic and Reconstructive surgery* (accepted for publication) reviewed 352 consecutive DIEP flaps performed by the senior author (SGB). In this study, 311



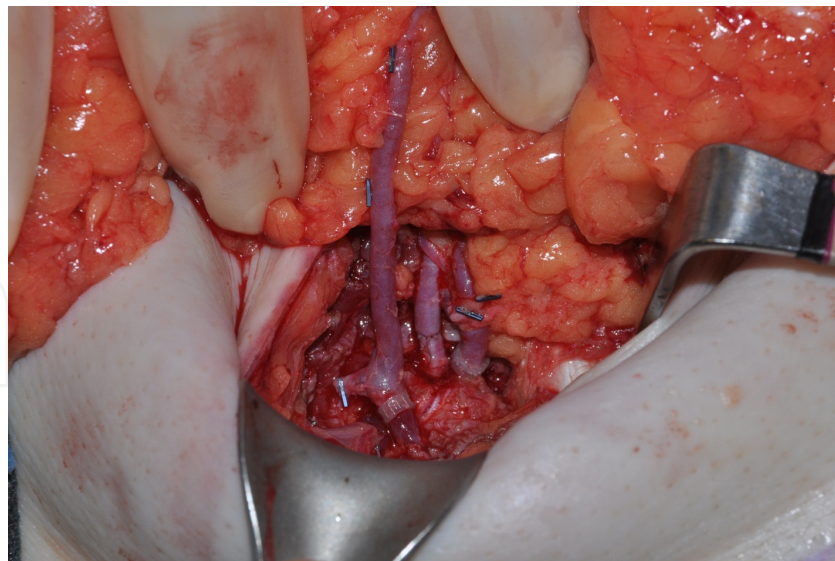
flaps underwent double venous anastomosis while 41 underwent one venous system anastomosis. There were no flap losses in either group. There was one operative exploration for venous congestion in the double system group (0.32%) and 2 in the single system group (4.9%). This difference was statically significant. The single system group take back rate was almost identical to prior published results.



**Figure 1.** Location of typical superficial vein for secondary venous system drainage



**Figure 2.** Superficial vein to the IMVP flap orientation



**Figure 3.** Closer view of the vascular layout for typical dual venous system drainage

### 3. Discussion

DIEP flaps are commonly performed in large academic hospitals or certain specialized microsurgical centers. The rapid availability of “in house” physicians and residents and the large volume of procedures performed in these settings contribute to excellent outcomes at many facilities [2-7,13,16]. With some exceptions, community-based hospitals tend not to be equipped for rapid return to the operating room should vascular complications arise. In these instances, referring physicians may then be more encouraged to refer to plastic surgeons who perform procedures with fewer short-term complications even if their long-term reconstructive outcomes are less optimal. Thus, the typical community reconstructive plastic surgeon may perform microsurgical breast reconstruction less often than those in academic settings.

One of the most common complications of DIEP flaps is venous insufficiency, which is likely multifactorial in nature. The superficial inferior epigastric vein (SIEV) is often the dominant venous drainage of the lower abdominal skin and subcutaneous tissue. It is typically located halfway between the anterior superior iliac spine and pubic symphysis and lies below the dermal vascular plexus but above Scarpa’s fascia. A system of choke vessels exists between the superficial inferior epigastric vein and the deep inferior epigastric system; however, certain variations in anatomy may exist. [8] Venous branches crossing the midline have been found to be absent in 36% of cases [4, 14]. This paucity of crossing branches explains why survival of Zone IV of the flap can be quite unpredictable.

During the standard harvest of an elliptical transverse fasciocutaneous island, the SIEV is transected. Venous drainage is thus rerouted to the perforating veins through choke vessels [8]. However, there are cases where the DIEP flap is more dependent on superficial drainage. Consequently, venous drainage through the DIEP system may be insufficient to adequately

drain the entire flap. Anatomic studies have shown that in certain patients, the drainage of the abdominal flap can be preferentially through the superficial system with little communication to the deep system [15]. Patients who have had preoperative imaging showing the absence of communication between the two systems were more likely to have venous problems intraoperatively. This anatomic variant may be a significant cause of venous insufficiency when surgeons rely on the DIEP system alone.

Despite the many advantages the DIEP flap has to offer, there may be a higher incidence of fat necrosis and venous congestion [16]. Several authors have reported various techniques to treat the congested breast DIEP flap. The DIEV and SIEV have been anastomosed to the internal mammary and thoracodorsal vessels by Cohn and Walton [17]. Niranjan et al describe using a vein graft to connect the DIEV to the cephalic vein [18]. Another option described by Tutor et al involved connecting a venae comitantes of the DIEP pedicle to an intercostal branch of the IMV [19]. Additionally, with routine harvest of a superficial vein, the superficial venous system may be used for venous augmentation of the congested DIEP flap. This may be accomplished by anastomosing the superficial vein to an internal mammary vein perforator (IMVP), a secondary IMV, to the distal end of the IMV in a retrograde fashion, to the deep system directly, or even to the basilic vein [20-22]. The SIEV is present in 95% of patients, and preservation of this vein can be very beneficial with minimal additional operative time and morbidity [23].

A possible negative aspect of the double venous system technique is the additional operative time required. However, many surgeons routinely dissect the superficial vein as a lifeboat in the event of venous congestion, thus mitigating a portion of the additional operative time required. With experience, the added time is less than 15 minutes per flap. We believe that this time added in a routine basis is insignificant in comparison to the time required for an operative take back.

## 4. Conclusion

The dual venous system technique adds minimal additional time to the operation and adds an additional layer of security by augmenting the venous drainage of the flap. In our experience, the use of the dual-venous technique has successfully minimized returns to the operating room for venous complications in the early postoperative period. Microsurgeons who routinely perform DIEP breast reconstructions should be familiar with this technique, as it has proved valuable in our own practice.

## Author details

Scott Reis, Jules Walters, Jason Hall and Sean Boutros\*

\*Address all correspondence to: [drseanboutros@drseanboutros.com](mailto:drseanboutros@drseanboutros.com)

Houston Plastic & Craniofacial Surgery, Houston, TX, USA



## References

- [1] Cronin TD, Gerow FJ. Augmentation mammoplasty: A new "natural feel" prosthesis. Transactions of the Third International Congress of Plastic and Reconstructive Surgery 1963: 41-49.
- [2] Gill P, Hunt J, Guerra A, et al. A 10-year retrospective review of 758 DIEP flaps for breast reconstruction. *Plast Reconstr Surg* 2004;113(4) 1153-60..
- [3] Scheer AS, Novak CB, Neligan PC, Lipa JE. Complications Associated With Breast Reconstruction Using a Perforator Flap Compared With a Free TRAM Flap. *Ann Plast Surg* 2006;56(4) 355-8.
- [4] Blondeel PN, Arnstein M, Verstraete K, Depuydt K, Van Landuyt KH, Monstrey SJ, Kroll SS. Venous congestion and blood flow in free transverse rectus abdominis myocutaneous and deep inferior epigastric perforator flaps. *Plast Reconstr Surg* 2000;106(6)1295-9.
- [5] Nahabedian MY, Momen B, Galdino G, Manson PN. Breast reconstruction with the free TRAM or DIEP flap: patient selection, choice of flap, and outcome. *Plast Reconstr Surg* 2002;10(2) 466-75.
- [6] Chen CM, Halvorson EG, Disa JJ, McCarthy C, Hu QY, Pusic AL, Cordeiro PG, Mehrara BJ. Immediate postoperative complications in DIEP versus free/muscle-sparing TRAM flaps. *Plast Reconstr Surg* 2007;120(6) 1477-82.
- [7] Tran NV, Buchel EW, Convery PA. Microvascular complications of DIEP flaps. *Plast Reconstr Surg* 2007;119(5) 1397-405.
- [8] Schaverien M, Saint-Cyr M, Arbique G, Brown SA. Arterial and venous anatomies of the deep inferior epigastric perforator and superficial inferior epigastric artery flaps. *Plast Reconstr Surg* 2008;121(6) 1909-19.
- [9] Xin Q, Luan J, Mu H, Mu L.J. Augmentation of venous drainage in deep inferior epigastric perforator flap breast reconstruction: efficacy and advancement. *Reconstr Microsurg* 2012;28(5) 313-8.
- [10] Sbitany H, Mirzabeigi MN, Kovach SJ, Wu LC, Serletti JM. Strategies for recognizing and managing intraoperative venous congestion in abdominally based autologous breast reconstruction. *Plast Reconstr Surg* 2012;129(4) 809-15.
- [11] Momeni A, Lee GK. A case of intraoperative venous congestion of the entire DIEP-flap--a novel salvage technique and review of the literature. *Microsurgery* 2010;30(6) 443-6.
- [12] Ali R, Bernier C, Lin YT, Ching WC, Rodriguez EP, Cardenas-Mejia A, Henry SL, Evans GR, Cheng MH. Surgical strategies to salvage the venous compromised deep inferior epigastric perforator flap. *Ann Plast Surg* 2010;65(4) 398-406.



- [13] Enajat M, Rozen W, Whitaker I, Smit J, Acosta R. A single center comparison of one versus two venous anastomoses in 564 consecutive DIEP flaps: Investigating the effect on venous congestion and flap survival. *Microsurgery* 2010;30(3) 185-91.
- [14] Carramenha e Costa MA, Carriquiry C, Vasconez LO. An anatomic study of the venous drainage of the transverse rectus abdominis musculocutaneous flap. *Plast Reconstr Surg* 1987;79(2) 208-217.
- [15] Schaverien MV, Ludman CN, Neil-Dwyer J, Perks AG, Raurell A, Rasheed T, McCulley SJ. Relationship between venous congestion and intraflap venous anatomy in DIEP flaps using contrast-enhanced magnetic resonance angiography. *Plast Reconstr Surg* 2010;126(2) 385-9.
- [16] Kroll SS. Fat necrosis in free transverse rectus abdominis myocutaneous and deep inferior epigastric perforator flaps. *Plast Reconstr Surg* 2000;106(3) 576-583.
- [17] Cohn AB, Walton RL. Immediate autologous breast reconstruction using muscle-sparing TRAM flaps with superficial epigastric system turbocharging: a salvage option. *J Reconstr Microsurg* 2006;22(3) 153-156.
- [18] Niranjan NS, Khandwala AR, Mackenzie DM. Venous augmentation of the free TRAM flap. *Br J Plast Surg* 2001;54(4) 335-337.
- [19] Tutor EG, Auba C, Benito A, et al. Easy venous superdrainage in DIEP flap breast reconstruction through the intercostals branch. *J Reconstr Microsurg*. 2002;18(7) 595-598.
- [20] Kerr-Valentic MA, Gottlieb LJ, Agarwal JP. The retrograde limb of the internal mammary vein: an additional outflow option in DIEP flap breast reconstruction. *Plast Reconstr Surg* 2009;124(3) 717-21.
- [21] Wechselberger G, Schoeller T, Bauer T, Ninkovic M, Otto A, Ninkovic M. Venous superdrainage in deep inferior epigastric perforator flap breast reconstruction. *Plast Reconstr Surg* 2001;108(1) 162-6.
- [22] Guzzetti T, Thione A. The basilic vein: an alternative drainage of DIEP flap in severe venous congestion. *Microsurgery* 2008;28(7) 555-8.
- [23] Reardon CM, Ceallaigh SO, O'Sullivan ST. An anatomical study of the superficial inferior epigastric vessels in humans. *Br J Plast Surg* 2004;57(6) 515-519.
- [24] Hanasono MM, Kocak E, Ogunleye O, Hartley CJ, Miller MJ. One versus Two Venous Anastomoses in Microvascular Free Flap Surgery. *Plast Reconstr Surg* 2010;126(5) 1548-57.