

We are IntechOpen, the world's leading publisher of Open Access books Built by scientists, for scientists

6,900

Open access books available

186,000

International authors and editors

200M

Downloads

Our authors are among the

154

Countries delivered to

TOP 1%

most cited scientists

12.2%

Contributors from top 500 universities



WEB OF SCIENCE™

Selection of our books indexed in the Book Citation Index
in Web of Science™ Core Collection (BKCI)

Interested in publishing with us?
Contact book.department@intechopen.com

Numbers displayed above are based on latest data collected.
For more information visit www.intechopen.com



Thoracic Hydatid Cyst: Clinical Presentation, Radiological Features and Surgical Treatment

Ihsan Alloubi

Additional information is available at the end of the chapter

<http://dx.doi.org/10.5772/53533>

1. Introduction

Hydatid disease is caused by an infection with the cestode *Echinococcus granulosus*. It has been known since the time of Galen and Hippocrates, and was described by Thebesius in the 17th century [1, 2]. Rudolphy (1808) first used the term hydatid cyst to describe echinococcosis in humans [1]. It's frequently encountered in sheep- and cattle-raising regions of the world and has been observed most often in Australia, New Zealand, South Africa, South America, and Mediterranean countries. Adult worms mature in the intestine of dog (definitive host) and the eggs are released in the stool. Animals like sheep get this disease by via ingestion of contaminated vegetables. When local people living in contaminated areas (accidental host) accidentally ingest eggs after contamination of the hands by handling dogs, oncospheres hatch in the duodenum, penetrate the intestines and are carried via the bloodstream to various organs. (Fig1). About 70 per cent of hydatids lodge in the liver and develop there. Those that pass the liver are likely to travel *via* the right side of the heart to the lungs, which are second to the liver in frequency of involvement. Finally, a few embryos pass through the lungs and lodge in the systemic distribution, as in brain, bones, or kidneys. The presence of pulmonary hydatid disease should be considered in patients that present with a well-defined, spherical density of the lung, particularly in those who have lived or traveled in endemic areas.

2. Epidemiology

Annual incidence which is as high as 13-27 cases per 1, 00,000 population in certain countries of central Asia 2. The prevalence have been of pulmonary involvement is reported to be 10% to 40% in different reported series [3].

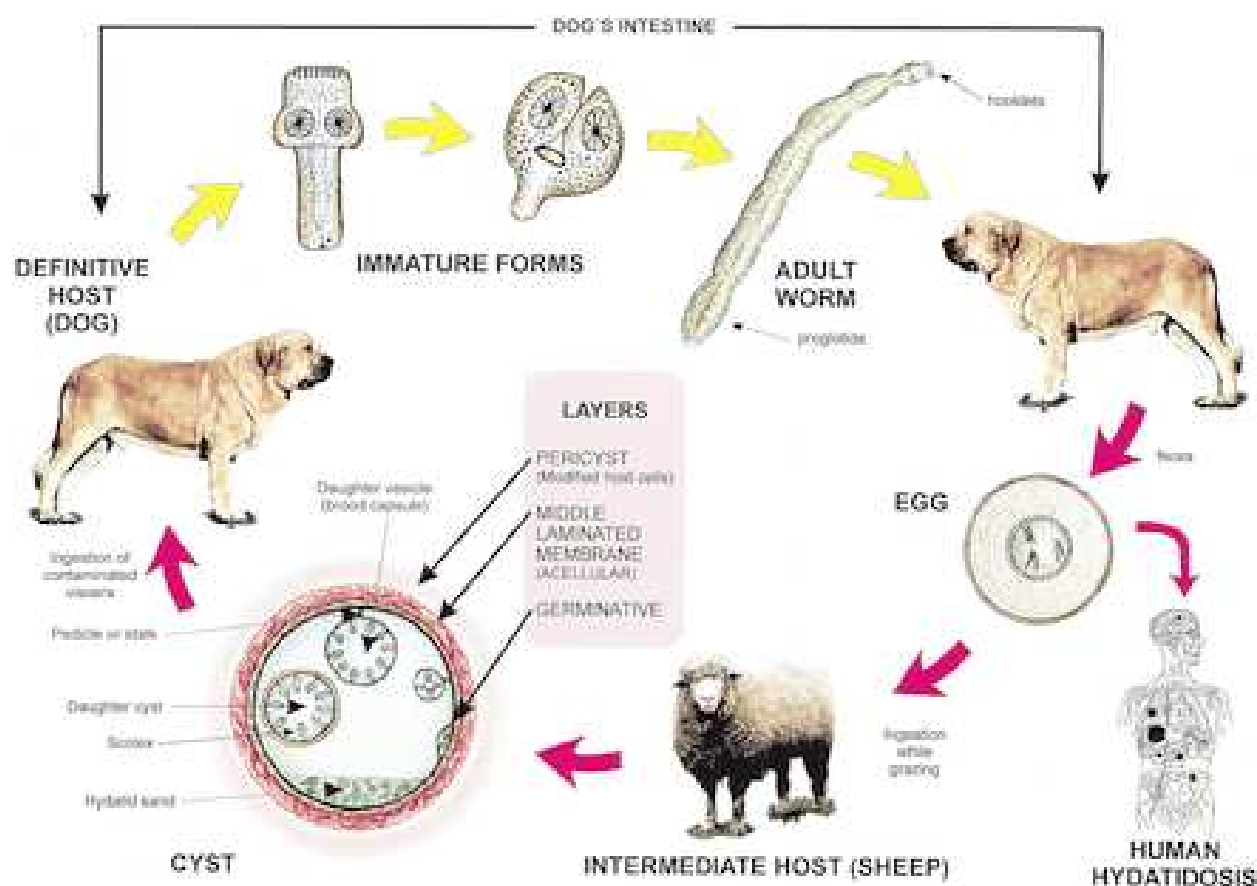


Figure 1. Life cycle (dog-sheep cycle) of *E. granulosus*. Diagram shows the most prevalent life cycle of *E. granulosus*, in which a dog and sheep serve as the definitive and intermediate hosts, respectively. Radiographics 2000; 20:795–817 (With permission)

3. Pathology

3.1. Cyst structure

Morphologically, hydatid cyst consists of three layers and hydatid fluid. The first is the avascular outer pericystic layer or adventitia which is the host tissue formed by the lung as a reaction to the foreign body (parasite) (Fig 2). The other two layers, the laminated membrane (external layer of the cyst) or the ectocyst laminated membrane is an acellular laminar mucopolysaccharide layer and the germative layer (inner layer of the cyst), or endocyst layer that gives rise to larval scolices (Fig 3).

The cyst fluid resembles water in appearance which may contain daughter vesicles. The cysts exist in different forms: intact or ruptured, single or multiple, unilateral or bilateral, solely located in the lung or concomitantly in other organ lodgements (especially in the liver).

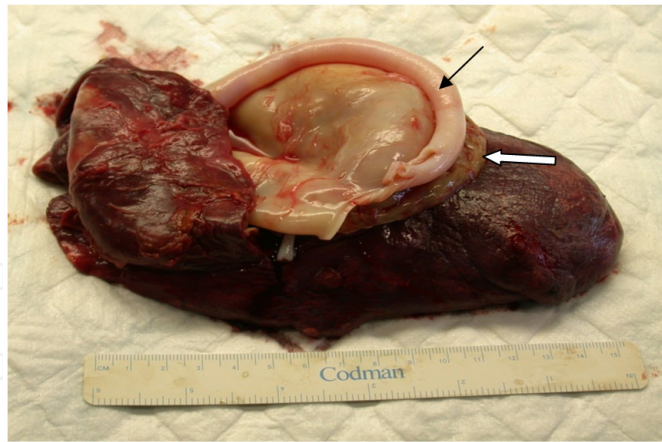


Figure 2. operative specimen: adventitia which is the host tissue formed by the lung as a reaction to the foreign body (white arrow) and de germinative membrane (black arrow); E Boeykens, A. M. Vints University Hospital of Antwerp (with permission)

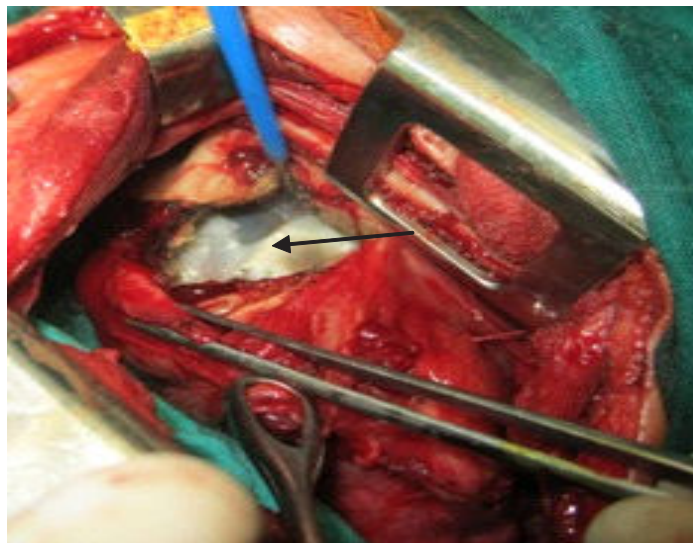


Figure 3. Operative view: endocyst layer that gives rise to larval scolices (arrow)

3.2. Cyst classification [4]

Based on morphology the cyst can be classified into 4 different types:

- **type I:** simple cyst with no internal architecture
- **type II:** cyst with daughter cyst(s) + matrix
 - **type IIa:** round daughter cysts at periphery
 - **type IIb:** larger, irregularly shaped daughter cysts occupying almost the entire volume of the mother cyst

- **type IIc:** oval masses with scattered calcifications and occasional daughter cysts
- **type III:** calcified cyst (dead cyst)
- **type IV:** complicated cyst : e.g. ruptures cyst

4. Clinical presentation

Pulmonary hydatid disease (echinococcosis) does not present a constant clinical pattern, and consequently the clinical diagnosis tends to be inaccurate. As is so often the case, failure to think of the condition rather than lack of knowledge about it accounts for most of the misdiagnoses. It would appear, therefore, of some value to re-emphasize certain of the features of hydatid disease, more particularly from the radiological point of view.

Clinical manifestations varied widely depending on the status of the hydatid cyst. The most common presenting symptom of the patients was a cough, followed by chest pains of varying severity. Clinical presentation of pulmonary hydatid cysts depends on the size of the cyst and whether the cyst is intact or ruptured. Intact cysts are either incidental findings or present with cough, dyspnea or chest pain. If it ruptures into a bronchus, pleural cavity or biliary tree it is called complicated cyst and may present with expectoration of cystic contents, productive cough, repetitive hemoptysis, fever or anaphylactic shock in addition.

Patients come to the clinician's attention for different reasons, such as when a large cyst has some mechanical effect on organ function or rupture of a cyst causes acute hypersensitivity reactions. The cyst may also be discovered accidentally during radiographic examination, body scanning, surgery, or for other clinical reasons.

Physical findings are hepatomegaly when associated with liver involvement, a palpable mass if on the surface of the liver or other organs, and abdominal distention. If cysts in the lung rupture into the bronchi, intense cough may develop, followed by vomiting of hydatid material and cystic membranes.

5. Diagnosis

The combination of imaging and serology usually enables diagnosis. The standard diagnostic approach for cystic Echinococcosis is based on the clinical setting, imaging characteristics, predominantly ultrasonography, computed tomography (CT), X-ray examinations, and confirmation by detection of specific serum antibodies by immunodiagnostic tests.

In the detection of pulmonary echinococcosis very important role played by mass x-ray examination of the population. It allows preventive examination at the present time to identify the disease before any clinical symptoms. Differential diagnosis of conduct between the echinococcus, tuberculoma, peripheral carcinoma, between the diseases, giving the spherical formation in the lungs. Use the full range of special methods except for the puncture. End of

suspected unacceptable because of the possibility Echinococcus cyst rupture, risk of falling hydatid fluid in the pleura with the development of severe anaphylactoid reactions and colonization by the parasite. (Fig 4a, Fig 4 b)

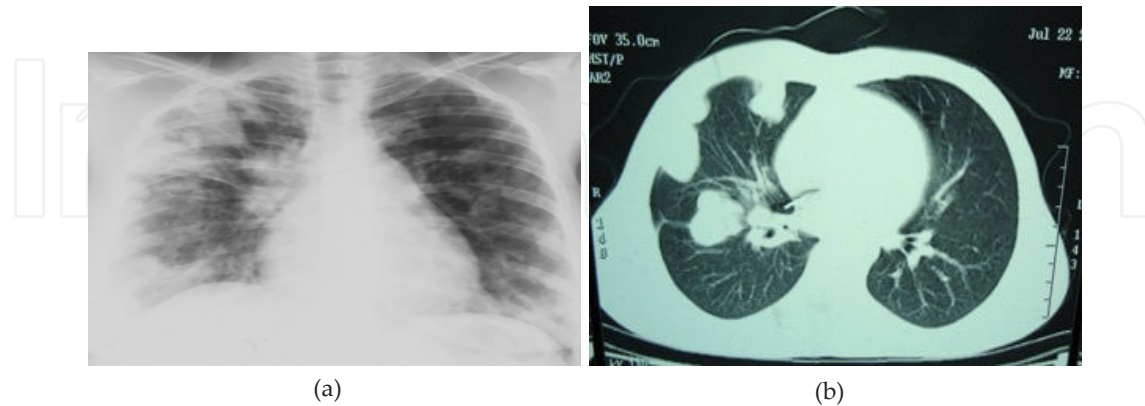


Figure 4. (a) Chest radiograph demonstrates multiple peripheral round areas of soft-tissue opacity.(b) CT scan shows a clearly defined capsule with a relatively hypo attenuating center, a finding that reflects the cystic nature of the lesions.

Bronchoscopy is unnecessary in patients with a typical clinical and radiological picture but it can be performed for differential diagnosis in cases of atypical radiological appearance [5, 6]. When bronchoscopy was performed in thoracic hydatidosis, pathologic findings were revealed in 70%. Bronchoscopy detected a whitish endobronchial lesion imitating endobronchial tuberculosis with a caseous lesion. (Fig 5)

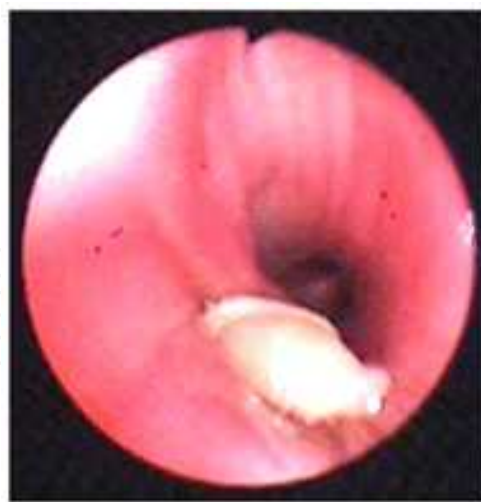

Figure 5. Flexible bronchoscopic image in a 42-year-old man with hemoptysis showing a white gelatinous membrane-like structure protruding from the medial basal segment of the right lower lobe; CMAJ (with permission)

When a cyst becomes infected or ruptures, the clinical and radiological profile can mimic diseases such as nonresolving pneumonia, tuberculosis, and abscess or tumor of the lungs. Direct bronchoscopic visualization with biopsy allowed to quickly clarifying the diagnosis,

leading to effective treatment. On the other hand, one should bear in mind the possibility that carcinoma may rarely have clinical, radiological, and serological features, similar to those of a hydatid disease. It is uncommon for the diagnosis to be made from the microscopic discovery of hooklets in respiratory secretions, highlighting the value of close liaison with microbiological staff.

5.1. Laboratory tests

Most serodiagnostic techniques have been evaluated for diagnosis of cystic hydatid disease caused by *Echinococcus granulosus*. Formerly, the laboratory diagnosis of echinococcosis has been based chiefly on the results of the Casoni intradermal (ID) or the complement-fixation (CF) test. The CF test has a limited sensitivity, while the ID test may be unreliable since, once acquired, skin sensitivity may persist for life. After, the findings of Garabedian et al and Kagan et al [7,8] reported that indirect haemagglutination (IHA) was more sensitive to formers tests but there were some limitations with the practical aspect of IHA, for example false positive reactions with other helminthic infections, cancers and chronic immune complex disease.

Actually, the most sensitive technique in detecting pulmonary hydatid disease is immunoglobulin G enzyme-linked immunosorbent assay (ELISA) test, with a sensitivity of 85.3%; it's a quantitative serodiagnostic method that specific IgG ELISA kit was available commercially. It was a better test for initial screening of suspected cases of human hydatidosis and was more acceptable due to its higher sensitivity and simplicity in practice [9]. Our data showed that ELISA is more sensitive than IHA for initial screening of suspected cases of hydatidosis.

Serological tests are often helpful, but measurable immunological responses do not develop in some patients, essentially in lung hydatid cyst contrary to liver localization, where it seems that it has more supply antigenic stimuli to host tissues. Laboratory testing should be used either in highly suspicious cases or for postoperative follow-up of pulmonary hydatid cyst disease. Antibody production is elevated during the first 4 - 6 weeks after surgical intervention, followed by a decrease during the next 12 - 18 months. In patients who have a recurrence before 2 years, antibody production remains similar to pre-operative levels [8, 9]. Eosinophilia is 10-30% positive in hydatid cyst disease. Eosinophilia increases if cyst rupture and it is also high in countries where parasitosis is endemic [10].

6. Radiological features

The plain chest radiograph is very helpful in diagnosis of pulmonary hydatid cyst. In uncomplicated hydatid cysts, radiologic diagnosis is relatively easy and is identified on routine chest radiograph incidentally. Unruptured pulmonary hydatid cyst shows one or more homogenous round or oval wellshaped masses with smooth borders surrounded by normal lung tissue on chest radiograph. It can access large volumes and compress to the adjacent structures. (Fig 6, 7, 8)

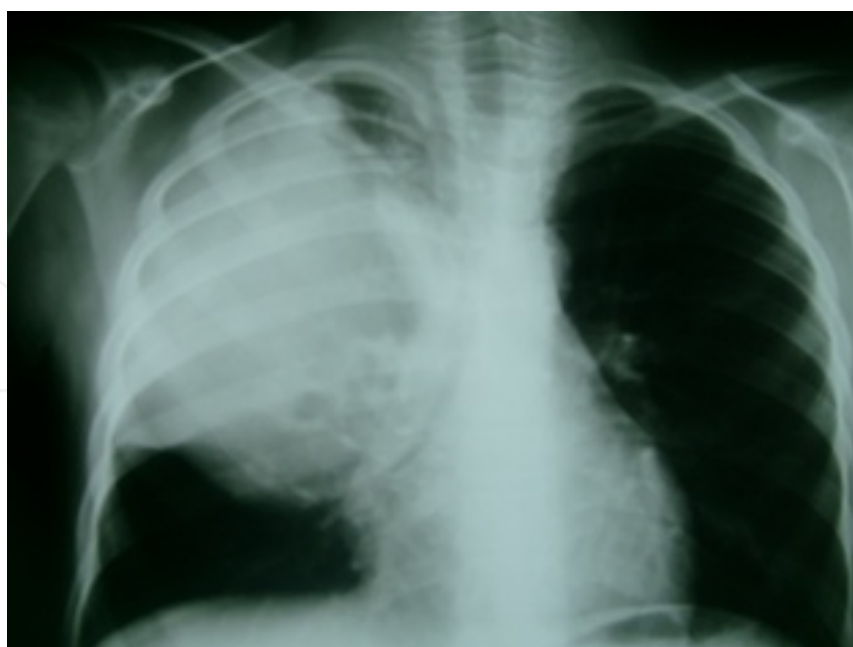


Figure 6. Chest radiograph showing large hydatid cyst right upper lobe causing mediastinal shift to opposite side

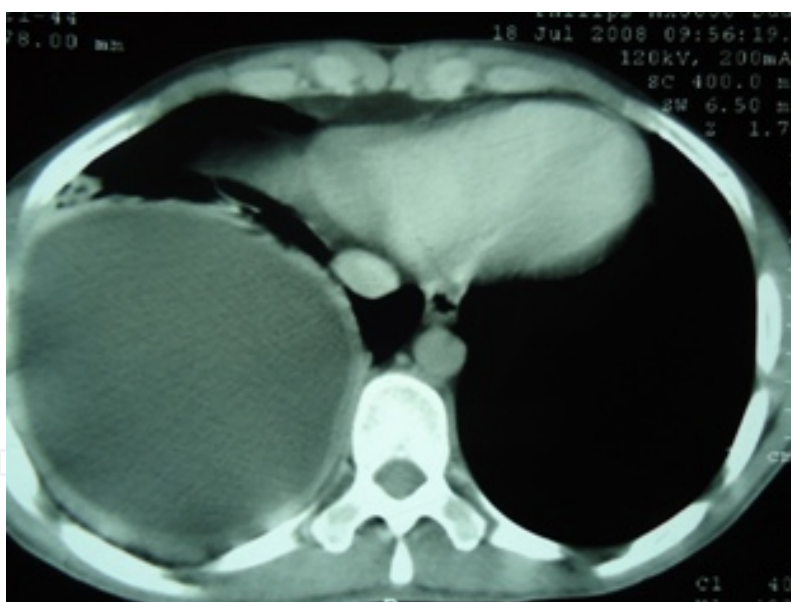


Figure 7. CT appearance of an uncomplicated giant hydatid cyst of the right lung.

If the hydatid cyst is infected or ruptured, the radiological appearance may become atypical and it may cause incorrect and delayed diagnosis.

Complicated, a variety of signs denoting different appearances of the hydatid cysts have been described. During enlargement, the cyst can erode into the bronchus and air can enter between the pericyst and endocyst leading to the thin crescent (meniscus) sign (fig 9)

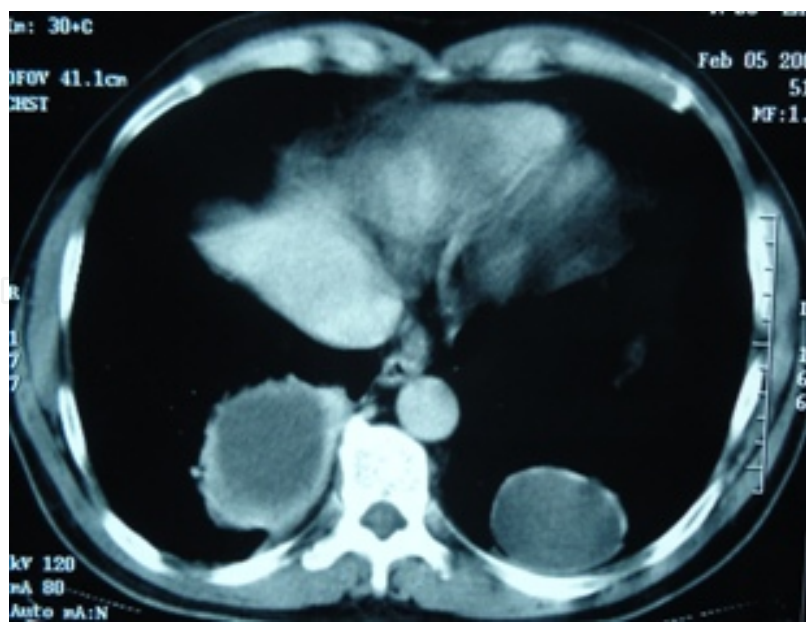


Figure 8. CT scan showing two well-circumscribed homogenous cysts over right and left lower lobes

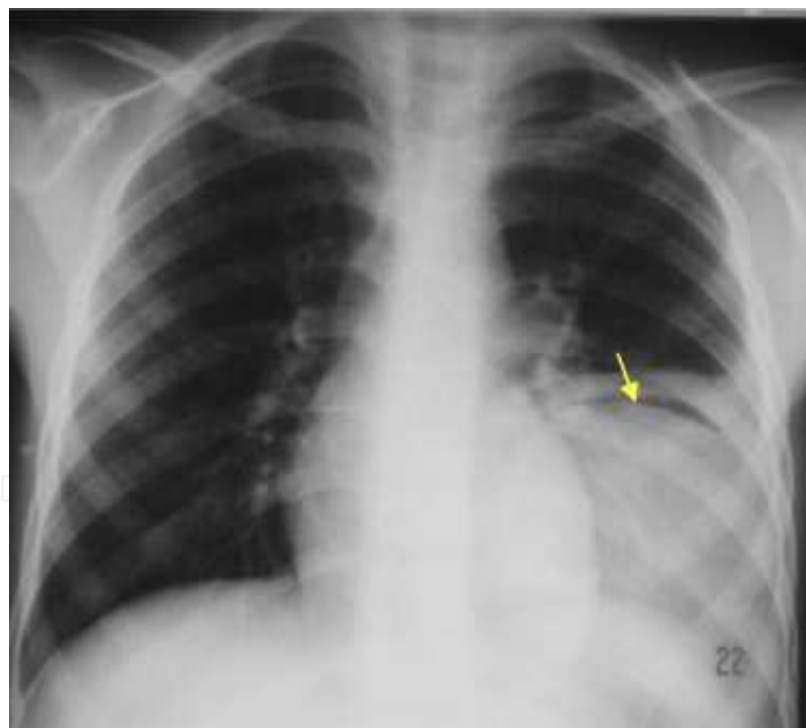


Figure 9. The pulmonary meniscus sign (arrow): crescent-shaped inclusion of air surrounded by consolidated lung tissue

As the air continues to enter this space, the cyst ruptures and air fills the endocyst. The air fluid level in the cyst and air like onion peel between pericyst and endocyst is called the Cumbo sign (Fig 10)

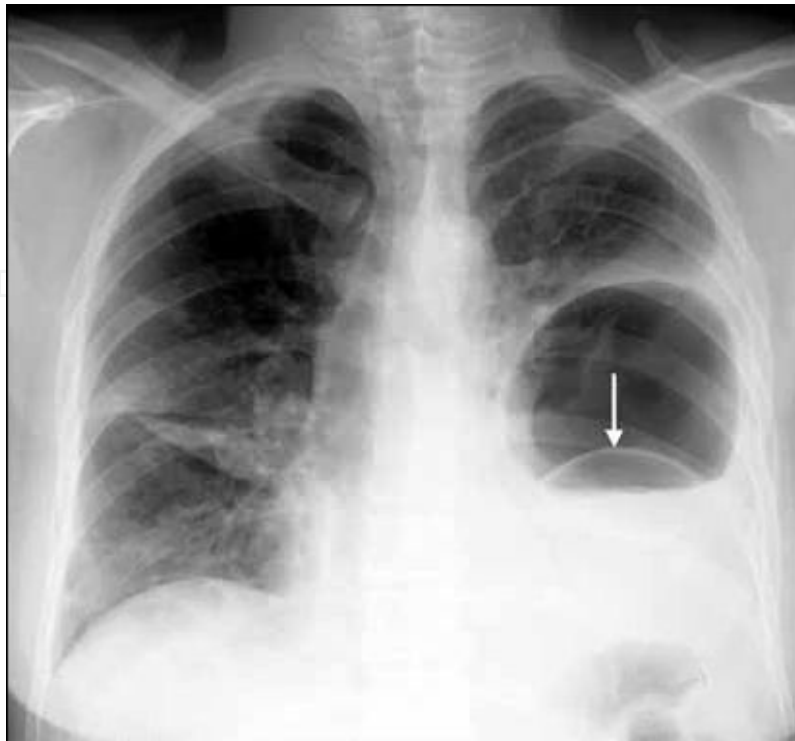


Figure 10. Combo sign (Double air layer appearances)

After the contents of the cyst are partially expectorated, collapsed membranes inside the cyst form the serpent sign. (Fig 11)

Another pathognomonic sign is the water lily sign which occurs after the endocyst detaches completely and the layer caves into the cyst cavity, floating freely on the cyst fluid. (Fig 12, 13)

In pulmonary hydatid disease, the radiological signs are usually precise contrary to the clinical presentation. The appearance of a pulmonary hydatid cyst may change secondary to perforation which necessitates further use of CT.

Rupture, with an incidence of 49%, is the most frequent complication of pulmonary hydatid disease. Communicating rupture occurs when the cyst contents escape via bronchial radicles which are incorporated in the pericyst. Rupture of the hydatid cyst into the bronchus occurs due to the degeneration of the membranes and manifests as coughing and expectoration of a large amount of salty sputum containing mucus, hydatid fluid, and rarely fragments of the laminated membrane. Thereby, solid remnants of the collapsed parasitic membrane are left in the cavity. (Fig 14)

In the other hand, pulmonary hydatid cyst may mimic a variety of clinical and radiological problems including tuberculosis, primary and secondary tumors, lung abscess, bronchopulmonary infections, Wegener's granulomatosis, bronchiectasis, pneumothorax, pleurisy, and empyema.

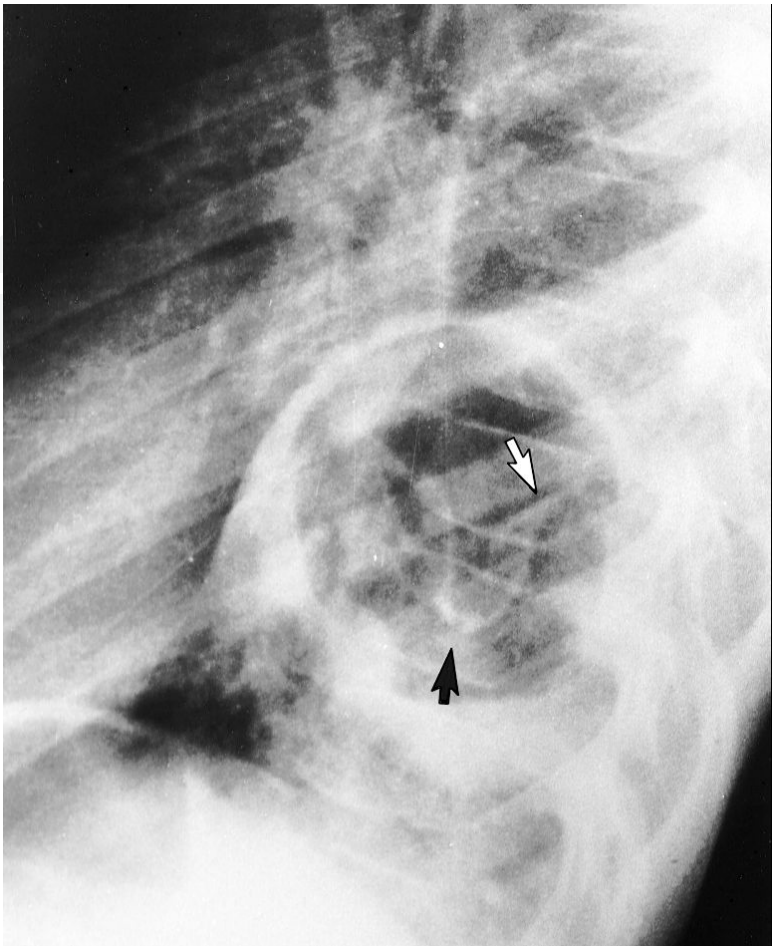


Figure 11. Lung involvement in a child with previous episodes of cough and expectoration. Collimated lateral chest radiograph shows an intracystic serpentine structure representing collapsed membranes (serpent sign) (arrows).

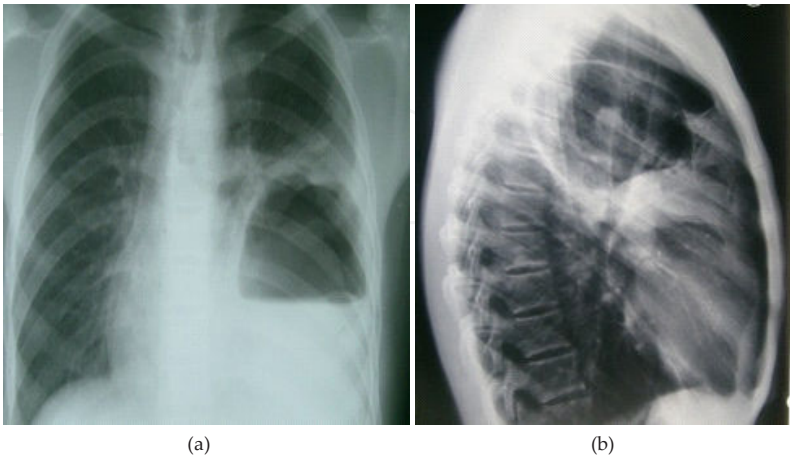


Figure 12. (a) Postero-anterior and lateral (b) chest radiographs showing a cavitory lesion located at the left paracardiac region in the left hemithorax with an air-fluid level having a convex serpinginous margin with hetrogenous contents

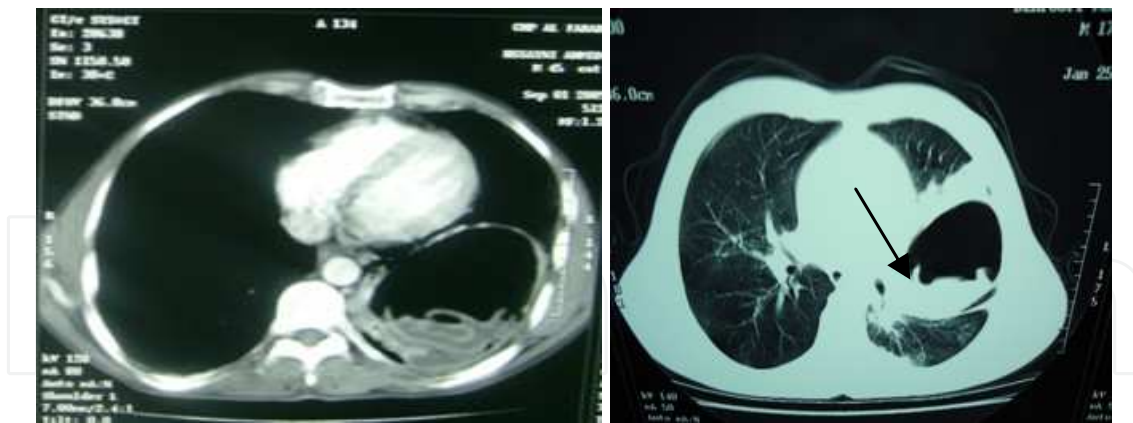

Figure 13. CT scan of thorax showing the torn germinal layer in the right hydatid cyst: the 'water-lily sign.'

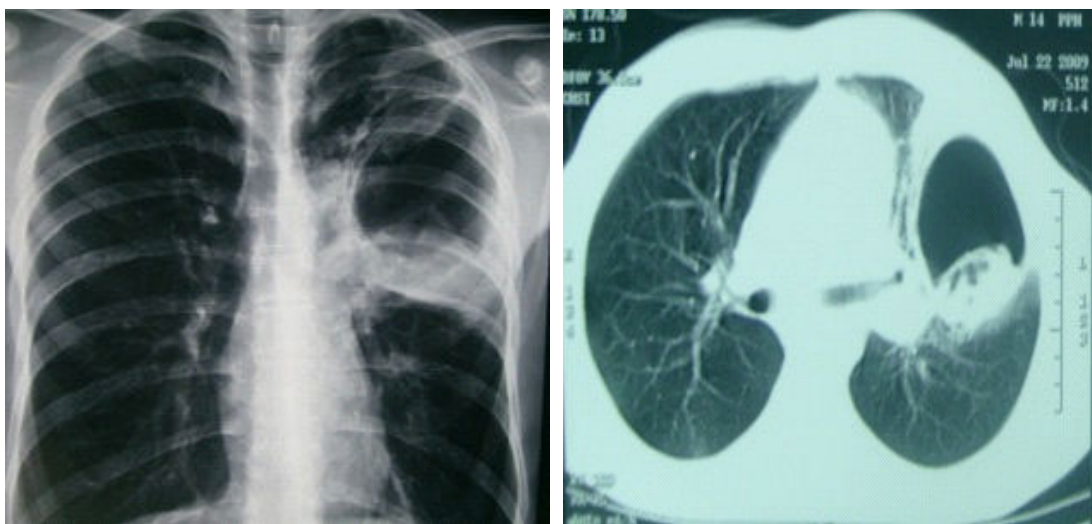


Figure 14. Chest X-ray showing a large cavity with a germinative layer in the left lung

However, CT scan can display the cystic appearance of a pulmonary mass lesion and help localize the cystic lesion for surgical purposes. CT provides further information in equivocal cases by revealing the fluid density of an intact cyst and the air-fluid density of a ruptured cyst. However, infection of the cyst may increase the attenuation values and produce a solid appearance, which may hamper the correct diagnosis. Such a complicated cyst, in the absence of positive history, serologic tests and other radiologic signs, may simulate a malignant tumor, tuberculosis, abscess and other infected cystic lesions of the lung [11].

The "air bubble sign" was described in complicated cysts and reported to be an important clue in the differentiation of hydatid cysts from other disease processes. Air bubble sign is best demonstrated in mediastinal window settings as single or multiple small, rounded radiolucent areas with very sharp margins within solid media or pericystic areas. They should not, however, be mistaken as cavitations or pseudocavitations. (Fig 15)

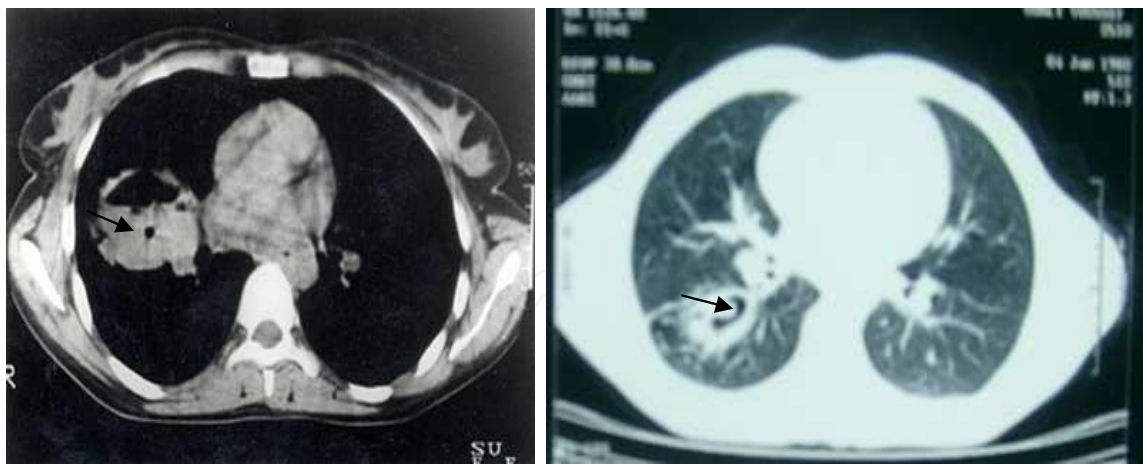


Figure 15. Mass with few air bubbles

The hydatid cysts can grow more easily and faster in the lungs because of the elastic structure of the lungs compared to the liver. For this reason, the growth rate of cysts in the lungs is estimated to be at least 5-fold higher than in the liver [12]. It has been noted that the percentage of pulmonary cysts larger than 10 cm (huge cyst) is 21.9%-25% [13, 14]. We also noted that huge pulmonary cysts occur more often in children than in adults.

Rarely, expectoration of the cystic fluid and germinative membrane may lead to spontaneous healing of the residual cavity in some of the small cysts. (Fig 16)

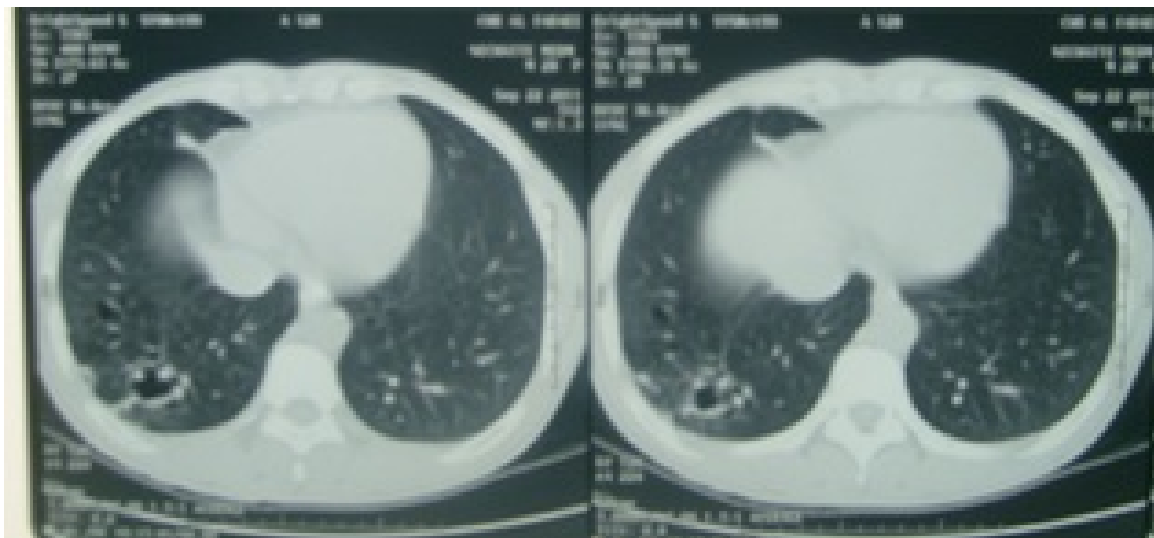


Figure 16. CT scan of the chest showing an empty cavity with thin walls after complete evacuation of hydatid membrane

The simultaneous involvement of the liver and lung is quite uncommon but when it occurs, the right lung is involved in 97% of the cases [15]. Transdiaphragmatic hydatid disease has been very seldom reported. (Fig 17)

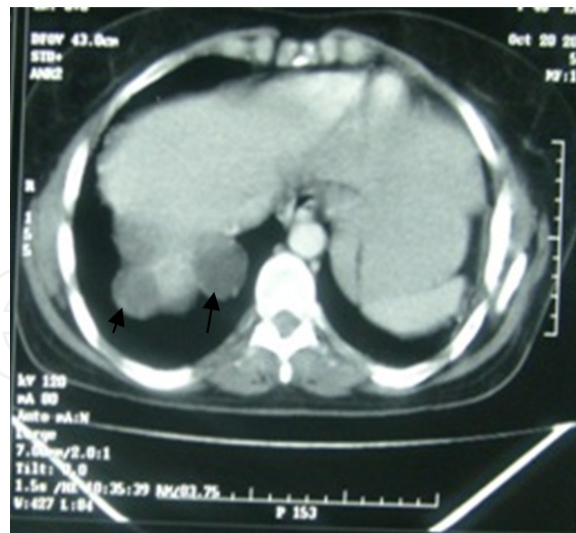

Figure 17. Contrast-enhanced CT scan obtained at the level of the dome of the diaphragm shows a partially calcified cyst originating in the posterior segment of the right hepatic lobe and growing through the diaphragm into the lung (arrows). The cyst has the characteristic hourglass shape.

7. Evolution

During the natural course of infection, the fate of the hydatid cysts is variable. Some cysts may grow (average increase: 1–30 mm per year) and persist without noticeable change for many years. Others may spontaneously rupture or collapse and can completely disappear. Calcified cysts are not uncommon. Spillage of viable protoscoleces after spontaneous or traumatic cyst rupture, or during interventional procedures, may result in secondary echinococcosis.

8. General principles of the treatment

8.1. Surgery methods

8.1.1. Conventional surgery

Initially, the surgical treatment of pulmonary hydatidosis involved the marsupialization of the cyst when it was attached to the wall, or an atypical pulmonary resection consisting of two stages: first pleurodesis was produced, followed by marsupialization in a second procedure. Evidently, these techniques have since been abandoned exceptly when the diagnosis of hydatid cyst rupture was carried later. We have treated young women with chronic pleuritis by marsupialization discovered one month after hydatid cyst rupture. (Fig 18, 19, 20)

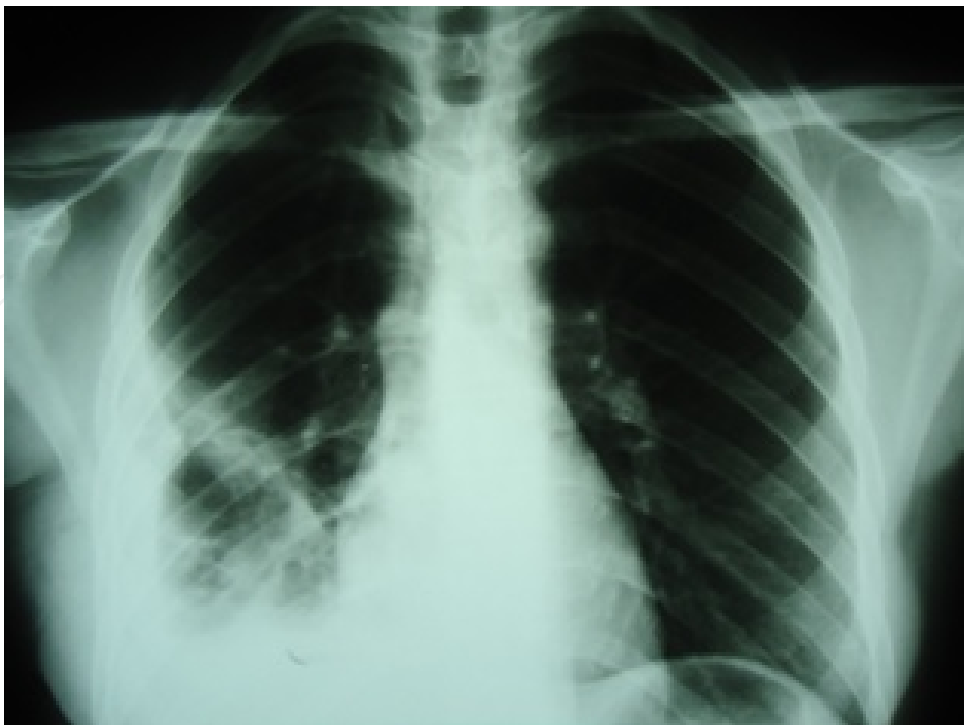

Figure 18. Complicated hydatid cyst with chronic pleuritis.

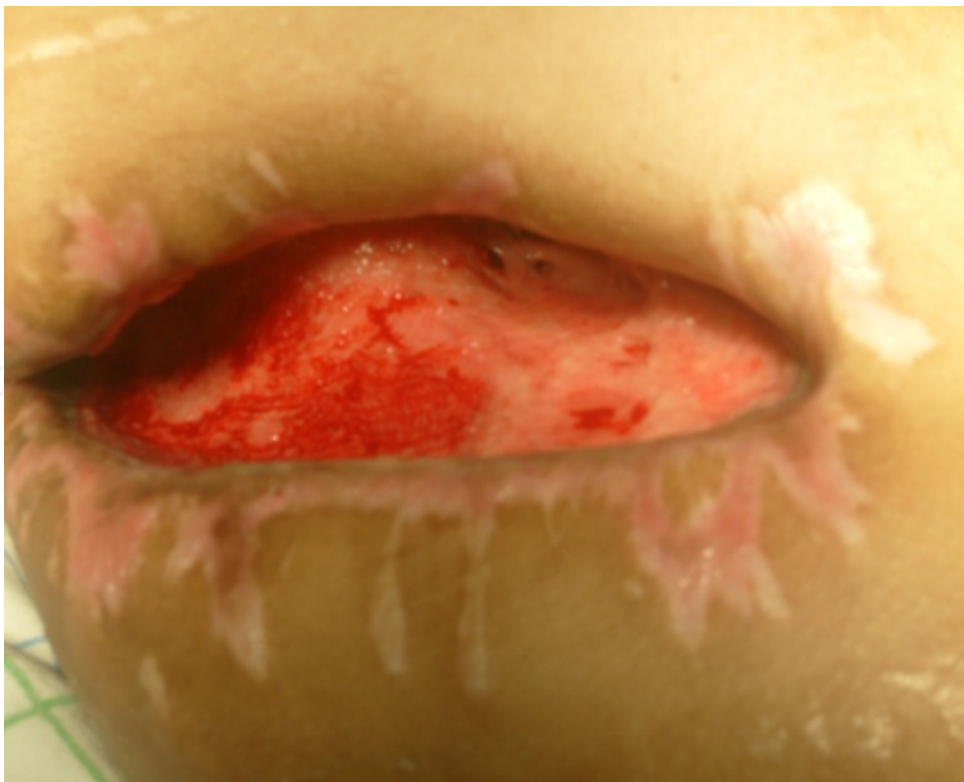


Figure 19. Marsupialization of the cyst

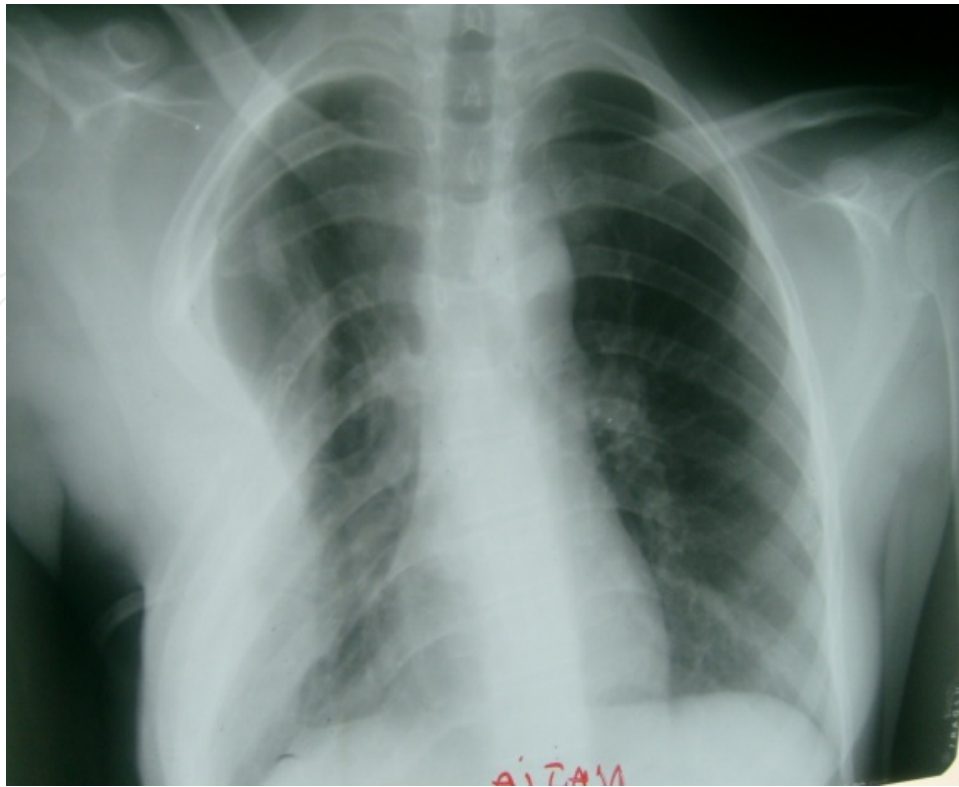

Figure 20. Outcomes of marsupialization after 1 year for complicated hydatid cyst

Actually the aim of surgery in pulmonary hydatid cyst is to remove the cyst completely while preserving the lung tissue as much as possible. Lung resection is performed only if there is an irreversible and disseminated pulmonary destruction. Careful manipulation of the cyst and adherence to the precaution to avoid the contamination of the operative field with the cyst content is the imperative part of the operation. Different surgical procedures have been described such as the enucleation of intact cyst, and needle aspiration for the evacuation of the cyst with serious risk by spillage of hydatid fluid around the puncture site. Cyst spillage may release a large number of viable scolices that implant elsewhere and produce secondary cysts [16]. Sood et al [17] reported a case of anaphylactic reaction following aspiration of a hydatid cyst in the liver during an operation under general anesthesia. The risks cited after fluid rupture by enucleation and needle aspiration are rare but serious, and prompted surgeons in endemic countries to develop a novel procedure to contain the cyst during surgery, preventing any spillage of hydatid fluid around the puncture; Santini et al [18] assembled a device using a transparent plastic cylinder used by nurses to perform venous blood harvesting. The top of the cylinder contains a hole that allows for the connection of two needles (Fig. 21). The base of the plastic cylinder was placed on top of the cyst. They penetrated the cyst using Needle A, and Needle B to create a negative depression in the plastic cylinder, thus allowing the tenacious adhesion of the cyst to the cylinder to eliminate the risk of extravasation of liquid during evacuation.

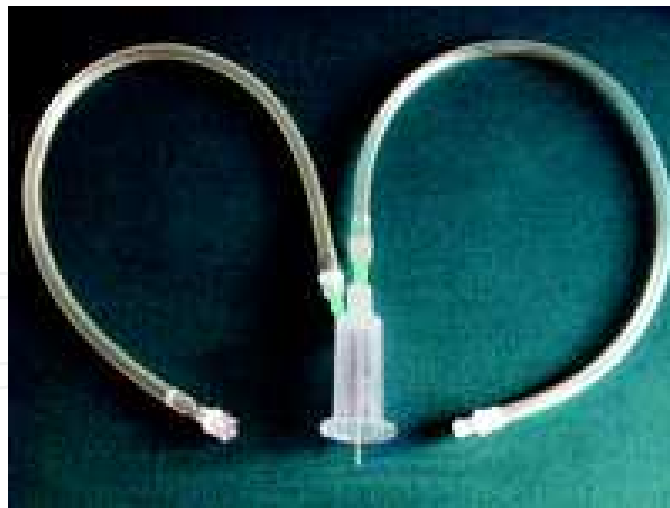


Figure 21. The photograph illustrates the home-made device of Mario Santini *Naples*.;With permission

Personally, Cystotomy and capitonnage, our preferred technique, was carried out in 95 % of our patients, we employed a trocar-suction device for needle aspiration (Fig. 22). The use of this instrument prevents the rupture of the cyst, eradicates the parasite and makes it possible to excise the residual cavity.

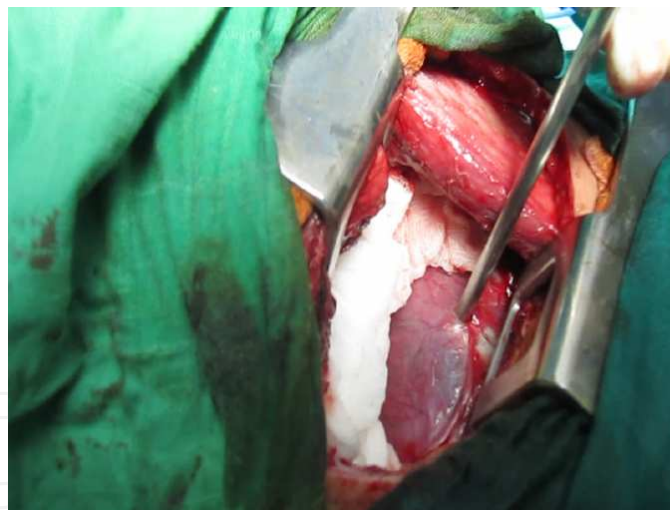


Figure 22. Trocar-suction device for needle aspiration

Thoracotomy was carried out under General anesthesia with double lumen endotracheal tubes for producing ipsilateral lung collapse during the procedure. After opening the chest wall and releasing the adhesions, we avoided any manipulation of the lung until evacuation of the cyst is not finished; the adjacent tissues were covered by towels soaked in 20% hypertonic saline solution (Fig. 23). We preferred sterilizing the cyst by aspiration of some fluid and its replacement with hypertonic saline for fifteen minutes before the cyst was aspirated by a trocar at a place and the contents of the cyst were evacuated by a powerful suction

through this trocar. There was another suction ready to be used by the assistant to remove any fluid leaking around the trocar. After evacuating the cyst contents, the cyst wall collapsed. Then the pericyst was incised and opened. All of the remaining contents including portions of the laminated membrane and the remaining fluid were removed under direct vision (Figure 24), followed by a partial resection of the pericystic area, the residual cavities were carefully treated with hypertonic saline solution, at this time, the anesthesiologist was asked to ventilate the operated lung to detect the exact location of all bronchial openings by observing air bubbles in the saline solution and all bronchial leaks found were closed individually with absorbable sutures (Fig 25). The cavity was obliterated with purse-string sutures of absorbable material (capitonnage).

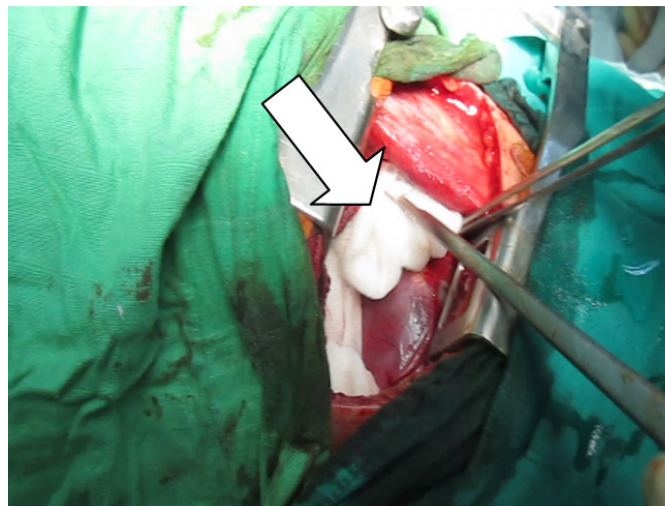


Figure 23. adjacent tissues were covered by towels soaked in 20% hypertonic saline solution (arrow)

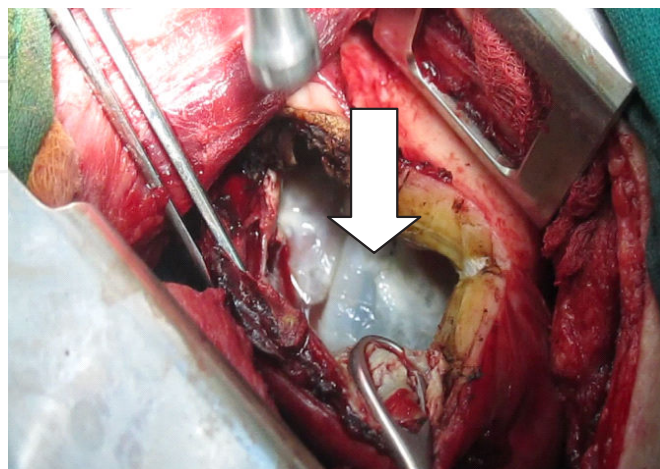


Figure 24. Simple cystectomy of germinative membrane (arrow)

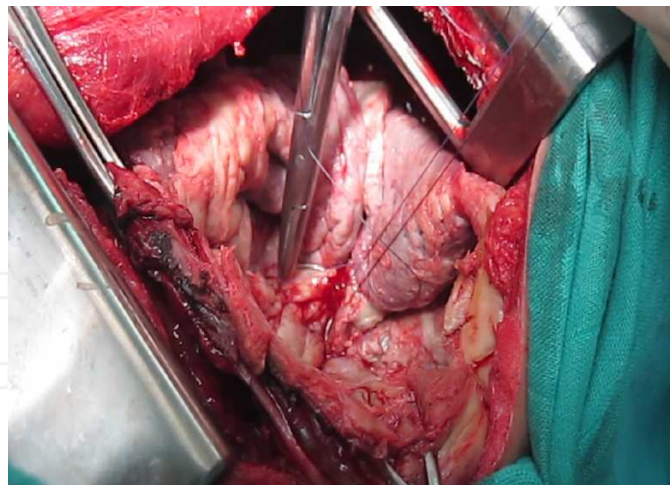


Figure 25. bronchial leaks found were closed individually with absorbable sutures

In our opinion, hypertonic saline solution 20% is effective to killing the ova (cyst injection) and for protection of the operation field with imbibed hypertonic saline pads. These precautions can limit disastrous complications of any spillage or per operative rupture.

Only 5 % of the patients with complicated cyst underwent wedge resection, segmentectomy, lobectomy, pneumonectomy or marsupialization.

8.1.2. Others conventional procedures [19, 20]

A number of methods have been described for the surgical removal of hydatid cysts of the lung.

The Barrett technique (Barrett and Thomas, 1952) which allows the removal of the parasite intact; the pericyst was incised and dissected carefully without rupturing the cyst. This procedure is eminently safe and free of risk of contamination of the pleural space, it's widely applicable, involves the loss of no appreciable pulmonary tissue or function. The technique is ideal for enucleation of all uncomplicated pulmonary hydatid cysts, even of the largest size, and after obliteration of the remaining cavity the inflated lobe looks normal

The Perez Fontana method: the cyst being removed with the pericyst (cystopericystectomy) and the residual cavity obliterated.

The Ugon technique: When the cyst is small and there is no risk of rupture, its complete removal can be attempted, aided by an increase in the airway pressure provided by the anesthetist.

However, the bronchial openings in the cavity must be closed by sutures in all techniques.

Capitonnage which is the folding of the pericystic zone by sutures for obliteration of the residual cavity is usually advocated to prevent air leak from residual bronchial openings. Without capitonnage, the wall of the pericystic cavity is supposed to be covered by epithelial cells for an uncertain length of time. On the other hand, capitonnage has the disadvantage

age of causing distortion of the pulmonary parenchyma, especially after removal of multiple or large cysts. However, there is no clear consensus on the use of capitonnage in surgical series of lung hydatid cyst. (Fig 26)

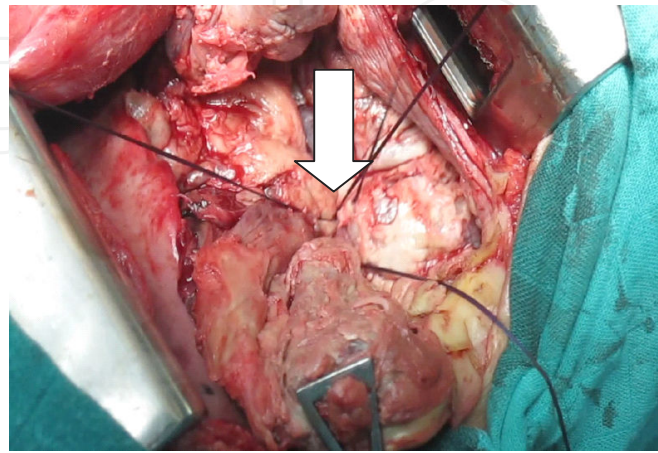


Figure 26. residual cavity after aspiration of hydatid cyst (capitonnage technique) (arrow)

Rarely, hydatid cysts can occur in other thoracic structures such as pulmonary artery, chest wall or diaphragm. (Fig 27, 28)

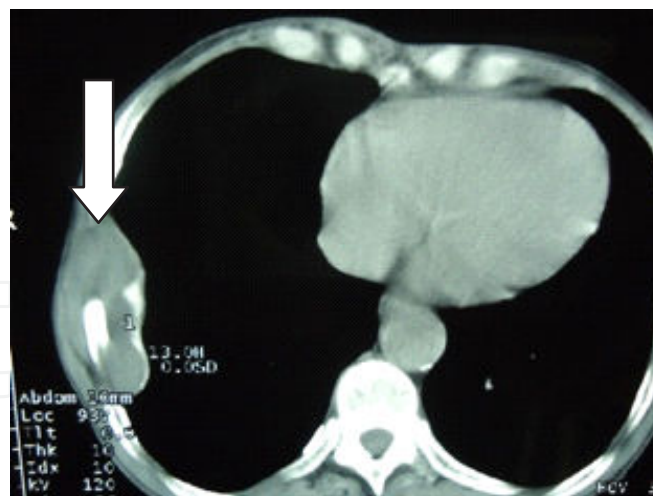


Figure 27. CT scan of rib hydatid cyst (arrow)

Most authors agree that the attempt should be made to remove as little lung tissue as possible and that resection of pulmonary parenchyma is only indicated when the adjacent tissue is seriously damaged or infected, when the atelectatic areas are presumably irrecoverable or when a big cyst or numerous cysts had destroyed a certain anatomical substrate [10].

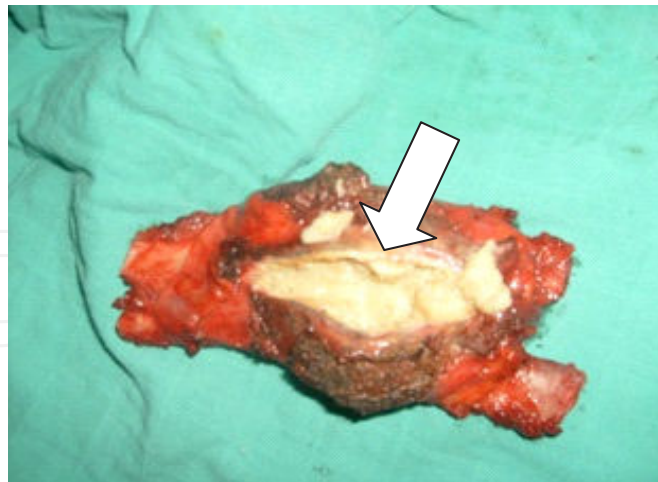


Figure 28. specimen of parietectomy for rib hydatid cyst with hydatid cyst material contained (arrow)

8.1.3. Video assisted thoracoscopic surgery

In adult, some authors [21] have reported the successful use of thoracoscopic procedures for the treatment of pulmonary hydatid disease. Sporadic cases were founded in the French and the other in the English literature. In our experience, we have treated three patients through this procedure. Postoperative course was uneventful in all cases. The thoracoscopic approach in pulmonary hydatid cysts must follow the same principles of the open technique, which include sterilization of the cyst with scolicidal agents (eg. hypertonic saline), complete excision of the endocyst, and closure of bronchial fistula, if present. The main advantage offered by thoracoscopy is less trauma and discomfort for the patient. The lack of intercostal muscle incision and the lower risk of rib fracture reduce the postoperative pain and when compared to thoracotomy, thoracoscopy reduces the chest tube duration and length of hospital stay. Conversion to thoracotomy is mainly related to major pleural adhesions.

8.2. Medical therapy

Although surgery remains the treatment of choice for hydatid disease, the usefulness of drug therapy has been reported in many studies. Medical treatment is an alternative to surgery where a surgical approach is not recommended in risk patients, and in cases with small and multiple lesions in one or more organs, or proximity of cysts to major vascular structures. Antihelminthic agents, Mebendazole, and more recently albendazole, and praziquantel, reduce recurrence post-operatively, particularly where there has been spillage of cyst contents [22].

Many and substantial questions still remain unanswered, however. What is the optimum duration of treatment? Clearly, duration of treatment of < 3 months produces less than optimal response, whereas results of extension beyond 6 months have yet to be gauged

because clinicians tend to adopt longer courses. We believe that the response of the therapy differs according to age (children and adults), cyst size, cyst structure (presence of daughter cysts inside the mother cysts and thickness of the pericystic capsule allowing penetration of the drugs), and localization of the cyst [23]. We think that selected pediatric patients with uncomplicated pulmonary hydatid cysts sized less than 5 cm, with thin pericystic capsule respond favorably to treatment. However a large pulmonary hydatid cyst should not be treated medically, because incomplete expectoration of the cyst contents after the parasite death may lead to infection through bronchial communication. Medical therapy may cause in some cases rupture of the lung cyst, and respiratory distress. We suggest that in patients with hydatid disease of the lungs associated with multiple organ involvement, medical treatment should not be given before the removal of hydatid cyst of lung.

We thought that medical treatment should be given after surgical therapy, patients surgically treated for complications following medical treatment are hospitalized twice as long as patients surgically treated in the first place. Postoperative Albendazole treatment (400 mg twice a day for the first 15 days of the month) was administered to patients for a period of 3 to 6 months.

9. Prevention

Necessary to strictly observe good personal hygiene when the content of the dogs and care for them, and be sure to wash your hands after contact with the dog, not to allow dogs to the food of man and his pot, limit direct exposure of children and dogs. Stray dogs are everywhere to be catching. In addition to current (and past) hydatid control campaigns, there have been significant technological improvements in the diagnosis and treatment of human and animal cystic echinococcosis, the diagnosis of canine echinococcosis, and the genetic characterization of strains and vaccination against *E. granulosus* in animals. Incorporation of these new measures could increase the efficiency of hydatid control programmes, potentially reducing the time required to achieve effective prevention of disease transmission to as little as 5 - 10 years.

10. Conclusion

We are of the view that surgical treatment of the lung cyst should be preferred firstly in cases of lung hydatid cyst disease. The diversity of the pathological process offers various tactics and approaches in the surgical treatment which must be individually tailored in each and every case. The goal of surgical therapy is to remove the cyst while preserving as much lung tissue as possible and medical treatment may be useful only in no operable patients.

Author details

Ihsan Alloubi*

Address all correspondence to: ialloubi@yahoo.fr

Thoracic surgery department, Centre Hospitalier Universitaire Oujda, Morocco

References

- [1] Aletras H, Symbas PN: Hydatid disease of the lung. In: Shields TW, LoCicero J, Ponn RB (eds.), *General Thoracic Surgery*, 5th ed. Philadelphia: Lippincott Williams & Wilkins; 2000; 1113–22
- [2] Torgerson PR, Oguljahan B, Muminov AE, Karaeva RR. The present situation of cystic echinococcosis in Central Asia. *Parasitol Int.* 2006; 55 Suppl: S207-12.
- [3] CFraser RS, Muller NL, Coleman N, Pare PD. Protozoa, Helminths, Arthropods and Leeches. In: Fraser and Pare's *Diagnosis of diseases of the chest*. 4th ed. WB Saunders Philadelphia. 1999;1033-66.
- [4] Santivanez S, Garcia HH. Pulmonary cystic echinococcosis. *Curr Opin Pulm Med* 2010;16(3):257-61.
- [5] Yilmaz A, Tuncer LY, Damadoglu E, Pulmonary hydatid disease diagnosed by bronchoscopy: a report of three cases. *Respirology* 2009; 14:141–3.
- [6] Saygi A, Otek I, Guder M, Sungun F, Arman B Value of fiberoptic bronchoscopy in the diagnosis of complicated pulmonary unilocular cystic hydatidosis. *Eur Respir J* (1997); 10: 811–814.
- [7] Hiras PR, Shweiki H.. Counterimmunoelectrophoresis using an Arc -5 antigen for the rapid diagnosis of hydatidosis and comparison with the IHA test. *Am J Trop Med Hyg* 1987; 36(3): 592- 97.
- [8] Porehi D, Felleisen E Differential immunodiagnosis between cystic hydatid disease and other cross- reactive pathologies *Am J Trop Med Hyg* 1999; 60: 193-198.
- [9] Zarzosa MP, Orduña Domingo A, Gutiérrez P, et al. Evaluation of six serological tests in diagnosis and postoperative control of pulmonary hydatid disease patients. *Diagn Microbiol Infect Dis* 1999;35:255-262.
- [10] Dogan R, Yuksel M, Cetin G, Süzer K, Alp M, Kaya S Surgical treatment of hydatid cysts of the lung: report on 1055 patients. *Thorax* 1989; 44: 192-9.
- [11] Von Sinner WN. New diagnostic signs in hydatid disease; radiography, ultrasound, CT and MRI correlated to pathology. *Eur J Radiol* 1991; 12(2): 150-9

- [12] Halezaroglu S, Celik M, Uysal A, Senol C, Keleş M, Arman B. Giant hydatid cysts of the lung. *J Thorac Cardiovasc Surg* 1997; 113: 712-7.
- [13] Solak H, Yeniterzi M, Yüksek T, et al. The hydatid cyst of the lung in children and results of surgical treatment. *Thorac Cardiovasc Surg* 1990; 38(1): 45-7
- [14] Saygı A, Öztekin I, Güder M, et al. Value of fiberoptic bronchoscopy in the diagnosis of complicated pulmonary unilocular cystic hydatidosis. *Eur Respir J* 1997;10(4): 811-4
- [15] Yörük Y, Yalçınkaya S, Çopkun I, et al. Simultaneous operation for coexisting lung and liver hydatid cyst: a treatment modality. *Hepatogastroenterology* 1998; 45(23): 1831-2
- [16] Ulku R, Onen A, Onat S. Surgical treatment of pulmonary hydatid cysts in children: report of 66 cases. *Eur J Pediatr Surg* 2004; 14: 255-9.
- [17] Sood D, Sharma DR, Santoshi ID. Anaphylactic shock on aspiration of hydatid cyst of liver during operation: treatment with ketamine. *Indian J Anaesth* 1994 Jun;42:213–214.
- [18] Santini M, Fiorello A, Vicidomini G, Perrone A. A home-made device for safe intraoperative aspiration of pulmonary hydatid cysts. *Interactive CardioVascular and Thoracic Surgery* 7 (2008) 365–367
- [19] Anadol D, Gocmen A, Kiper N, Ozcelik U. Hydatid disease in childhood: a retrospective analysis of 376 cases. *Pediatr Pulmonol* 1998; 26: 190-6.
- [20] Safioleas M, Misiakos EP, Dosios T, et al. Surgical treatment for lung hydatid disease. *World J Surg* 1999; 23(11): 1181-5
- [21] Mallick MS, Al-Qahtani A, Al-Saadi MM, Al-Boukai AA. Thoracoscopic treatment of pulmonary hydatid cyst in a child. *J Pediatr Surg*. 2005 Dec;40(12):e35-7
- [22] Mahin Jamshidi, Minou Mohraz, Mehrangiz Zangeneh, Ali Jamshidi; The effect of combination therapy with albendazole and praziquantel on hydatid cyst treatment ; *Parasitology Research* Volume 103, Number 1 (2008), 195-199
- [23] Stamatakis M, Sargedi C, Stefanaki Ch, Safioleas C, Matthaiopoulou I, Safioleas M. Anthelmintic treatment: an adjuvant therapeutic strategy against *Echinococcus granulosus*. *Parasitol Int*. 2009 Jun; 58(2):115-20.

