

We are IntechOpen, the world's leading publisher of Open Access books Built by scientists, for scientists

6,900

Open access books available

186,000

International authors and editors

200M

Downloads

Our authors are among the

154

Countries delivered to

TOP 1%

most cited scientists

12.2%

Contributors from top 500 universities



WEB OF SCIENCE™

Selection of our books indexed in the Book Citation Index
in Web of Science™ Core Collection (BKCI)

Interested in publishing with us?
Contact book.department@intechopen.com

Numbers displayed above are based on latest data collected.
For more information visit www.intechopen.com



Veno-Arterial Extracorporeal Membrane Oxygenation for Refractory Cardiogenic Shock and Cardiac Arrest

Francesco Formica and Giovanni Paolini

Additional information is available at the end of the chapter

<http://dx.doi.org/10.5772/54719>

1. Introduction

Cardiogenic shock (CS) following acute myocardial infarction (AMI) occurs in 7% to 9% of patients affected by AMI with a high mortality rates. Despite all recent advanced treatments such as use of inotropes, vasoconstrictors and intra-aortic balloon pump (IAPB) therapy, revascularization techniques and application of different systems of mechanical circulatory support, CS is still the most common cause of hospital mortality ranging between 60%-70% compared to patients with AMI without advanced CS whose hospital mortality is about 10% [1]. Cardiac arrest is a major cause of unexpected death and complicates about 22% of patients with acute myocardial infarction [2]. Cardiac arrest has a poor prognosis, and despite conventional cardiopulmonary resuscitation (CPR) maneuvers, only a few patients can fully return to a normal lifestyle. The main reasons for very poor outcome and prognosis in CA are a lack of return of spontaneous circulation (ROSC), a long time of CPR [3],[4], re-arrest from hemodynamic instability after ROSC, hypoxic encephalopathy [5], out-of-hospital CA [6-8]. In both refractory CS and CA secondary AMI, which are very critical circumstances, Veno-Arterial Extracorporeal Membrane Oxygenation (V-A ECMO) has been proposed and utilized during the last decades to obtain rapid resuscitation, stabilization, and subsequent triage to a more permanent treatment strategy.

The aim of this chapter is to describe the more recent indications, techniques and results in the usage of the V-A ECMO in patients with refractory cardiogenic shock and cardiac arrest secondary to acute myocardial infarction.

2. Definition of V-A ECMO

Extracorporeal membrane oxygenation is essentially a modification of the cardiopulmonary bypass circuit, which is used routinely in cardiac surgery. Blood is removed from the venous system, oxygenated by an oxygenator and then returned back to the body by a pump. ECMO provides both full cardiac and respiratory support. In brief, every ECMO system is basically a closed tubing loop with the interpolation of a blood pump (centrifugal or roller) and an oxygenator. Two vessel cannulas complete the system. Technically the ECMO system is more complex and several configurations have been developed according to the primary etiology.

The veno-arterial ECMO configuration is a tubing loop with a venous arm connected to a venous cannula to allow the venous blood drainage and an arterial arm to return back the oxygenated blood inside the patient's circulatory system. This mode provides both cardiac and respiratory support and can be achieved by either peripheral or central cannulation (Figure1).

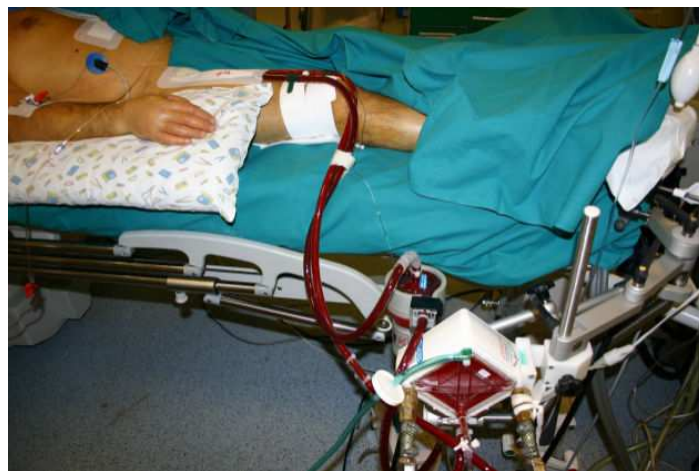

Figure 1. Patient supported with peripheral V-A ECMO

The veno-venous ECMO mode refers to blood, which is drained from the venous system and returned back to the venous system. This mode only provides respiratory support and is obtained by peripheral cannulation, usually of both femoral veins and jugular vein. This ECMO configuration will be not discussed in this chapter.

2.1. Definition of cardiogenic shock

Cardiogenic shock is a state of impaired and non-physiologic end-organ perfusion owing to a low cardiac output. Being characterized by hypotension cardiogenic shock is defined mainly by haemodynamic parameters as follows [9,10]:

- a. a systolic blood pressure of less than 90 mmHg for more than 30 min with normovolemia;
- b. the need of inotropic drugs to obtain a systolic blood pressure more than 90 mmHg with;

- c. a cardiac index less than 1.8 L/min/m² without inotropic support and 2.0–2.2 L/min/m² with inotropic and intra-aortic balloon pump (IABP) support;
- d. high left ventricular (LV) filling pressures (pulmonary capillary wedge pressure more than 18 mmHg).

End-organ hypoperfusion may be manifested clinically by:

- a. pale, cool, and clammy peripheries;
- b. alteration in mental status such delirium, confusion, clouded sensorium, psychomotor agitation;
- c. decreased urine output (less than 1 ml/kg/min);
- d. pulmonary congestion or edema;
- e. tachycardia;
- f. hyperlactacidemia (more than 3.mmol/L) as expression of impaired peripheral microcirculation;
- g. mixed venous saturation of less than 65%.

3. Definition of in-hospital and out-hospital cardiac arrest

Cardiac arrest is a major cause of unexpected death in developed countries with a low probability of patient survival. Survival is influenced by several variables common to both in-hospital and out-of-hospital arrest, such as time to recognition of the cardiac arrest, time to initiation of CPR, rhythm presentation, first defibrillation [2, 11, 12]. In current resuscitation guidelines for in-hospital cardiac arrest (IHCA) patients [13], CPR using ECMO (E-CPR) has been assigned a low-grade recommendation. It is reported that ECMO for out-of-hospital cardiac arrest (OHCA) has worse outcomes compared with ECMO for IHCA patients [7, 14]. In the United States, more than 166,000 patients experience an OHCA annually [15] and approximately 60% are treated by emergency medical services. OHCA survival to hospital discharge range from 0.3% in Detroit [16] to 20.4% in Slovenia [17]. Five clinical criteria to predict survival from OHCA [18] have recently been reported. They are: cardiac arrest witnessed by a bystander, arrest witnessed by emergency medical personnel, provision of bystander CPR, shockable cardiac rhythm, and return of spontaneous circulation (ROSC) in the field. These criteria are applicable on IHCA too.

4. Indication and contraindications for v-a ECMO

Patient selection is a crucial point when the physician needs to take the decision to institute ECMO and several considerations must be focused up. Most importantly, it must be consider

the likelihood of heart and end organs recovery. If the organs failure is thought to be reversible with ECMO, in such situation the device application is to be encouraged. If the likelihood of recovery of the heart or other end organs is thought to be very low or even impossible, then other factors must be taken into account. In such clinical scenario, the decision to institute ECMO should be based on an experienced ECMO team approach, which has to evaluate the patient's eligibility for heart transplantation or a definitive mechanical assist device (LVAD) implant as destination therapy.

4.1. Indications for v-a ECMO

The following factors need to be evaluated for the indications [19]:

- Age of patient and body surface area;
- sufficient medical expertise in the field of ECMO;
- possibilities for myocardial revascularization therapy, such as a coronary artery bypass grafting or coronary angioplasty;
- possibilities for heart transplantation or LVAD implant as destination therapy;
- status of central organs such as kidney, liver, and brain.

4.2. Contraindications for v-a ECMO

Contraindications to the institution of v-a ECMO include [20]:

- disseminated malignancy;
- advanced age;
- graft vs. host disease;
- known severe brain injury;
- unwitnessed cardiac arrest or cardiac arrest of prolonged duration;
- aortic dissection aortic incompetence.

5. Equipment of v-a ECMO circuit

5.1. ECMO circuit

The ECMO circuit is made of PVC tubing and the diameter of lines varies from $\frac{1}{4}$ inch for a neonate to $\frac{1}{2}$ inch for pediatric and adult patients. The length of the circuit is kept not more than 2 meters to avoid increasing of resistance within a tube and twisting, but the length should be suitable to allow the movements of the patient by ECMO staff.

Areas of turbulent flow can predispose to clot formation; therefore loop and connectors should be avoided or kept at minimum.

5.2. ECMO cannulas and cannulation techniques

Cannulation is one of the most challenging aspects of ECMO. Peripheral percutaneous approach [6, 21] is the most used in cardiogenic shock and cardiac arrest [7, 22] because is quicker with less bleeding complications and easier decannulation. (Figure 2).

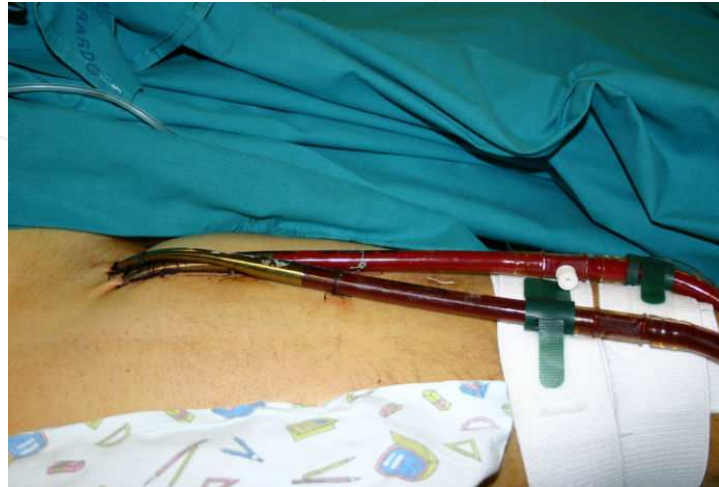

Figure 2. Peripheral cannulation for V-A ECMO.

The open surgical approach is considered for patients with severe peripheral vascular disease or for patients with postcardiotomy syndrome or failure of weaning from cardiopulmonary bypass [23, 24] (Figure 3). The open or central cannulation has more complications such as bleeding, infections, and mediastinitis.

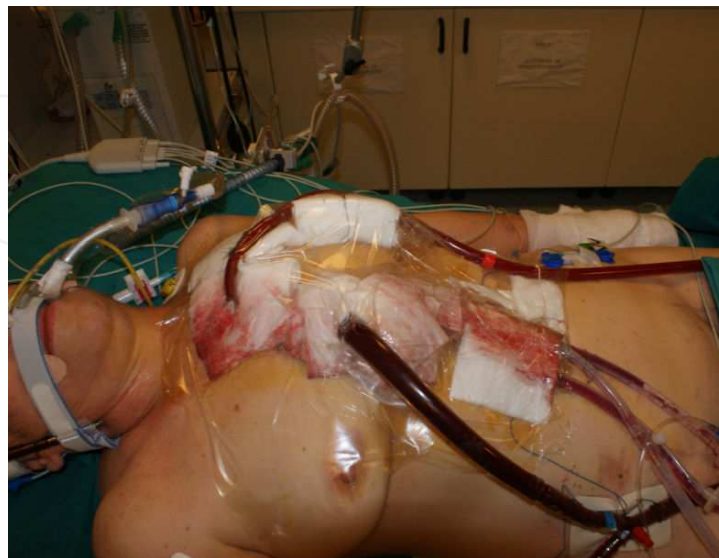

Figure 3. Central cannulation for V-A ECMO

Percutaneous cannulas are usually made of polyurethane (Figure 4) and they are inserted using the Seldinger technique (Figure 5).

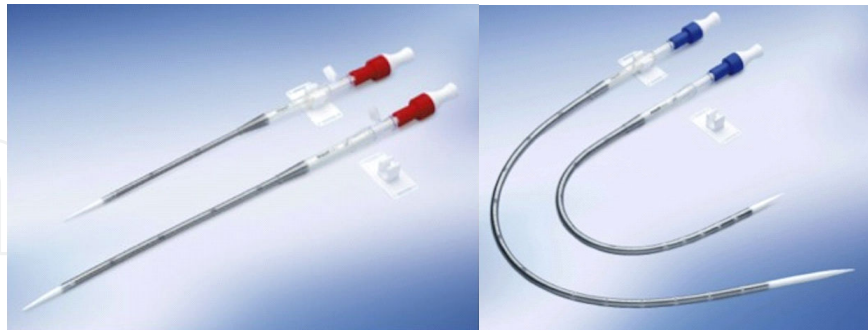


Figure 4. Percutaneous arterial cannulas (right) and percutaneous venous cannulas (left).

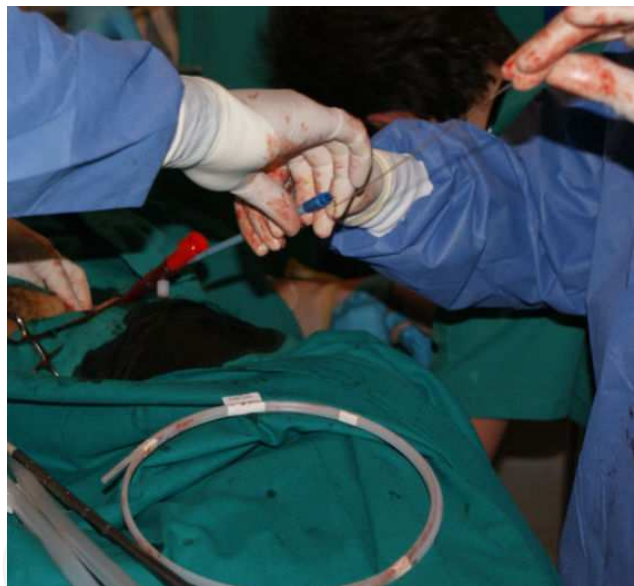

Figure 5. Percutaneous cannula insertion by Seldinger technique.

The size of the cannulas depends on the size of the patient; usually the arterial cannula ranges between 17 Fr to 21 Fr and the venous cannula ranges between 21 Fr and 25 Fr. Cannulas of sufficient size are required to support high blood flow with low resistance. Local complications, particularly at the site of peripheral insertion of VA-ECMO can occur, of which the most concerning is leg ischemia. For this reason all attempts the limb perfusion is restored, after noted the absence of anterior and posterior tibial artery flow, by inserting a 9-Fr catheter distally to the arterial cannula by means of vascular ultrasound scan as soon as possible after ECMO implantation (Figure 6).



Figure 6. Distal leg perfusion to restore the blood flow.

Some Authors [25] suggested to insert a catheter for a distal perfusion if the mean pressure of the superficial femoral artery is lower than 50 mmHg.

Alternative arterial approach, such as axillary arterial cannulation, has been reported [26] (Figure 7).

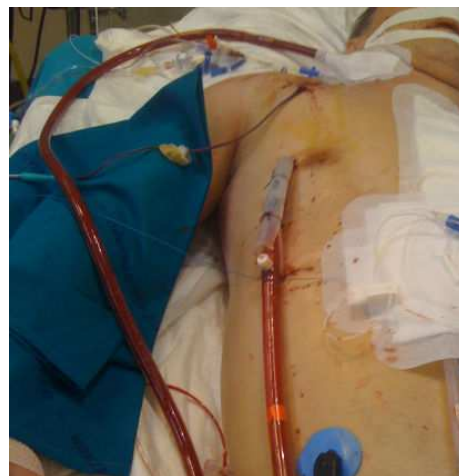

Figure 7. Cannulation of right axillary artery (tube on the right). Cannula is tunneled below the skin to protect by accidental trauma.

Whatever the type of approach cannulation is considered, it requires always a highly skilled medical staff, usually a cardiac or vascular surgeon, who are able to undertake this procedure under often very difficult conditions as the patients are so unstable or even in cardiac arrest.

5.3. Pumps

The pump pushes the blood through the oxygenator and then back to the patient. The most used pump in adult patients is the centrifugal pump. These pumps consist of a polycarbonate housing with a one-point sapphire bearing linked to a magnetic field, which create a vortex flow at an adjustable rate (Figure 8). Vortex creates a negative pressure in

the pump head and this negative pressure pulls blood into the pump and then the blood is pushed towards the oxygenator.

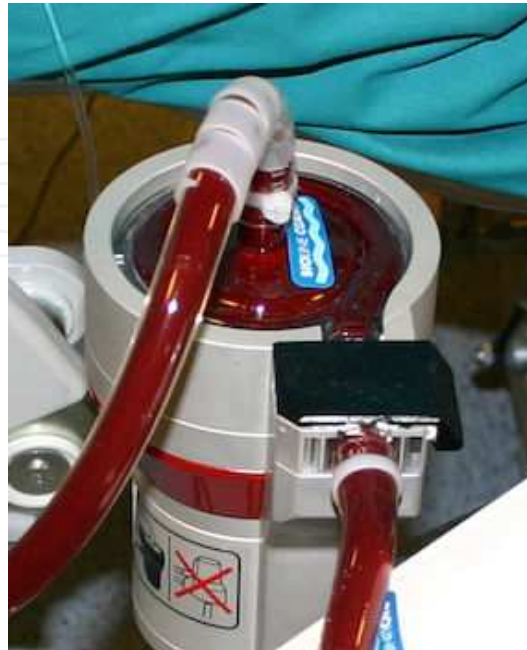

Figure 8. Centrifugal pump.

5.4. Oxygenators

The silicone membrane has been the principal artificial lung used for ECMO for many years and introduced in the clinical practice by Kolobow [27] and Bartlett [28]. The silicone oxygenators were used until the diffusion of microporous hollow fibers oxygenators in the 90s. The silicone surface is homogeneous and does not contain micropores, which can cause plasma leakage. However, the silicone oxygenator has a very large membrane surface to ensure adequate gas exchange and needs both high prime volume and high pressure drop; moreover, the procedure to optimize the efficacy of the oxygenator is cumbersome and lengthy, requiring a CO₂ gas flush. The hollow-fiber polypropylene membrane oxygenators had advantages over the silicone oxygenators, such as high gas exchange efficiency with a smaller change surface, lower prime volume, and lower pressure gradient. However, this generation of oxygenators has micropores causing plasma leakage for periods more than 6 hours, thus reducing the gas exchange. Recently, a new generation of poly-methylpentene (PMP) membrane oxygenators have been introduced with the aim of allowing longer support without the complications linked to the hollow-fiber oxygenators, such as plasma leakage [29] (Figure 9).

The adjunct equipment that completes the ECMO system includes a heat exchanger for temperature regulation, monitors that measure blood flow, venous and arterial saturation, hematocrit, and other variables. ECMO systems also can measure circuit pressures and changes in circuit resistance. Additional safety features include continuous monitoring of venous drainage and air detection.

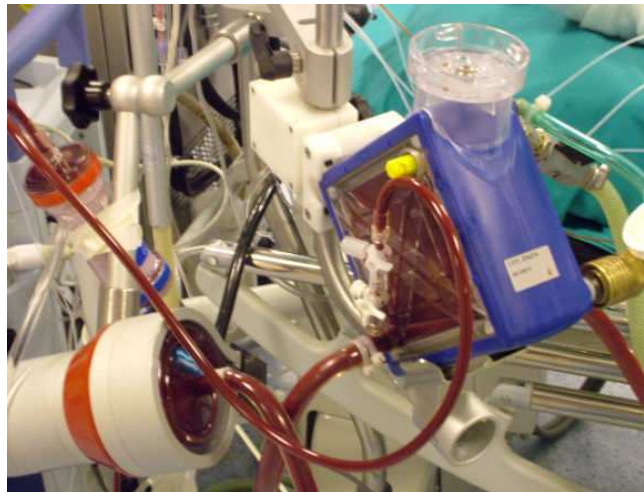

Figure 9. V-A ECMO circuit with polymethylpentene oxygenator (blue case)

Recently a new miniaturized system for V-A ECMO was introduced in the clinical practice. The system has the console directly connected with the oxygenator and the blood pump, which are integrated to each other. The console has a touch screen where is possible to monitor continuously several parameters such as hematocrit, hemoglobin, SVO₂, resistance at the inlet and the outlet of oxygenator and the pressure drop (Figure 10).

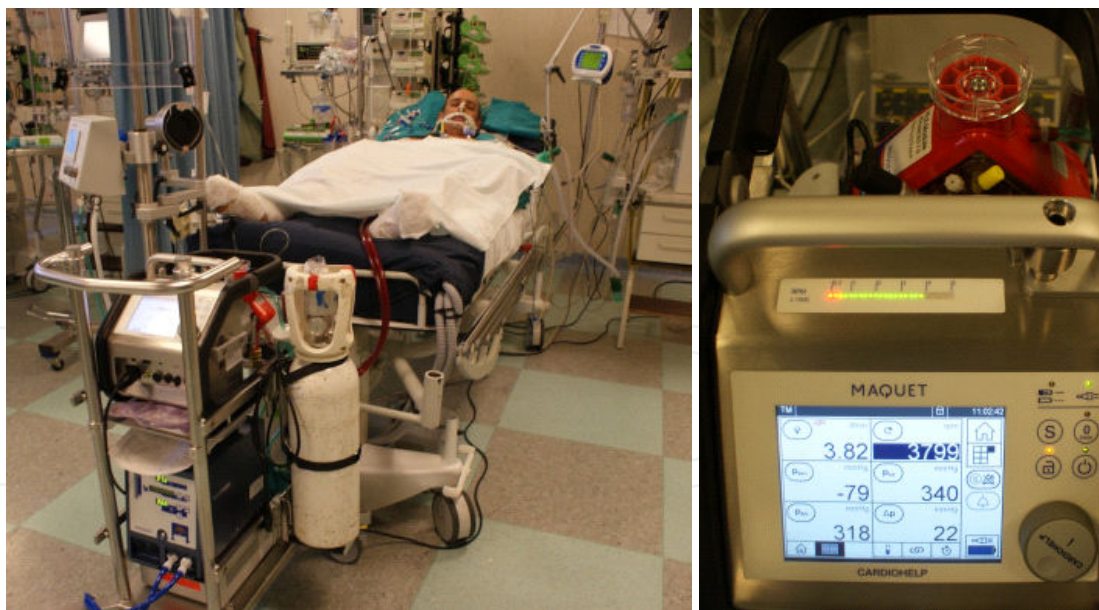

Figure 10. On the left the miniaturized V-A ECMO system (Cardiohelp by Maquet); on the right the particular of console.

This system is very useful because of his reduced dimension and weight (the weight of console is about 10 Kgs); for this reason this system can be used for transportation of V-A ECMO patients within the different sites of the hospital or from hospital to other hospital.

6. Management of v-a ECMO

Systemic heparinization is obtained with an intravenous bolus of 5,000 UI of heparin, 5 minutes prior to vessels cannulation. ECMO blood flow is calculated to maintain a Cardiac Output (CO) index of 2.5 L/min/m², an SvO₂ of about 70% and a mean blood arterial pressure of 60-70 mmHg during the first 24-48 hours. Continuous intravenous heparin is administered in order to achieve an activate clotting time (ACT) of 160-180 seconds and a prothrombin time value of 50-60 seconds. Small doses of inotrope (dobutamine, 5 to 7 µg/Kg/min) are given to maintain the ventricular ejection, to allow the opening of aortic valve and to prevent the formation of clots inside the left ventricle (LV). Oxygenator is always connected with a heat exchange to maintain a body temperature of 36 °C. Those patients who had a cardiac arrest before ECMO implantation are gradually cooled to 32-34°C during the first 24-36 hours. The assessment of the neurologic status is initiated by electroencephalography after body rewarming; serial neurologic evaluations and cerebral computed tomography scan are always considered to assess cerebral hemorrhage, stroke or hypoxic encephalopathy. In those patients with criteria of irreversible brain damage, ECMO withdrawn is usually considered.

Multiple heart examinations by transesophageal echo are performed to monitor the LV pulsatility. Left ventricular venting is considered in case of irreversible pulmonary edema, LV distension or pulseless heart with blood stasis. If the heart needs to be decompressed, several techniques can be considered. An 18-20 Fr catheter could be inserted into the apex of LV after surgery when patient cannot be weaned from cardiopulmonary bypass (Figure 11).

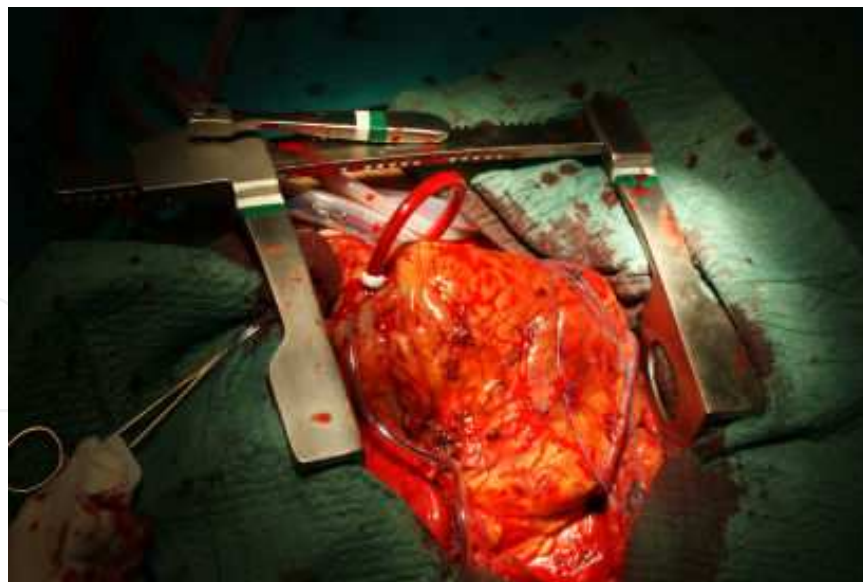


Figure 11. The left ventricle is decompressed by a 20 Fr catheter inserted in the apex of the ventricle.

Alternatively, the LV can be indirectly decompressed with a 16-Fr percutaneous venous cannula inserted in the right internal jugular vein and advanced into the main pulmonary artery; the cannula was connected to the venous arm of the ECMO circuit [30] (Figure 12).

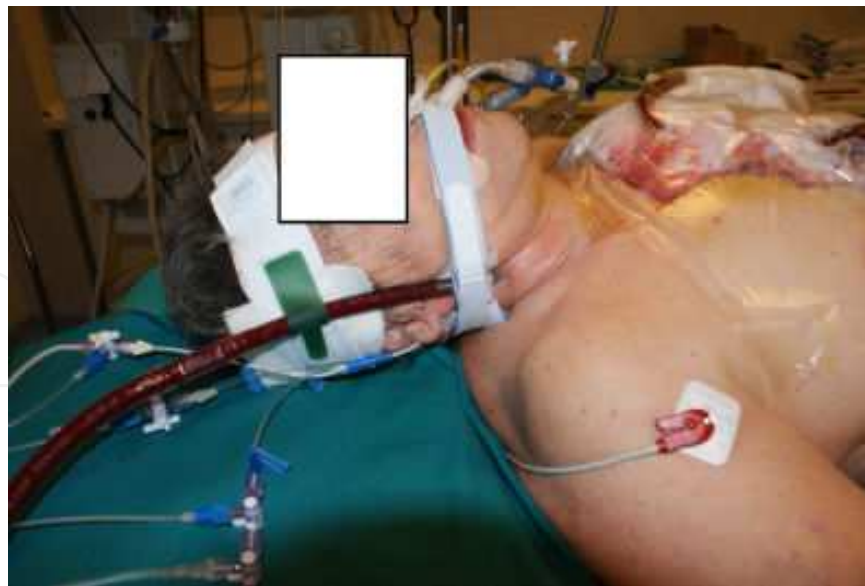

Figure 12. The cannula is inserted in the right jugular vein and advanced up to the main arterial pulmonary trunk.

Other techniques of LV decompression have been described such as the use of Pulse-Cath [31], Insertion of a pigtail inside the LV through the aortic valve [32], use of a transeptal atrial cannula [33].

Red blood cells (RBCs) transfusions are given to achieve a hematocrit of 30-32% and platelets are infused when the platelet count is less than 50,000-60,000/ μ L. Mechanical ventilation is continued throughout the ECMO support with the same management for each patient. Ventilator setting is commonly set at a tidal volume of 8 ml/Kg, 4 breaths/min, positive end expiratory pressure of 10 cm H₂O and a FiO₂ of 0.40-0.60.

Intraortic balloon pump (IABP) [24, 34] is employed with the aim to reduce the afterload, to increase the coronary and cerebral perfusion [35] and to maintain a pulsatile flow.

No attempts to wean off ECMO are usually considered during the first 48 hours. Step by step is the main strategy for weaning off ECMO using transesophageal echocardiography monitoring. This consists to reduce the pump flow at 1.0 L/min/m² for about 40-60 minutes after having obtained an ACT of 180 seconds. In patients who are supported also with IABP, this is set to 1:1 ratio. If systemic pressure, LV contractility, central venous pressure, wedge pressure and SvO₂ had not significant changes without the addition of new inotropes, then heparin is stopped and ECMO is removed at patient's bedside or in operating room within the next few hours.

Transthoracic and transesophageal echocardiography play a very important role in the assessment of LV and RV function and during the delicate phase of weaning from ECMO. Echocardiographic knowledge and facilities are becoming mandatory to start and continue an ECMO program with the aim to improve the outcome. Such echocardiographic parameters, such as transmitral E velocity, E/e' ratio, LV ejection fraction, aortic valve velocity-time integral, tissue Doppler lateral Ea, Sa, and parameters derived from Velocity Vector Imaging,

including lateral systolic velocity, strain, and strain rate, are now considered important data [36] to drive a safe weaning from ECMO and they should be frequently collected in each ECMO patient.

7. Results and discussion

Extracorporeal membrane oxygenation is now considered a validate tool to support very ill patients affected by refractory cardiogenic shock to conventional therapy or cardiac arrest [4, 7, 37-39] and it is a well-established technology to provide a rapid and full circulatory support and to reverse the severe hypoperfusion organ injury. The ECMO system has several advantages: a) it can easily be implanted at patient's bedside, b) it can be initiated through a peripheral percutaneous cannulation, c) it is possible to stabilize the patient in the out-center hospital [6,22] d) it provides a full cardiopulmonary support, e) it allows to take time for diagnosis and further decision f) it is a relative *low-cost* support and g) it is a validate system for a "bridge strategy" [40]. However, the use of ECMO for cardiogenic shock has several limitations. All patients need to be anticoagulated during the ECMO support and complications such as neurological damage [41], infections [42], limb ischemia [43], bleeding and transfusion requiring [44] are frequently reported. However, the use of ECMO in patients with acute coronary syndrome complicated by advanced cardiogenic shock or by cardiac arrest is becoming an increasingly accepted procedure [3, 38, 39, 45].

Although the results about the use of IABP before and during ECMO are not univocal, the use of IABP seems to affect positively the early outcome. Some Authors [23, 24, 34, 46] found that the nonuse of IABP was one of the significant predictors of in-hospital death. On the other side, other Authors [39, 40, 47] could not find significant difference about the use of IABP during ECMO support. According to these different results, we cannot confirm whether the use of IABP has a determinant role in the cardiac function improvement. It can be argued that the use of IABP during ECMO, through the increase of coronary blood flow as reported by Madershahian [35], could favorite the cardiac recovery in ischemic patients.

Higher lactate levels are an index of severe acidosis and tissue hypoxia. The trends of blood lactate levels during the first three days of ECMO are considered as independent predictors of early mortality. Hyperlactatemia (level of blood lactate above 3 mmol/l) during cardiopulmonary bypass is associated with an increased mortality and morbidity, and appears to be related primarily to a state of inadequate perfusion [48]. We have already observed [44] that, when blood lactate level is > 3 mmol/l at 48 hours after ECMO initiation, the predicted probability of mortality is 52%. The earlier ECMO initiation should improve the organ perfusion and reduce dramatically the incidence of multi-organ failure. The persistence of hyperlactacidemia during the first days of ECMO support in nonsurvivors patients, even though the flow of the pump during the same period is similar to that of surviving patients, is likely to be referred to the persistent systemic and splanchnic hypoperfusion due to the extent of atherosclerotic disease or other unknown causes.

Bleeding and transfusion requiring can negatively affect the ECMO course and the early outcome and they are considered important complications during ECMO [23, 24, 47]. It is worthy to point out that lower number of RBCs transfused the number of RBCs units transfused was an independent predictor of in-hospital and late mortality. The need for RBCs transfusion depends not only by the fact that some patients on ECMO have undergone surgery; other factors such as systemic heparinization during ECMO and the use of platelet inhibitors after PTCA can cause bleeding and need for transfusions with increased risk of early mortality. Alternative therapy to conventional heparin anticoagulation therapy, such as bivalirudin or fondaparinux, to reduce the risk of bleeding and for the treatment of heparine induced thrombocytopenya have been recently published [49, 50].

High incidences of central nervous system (CNS) injury meeting the criteria of brain death are reported. These patients usually are withdrawn from ECMO sooner than the rest of the other patients. Brain death is frequent in patients who presented with cardiac arrest and received V-A ECMO implantation during cardiopulmonary resuscitation maneuvers. The incidence of brain death is ranging between 10% and 40% [6, 7, 39, 51]. Thiagarajan et al.[5] analyzing data of 297 patients supported by ECPR and extracted from the Extracorporeal Life Support Organization (ELSO) Registry reported an incidence of 33% of CNS damage and 21% had irreversible hypoxic encephalopathy. Other Authors [3, 4] described a very low survival when cardiopulmonary resuscitation (CPR) time is 60 minutes and a survival approaching to 0% when the CPR was more than 90 minutes.

Left ventricular decompression during ECMO support is an important priority in cases in which the contractile activity of the heart is inadequate to allow the opening of the aortic valve. In such scenario, the risk of clotting formation inside the left cavities is very high and the clots may embolize.

Several techniques to unload the left ventricle such as atrial septostomy [4, 33], direct LV apex cannulation [21], insertion of PulseCath iVAC [31], use of Impella [52, 53], percutaneous insertion of a pigtail [32] or percutaneous pulmonary truck drainage [30] have been described. One of the most followed strategies is to use as soon as the IABP associated with low dose of inotrope (dobutamine 5 mcg/min/Kg) with the aim to reduce the systemic resistance, improve the coronary and cerebral flow and increase the cardiac contractility. Whether the use of IABP is a useful tool to dramatically reduce the afterload mainly in such patients with a peripheral retrograde arterial return [21], and whether the IABP simply increases the coronary blood flow [35], is still debated.

Peripheral percutaneous cannulation represents a big challenging for all ECMO teams. Several peripheral complications such as retroperitoneal hemorrhage, cannula dislocation, cannulation failure, leg ischemia and leg amputation are described [43, 54]. According to early or late vascular complication following peripheral cannulation, Huang et al. [25] suggested measuring the mean pressure of the superficial femoral artery and they indicate to insert a catheter for a distal perfusion if the mean pressure is lower than 50 mmHg. It is extremely important to verify the pulsatility of the anterior and posterior tibial artery by an ultrasound vascular Doppler and to restore the limb perfusion signs of hypoperfusion are observed. In such case an 8-9 F catheter is placed distally to the arterial cannula by means of vascular ultrasound scan.

In female patients or in patients with a BSA less than 1.7 m² or in patients with a severe peripheral vascular disease, the distal catheter is inserted as soon as possible.

Patients with acute coronary syndrome complicated by advanced cardiogenic shock had a higher survival than patients presented with cardiac arrest. Kim et al. [45] reported an early survival of 59.2% in a group of 27 patients and described a long-term survival of 42.9% at 3 years. Bermudez et al. [39] described an early survival of 64% in a group of 33 patients affected by AMI and advanced CS. The 2-year survival was 48%. Sakamoto et al. [38] reported a cumulative early survival of 32.7% in a group of 98 patients affected by refractory CS following AMI in which 36.7% had CA on arrival. Other early survival rate ranging between 33.3% and 56.8% have been reported [37, 55, 56].

8. Future implications

Recently, some Authors have reported early results about the use of IABP in the setting of cardiogenic shock following acute myocardial infarction and in these articles the IABP seems to have not robust data to be still considered as the tool of first choice in the treatment of cardiogenic shock. Seyfart et al [57], in a randomized study of 25 patients with CS, randomly assigned to IABP (n=13) and percutaneous Impella 2.5 (n=12), reported a superior hemodynamic parameter and a significative increasing of cardiac index in patients treated with Impella; the 30 days mortality (46%) was not different in both groups. In a meta-analysis published by Sjauw et al. [58] about the use of IABP in the setting of ST-elevation myocardial infarction complicated by cardiogenic shock, the Authors could not find robust data in favours of the use of IABP. Different complications such as stroke and bleeding and increasing of 30-days mortality in patients managed with IABP were observed. A very recent article by Thiele and al [59], 600 patients affected by CS following acute myocardial infarction, were randomly assigned to IABP therapy (n = 300) or conventional therapy (n = 298). The Authors could not find significant differences in 30-days mortality and in secondary end points or in process-of-care measures, including the time to hemodynamic stabilization, the length of stay in the intensive care unit. No other significant differences with respect to the rates of major bleeding, peripheral ischemic complications and stroke were reported between the two groups. However all these results have received different criticisms due to small number of patients [57] or a high number of patients with a relatively low mortality risk if treated with conventional therapy [59] and therefore these report could be influenced from some confounding factors.

According to these recent results, in the next close future, it can be argued that the use of ECMO could be more encouraged and anticipated in such patient who are in the setting of “pre-shock”, in order to reduce the complications linked to the low cardiac output and to reduce the rate of very late application of ECMO. The current systems are safe and simple to apply, due to the advance in miniaturized centrifugal pumps and circuits, to the increased biocompatibility (heparin-coated system), but they are still associated with major complications in a relatively high percentage. Big efforts are still needed to improve the current techniques and devices.

9. Conclusion

The use of V-A ECMO in patients with acute myocardial infarction complicated by refractory cardiogenic shock and or cardiac arrest is widely increasing due to the improving in the early e mid-term results. The relatively low early survival rate in these very illness patients supported by ECMO should be considered an encouraging data, because in these patients the mortality without the ECMO support is dramatically higher. Bleeding, infections and CNS irreversible damage remain still serious complications and efforts to reduce or prevent them are necessary and strongly recommended to improve the outcome.

Acknowledgements

The Authors wish to thank Dr Giorgia Pavan for her editing and English language support, all the cardiac surgeons and the cardiologist team, the anesthesiologist medical staff, the perfusionist service an the nurse staff of the operating room and the intensive care unit.

Author details

Francesco Formica and Giovanni Paolini

Cardiac Surgery Unit, San Gerardo Hospital, Monza, Department of Surgical Science and Interdisciplinary Medicine, University on Milano-Bicocca, Italy

References

- [1] Goldberg RJ, Spencer FA, Gore JM, Lessard D, Yarzebski J. Thirty-year trends (1975 to 2005) in the magnitude of, management of, and hospital death rates associated with cardiogenic shock in patients with acute myocardial infarction: a population-based perspective. *Circulation* 2009;119:1211-9.
- [2] Brady WJ, Gurka KK, Mehring B, Peberdy MA, O'Connor RE, American Heart Association's Get with the Guidelines (formerly NRCPI. In-hospital cardiac arrest: impact of monitoring and witnessed event on patient survival and neurologic status at hospital discharge. *Resuscitation* 2011;82:845-52.
- [3] Chen YS, Chao A, Yu HY, Ko WJ, Wu IH, Chen RJ et al. Analysis and results of prolonged resuscitation in cardiac arrest patients rescued by extracorporeal membrane oxygenation. *J Am Coll Cardiol* 2003;41:197-203.

- [4] Massetti M, Tasle M, Le Page O, Deredec R, Babatasi G, Buklas D et al. Back from irreversibility: extracorporeal life support for prolonged cardiac arrest. *Ann Thorac Surg* 2005;79:178-83; discussion 83-4.
- [5] Thiagarajan RR, Brogan TV, Scheurer MA, Laussen PC, Rycus PT, Bratton SL. Extracorporeal membrane oxygenation to support cardiopulmonary resuscitation in adults. *Ann Thorac Surg* 2009;87:778-85.
- [6] Beurtheret S, Mordant P, Paoletti X, Marijon E, Celermajer DS, Léger P et al. Emergency circulatory support in refractory cardiogenic shock patients in remote institutions: a pilot study (the cardiac-RESCUE program). *Eur Heart J* 2012.
- [7] Avalli L, Maggioni E, Formica F, Redaelli G, Migliari M, Scanziani M et al. Favourable survival of in-hospital compared to out-of-hospital refractory cardiac arrest patients treated with extracorporeal membrane oxygenation: an Italian tertiary care centre experience. *Resuscitation* 2012;83:579-83.
- [8] Sasson C, Forman J, Krass D, Macy M, Kellermann AL, McNally BF. A qualitative study to identify barriers to local implementation of prehospital termination of resuscitation protocols. *Circ Cardiovasc Qual Outcomes* 2009;2:361-8.
- [9] Cove ME, MacLaren G. Clinical review: mechanical circulatory support for cardiogenic shock complicating acute myocardial infarction. *Crit Care* 2010;14:235.
- [10] Thiele H, Allam B, Chatellier G, Schuler G, Lafont A. Shock in acute myocardial infarction: the Cape Horn for trials? *Eur Heart J* 2010;31:1828-35.
- [11] Kayser RG, Ornato JP, Peberdy MA, Resuscitation AHA/NRCC. Cardiac arrest in the Emergency Department: a report from the National Registry of Cardiopulmonary Resuscitation. *Resuscitation* 2008;78:151-60.
- [12] Peberdy MA, Kaye W, Ornato JP, Larkin GL, Nadkarni V, Mancini ME et al. Cardiopulmonary resuscitation of adults in the hospital: a report of 14720 cardiac arrests from the National Registry of Cardiopulmonary Resuscitation. *Resuscitation* 2003;58:297-308.
- [13] ECC Committee SbaTFotAHA. 2005 American Heart Association Guidelines for Cardiopulmonary Resuscitation and Emergency Cardiovascular Care. *Circulation* 2005;112:IV1-203.
- [14] Le Guen M, Nicolas-Robin A, Carreira S, Raux M, Leprince P, Riou B et al. Extracorporeal life support following out-of-hospital refractory cardiac arrest. *Crit Care* 2011;15:R29.
- [15] Rosamond W, Flegal K, Furie K, Go A, Greenlund K, Haase N et al. Heart disease and stroke statistics--2008 update: a report from the American Heart Association Statistics Committee and Stroke Statistics Subcommittee. *Circulation* 2008;117:e25-146.
- [16] Dunne RB, Compton S, Zalenski RJ, Swor R, Welch R, Bock BF. Outcomes from out-of-hospital cardiac arrest in Detroit. *Resuscitation* 2007;72:59-65.

- [17] Grmec S, Kupnik D. Does the Mainz Emergency Evaluation Scoring (MEES) in combination with capnometry (MEESc) help in the prognosis of outcome from cardiopulmonary resuscitation in a prehospital setting? *Resuscitation* 2003;58:89-96.
- [18] Morrison LJ, Verbeek PR, Vermeulen MJ, Kiss A, Allan KS, Nesbitt L et al. Derivation and evaluation of a termination of resuscitation clinical prediction rule for advanced life support providers. *Resuscitation* 2007;74:266-75.
- [19] Beckmann A, Benk C, Beyersdorf F, Haimerl G, Merkle F, Mestres C et al. Position article for the use of extracorporeal life support in adult patients. *Eur J Cardiothorac Surg* 2011;40:676-80.
- [20] Marasco SF, Lukas G, McDonald M, McMillan J, Ihle B. Review of ECMO (extra corporeal membrane oxygenation) support in critically ill adult patients. *Heart Lung Circ* 2008;17 Suppl 4:S41-7.
- [21] Russo CF, Cannata A, Lanfranconi M, Bruschi G, Milazzo F, Paino R et al. Veno-arterial extracorporeal membrane oxygenation using Levitronix centrifugal pump as bridge to decision for refractory cardiogenic shock. *J Thorac Cardiovasc Surg* 2010;140:1416-21.
- [22] Formica F, Avalli L, Redaelli G, Paolini G. Interhospital stabilization of adult patients with refractory cardiogenic shock by veno-arterial extracorporeal membrane oxygenation. *Int J Cardiol* 2011;147:164-5.
- [23] Bakhtiary F, Keller H, Dogan S, Dzemali O, Oezaslan F, Meininger D et al. Venoarterial extracorporeal membrane oxygenation for treatment of cardiogenic shock: clinical experiences in 45 adult patients. *J Thorac Cardiovasc Surg* 2008;135:382-8.
- [24] Rastan AJ, Dege A, Mohr M, Doll N, Falk V, Walther T et al. Early and late outcomes of 517 consecutive adult patients treated with extracorporeal membrane oxygenation for refractory postcardiotomy cardiogenic shock. *J Thorac Cardiovasc Surg* 2010;139:302-11, 11.e1.
- [25] Huang SC, Yu HY, Ko WJ, Chen YS. Pressure criterion for placement of distal perfusion catheter to prevent limb ischemia during adult extracorporeal life support. *J Thorac Cardiovasc Surg* 2004;128:776-7.
- [26] Javidfar J, Brodie D, Costa J, Miller J, Jurrado J, Lavelle M et al. Subclavian artery cannulation for venoarterial extracorporeal membrane oxygenation. *ASAIO J* 2012;58:494-8.
- [27] Kolobow T, Bowman RL. Construction and evaluation of an alveolar membrane artificial heart-lung. *Trans Am Soc Artif Intern Organs* 1963;9:238-43.
- [28] Bartlett RH, Gazzaniga AB, Jefferies MR, Huxtable RF, Haiduc NJ, Fong SW. Extracorporeal membrane oxygenation (ECMO) cardiopulmonary support in infancy. *Trans Am Soc Artif Intern Organs* 1976;22:80-93.
- [29] Formica F, Avalli L, Martino A, Maggioni E, Muratore M, Ferro O et al. Extracorporeal membrane oxygenation with a poly-methylpentene oxygenator (Quadrox D). The

experience of a single Italian centre in adult patients with refractory cardiogenic shock. *ASAIO J* 2008;54:89-94.

- [30] Avalli L, Maggioni E, Sangalli F, Favini G, Formica F, Fumagalli R. Percutaneous left-heart decompression during extracorporeal membrane oxygenation: an alternative to surgical and transeptal venting in adult patients. *ASAIO J* 2011;57:38-40.
- [31] Anastasiadis K, Chalvatzoulis O, Antonitsis P, Tossios P, Papakonstantinou C. Left ventricular decompression during peripheral extracorporeal membrane oxygenation support with the use of the novel iVAC pulsatile paracorporeal assist device. *Ann Thorac Surg* 2011;92:2257-9.
- [32] Barbone A, Malvindi PG, Ferrara P, Tarelli G. Left ventricle unloading by percutaneous pigtail during extracorporeal membrane oxygenation. *Interact Cardiovasc Thorac Surg* 2011;13:293-5.
- [33] Aiyagari RM, Rocchini AP, Remenapp RT, Graziano JN. Decompression of the left atrium during extracorporeal membrane oxygenation using a transseptal cannula incorporated into the circuit. *Crit Care Med* 2006;34:2603-6.
- [34] Doll N, Kiaii B, Borger M, Bucerius J, Krämer K, Schmitt DV et al. Five-year results of 219 consecutive patients treated with extracorporeal membrane oxygenation for refractory postoperative cardiogenic shock. *Ann Thorac Surg* 2004;77:151-7; discussion 57.
- [35] Madershahian N, Liakopoulos OJ, Wippermann J, Salehi-Gilani S, Wittwer T, Choi YH et al. The impact of intraaortic balloon counterpulsation on bypass graft flow in patients with peripheral ECMO. *J Card Surg* 2009;24:265-8.
- [36] [Firstenberg, 2012, ECMO and ECHO: the evolving role of quantitative echocardiography in the management of patients requiring extracorporeal membrane oxygenation
- [37] Chen JS, Ko WJ, Yu HY, Lai LP, Huang SC, Chi NH et al. Analysis of the outcome for patients experiencing myocardial infarction and cardiopulmonary resuscitation refractory to conventional therapies necessitating extracorporeal life support rescue. *Crit Care Med* 2006;34:950-7.
- [38] Sakamoto S, Taniguchi N, Nakajima S, Takahashi A. Extracorporeal life support for cardiogenic shock or cardiac arrest due to acute coronary syndrome. *Ann Thorac Surg* 2012;94:1-7.
- [39] Bermudez CA, Rocha RV, Toyoda Y, Zaldonis D, Sappington PL, Mulukutla S et al. Extracorporeal membrane oxygenation for advanced refractory shock in acute and chronic cardiomyopathy. *Ann Thorac Surg* 2011;92:2125-31.
- [40] Hoefer D, Ruttman E, Poelzl G, Kilo J, Hoermann C, Margreiter R et al. Outcome evaluation of the bridge-to-bridge concept in patients with cardiogenic shock. *Ann Thorac Surg* 2006;82:28-33.

- [41] Mateen FJ, Muralidharan R, Shinohara RT, Parisi JE, Schears GJ, Wijdicks EF. Neurological injury in adults treated with extracorporeal membrane oxygenation. *Arch Neurol* 2011;68:1543-9.
- [42] Pieri M, Greco T, De Bonis M, Maj G, Fumagalli L, Zangrillo A et al. Diagnosis of infection in patients undergoing extracorporeal membrane oxygenation: a case-control study. *J Thorac Cardiovasc Surg* 2012;143:1411-6.
- [43] Bisdas T, Beutel G, Warnecke G, Hoepfer MM, Kuehn C, Haverich A et al. Vascular complications in patients undergoing femoral cannulation for extracorporeal membrane oxygenation support. *Ann Thorac Surg* 2011;92:626-31.
- [44] Formica F, Avalli L, Colagrande L, Ferro O, Greco G, Maggioni E et al. Extracorporeal membrane oxygenation to support adult patients with cardiac failure: predictive factors of 30-day mortality. *Interact Cardiovasc Thorac Surg* 2010;10:721-6.
- [45] Kim H, Lim SH, Hong J, Hong YS, Lee CJ, Jung JH et al. Efficacy of veno-arterial extracorporeal membrane oxygenation in acute myocardial infarction with cardiogenic shock. *Resuscitation* 2012;83:971-5.
- [46] Smedira NG, Moazami N, Golding CM, McCarthy PM, Apperson-Hansen C, Blackstone EH et al. Clinical experience with 202 adults receiving extracorporeal membrane oxygenation for cardiac failure: survival at five years. *J Thorac Cardiovasc Surg* 2001;122:92-102.
- [47] Wang J, Han J, Jia Y, Zeng W, Shi J, Hou X et al. Early and intermediate results of rescue extracorporeal membrane oxygenation in adult cardiogenic shock. *Ann Thorac Surg* 2009;88:1897-903.
- [48] Ranucci M, De Toffol B, Isgrò G, Romitti F, Conti D, Vicentini M. Hyperlactatemia during cardiopulmonary bypass: determinants and impact on postoperative outcome. *Crit Care* 2006;10:R167.
- [49] Pappalardo F, Maj G, Scandroglio A, Sampietro F, Zangrillo A, Koster A. Bioline heparin-coated ECMO with bivalirudin anticoagulation in a patient with acute heparin-induced thrombocytopenia: the immune reaction appeared to continue unabated. *Perfusion* 2009;24:135-7.
- [50] Ranucci M, Ballotta A, Kandil H, Isgrò G, Carlucci C, Baryshnikova E et al. Bivalirudin-based versus conventional heparin anticoagulation for postcardiotomy extracorporeal membrane oxygenation. *Crit Care* 2011;15:R275.
- [51] Jaski BE, Ortiz B, Alla KR, Smith SC, Glaser D, Walsh C et al. A 20-year experience with urgent percutaneous cardiopulmonary bypass for salvage of potential survivors of refractory cardiovascular collapse. *J Thorac Cardiovasc Surg* 2010;139:753-7.e1-2.
- [52] Beurtheret S, Mordant P, Pavie A, Leprince P. Impella and extracorporeal membrane oxygenation: a demanding combination. *ASAIO J* 2012;58:291-3.

- [53] Koeckert MS, Jorde UP, Naka Y, Moses JW, Takayama H. Impella LP 2.5 for left ventricular unloading during venoarterial extracorporeal membrane oxygenation support. *J Card Surg* 2011;26:666-8.
- [54] Zimpfer D, Heinisch B, Czerny M, Hoelzenbein T, Taghavi S, Wolner E et al. Late vascular complications after extracorporeal membrane oxygenation support. *Ann Thorac Surg* 2006;81:892-5.
- [55] Combes A, Leprince P, Luyt CE, Bonnet N, Trouillet JL, Léger P et al. Outcomes and long-term quality-of-life of patients supported by extracorporeal membrane oxygenation for refractory cardiogenic shock. *Crit Care Med* 2008;36:1404-11.
- [56] Aissaoui N, Luyt CE, Leprince P, Trouillet JL, Léger P, Pavie A et al. Predictors of successful extracorporeal membrane oxygenation (ECMO) weaning after assistance for refractory cardiogenic shock. *Intensive Care Med* 2011;37:1738-45.
- [57] Seyfarth M, Sibbing D, Bauer I, Fröhlich G, Bott-Flu[®]gel L, Byrne R, et al. A randomized clinical trial to evaluate the safety and efficacy of a percutaneous left ventricular assist device versus intra-aortic balloon pumping for treatment of cardiogenic shock caused by myocardial infarction. *J Am Coll Cardiol* 2008;52:1584-8
- [58] Sjaauw KD, Engstrom AM, Vis MM, van der Schaaf RJ, Baan J, Koch, et al. A systematic review and meta-analysis of intra-aortic balloon pump therapy in ST-elevation myocardial infarction: should we change the guidelines? *Eu Heart Journal* 2009;30:459-468
- [59] Thiele H, Zeymer U, Neumann F-J, Ferenc M, Olbrich H-G, M.D., Hausleiter J, et al. Intraaortic Balloon Support for Myocardial Infarction with Cardiogenic Shock. *N Engl J Med* 2012;367:1287-96.