

# We are IntechOpen, the world's leading publisher of Open Access books Built by scientists, for scientists

6,900

Open access books available

186,000

International authors and editors

200M

Downloads

Our authors are among the

154

Countries delivered to

TOP 1%

most cited scientists

12.2%

Contributors from top 500 universities



WEB OF SCIENCE™

Selection of our books indexed in the Book Citation Index  
in Web of Science™ Core Collection (BKCI)

Interested in publishing with us?  
Contact [book.department@intechopen.com](mailto:book.department@intechopen.com)

Numbers displayed above are based on latest data collected.  
For more information visit [www.intechopen.com](http://www.intechopen.com)



---

## **Office – Based Facial Cosmetic Procedures**

---

Farzin Sarkarat, Behnam Bohluli and  
Roozbeh Kahali

Additional information is available at the end of the chapter

<http://dx.doi.org/10.5772/53882>

---

### **1. Introduction**

The human face has an important role in a person's identity, communication and self-confidence. Thus, any disfigurement or deformity of the face can cause both functional and social isolation. Facial cosmetic surgery seeks to rejuvenate and restore facial volume loss, static and dynamic rhytids and facial form from the effects of aging, facial muscle movements and gravity. The sudden explosion in recent years of non-surgical rejuvenative techniques is patient-driven. Addressing facial rhytids and undesirable skin changes has required an in-patient stay and a significant period of recovery time. But today's cosmetic patients increasingly desire office-based procedures with minimal recovery time. They are looking for maximal improvement with minimal risks, and cost that will provide them some form of facial rejuvenation and at the same time allow them to get back to work or their social lives as soon as possible. Minimal recovery procedures, offer patients significant esthetic options with minimal or no recovery time and minimal risks. These procedures including the use of injectable fillers, fat transfer, botulinum toxin injection and facial resurfacing techniques are among the most popular and widely performed office procedures. In this chapter, we discuss office-based facial cosmetic procedures, their indications and contraindications, benefits and risks and procedural methods.

### **2. Injectable fillers**

Soft tissue augmentation with the various soft tissue filler materials is particularly performed on patients with minimal to moderate signs of facial aging and because of its non-surgical procedure and minimal downtime, is very popular.

## 2.1. Background

Various materials for facial rejuvenation, such as wax, silicone and animal products have been used. In 1893, Neuber used autologous fat transfer for soft tissue augmentation [1]. Paraffin and vaseline were injected for soft tissue augmentation, just a few years later [2]. In 1940 liquid silicone was injected for cosmesis [3,4]. Bovine collagen injection became popular in 1980 [1].

## 2.2. Anatomy of the skin

Human skin has several layers. The most superficial layer which acts as a barrier is the epidermis. The deeper layer to epidermis is the dermis and it consists of the papillary dermis and the reticular dermis. The papillary dermis contains a web of primarily type 3 collagen that reaches the epidermis. The reticular dermis is primarily made of type 1 collagen fibers [5]. Elastic fibers are very low and they are responsible for skin resiliency. Ground substance is also a part of dermis and is composed of hyaluronic acids, glycosaminoglycans and proteins and it fills the spaces between other components of dermis [6]. Sub cutis which is seen under the dermis, consists of fat which is responsible for skin volume. The amount of skin collagen decreases with aging, which affects primarily type 1 collagen fibers [5]. In addition to aging, exposure to tobacco smoke and excessive sun can cause a decrease in collagen fiber contents by increasing collagenase levels responsible for wrinkle formation by loss of skin elasticity and turgor [7].

## 2.3. Filler types

Injectable filler products are syringes containing filler agents. Their needle size is proportional to the filler viscosity; the higher the viscosity, the larger the needle lumen. The smallest appropriate needle size is used to minimize injection pain [8]. High viscous agents are generally used for deeper defects and lower viscous fillers are ideal for superficial defects [1]. The depth of the injection is also important. For superficial defects, the needle tip enters the skin very superficially, but for moderate defects, the level of entrance is mid to deep dermis, and for deeper defects, the needle tip enters at the level of dermal-sub cutis junction. After injection, gentle massage is required for evenness of the injected material. An ideal filler agent must meet criteria such as biocompatibility, and be non-antigenic, non-toxic, easy to handle, long-lasting, inexpensive and reversible [8,9]. Generally filler agents are categorized into three groups, according to their duration: first, non-permanent fillers, which are short-lasting fillers and they need repeated injections after their resorption. Second, semi-permanent fillers, which last longer but they will undergo some resorption as well. Third, the permanent fillers which may be long lasting with only a single injection.

### 2.3.1. Non-permanent fillers

#### 2.3.1.1. Collagen replacements

These agents are purified bovine or human collagen and before the advent of Hyaluronic acid filler, was the 'gold standard' filler agents for many years. Bovine collagen was the first

product approved by FDA for soft tissue augmentation [8,10]. Because the possibility of allergy reaction, allergy testing was needed. It has been suggested to do the second skin test a month later before augmentation [11,12]. Several collagen replacements have been introduced: Zyderm, Zyplast, Cosmoderm and Cosmoplast (INAMED Aesthetics, Irvine, CA). Zyderm and Zyplast are bovine collagen materials. Zyderm got FDA approval in 1981. Zyplast was longer lasting and got FDA approval in 1985. [7]. All of these materials are eventually degraded by inflammatory responses in 4- 5 months [8]. In 2003, Cosmoderm and Cosmoplast were introduced into the market, which are human-derived collagen products. They are derived from cultures of human fibroblast cells [8,13,14]. Because these products are human-derived, there is no need for allergy testing and they are easier to use but their longevity are less than bovine-collagen products [8].

#### 2.3.1.2. *Hyaluronic acid*

Hyaluronic acid is a part of skin dermis and provides a scaffold for collagen development. Aging decreases the amount of hyaluronic acid and this leads to decreasing of skin hydration and elasticity and formation of rhytids and increased folds [15,16]. It increases the skin hydration and turgor by binding to water molecules and helps to maintain the skin volume and elasticity. It has a uniform structure among various species and this makes it a suitable filler for injection, because there is no need for allergy testing. Its natural molecule is unstable and will degrade in two days after injection [15]. Companies have cross-linked natural hyaluronic acids to increase longevity and cross-linked materials are called hylans [8,17,18]. Hylans are highly viscous materials but their viscosity decreases by applying shear forces to them, in this way their injection is easier [19,20]. Hyaluronic acid fillers are injected intradermally, and if the result of injection is not desirable, hyaluronidase can be injected to degrade the filler. Hyaluronic acid products are not combined with anesthetic agents, meaning anesthetic local block injections may be necessary [19]. During hyaluronic acid injections, the defect must be treated completely and no over-correction should be performed. The longevity ranges between 6 to 9 months [17]. The first hyaluronic acid product introduced into the market was Restylane (Medicis Aesthetics, Inc., Scottsdale, Arizona) and received FDA approval in 2003 [9,11]. It is a partially cross-linked hyaluronic acid and binds water strongly and is derived from *Streptococcus* cultures [17] and is ideal for mid to deep dermal injections [9,21]. The high degree of cross-linking is responsible for maintaining its bulk and its stability which makes it last up to 4 to 6 months depending on the injection site [21]. In contrast to collagen materials which are simply degraded and lose volume, when hyaluronic acids are more degraded, more water molecules are drawn into the filler and this leads to maintaining the volume much longer than collagen fillers [11,19,20]. Because Restylane is a human-derived product and there is no need for allergy testing; longevity lasting up to 8 months has been reported [21,22]. There are two other formulations of Restylane. Restylane Fine Line has smaller particle size and has lower viscosity which means it is ideal for more superficial dermis injections. Restylane Perlane has larger particle size than Restylane and has higher viscosity and longer-lasting results and is ideal for deep dermal injections [9,17]. Hylaform (Inamed, Santa Barbara, Calif.) and Hylaform Plus were introduced to market and

were approved by the FDA in 2004 [9]. Hylaform is derived from rooster combs [20] and has smaller amount of hyaluronic acid and higher degree of cross-linking in comparison to Restylane, which makes its longevity slightly shorter [23]. It also has a small amount of avian protein that may lead to allergic reaction. It is used for mid dermis injections. Hylaform Plus has larger particle size than Hylaform, which makes it ideal for deep dermis injections [9,19]. Captique (Allergan, Santa Barbara, Calif.) introduced in 2004 and received FDA approval, is a non-animal-derived hyaluronic acid produced by bacterial fermentation. It is a cross-linked product and is used for mid to deep dermis injections [9]. Juve'derm (Allergan, Inc., Irvine, Calif.) received FDA approval in 2006. It is a bacterially-derived hyaluronic acid homogenous gel rather than a particle suspension like other hyaluronic acid products, and this makes it more biocompatible. It has three different formulations. Juve'derm 24 HV and Juve'derm 30 HV are highly cross-linked and more highly cross-linked products respectively, which are used for deeper dermis injections. Juve'derm 30 is used for superficial dermal injections [9,24].

#### 2.3.1.3. *Autogenous fat*

First, Neuber used autologous fat for soft-tissue augmentation in 1893. After a period of decline until 1970s, with the advent of liposuction, autologous fat augmentation again became popular [8,25]. The main advantage of autologous fat augmentation is that it is autologous, and there is no risk of allergy reactions. The most important concern about autologous fat augmentation is its unpredictable results and longevity [25,26]. In contrast to other fillers, it requires a harvesting procedure, which increases the procedure time and cost [19].

#### 2.3.1.4. *Cymetra*

Cymetra (LifeCell Corporation, Branchburg, NJ) is a micronized form of acellular dermal tissue product from human donors called alloderm. It consists of collagen, proteoglycans, and all components of the dermal tissue with the exception of cells. This product forms a web for aggregation of fibroblasts to promote collagen formation. Cymetra is a packaged powder which must be mixed with saline prior to injection. It lasts approximately 3 to 6 months [12].

### 2.3.2. *Semi-permanent fillers*

#### 2.3.2.1. *Sculptra*

Sculptra (Dermik Laboratories, Berwyn, PA) is a synthetic poly-L-lactic acid. It is packaged as a powder and must be mixed with saline at least 2 hours prior to injection. It is injected into subcutaneous tissues and is good for correction of deep and large defects. The filler acts as a web for fibroblast proliferation and collagen production [27]. Over-correction of the defect should not be performed and because of its unpredictability, several touch-up sessions 4 to 6 weeks apart may be needed. Sculptra lasts about 18 to 24 months according to the injection site [19].

#### 2.3.2.2. *Hydroxyapatite fillers*

Radiesse (BioForm Medical, San Mateo, CA) is an FDA approved filler product containing calcium hydroxyapatite spheres. It is a viscous product and is used for deep dermis and subdermal injections [28]. Calcium hydroxyapatite is the mineral component of bones and it promotes no allergy reactions. These spheres maintain volume augmentation by promoting collagen production. So there are two mechanisms for maintaining long-term volume. First is the carrier itself, which degrades after 6 to 8 weeks. However during its degradation, collagen ingrowth occurs at the injection site and maintains the volume [20]. It is seen that hydroxyapatite particles will become encapsulated by a localized fibroblastic reaction, which is helpful in limiting particle migrations and maintaining volume [28]. The injected filler is palpable for about 2 to 3 months until the particles degrade and collagen appears in the site [19]. Radiance FN consists of hydroxyapatite microspheres in a soluble gel vehicle [29]. It does not have FDA approval for cosmetic purposes. This product lasts long, therefore no over-correction should be done [11].

#### 2.3.3. *Permanent fillers*

##### 2.3.3.1. *ArteFill*

ArteFill (Artes Medical, San Diego, CA) is an FDA approved product composed of 20% polymethylmethacrylate microspheres and 80% bovine collagen as a delivery agent [30]. Because of bovine collagen, allergy testing is needed. The delivery agent degrades after about 4 months, but microspheres are permanent and become encapsulated by inflammatory reactions, which are responsible for 50 to 70 percent of permanent correction and volume maintenance. Overcorrection should not be performed and the patient may need several touch-up injections spaced 3 to 4 months apart for optimal results [8]. Three to four days following injection, the microspheres are prone to migration and the patient should avoid facial expressions [20].

##### 2.3.3.2. *Injectable silicone*

Silicone refers to polymers of silicon. Small volumes of Silicone are injected in a grid-like fashion spaced at 1 to 3 mm into the deep dermis called micro-droplet technique. Several injections spaced four weeks apart are required for gaining final results. Encapsulation occurs around particles and is permanent. [31]. Silikon (Alcon Laboratories, Fort Worth, TX) is an injectable silicone for facial augmentation. AdatoSil (Bausch & Lomb, Rochester, NY) is another injectable silicone which is more viscous than Silikon.

## 2.4. **Treatment considerations**

When injecting fillers, some considerations should be kept in mind. Before injection a combination of topical, local and regional anesthesia can be administered. Topical anesthetic creams must be applied 20 minutes before the injection of local anesthesia. Usually lidocaine 1% with 1:200,000 epinephrine is used. Filler injection around thin skin of eyes and cheeks



with fine wrinkles is contraindicated; instead resurfacing or chemical peel is needed. Blindness has been reported with the peri-orbital injection of Zyplast and fat due to intravascular injection [32-34], therefore the injection should be very superficial, and without extreme pressure. Allergic reactions occur more in patients with lighter skin. Intramuscular injection of all fillers is contraindicated because the filler dislocation due to muscle movements. Implant dislocation can occur during the first three days after injection, therefore early facial muscle movement should be kept at a minimum. During filler injections the gray of the needle should never be visible through the skin, because in this case the needle is very superficial and the filler is injected intradermally. Acne or surgical/traumatic scars, which are not mobile like wrinkles are the only indications for superficial injections. It has been suggested to cover the lower face during cold weather and exposure to extreme cold. For patients with dark shadowed eyelids, it has been suggested to augment the orbital rim epiperiosteally by scratching the needle tip on the bone. Care has to be taken not to inject into the orbicularis muscle [35]. Regular follow-up is necessary after filler injection. The patient should be visited 1 to 2 weeks after injection for evaluation and touch-up corrective injections if needed in cases of underfill or asymmetry. Touch-up injections also may be needed 1 to 3 months after injection, when the permanent filler has assumed its final volume and shape [9,11,35].

## 2.5. Injection techniques

There are 4 commonly reported techniques for filler injection: serial puncture, threading, fanning and crosshatching.

### 2.5.1. Serial Puncture

Serial puncture is often used for the glabella injection, philtral column enhancement, lip augmentation, nasolabial folds and fine wrinkles. In this technique multiple injections are made serially along the area. First, the skin is held taut and pulled slightly away and out from the injection area. Then the needle is inserted up to the appropriate depth. The filler agent is then injected in a small amount. Following that, the needle is removed and reinserted along a particular defect and a new injection is made. The injection sites should be close together, so that the injected filler agents merge into each other [1, 9, 11].

### 2.5.2. Linear threading

Linear threading is commonly used for lip augmentation, nasolabial fold injection and vermilio-cutaneous border augmentation. In this technique, first, the skin is held taut. Then the full length of the needle is inserted into the defect to create a channel. Then the filler agent is delivered slowly and continuously while withdrawing the needle [8,9,11].

### 2.5.3. Fanning

Fanning injection technique is ideal for large area augmentation such as deep malar injection. In this technique several linear threading injections are done in a radial fashion by just one entrance point for the needle. After full length insertion of the needle and continuous

injection of the filler while needle withdrawal, just immediately before the needle is withdrawn completely, the direction of the needle is changed in a radial fashion, and new lines are injected the same way. The fanning pattern of lines should be evenly spaced so that the contour is evenly filled and shaped [9,17].

#### *2.5.4. Cross-hatching*

Cross-hatching technique is generally used to fill large defect areas, especially oral commissures and perioral area. Cross-hatching involves a series of linear threading injections in a perpendicular fashion to each other. The pattern of lines should be evenly spaced so that the contour is evenly filled and shaped [9,17].

### **2.6. Indications**

#### *2.6.1. Treating the lips*

The lips are the most common areas requested for tissue augmentation. Younger patients who have enough lip volume usually only need vermilio-cutaneous border enhancement. In older patients and people with thin lips, volume enhancement is also indicated. Injecting the lips can provide significant discomfort and usually local anesthesia is needed. Bilateral infra-orbital blocks are used during upper lip injection and bilateral mental blocks are performed for the lower lips [36]. Generally, the white roll of Cupid's bow is injected in the intradermal or submucosal plane or both. Linear threading and/or serial puncture techniques are used starting at the oral commissures and proceeding in a lateral to medial direction. By using the non-injecting hand to pinch the lip with the thumb and forefinger, the surgeon can contain the filler to the desired space laterally along the lip. The needle is inserted at the mucocutaneous junction or slightly on the mucosal side and inserted all the way to the hub. Care should be taken to avoid superficial injection in this region, as a light blue hue may become visible. As the needle is withdrawn, the filler is evenly injected into this potential space. Finally, the descending legs of the central M configuration are injected to make sharp angles in the central upper lip. The white roll is also created in the lower lip but is more curvilinear than in the upper lip. The lower lip is injected in a similar manner but without sharp angles. The filler is injected in the potential space just beneath the mucosa across the entire lower lip. Marionette lines are a key element in overall lip enhancement; otherwise, results are destined to be disappointing to both the patient and the physician [9,11]. Some patients may desire more vermilion volume and want bigger lips as opposed to simply more-defined lips. Instead of injecting at the vermilion/cutaneous junction, the needle is inserted several millimeters below the cutaneous margin and well into the vermilion. Depending on the desired area to be augmented, the needle is sometimes positioned at the wet/dry line. Again, the needle is inserted to the hub and slowly withdrawn while continuous, steady injection is performed. In this area, the goal is to spread a thin, flat layer to plump the vermilion. The needle can also be placed deeper into the lip when greater volume is required [11]. To enhance the philtral columns, the needle is inserted at the vermilion/cutaneous junction in the intradermal plane and directed all the way to the base of the ala. The



skin is then pinched with the non-injecting hand to create a triangle. Less filler is injected near the alar base, with more filler injected toward the vermilion border. By pinching the skin with the non-injecting hand, the injected filler can be formed into the specific shape. Intravascular injection could cause lip necrosis. Notice that the artery lies in the posterior one third of the lip at about the level of the incisal edge of the anterior teeth. This level also corresponds with the vermilion/cutaneous junction on the facial surface of the lip [11,37].

#### 2.6.2. *Injecting oral commissures*

Aging causes oral commissures to become depressed and also causes a down-turned smile. Oral commissures are where multiple tissue planes and muscles converge together and this makes it difficult to augment; usually a significant amount of filler material is necessary [11]. This area is augmented using the cross-hatching technique. In this area, filler must be injected into multiple layers. The filler must be injected deep to create a base, then the rest of the filler is injected on top of it interdermally [9].

#### 2.6.3. *Injecting perioral rhytids*

Perioral rhytids which are also called lipstick lines, are usually treated by just white roll and lip augmentations. By doing this, most of the rhytids are faded because of stretching of the skin. If this does not solve the problem, rhytids are treated individually by injecting fine particle-sized filler agents intradermally using linear threading technique. The needle is inserted into the rhytide at the vermilio-cutaneous junction, and the filler is injected while withdrawing the needle [11].

#### 2.6.4. *Injecting the nasolabial folds*

The nasolabial fold is a normal and natural anatomic structure present even in young people. Aging causes the nasolabial fold to deepen and the treatment goal is to improve it not to make it disappear. This area is treated by injecting filler (Figure 1-A) using serial puncture or linear threading technique or the combination of both. The patient should always be seated upright and the filler is injected into the mid to deep dermis beginning inferiorly and moving superiorly. It is important to be careful not to inject the filler material into the lateral side of the nasolabial fold, which makes the fold look deeper. Using linear threading technique, the needle is inserted into the fold and the filler is injected while withdrawing the needle. For serial puncture technique augmentation, a small amount of filler is injected along the nasolabial fold [9,11].

#### 2.6.5. *Glabellar folds*

The mobility of the muscles of this area can decrease the longevity of the filler; therefore it is recommended to treat this area with a combination of filler augmentation and botulinum toxin injections; this can increase the longevity as long as nine months. This area is usually treated by injecting the filler using serial puncture technique into the mid-dermis of the wide and deep rhytids, and injecting fine-sized particle filler using linear threading techni-

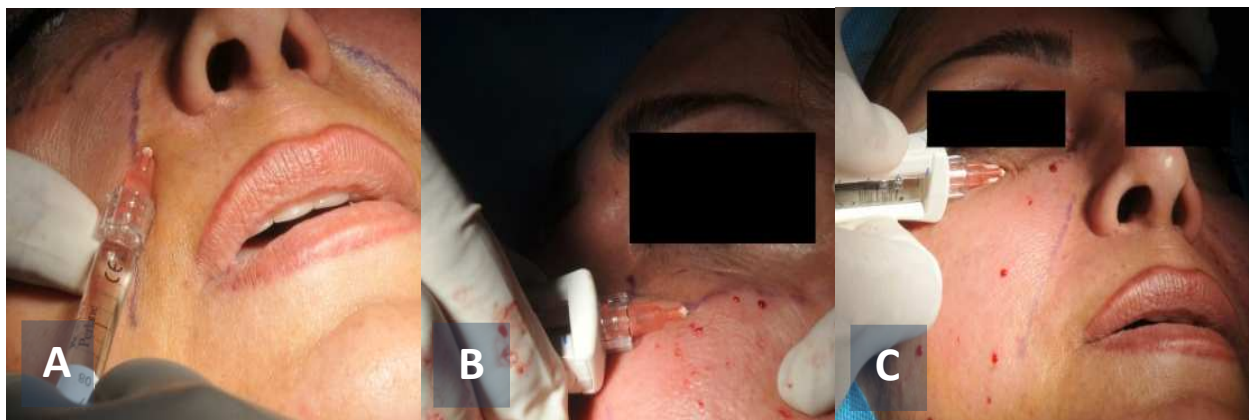que into the dermal-epidermal junction of the narrow and fine rhytids. Compressing the supra-trochlear vessel with the non-injecting hand is necessary to prevent intravascular injection of the filler agent [9].

#### 2.6.6. Forehead lines

Linear threading technique is usually used for the treatment of forehead rhytids. Fine-sized particle fillers are used for injection into the dermal-epidermal junction of this area. In the glabellar region, because of the activity of the muscles of this area, combination therapy of this area with botulinum toxin injection is preferred for longevity of the results [9].

#### 2.6.7. Tear trough/malar region

For augmentation of this area, large-sized particle fillers are used for supra-periosteal injection using linear threading or serial puncture technique (Figure 1-B,C). For deep rhytids of this area, filler augmentation alone may not be effective enough and face lift surgery may be needed [9].



**Figure 1.** Filler agent injection. A, B, C, The injectable filler agent is used for the augmentation of the nasolabial folds, malar region and tear trough region respectively.

#### 2.7. Post – operative care

There are several post-treatment considerations that patients should mind following filler injection. The patients are recommended to use cold compresses for 24 to 48 hour to reduce swelling and the patient should have 30 degrees head elevation for the first 24 hours. Physical activities and facial expressions should be limited immediately after injection to prevent filler migration. They also should avoid excessive sun exposure until erythema and swelling disappears. Aspirin, NSAIDs and blood-thinning medications should be avoided for 24 to 48 hours before and after injection to minimize the bruising which may last 7 to 10 days. Acetaminophen is usually enough for pain control. Oral antihistamines can blunt the histamine release and resultant early edema and may be most useful in patients who develop more edema than usual or redness immediately after injection. Swelling occurs following injection

and usually last for 2 days but it may continue for up to 3 weeks. Oral antihistamines can help to decrease the early edema [1,8,9,17].

## 2.8. Complications

Pain is common following injection. Using small needles can decrease the injection pain, but viscous filler agents may require larger needles for injection. It is also recommended to use topical or regional anesthesia prior to filler injection to reduce injection discomfort [8,38]. Acetaminophen is also effective to manage post-injection pain, but aspirin or NSAIDs are contra-indicated due to their anticoagulation effects and they should be discontinued prior to injection if possible. Blood-thinning medications are also no exception because of their ability to increase the risk of bleeding. Post-operative infections are rare, but people with the history of herpes simplex infections should be treated with prophylactic antiviral agents [1,8]. Granuloma formation is common with alloplastic filler agents and semi-permanent and permanent materials, but it is also reported with using biologic filler agents [39-41]. Granulomas can often be treated with simple excision and incision/drainage. Hyaluronidase is also recommended for hyaluronic acid fillers [40,42]. To prevent complications such as filler palpability and lumps, care should be taken to inject more viscous and large-sized particle filler agents into the deep dermis and less viscous and small-sized particle filler agents more superficially [8]. Major complications are rare but serious. Allergic reactions can occur with animal-derived products and allergy testing prior to injection of these materials is required [41,43]. Some other serious complications such as skin necrosis, blindness and death are also reported [1,8,13].

## 3. Autologous fat transfer

As mentioned previously, ideal fillers should be safe, efficient, easy to use and biocompatible. Autologous fat is the closest to an ideal filler. It is autologous and therefore biocompatible and non-immunogenic, it is available and inexpensive and it can be easily acquired through a minimally invasive procedure [44-47]. Fat tissue transfer has become a commonly used technique because of its advantages. One of its disadvantages is its longevity and survival rate, which is very unpredictable and survival rates between 40 to 80 percent have been reported [48-51].

### 3.1. Background

Autologous fat grafting, first performed in 1890s, and as injectable filler in the 1920s [1,52]. In 1893, Neuber first described the free autologous fat graft transfer for soft tissue augmentation. He transferred tiny parcels of fat into the scar tissues and studied their survival and reported that smaller grafts survived longer with more predictable results. Silex, Axenfeld and Verderame have also separately studied free abdominal fat grafts for treating depressed skin scars as a result of tuberculosis [53]. In 1912, Hollander described changes after fat injection in patients with facial lipo-atrophy [54]. In 1926, Miller described the methods for fat

injection via cannulas [52]. Neuhof performed several studies on fat graft survival and reported that with time the graft cells die and are replaced by fibrous tissue [55]. In 1956, Peer mentioned that good blood supply at the recipient site and the need for hemostasis are important factors for graft survival [56]. In 1997, Coleman introduced his modified technique for atraumatic fat harvesting, centrifugation and injection to maximize survival rate [57].

### **3.2. Indications**

The fat transfer technique can be used for the correction of facial asymmetries. Today, it is also used for cosmetic purposes, as a filler for facial rejuvenation.

### **3.3. Fat harvesting**

#### *3.3.1. Donor site*

The most common fat harvest sites include the abdominal wall, extremities, trochanteric area, inner knee, dorsocervical fat pad, and flank sites. There is no evidence to claim that which donor site is optimal for fat harvesting [50,58]. Rohrich et al. found no difference between the viability of the fat cells harvested from abdomen, flank, thigh and medial knee [58]. According to this, the donor site is usually chosen for ease of access and availability. Lower abdomen and the thighs are the most two easily accessible sites for fat harvesting because these sites do not require patient repositioning and redraping (Figure 2).

##### *3.3.1.1. Lower abdomen*

The central part of the abdomen, in the lower and upper region usually contains low contents of fat for harvesting. The harvesting should be kept minimized in the midline to prevent contour irregularity. The cannula should be entered into the lower abdomen while feathered upward and outside into the upper-lateral abdomen. It is important harvest the upper abdomen beyond the lateral limit of the lower abdomen to prevent the occurrence of contour irregularities [59].

##### *3.3.1.2. Inner thigh*

Fat can be harvested from inner thigh by performing a stab incision along the inguinal line. Then the cannula is inserted. The shadow of the cannula should not be visible through the skin, which means that the cannula is very superficial and harvesting will lead to contour irregularities. The harvesting should be feathered out toward the anterior thigh to minimize contour changes [59].

##### *3.3.1.3. Anterior thigh*

The anterior thigh has variable amounts of fat in different patients and can be accessed through the same access point as for the inner thigh [59].

#### 3.3.1.4. *Lateral thigh*

The lateral thigh is accessed via a stab incision made laterally along the inguinal line and the harvesting is performed inferio-laterally.

#### 3.3.1.5. *Inner knee*

This is an easy area to harvest and usually is used only in very thin patients with low fat reserves. A stab incision is made in the medial, inferior and posterior portion of the fat pad and the cannula is inserted in an antero-superior direction for fat harvesting [59].

#### 3.3.1.6. *Buttock*

The buttock can be used in the very thin patients with low fat reserves, because everyone has some fat in the buttock. The reason that this area is not commonly used for fat harvesting, is that it needs patient repositioning and redraping. The stab incision should be made along the buttock crease to minimize the scar and pigmentation of the skin [59].

#### 3.3.1.7. *Lower back*

The lower lateral back is another area for fat harvesting in thin patients. The incision should be made along the lower lateral skin fold to harvest the lower back fat [59].

#### 3.3.1.8. *Triceps region*

This area is also usually used in thin patients. The stab incision is made on the back of the arm, near the elbow, along the triceps for fat harvesting. Over-harvesting this area can lead to contour irregularities [59].

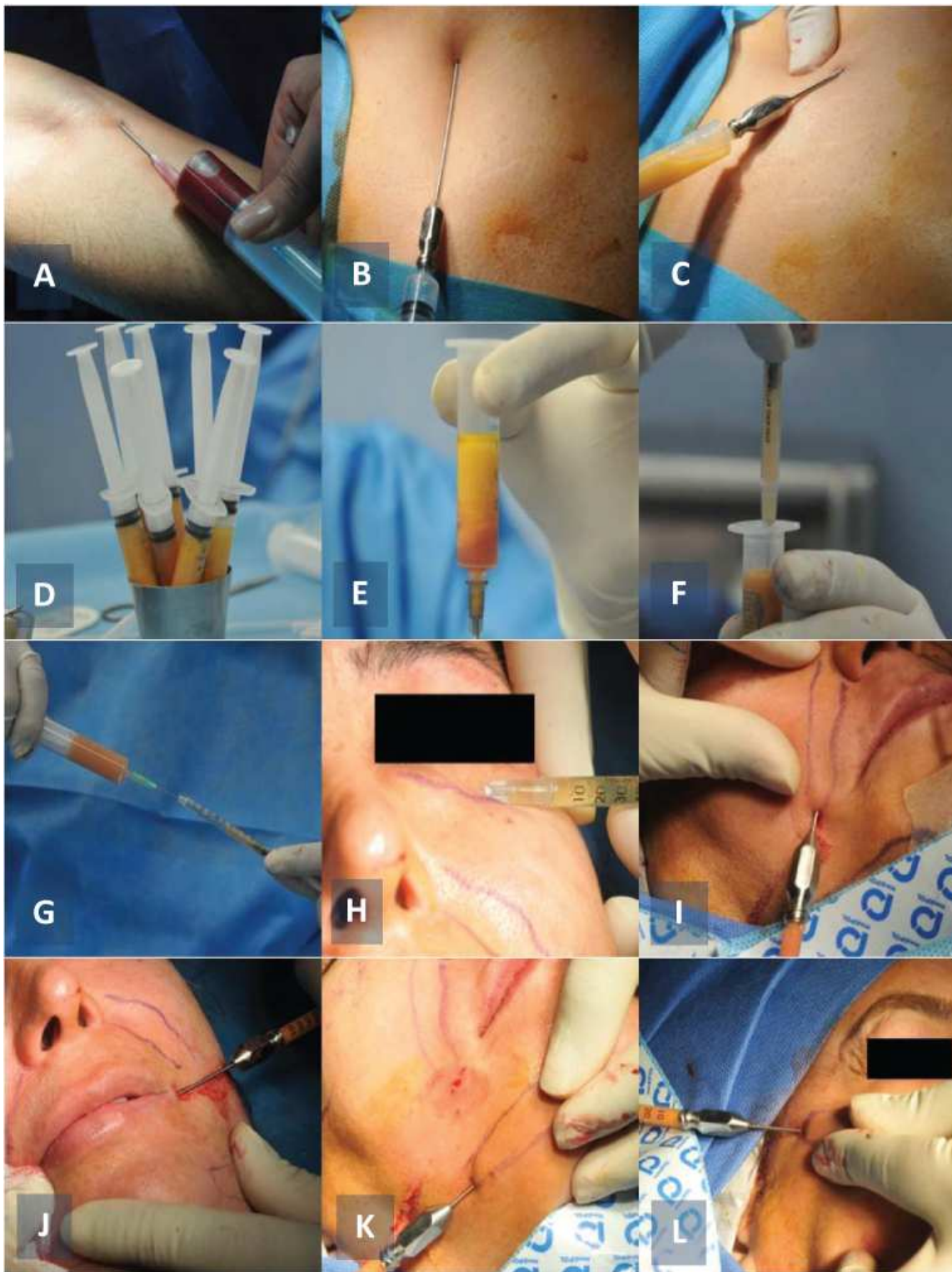
#### 3.3.2. *Local anesthesia*

Moor et al. studied the effect of epinephrine and lidocaine on human fat viability and they mentioned that it had no adverse effect on fat cells [60]. Fat harvested with normal saline, lidocaine and epinephrine solution has no significant effect on cell viability [61-65]. Today, most clinicians inject the donor site with local anesthetic. Some surgeons however, do not use any local anesthesia to avoid exposing the fat cells to lidocaine, which has been shown to temporarily restrain adipocyte growth in cell culture [60]. For patients who are under deeper levels of sedation or under full general anesthesia, a mixture of 5 ml 1% lidocaine and 1:100,000 epinephrine with 15 ml plain saline is enough. Half of the mixture is placed deeper to the fat plane, and the other half is distributed superficially into the subcutaneous plane [59].

#### 3.3.3. *Aspiration technique*

Rohrich et al. harvested fat using traditional liposuction, internal ultrasound-assisted liposuction and external ultrasound-assisted liposuction and they found that internal ultra-





**Figure 2.** Autologous fat transfer. A, Blood is collected from the patient for PRP preparation. B, The donor site is injected with local anesthetic solution. C, The fat graft is aspirated with a cannula connected to syringe. D, Syringes containing aspirated fat graft. E, Harvested fat graft after washing with lactated Ringer's solution. F, PRP is added to the graft to increase its longevity. G, The fat graft is delivered into the insulin syringe for reinjection. H, The tear trough area is augmented with PRP injection. I, J, K, L, The fat graft is injected into the nasolabial groove, lips, jowl and malar areas respectively.

sound-assisted liposuction can lead to thermal liquefaction of the fat cells [67]. Shiffman and Mirrafati compared various cannulas, needles and suction pressures due their effect on cell viability and found that vacuum pressure more than 700 mmHg can lead to cell damage [68]. Leong et al. found no difference between syringe liposuction and pump-assisted liposuction in cell viability [69]. Ozsoy et al. compared the effect of different cannula diameter in the cell viability and found that larger cannula leads to more viable cells [70,71]. Pu et al. compared the effect of fat harvesting using Coleman technique versus liposuction technique in the cell viability and found more viable cells in the Coleman technique group (use of a 3-mm cannula connected to a 10-cc syringe with manual suction via withdrawing the plunger) [72]. Conventional liposuction cause up to 90 percent fat cell rupture [73]. Carpaneda and Ribeiro mentioned the benefits of tiny particle fat grafts aspiration. They mentioned that the graft thickness was inversely proportional to the survival rate of the graft if its thickness exceeds 3mm [74]. As discussed above, syringe aspiration is currently the most popular fat harvesting technique. After the patient has been sedated, prepared and draped, the anesthetic material is injected into the donor site and a 3 mm stab incision is made into a discreet area. A blunt 2-hole cannula attached to a 10 cc syringe is used for harvesting the graft by applying a gentle negative pressure by retracting the syringe plunger [50,64,66,75]. The cannula should be move inside the donor site, in the curetting action fashion to let the small fat parcels enter the cannula [75]. The non-dominant hand should be used to stabilize the fat pad during cannula movement with the palm flat on the skin. After a few passes of the cannula along one straight path, the cannula should be withdrawn but not completely and then the cannula should be redirected to the adjacent linear path.

### 3.4. Preparation

#### 3.4.1. Centrifugation / washing

Coleman stressed the importance of removing nonviable components of fat aspirate such as oil, blood, and lidocaine by sedimentation or centrifugation at 3000 rpm for 3 minutes [45]. Centrifugation and washing are both aspects of fat graft preparation that have been examined for greatest graft success. Butterwick and others compared centrifuged versus non-centrifuged fat, grafted in hands and found that the centrifuged fat showed more longevity [76,77]. Ferraro et al. evaluated fat grafting in patients using 1300 rpm for 5 minutes showed less resorption in patients grafted [78-80]. Rohrich et al found no difference in adipose viability between non-centrifuged fat and fat that underwent the centrifugation (500 g for 2 minutes) and challenged the role of centrifugation [58]. Xie et al. found that the increased centrifugal force, especially greater than 1145 g, significantly decreased the viability of cells [81]. Ramon et al. also found no difference between centrifuged fat grafts in comparison to fat harvested after the use of a sponge to wipe away fluids, debris and oil [82]. Karacalar et al. introduced fat harvesting technique in a bloodless field by using a pneumatic tourniquet to eliminate the need for centrifugation [83]. Washing harvested fat before injection has also been described as a means of enhancing graft survival. Marques et al. used washing technique instead of centrifugation. They used lactated Ringer's solution to wash the harvested fat

and reported increased graft survival rate [84]. It has been stated that washing, will eliminate the inflammatory components from the graft.

#### *3.4.2. Addition of growth factors*

The addition of growth factors and nutrients to the harvested fat is not advocated by many. Coleman emphasized to prevent damage to the delicate fat grafts and opposed the addition of chemicals, hormones, drugs, or foreign substances to it [57]. Karacalar et al. [83] and Nordstrom [64] advised not to add any growth factors to the harvested graft. In contrast, some studies proposed the addition of supplements to improve the fat survival [85]. Har-Shai et al. proposed the suspension of the fat graft in a nutrient cell culture supplemented with non-steroidal anabolic hormones, insulin, thyroxine, and growth hormone [86]. Yuksel et al. delivered a relatively continuous dose of insulin, IGF-1, basic fibroblast growth factor (bFGF), or varying combinations to inguinal fat grafts and found increased fat graft weight and volume [87].

### **3.5. Fat reinjection**

It is believed that the method of injection has great effect on the success and longevity of treatment [51,75]. The injected fat should be within 2 mm of an arterial blood supply. This will increase the fat survival and minimize graft necrosis and scar tissue formation [65]. Butterwick and Lack described a technique known as “fat autograft muscle injection” that involved using blunt-tipped cannulas for fat injection directly into the intrinsic facial muscles [88]. Nordstrom described a “spaghetti” fat grafting technique in which 3 mm grafts were laid down in tunnels that did not touch each other [64]. To maximizing the surface area of the graft in contact with blood supply, injecting small particles of fat in multiple tunnels in a fanning fashion has been proposed [53]. This technique involves the creation of multiple tunnels by inserting the cannula through a 2 mm stab incision and then injecting small fat particles during cannula withdrawal (Figure 2). Coleman uses a 17 gauge blunt cannula connected to syringe [45], but the use of a 14 gauge blunt tip or curved micro-cannula is also suggested [47,65,89]. Tzikas used a 16 gauge, bullet-tipped, one-hole cannula for injection [66]. Trepsat used a 0.3 mm cannula attached to a 1 cc syringe for upper lid injection from the deep layer near the bone to a superficial layer just under the orbicularis oculi muscle. He also used a fine 19 gauge cannula on a 1 cc syringe for the lower lid to lay down fat cells in a multi-pass, pre-tunneled areas of the sub-orbicularis oculi fat [90].

### **3.6. Fat graft survival**

Fagrell et al. compared the longevity of the excised fat grafts, fat harvested in a cylinder shape with a 4.5 mm cannula, and fat grafts aspirated with a 2 mm cannula and found 60 percent weight loss in the aspirated group, 1 percent in the excised group and 2 percent in the cylinder group [91]. Coleman believes that stabilization of the graft volume occurs 3 to 4 months after injection and remain constant for 8 to 12 years [75].

### 3.7. Fat storage

Lidagoster et al. compared fresh, refrigerated (1°C), and frozen (−16° C) fat specimens injected 1 to 2 weeks after harvesting, with a group that underwent immediate injection. They found more inflammation and less viable fat in the stored group in comparison to the immediately injected group [92]. Butterwick et al. compared fat augmentation by using freshly isolated fat with frozen fat (−40°C) and found no difference in the esthetic results between them at 1, 3, and 5 months [93]. It has been reported that even brief exposure of the fatty tissue to air causes up to 50 percent of it undergo cytoplasmic lysis [94]. MacRae et al. compared the differential effect of incubation temperature on the fatty tissue viability versus storage at low temperature and they found that viability was superior in the frozen group [95]. Pu et al. found that there was no difference between fat graft mixed with cryoprotective agent and fresh fat graft in terms of cell viability [96].

### 3.8. Complications

Fat injection has some minor common complications such as edema and bruising with are transient and can be minimized by head elevation, compression and anti-inflammatory medicines. Using blunt cannula can minimize the damage to the underlying tissues and minimize the edema. Infection is rare using sterile technique. A rarely reported esthetic complication is the overgrowth of the graft [97-99]. Liposuction deformities may occur if the donor site is not correctly chosen. The most severe complications reported include fat embolism with subsequent blindness, aphasia, motor restriction and even acute fatal stroke [32,100-103].

## 4. Botulinum neurotoxin injection

Hyper-dynamic contraction of the facial muscles cause overlying skin folds perpendicular to the direction of the muscles. These facial folds produced by muscle contractions cause dynamic wrinkles. Dynamic wrinkles are best treated with botulinum toxin injections.

### 4.1. Background

Justinus Kerner, first described a case of lethal food poisoning particular to poorly-prepared meat products. The symptoms were mydriasis, diplopia, gastrointestinal problems and muscle paralysis. He named the causative poison botulism [104,105]. In 1897, Emile van Ermen-gem, isolated the causative pathogen, later named *clostridium botulinum* [106-108]. *Clostridium botulinum* is a gram-positive spore-forming bacillus. In 1949, neuromuscular blockade was described as the mechanism of action of the botulinum neurotoxin [109]. In 1973, Scott et al, studied the therapeutic effect of botulinum neurotoxin type-A (BoNT-A) in primates [110]. In the 1989, Alan Scott used this toxin in human to treat strabismus and blepharospasm [111,112]. Oculinum received FDA approval in 1989 for the treatment of strabismus, blepharospasm and hemi-facial spasm in 1989, which was then



renamed by Allergan (Irvine, USA) company to Botox Medical. In the same period, Ipsen (Slough, UK) introduced Dysport to European markets [113]. In 1992, Carruthers and Carruthers observed the improvement in peri-orbital wrinkles in patient treated for blepharospasm using Botox and they discovered a new treatment indication for BoNT [113]. Since then, many published the cosmetic use of BoNT [113-116]. In 1999 and 2000, Niamtu introduced the cosmetic uses of BoNT in maxillofacial practice [117,118]. Botox Cosmetic, received FDA approval for the glabellar region in 2002 [108].

#### **4.2. Bacteriology**

As mentioned earlier, *Clostridium Botulinum* is an anaerobic, gram-positive, spore-forming bacillus which produces exotoxin. Based on their exotoxin antigenic specificity, eight serotypes of this bacterium are recognized: A, B, C1, C2, D, E, F and G [106,119,120]. Neurotoxin strains A, B, E, F and G can affect humans [121,122]. Neurotoxin strains A and B are antigenicity different, but they have similar functions and are commercially available for medical treatments [108,123]. Although these toxins are antigenically different, there are some serum cross-reactivity among them and with tetanus toxin, because of some similar homological sequences [124].

#### **4.3. Structure and toxicity**

BoNT is a high-molecular weight protein complex made of 3 different proteins: First, a 150-KDa toxin which itself is composed of a 100-kDa heavy chain and a 50-kDa light chain that are binded together with disulfide non-covalent bonds. This bond disrupts during toxin activation. Second, a non-toxin hemagglutinin protein, which protects the toxin from being destroyed by acids. Third, a non-toxin non-hemagglutinin protein [125]. *Clostridium botulinum* spores are heat resistant and can survive in inadequately processed foods and can produce toxin, which can cause food-borne botulism [126]. Symptoms of toxin poisoning include weakness, vertigo, diplopia, difficult speaking and swallowing, difficult breathing, muscular weakness and constipation. These usually appear 18 to 36 hours after food poisoning [108]. The lethal dose of BoNT in humans is not known exactly, but according to animal studies the LD<sub>50</sub> (lethal dose for the death of 50% of population) for a 70 kg human is estimated about 0.09–0.15 mg by intravenous injection, 0.7–0.9 mg by inhalation and 70 mg by oral administration [122,127,128]. The standard vial of BoNT-A has a lethal dose 200 million times less [129].

#### **4.4. Mechanism of action**

Facial muscle contractions are responsible for the creation of dynamic facial folds. When the action potential passing along a nerve reaches the nerve ending; it causes acetylcholine vesicles to attach to the nerve ending membrane and then acetylcholine is excreted from the nerve ending membrane, into the neuro-muscular junction. Acetylcholine fuses to the muscle membrane and causes muscle contractions [130]. When BoNT is injected on neuromuscular junction, its heavy chain binds to the cell membrane of the nerve ending and creates a passage for the light chain to enter the nerve ending via endocytosis and vesicle formation. These toxin-containing vesicles



inhibit the acetylcholine release from nerve endings. As mentioned earlier acetylcholine is responsible for muscle contraction. Without acetylcholine release, muscle contraction is inhibited and leads to reversible muscle atrophy [131-134]. By doing this the facial muscles which are responsible for facial dynamic folds, will become paralyzed. The paralytic effect of BoNT is dose-dependent. BoNT effects usually take 2 to 3 days to appear after injection and its maximum effects occurring 1 to 2 weeks later and then level off slowly until full nerve recovery within 3 to 6 months following administration [119,135-137]. This nerve blocking effect of BoNT is permanent but the reason for the loss of effect after 3 to 6 months is due to synaptic switching and spouting of new axon terminals and the re-establishment of neuromuscular transmission [108,133,138,139]. It is seen that BoNT can diffuse across fascial planes to surrounding muscles, which can cause weakening of the surrounding muscles not injected and creates a flaccid area larger than the area of muscle denervation [140].

#### 4.5. Preparations

There are several BoNT preparations in different countries. The most common available BoNT-A preparations are Botox, Dysport, Xeomin, Prosigne and PurTox. Myobloc is a BoNT-B preparation. The treatment dose varies for each brand of toxin and for different parts of the body.

##### 4.5.1. BoNT-A

**Botox** was first produced by Allergan Inc, USA in 1968 for the treatment of strabismus which was originally called Oculinum. Then in 1991, Allergan Inc. renamed it Botox [106,110]. Each vial of Botox contains 5 ng (100 U) of air-dried BoNT-A, 500 µg of albumin and 900 µg of sodium chloride [141].

**Dysport** produced by Ipsen Limited, UK is a cosmetic product mostly available in Europe. Each vial of Dysport contains 12.5 ng (500 U) of air-dried BoNT-A, 125 µg of albumin and 2.5 µg of lactose. It is important to remember that because of different type and strain of bacteria used for the production of Botox and Dysport, their doses are equivalent to each other [141].

**Xeomin** is a freeze-dried powder of BoNT-A without any accessory proteins produced by Merz Pharmaceuticals GmbH, Germany. Because in contrast to other BoNT-A products, it does not contain additive proteins, it is less immunogenic and can be used when large amounts of BoNT are required to be injected [142,143]. Botox and Xeomin have similar dose-dependent paralytic effects and their diffusion to the surrounding muscles are low [144].

**Prosigne** is a BoNT-A product made by Lanzhou Biological Products Institute, China, in 1993 and is only available in China [145].

**PurTox** is a purified BoNT-A which is produced by Mentor Corp, Santa Barbara, CA, USA [143].

##### 4.5.2. BoNT-B

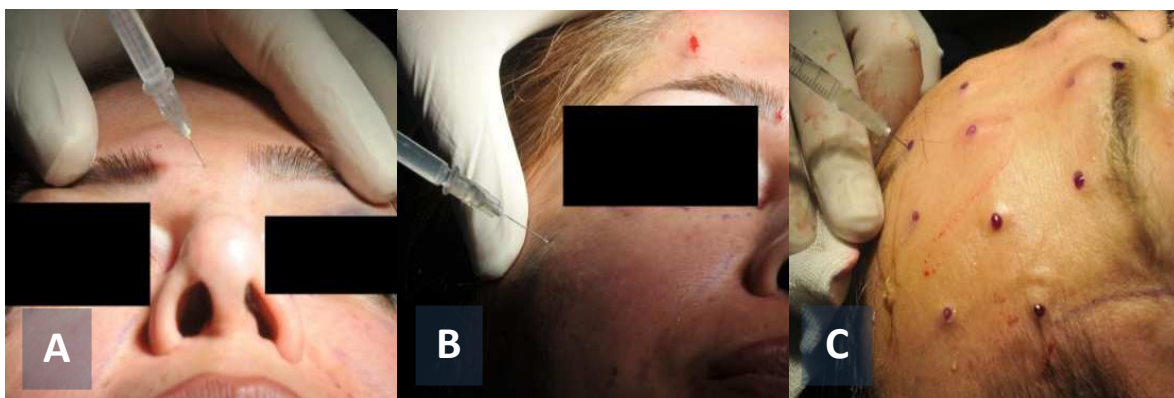
Myobloc is a BoNT-B product made by Solstice Pharmaceuticals, South San Francisco, CA, USA [141]. Myobloc has received FDA approval of the treatment of cervical dystonia and

hemi-facial spasm in 2001, but it does not have cosmetic approval, and its cosmetic use is off-label [146]. It is usually used for cosmetic purposes when the patient shows resistance to BoNT-A products [141,147-150].

Each 0.5 cc vial of Myobloc contains 25 ng (2500 U) of BoNT-B, 1.0 cc vial contains 50 ng (5000 U) and 2.0 cc vial contains 100 ng (10,000 U). Each product is pre-constituted in solution with 0.05% albumin [141]. Several studies have shown that the duration of action of BoNT-B is shorter than BoNT-A, and it has a less predictable diffusion pattern [141,150-152].

#### 4.6. Indications

BoNT is used for cosmetic purposes in the face for dynamic folds and should be injected in areas with dynamic muscle contractions, such as the glabellar region, frontal region and peri-orbital lines (Figure 3). It is also used for the treatment of gummy smile [137,153-155].



**Figure 3.** Botulinum neurotoxin injection. A, B, C, The BoNT is injected for the treatment of the glabellar rhytids, peri-orbital rhytids and horizontal forehead rhytids respectively.

#### 4.7. Contra – indications

BoNT should not be injected to pregnant women and nursing mothers. Patients who are taking aminoglycoside antibiotics, quinine, calcium channel blockers, magnesium sulfate, succinylcholine, polymyxin, cyclosporine and cholinesterase inhibitors should not be given BoNT, because these may potentiate the effect of the toxin [122,136,156]. BoNT injection is also contra-indicated in patients with neuromuscular disorders such as myasthenia gravis, amyotrophic lateral sclerosis and Lambert-Eaton syndrome. BoNT administration is also contra-indicated in patients who may have hypersensitivity to BoNT or to any of the additive ingredients [157,158].

#### 4.8. Dosage

There are several brands of BoNT-A products available, but Botox (also known as Botox Cosmetic, Vistabel, and Vistabex) is the most well-known brand. Botox should be kept frozen prior to use. The manufacturer recommends reconstitution of the vial with sterile injectable normal

saline. The reconstituted toxin should be stored at a temperature of 2 to 8 °C and should be injected within 4 to 8 hours [136]. This concern is mostly about its sterility. Although there are some reports that shows no bacterial contamination even after 15 days [159,160]. The reconstitution should be done by gently injecting the diluent into the toxin vial to avoid foam formation, which can compromise the effectiveness of the toxin. The volume of the diluent to be injected into the toxin vial differs according to the injection site and desired concentration, the number of units to be injected, the clinician preferences and muscular mass. It is seen that injecting higher doses of toxin in smaller volumes prevent the toxin from diffusing around and keeps the toxin effects localized, but when there is a need to treat a large area such as the forehead injecting higher doses in smaller volumes is hard to do [131,161-163]. Male patients usually have larger muscle volumes than female patients and they need more units of toxin to be injected to achieve the same effects as female patients. [162,164,165].

#### 4.9. Injection technique

For maximal effect, the toxin should be injected into the mass of the muscle which causes skin folds, not into the skin folds and depressions. This is achieved by identifying the causative muscle when examining the patient at rest and maximal facial muscle contraction situation [136]. The injection technique is simple. The injection should be performed intramuscularly and should avoid superficial intra-dermal injections. Usually there is no need for anesthesia, but if the patient insists topical anesthetics can be used at least 45 minutes before injection [136,166].

#### 4.10. Applications

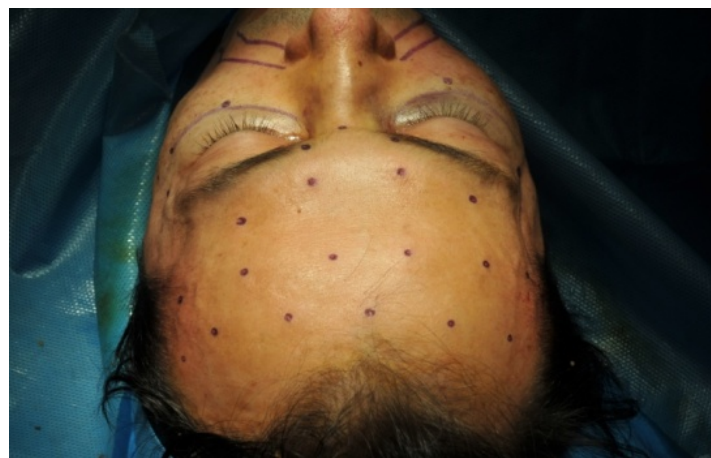##### 4.10.1. Glabellar rhytids

Deep vertical folds of the glabellar region which are also called frown lines are best treated by BoNT injection [136]. Corrugator supercilii muscles with contribution from the frontalis, orbicularis and procerus muscles are responsible for these dynamic folds, but with aging, these folds become static. Orbicularis oculi and corrugator supercilii muscle are responsible for adduction of the brows. Depressor supercilii and procerus muscles cause brows to move inferiorly [136,167,168]. The physician asks the patient to frown to be able to palpate and identify the muscles. The corrugator supercilii muscle should be injected about 1 cm above the orbital rim in the mid-pupillary line to prevent toxin diffusion into the medial part of the brows which can cause brow ptosis [136,169]. The dermal insertion of the corrugator muscle should also be assessed, because it determines the lateral extent of the toxin injection. Injections just above the brow in the mid-pupillary line must be avoided because they will cause eyelid ptosis [156]. The toxin effects usually last for 3 to 6 months. Male patients may need more doses of toxin due to their greater muscular mass [162,165].

##### 4.10.2. Horizontal forehead rhytids

The frontalis muscle is a large muscle which originates superiorly to the brows. Its contraction causes horizontal forehead folds. These folds can be treated by injecting BoNT into the

frontalis muscle (Figure 4). The injections should be made higher than half way between the hairline and brows, because lower injections can cause brow ptosis. Injections are done at 5 to 7 sites distributed horizontally, 2 to 3 cm above the eyebrows. The injections should extend laterally enough at the lateral part of the brow to prevent the lateral part of the eyebrows being pulled up excessively, but not more than 2 cm lateral to the most lateral part of the eyebrow [136,170-172]. For patients who want elevation of the lateral part of the brows, these areas should not be injected [169,173,174]. The effects of the toxin injection usually last for 4 to 6 months [175]. The side effects, such as headache, eyelid swelling, and brow ptosis, are more common with higher doses, but it has been shown that lower doses are prone to faster relapse [167,176].



**Figure 4.** BoNT injection into the frontalis muscle.

#### *4.10.3. Brow lift*

Contraction of the corrugator supercilii, procerus and the medial portion of the orbicularis oculi causes inferior positioning of the medial part of the brow. Contraction of the lateral portion of the orbicularis oculi is responsible for inferior positioning of the lateral part of the brow. As mentioned earlier, treating the forehead folds can also causes eyebrow elevation [175]. Injecting the procerus muscles and the supero-lateral portion of the orbicularis oculi could also causes eyebrow elevation. The injection is done at the temporal fusion line, below the lateral third of the brow and superior to the orbital rim [167,173].

#### *4.10.4. Eyebrow asymmetry*

There are some conditions that could cause eyebrow asymmetry, such as unilateral facial nerve palsy, uneven brow lift surgery, hemi-facial paralysis and the patients with binocular vision combined with ipsilateral brow ptosis. In these cases, unilateral injection of the procerus and lateral portion of the orbicularis oculi with the BoNT at the inferiorly positioned eyebrow side, can improve the condition [177].



#### 4.10.5. *Peri – orbital rhytids*

Contraction of the lateral portion of the orbicularis oculi muscle is responsible for the development of the peri-orbital folds at the lateral side of the orbit, which are also called crow's feet appearance. At first, they are only dynamic folds, but by aging, muscle activity and sun exposure they became static [136,137].

For treating these folds, three injections should be done in the lateral portion of the orbicularis oculi muscle. The injection sites are identified while the patient is smiling. It is important for these injections to be at least 1 cm lateral to the lateral orbital rim, to prevent the diffusion of the toxin into the orbit. The upper most injection site is just below the eyebrow and the lower most site is 1 to 2 cm lower to the first one [178,179]. The injections should be done when the patient is relaxed and not smiling to prevent the diffusion of the toxin into the zygomaticus muscles which causes upper lip ptosis [180]. The injections should be superficial to prevent injecting the toxin into the orbital septum, which could migrate into the ocular muscles and cause diplopia [181].

#### 4.10.6. *Hypertrophic pre – tarsal orbicularis*

Injecting the pre-tarsal orbicularis muscle with BoNT can widen the palpebral aperture for better esthetic appearance. The injection is done 3 mm inferior to the lower pre-tarsal orbicularis oculi muscle both at rest and while smiling [167,179].

#### 4.10.7. *Nasalis muscle*

Nasalis muscle has 2 parts. The upper nasalis muscle extends inferio-laterally from the dorsum of the nose to the skin lateral to the nose. Its contraction is responsible for the development of fanning-shaped, radial folds of the skin lateral to the nose, which are called "bunny lines". The lower nasalis muscle extends into the lateral portion of the nasal ala and its contraction causes nostrils to dilate. Some patients might be unsatisfied of these contractions, especially because these contractions are usually involuntarily. This condition can be treated easily by injecting toxin into the nasalis muscle. The injection site should be superior to the nasofacial groove and antero-inferior to the angular vein [167].

#### 4.10.8. *Gummy smile*

There are several reasons that could make a patient have a gummy smile appearance. One of its reasons is the hyper-functionality of the upper lip elevating muscles. The levator labii superioris alaeque nasi muscle, the levator labii superioris muscle and zygomaticus minor muscles are responsible for the elevation of the upper lip. By injecting the toxin into these muscles, their tonicity can be reduced, which could treat the gummy smile. The toxin is injected lateral to each nostril, which can cause relaxation of the muscles. Weakening of these muscles decreases the amount of lip elevation and decreases the amount of gingival show [137,182].



#### *4.10.9. Perioral rhytides*

Contraction of the orbicularis oris muscle is responsible for the creation of the vertical perioral folds. This muscle encircles the mouth and acts as a sphincter which causes the lip to close. For treating these folds, several micro-dose injections into the orbicularis oris are required to weaken this muscle. Usually 6 to 8 injections are required to accomplish this [167].

#### *4.10.10. Mid – facial asymmetry*

There are two functional reasons for producing mid-facial asymmetry: the hyper-function of the muscles of one side, or the hypo-function of the muscles of the other side. These patients can be treated by injecting toxin into the zygomaticus muscle, risorius muscle, orbicularis oris and masseter. In patients with hemi-facial spasm, the facial midline moves toward the hyper-functional side, and the muscles of the hyper-functional side should be injected for the correction of the facial midline. In contrast, in patients with facial nerve paresis, the midline moves toward the normal side, the normo-functional side muscles should be injected [167].

#### *4.10.11. Depressor anguli oris*

The depressor anguli oris muscle originates from modiolus and extends inferiorly into the inferior border of the mandible. Its contraction is responsible for the inferior movement of the mouth corners. Its hyper-functionality leads to a constant downward turn of the mouth corners and constant bitter appearance. Because of its origin, which is in close proximity to other muscles, it should not be injected directly. It is proposed to inject this muscle at the level of the mandible, at its posterior margin and close to the anterior margin of the masseter muscle [167]. Because the upward motion of the mentalis muscle is also responsible for this bitter appearance, the injection of this muscle is also advisable.

#### *4.10.12. Mental crease*

Hyper-functionality of the mentalis muscle can cause a deep mental crease and unesthetic appearance. Weakening this muscle can soften this crease. To accomplish this, toxin should be injected into this muscle, at each side of the midline and below the mental crease. Injections above the mental crease can cause perioral muscle weakness [167].

#### *4.10.13. Lower facial asymmetry*

Lower facial asymmetry is usually seen in patients with hypo-functionality of one side of the face. This hypo-functionality can be due to a surgical procedure, traumatic cutting of the orbicularis oris or risorius muscles, congenital or acquired weakness of the depressor anguli oris muscle, or due to innervation problem. To treat this condition, the risorius muscle at the normo-functional side should be injected with BoNT [167].

#### 4.10.14. *Masseteric hypertrophy*

Para-functional habits such as bruxism and clenching can lead to hypertrophic masseter muscles, which can cause an unesthetic appearance. This condition can be treated by injecting BoNT into the masseter muscle to reduce its tonicity and its mass, but the para-functional habits should be first treated prior to BoNT injection. Each masseter is injected in 3 to 6 sites in the thickest part of the muscle at the inferior mandibular border, with low dose toxin. The muscle can be palpated by asking the patient to clench the teeth together [137,167,183].

#### 4.11. **Complications**

Side effects of cosmetic BoNT are usually mild and transient. The most common side effects are pain, swelling, bruising and ecchymosis. Some transient rare systemic side effects such as weakness, fatigue, nausea, pruritus and flu-like syndromes have also been reported [184]. These symptoms are usually transient and there is no need for any treatment. It is important to use the smallest needle possible to minimize the bruising. Injection into the superficial vessels, should also be avoided and the toxin should be injected into the subcutaneous layer. Bruising usually resolves in 10 days [136]. The headache usually occurs on the first day after injection, and it is not due to BoNT. The studies have shown that it is related to the injection procedure itself [185]. Injecting the lower half of the frontalis muscle can cause brow ptosis. This also can occur by diffusion of the BoNT into the lower half of the frontalis muscle. For the patients with pre-existing brow ptosis, the frontalis injections should be avoided. It has been suggested that the higher the volume, the greater the diffusion [186]. Transient upper eyelid ptosis may occur in the first two days after glabellar BoNT injections. This is due to toxin diffusion through the orbital septum, to the upper eyelid levator muscle. This condition usually resolves itself over the first week [184]. This can be prevented by using high dose, low volume BoNT no closer than 1 cm above the orbital rim. It has been seen that Dysport diffuses more than Botox. It is also important to apply digital pressure on the orbital rim during injection to prevent the toxin diffusion. Ectropion has been seen in patients with pre-existing lower eyelid laxity, due to weakening the orbicularis oculi muscle with BoNT [187].

When treating crow's feet, the inferior limit for injection should be superior to the zygomatic arch and the injections should not be deep, because this can cause zygomaticus major palsy, which is responsible for the lip drop after BoNT injection [181]. It has been suggested that the patient could exhibit an allergic reaction to the albumin that is used in the preparation of some BoNT products. The estimated lethal dose of BoNT-A for humans has been estimated about 2500 to 3000 U, which shows that it has a large margin of safety [106].

## 5. **Facial resurfacing**

Facial resurfacing refers to procedures that change the texture and appearance of skin. Photo-aging and acne scarring are the most common reasons for which patients seek resurfacing procedures. Facial resurfacing includes mechanical derm-abrasion in 1905 by Kromayer, the Baker-

Gordon phenol peel in the 1960s, the laser principle of selective photo-thermolysis by Anderson and Parrish in 1983, and medium-depth chemical peeling by Brody in 1986 [188-191].

### **5.1. Anatomy of the skin**

The skin consists of two layers: the epidermis and the dermis. The epidermis is composed of epithelium which is subdivided into 5 layers: the stratum corneum, stratum lucidum, stratum granulosum, stratum spinosum, and the stratum basale. The stratum corneum is the most superficial layer and composed of layers of keratinocyte. The stratum lucidum contains a dense layer of keratin filaments that provides additional structural support. The stratum granulosum contains lipid granules which makes the skin waterproof. The stratum spinosum is characterized by the presence of multiple spiny cells containing cytokeratin. The stratum basale generates the cells composing all other layers of the epidermis. The dermis consists of two layers: the papillary layer and the reticular layer. The papillary layer contains the capillary network and nerve endings. The reticular layer contains densely packed collagen, hair follicles and sweat and sebaceous glands [192].

### **5.2. Patient selection**

The ideal patient for a resurfacing procedure is one who has signs of photo-aging or acne scarring. Acne scarring is classified as ice pick, rolling, or boxcar type. Ablative resurfacing is most effective for boxcar and rolling types [193]. The first step is to review the patient's medical history and lifestyle. Patients with a history of keloids, smoking, extensive undermining of skin and facelift surgery in the last 6 months, history of skin radiation, HSV infections and diabetes are relative contra-indications to ablative procedures [194]. Chronic smoking causes micro-vascular damage and leads to poor tissue healing. Smoking should be stopped as least a month prior to peeling and 6 months after that [195]. Excessive sun exposure could also lead to poor healing and the patient should be advised to avoid sun exposure after peeling [195]. Birth control pills, exogenous estrogens and photosensitizing drugs are to be avoided because of risks of hyperpigmentation. The patients who are planning to become pregnant within the first 6 months after treatment are not good candidates for peeling due to the elevation of the estrogen level. [196]. Isotretinoin use is an absolute contraindication to resurfacing procedures, because it prevents re-epithelialization and should be stopped 12 to 24 months prior to the treatment [195].

### **5.3. Pretreatment skin preparation**

Skin preparation and protection is essential prior to resurfacing treatments. These pretreatment considerations contain preconditioning the skin with topical retinoids, alpha-hydroxy acids, and hydroquinones and photo-protection after ablative procedures [197]. Sunscreens should be started to prevent pre-peel burns or tanning to decrease melanocyte activity 3 months prior to the peel in combination with minimal sun exposure [195]. Tretinoin aids in re-epithelialization and leads to increased melanin distribution [198]. It also has synergistic qualities with trichloroacetic acid [199,200]. It is recommended to use topical tretinoin (0.05% to 0.1%) 6 to 12 weeks prior to the treatment.

Hydroquinone is used prior to treatment in patients with melisma, dyschromia, lentigines, hyper-pigmentation and Fitzpatrick skin types 3 to 6 [201]. Hydroquinone decreases melanin production by blocking tyrosinase and preventing the conversion of tyrosine to L-Dopa. Hydroquinone (4 to 8%) should be started 4 to 6 weeks prior to treatment. Antiviral prophylaxis should be started prior to the procedure. Acyclovir should be used 400 mg 3 times a day, or 500 mg twice a day, 3 days prior to the treatment and should be continued for at least 7 days after. For those patients with a positive history of active HSV infections, Valacyclovir 1 g should be used [202,203]. A study by Manuskiatti et al. showed a bacterial infection rate of 4% in patients pretreated with prophylactic antibiotic undergoing laser resurfacing and 8% in the untreated group [204,205]. The use of appropriate prophylactic antibiotic especially against staphylococcal and streptococcal species is recommended, but it is controversial.

It is necessary for the patient to avoid waxing, derm-abrasion, and electrolysis for 3 to 4 weeks prior to peeling. These procedures could affect the uniform depth penetration of the peeling agents [195].

#### **5.4. Resurfacing procedures**

Resurfacing procedures are classified into ablative or non-ablative procedures. Ablative procedures are those which wound the skin to the level of the dermis. These procedures include chemical peels, derm-abrasion, laser ablation and plasma resurfacing techniques. They can cause a wound to the level of superficial, medium or deep. The disadvantages of these techniques are increased risk of infection, erythema, post-inflammatory hyperpigmentation, cicatricial scarring and hypopigmentation. The non-ablative procedures include lasers and radiofrequency techniques. Their advantages are minimal recovery time and low risk of scarring.

##### *5.4.1. Chemical peel resurfacing*

###### *5.4.1.1. Introduction*

Chemical resurfacing is the application of chemical agents to produce a controlled partial thickness wound of the skin. Chemical peeling agents are categorized as superficial, medium, and deep based on the depth of ablation. Superficial peels cause exfoliation of the epidermis, medium peels cause epidermal to papillary dermal peel and deep peels penetrate to the reticular dermis [202,206].

###### *5.4.1.2. Indications*

Chemical peel indications are rhytides, irregular pigmentation, scars, actinic keratosis, and acne [207]. Superficial peels are effective for treating the mild actinic damage, superficial lentigines, mild rhytids, post-inflammatory erythema and mild photo-aging. The superficial peels result in epidermal sloughing and mild inflammatory response in the superficial papillary dermis. They are safely used in all Fitzpatrick skin types. Medium depth peels are used

for dyschromia from dermal melasma moderate photo-aging and mild to moderate acne scars. They result in sloughing of the epidermis, variable necrosis of the papillary dermis and some inflammation within the reticular dermis. These peels should not be used for Fitzpatrick skin type 5 and 6, due to the risk of dyschromia [208]. Deep peels are used for advanced photo-aging and deep rhytids of the perioral and peri-orbital. They create sloughing of the epidermis and papillary dermis and cause inflammation within the reticular dermis. They should be used for patients with Fitzpatrick skin type 1 and 2 [195].

#### *5.4.1.3. Superficial chemical peels*

Alpha-hydroxy acids (AHAs) are usually used for superficial peeling. They include glycolic acid and lactic acid. They are time-dependent and after achieving appropriate peeling depth, they should be neutralized by using ammonium salts, sodium bicarbonate or sodium hydroxide to prevent excessive peeling and healing problems [201,206]. These agents affect epidermis and the superficial dermis by creating the loss of cohesion of keratinocytes. Salicylic acid is a beta-hydroxy acid agent which exfoliates the dead skin cells. This agent is usually used in combination with other agents [209]. Jessner's solution consists of 14 g salicylic acid, 14 g lactic acid, 14 g resorcinol in 100 ml of 95% ethanol [202,203]. Its penetration depth is coat-dependent. By applying one to three coats the penetration depth is limited to the stratum corneum. However, by applying 5 to 10 coats, the penetration depth extends to the basal cell layer. The desired end point of superficial agents can be determined by erythema and light peeling of the epidermis. A clear frost indicates penetration into the dermis and should be avoided [210,211]. Mild stinging occurs during the procedure which resolves within a few minutes. Mild erythema subsides within a few hours. Desquamation begins 2 to 3 days later and can last 1 to 4 days. Usually 3 to 5 treatment sessions spaced 2 to 4 weeks apart are necessary for desirable results.

#### *5.4.1.4. Medium-depth peels*

Trichloroacetic acid (TCA) is the gold standard agent used for medium-depth peeling. At concentrations up to 35%, it acts as a medium depth peel, but at concentrations of 45% to 50%, acts as a deep peel [212]. The risk of scarring increases at concentrations more than 50% [213]. It does not require neutralization. To lessen the risk of scarring, and to achieve the appropriate peeling depth, Coleman combined glycolic acid with 35% TCA [214]. When combining Jessner's or 70% glycolic acid with 35% TCA, Jessner's solution or glycolic acid is applied first within 60 seconds until a faint frosting with mild erythema appears. The glycolic acid needs to be neutralized [215]. Jessner's solution is allowed to dry. Then the 35% TCA is applied [216]. Jessner's solution destroys the epidermis and allows for even application of the TCA solution to achieve a deeper penetration [217]. The endpoint is a white frost that usually appears within 30 to 120 seconds of application. If it does not appear, additional passes are done. It is important to wait at least 120 seconds between passes for the frost to appear. The face develops erythema for the first 12 hours, followed by moderate edema. Full re-epithelialization usually occurs 7 to 10 days after the treatment. The treatment can be repeated as necessary on a yearly basis.



#### 5.4.1.5. *Deep phenol peels*

The Baker-Gordon solution is usually used for deep peels. It consists of 3ml of 88% phenol, 3 drops of 2.1% Croton oil, 8 drops of Septisol and 2ml of water [218,219]. This mixture should be freshly prepared for each treatment. It was thought that, phenol was responsible for deep peeling, but Hetter showed that in fact, croton oil was responsible for peeling [220]. Because the potential toxic effects of phenol to the cardiac system, and its ability for causing cardiac arrhythmias, the blood pressure, pulse oximetry and ECG monitoring should be used during treatment. This complication is more common when more than half of the face is treated in less than 30 minutes [207,221]. It also can cause renal toxicity and irreversible hypopigmentation and should be used only in patients with Fitzpatrick skin type 1 and 2 [195]. The deep phenol peel is applied within 15 minutes interval between each esthetic unit. The endpoint of the application is a white frost followed by a deep brawny erythema. The skin should be protected and moistened during the first 4 days after the treatment [218]. Full re-epithelialization occurs in 10 to 14 days. The erythema typically resolves within 2 months [194].

#### 5.4.1.6. *Technique*

Prior to application of peeling agent, preparing the skin is needed. A soap free cleanser is used to remove makeups. Then the skin is vigorously cleaned by rubbing alcohol or acetone for about 3 minutes to degrease the skin and reach a brisk erythema [195]. 10 to 15 mg oral diazepam is usually administered preoperatively to reduce the patient's anxiety. The intravenous catheter is placed and fluid therapy is administered for the patient to regain intravascular volume. Usually a sedative dose of propofol is administered. Then the supra-orbital, infra-orbital and mental nerves are blocked by lidocaine 2% without epinephrine, to prevent the accumulation of the phenol agent. The peeling agent is uniformly applied to each esthetic unit (forehead, left cheek, right cheek, nose, chin, and peri-orbital area) with a cotton gauze. The cotton tipped applicator is used for the application of phenol peels. The upper eyelids should be left untreated. The peel should be performed to within 3 mm of the ciliary line of the lower eyelids [194,195]. If phenol is used, 10 to 15 minutes must be allowed between each unit peeled for the phenol clearance. The peel should be carried into the hairline and over the vermilion border to prevent lines of demarcation. The adjacent esthetic units should also be peeled adequately by overlapping the adjacent application areas for the same reason.

#### 5.4.1.7. *Post-operative care*

The burning sense may last up to 8 hours after the treatment. An oral narcotic analgesic is usually prescribed to minimize the burning sensation. When the frost subsides and only erythema persists, a bland emollient should be applied to the skin to ease the skin monitoring on a daily basis. A day after treatment, the patient is advised to apply cream, 3 times a day. In the first 12 weeks after the treatment, sun exposure can result in hyperpigmentation and the patient should be advised to avoid excessive sun exposure. The sunscreens should also be avoided for the first 6 weeks because of their para-amino-benzoic acid formulation

which could lead to irritation and erythema [195]. The healing process occurs in five stages. The first stage is inflammation which increases during the first 12 hours. At the second stage, the epidermis becomes leathery and separates from the dermis and sloughs. The third stage is desquamation and will occur over 4 to 7 days. At the fourth stage, re-epithelialization begins within 48 to 72 hours and lasts about 7 to 10 days. Finally, fibroplasia begins within the first week and continues for 3 to 4 months after the treatment [222].

#### *5.4.1.8. Complications*

As mentioned earlier, cardiac arrhythmias is one of the complications of the phenol peels. When it happens, the patient will develop a supraventricular tachycardia within 30 minutes, which if continues can lead to ventricular tachycardia and atrial fibrillations. Once arrhythmia is noted, the treatment should be stopped and adequate fluid therapy should be administered until the patient's rhythm is back to normal [195]. If re-epithelialization does not occur within 10 days after the treatment, those areas should be checked for the presence of infection [223]. Bacterial infection can delay wound healing and lead to scarring. In this case antibacterial therapy should be initiated. HSV infection can also occur and must be treated with 1g Valacyclovir, 3 times a day for 10 days [195]. The erythema may last longer than expected in patients with sensitive skin. The administration of topical 2.5% hydrocortisone lotions are recommended in these patients [195]. Post-inflammatory hyperpigmentation might occur in patients with Fitzpatrick skin type 3 to 6. For eliminating this, the use of glycolic acid lotion or the combination of 0.05% retinoic acid, 8% hydroquinone and hydrocortisone cream is recommended [224]. Hypopigmentation may occur by using phenol peels and this complication is irreversible.

#### *5.4.2. Dermabrasion*

##### *5.4.2.1. Introduction*

Derm-abrasion is a skin-resurfacing technique that has been around since the 1930s. It has been used for treating wrinkles, scars, and the precancerous lesions [195,225]. By performing the derm-abrasion, the epidermis and partial of the underlying dermis is mechanically removed. Usually two passes are performed, in directions perpendicular to each other. Kromeyer was the first performed derm-abrasion using a rotating burr or rasp after freezing the skin with carbon dioxide snow or ether spray [189]. Derm-abrasion is ideally performed in the face because of its high density of skin appendages. The neck has thinner dermis and less skin appendages and should be avoided because of the risk of hypertrophic scarring and depigmentation occurrence [195].

##### *5.4.2.2. Indications and contra-indications*

Its indications are similar to superficial chemical peels including boxcar and rolling acne scars, rhinophyma, scarring, tattoos, lentigines, facial rhytides, fine perioral rhytids, seboreic or actinic keratosis and removal of benign and premalignant epidermal growths. Indications for full thickness derm-abrasion include deep peri-orbital or perioral rhytids [226]. It

is also used to revise scars from trauma, skin grafts, and surgical incisions [225]. Treating hypertrophic scars and keloids with derm-abrasion is contra-indicated due to the lack of adnexal structures for epidermal regeneration. Use of isotretinoin within the recent year is also contra-indicated, due to their healing impairment which leads to keloid formation [195]. Derm-abrasion during active acne is a relative contra-indication due to its increased risk of postoperative infection [225].

#### 5.4.2.3. *Dermabradors and devices*

Many dermabradors are available for skin resurfacing, which are connected to a pneumatic or electric motor rotating handpiece. The desired speed for derm-abrasion is approximately 12,000 to 15,000 revolutions per minute. The most common dermabradors include diamond burs, serrated wheels, or wire brushes [194]. During the procedure, they must be kept in contact with the skin with a gentle pressure [225]. One of the alternative equipments that is useful for derm-abrasion of the scars is sterile, medium grade (220 grit) silicone carbide sandpaper that is wrapped around gauze [227].

#### 5.4.2.4. *Pre-operative considerations*

Any patient with the history of isotretinoin use during the past year is prone to hypertrophic scarring or keloid formation due to their delayed wound healing and should not undergo the procedure. Those patients who use blood-thinners and having bleeding disorders are prone to post-operative hyperpigmentation and if medically possible, their medication should be discontinued. Patients with the history of HSV may require prophylactic antiviral medications [225]. Patients with darker skin shades are more prone to irreversible hypopigmentation and are not good candidates for derm-abrasion [225]. Administration of tretinoin, a few weeks before the procedure is recommended due to its promotion of the wound healing process.

#### 5.4.2.5. *Pre-operative considerations*

Derm-abrasion is usually performed under local anesthesia, but sedation or general anesthesia could also be used due to the patient's pain tolerance and patient's overall health [225]. The patient's ECG, blood pressure and pulse oximetry should be monitored if sedation or general anesthesia is used. Regional nerve blocks are administered adequately before the procedure [194]. The appropriate diamond bur or wire brush is chosen and attached to the handpiece. Diamond burs abrade the skin slowly and are more conservative than wire brushes and serrated wheels [195]. The affected area is stabilized with the non-dominant hand, and the handpiece is held at a right angle to the skin with the dominant hand and by applying slow and even pressure to the skin, the dermabrader is moved across the skin in a back and forth motion for diamond burs and in one-direction motion for wire brushes [228]. When performing the derm-abrasion, the epidermal layer is removed first. Then by entering the papillary dermis, pinpoint bleedings from small capillary loops occur. By the disappearance of the pinpoint bleedings, the upper reticular dermis has been reached and small parallel strands of whitish-yellow colored collagen

are visualized. The papillary-reticular junction is the ideal endpoint of derm-abrasion and is identified by increased, confluent bleeding. No more penetration into the reticular dermis should be performed, due to the risk of scar formation [194,195,225]. The periphery of the area should be slightly feathered to blend treated and untreated areas. Protection from blood exposure and aerosolized particles must be considered during the treatment, especially for patients with a history of HIV or hepatitis.

#### *5.4.2.6. Post-operative care*

Immediately following the procedure, saline-soaked gauze moistened with dilute epinephrine is placed on the wounds to achieve hemostasis [225]. Post-operatively, the wound is cleansed daily with a wet gauze and petroleum-based products are applied several times a day to moistens the wound and keep it from crusting. Re-epithelialization time is approximately 5 to 7 days and is fully completed by day 10 to 14 [225]. Erythema is common and can persist for 2 to 3 months [195]. Patients should avoid excessive sun exposure for 6 to 12 months following the procedure to avoid hyperpigmentation. Hydroquinone can be used to treat post-inflammatory hyperpigmentation following the procedure.

#### *5.4.2.7. Complications*

Common complications include dyspigmentation, hypertrophic scarring, acne eruptions, and postoperative infections [195]. If the derm-abrasion is performed beyond the reticular dermal layer, it can lead to abnormal scarring, hypertrophic scars and keloids. It is also seen in patients with collagen disorders. Excessive sun exposure can lead to post-inflammatory hyperpigmentation and hydroquinone is administered to treat this condition [225]. Patients with Fitzpatrick skin types 3 to 6 are prone to irreversible hypopigmentation. Patients with active acne are more prone to infection. Infections should be treated with antibiotic and antiviral therapy. Patients with a history of HSV should be treated with prophylactic antivirals. The formation of Milia is a small white keratin-filled cyst, which might occur following derm-abrasion. Its treatment is incision and drainage, if it does not resolve spontaneously [225].

#### *5.4.3. Microdermabrasion*

Microdermabrasion is a less invasive and less painful skin resurfacing technique that uses an inert substance such as aluminum oxide or sodium chloride crystals to remove the superficial layers of the skin. It is used for the treatment of photo-damaged skin, hyperpigmentation, superficial rhytides, stretch marks, scars, acne scarring, and enlarged pores [225,229]. It can be performed on all Fitzpatrick skin types. The operator uses a device that mobilizes a fine stream of ablative substances on the skin with the intent of disrupting the stratum corneum. The cells at the most superficial layer are dislodged and simultaneously removed by vacuum suction [225]. Side effects include mild erythema and tenderness. These complications are treated with non-steroidal anti-inflammatory drugs.

#### 5.4.4. Laser resurfacing

##### 5.4.4.1. Introduction

Lasers are generally categorized into 2 groups: ablative and non-ablative lasers. Ablative lasers are mostly used for the treatment of photo-damaged skins, deep rhytides, solar elastoses, uncontrollable acne, acne scars, telangiectasias and actinic keratosis. These lasers ablate the outer layers of the skin to the level of the dermis and cause thermal damage to the dermis resulting in collagen remodeling and new collagen formation which leads to smoother and firmer skin [195,230,231]. Patients with Fitzpatrick skin type 1 to 4 are good candidates for ablative laser resurfacing [232]. Non-ablative lasers are less aggressive and cause minimal injury to the epidermis and their side effects are less than ablative lasers. They are effective in the treatment of mild to severe rhytides [195,230]. Fractional photo-thermolysis (FP) is a laser technology with decreased side effects and improved recovery time. FP therapy is done by delivering an ablative or non-ablative laser to the skin to create micro-thermal zones of injury. By this method the normal skin is preserved and treated area is decreased which leads to improved recovery time [195,233]. The surrounding unaffected follicular units and fibroblasts are responsible for rapid collagen remodeling and faster recovery time. FP is effective in the treatment of moderate to severe acne scarring and moderate to severe photo-aging [234].

##### 5.4.4.2. Ablative lasers

Ablative lasers include the CO<sub>2</sub> and Er:YAG devices. They cause homogenous tissue vaporization with surrounding residual thermal damage after selective absorption by intracellular water in the epidermis. Er:YAG lasers have 10 times more absorption by water than CO<sub>2</sub> lasers and are able to ablate the tissue more precisely with less residual thermal damage [235,236]. The CO<sub>2</sub> laser was first introduced in the 1980s and initially it created excessive thermal damage and led to excessive scar formation [195]. CO<sub>2</sub> laser works by delivering energy at 10,600 nm wavelength. For decreasing the residual thermal damage, the CO<sub>2</sub> is delivered at 5 J/cm<sup>2</sup> in less than 1 millisecond, which creates 20 to 30 µm of tissue ablation and 40 to 120 µm of residual thermal damage [194]. CO<sub>2</sub> lasers are able to ablate tissue of the reticular dermis, because of their hemostatic effects. The Er:YAG laser is an alternative for CO<sub>2</sub> with minimized risks. The laser beam is delivered at 2940 nm wavelength, which is close to the peak absorption of water at 3000 nm. This would limit the penetration depth and residual thermal damage and leads to less side effects and decreased healing time [195]. The energy is delivered at 0.6 to 5 J/cm<sup>2</sup> which causes 4 µm of tissue ablation and 10 to 40 µm of residual thermal damage. The ablation depth of Er:YAG lasers are limited to the papillary dermis due to their inability to coagulate blood vessels. Bleeding absorbs the laser light and prevents further penetration. Usually these two lasers are combined to minimize the side effects and maximize the benefits. After the treatment with CO<sub>2</sub> laser, Er:YAG is used to remove the coagulated tissues produced by the CO<sub>2</sub> laser, which leads to shorter healing time [195].

##### 5.4.4.3. Non-ablative lasers

Non-ablative lasers are introduced to minimize the tissue damage and healing time. These lasers are divided into three groups: infrared lasers, intense pulsed light (IPL) and visible lasers. Infrared lasers which are mostly used include the 1320 nm Nd:YAG laser, 1450 nm



diode and 1540 nm erbium-doped phosphate glass laser. These lasers only target the dermis to promote new collagen formation and rhytides improvement, and are not effective on patients with epidermal changes and severe photo-damaged skin [195]. IPL devices are not real lasers, but they have a wide spectrum range 550 to 1200 nm. They are able to target the hemoglobin, melanin and blood vessels, so they are used for the treatment of dyschromias, telangiectasias, increased vascularity and pigment changes from photo-damaged skin [195].

Visible lasers include pulsed dye laser (PDL) and pulsed 532 nm potassium titanyl phosphate laser (KTP). These lasers target the blood vessels and superficial pigmentations and are used to treat telangiectasias in photo-damaged skins [195]. Lasers have been combined with radiofrequency (RF) devices to increase the depth of the lasers penetration without increasing the ablative effects. This increased penetration depth leads to increased skin tightening and increased new collagen formation [230,237].

#### *5.4.4.4. Indications*

The indications for CO<sub>2</sub> and Er:YAG lasers include acne scarring and moderate to severe photo-aging. CO<sub>2</sub> laser is also used for the treatment of the skin laxity and deep rhytides [238,239].

#### *5.4.4.5. Technique*

Each esthetic unit is treated individually. The borders of the units should be feathered to prevent demarcation lines. Overlapping of the pulses is not recommended with CO<sub>2</sub> resurfacing [240]. Lasers could cause damage to the hair follicles, therefore protecting the hair is mandatory. The endpoint of the treatment is a visible smoothing of the rhytids. This is achieved by 1 to 4 passes with CO<sub>2</sub> laser. Between the passes, the epidermal debris should be wiped away. When using Er:YAG laser, because of its minimal residual thermal damage, the overlapping of the pulses is possible and wiping the debris between the passes is not necessary [241].

#### *5.4.4.6. Post-operative care*

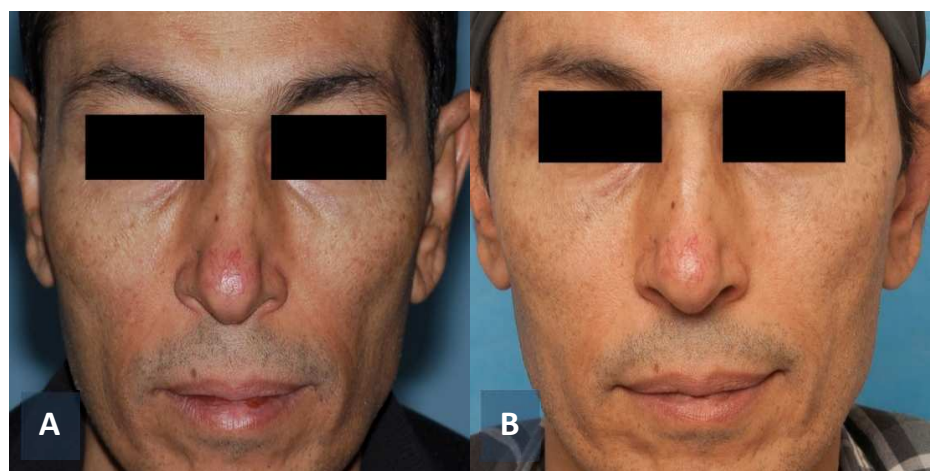The postoperative care is similar to that described for deep phenol peels. The full re-epithelialization time with laser resurfacing is approximately 7 to 10 days which is faster than with deep phenol peeling. Usually the erythema, edema and crusting occur during the first 3 to 4 days.

#### *5.4.4.7. Complications*

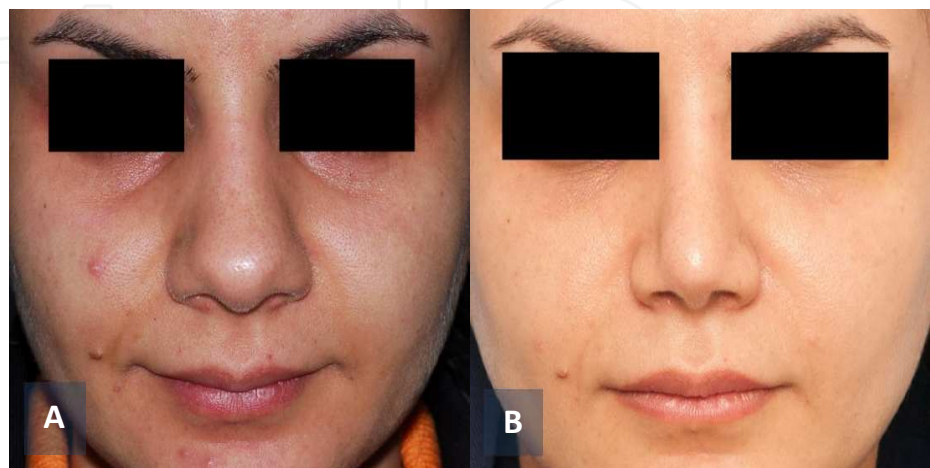
The erythema usually lasts from 1 to 4 months and may even last up to a year. The post-inflammatory hyperpigmentation is common in patients with Fitzpatrick skin type 3 to 6. Hydroquinone and retinoic acid may be used to treat this hyperpigmentation and the patients should be advised to avoid excessive sun exposure. Hypopigmentation may occur 6 to 12 months after the treatment which is irreversible. In the case of infection, antimicrobial agents should be used for treatment. Acne eruptions are common in patients with a history of acne and should be treated with standard acne treatments. The risk for scarring is higher with CO<sub>2</sub> resurfacing compared with erbium resurfacing because of the higher residual thermal damage.

5.4.5. Fractional photo-thermolysis (FP)

The traditional ablative and non-ablative lasers create a homogenous zone of thermal damage, but FP creates multiple microsomal thermal zones surrounded by normal skin with intact stratum corneum, which results in a shorter healing time [242]. Each microsomal thermal zone consists of an area within 70 to 100  $\mu\text{m}$  wide and 250 to 800  $\mu\text{m}$  deep containing necrotic debris of epidermal and dermal tissues [243]. Ablative FP devices include CO<sub>2</sub>, Er:YAG and yttrium scandium gallium garnet and they have high affinity for water molecules. Non-ablative FP devices include 1550 nm erbium doped laser, 1540 nm pulsed device, 1440 nm neodymium yttrium aluminum garnet and 1410 nm erbium fiber devices. These devices have moderate affinity for water.



**Figure 5.** A patient treated with fat and PRP injection. A, Before treatment. B, After treatment.



**Figure 6.** A patient treated with fat and PRP injection. A, Before treatment. B, After treatment.

## 6. Conclusion

The field of cosmetic surgery continues to be a rapidly changing and expanding one. Use of minimally invasive facial rejuvenation continues to increase. With the understanding of the changes that take place in aging and contribute to photo-damaged skin, technologic advances have become more science-based. Patients are aware of these changes and it has become more important than ever for surgeons to be knowledgeable about available procedures, limitations, techniques, risks and complications. Figures 5 and 6 show two patients before and after treatment.

## Author details

Farzin Sarkarat, Behnam Bohluli and Roozbeh Kahali

Department of Oral and Maxillofacial Surgery, Bouali Hospital, Islamic Azad University of Medical Sciences, Tehran, Iran

## References

- [1] Donald W. Buck II, Murad Alam, John YS Kim: Injectable fillers for facial rejuvenation: a review. *Journal of Plastic, Reconstructive & Aesthetic Surgery* (2009) 62, 11-18.
- [2] Glicenstein J. The First "Fillers", vaseline and paraffin. From miracle to disaster. *Ann Chir Plast Esthet* 2007;52: 157-61.
- [3] Narins RS, Beer K. Liquid injectable silicone: a review of its history, immunology, technical considerations, complications, and potential. *Plast Reconstr Surg* 2006;118:77S-84S.
- [4] Rapaport MJ, Vinnik C, Zarem H. Injectable silicone: cause of facial nodules, cellulites, ulceration and migration. *Aesthetic Plast Surg* 1996;20:267-76.
- [5] Arndt KA, LeBoit PE, Robinson JK, et al: What is normal skin? In White CR Jr, Bigby M, Sanguenza OP (eds): *Cutaneous Medicine and Surgery: An Integrated Program in Dermatology*, vol. 1. Philadelphia, W.B. Saunders Company, 1996 pp 3-45
- [6] Uitto J, Bernstein EF, McGrath JA. The dermis, in White CR Jr, Bigby M, Sanguenza OP (eds): *Cutaneous Medicine and Surgery: An Integrated Program in Dermatology*, vol. 1. Philadelphia, W.B. Saunders Company, 1996 pp 857-881
- [7] Bauman L: CosmoDerm/CosmoPlast (human bioengineered collagen) for the aging face. *Facial Plast Surg* 20:125-128, 2004
- [8] Murray CA, Zloty D, Warshawski L. The Evolution of soft tissue fillers in clinical practice. *Dermatol Clin* 2005;23:343-63.

- [9] Rod J. Rohrich, Ashkan Ghavami, Melissa A. Crosby: The Role of Hyaluronic Acid Fillers (Restylane) in Facial Cosmetic Surgery: Review and Technical Considerations. *Plast. Reconstr. Surg.* 120 (Suppl.): 41S-54S, 2007.
- [10] Keefe J, Wauk L, Chu S, et al. Clinical use of injectable bovine collagen: a decade of experience. *Clin Mater* 1992;9(3-4):155-62.
- [11] Joseph Niamtu III: New Lip and Wrinkle Fillers. *Oral Maxillofacial Surg Clin N Am* 17 (2005) 17 – 28.
- [12] Owens JM: Soft tissue implants and fillers. *Otolaryngol Clin N Am* 38:361-369, 2005
- [13] Eppley BL, Dadvand B. Injectable soft-tissue fillers: clinical overview. *Plast Reconstr Surg* 2006;118:98e-106e.
- [14] Baumann L, Kaufman J, Saghari S. Collagen fillers. *Dermatol Ther* 2006;19:134-40.
- [15] Devore, D. P., Hughes, E., and Scott, J. B. Effectiveness of injectable filler materials for smoothing wrinkle lines and depressed scars. *Med. Prog. Technol.* 20: 243, 1994.
- [16] Longas, M. O., Russell, C. S., and He, X. Y. Evidence for structural changes in dermatan sulfate and hyaluronic acid with aging. *Carbohydr. Res.* 159: 127, 1987.
- [17] Matarasso SL, Carruthers JD, Jewell ML, et al. Consensus recommendations for soft-tissue augmentation with nonanimal stabilized hyaluronic acid (Restylane). *Plast Reconstr Surg* 2006;117:3S-33S.
- [18] Monheit GD, Coleman KM. Hyaluronic acid fillers. *Dermatol Ther* 2006;19:141-50.
- [19] Raghu S. Athre: Facial filler agents. *Operative Techniques in Otolaryngology* (2007) 18, 243-247
- [20] Narins RS, Bowman PH: Injectable skin fillers. *Clin Plast Surg* 32: 151-162, 2005
- [21] Narins, R. S. A randomized, double-blind, multicenter comparison of the efficacy and tolerability of Restylane versus Zyplast for the correction of nasolabial folds. *Dermatol. Surg.* 29: 588, 2003.
- [22] Lemperle G, Morhenn VV, Charrier U. Human histology and persistence of various injectable filler substances for soft tissue augmentation. *Aesthetic Plast Surg* 2003;27(5):354 –66.
- [23] Rao J, Chi GC, Goldman MP: Clinical comparison between two hyaluronic acid-derived fillers in the treatment of nasolabial folds: Hylaform versus restylane. *Dermatol Surg* 31:1587-1590, 2005
- [24] Baumann L: Replacing dermal constituents lost through aging with dermal fillers. *Semin Cutan Med Surg* 23:160-166, 2004
- [25] Kaufman MR, Miller TA, Huang C, et al. Autologous fat transfer for facial recontouring: is there science behind the art? *Plast Reconstr Surg* 2007;119:2287-96.

- [26] Kanchwala SK, Holloway L, Bucky LP. Reliable soft tissue augmentation. A clinical comparison of injectable soft-tissue fillers for facial-volume augmentation. *Ann Plast Surg* 2005;55:30-5.
- [27] Vleggaar D: Facial volumetric correction with injectable poly-L-lactic acid. *Dermatol Surg* 2005;31:1511-1518
- [28] Flaharty P: Radiance. *Facial Plast Surg* 20:165-169, 2004
- [29] Sklar JA, Soren M, White MD. Radiance FN: a new soft tissue filler. *Derm Surg* 2004;30(5):764–8.
- [30] Thaler MP, Ubogly ZI: Artecoll: The Arizona experience and lessons learned. *Dermatol Surg* 31:1566-1576, 2005
- [31] Duffy DM: Liquid silicone for soft tissue augmentation. *Dermatol Surg* 31:1530-1541, 2005
- [32] Teimourian B. Blindness following fat injections. *Plast Reconstr Surg* 1988;82(2):361.
- [33] Castillo GD. Management of blindness in the practice of cosmetic surgery. *Otolaryngol Head Neck Surg* 1989;100(6):559–62.
- [34] Egido JA, Arroyo R, Marcos A, et al. Middle cerebral artery embolism and unilateral visual loss after autologous fat injection into the glabellar area. *Stroke* 1993; 24:615–6.
- [35] Gottfried Lemperle, Peter P. Rullan, Nelly Gauthier-Hazan: Avoiding and Treating Dermal Filler Complications. *Plast. Reconstr. Surg.* 118 (Suppl.): 92S-107S, 2006.
- [36] Niamtu J. Local anesthetic blocks of the head and neck for cosmetic facial surgery. Part I. A review of basic sensory neuroanatomy. *Cosmet Dermatol* 2004;17: 515–22.
- [37] Larrabee WF, Makielski KH, editors. *Surgical anatomy of the face*. New York, NY: Raven Press; 1993.
- [38] Lam SM, Azizzadeh B, Graivier M. Injectable poly-L-Lactic acid (Sculptra): technical considerations in soft-tissue contouring. *Plast Reconstr Surg* 2006;118:55S-e63S.
- [39] Brody HJ: Use of hyaluronidase in the treatment of granulomatous acid reactions or unwanted hyaluronic acid placement. *Dermatol Surg* 31:893-897, 2005
- [40] Hönig JF, Brink U, Korabiowski M: Severe granulomatous allergic tissue reaction after hyaluronic acid injection in the treatment of facial lines and its surgical correction. *J Craniofac Surg* 14:197-200, 2003
- [41] Johl SS, Burgett RA. Dermal filler agents: a practical review. *Curr Opin Ophthalmol* 2006;17:471-9.
- [42] Honig JF, Brink U, Korabiowski M. Severe granulomatous allergic tissue reaction after hyaluronic acid injection in the treatment of facial lines and its surgical correction. *J Craniofac Surg* 2003;14:197-200.



- [43] Zimmerman U, Clerici TJ. The Histologic aspects of fillers complications. *Semin Cutan Med Surg* 2004;23:241-50.
- [44] Bucky LP, Kanchwala SK. The role of autologous fat and alternative fillers in the aging face. *Plast Reconstr Surg*. 2007; 120(Suppl):89S–97S.
- [45] Coleman SR. Structural fat grafts: The ideal filler? *Clin Plast Surg*. 2001;28:111–119.
- [46] Kanchwala SK, Holloway L, Bucky LP. Reliable soft tissue augmentation: A clinical comparison of injectable soft-tissue fillers for facial-volume augmentation. *Ann Plast Surg*. 2005; 55:30–35; discussion 35.
- [47] Guerrerosantos J: Long-term outcome of autologous fat transplantation in aesthetic facial recontouring: sixteen years of experience with 1936 cases. *Clin Plast Surg* 27: 515e543, 2000
- [48] Zocchi ML, Zuliani F. Bicompartmental breast lipostructuring. *Aesthetic Plast Surg*. 2008;32:313–328.
- [49] Wolf GA, Gallego S, Patro'n AS, et al. Magnetic resonance imaging assessment of gluteal fat grafts. *Aesthetic Plast Surg*. 2006;30:460–468.
- [50] Kaufman MR, Miller TA, Huang C, Roostaien J, Wasson KL, Ashley RK, et al: Autologous fat transfer for facial recontouring: is there science behind the art? *Plast Reconstr Surg* 119: 2287-2296, 2007
- [51] Calabria R: Fat grafting: fact or fiction? *Aesthet Surg J* 25: 55, 2005
- [52] Miller, C. G. *Cannula Implants and Review of Implantation Techniques in Esthetic Surgery*. Chicago: Oak Press, 1926.
- [53] Matthew R. Kaufman, Timothy A. Miller, Catherine Huang, Jason Roostaien, Kristy L. Wasson, Rebekah K. Ashley, James P. Bradley: Autologous Fat Transfer for Facial Recontouring: Is There Science behind the Art? *Plast. Reconstr. Surg*. 119: 2287-2296, 2007.
- [54] R. Guijarro-Martínez, L. Miragall Alba, M. Marqués Mateo, M. Puche Torres, J. Vicente Pascual Gil: Autologous fat transfer to the cranio-maxillofacial region: Updates and controversies. *Journal of Cranio-Maxillo-Facial Surgery* 39 (2011) 359-363.
- [55] Neuhof, H. *The Transplantation of Tissues*. New York: D. Appleton & Co., 1923.
- [56] Peer, L. A. The neglected free fat graft. *Plast. Reconstr. Surg*. 18: 233, 1956.
- [57] Coleman, S. R. Facial recontouring with lipostructure. *Clin. Plast. Surg*. 24: 347, 1997.
- [58] Rohrich RJ, Sorokin ES, Brown SA: In search of improved fat transfer viability: a quantitative analysis of the role of centrifugation and harvest site. *Plast Reconstr Surg* 113: 391-395, 2004
- [59] Samuel M. Lam, Robert A. Glasgold, Mark J. Glasgold: Fat Harvesting Techniques for Facial Fat Transfer. *Facial Plast Surg* 2010;26:356–361.

- [60] Moore JH Jr, Kolaczynski JW, Morales LM, et al. Viability of fat obtained by syringe suction lipectomy: Effects of local anesthesia with lidocaine. *Aesthetic Plast Surg.* 1995;19:335–339.
- [61] Shoshani O, Berger J, Fodor L, et al. The effect of lidocaine and adrenaline on the viability of injected adipose tissue: An experimental study in nude mice. *J Drugs Dermatol.* 2005;4: 311–316.
- [62] Kim IH, Yang JD, Lee DG, Chung HY, Cho BC. Evaluation of centrifugation technique and effect of epinephrine on fat cell viability in autologous fat injection. *Aesthet Surg J.* 2009; 29:35–39.
- [63] Keck M, Janke J, Ueberreiter K. Viability of preadipocytes in vitro: The influence of local anesthetics and pH. *Dermatol Surg.* 2009;35:1251–1257.
- [64] Nordstrom, R. E. A. “Spaghetti” fat grafting: A new technique. *Plast. Reconstr. Surg.* 99: 917, 1997.
- [65] Cook, T., Nakra, T., Shorr, N., et al. Facial recontouring with autogenous fat. *Facial Plast. Surg.* 20: 145, 2004.
- [66] Tzikas, T. L. Lipografting: Autologous fat grafting for total facial rejuvenation. *Facial Plast. Surg.* 20: 135, 2004.
- [67] Rohrich RJ, Morales DE, Krueger JE, et al. Comparative lipoplasty analysis of in vivo-treated adipose tissue. *Plast Reconstr Surg.* 2000;105:2152–2158; discussion 2159–2160.
- [68] Shiffman MA, Mirrafati S. Fat transfer techniques: The effect of harvest and transfer methods on adipocyte viability and review of the literature. *Dermatol Surg.* 2001;27:819–826.
- [69] Leong DT, Hutmacher DW, Chew FT, Lim TC. Viability and adipogenic potential of human adipose tissue processed cell population obtained from pump-assisted and syringe-assisted liposuction. *J Dermatol Sci.* 2005;37:169–176.
- [70] Ozsoy Z, Kul Z, Bilir A. The role of cannula diameter in improved adipocyte viability: A quantitative analysis. *Aesthet Surg J.* 2006;26:287–289.
- [71] Erdim M, Tezel E, Numanoglu A, Sav A. The effects of the size of liposuction cannula on adipocyte survival and the optimum temperature for fat graft storage: An experimental study. *J Plast Reconstr Aesthet Surg.* 2009;62:1210–1214.
- [72] Pu LL, Coleman SR, Cui X, Ferguson RE Jr, Vasconez HC. Autologous fat grafts harvested and refined by the Coleman technique: A comparative study. *Plast Reconstr Surg.* 2008; 122:932–937.
- [73] Nguyen A, Pasyk KA, Bouvier TN, Hassett CA, Argenta LC: Comparative study of survival of autologous adipose tissue taken and transplanted by different techniques. *Plast Reconstr Surg* 85: 378-386, 1990

- [74] Pu LL, Cui X, Fink BF, Cibull ML, Gao D. The viability of fatty tissues within adipose aspirates after conventional liposuction: A comprehensive study. *Ann Plast Surg.* 2008;54:288-292; discussion 292.
- [75] Coleman SR: Structural fat grafting: more than a permanent filler. *Plast Reconstr Surg* 118: 108-120, 2006
- [76] Butterwick KJ. Lipoaugmentation for aging hands: A comparison of the longevity and aesthetic results of centrifuged versus noncentrifuged fat. *Dermatol Surg.* 2002;28:987-991.
- [77] Khater R, Atanassova P, Anastassov Y, Pellerin P, Martinot-Duquennoy V. Clinical and experimental study of autologous fat grafting after processing by centrifugation and serum lavage. *Aesthetic Plast Surg.* 2009;33:37-43.
- [78] Ferraro GA, De Francesco F, Tirino V, et al. Effects of a new centrifugation method on adipose cell viability for autologous fat grafting. *Aesthetic Plast Surg.* 2011;35:341-348.
- [79] Botti G, Pascali M, Botti C, Bodog F, Cervelli V. A clinical trial in facial fat grafting: Filtered and washed versus centrifuged fat. *Plast Reconstr Surg.* 2011;127:2464-2473.
- [80] Boschert MT, Beckert BW, Puckett CL, Concannon MJ. Analysis of lipocyte viability after liposuction. *Plast Reconstr Surg.* 2002;109:761-765; discussion 766-767.
- [81] Xie Y, Zheng D, Li Q, Chen H, Lei H, Pu LL. The effect of centrifugation on viability of fat grafts: An evaluation with the glucose transport test. *J Plast Reconstr Aesthet Surg.* 2010;63: 482-487.
- [82] Ramon, Y., Shoshani, O., Peled, I. J., et al. Enhancing the take of injected adipose tissue by a simple method for concentrating fat cells. *Plast. Reconstr. Surg.* 115: 197, 2005.
- [83] Karacalar, A., Orak, I., Kaplan, S., et al. No touch technique for autologous fat harvesting. *Aesthetic Plast. Surg.* 28: 158, 2004.
- [84] Marques, A., Brenda, E., Saldiva, P. H., et al. Autologous fat grafts: A quantitative and morphometric study in rabbits. *Scand. J. Plast. Reconstr. Surg. Hand Surg.* 28: 241, 1994.
- [85] Huss, F. R., and Kratz, G. Adipose tissue processed for lipoinjection shows increased cellular survival in vitro when tissue engineering principles are applied. *Scand. J. Plast. Reconstr. Surg. Hand Surg.* 36: 166, 2002.
- [86] Har-Shai, Y., Lindenbaum, E. S., Gamliel-Lazarovich, A., et al. An integrated approach for increasing the survival of autologous fat grafts in the treatment of contour defects. *Plast. Reconstr. Surg.* 104: 945, 1999.
- [87] Yuksel, E., Weinfeld, A., Cleek, R., et al. Increased free fat-graft survival with the long-term, local delivery of insulin, insulin-like growth factor-I, and basic fibroblast growth factor by PLGA/PEG microspheres. *Plast. Reconstr. Surg.* 105: 1712, 2000.

- [88] Butterwick, K. J., and Lack, E. A. Facial volume restoration with the fat autograft muscle injection technique. *Dermatol. Surg.* 29: 1019, 2003.
- [89] Guerrerosantos, J. Long-term outcome of autologous fat transplantation in aesthetic facial recontouring. *Clin. Plast. Surg.* 27: 515, 2000.
- [90] Trepsat, F. Periorbital rejuvenation combining fat grafting and blepharoplasties. *Aesthetic Plast. Surg.* 27: 243, 2003.
- [91] Fagrell, D., Enestrom, S., Berggren, A., et al. Fat cylinder transplantation: An experimental comparative study of three different kinds of fat transplants. *Plast. Reconstr. Surg.* 98: 90, 1996.
- [92] Lidagoster, M. I., Cinelli, P. B., and Levee, E. M. Comparison of autologous fat transfer in fresh, refrigerated, and frozen specimens: An animal model. *Ann. Plast. Surg.* 44: 512, 2000.
- [93] Butterwick KJ, Bevin AA, Iyer S. Fat transplantation using fresh versus frozen fat: A side-by-side two-hand comparison pilot study. *Dermatol Surg.* 2006;32:640–644.
- [94] Aboudib, J. H. C., Cardoso de Castro, C., and Gradel, J. Hand rejuvenescence by fat filling. *Ann. Plast. Surg.* 28: 559, 1992.
- [95] Aygit, A. C., Sarikaya, A., Doganay, L., et al. The fate of intramuscularly injected fat grafts: An experimental study in rabbits. *Aesthetic Plast. Surg.* 28: 334, 2004.
- [96] Feinendegen, D. L., Baumgartner, R. W., Vuadens, P., et al. Autologous fat injection for soft tissue augmentation in the face: A safe procedure? *Aesthetic Plast. Surg.* 22: 163, 1998.
- [97] Latoni JD, Marshall DM, Wolfe SA: Overgrowth of fat autotransplanted for correction of localized steroid-induced atrophy. *Plast Reconstr Surg* 106: 1566-1569, 2000
- [98] Miller JJ, Popp JC: Fat hypertrophy after autologous fat transfer. *Ophthal Plast Reconstr Surg* 18: 228-231, 2002
- [99] Guaraldi G, De Fazio D, Orlando G, Murri R, Wu A, Guaraldi P, et al: Facial lipohypertrophy in HIV-infected subjects who underwent autologous fat tissue transplantation. *Clin Infect Dis* 40: 13-15, 2005
- [100] Dreizen NG, Framm L: Sudden unilateral visual loss after autologous fat injection into the glabellar area. *Am J Ophthalmol* 107: 85-87, 1989
- [101] Egido JA, Arroyo R, Marcos A, Jiménez-Alfaro I: Middle cerebral artery embolism and unilateral visual loss after autologous fat injection into the glabellar area. *Stroke* 1993: 615-616, 1993
- [102] Feinendegen DL, Baumgartner RW, Vuadens P, Schroth G, Mattle HP, Regli F, et al: Autologous fat injection for soft tissue augmentation in the face: a safe procedure? *Aesthetic Plast Surg* 22: 163-167, 1998

- [103] Yoon SS, Chang DI, Chung KC: Acute fatal stroke immediately following autologous fat injection into the face. *Neurology* 61: 1151-1152, 2003
- [104] Erbguth FJ. Historical notes on botulism, *Clostridium botulinum*, botulinum toxin and the idea of the therapeutic use of the toxin. *Mov Disord* 2004;19:S2-S6.
- [105] Erbguth FJ. From poison to remedy: the chequered history of botulinum toxin. *J Neurol Transm* 2008; 115: 559-565.
- [106] Ting PT, Freiman A. The story of *Clostridium botulinum*: from food poisoning to Botox. *Clin Med* 2004; 4: 258-261.
- [107] Cherington M. Botulism: update and review. *Semin Neurol* 2004; 24: 155-163.
- [108] MG Berry, Jan J. Stanek: Botulinum neurotoxin A: A review. *Journal of Plastic, Reconstructive & Aesthetic Surgery* (2012) xx, 1-9
- [109] Burgen ASV, Dickens F, Zatman LJ. The action of botulinum toxin on the neuro-muscular junction. *J Physiol* 1949;109: 10-24.
- [110] Scott AB, Rosenbaum A, Collins CC. Pharmacologic weakening of extraocular muscles. *Invest Ophthalmol* 1973; 12: 924-927.
- [111] Scott AB. Botulinum toxin injection of eye muscles to correct strabismus. *Trans Am Ophthalmol Soc* 1981; 79: 734-770.
- [112] Scott AB, Kennedy RA, Stubbs HA. Botulinum toxin A injection as a treatment for blepharospasm. *Arch Ophthalmol* 1985; 103:347-50.
- [113] Carruthers J, Carruthers A. Treatment of glabellar frown lines with C. botulinum-A exotoxin. *J Dermatol Surg Oncol* 1992; 18: 17-21.
- [114] Benedetto AV. The cosmetic uses of Botulinum toxin type A. *Int J Dermatol* 1999; 38: 641-655.
- [115] Blitzler A, Brin MF, Keen MS, Aviv JE. Botulinum toxin for the treatment of hyperfunctional lines of the face. *Arch Otolaryngol Head Neck Surg* 1993; 119: 1018-1022.
- [116] Carruthers A, Carruthers J. History of the cosmetic use of Botulinum A exotoxin. *Dermatol Surg* 1998; 24: 1168-1170.
- [117] Niamtu J. Aesthetic uses of botulinum toxin A. *J Oral Maxillofac Surg* 1999; 57: 1228-1233.
- [118] Niamtu J. Cosmetic facial surgery. *Oral Maxillofac Surg Clin North Am* 2000; 12: 595.
- [119] Osako M, Keltner JL. Botulinum A toxin (Oculinum) in ophthalmology. *Surv Ophthalmol* 1991;36:28-46.
- [120] Smith LDS. The occurrence of *Clostridium botulinum* and *Clostridium tetani* in the soil of the United States. *Health Lab Sci* 1978; 15: 74-80.
- [121] Flynn TC. Update on botulinum toxin. *Semin Cutan Med Surg* 2006; 25: 115-121.



- [122] O. W. Majid: Clinical use of botulinum toxins in oral and maxillofacial surgery. *Int. J. Oral Maxillofac. Surg.* 2010; 39: 197–207.
- [123] Hatheway CL. Clostridium botulinum and other clostridia that produce botulinum neurotoxins. In: Hauschild AHW, Dodds KL, eds: *Clostridium botulinum Ecology and Control in Foods*. New York, NY: Marcel Dekker, Inc 1992: 3–10.
- [124] Halpern JL, Smith LA, Seamon KB, Groover KA, Habig WH. Sequence homology between tetanus and botulinum toxins detected by an antipeptide antibody. *Infect Immun* 1989; 57: 18–22.
- [125] Huang W, Foster JA, Rogachefsky AS. Pharmacology of botulinum toxin. *J Am Acad Dermatol* 2000; 43(2 Pt 1):249–259.
- [126] Setlow P. I will survive: DNA protection in bacterial spores. *Trends Microbiol* 2007;15:172-80.
- [127] Franz DR, Pitt LM, Clayton MA, Hanes MA, Rose KJ. Efficacy of prophylactic and therapeutic administration of antitoxin for inhalation botulism. In: DasGupta BR, ed: *Botulinum and Tetanus Neurotoxins: Neurotransmission and Biomedical Aspects*. New York, NY: Plenum Press 1993: 473–476.
- [128] Herrero BA, Ecklung AE, Streett CS, Ford DF, King JK. Experimental botulism in monkeys Aclinical pathological study. *Exp Mol Pathol* 1967; 6: 84–95.
- [129] Cartee TV, Monheit GD. An overview of botulinum toxins: past, present, and future. *Clin Plast Surg* 2011;38:409-26.
- [130] Brin MF. Botulinum toxin therapy: basic science and overview of other therapeutic applications. In: Blitzer A, ed: *Management of facial lines and wrinkles*. Philadelphia: Lippincott, Williams and Wilkins 2000 p : 279–302.
- [131] Klein AW. Dilution and storage of botulinum toxin. *Dermatol Surg* 1998; 24: 1179–1180.
- [132] Koriazova LK, Montal M. Translocation of botulinum neurotoxin light chain protease through the heavy chain channel. *Nat Struct Biol* 2003;10:13-8.
- [133] Angaut-Petit D, Molgo´ J, Comella JX, Faille L, Tabti N. Terminal sprouting in mouse neuromuscular junctions poisoned with botulinum type A toxin: morphological and electrophysiological features. *Neuroscience* 1990;37:799-808.
- [134] Schiavo G, Matteoli M, Montecucco C. Neurotoxins affecting neuroexocytosis. *Physiol Rev* 2000;80:717-66.
- [135] Sanders DB, Massey EW, Buckley EG. Botulinum toxin for blepharospasm: single-fibre EMG studies. *Neurology* 1986;36: 545-7.
- [136] Benjamin A. Bassichis: *Cosmetic use of botulinum toxin in the upper face. Operative Techniques in Otolaryngology* (2007) 18, 248-253.

- [137] G. W. C. Jaspers, J. Pijpe, J. Jansma: The use of botulinum toxin type A in cosmetic facial procedures. *Int. J. Oral Maxillofac. Surg.* 2011; 40: 127–133.
- [138] de Paiva A, Meunier FA, Molgo J, Aoki KR, Dolly JO. Functional repair of motor endplates after botulinum neurotoxin type A poisoning: biphasic switch of synaptic activity between nerve sprouts and their parent terminals. *Proc Natl Acad Sci USA* 1999;96:3200-5.
- [139] Blitzer A, Sulica L. Botulinum toxin: basic science and clinical uses in otolaryngology. *Laryngoscope* 2001; 111: 218–226.
- [140] Shaari CM. Quantifying the spread of botulinum toxin through muscle fascia. *Laryngoscope* 1991; 101: 960–963.
- [141] Matarasso SL. Comparison of botulinum toxin types A and B: A bilateral and double-blind randomized evaluation in the treatment of canthal rhytides. *Dermatol Surg* 2003; 29: 7–13.
- [142] Jost Wh. Blumel J, Grafe S. Botulinum neurotoxin type A free of complexing proteins (XEOMIN) in focal dystonia. *Drugs* 2007; 67: 669–683.
- [143] Freeman SR, Cohen JL. New Neurotoxins on the Horizon. *Aesthetic Surg J* 2008; 28: 325–330.
- [144] DRESSLER D, MANDER GJ, FINK K. Equivalent potency of Xeomin and BOTOX. *Abstracts Toxins* 2008/Toxicon 51: 10.
- [145] Tang X, Wan X. Comparison of Botox with a Chinese type A botulinum toxin. *Chin Med J (Engl)* 2000; 113: 794–798.
- [146] Ramirez AL, Reeck J, Maas CS. Botulinum toxin type B (MyoBloc) in the management of hyperkinetic facial lines. *Otolaryngol Head Neck Surg* 2002; 126: 459–467.
- [147] Alster T, Lupton J. Botulinum toxin type B for dynamic glabellar rhytides refractory to botulinum toxin type A. *Dermatol Surg* 2003; 29: 516–518.
- [148] Baumann L, Stezinger A, Vujevich J, Halem M, Bryde J, Black L. A double-blinded, randomized, placebocontrolled pilot study of the safety and efficacy of Myobloc (botulinum toxin type B)-purified neurotoxin complex for the treatment of crow's feet: A double-blinded, placebo- controlled trial. *Dermatol Surg* 2003; 29: 508–515.
- [149] Lew MF, Brashear A, Factor S. The safety and efficacy of botulinum toxin type B in the treatment of patients with cervical dystonia: Summary of three controlled clinical trials. *Neurology* 2000; 55(12 Suppl 5):S29–S35.
- [150] Lowe NJ, Yamauchi PS, Lask GP, Patnaik R, Moore D. Botulinum toxins types A and B for brow furrows: Preliminary experiences with type B toxin dosing. *J Cosmet Laser Ther* 2002; 4: 15–18.
- [151] Flynn TC. Myobloc. *Dermatol Clin* 2004; 22: 207–211.

- [152] Flynn TC, Clark RE. Botulinum toxin type B (MYOBLOC) versus botulinum toxin type A (BOTOX) frontalis study: rate of onset and radius of diffusion. *Dermatol Surg* 2003; 29: 519–522.
- [153] Guerrissi J, Sarkissian P: Local injection into mimetic muscles of botulinum toxin A for the treatment of facial lines. *Ann Plast Surg* 39:447-453, 1997
- [154] Blitzer A, Binder WJ, Aviv JE, et al: The management of hyperfunctional facial lines with botulinum toxin. A collaborative study of 210 injection sites in 162 patients. *Arch Otolaryngol Head Neck Surg* 123:389-392, 1997
- [155] Fagien S: Botox for the treatment of dynamic and hyperkinetic facial lines and furrows: Adjunctive use in facial aesthetic surgery. *Plast Reconstr Surg* 103:701-713, 1999
- [156] Carruthers JA, Lowe NJ, Menter MA, et al: A multicentre, doubleblind, randomized, placebo-controlled study of efficacy and safety of botulinum toxin type A in the treatment of glabellar lines. *J Am Acad Dermatol* 46:840-849, 2002
- [157] Borodic G. Immunologic resistance after repeated botulinum toxin type a injections for facial rhytides. *Ophthal Plast Reconstr Surg* 2006; 22: 239–240.
- [158] Pribitkin EA, Greco TM, Goode RL, et al: Patient selection in the treatment of glabellar wrinkles with botulinum toxin type A injection. *Arch Otolaryngol Head Neck Surg* 123:321-326, 1997
- [159] Hexsel D, Rutowitsch MS, de Castro LC, do Prado DZ, Lima MM. Blind multicenter study of the efficacy and safety of injections of a commercial preparation of botulinum toxin type A reconstituted up to 15 days before injection. *Dermatol Surg* 2009; 35: 933–939.
- [160] Hexsal DM, de Almeida AT, Rutowitsch M, et al: Multicenter, doubleblind study of the efficacy of injections with botulinum toxin type A reconstituted up to six consecutive weeks before application. *Dermatol Surg* 29:523-529, 2003
- [161] Carruthers A, Carruthers J, Cohen J. Dilution volume of botulinum toxin type A for the treatment of glabellar rhytides: Does it matter? *Dermatol Surg* Volume 33:S97, 2007
- [162] Carruthers A, Carruthers J: Prospective, double-blind, randomized, parallel-group, dose-ranging study of botulinum toxin type A in men with glabellar rhytids. *Dermatol Surg* 31:1297-1303, 2005
- [163] Carruthers J, Fagien S, Matarasso SL, et al: Consensus recommendations on the use of botulinum toxin type A in facial aesthetics. *Plast Reconstr Surg* 114:1S-22S, 2004
- [164] Carruthers A, Carruthers J, Flynn TC, Leong MS. Dose-finding, safety, and tolerability study of botulinum toxin type B for the treatment of hyperfunctional glabellar lines. *Dermatol Surg* 2007; 33: S60–S68.

- [165] Carruthers A, Carruthers J, Said S. Dose-ranging study of botulinum toxin type A in the treatment of glabellar rhytids in females. *Dermatol Surg* 2005; 31: 414–422.
- [166] Niamtu J, Campbell RL. The anesthetic skin patch for topical cutaneous anesthesia. *J Oral Maxillofac Surg* 1984; 42: 839–840.
- [167] Carruthers J, Carruthers A: The use of botulinum toxin type A in the upper face. *Facial Plast Surg Clin North Am*. 2006 Aug;14(3):253-60.
- [168] Hegedus F, Diecidue R, Taub D, Nyirady J. Non-surgical treatment modalities of facial photodamage: practical knowledge for the oral and maxillofacial professional. *Int J Oral Maxillofac Surg* 2006; 35: 389–398.
- [169] Carruthers A, Carruthers J. Eyebrow height after botulinum toxin type A to the glabella. *Dermatol Surg* 2007; 3: S26–S31.
- [170] Fagien S, Carruthers JD. A comprehensive review of patient-reported satisfaction with botulinum toxin type a for aesthetic procedures. *Plast Reconstr Surg* 2008; 122: 1915–1925.
- [171] Dayan SH, Bassichis BA: Evaluation of the patient for cosmetic Botox injections. *Facial Plast Surg Clin North Am* 11:349-358, 2003 (review)
- [172] Spencer JM, Gordon M, Goldberg DJ: Botulinum B treatment of the glabellar and frontalis regions: A dose response analysis. *J Cosmet Laser Ther* 4:19-23, 2002
- [173] Ahn MS, Catten M, Maas CS. Temporal brow lift using botulinum toxin A. *Plast Reconstr Surg* 105:1129-1135; discussion 1136-1139, 2000
- [174] Huilgo SC, Carruthers A, Carruthers JD: Raising eyebrows with botulinum toxin. *Dermatol Surg* 25:373-375, 1999
- [175] Carruthers A, Carruthers J: Botulinum toxin type A: History and current cosmetic use in the upper face. *Semin Cutan Med Surg* 20:71-84, 2001
- [176] Carruthers A, Carruthers J, Cohen J. A prospective, double-blind, randomized, parallel-group, dose-ranging study of botulinum toxin type a in female subjects with horizontal forehead rhytides. *Dermatol Surg* 2003; 29: 461–467.
- [177] Fagien S, Brandt FS: Primary and adjunctive use of botulinum toxin type A (Botox) in facial aesthetic surgery: Beyond the glabella. *Clin Plast Surg* 28:127-148, 2001
- [178] Coroneo MT, Rosenberg ML, Cheung LM. Ocular effects of cosmetic products and procedures. *Ocul Surf* 2006; 4: 94–102.
- [179] Carruthers J, Carruthers A: BOTOX use in the mid and lower face and neck. *Semin Cutan Med Surg* 20:85-92, 2001
- [180] Matarasso SL, Matarasso A: Treatment guidelines for botulinum toxin type A for the periorcular region and a report on partial upper lip ptosis following injections to the lateral canthal rhytids. *Plast Reconstr Surg* 108:208-214; discussion 215-217, 2001

- [181] Balikian RV, Zimble MS: Primary and adjunctive uses of Botulinum Toxin Type A in the periorbital region. *Facial Plast Surg Clin North Am* 13:583-590, 2005 (review)
- [182] CARRUTHERS A: Facial aesthetic enhancement educational initiative. Chicago, IL, Faculty Training, July 2001; 13-15.
- [183] Bentsianov B, Francis A, Blitzer A. Botulinum toxin treatment of temporomandibular disorders, masseteric hypertrophy, and cosmetic masseter reduction. *Oper Tech Otolaryngol Head Neck Surg* 2004; 15: 110–113.
- [184] Vartanian AJ, Dayan SH: Complications of botulinum toxin A use in facial rejuvenation *Facial Plast Surg Clin North Am* 13:1-10, 2005 (review)
- [185] Brin MF, Tl Boodhoo, Pogoda JM, et al. Safety and tolerability of onabotulinumtoxinA in the treatment of facial lines: a metaanalysis of individual patient data from global clinical registration studies in 1678 participants. *J Am Acad Dermatol* 2009; 61:961-70.
- [186] Hsu TSJ, Dover JS, Arndt KA: Effect of volume and concentration on the diffusion of botulinum exotoxin A. *Arch Dermatol* 140:1351-1354, 2004
- [187] Wollina U, Konrad H. Managing adverse events associated with botulinum toxin type A: a focus on cosmetic procedures. *Am J Clin Dermatol* 2005; 6: 141–150.
- [188] McKee GM, Karp FL: The treatment of postacne scars with phenol. *Br J Dermatol* 64:456, 1952
- [189] Kromayer E: *The Cosmetic Treatment of Skin Complaints*. New York, Oxford University Press, 1930 (English Translation of 2nd German Edition, 1929)
- [190] Baker TJ: The ablation of rhytides by chemical means. *J Fla Med Assoc* 47:451-454, 1961
- [191] Anderson RR, Parrish RR: Selective photothermolysis: Precise microsurgery by selective absorption of pulsed radiation. *Science* 220:524-527, 1983
- [192] Gartner LP, Hiatt JL. *Color textbook of histology*. 2nd edition. Baltimore (MD): Saunders; 2001.
- [193] Jacob CI, Dover JS, Kaminer MS: Acne scarring: A classification system and review of treatment options. *J Am Acad Dermatol* 45:109-117, 2001
- [194] Naga B. Meduri: Facial resurfacing: An overview. *Operative Techniques in Otolaryngology* (2007) 18, 172-180
- [195] Mangat DS, Tansavatdi K, Garlich P: Current chemical peels and other resurfacing techniques. *Facial Plast Surg*. 2011 Feb;27(1):35-49. Epub 2011 Jan 18.
- [196] Brody HJ. Complications of chemical peeling. *J Dermatol Surg Oncol* 1989;15:1010–1019



- [197] Sadick NS: Overview of complications of nonsurgical facial rejuvenation procedures. *Clin Plast Surg* 28:163-176, 2001
- [198] Popp C, Kligman AM, Stoudemayer TJ. Pretreatment of photoaged forearm skin with topical tretinoin accelerates healing of full-thickness wounds. *Br J Dermatol* 1995;132: 46–53
- [199] Vagotis FL, Brundage SR. Histologic study of dermabrasion and chemical peel in an animal model after pretreatment with Retin-A. *Aesthetic Plast Surg* 1995;19:243–246
- [200] Kim IH, Kim HK, Kye YC. Effects of tretinoin pretreatment on TCA chemical peel in guinea pig skin. *J Korean Med Sci* 1996;11:335–341
- [201] Tung RC, Bergfeld WF, Vidimos AT, Remzi BK. alpha-Hydroxy acid-based cosmetic procedures: Guidelines for patient management. *Am J Clin Dermatol*. 2000;1:81–88.
- [202] Herbig K, Trussler AP, Khosla RK, Rohrich RJ. Combination Jessner's solution and trichloroacetic acid chemical peel: Technique and outcomes. *Plast Reconstr Surg*. 2009; 124:955–964.
- [203] Rohrich RJ, Herbig KS. The role of modified Jessner's solution with 35% trichloroacetic acid peel. *Plast Reconstr Surg*. 2009;124:965–966.
- [204] Manuskiatti W, Fitzpatrick RE, Goldman MP: Prophylactic antibiotics in patients undergoing laser resurfacing of the skin. *J Am Acad Dermatol* 40:77-84, 1999
- [205] Sabini P: Classifying, diagnosing, and treating the complications of resurfacing the facial skin. *Facial Plast Surg Clin N Am* 12:357-361, 2004
- [206] Fischer TC, Perosino E, Poli F, Viero MS, Dreno B; Cosmetic Dermatology European Expert Group. Chemical peels in aesthetic dermatology: An update 2009. *J Eur Acad Dermatol Venereol*. 2010;24:281–292.
- [207] Rohrich RJ, Hollier LH. Chemical peels in plastic surgery. *West J Med*. 1995;162:538–539.
- [208] Brody HJ, Hailey CW: Medium depth chemical peeling. *J Dermatol Surg Oncol* 12:1268-75, 1989
- [209] Kligman D, Kligman AM. Salicylic acid peels for the treatment of photoaging. *Dermatol Surg*. 1998;24:325–328.
- [210] Van Scott EJ, Yu RJ. Alpha hydroxy acids: procedures for use in clinical practice. *Cutis* 1989;43:222–228
- [211] Perkins SW, Castellano R: Use of combined modality for maximal resurfacing. *Facial Plast Surg Clin N Am* 12:323-337, 2004
- [212] Nguyen AT, Ahmad J, Fagien S, Rohrich RJ: Cosmetic medicine: facial resurfacing and injectables. *Plast Reconstr Surg*. 2012 Jan;129(1):142e-153e.

- [213] Brody HJ. Variations and comparisons in medium-depth chemical peeling. *J Dermatol Surg Oncol* 1989;15:953–963
- [214] Coleman WP III, Futrell JM. The glycolic acid trichloroacetic acid peel. *J Dermatol Surg Oncol* 1994;20:76–80
- [215] Tse Y, Ostad A, Lee HS, et al: A clinical and histologic evaluation of two medium-depth peels: Glycolic acid versus Jessner's trichloroacetic acid. *Dermatol Surg* 22:781-786, 1996
- [216] Asken S: Unoccluded Baker-Gordon phenol peels—Review and update. *J Dermatol Surg Oncol* 15:9, 1989
- [217] Monheit GD. Advances in chemical peeling. *Facial Plast Surg Clin North Am* 1994;2:5–9
- [218] Stuzin JM, Baker TJ, Gordon HL. Chemical peel: A change in the routine. *Ann Plast Surg*. 1989;23:166–169.
- [219] Roy D: Ablative Facial Resurfacing. *Dermatol Clin* 23:549-559, 2005
- [220] Hetter GP. An examination of the phenol-croton oil peel: Part II. The lay peelers and their croton oil formulas. *Plast Reconstr Surg*. 2000;105:240–248; discussion 249–251.
- [221] Vermeer BJ, Gilchrist BA. Cosmeceuticals: A proposal for rational definition, evaluation, and regulation. *Arch Dermatol*. 1996;132:337–340.
- [222] Monheit GD. Medium-depth chemical peels. *Dermatol Clin* 2001;19:413–425, vii
- [223] Szachowicz EH, Wright WK. Delayed healing after full-face chemical peels. *Facial Plast Surg* 1989;6:8–13
- [224] Brody HJ. Complications of chemical resurfacing. *Dermatol Clin* 2001;19:427–438, vii–viii
- [225] Kim EK, Hovsepian RV, Mathew P, Paul MD: Dermabrasion. *Clin Plast Surg*. 2011 Jul;38(3):391-5, v-vi.
- [226] Holmkvist KA, Rogers GS: Treatment of perioral rhytides: A comparison of dermabrasion and superpulsed carbon dioxide laser. *Arch Dermatol* 136:725-731, 2000
- [227] Fezza JP: Laserabrasion: The combination of carbon dioxide laser and dermasanding. *Plast Reconstr Surg* 118:1217-1221, 2006
- [228] Gold M. Dermabrasion in dermatology. *Am J Clin Dermatol* 2003;4(7):467–71.
- [229] Freedman BM, Rueda-Pedraza E, Waddell SP: The epidermal and dermal changes associated with microdermabrasion. *Dermatol Surg* 27:1031-1033, 2001
- [230] Alexiades-Armenakas MR, Dover JS, Arndt KA. The spectrum of laser skin resurfacing: Nonablative, fractional, and ablative laser resurfacing. *J Am Acad Dermatol*. 2008;58:719–737; quiz 738–740.

- [231] Roy D. Ablative facial resurfacing. *Dermatol Clin*. 2005;23: 549–559, viii.
- [232] Fitzpatrick TB. Soleil et peau. *J Med Esthet*. 1975;2:33–34.
- [233] Narurkar VA. Nonablative fractional laser resurfacing. *Dermatol Clin*. 2009;27:473–478, vi.
- [234] Hunzeker CM, Weiss ET, Geronemus RG. Fractionated CO2 laser resurfacing: Our experience with more than 2000 treatments. *Aesthet Surg J*. 2009;29:317–322.
- [235] Airan LE, Hruza G: Current lasers in skin resurfacing. *Facial Plast Surg Clin N Am* 13:127-139, 2005
- [236] Yang CC, Chai CY: Animal study of skin resurfacing using the ultrapulse carbon dioxide laser. *Ann Plast Surg* 35:154-158, 1995
- [237] Tierney EP, Hanke CW. Recent advances in combination treatments for photoaging: review of the literature. *Dermatol Surg* 2010;36:829–840
- [238] Khatri KA, Ross V, Grevelink JM, et al: Comparison of Erbium:YAG and carbon dioxide lasers in resurfacing of facial rhytides. *Arch Dermatol* 135:391-397, 1999
- [239] Ross EV, Naseef GS, McKinlay JR, et al: Comparison of carbon dioxide laser, Erbium:YAG laser, dermabrasion, and dermatome: a study of thermal damage, wound contraction, and wound healing in a live pig model: implications for skin resurfacing. *J Am Acad Dermatol* 42:92-105, 2000
- [240] Fitzpatrick RE, Smith SR, Sriprachya-Anunt S: Depth of vaporization and the effect of pulse stacking with a high energy, pulsed carbon dioxide laser. *J Am Acad Dermatol* 40:615-622, 1999
- [241] Goldman MP, Manuskiatti W: Combined laser resurfacing with the 950-microsec pulsed CO2 Er:YAG lasers. *Dermatol Surg* 25:160-163, 1999
- [242] Manstein D, Herron GS, Sink RK, et al: Fractional photothermolysis: A new concept for cutaneous remodeling using microscopic patterns of thermal injury. *Lasers Surg Med* 34:426-438, 2004
- [243] Rahman Z, Alam M, Dover JS: Fractional laser treatment for pigmentation and texture improvement. *Skin Therapy Lett* 11:7-11, 2006