

We are IntechOpen, the world's leading publisher of Open Access books Built by scientists, for scientists

6,900

Open access books available

185,000

International authors and editors

200M

Downloads

Our authors are among the

154

Countries delivered to

TOP 1%

most cited scientists

12.2%

Contributors from top 500 universities



WEB OF SCIENCE™

Selection of our books indexed in the Book Citation Index
in Web of Science™ Core Collection (BKCI)

Interested in publishing with us?
Contact book.department@intechopen.com

Numbers displayed above are based on latest data collected.
For more information visit www.intechopen.com



Outfracture Osteotomy Sinus Graft: A Modified Technique Convenient for Maxillary Sinus Lifting

Jeong Keun Lee and Yong Seok Cho

Additional information is available at the end of the chapter

<http://dx.doi.org/10.5772/53301>

1. Introduction

Edentulous alveolar ridges always demonstrate atrophy when left alone without dental treatment, making rehabilitation of masticatory function in this atrophic ridge in need of auxiliary augmentation procedures. This is always challenging in posterior maxillary edentulous area because local anatomical condition of this region is easily hampered as masticatory force in the posterior dentition and maxillary sinus is three times greater and the antrum is always subject to pneumatization; thus, facilitating the alveolar bone resorption of the maxillary sinus floor. The best way for a functional rehabilitation of the edentulous alveolar ridge is a dental implant; augmentation sinus surgery can circumvent the anatomical problems (i.e. lack of bone) associated with implant fixture installation.

Tatum introduced a surgical technique to approach the maxillary sinus [1] in 1976, when he first suggested the trapdoor approach; a new method of opening a bony window inward using a top hinge in the lateral maxillary sinus wall. Most maxillary sinuses can be accessed with this inward osteotomy technique with the exception of anatomical variations such as the presence of sinus septum in the operation field or a thick lateral maxillary sinus wall. We however, instead of inward opening, choose to move the osteotomized bony window completely out of the original site to access the Schneiderian membrane of the maxillary sinus (Fig 1). The outfractured bony segment is saved in the normal saline which will be repositioned to the original site after the completion of sinus grafting. The authors experienced excellent treatment results with this modified “outfracture osteotomy sinus grafting (OOSG)” technique which is presented herein.

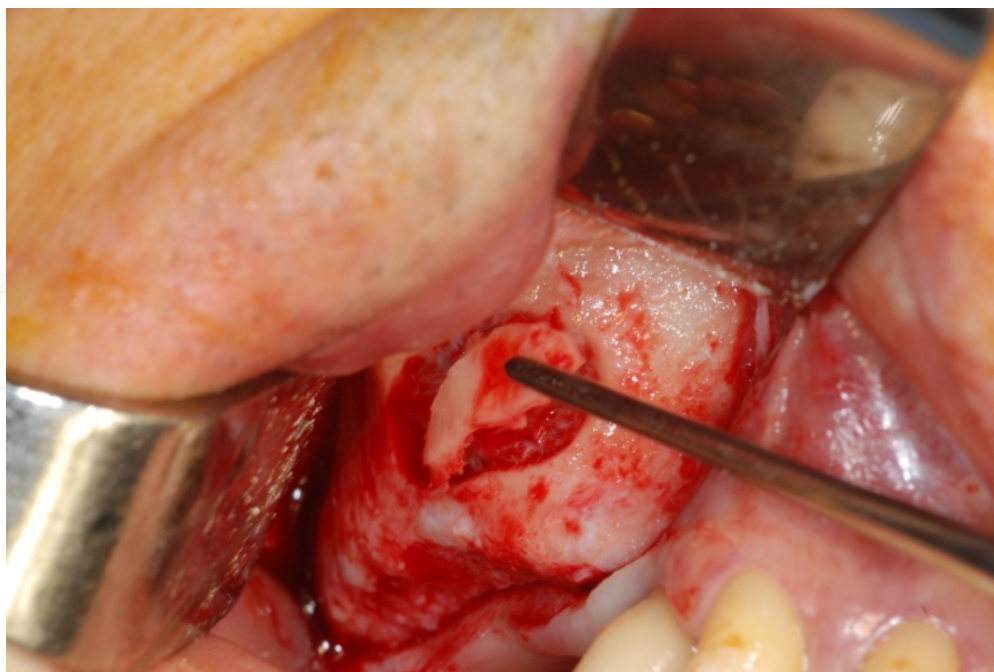

Figure 1. Outfracture osteotomy sinus grafting. The entrance to the lateral sinus wall is prepared by complete outward removal of the bony window which was carefully osteotomized by a rotary device.

2. Concept of the Outfracture Osteotomy Sinus Grafting (OOSG) technique

2.1. Conventional method

In contrast to the structural basal bone, alveolar bone is a labile bone implying it has a functional role of it which gradually degenerates following the loss of the teeth [2]. The floor of the maxillary sinus, forming the roof of the maxillary posterior alveolar bone, is always expanding downward through pneumatization especially when the alveolar bone becomes edentulous [3]. For the above two reasons, the maxillary alveolar bone is prone to atrophy when adequate tooth support is lost making problems for dentists to rehabilitate this region.

The first to introduce sinus surgery for prosthodontic preparation was Dr. Tatum. However, in 1980 Boyne and James [4] first published the detailed surgical technique and its results was for preprosthetic surgery prior to conventional prosthodontic treatment. It involved osteotomy of the lateral maxillary wall and inward fracture of the bony window with a top hinge (Fig 2). The Schneiderian membrane is elevated with this inward movement of the bony segment. It was in 1996 a consensus conference was held on sinus grafting; it was agreed that sinus grafting is an efficacious procedure and an adjunctive procedure for implant-supported restorations in the posterior maxilla [5]. Most cases are treatable with this conventional technique with the exception of some conditions.

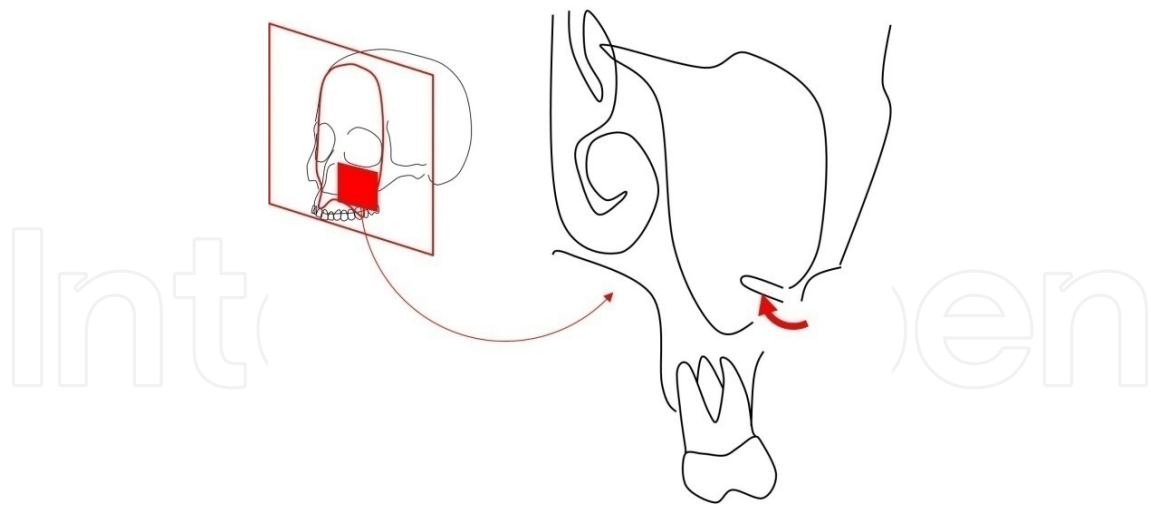


Figure 2. Concept of the original sinus approach method. It involves osteotomy of the lateral maxillary wall and inward fracture of the bony window with a top hinge.

2.2. New concept

When the lateral maxillary wall is thick enough to resist the inward force of the bony segment, sinus surgery is difficult with the conventional technique. The Schneiderian membrane may tear with excessive uncontrolled force applied to counteract this resistance. In case of sinus septae in the operative field, they may stand in way of infracture of the bony segment. The authors modified the technique to completely remove the osteotomized bony segment of the lateral wall instead of infracture and inward hinge movement. The outfractured bony segment is placed in normal saline during sinus grafting and is replaced to its original position when grafting is complete (Fig 3).

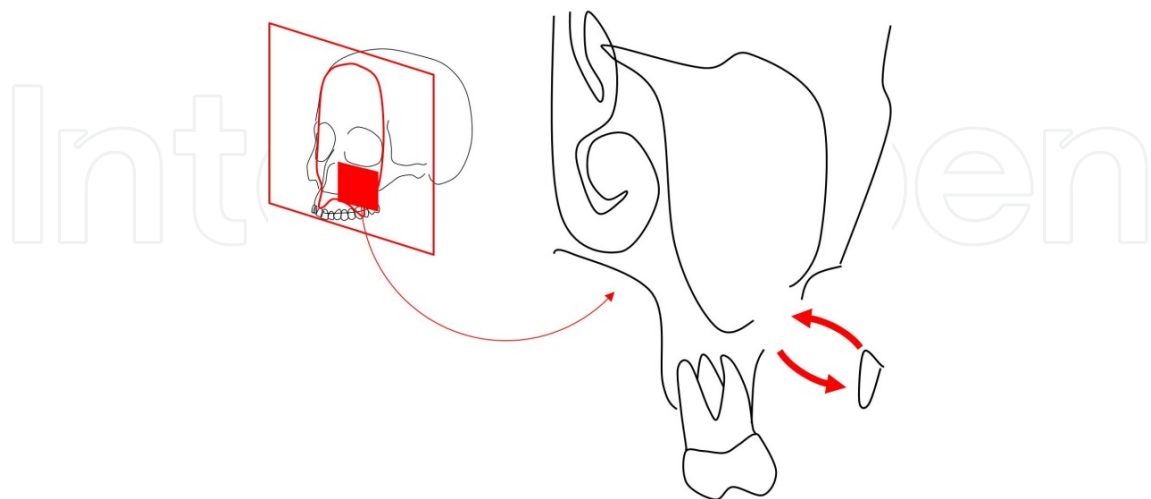


Figure 3. Concept of the outfracture osteotomy sinus grafting method. Bony window is completely removed from the lateral maxillary wall and the outfractured bony segment is placed in the normal saline during sinus grafting and is replaced to its original position before soft tissue closure.

3. Advantages and Indications of the OOSG Technique

Outfracture osteotomy sinus grafting technique is advantageous in the below situations:

1. In cases with both height and width problems
2. Sinus septum resisting infracture of the bony window
3. Thick lateral sinus wall accompanying intrabony bleeding

3.1. Solution to width, as well as height problems

Essentially sinus grafting is a solution to alveolar height problems in installation of dental implant fixtures in the posterior maxillary edentulous alveolar ridges. One of the most influencing factors on the survival of the installed implant fixtures is known to be the height of the remaining alveolar bone [6]. Usually alveolar bone goes atrophic not only vertically but also transversely causing width problems in addition to height problems. In complicated cases of both height and width problems, outfracture osteotomy sinus grafting technique provides a good solution to both problems [7]. The width problem is resolved by transverse augmentation with cortical bone blocks. Outfracturing of the bony segment will secure an access to the lateral maxillary wall after elevation of the Schneiderian membrane, which will provide room for fixation screws for augmentation using cortical bone blocks (Fig 4).

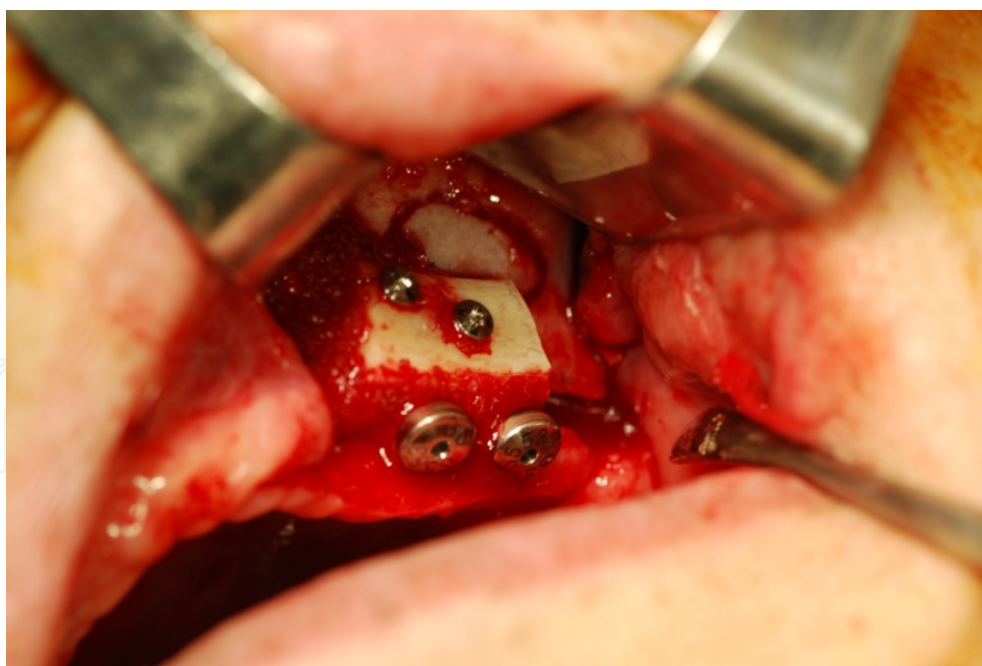


Figure 4. Outfracture osteotomy sinus grafting can be a solution to cases of both height and width problems. Complete outfracturing of the bony segment helps provide room for both sinus floor elevation and screw fixation of the cortical bone block. This patient underwent sinus grafting with OOSG technique simultaneously with a block bone graft from the mandibular ramus. Outfractured bone segment was put back to its original position before soft tissue closure.

3.2. Anatomical considerations

All cases of conventional sinus surgery are also indicated for the outfracture osteotomy sinus graft especially those with anatomic variations such as maxillary septae or a thick lateral maxillary wall. Presurgical evaluation of the computerized tomography (CT) is useful for the information essential to sinus surgery. Intraosseous arterial structures can be visualized in the CT crosscut in up to 64.5 % of all maxillary sinuses [8]. Sinus septae and thick lateral walls of the maxillary sinus is also easily visualized with CT scans, which is a good indication for outfracture osteotomy sinus grafting.

4. Surgical technique

In preparation for the simultaneous installation of the fixtures, the lateral maxillary wall is usually accessed via crestal incision with adequate vertical extension over the buccal surface (Fig 5). Periosteal elevation is followed by a gentle osteotomy, with the borders of the maxillary sinus imagined in mind. Osteotomy line is outlined 2mm away from the imaginary anterior and lower borders. The osteotomy line is extended with the image in mind that antero-posteral and vertical dimension of the window is designed to be 10 mm and 5 mm, respectively (Fig 6). Instead of usual osteotomy, the author intends a thin osteotomy line minimizing the lost bone to help reposition the bony segment to the original position after graft material is placed in. The usual rotary instrument is a No. 2 round carbide bur which is adequate for minimizing bone loss (Fig 7).

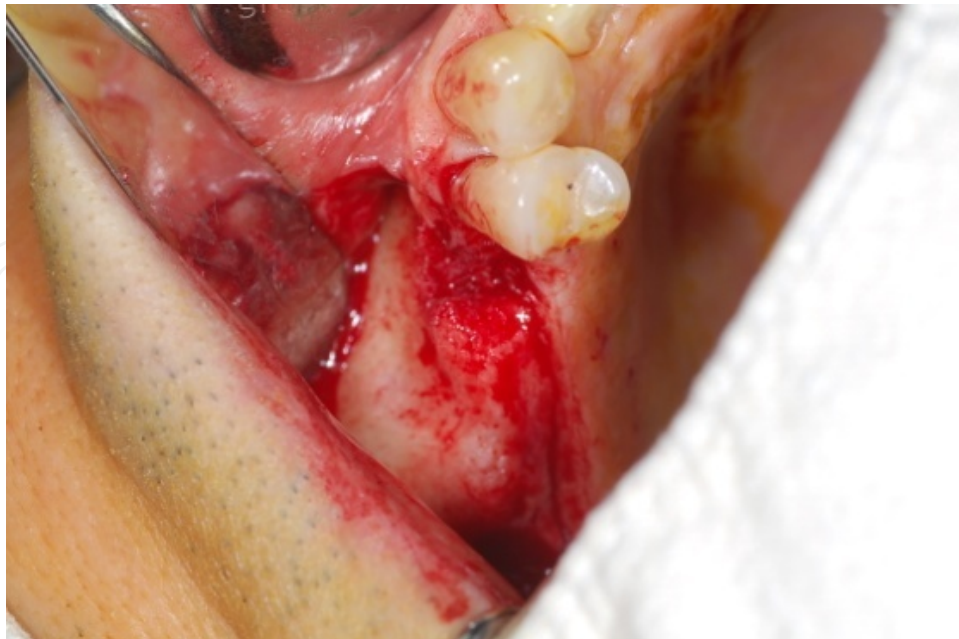

Figure 5. Lateral maxillary wall is exposed via elevation of the flap after vertical extension of the buccal side of the aimed site which is usually accessed by crestal approach for simultaneous installation of the fixtures.

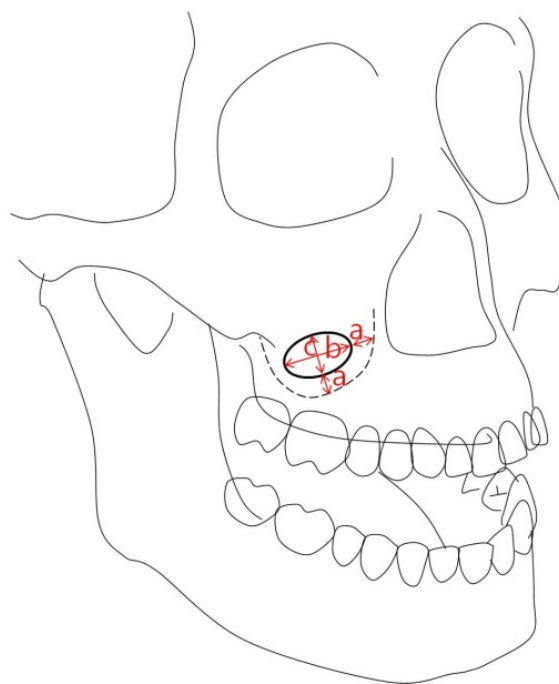


Figure 6. Osteotomy design. Imaginary border of the maxillary sinus (dashed line) is outlined based on the panoramic radiograph. Osteotomy line is designed 2mm away from the imaginary anterior and lower borders (a). The osteotomy line is extended with the image in mind that antero-posteral and vertical dimension of the window is designed to be 10 mm and 5 mm, respectively (b and c).

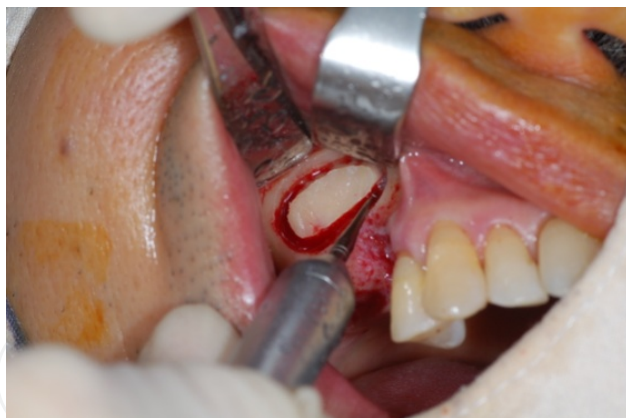

Figure 7. Exposure of the lateral maxillary wall is followed by a gentle osteotomy with rotary instrument using No. 2 round carbide bur which is adequate for minimizing bone loss. A thin osteotomy line is preferred for minimizing the lost bone to help reposition of the bony segment to the original position.

A bluish grey color beneath the osteotomy line indicates the exposure of the Schneiderian membrane which must be extended along the whole osteotomy line. Usually Schneiderian membrane is identified along the osteotomy line as a bluish grey line, a landmark to stop further bone reduction not to invade the membrane surface (Fig 8). This is difficult in case of thick lateral sinus wall (to identify the bluish grey color) but instead of inward force, light outward force induces slice fragmentation of the thick lateral wall partially, just like onion

skin peeling out without exposure of the Schneiderian membrane as a whole. In view of underlying remaining bone after slice outfracture, remaining bone is still thick to be removed further repeatedly until Schneiderian membrane can be seen definitely. For detailed information, please see section 5.2. and Fig 14.

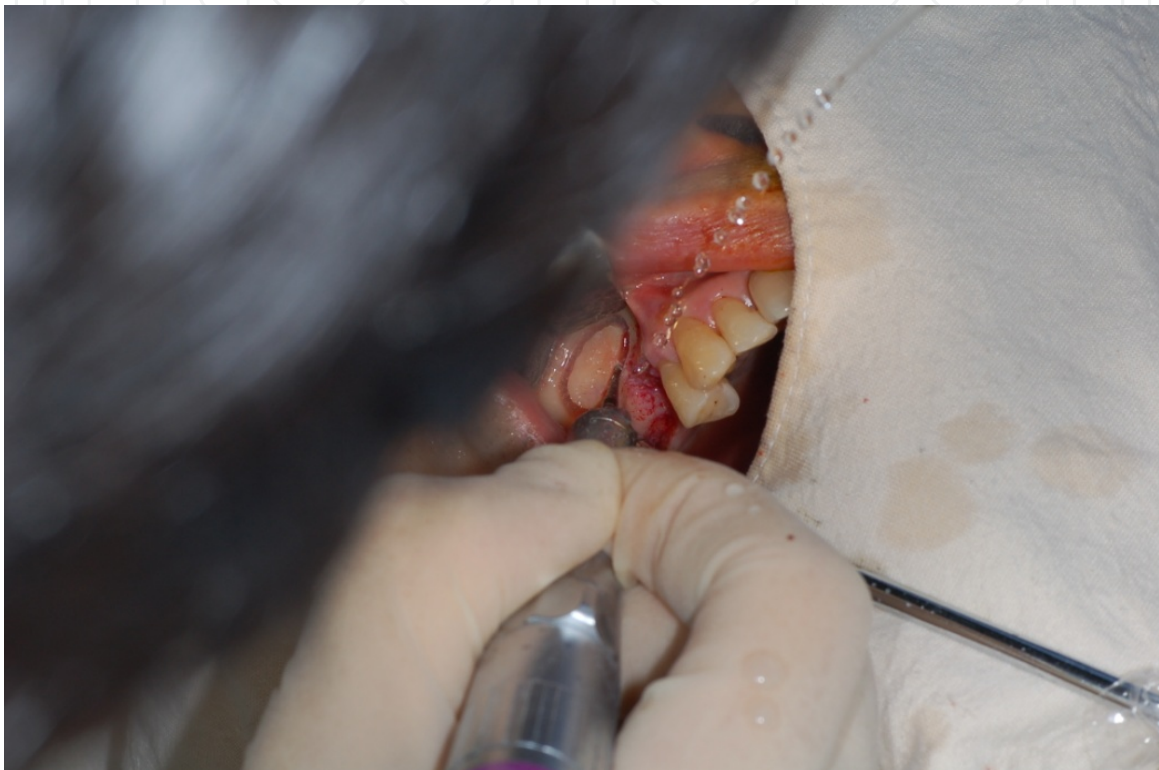


Figure 8. Osteotomy is continued until a bluish grey line is visible not to invade the Schneiderian membrane.

Outward leverage action beneath the formed bony window causes it to separate. The bony segment of the window is preserved in normal saline solution and the Schneiderian membrane is undermined to separate it from the sinus floor (Fig 9). The most vulnerable stage for membrane tears is in this stage. The best way to prevent membrane perforation is to keep the tip of the sinus elevator in intimate contact with the bony floor of the maxillary sinus. The room created is filled with adequate bulk of the graft material and the bony fragment which was kept in normal saline solution is secured without any plate or screws (Fig 10). The flap is closed as usual with 4-0 Vicryl and pressure dressing for minimizing postoperative swelling.

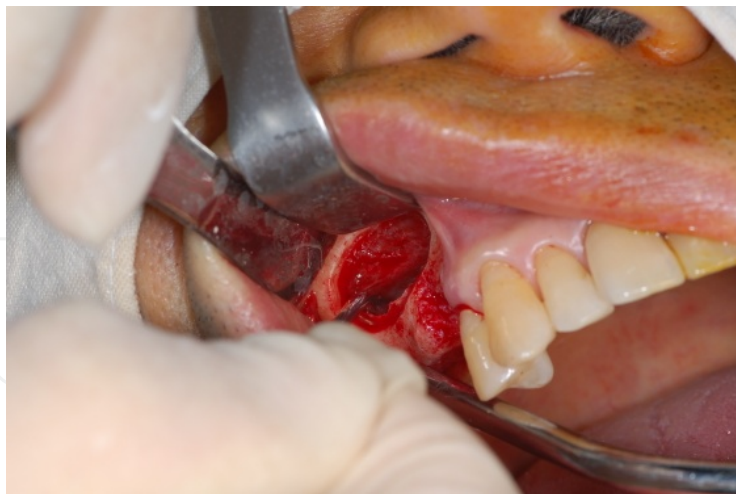

Figure 9. The Schneiderian membrane is undermined to be separated it from the sinus floor with curved sinus elevators. The elevator must be kept in contact with the bony sinus floor to prevent perforation of the Schneiderian membrane.

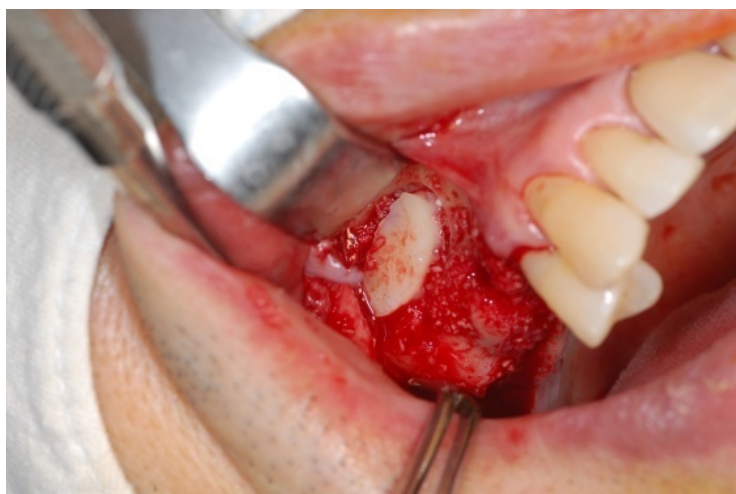

Figure 10. After the graft material is filled over the sinus floor, the bony window fragment is put back to its original position without any plate or screws followed by flap approximation with 4-0 vicryl sutures.

5. Considerations

5.1. Septum crossing the maxillary sinus

The first article on the prevalence of the septae in the maxillary sinus was in 1910 by Underwood reporting 33.0 % in 45 cadavers [9] which was an anatomical study. Varying degrees of the incidence of sinus septae, namely Underwood septae, were reported ranging from 9 % to 33.2 % [10,11,12,13,14] in clinical studies using CT scanning. Anatomical studies using cadavers demonstrated 31.7 % to 40 % of incidences [15,16,17]. Septal direction is usually buc-

copalatal, obstructing the inward path of the bony window in approaching the maxillary sinus (Fig 11) [14,17]. Outfracture of the bony segment can evade this problem and adequate approach becomes possible. Either two separate windows (Fig 12) or one large opening (Fig 13) can be made on the lateral wall without concern of tearing the underlying Schneiderian membrane, for there is outward leverage force instead of inward hinge movement.

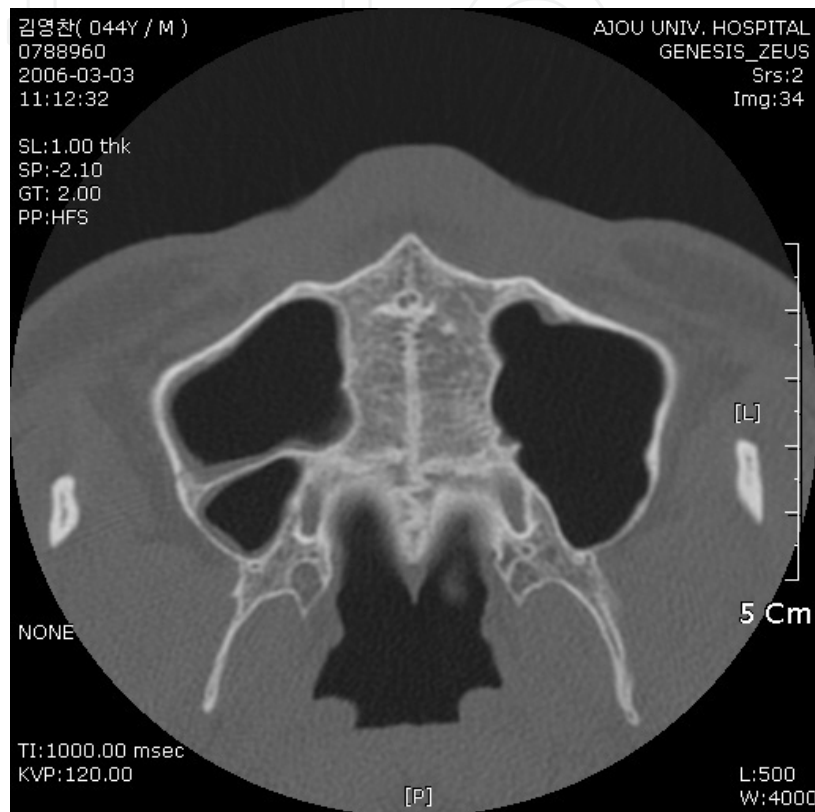


Figure 11. Typical septal structure crossing the maxillary sinus in the buccopalatal direction. It will stand in the way of sinus entry with the conventional method of inward fracturing of the bony window.

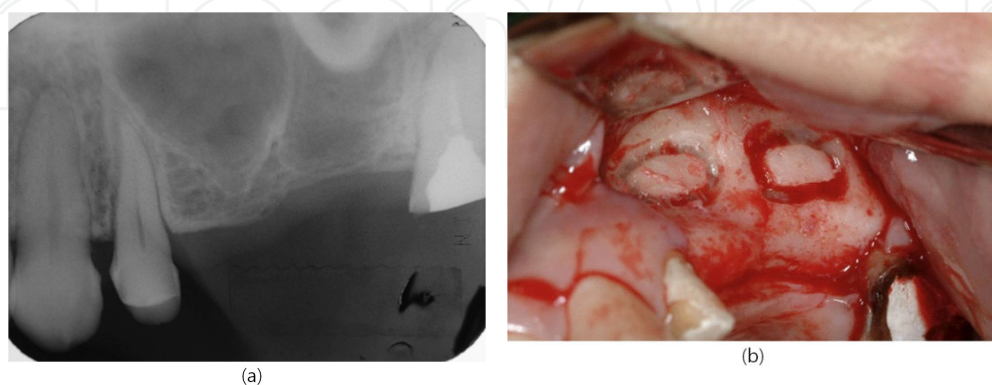


Figure 12. Sinus septum seen on a standard periapical radiograph (a), and two separate windows sinus approach (b). Separate windows can be utilized with respective outfracturing.

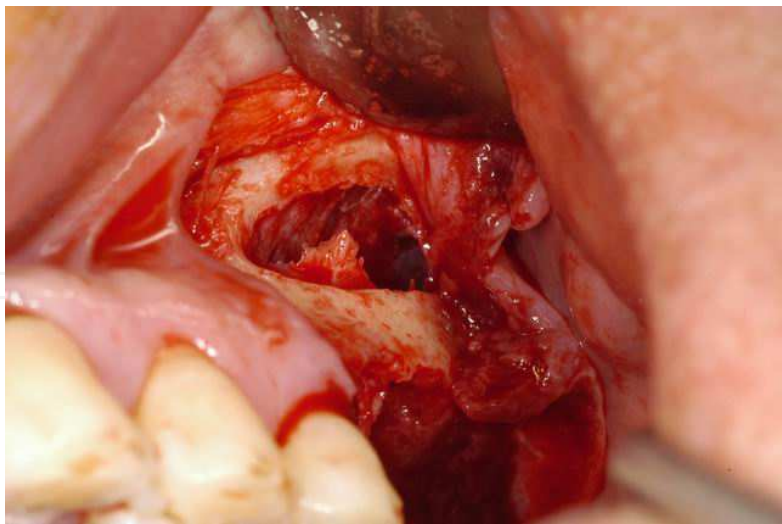


Figure 13. One large window can be utilized because of the outward, not inward vector of the segment fracturing. Septal anatomy can be identified without concerns about membrane tearing with the outfracture technique.

5.2. Thick lateral wall of the maxillary sinus

Thick lateral maxillary wall which resists inward movement is easily removed outward with only a gentle pressure. In extreme cases, the wall is fragmented out a couple of times just like onion skin peeled out one by one (Fig14 a through d). Outfracture of the thick bony segment is repeated until complete exposure of the Schneiderian membrane without concern of tearing.

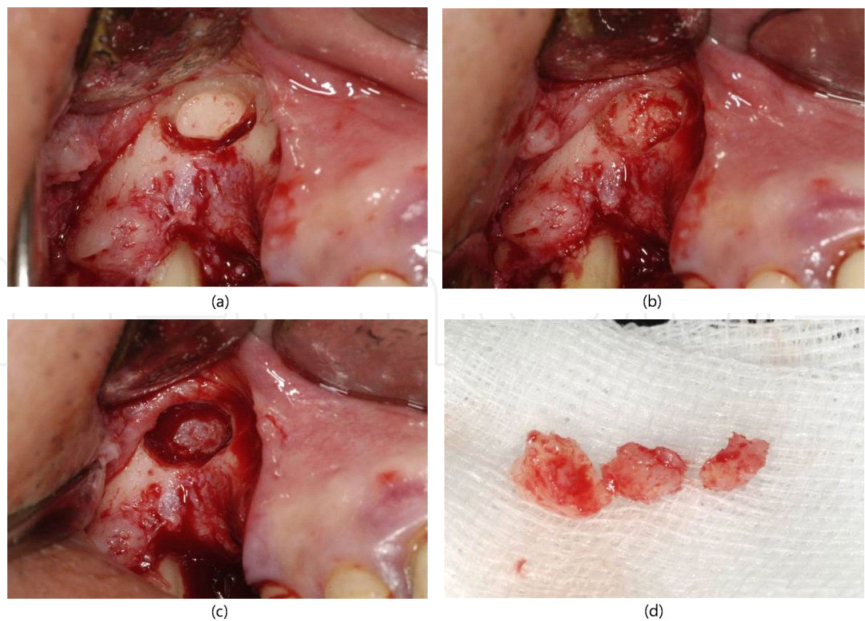


Figure 14. Repeated outfracture of the bony segments in thick lateral maxillary wall. Initial outfracture osteotomy (a) didn't succeed in revealing Schneiderian membrane (b), but continued osteotomy (c) lead to exposure of the Schneiderian membrane and left three pieces of osteotomized segments (d).

5.3. Bone bleeding during sinus approach

Head and neck structures have a high vascularity enhancing the healing capacity of this region. Extended from the external carotid artery, the internal maxillary artery feeds the maxillary sinus with its branches, infraorbital artery (IOA) and posterior superior alveolar artery (PSAA) anastomosing on the lateral maxillary wall. In a study using 100 CT scans, 94 out of 200 (47 %) examined sinuses demonstrated well-defined bony canals in the areas of sinus surgery to be done, whereas intra-osseous anastomoses of the IOA and PSAA was found by dissection in a total of 30 cadaveric maxillary sinuses [18]. Another study revealed that 52.9 % of the intraosseous branches of PSAA can be visualized on the CT scans and its average distance from the alveolar crest was demonstrated to be 16 ± 3.5 mm [19]. Typical coronal crosscut image of the CT shows the passage of the arterial structure on the lateral maxillary sinus wall as a notching inside of it (Fig 15). Adequate design of the surgical planning based on this radiographic anatomy will help prevent bleeding with outfracture osteotomy sinus graft technique because of its technical convenience.

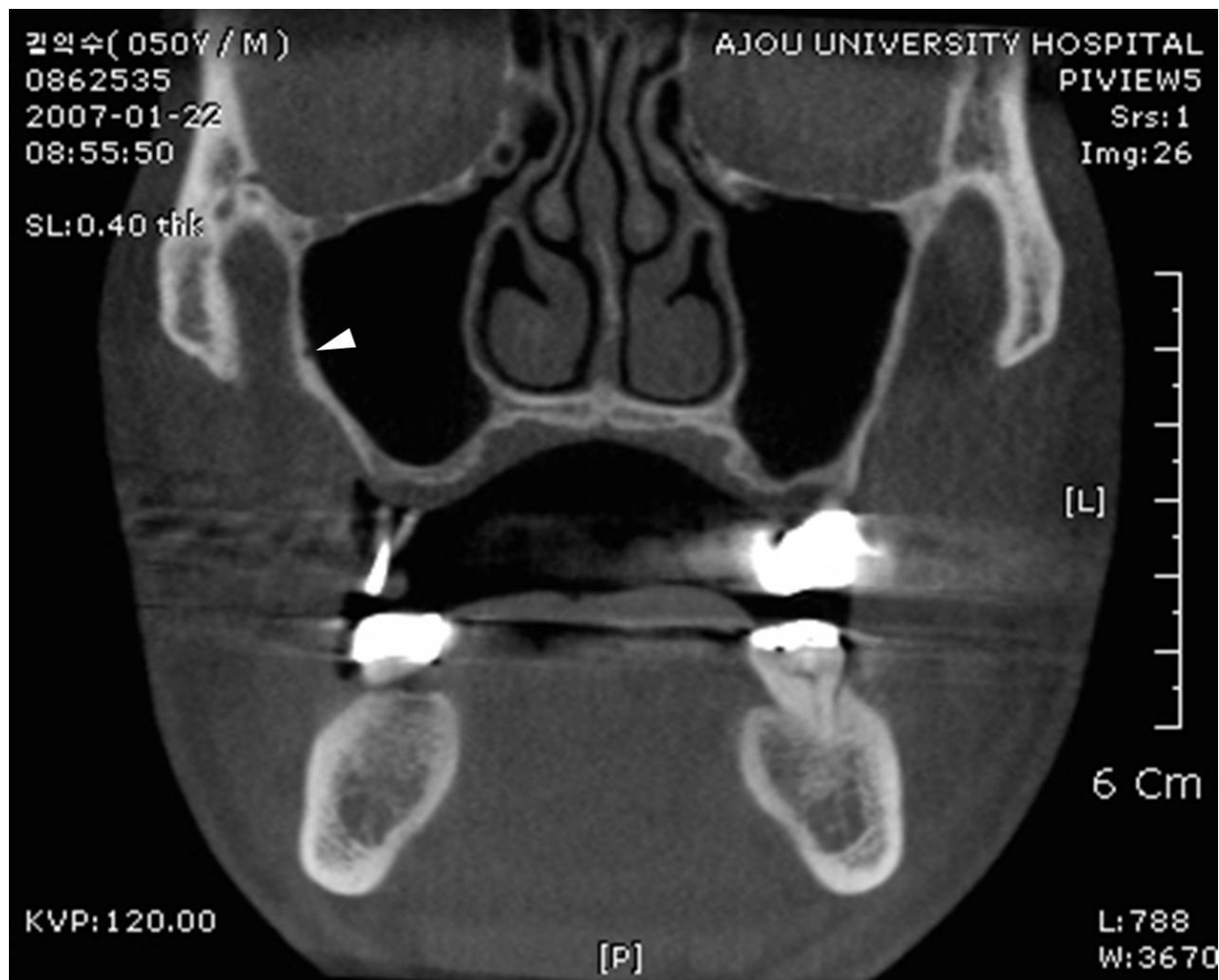


Figure 15. Crosscut image showing the notch inner cortical side of the lateral maxillary sinus wall revealing the arterial structure passing over the Schneiderian membrane (white arrowhead).

There was no vessel visible or no vessel present in most cases (120 sinuses, i.e. 89.5 %) in the cadaveric and radiographic study of 134 maxillary sinuses [20]. The other 14 cases demonstrated its appearance in two thirds of the lateral wall of the maxillary sinuses, 12 of which (85.7 %) showing vessels in the middle third. Another study showed bony canal in 114 (55 %) out of 208 CT scans in surgical planning of the maxillary sinus [21]. Because the anastomosis of the IOA and PSAA is usually in the surgical field as in these studies, surgeons approaching lateral maxillary wall encounter these vessels occasionally. During the conventional sinus approach intrabony bleeding is more difficult to deal with in the thick lateral sinus wall, for inward mobilization of the bony segment; this will be possible only after the complete reduction of the thick lateral wall. By contrast, outfracturing immediately reveals any bleeding in the surgical field. Sometimes, large arterial feature running across the surgical field can be visible after outfracturing of the bony window (Fig 16). Even in the case of thick lateral wall it may cause slice fragmentation just like an onion skin, which will not hide the bleeding in the surgical field. Surgical approach can be done with adequate bleeding control in the course of the sinus window opening.

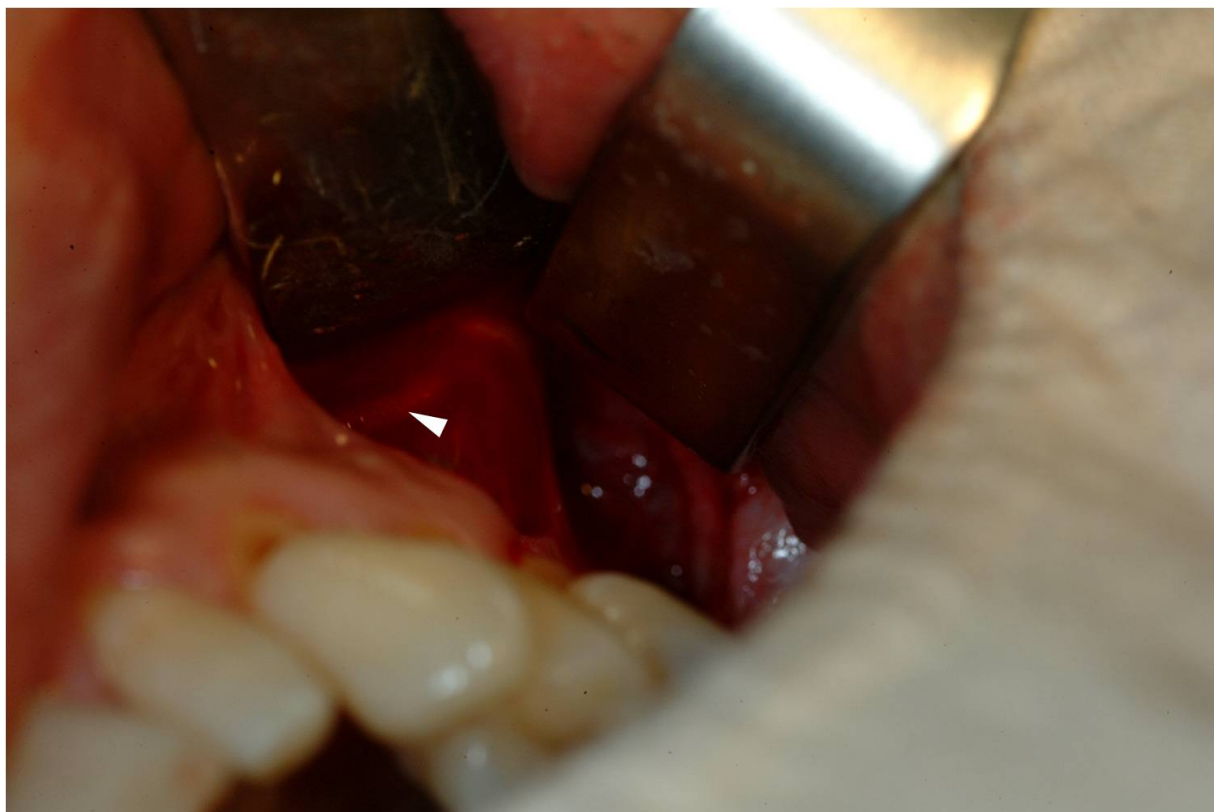

Figure 16. Large artery running across the surgical field is visible after complete removal of the bony window segment outward (white arrowhead).

5.4. Most natural covering membrane

Covering membrane is used to block access window after completion of the sinus graft procedure. In a clinical study comparing the effect of barrier membrane in the bilateral sinus floor elevation, Tarnow concluded that the barrier membrane tends to increase vital bone formation and recommended membrane placement in all sinus elevation procedures [22]. Although many kinds of barrier membranes are commercially available, outfractured bony segment functions as a covering membrane instead of artificial membrane [7,23]. It can participate in the bone remodeling procedure, for it is of self origin functioning as a natural covering membrane. It's rather a free bone graft and most of the repositioned bony segment is to take part in remodeling procedure absorbed in healing process with consolidation of graft material.

5.5. Grafting materials

Success of the bone graft depends more upon the condition of the recipient site than the kinds of the graft materials. There is little difference of success rate among various kinds of graft materials with the result of the materials used is all acceptable [5]. There are a lot of studies demonstrating many kinds of grafting materials in sinus augmentation either in animal experiment [24,25] or human studies using peripheral blood [26], absorbable gelatin sponge [27], and autologous fibrin-rich block with concentrated growth factors [28]. Antral ossification was also reported even after Schneiderian membrane elevation without graft material in experimental studies in rabbits [24, 25]. New bone formation was also confirmed clinically, radiographically, and histologically in a human study with elevation of the Schneiderian membrane without graft material [29]. We are now grafting a material derived from autogenous teeth, the effect of which is confirmed in in-vivo study using miniature pigs [30] and by the histologic result of a human study [31].

Despite of the diverse range of treatment results of the graft materials, the overall effect of the various materials used in the sinus graft seems to be acceptable [5]. It means maxillary sinus is anatomically acceptable for graft procedure irrespective of the materials used. Maxillary sinus is a confined cavity with excellent cortical housing adequate for immobilization of the graft material, a prerequisite for an optimal healing that can induce new bone formation.

6. Fixture survival rate with outfracture osteotomy sinus graft technique

The survival of the installed implant fixture is most dependant on the initial stability of the fixture [32] and the quality of bone that takes the fixtures and not on the graft materials [33]. The conventional sinus graft technique has no advantage over the outfracture osteotomy technique, for bone segment which is trapped in is not stable to take the installed fixture.

The author has been performing sinus graft at Ajou University Hospital Dentofacial Center in Suwon, Korea when the posterior maxillary alveolar ridge is inadequate for fixture

installation. All patients needing augmentation sinus surgery by lateral approach technique underwent outfracture osteotomy sinus grafting. As an independent procedure, our department has recorded 97.2 % (174 out of 179 fixtures involved in sinus graft) 5-year implant survival rate in 2009 [34]. Our overall total implant survival rate in our department was 97.9 % (751 out of 767 fixtures) with fixtures 3.75 mm in their diameters after 4.5 years [35].

As a continuing study following the previous one, a retrospective study was done on the cumulative survival rate of the fixtures. One hundred and fifty- six patients with loss of teeth and atrophy of posterior maxilla underwent augmentation sinus surgery with outfracture osteotomy sinus grafting. One hundred and fourty two out of 156 patients received simultaneous or delayed fixture installation according to our diagnostic criteria. Fixture installations were not done for the 14 patients whose implant treatments were done at respective local dental clinics. Three hundred and fourty two fixtures were installed in 142 patients and 320 fixtures were selected which fulfilled the inclusion criteria of follow-up period over 4 months. The time for follow-up ranged from a minimum of 4.2 months to a maximum of 88.2 months (average 26.8 months). The total number that underwent sinus graft surgery with outfracture osteotomy sinus graft technique was 171 (113 unilateral and 29 bilateral cases in 142 patients). Fourteen fixtures were recorded as failures, making the total cumulative survival rate 95.6 % (306 out of 320 fixtures) (Table 1). Although the cumulative survival rate was slightly less compared to the previous study [34], 171 sinuses exhibited good results without a case of major complications such as graft failure.

Age Tooth No.	Under 10	11-20	21-30	31-40	41-50	51-60	61-70	Over 70	Total
#17	0	0	0	5	20	14(1)	7	1	47(1)
#16	0	0	2	6	27(2)	17(2)	9	2	63(4)
#15	0	0	1	2	11	6	3	1	24
#14	0	0	1	1	3	4	2	0	11
#13	0	0	0	0	1(1)	1	0	0	2(1)
#23	0	0	0	0	1	1	0	0	2
#24	0	0	2	2(1)	8(1)	9	3	0	24(2)
#25	0	1	1	2	12	11	3	0	30
#26	0	0	4	11(2)	24(3)	30	7	2	78(5)
#27	0	0	2	4	13	14(1)	4	2	39(1)
Total	0	2	12	31	126	106	36	8	321

Failure cases were designated in the parentheses in relevant column.

Table 1. Total implant fixtures installed in the atrophic maxillary alveolar bone with OOSG technique.

7. Conclusion

Sinus augmentation surgery is an established procedure effective for implant-supported restorations in the posterior maxilla. Although the lateral approach to the maxillary sinus can be done with conventional inward trapdoor method using upper hinge, the authors recommend the new method of outfracture osteotomy and repositioning of the bony window. So called outfracture osteotomy sinus graft is technically easy and convenient for coping with intraoperative complications such as marrow bleeding. It is a versatile method enabling the lateral approach of the maxillary sinus even in anatomical difficulties such as the presence of antral septae.

Author details

Jeong Keun Lee¹ and Yong Seok Cho²

1 Department of Dentistry Oral and Maxillofacial Surgery, Ajou University School of Medicine, Suwon, Korea

2 Apseon Dental Hospital, Seoul, Korea

References

- [1] Tatum H Jr. Maxillary and sinus implant reconstructions. *Dental Clinics of North America* 1986;30(2) 207-209
- [2] Lee J.K. Bone biology for implant dentistry in atrophic alveolar ridge- theory and practice. In: Turkyilmaz I. (ed) *Implant Dentistry: A Rapidly Evolving Practice*. Rijeka: InTech; 2011. P413-434. Available from <http://www.intechopen.com/books/implant-dentistry-a-rapidly-evolving-practice/bone-biology-for-implant-dentistry-in-atrophic-alveolar-ridge-theory-and-practice> (accessed 15 August 2012).
- [3] Sharan A, Madjar D. Maxillary Sinus Pneumatization Following Extractions: A Radiographic Study. *International Journal of Oral and Maxillofacial Implants* 2008;23(1) 48-56
- [4] Boyne PJ, James R. Grafting of the maxillary sinus floor with autogenous marrow and bone. *Journal of Oral Surgery* 1980;38(8) 613-616
- [5] Jensen OT, Shulman LB, Block MS, Iacono VJ. Report of the sinus consensus conference of 1996. *International Journal of Oral and Maxillofacial Implants* 1998;13(Suppl) 11-45
- [6] Froum SJ, Tarnow DP, Wallace SS et al.: Sinus floor elevation using anorganic bovine bone matrix (OsteoGraf/N) with and without autogenous bone: a clinical, histologic,

- radiographic, and histomorphometric analysis--Part 2 of an ongoing prospective study. *International Journal of Periodontics and Restorative Dentistry* 1998;18(6): 528-543
- [7] Lee JK. Outfracture osteotomy on lateral maxillary wall as a modified sinus graft technique. *Journal of Oral and Maxillofacial Surgery* 2010;68(7) 1639-1641
 - [8] Güncü GN, Yildirim YD, Wang HL, Tözüm TF. Location of posterior alveolar artery and evaluation of maxillary sinus anatomy with computerized tomography: a clinical study. *Clinical Oral Implants Research* 2011;22(10) 1164-1167
 - [9] Underwood AS. An inquiry into the anatomy and pathology of the maxillary sinus. *Journal of Anatomy and Physiology* 1910;44(4) 354-369
 - [10] Lee DH, Lee SH, Hwang JH, Lee JK. Clinical study on the Korean posterior maxillae related to dental implant treatment. *Journal of Korean Association of Maxillofacial Plastic and Reconstructive Surgeons* 2010;32(1) 27-31
 - [11] Lee WJ, Lee SJ, Kim HS. Analysis of location and prevalence of maxillary sinus septa. *Journal of Periodontal Implant Science* 2010;40(2) 56-60
 - [12] Kim MJ, Jung UW, Kim CS, Kim KD, Choi SH, Kim CK, Cho KS. Maxillary sinus septa: prevalence, height, location, and morphology. A reformatted computed tomography scan analysis. *Journal of Periodontology* 2006;77(5) 903-908
 - [13] Park YB, Jeon HS, Shim JS, Lee KW, Moon HS. Analysis of the anatomy of the maxillary sinus septum using 3-dimensional computed tomography. *Journal of Oral and Maxillofacial Surgery* 2011;69(4) 1070-1078
 - [14] Neugebauer J, Ritter L, Mischkowski RA, Dreiseidler T, Scherer P, Ketterle M, Rothamel D, Zöller JE. Evaluation of maxillary sinus anatomy by cone-beam CT prior to sinus floor evaluation. *International Journal of Oral and Maxillofacial Implants* 2010;25(2) 258-265
 - [15] Ulm CW, Solar P, Krennmaier G, Matejka M, Watzek G. Incidence and suggested surgical management of septa in sinus-lift procedures. *International Journal of Oral and Maxillofacial Implants* 1995;10(4) 462-465
 - [16] Ella B, Noble RDa, Lauverjat Y, Sédarat C, Zwetyenga N, Siberchicot F, Caix P. Septa within the sinus: effect on evaluation of the sinus floor. *British Journal of Oral and Maxillofacial Surgery* 2008;46(4) 464-467
 - [17] Rosano G, Taschieri S, Gaudy JF, Lesmes D, DelFabbro M. Maxillary sinus septa: a cadaveric study. *Journal of Oral and Maxillofacial Surgery* 2010;68(6) 1360-1364
 - [18] Rosano G, Taschieri S, Gaudy JF, Weinstein T, Del Fabbro M. Maxillary sinus vascular anatomy and its relation to sinus surgery. *Clinical Oral Implants Research* 2011;22(7) 711-715

- [19] Elian N, Wallace S, Cho SC, Jalbout ZN, Froum S. Distribution of the maxillary artery as it relates to sinus floor augmentation. *International Journal of Oral and Maxillofacial Implants* 2005;20(5) 784-787
- [20] Ella B, Sédarat C, Noble RDa C, Normand E, Lauverjat Y, Siberchicot F, Caix P, Zwytyenga N. Vascular connections of the lateral wall of the sinus: surgical effect in sinus augmentation. *International Journal of Oral & Maxillofacial Implants* 2008;23(6) 1047-1052
- [21] Mardinger O, Abba M, Hirshberg A, Schwartz-Arad D. Prevalence, diameter and course of the maxillary intraosseous vascular canal with relation to sinus augmentation procedure: a radiographic study. *International Journal of Oral and Maxillofacial Surgery* 2007;36(8) 735-738
- [22] Tarnow DP, Wallace SS, Froum SJ, Rohrer MD, Cho SC. Histologic and clinical comparison of bilateral sinus elevations with and without barrier membrane placement in 12 patients: Part 3 of an ongoing prospective study. *International Journal of Periodontics and Restorative Dentistry* 2000;20(2) 117-125
- [23] Cho YS, Park HK, Park CJ. Bony window repositioning without using a barrier membrane in the lateral approach for maxillary sinus bone graft; clinical and radiologic results at 6 months. *International Journal of Oral and Maxillofacial Implants* 2012;27(1) 211-217
- [24] Sohn DS, Kim WS, An KM, Song KJ, Lee JM, Mun YS. Comparative histomorphometric analysis of maxillary sinus augmentation with and without bone grafting in rabbit. *Implant Dentistry* 2010;19(3) 259-270
- [25] Sohn DS, Moon JW, Lee WH, Kim SS, Kim CW, Kim KT, Moon YS. Comparison of New Bone Formation in the Maxillary Sinus With and Without Bone Grafts; Immunohistochemical Rabbit Study. *International Journal of Oral and Maxillofacial Implants* 2011;26(5) 1033-1042
- [26] Moon JW, Sohn DS, Heo JW, Shin HI, Jung JK. New bone formation in the maxillary sinus using peripheral venous blood alone. *Journal of Oral and Maxillofacial Surgery* 2011;69(9) 2357-2367
- [27] Sohn DS, Moon JW, Moon KN, Cho SC, Kang PS. New bone formation in the maxillary sinus using only absorbable gelatin sponge. *Journal of Oral and Maxillofacial Surgery* 2010;68(6) 1327-1333
- [28] Sohn DS, Heo JU, Kwak DH, Kim DE, Kim JM, Moon JW, Lee JH, Park IS. Bone Regeneration in the Maxillary Sinus Using an Autologous Fibrin-Rich Block With Concentrated Growth Factors Alone. *Implant Dentistry* 2011;20(5) 389-395
- [29] Sohn DS, Lee JS, Ahn MR, Shin HI. New bone formation in the maxillary sinus without bone grafts. *Implant Dentistry* 2008;17(3) 321-331

- [30] Jeong HR, Hwang JH, Lee JK. Effectiveness of autogenous tooth bone used as a graft material for regeneration of bone in miniature pig. *Journal of the Korean Association of Oral and Maxillofacial Surgeons* 2011;37(5) 375-379
- [31] Kim YK, Kim SG, Byeon JH, Lee HJ, Um IU, Lim SC, Kim SY. Development of a novel bone grafting material using atogenous teeth. *Oral Surgery, Oral Medicine, Oral Pathology, Oral Radiology, and Endodontology* 2010;109(4) 496-503
- [32] Albrektsson T, Brånemark PI, Hansson HA, Lindström J. Osseointegrated titanium implants. Requirements for ensuring a long-lasting, direct bone-to-implant anchorage in man. *Acta Orthopaedica Scandinavica* 1981; 52(2) 155-170
- [33] Molly L. Bone density and primary stability in implant therapy. *Clinical Oral Implants Research* 2006;17(Suppl 2) 124-35
- [34] Song SI, Jeong HR, Kim HM, Lee JK. Clinical investigation on the feasibility of out-fracture osteotomy sinus graft technique. *Journal of the Korean Association of Oral and Maxillofacial Surgeons* 2009;35(5) 367-371
- [35] Ko SM, Lee JK, Eckert SE, Choi YG. Retrospective Multicenter Cohort Study of the Clinical Performance of 2-stage Implants in South Korean Populations. *International Journal of Oral and Maxillofacial Implants* 2006;21(5) 785-788