

# We are IntechOpen, the world's leading publisher of Open Access books Built by scientists, for scientists

6,900

Open access books available

186,000

International authors and editors

200M

Downloads

Our authors are among the

154

Countries delivered to

TOP 1%

most cited scientists

12.2%

Contributors from top 500 universities



WEB OF SCIENCE™

Selection of our books indexed in the Book Citation Index  
in Web of Science™ Core Collection (BKCI)

Interested in publishing with us?  
Contact [book.department@intechopen.com](mailto:book.department@intechopen.com)

Numbers displayed above are based on latest data collected.  
For more information visit [www.intechopen.com](http://www.intechopen.com)



---

# Management of Mandibular Fractures

---

Amrish Bhagol, Virendra Singh and Ruchi Singhal

Additional information is available at the end of the chapter

<http://dx.doi.org/10.5772/53854>

---

## 1. Introduction

The treatment of mandibular fractures has been in a constant state of evolution over the past few decades. The most significant advancements related to the management of fractures of the mandible are based on specific technical refinements in the methods of internal fixation. Also there is improvement in the knowledge of anatomy, pathophysiology, pharmacology and biomaterial science which influence our current management of mandibular fractures. Recent mandibular fracture management techniques have allowed for decreased infection rates and biological stable fixation of bone segments. This philosophy produces bony union and restoration of preinjury occlusion and normally eliminates the need for wire maxillomandibular immobilization. All this adds up to a faster, safer, more comfortable return to function. In spite of the presence of these modern techniques, closed reduction has by no means fallen by the wayside and still remains a commonly used procedure. This chapter presents an overview of general treatment principles in the management of mandibular fractures and also discusses the treatment strategies in detail depending on the age and anatomical site involved (symphysis, angle, condyle etc). Mandibular fractures in children and adults need different treatment approaches. Similarly, fractures of different anatomical sites in the mandible need different treatment modalities; they differ in their biomechanics, treatment requirements and complications. So each fracture is discussed individually taking care of the different schools of thought and controversies regarding their management. Major advances in the treatment of mandibular fracture in terms of biomaterials and minimally invasive surgical techniques are also discussed.

## 2. Historical overview

Historical references to mandible fracture diagnosis and treatment date back to 1650 BC as evidenced by the Edwin Smith Surgical Papyrus.[1,2] The patient described subsequently

died, likely from infection secondary to the mandibular fracture. Hippocrates, the "father of medicine," also described the treatment of mandible fractures with circumferential dental wiring in some of his initial writings.[3] However, it was Salicetti, in 1275, who first presented maxillomandibular fixation as a treatment for fractures of the mandibles,[4,5] ; the reader was advised to "tie the teeth of the uninjured jaw to the teeth of the injured jaw." Although a fundamental concept in contemporary facial fracture management, Salicetti's concept of MMF disappeared for centuries until Gilmer applied the technique clinically and described its utility in more detail in the United States in 1887.[6] Despite a few early attempts at rigid internal fixation, for most of the 20th century[7], the management of mandibular and maxillary fractures was limited to the application of bandages, maxillomandibular fixation or Gunning-type splints for the edentulous. Later external frames were used in combination with pin fixation. Fracture treatment by open approach and direct transosseous wiring was avoided in the preantibiotic era since it almost inevitably produced infection and osteomyelitis. It was reserved for use in select cases involving the posterior mandible (i.e. ramus/angle) or in edentulous patients. The earliest reports of mandibular fractures treated with an open reduction were from Buck, using an iron loop, and Kinlock, using a silver wire. [8,9] Gilmer, in 1881, described the use of two heavy rods placed on either side of the fracture that were wired together.[10] Schede (circa 1888) is credited with the first use of a true bone plate made of steel and secured with four screws.[9] In the 1960s, Luhr developed the vitallium mandibular compression plate through his research on rigid fixation of the facial skeleton. Luhr and Spiessl reintroduced the idea of utilizing miniature bone plates in the repair of mandibular fractures in 1968 and 1972.[11] In 1976, Spiessl and others continued to advance techniques of open reduction and internal fixation (ORIF) and developed the principles now advocated by the Arbeitsgemeinschaft für Osteosynthesefragen (Association for Osteosynthesis/Association for the Study of Internal Fixation (AO/ ASIF)).[12] This concept was unfortunately based on trying to 'fit' orthopedic principles and, worse, orthopaedic materials to the complex structures of the facial skeleton. The belief was that callus formation represented a failure of the healing process, because of excessive and undesirable movements across the fracture. Thus more heavy and complex methods were devised to increase the stability across the fracture. These plates were bulky, difficult to use and always required large skin incisions. This philosophy failed to see that perfectly good reduction and healing could be achieved by very unstable fixation methods like wiring of the teeth together. Whilst mandibular maxillary wire fixation was potentially dangerous and unpleasant, it was very effective in healing bones. These crude, heavy plating systems did, however, demonstrate the benefits of avoiding wire maxillomandibular fixation, including comfort, return to normal mastication and normal oral function. In reality, these heavy compression plates had a high morbidity. The neck scars were undesirable, nerve damage to both the facial and inferior alveolar nerves was common and infection of the plates frequent; a second operation to remove the plates was always necessary. The principles of heavy compression plating could not be applied to the thin bones of the upper facial skeleton.

One useful technique to arise from this principle of applying orthopedic material to the facial skeleton was the use of lag screws, which is a simple technique of producing interfragmentary stability by compression. These have a large screw hole bored on the outer

fragment and allow the tightening of the screw to compress the fragments together. In a few sites in the mandible it can be a simple effective treatment via the intraoral approach but since the screw must cross the fracture at right angles it has limited use. In the 1970s another concept of internal fixation for the repair of mandibular fractures was introduced by Michellet and colleagues and refined by Champy and co-workers; they placed small, bendable, non-compression plates along the lines of ideal osteosynthesis.[13,14] Both of these techniques have proven to be effective and are routinely used in the contemporary management of mandibular fractures. The use of small miniplates was successfully integrated into the rest of the facial skeleton, being refined and miniaturized for the periorbital and cranial non-load bearing areas. Most recently, bone-plating systems made from resorbable polymer have been introduced. Although these materials show significant promise, they have been utilized most often in the non-load bearing cranial and orbital regions. The resorbable materials themselves and the techniques used in their application continue to be redefined at a rapid pace in this early phase of development.[15,16]

### 3. Diagnosis

The diagnosis of mandibular fractures must begin with a careful history and clinical examination. Immediate attention must always be given to problems associated with airway compromise and bleeding which may endanger the patient's life. Once the airway, breathing and circulation have been adequately assessed, a quick neurologic function evaluation should be performed. Standard trauma protocols such as those described in the Advanced Trauma Life Support guidelines from the American College of Surgeons should be utilized for a comprehensive evaluation. While taking history, information about the mode of injury will often suggest a specific fracture pattern and may provide the surgeon with valuable insight regarding the potential for concomitant injuries. Patients who sustain fractures involving the mandible will often report a paresthesia or change in their occlusion noted immediately after the traumatic event. The patient's past medical and surgical history, medication use and known drug allergies should also be reviewed. Temporomandibular joint dysfunction and any previous non-surgical or surgical treatment should be carefully documented. When a mandibular fracture is suspected, meticulous clinical examination of the maxillofacial region is critical and should be carried out prior to the ordering of radiographic imaging studies.

#### 3.1. Clinical examination

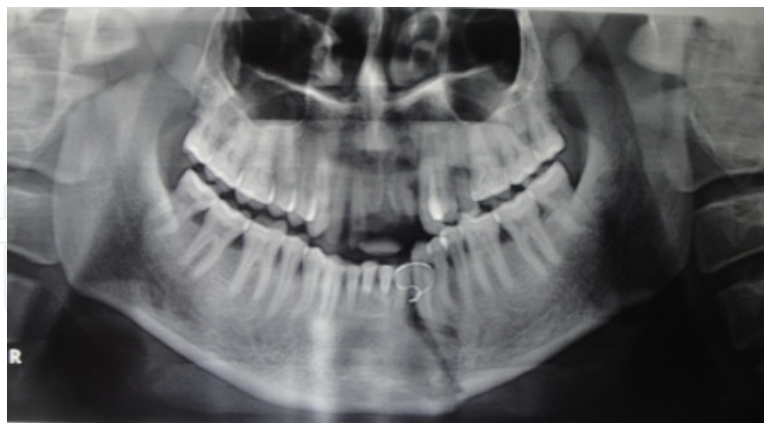Without question, a change in occlusion is the most common physical finding in patients with fractures of the mandible. When examining the occlusion, it is important to consider that the patient may have had an abnormal dental or skeletal occlusal relationship (Class II or Class III) prior to the injury. Changes in occlusion will likely accompany fractures of the mandible, but may also be present in soft tissue trauma of the TMJ, fractures of the alveolus, dental fractures or fractures of the maxilla. When the fracture traverses a region of the mandible that includes the inferior alveolar nerve, some level of neurosensory disturbance in-

volving this nerve will result. Abnormalities in the mandibular range of motion or deviation of the mandible are also indicative of fracture, as can be an inability to close completely. These restrictions may also be the result of internal TMJ injury or hematoma. Sublingual ecchymosis is highly suggestive of a fracture involving the mandibular arch. Another indication of fracture is a bony step which is most easily recognized by careful palpation along the inferior border of the mandible.

### 3.2. Radiographic examination

Proper treatment of fractures of the mandible is dependent on proper diagnosis of the injury. Paramount in diagnosis of the details of the fracture and therefore the treatment options is the radiographic evaluation. In principle, these should be at least two films taken at right angles to each other. The plain films used include oblique views, posteroanterior (PA) Towne's view, and possibly a lateral view. All institutions have these views available to them. Some continue to use these views for routine screening of mandibular trauma. The efficacy of these views remains controversial if other screening techniques are available. Because of the diagnostic efficacy of panoramic radiographs and CT, the surgeons at our institution seldom obtain plain views except for the Towne's view, which we have found to be very useful in assessing displacement of subcondylar fractures.

A diagnostic-quality panoramic radiograph is the most comprehensive view possible with a single film and allows satisfactory visualization of all regions of the mandible (condyle, ramus, body and symphysis).[17] It is also useful in examining the existing dentition, presence of impacted teeth with respect to the fracture, alveolar process and position of the mandibular canal. [Figure 1]



**Figure 1.** Panoramic tomogram showing parasymphysis and subcondylar fractures of mandible.

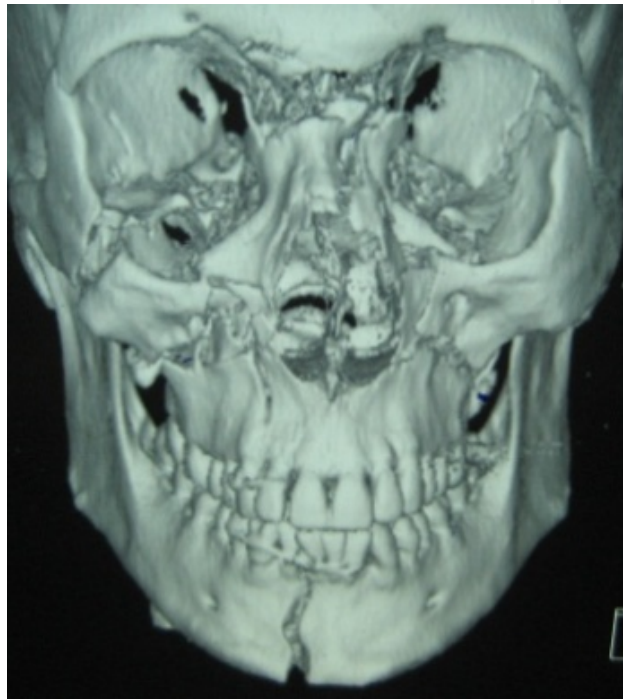In situations where a panoramic view of the mandible is not available, a series of different views of the mandible is required to adequately view all the anatomic regions of interest. This is more labor intensive and costly and subjects the patient to a higher dose of radiation. Despite the good visualization of the dentoalveolar structures obtained by a panoramic radiograph, additional periapical or occlusal radiographs are often helpful in viewing specific



areas of concern with more detail, especially when tooth or alveolar fractures are suspected. Parasymphysis fractures often benefit from occlusal films to display any obliquity of the fracture, which will certainly change the fixation method.

### 3.3. Computed tomography examination

Computed tomography (CT) currently offers the most detailed and comprehensive view of the facial skeleton. Current protocols allow for axial, coronal and reconstructed three-dimensional images to be formulated [Figure 2].



**Figure 2.** Three dimensional reconstruction CT of a panfacial fracture.

Despite this superior three-dimensional visualization, the use of CT scans for the diagnosis of isolated mandibular fractures is uncommon and may be cost-prohibitive. In our experience, the use of CT scans is reserved for cases involving complex (comminuted, avulsive, etc.) mandibular injuries or concomitant midfacial or orbital injuries. In some cases where a condylar fracture is suspected, the CT will allow for detailed three-dimensional imaging. Another useful application of the CT scan is in clinical situations (cervical spine injury, head injury) where the patient is not able to submit to routine radiographic positioning and techniques. Very young patients with limited cooperation may also be candidates for CT scan evaluation, but will often require sedation during the procedure. Magnetic resonance imaging (MRI) is of very limited value in evaluating bony injuries. It may be helpful to delineate injuries to the intracapsular structures of the TMJ, associated soft tissues or in cases of condylar displacement into the middle cranial fossa. Ultrasound has occasionally been used to determine condylar position after fractures.

#### 4. Closed versus open treatment of mandibular fractures

Mandibular fractures have been successfully treated by closed-reduction methods for hundreds of years. Maxillomandibular fixation (MMF) is used to immobilize the fractured segments and allow osseous healing. When considering between open versus closed reduction of mandibular fractures the advantages should be weighed against the disadvantages. Considerations include the site and characteristics of the fracture and the morbidities of the treatment. Unwanted results including bony ankylosis or decreased mouth opening can be prevented by early mobilization of the mandible. Early mobilization helps to prevent possible ankylosis especially in patients with intracapsular fractures of the condyle. It is preferred to avoid maxillomandibular fixation when fractures involve the temporomandibular joint (TMJ) because postoperative physiotherapy can be started much earlier.

Advantages of closed reduction include simplicity, decreased operative time, and avoidance of damage to adjacent structures. Disadvantages of maxillomandibular fixation include inability to directly visualize the reduced fracture, need to keep the patient on a liquid diet, and difficulties with speech and respiration. The traditional length of immobilization of fractures when treated by closed reduction has been 6 weeks. Juniper and Awty found that 80% of mandibular fractures treated with open or closed reduction and maxillomandibular fixation had clinical union in 4 weeks [18]. They were able to show a correlation between the age of the patient and the predictability of early fracture union. Armaratunga found that 75% of mandible fractures had achieved clinical union by 4 weeks. Fractures in children healed in 2 weeks whereas a significant number of fractures in older patients took 8 weeks to achieve clinical union [19]. Although maxillomandibular fixation has long been considered a benign procedure it can be associated with significant problems. An excellent review of the deleterious effects of mandibular immobilization on the masticatory system is provided by Ellis [20]. Closed reduction of mandibular fractures can adversely affect bone, muscles, synovial joints, and periarticular connective tissues. The effects of immobilization on bone have been recognized in the orthopedic literature for many years as “disuse osteoporosis”. Cortical and trabecular thinning, vascular distention, and increased osteoclastic activity have been described following joint immobilization [21]. Changes involving the musculature include not only muscle atrophy but also changes in muscle length and function.

#### 5. Rigid fixation

Rigid fixation in the mandible refers to a form of treatment that consists of applying fixation to adequately reduce the fracture and also permit active use of the mandible during the healing process. The four AO/ASIF principles are

1. anatomical reduction
2. functionally stable fixation
3. atraumatic surgical technique

#### 4. immediate active function.

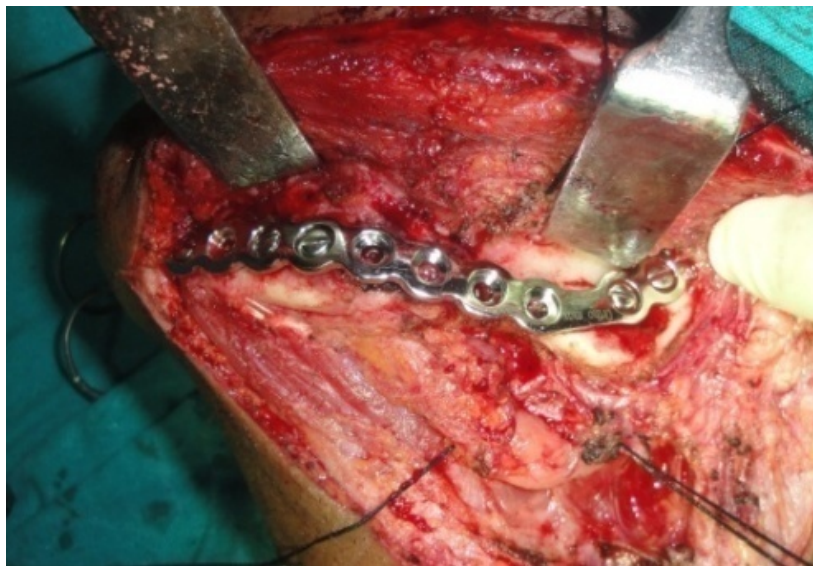
Although many osteosynthesis systems are currently available to treat mandibular fractures, the principles of plate application are similar. An overview of the various types follows.

#### 5.1. Compression plates

Compression plates cause compression at the fracture site making primary bone healing more likely. These plates can be bent in only two dimensions because of their design and if they are not contoured properly they are unable to produce compression. It is important to avoid compressing oblique fractures. They also require bicortical screw engagement to produce even compression along the fracture line. This necessitates their placement at the inferior border to eliminate damage to the inferior alveolar neurovascular structures or the roots of the teeth. A higher incidence of complications has been noted in fractures treated with compression plates [22]. Because of the relatively small cross section of bone surface in some fractures, interfragmentary compression is often not possible. At our centre, surgeons prefer noncompression plates for treating mandibular fractures.

#### 5.2. Reconstruction plates

Reconstruction plates are recommended for comminuted fractures and also for bridging continuity gaps. These plates are rigid and have corresponding screws with a diameter of 2.3–3.0 mm. Reconstruction plates can be adapted to the underlying bone and contoured in three dimensions. [Figure 3]



**Figure 3.** ORIF of a comminuted fracture using a Reconstruction Plate.

A problem that may be associated with conventional reconstruction plates is loosening of the screws during the healing process leading to instability of the fracture.



### 5.3. Locking reconstruction plates

In 1987 Raveh et al. introduced the titanium hollow-screw osteointegrated reconstruction plate (THORP) [23]. This system achieves stability between the screw and plate by insertion of an expansion screw into the head of the bone screw. This causes expansion of the screw flanges and locks them against the wall of the hole in the bone plate. Later Herford and Ellis described the use of locking reconstruction bone plate/screw system for mandibular surgery [24]. This system simplified the locking mechanism between the plate and the screw (Locking Reconstruction Plate, Synthes Maxillofacial, Paoli, PA) by engaging the threads of the head of the screw with the threads in the reconstruction plate, thus eliminating the need for expansion screws. Locking plate/screw systems offer advantages over conventional reconstruction plates. These plates function as internal fixators by achieving stability by locking the screw to the plate and allow greater stability as compared to conventional plates [25]. Fewer screws are required to maintain stability. The most significant advantage of this type of system is that it becomes unnecessary for the plate to intimately contact the underlying bone in all areas. As the screws are tightened they will not draw the plate and underlying bone toward each other.

### 5.4. Lag screw fixation

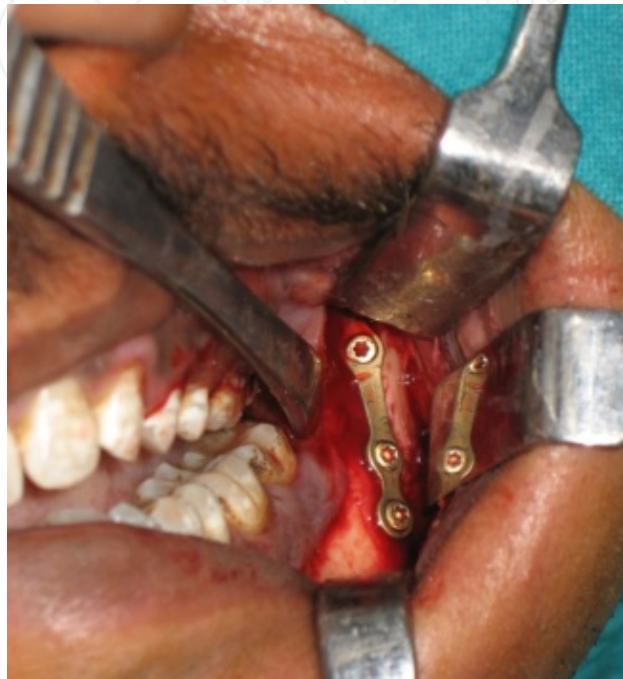Lag screws can provide osteosynthesis of mandibular fractures [26,27]. They work well in oblique fractures and require a minimum of two screws. The lag screw engages the opposite cortex while fitting passively in the cortex of the outer bone segment. This can be accomplished by using a true lag screw or by overdrilling the proximal cortex. This causes compression of the osseous segments and provides the greatest rigidity of all fixation techniques. The proximal cortex should be countersunk to distribute the compressive forces over a broader area and avoid microfractures. The anatomy of the symphyseal region of the mandible lends itself to use of lag screws in a different technique. The lag screws can be placed through the opposing cortices between the mental foramen and inferior to the teeth. Fractures should not be oblique with this technique because it may cause the fractures to override each other.

### 5.5. Miniplates

Miniplates typically refer to small plates with a screw diameter of 2.0 mm. These plates have been shown to be effective in treating mandibular fractures. Typically a superior and inferior plate is required for adequate fixation. An exception to this is in the mandibular angle region where a superior border plate placed at the point of maximal tension is sufficient [Figure 4].

An advantage of these plates is that they are stable enough to obviate the need for maxillo-mandibular fixation and have a very low profile. They are less likely to be palpable, which reduces the need for subsequent plate removal. Typically screws are placed monocortically but may be placed bicortically when positioned along the inferior border of the mandible. A minimum of two screws should be placed in each osseous segment. Smaller incisions and

less soft-tissue reflections are required with these plates when compared to larger plates and they can be placed from an intraoral approach, thus eliminating an external scar. Because these plates are less rigid than reconstruction plates, their use in treating comminuted fractures should be avoided. [28] A study at our centre evaluated the efficacy of 2.0-mm locking miniplate system versus 2.0-mm nonlocking miniplate system for mandibular fracture and concluded that both miniplate system present similar short-term complication rates. [29]



**Figure 4.** ORIF of an angle fracture using a single miniplate at the superior border.

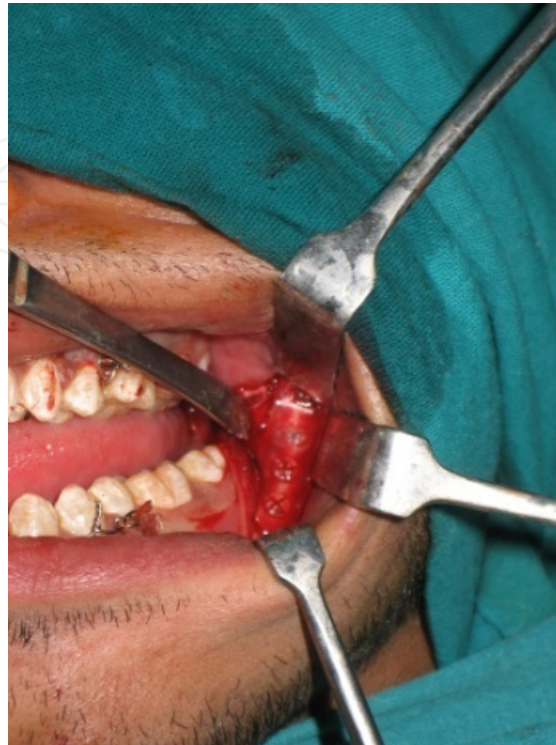### 5.6. Microminiplates

Microminiplates usually refer to small malleable plates with a screw diameter of 1.0–1.5 mm. Their use for mandibular surgery is limited because of their inability to provide rigid fixation and because they have a tendency for plate fracture during the healing process [30]. These plates can work well in the midface where the muscular forces are much less than those acting on the mandible. A recent study found a 30.4% complication rate when 1.3-mm microminiplates were used to provide osteosynthesis for mandibular fractures [31].

### 5.7. Bioresorbable plates

Bioresorbable plates are manufactured from varying amounts of materials including poly-dioxanone (PDS), polyglycolic acid, and polylactic acid. It has been shown that the breakage of a poly-L-lactic acid (PLLA) plate occurred at 50% of the yield strength required to break a miniplate [32]. Complications associated with these plates include inflammation and foreign-body-type reactions. Laughlin et al. showed in their study that resorbable plates are equal to the performance of titanium 2-mm plates, regarding healing of the fracture with

bone union and restoration of function. [33] We are also using resorbable plates for routine treatment of mandibular fractures. [Figure 5]



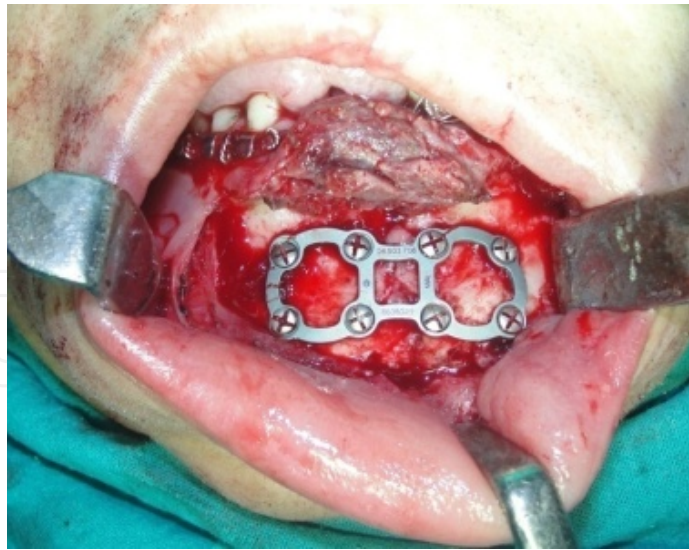
**Figure 5.** ORIF using a resorbable plate at the angle region.

The common complication which we encountered during their use was screw head fracture during tightening. Consideration may be given for use in pediatric patients with the understanding of the possible complications.

### 5.8. Three-dimensional miniplates

These miniplates are based on the principle that when a geometrically closed quadrangular plate is secured with bone screws, it creates stability in three dimensions. The smallest structural component of a 3-D-plate is an open cube or a square stone. [Figure 6]

Clinical results and biomechanical investigations in a study have shown a good stability of the 3-D-plates in the osteosynthesis of mandibular fractures without major complications. The thin 1.0 mm connecting arms of the plate allow easy adaptation to the bone without distortion. The free areas between the arms permit good blood supply to the bone. [34]. A study conducted at our center showed that there is no major difference in terms of treatment outcome between conventional and 3-Dimensional Miniplates, and both are equally effective in managing mandibular fracture. [35] We believe 3-D miniplates provide good stability and operative time is less because of simultaneous stabilization at both superior and inferior borders.



**Figure 6.** ORIF using a 3-Dimensional plate at symphysis fracture site.

## 6. General principles

### 6.1. Surgical technique

Intermaxillary fixation is placed prior to reducing a fracture. This allows for use of the occlusion to aid in anatomical reduction of the fracture. Use of full-arch bars combined with maxillomandibular fixation is the preferred method. The arch bars provide a way to maintain the occlusion postoperatively with elastic bands as needed during physiotherapy. The arch bars are usually removed after 4 weeks postoperatively.

The surgical approach depends on the site of the fracture. Either a transoral, vestibular, or transfacial approach may be performed. A facial approach provides excellent access but also produces a facial scar and adds the risk of damage to the facial nerve. Most fractures, excluding those of the condyle, can easily be approached through a transoral incision. A subperiosteal dissection with a periosteal elevator provides adequate access for reduction of the fracture and placement of fixation. Attention should be given to avoiding damage to the mental nerve, which exists the mental foramen near the apices of the premolar teeth. If additional exposure is needed, the nerve can be released by gently scoring the periosteum surrounding the nerve. Bone-reducing forceps are often helpful in reducing the fracture while adapting the bone plate. This also provides interfragmentary compression, making primary bone healing more likely. The smallest bone plate that will provide adequate stability under functional loads during the healing period is chosen. A minimum of two screws on either side of the fracture is required. Larger, more rigid plates are required to treat comminuted fractures or continuity defects [24]. The intermaxillary fixation that aided reduction of the fractures during plating is removed after the fixation is applied. A soft diet is recommended



for at least 3 weeks after miniplate fixation. It is important during the postoperative period to regain preinjury function, including maximal mouth opening, with active physiotherapy.

#### *6.1.1. Teeth in the line of fracture*

Most teeth in the line of fracture can be saved if appropriate antibiotic therapy and fixation techniques are used. Indications for removal of teeth in the line of fracture include grossly mobile teeth, partly erupted third molars with pericoronitis, teeth that prevent reduction of the fractures, fractured tooth roots, entire exposed root surfaces, or an excessive delay from the time of fracture to treatment. [36,37]

#### *6.1.2. Antibiotics and mandible fractures*

Zallen and Curry showed that mandibular fractures were associated with a 50% infection rate when patients did not receive antibiotic therapy. The infection rate was reduced to 6% for those patients who received antibiotics [38].

## **7. Treatment of specific fractures**

### **7.1. Symphysis fractures**

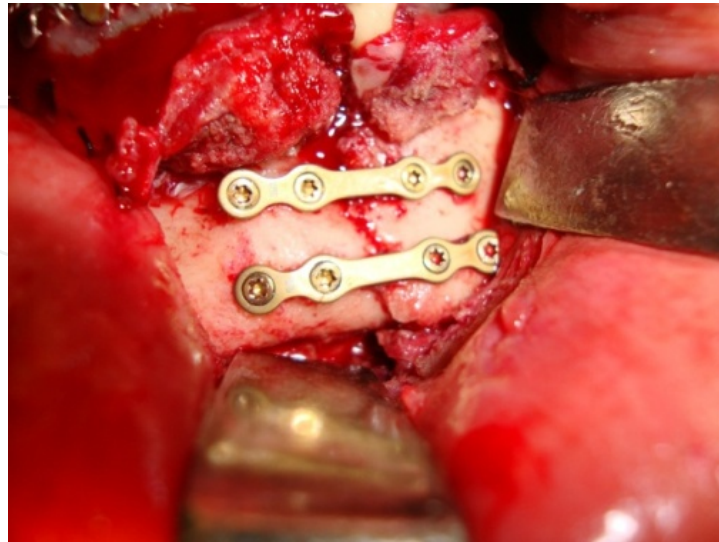
The optimal management of symphyseal and parasymphyseal fractures continue to evolve. Fractures in this area of the mandible predispose the patients to malocclusion and widening of the face if not properly treated. Arch bars and MMF are necessary to establish the pre-morbid relationship of the mandibular and maxillary teeth. However, care must be taken to avoid overtightening the MMF, which can cause flaring of the mandibular angles. The most common approach to the symphysis and parasymphysis is the transoral gingivolabial and gingivobuccal incision. With larger, comminuted fractures, an external approach may be necessary to accurately and rigidly fixate the mandible. Simple symphysis fractures can be treated with two miniplates. Because of the torsional forces generated during function, a single miniplate is insufficient to predictably maintain rigid fixation during healing [39]. One miniplate is placed at the inferior border and a second plate is placed superiorly. The superior plate is secured with a minimum of two monocortical screws in each segment whereas bicortical screws can be used on the inferior plate. Care should be taken to avoid damage to tooth roots while fixing the superior plate. These plates were placed in accordance to Champy's line of osteosynthesis. [Figure 7]

Several authors have shown that miniplate fixation along these lines is a very effective way to fixate these fractures. [40]

More rigid fixation should be considered for comminuted fractures. It is important to avoid "flaring" of the ramus in patients with a symphysis fracture and especially when combined with condyle fractures. This will be seen clinically as a dental crossbite of the posterior occlusion and also fullness of the mandibular angle region. This can be avoided by applying



pressure at the angle region during fixation, overbending the plate(s), and directly visualizing the lingual aspect of the reduced fracture.



**Figure 7.** ORIF of symphysis fracture using two miniplates; one at the superior border and other at the inferior border along Champy's line of osteosynthesis.

Lag screw fixation is other useful technique in the symphysis and parasymphysis region [41]. When the lag screws are applied, it is imperative to reduce the lingual border of the fracture and re-establish the appropriate intergonial distance by squeezing the mandibular angles together. While holding the reduction, the lag screws may be applied. For optimal strength, two lag screws are placed. Several authors have suggested that a single strong plate with an arch bar is adequate in managing symphyseal fractures. We are also using single strong plates at inferior border along with arch bar as a tension band in our cases. No major complications have been noted in any of our patients.

#### *7.1.1. Mandibular body fractures*

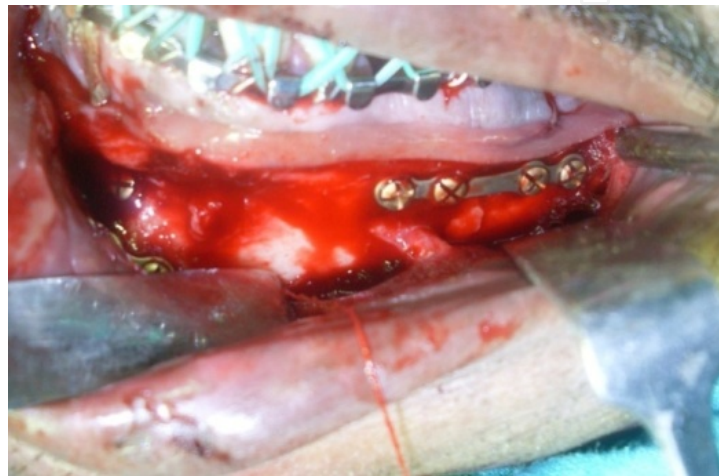Simple fractures involving the body of the mandible can be effectively treated with one miniplate along the Champy line of osteosynthesis. [Figure 8]

Care should be taken during the dissection to avoid damaging the mental nerve, which supplies sensation to the lower lip. If further reflection is necessary, the periosteum can be scored to release the nerve and allow improved visualization. Often a bone-reducing clamp can be applied prior to plate placement to aid in reduction of the fracture.

#### *7.1.2. Angle fractures*

The angle region of the mandible is one of the most common sites of fracture. Often trauma to the lateral mandible will cause a fracture at the angle and also involve the contralateral mandible. Many reasons for the greater proportion of fractures to this site have been cited. These include the presence of impacted third molars, a thinner cross-sectional area in this

region, and also the biomechanical lever arm in this area. A recent study looked at the incidence of fractures when teeth were involved. They found a significantly increased incidence of fractures involving the mandibular angle when there was an associated impacted third molar [42]. The angle region is a weak point, because the bone anterior and posterior (body and ramus, respectively) are thicker than the bone in the angle region [43]. These fractures are associated with the highest rate of complications [18]. The angle fracture can be further complicated by distraction and rotation by opposing forces of the elevator muscles (masseter, medial and lateral pterygoid, temporalis) and the depressor muscles (geniohyoid, genio-glossus, mylohyoid, digastrics).



**Figure 8.** ORIF of a mandibular body fracture with a single miniplate between root apices and inferior alveolar canal along Champy's line of osteosynthesis.

Many techniques for treating mandibular angle fractures have been described. Because no teeth are present in the posterior (proximal) segment, arch bars cannot be used to stabilize the segments and there is no control over the proximal segment. Closed-reduction techniques are often associated with rotation of the ramus. With the introduction of plate-and-screw osteosynthesis many surgical methods have been described. Those who advocate large bone plates are attempting to eliminate interfragment mobility and thus allow for primary bone union [23,44]. Others have questioned the need for absolute rigidity for treatment of angle fractures. In 1973, Michelet et al, described the use of small, malleable bone plates for treatment of angle fractures [13]. This led to a change from the previous belief that rigid fixation was necessary for bone healing. Later, Champy et al. validated the technique by performing several clinical investigations [14]. They determined the most stable location where bone plates should be placed based on the "ideal lines of osteosynthesis". The "Champy technique" involves placing a small bone plate along the superior border and using monocortical screws to secure the plate and avoid damage to the adjacent teeth or inferior alveolar neurovascular bundle. Absolute immobilization is not provided with this form of treatment (semirigid fixation). Clinical studies have shown that the amount of stability of the fractures is significant enough to eliminate the need for maxillomandibular fixation [45].

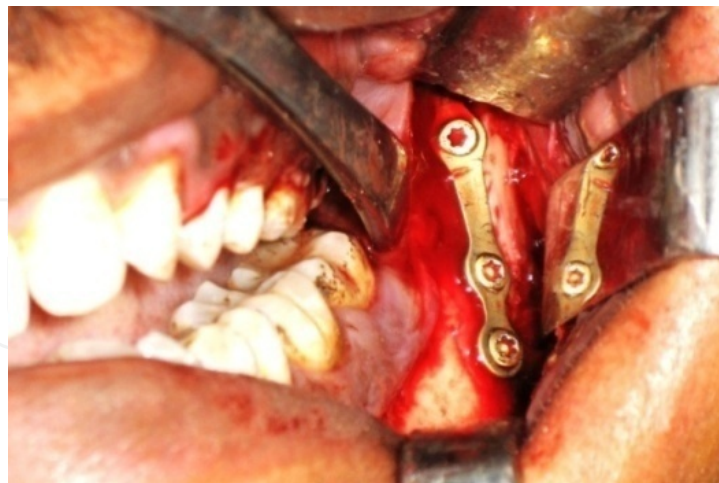The superior border plate neutralizes distraction forces (tension) on the mandible while preserving the self-compressive forces that occur during function.

A prospective study looked at eight methods for treating mandibular angle fractures [45]:

1. closed reduction;
2. extraoral ORIF with a large reconstruction plate;
3. intraoral ORIF using a single lag screw;
4. intraoral ORIF using two 2.0-mm minidynamic compression plates;
5. intraoral ORIF using two 2.4-mm mandibular compression plate;
6. intraoral ORIF using two noncompression miniplates;
7. intraoral ORIF using a single noncompression miniplate; and
8. intraoral ORIF using a single malleable noncompression miniplate.

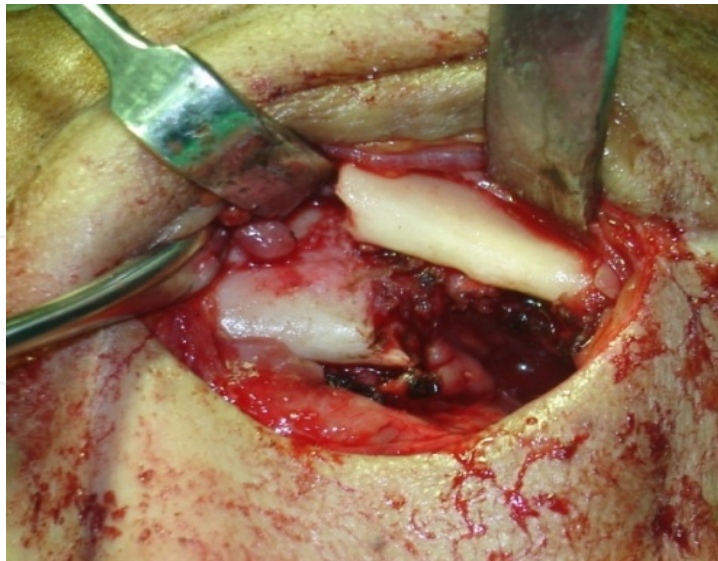
The results revealed that extraoral ORIF with a reconstruction plate and intraoral ORIF using a single miniplate are associated with the fewest complications (7.5% and 2.5%, respectively). This finding is interesting because the single miniplate is less rigid than the other forms of fixation, yet it is associated with the fewest complications. A possible explanation is that less extensive dissection is required and more of the blood supply is maintained.

We are also using intraoral ORIF using a single miniplate along the Champy's ideal line of osteosynthesis for angle fractures. [Figure 9]

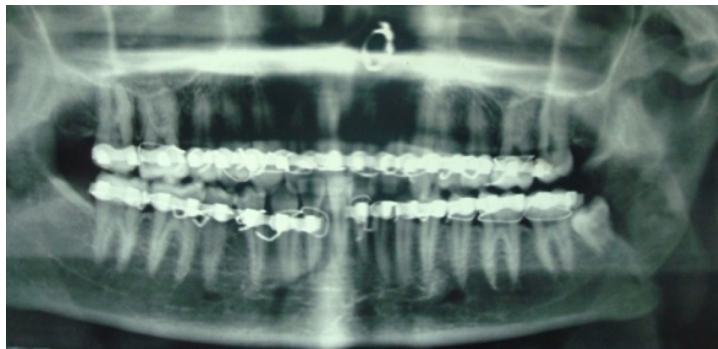


**Figure 9.** Intraoral ORIF using a single miniplate along the Champy's ideal line of osteosynthesis for angle fractures.

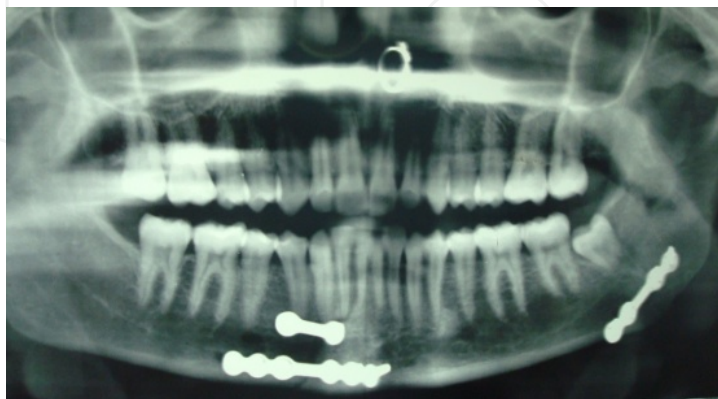
The main problem we encountered is the inability to achieve anatomic reduction in cases of severely displaced angle fractures through intraoral approach. A study conducted at our centre evaluated the efficacy of using a single miniplate at the inferior border in the management of a displaced angle fracture through extraoral approach. [Figure 10-12]



**Figure 10.** Intraoperative view showing displaced angle fracture exposed through extraoral approach.



**Figure 11.** Panoramic Tomogram showing displaced left angle fracture.



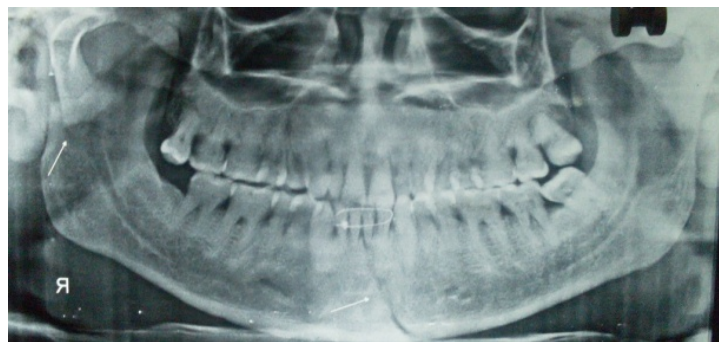
**Figure 12.** Panoramic Tomogram showing anatomically reduced angle fracture and fixation with a single miniplate at inferior border.



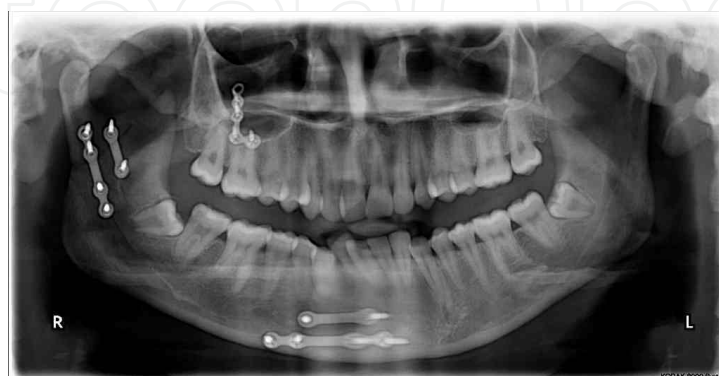The study concluded that outcomes are acceptable in patients but a multicenter study with an appropriate comparison group is required to substantiate a more generalizable conclusion of efficacy of this single miniplate at inferior border. [46]

### 7.1.3. Condyle fractures

Fractures of the condyle can involve the head (intracapsular), neck, or subcondylar region. The head of the condyle may be dislocated outside of the fossa. The most common direction of displacement is in an anteromedial direction because of the pull from the lateral pterygoid muscle, which inserts on the anterior portion of the head of the condyle. No other type of mandibular fracture is associated with as much controversy regarding treatment as those involving the condyle. Factors considered in deciding whether to treat a condyle fracture open or closed include the fracture level, amount of displacement, adequacy of the occlusion, and whether the patient can tolerate maxillomandibular fixation. Those who advocate open treatment cite advantages including early mobilization of the mandible, better occlusal results, better function, maintenance of posterior ramal height, and avoidance of facial asymmetries [47]. The ramal height shortening can be assessed on panoramic radiograph [Figure 13] and can be restored by open treatment of condylar fractures. [Figure 14]



**Figure 13.** Panoramic Tomogram showing displaced right subcondylar fracture and left parasymphysis fracture. Note that there is loss of ramal height on the right side.



**Figure 14.** Panoramic Tomogram of fixation of subcondylar fracture using two miniplates; the vertical ramal height is restored by ORIF of subcondylar fracture.



Others prefer closed reduction mainly because of the possible complications associated with open reduction including damage to branches of the facial nerve and a cutaneous scar. Recently endoscopic subcondylar fracture repair has been described with encouraging results [48]. Nonsurgical management (closed reduction) includes MMF with elastics for a variable period followed by guiding elastics so as to maintain the occlusion while allowing jaw physiotherapy during healing. Measurable criteria should be assessed whether treating by closed or open methods. These should include pain-free movement, mouth-opening, jaw movement in all excursions, preinjury occlusion, radiographic assessment of deviation of the fractured fragment and shortening of the ascending ramus [49]. Zide and Kent described the absolute and relative indications for open reduction of condyle fractures [50]. Absolute indications include

1. displacement of the condylar head into the middle cranial fossa;
2. impossibility of obtaining adequate occlusion by closed reduction;
3. lateral extracapsular displacement of the condyle; and
4. invasion by a foreign body (e.g. gunshot wound)

Relative indications include

1. bilateral condyle fractures in an edentulous patient;
2. unilateral or bilateral condyle fractures when splinting is not recommended for medical reasons;
3. bilateral condyle fractures associated with comminuted midface fractures; and
4. bilateral condyle fractures and associated gnathological problems (e.g. lack of posterior occlusal support).

The degree of displacement of the condylar fracture has been used in deciding between open or closed treatment. Mikkonen et al. and Klotch and Lundy recommended open reduction if the condylar displacement was greater than 45 degrees in a sagittal or coronal plane and Widmark et al. recommended opening such fractures if the displacement was greater than 30 degrees [51-53]. The author proposed a new classification of subcondylar fractures of the mandible based on ramal height shortening and degree of fracture angulation. [54] The classification is as follows:

## 8. Fracture classification

On the basis of Towne's and panoramic radiograph, the fractures are categorized into 3 classes:

1. Class 1 (minimally displaced)—fracture with ramal height shortening; < 2 mm and/or degree of fracture displacement; <10°.

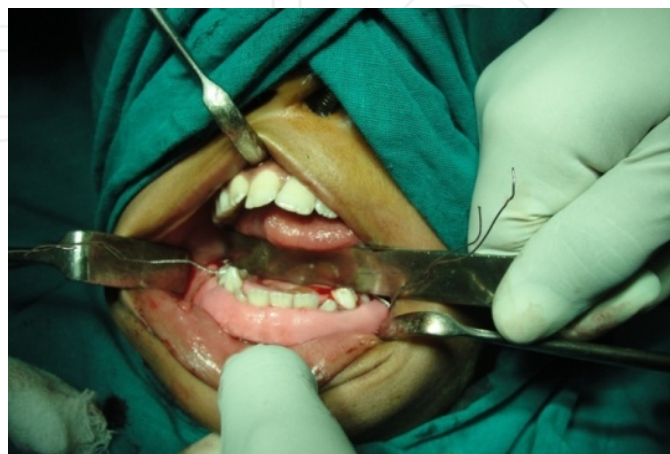2. Class 2 (moderately displaced)—fracture with ramal height shortening; 2 to 15 mm and/or degree of fracture displacement; 10 to 35°
3. Class 3 (severely displaced)—fracture with ramal height shortening; >15 mm and/or degree of fracture displacement; >35°.

This new classification based on ramal height shortening and degree of fracture displacement can better guide clinical treatment. Class 1 fractures should be treated by closed method, while open reduction is recommended in Class 2 and Class 3 cases.

Intracapsular fractures involving the condylar head are difficult to treat and most recommend close treatment of these fractures to avoid damage to adjacent structures. Fractures involving the condylar neck and subcondylar region can be approached with less morbidity. Many surgical approaches have been described with the most common being the retromandibular, submandibular, and preauricular approaches [55]. A nerve stimulator can be helpful in identifying branches of the facial nerve during the dissection. A prospective study compared the effect on facial symmetry after either closed or open treatment of mandibular condylar process fractures [56]. It was found that treatment by closed methods led to asymmetries characterized by shortening of the face on the side of the injury. The loss of posterior height on the side of fracture is an adaptation that helps re-establish a new temporomandibular articulation. Loss of facial height on the affected side can lead to compensatory canting of the occlusal plane. Treatment of condylar process fractures should be individualized. Many factors, including the patient's own preference, should be considered. Whether surgical or nonsurgical treatment is chosen, we recommend early mobilization during the healing process.

### 8.1. Pediatric fractures

The management of pediatric fractures is complicated by the presence of deciduous teeth and the growing mandible. Children tend to be less tolerant of MMF. An acrylic splint can be helpful in managing mandibular fractures in children. [Figure 15]



**Figure 15.** Intraoperative view of use of acrylic splint in managing mandibular fractures in children.

This can be used without MMF to allow early postoperative physiotherapy to avoid ankylosis and/or growth disturbances, which are more common in pediatric patients [57].

Condylar process fractures in children younger than age 12 should be treated by closed methods in most instances. Damage to the condylar growth center can result in delayed growth and in facial asymmetry. Dalhlstrom et al. showed good restitution of the TMJ and no growth disturbances in 14 children, 5 years after nonsurgical treatment of their fractures [58].

Early animal studies showed that there was little sacrifice of mandibular growth and symmetry with induced condyle fractures when treated with closed reduction. Boyne compared three methods of fracture treatment in Rhesus monkeys and found no difference between those treated with internal fixation (wire), MMF, or no treatment [59].

## 8.2. Edentulous fractures

Fractures of the edentulous mandible most commonly involve the body region. Changes that occur with age include decreased osteogenesis, mandibular atrophy, and reduced blood supply. With age the inferior alveolar artery contributes less and less to perfusion of the mandible [60]. The lack of teeth makes it difficult to adequately reduce the fracture because MMF cannot be used to help reduce the bony fragments. It is important to define more carefully 'edentulous' mandibles, since the literature shows that only those severely atrophic mandibles with a bone height less than 10 mm stand out as a 'difficult' or special problem. Above these heights, normal miniplate fixation may be effective.

These fractures can be treated by either open or closed reduction methods. Closed techniques often involve wiring a mandibular prosthesis in place with circummandibular wires to stabilize the fracture. The second Chalmers J. Lyons Academy Study of fractures of the edentulous mandible reviewed 167 fractures in 104 edentulous mandibles. Fifteen percent of the patients developed a delayed fibrous union and 26% treated by closed reduction techniques had problems with union. The fewest complications occurred with the patients who received transfacial open reduction and internal fixation [61].

In addition to adequate reduction and stabilization of the fractured segments, the successful management of fractures involving the edentulous mandible requires that consideration be given to the amount of bone present. When the mandible is severely atrophic, it is possible that healing will not occur even if open reduction and internal fixation principles are properly applied. In some circumstances, treatment consists of simultaneous bone graft reconstruction at the time of fracture repair. This is also appropriate treatment for patients presenting with non-union of an edentulous fracture. In most cases plans for definitive prosthetic reconstruction are delayed until full healing of the bony site has occurred. Some authors, however, do advocate early reconstruction with bone grafting and osseointegrated implants. [62]

Treatment methods for edentulous mandible fractures

- Closed reduction with the use of prosthetics (existing dentures or Gunning splints)

- External fixation
- Wire fixation
- Open reduction with internal fixation:
  1. reconstruction plates (2.3-2.7 mm diameter screws)
  2. mandible fixation plates (2.0-2.4 mm diameter screws):
    - dynamic compression plates
    - plates at both inferior and superior borders of the fracture
  3. bone grafting and miniplate fixation

### 8.3. Infected fractures

Infected mandibular fractures resulting from a delay in treatment can present certain challenges. Treatment by MMF, external fixation, and rigid internal fixation has been recommended. The goals of treating mandibular fractures that are complicated by an infection include resolution of the infection and achievement of bony union. Rigid internal fixation can predictably be used for treatment of infected mandibular fractures [63]. Fracture union and resolution can be attained with fixation. Even if the infection is prolonged, the fracture can heal as long as rigidity of the fracture is maintained. The plate can be removed after the bony union is achieved. Alternatively, if it is noted that plate or screw loosening has occurred and rigidity between the osseous segments is lacking, a nonunion is likely. The patient should be treated to regain rigidity and eliminate any loose hardware.

## 9. Complications

Complications following mandible fracture repair may be the result of the severity of the original injury, the surgical treatment or patient non-compliance with the postoperative regimen. Problems related to mandibular fractures present unique challenges to even the most experienced surgeon. The consequences of complications may include problems in anatomic form (cosmetic deformity) or residual functional disturbances. Complication rates have improved since the early days of wire fixation, but even the most sound fixation techniques can yield undesirable results. Probably no other specific area of oral and maxillofacial surgery has been studied in more detail than the mandible fracture. Despite this fact, little prospective evidence is available regarding the outcomes of the various treatment modalities. Retrospective studies offer some evidence that certain techniques have independently done better than others, but better prospective studies are needed to further evaluate and compare these techniques.

### 9.1. Malocclusion and malunion

Improper alignment of the fracture fragments results in facial asymmetry and malocclusion. Malunions occur in 0–4.2% of fractures. Malunions result from improper reduction, insufficient immobilization, poor patient compliance, and the improper use of rigid internal fixation [64]. Residual arch form deformity following the surgical repair of a mandibular fracture is often the result of inadequate reduction. Failure to re-establish the anatomic configuration of the arch form result in occlusal prematurities and misalignment which will compromise masticatory function. Clinicians treating mandibular fractures need to be familiar with dental anatomy and occlusion in order to balance the functional forces appropriately. Preoperative study models (with or without model surgery) and splint fabrication may aid in fracture reduction in some cases. Poor apposition of fracture segments may result from a delay in or an absence of treatment, inadequate treatment, inability to align segments secondary to the presence of a foreign body or loss of bony landmarks. Malaligned fracture segments noted early in the postoperative course may be corrected by returning to the operating room for removal of the hardware and repeat reduction with internal fixation. When the discrepancies are not caught early, the fracture segments will go on to heal in the improper anatomic position (malunion). Significant malunions of the mandible will produce asymmetry and/or functional disturbances and can only be resolved through carefully planned osteotomies for reconstruction of the mandibular arch form. The most common cause of failure of fracture healing (non-union) is residual mobility across the fracture site. Movement of the bone ends will disrupt the fibrovascular structures, decrease the recruitment of osteoprogenitor cells and allow for fibrous tissue ingrowth instead of bony healing. Other contributors to fracture non-union include impaired healing capacity secondary to illness, tobacco use and infection. Non-union of mandibular fractures requires reoperation to excise any fibrous tissue within the fracture gap in combination with application of bone fixation. In some instances, there may be loss of bone, producing a continuity defect which will require bone graft reconstruction. Treatment strategies vary from patient to patient and with each surgeon's experience in using different techniques.

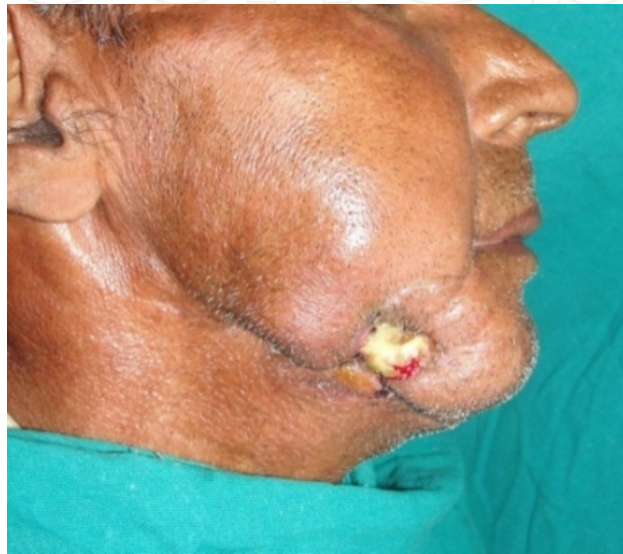Comprehensive management of malocclusion and malunion requires a full orthognathic workup. Standard osteotomies are performed at a different site from the malunion for restoration of preinjury occlusion. In general, treatment involves osteotomies at the healed fracture sites if they are within the dental arch, whereas fractures proximal to the dental arch are treated with ramus procedures.

### 9.2. Infection

Infection, the most common complication of mandibular fractures, is reported in 0.4–32% of all cases [64]. The potential for infection is always a consideration when treating fractures of the mandible, especially when there is communication with the oral cavity (e.g. compound fracture). Other risk indicators for increased chance of infection include active substance abuse and non-compliance with postoperative regimens [65]. A significant delay in treatment has also been associated with an increase in infection rates. [66] Other factors include mobility of the segments across the fracture site or loosening of screws



securing the plate. Poor plate adaptation, inadequate cooling during drilling, or placing the screw in the fracture line itself can lead to increased chance of infection developing. Leaving a tooth in the line of fracture can also lead to an increased incidence of complications. Of the facial bones, the mandible is the most frequently infected region following surgical intervention for traumatic injury. This is likely due to instability of the segments from muscular actions on the proximal and distal segments and the density of the bone. Manifestations of infection include cellulitis, abscess formation, fistula, osteomyelitis and rarely necrotizing fasciitis. [Figure 16]



**Figure 16.** Patient with non-union of body fracture of edentulous mandible; exposed necrotic bone with pus discharge can be noticed.

Management begins with clinical examination and plain radiographic studies to assess the status of the fractured segments and the hardware. The use of CT and MRI is appropriate when there is concern that the infection involves the surrounding soft tissues of the neck. Specimens for bacterial culture and sensitivity studies should be done as early as possible in the patient's clinical course.

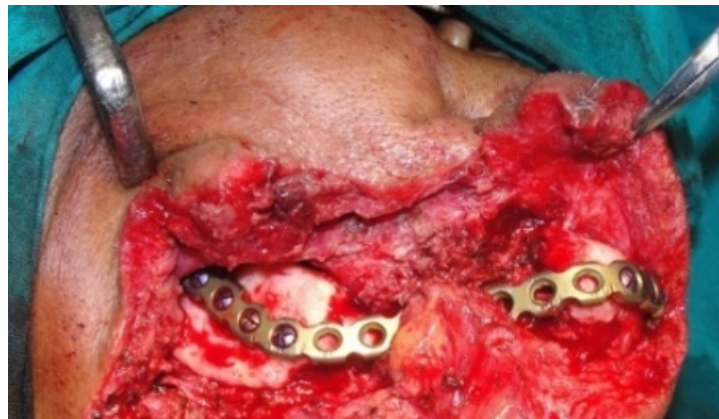Infections involving rigid fixation of mandibular fractures may not necessitate plate removal (minor) or may be major and require plate removal (loose hardware). Treatment of the infection requires antibiotics and determination of the stability of the fracture. The fracture site can heal and develop union in the face of infection as long as there is rigidity across the fracture site.

### 9.3. Delayed union and nonunion

Delayed union is failure of fracture union by 2 months. Infection, mobility, systemic disease, advanced age, and mandibular atrophy are contributing factors [64]. Delayed union by definition means that the fracture will eventually heal without further surgery. Rigid internal

fixation carries a lower incidence of delayed union compared to nonrigid fixation: 0–2.8% versus 1–4.4% [64].

Nonunion is the failure of a fracture to unite owing to arrested healing and requiring additional treatment to achieve fracture union. Mobility is the major cause of nonunion. More than 33% of nonunions involve infection [64]. Large bony gaps, traumatized devitalized tissue, older age, intervening soft tissue, and systemic disease all can contribute to nonunion. Mobility at the fracture site is manifested in nonunions. Debridement of the fracture fragments, bone grafting, usually from the iliac crest, and rigid fixation with internal or external fixation usually achieves fracture union. [Figure 17]



**Figure 17.** Placement of a Locking Reconstruction Plate for treatment of a mandibular non-union site.

#### 9.4. Nerve injury

Sensory nerve injury, particularly of the inferior alveolar and mental nerves, commonly occurs with mandibular fractures [67]. In 11–59% of displaced mandibular fractures there is sensory nerve injury at diagnosis [68,69]. Most injuries are neuropraxias secondary to stretching or compression and resolve spontaneously. Causes of inferior alveolar or mental nerve injury are displaced fractures, delay in treatment, and improper use of drill or screws. Facial nerve dysfunction infrequently results from mandibular trauma. Damage to the facial nerve in temporal bone fractures can lead to paralysis. Retrograde edema distal to the geniculate ganglion can cause temporary facial nerve loss after condylar fractures. Condylar dislocations can cause facial nerve injury distal to the stylomastoid foramen. Injury to the facial nerve branches usually takes place iatrogenically during surgical treatment, though lateral displacement of the condyle can cause facial nerve injury [69]. The marginal mandibular branch is the one usually injured. The surgical anatomy of this branch has been well described by Dingman and Grabb [70], and meticulous dissection under the platysma in the region of the facial artery with identification of the branches of the marginal mandibular nerve can prevent injury to this nerve [71]. The design of the preauricular incision in the approach to the condyle can be accomplished by observing the landmark work of Al-Kayat and Bramley [72].

Patients with a paresthesia following a mandibular fracture should be observed during the postoperative period and the level of neurosensory return (subjective) is documented. In cases where patients report no improvement in their level of sensation after 6-8 weeks, the clinician may consider obtaining baseline nerve function data using objective testing. Objective neurosensory testing before 6 weeks may be of limited value because it is difficult to discern a Sunderland Class I injury (excellent prognosis without surgery) from a Sunderland Class V injury (poor prognosis without surgery) that early in the postoperative course. In the case of Sunderland Class IV and V injuries (equivalent to axonotmesis and neurotmesis) surgical repair is considered between 3 and 6 months [73]. Immediate management of inferior alveolar nerve injury at the time of mandibular fracture repair has been advocated in situations where there is displacement at the fracture site and anesthesia [74]. Although a more aggressive approach may have merit, it would be limited to situations where there is an observed transection of the nerve. Immediate decompression and exploration are not necessary in less severe nerve injuries (Sunderland Class I, II, III) and surgical maneuvers used to expose the nerve trunk (decortication) may compromise subsequent fracture healing

## Author details

Amrish Bhagol<sup>1\*</sup>, Virendra Singh<sup>1</sup> and Ruchi Singhal<sup>2</sup>

\*Address all correspondence to: [bhagol.amrish@gmail.com](mailto:bhagol.amrish@gmail.com)

1 Department of Oral and Maxillofacial Surgery, Post Graduate Institute of Dental Sciences, Pt. B.D. Sharma University of Health Sciences, Rohtak, Haryana, India

2 Department of Pedodontic and Preventive Dentistry, Post Graduate Institute of Dental Sciences, Pt. B.D. Sharma University of Health Sciences, Rohtak, Haryana India,

## References

- [1] The Edwin Smith Surgical Papyrus (trans. Breasted JH) University of Chicago Press, Chicago 1930
- [2] Lipton JS. Oral surgery in ancient Egypt as reflected in the Edwin Smith Papyrus. *Bulletin of the History of Dentistry* 1982; 30: 108
- [3] Hippocrates. *Oeuvres completes* (English trans. Withington ET) Cambridge, MA 1928
- [4] Salicetti G. *Cirurgia* 1275
- [5] Prevost N. Translation of Salicetti's *Cirurgia*. Lyons, France 1492

- [6] Gilmer TL. A case of fracture of the lower jaw with remarks on the treatment. *Archives of Dentistry* 1887; 4: 388
- [7] Ivy RH. Fracture of condyloid process of the mandible. *Annals of Surgery* 1915; 61: 502
- [8] Buck G. Fracture of the lower jaw with replacement and interlocking of the fragments. *Annalist NY* 1846; 1:245.
- [9] Dorrance GM, Bransfield JW. *The History of Treatment of Fractured Jaws*, vols 1 and 2. Washington, DC, 1941.
- [10] Gilmer TL. Fractures of the inferior maxilla. *Ohio State J Dent Sci* 1881-1882;1: 309;2:14,57, 112.
- [11] Luhr HG: Zur Stablen osteosynthese bei Unterkeiferfrakturen. *Dtsch Zahnarzt Z* 1968;23: 754.
- [12] Spiessl B. *New concepts in maxillofacial bone surgery*. Springer-Verlag, Berlin 1976
- [13] Michelet FX, Deymes J. Dessus B. Osteosynthesis with miniaturized screwed plates in maxillofacial surgery. *J Maxillofac Surg* 1973; 1: 79.
- [14] Champy M, Lodde JP, Schmitt R, et al. Mandibular osteosynthesis by miniature screwed plates via a buccal approach. *J Maxillofac Surg* 1978;6: 14.
- [15] Suuronen R. Biodegradable fracture fixation devices in maxillofacial surgery. *International Journal of Oral and Maxillofacial Surgery* 1993;22: 50
- [16] Eppley BL, Prevel CD, Sarver D. Resorbable bone fixation: its potential role in cranio-maxillofacial trauma. *Journal of Craniomaxillofacial Trauma* 1996;2: 56
- [17] Chayra GA, Meador LR, Laskin OM. Comparison of panoramic and standard radiographs for the diagnosis of mandibular fractures. *Journal of Oral and Maxillofacial Surgery* 1985;44: 677
- [18] Juniper RP, Awty MD. The immobilization period for fractures of the mandibular body. *J Oral Surg* 1973; 36:157.
- [19] Armaratunga NA de S. The relation of age to the immobilization period required for healing of mandibular fractures. *J Oral Maxillofac Surg* 1987; 45:111.
- [20] Ellis E. The effects of mandibular immobilization on the masticatory system: a review. *Clin Plast Surg* 1989; 16:133–146.
- [21] Geiser M, Trueta J. Muscle action, bone rarefaction and bone formation: an experimental study. *J Bone Joint Surg* 1958; 40B:282–311.
- [22] Iizuka T, Lindqvist C. Rigid internal fixation of fractures in the angular region of the mandible: an analysis of factors contributing to different complications. *Plast Reconstr Surg* 1993; 91:265–271.

- [23] Raveh J, Vuillemin T, Ladrach K, et al. Plate osteosynthesis of 367 mandibular fractures. *J Craniomaxillofac Surg* 1987; 15:244–253.
- [24] Herford AS, Ellis E. Use of a locking reconstruction plate=screw system for mandibular surgery. *J Oral Maxillofac Surg* 1998; 56(11):1261–1265.
- [25] Soderholm A-L, Lindqvist C, Skutnabb K, et al. Bridging of mandibular defects with two different reconstruction systems: an experimental study. *J Oral Maxillofac Surg* 1991; 49:1098.
- [26] Niederdellman H, Shetty V. Solitary lag screw osteosynthesis in the treatment of fractures of the angle of the mandible: a retrospective study. *Plast Reconstr Surg* 1987; 80(1):68–74.
- [27] Forrest CR. Application of minimal-access techniques in lag screw fixation of fractures of the anterior mandible. *Plast Reconstr Surg* 1999; 104:2127–2134.
- [28] Edwards TJ, David DJ. A comparative study of miniplates used in the treatment of mandibular fractures. *Plast Reconstr Surg* 1996; 97(6):1150–1157.
- [29] Singh V, Kumar I, Bhagol A. Comparative evaluation of 2.0-mm locking plate system vs 2.0-mm nonlocking plate system for mandibular fracture: a prospective randomized study. *Int J Oral Maxillofac Surg*. 2011; 40(4):372-7.
- [30] Potter J, Ellis E. Treatment of mandibular angle fractures with a malleable noncompression miniplate. *J Oral Maxillofac Surg* 1999; 57:288–292.
- [31] Kim YK, Nam KW. Treatment of mandible fractures using low-profile titanium miniplates: preliminary study. *Plast Reconstr Surg* 2001; 108:38–43.
- [32] Bos RRM, Boering G, Rozema FR, et al. Resorbable poly (L-lactide) plates and screws for the fixation of zygomatic fractures. *J Oral Maxillofac Surg* 1987; 45:751.
- [33] Laughlin RM, Block MS, Wilk R, Malloy RB, Kent JN. Resorbable plates for the fixation of mandibular fractures: a prospective study. *J Oral Maxillofac Surg*. 2007 ;65(1): 89-96
- [34] Farmand M. Experiences with the 3-D miniplate osteosynthesis in mandibular fractures. *Fortschr Kiefer Gesichtschir*. 1996; 41:85-7.
- [35] Singh V, Puri P, Arya S, Malik S, Bhagol A. Conventional versus 3-Dimensional Miniplate in Management of Mandibular Fracture -A Prospective Randomized Study. *Otolaryngol Head Neck Surg*. May 2012 ( Online Published)
- [36] Neal DC, Wagner W, Alpert B. Morbidity associated with teeth in the line of mandibular fractures. *J Oral Surg* 1978; 36:859.
- [37] Shetty V, Freymiller E. Teeth in the line of fracture: a review. *J Oral Maxillofac Surg* 1989; 47:1303.
- [38] Zallen RD, Curry JT. A study of antibiotic usage in compound mandibular fractures. *J Oral Surg* 1975; 33:431.



- [39] Champy M, Lodde JP, Schmitt R, et al. Mandibular osteosynthesis by miniature screwed bone plates via a buccal approach. *J Oral Maxillofac Surg* 1978; 6:14.
- [40] Chritah A, Lazow SK, Berger J. Transoral 2.0-mm miniplate fixation of mandibular fractures plus 2 weeks maxillomandibular fixation: A prospective study. *J Oral Maxillofac Surg* 2002; 60:167-170.
- [41] Ellis E 3<sup>rd</sup>. Lag screw fixation of mandibular fractures. *J Craniomaxillofac Trauma* 1997; 3: 16-26
- [42] Fuselier JC, Ellis E, Dodson TB. Do mandibular third molars alter the risk of angle fractures? *J Oral Maxillofac Surg* 2002; 60(5):514-518.
- [43] Shubert W, Kobienia BJ, Pollock RA. Cross-sectional area of the mandible. *J Oral Maxillofac Surg* 1997; 55:689-692.
- [44] Becker R. Stable compression plate fixation of mandibular fractures. *Br J Oral Surg* 1974; 12:13-23.
- [45] Ellis E III. Treatment methods for fractures of the mandibular angle. *Int J Oral Maxillofac Surg* 1999; 28(4):243-252.
- [46] Singh V, Gupta M, Bhagol A. Is a Single Miniplate at the Inferior Border Adequate in the Management of an Angle Fracture of the Mandible? *Otolaryngol Head Neck Surg*. 2011;145(2):213-6.
- [47] Ellis E, Throckmorton G. Facial symmetry after closed and open treatment of fractures of the mandibular condylar process. *J Oral Maxillofac Surg* 2000; 58(7):719-728.
- [48] Martin M, Lee C. Endoscopic mandibular condyle fracture repair. *Atlas Oral Maxillofac Surg Clin North Am*. 2003;11(2):169-78.
- [49] Singh V, Bhagol A, Goel M, Kumar I, Verma A. Outcomes of Open Versus Closed Treatment of Mandibular Subcondylar Fractures: A Prospective Randomized Study. *J Oral Maxillofac Surg*. 2010;68(6):1304-9
- [50] Zide MF, Kent JN. Indications for open reduction of mandibular condyle fractures. *J Oral Maxillofac Surg* 1983; 41:89.
- [51] Mikkonen P, Lindqvist C, Pihakari A, et al: Osteotomy-osteosynthesis in displaced condylar fractures. *Int J Oral Maxillofac Surg* 1989; 18:267.
- [52] Klotch DW, Lundy LB. Condylar neck fractures of the mandible. *Otolaryngol Clin North Am* 1991; 24:181.
- [53] Widmark G, Bagenholm T, Kahnberg KE, et al: Open reduction of subcondylar fractures. *Int J Oral Maxillofac Surg* 1996; 25:107.
- [54] Bhagol A, Singh V, Kumar I, Verma A. Prospective Evaluation of a New Classification System for the Management of Mandibular Subcondylar Fractures.. *J Oral Maxillofac Surg*. 2010;68(6):1304-9

- [55] Ellis E, Dean J. Rigid Fixation of mandibular condyle fractures. *Oral Surg Oral Pathol* 1993; 76:6.
- [56] Ellis E, Throckmorton G, Palmieri C. Open treatment of condylar process fractures: assessment of adequacy of repositioning and maintenance of stability. *J Oral Maxillofac Surg* 2000; 58:27–34.
- [57] Kaban LB, Mulliken MD, Murray JE. Facial fractures in children: an analysis of 122 fractures in 109 patients. *Plast Reconstr Surg* 1977; 59:15.
- [58] Dahlstrom L, Kahnberg KE, Lindahl. 15 years follow-up on condylar fractures. *Int J Oral Maxillofac Surg* 1989; 18(1):18–23.
- [59] Boyne PJ. Osseous repair and mandibular growth after subcondylar fractures. *J Oral Surg* 1967; 25(4):300–309.
- [60] Bradley JC. Age changes in the vascular supply of the mandible. *Br Dent J* 1972; 132(4):142–144.
- [61] Bruce RA, Ellis E III. The second Chalmers J Lyons Academy study of fractures of the edentulous mandible. *J Oral Maxillofac Surg* 1993; 51(8):904–911.
- [62] Eyrich GK, Gratz Kw, Sailer HF. Surgical treatment of the edentulous mandible. *Journal of Oral and Maxillofacial Surgery* 1997;55: 1081-1087
- [63] Koury M, Ellis E. Rigid internal fixation for treatment of infected mandibular fractures. *J Oral Maxillofac Surg* 1992; 50:434–443.
- [64] Koury M. Complications of mandibular fractures. In: Kaban LB, Pogrell AH, Perrot D, eds. *Complications in Oral and Maxillofacial Surgery*. Philadelphia: WB. Saunders, 1997:121–146.
- [65] Passeri LA, Ellis E, Sinn DP. Relationship of substance abuse to complications with mandibular fractures. *Journal of Oral and Maxillofacial Surgery* 1993;51: 22-25
- [66] Moulton-Barrett R, Rubinstein AJ, Salzhauer MA et al. Complications of mandibular fractures. *Annals of Plastic Surgery* 1998;41 :258-263
- [67] Thaller SR. Management of mandibular fractures. *Arch Otolaryngol Head Neck Surg* 1994; 120:44.
- [68] Izuka T, Lindquist C. Sensory disturbances associated with rigid internal fixation of mandibular fractures. *J Oral Maxillofac Surg* 1991; 49:1264.
- [69] Marchena JM, Padwa BL, Kaban LB. Sensory abnormalities associated with mandibular fractures: incidence and natural history. *J Oral Maxillofac Surg* 1998; 56:822–825.
- [70] Dingman RO, Grabb WC. Surgical anatomy of the mandibular ramus of the facial nerve based on the dissection of 100 facial halves. *Plast Reconstr Surg* 1962; 29:266.
- [71] Brusati R, Paini P. Facial nerve injury secondary to lateral displacement of the mandibular ramus. *Plast Reconstr Surg* 1978; 62(5):728–733.

- [72] Al-Kayat A, Bramley PA. A modified pre-auricular approach to the temporomandibular joint and malar arch. *Br J Oral Maxillofac Surg* 1979.
- [73] Zuniga JR. Advances in microsurgical nerve repair. *Journal of Oral and Maxillofacial Surgery* 1993; 51 (suppl I): 62-68
- [74] Thurmuller P, Dodson TB, Kaban LB. Nerve injuries associated with facial trauma: natural history, management, and outcomes of repair. *Oral and Maxillofacial Surgery Clinics of North America* 2001; 13(2): 283-293