

We are IntechOpen, the world's leading publisher of Open Access books Built by scientists, for scientists

6,900

Open access books available

186,000

International authors and editors

200M

Downloads

Our authors are among the

154

Countries delivered to

TOP 1%

most cited scientists

12.2%

Contributors from top 500 universities



WEB OF SCIENCE™

Selection of our books indexed in the Book Citation Index
in Web of Science™ Core Collection (BKCI)

Interested in publishing with us?
Contact book.department@intechopen.com

Numbers displayed above are based on latest data collected.
For more information visit www.intechopen.com



New Concepts in Impacted Third Molar Surgery

Mohammad Hosein Kalantar Motamedi and Farshid Kavandi

Additional information is available at the end of the chapter

<http://dx.doi.org/10.5772/54648>

1. Introduction

Surgery for removal of impacted third molar surgeries may be associated with several postoperative complications; these complications are more common in the mandible than in the maxilla; they may include bleeding, dry socket, nerve injury, delayed healing, periodontal pocketing, and infection. Many are preventable.[1] All third molars need not be removed independent of disease findings and patients need not unnecessarily have to accept adverse consequences associated with the surgery risks and discomforts in the absence of pain, radiographic findings of pathology, and or marked clinical evidence of disease. However, when surgery is indicated several new concepts and techniques presented in this chapter can prevent and or manage some of the common postoperative sequel of impacted third molar surgery.[1,2]

2. Assessments for removal of impacted third molars

2.1. Arch-space tooth-size discrepancy

The most significant variable associated with eruption seems to be the retromolar space available for the tooth. [3] The accuracy of prediction has improved remarkably, with the highest values being 97%. Thus, when there is no space available for eruption the tooth should be removed (Fig.1).

2.2. Other factors for preventive removal

The Finnish Current Care guideline indicates three distinct groups of teeth for preventive removal: horizontal teeth, root ends growing close to the nerve, and partially erupted vertical teeth. On average, this preventive group comprises 25% of lower 3rd molars. Thus, instead of

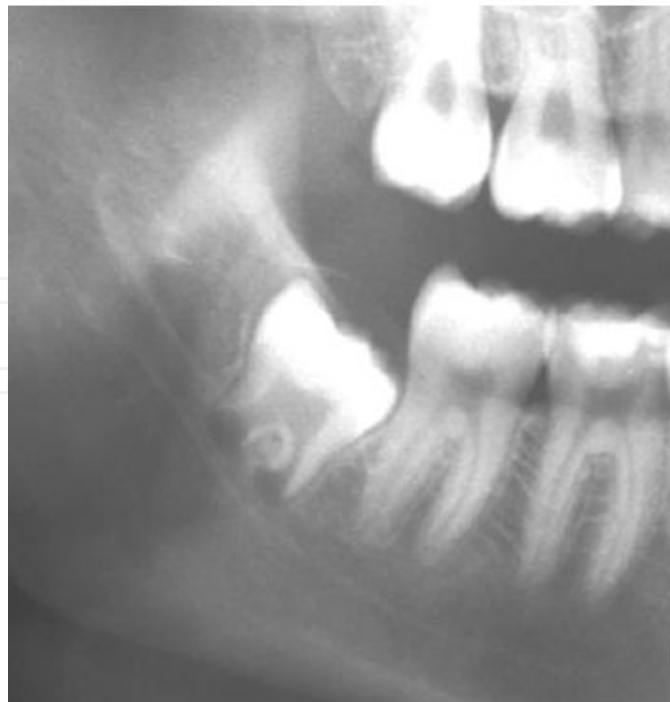

Figure 1. Lack of space for eruption of impacted lower 3rd molar.

removing all third molars preventively, actually, it is necessary to remove only one fourth of third molars. The remaining may be treated later according to signs and symptoms. [3] Dental caries, tooth displacement and pathology are obvious indications for removal of third molars (Fig.2).

2.3. Presurgical assessment

Surgical procedures should be planned and executed according to scientific evidence. Estimating possible difficulty in the removal of third molars is a constant challenge for surgeons. [4] There is a highly significant correlation between the level of difficulty for surgical removal of lower third molars (predicted by the anatomic variables) and postoperative inflammatory complications.[5]

2.3.1. Weight

Surgical difficulty in overweight patients is attributed to the herniation of the cheek intraorally making retraction difficult. [4]

2.3.2. Depth of impaction

The results of Tong Lim et al showed that the depth of impaction of the maxillary wisdom tooth serves as a factor for greater possibility of an oroantral perforation.; a deeper impaction requires a larger amount of bone removal to deliver the third molar and, hence, is more likely to cause damage to the sinus lining during the operative procedure. A cone-beam computed

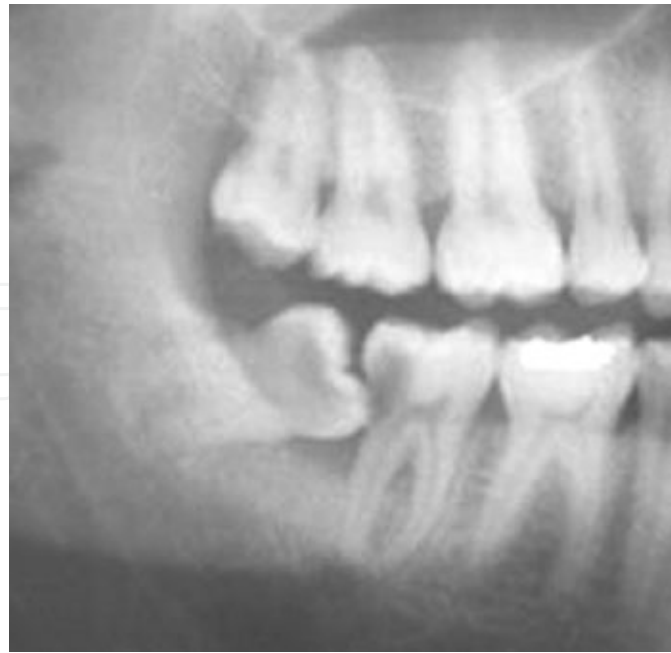

Figure 2. Carious lesion of the 2nd molar and pulpal exposure caused by impacted lower 3rd molar.

tomogram may be a better method to measure the proximity of the roots of the maxillary third molar to the sinus floor.[6]

2.3.3. Pathological processes

Complications are inevitable when the tooth is associated with a pathological process and must be removed. In these cases, bone resorption reduces the degree of difficulty; unless the pathology is an associated odontoma or cementoblastoma etc. [7] Complications occur in nearly half of the cases with associated pericoronitis which includes alveolitis, infection, etc.

2.3.4. Orientation of the impaction

Deviation from the vertical alignment of the tooth increases surgical difficulty. Greater difficulty occurs in cases classified as C3 category (Pell and Gregory classification). [4]

2.3.5. Root morphology and number of roots

Root morphology and number of roots are significantly associated with difficulty. Limited root development (tooth germ) allows rotation of the tooth around its axis, commonly requiring sectioning and time-consuming surgery of more than 30 minutes. Teeth with complete and divergent roots also prove more difficult to remove. Such teeth are often treated with sectioning before any mobility is attained because the fragmentation reduces the retention areas and facilitates removal with greater preservation of the adjacent bone and anatomical structures.[4]

2.3.6. Proximity of the alveolar nerve

The relation between the mandibular canal and tooth roots should be considered during extractions. However, radiographic images do not provide the necessary reliability.

The hypothesis is that when the white line of the mandibular canal is absent or indistinct where the canal intersects the tooth root, or divergence of the canal or darkening of the root at that location the mandibular canal is possibly entrapped.[8] Cone beam CT is indicated.

2.3.7. Proximity between the second and third molars

Closeness and proximity between the second and third molars makes surgery more difficult. The space between the distal surface of the second molar and mesial surface of the third molar and the periodontal ligament space was significantly associated with surgical difficulty. Contact of the root of the second molar and the crown of the impacted third molar require sectioning and special surgical technique.[1,2,4]

2.3.8. Angulation of the third molar

According to Chang, the greater the angulation of the third molar, the more difficult it is to remove and to maintain oral hygiene. During a multivariate logistical regression analysis, angulation was continually an important factor. Tooth angulation can be a precise indicator for the prophylactic removal of partially erupted mandibular third molars. The partially erupted third molar is also a predisposing factor to food impaction and in the development of distal caries on the mandibular second molar as well (Fig. 3). [6]

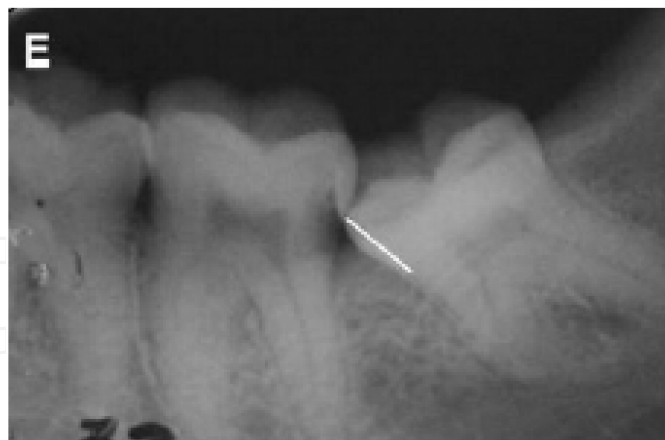

Figure 3. Angulated impacted lower 3rd molar causing carious lesion of the 2nd molar and predisposing to food impaction and periodontal pocket formation.

2.3.9. Existing periodontal pocket

There is evidence that supports removing third molars when at least 1 pocket depth of at least 4mm is measured in the third molar region in young adults around an asymptomatic third

molar, or distal of an adjacent second molar because of an association with a decreased odds of periodontal disease progressing over time in teeth more anterior in the mouth. The removal of mandibular third molars appears to significantly improve the periodontal status on the distal root of second molars, positively affecting overall periodontal health.[2] Although the prevention of progression of periodontal disease, or the elimination of periodontal disease is often given as justification for third molar removal. Nevertheless, there are occasions when removal of third molars can either create or exacerbate periodontal problems on the distal aspect of the lower second molar.[9] The most important predictor of the final bone level behind the second molar was the bone level on the distal aspect of the second molar on completion of removal of the third molar [9]; when there is no distal septum bone formation may be hampered.

2.3.10. Preoperative NSAIDs and analgesic agents

Studies evaluating the preoperative administration of NSAIDs and pain in oral surgery have been published. The beneficial effects of the preoperative administration of piroxicam, ketorolac, meloxicam, parecoxib and dexamethasone with rofecoxib have been documented. Some authors found a lower consumption of rescue analgesics and a delay in the onset of pain when the NSAIDs were administered before the surgical procedure. [10]

The maximum plasma peak (MMP) after the administration of 400 mg of ibuprofen occurs after 32 min. It is also known that the maximum concentrations of prostaglandins around damaged tissues are obtained approximately 1 h after injury. Another important aspect that has to be taken into account is to obtain MMP of the NSAIDs before the local anesthetic wears off. This is an important consideration and seems to support the use of long-lasting anesthetics to increase the residual analgesic effect.[10]

2.3.11. Radiographic evaluations

More attention should be given to optimize the use of CBCT to cover difficult cases that may give rise to complications.[11,12] Although CT scan is the gold standard to disclose a close relation between the lower third molar roots and the mandibular canal, for several reasons, including cost and radiation dose, it is not usually the first radiographic technique of choice. IAN injury after third molar extraction is normally caused by close anatomic proximity or by the surgical technique. If the cause of injury is the anatomic relation, then CT would be useful only for diagnostic purposes, i.e. to warn the patient of an increased risk with a higher positive predictive value than with panoramic radiography alone. However, the value and accuracy of this prediction is questionable, because if the cause of the injury is the surgical technique, then CT would help to minimize the risk of IAN injury only if it changed the way the surgeon operates, e.g. planning tooth sectioning if the IAN has a course between the roots or minimizing buccal osteotomy if the IAN has a buccal position close to the crown of the third molar impaction.[13]

2.3.12. Age

According to a number of authors, age is the most consistent factor in the determination of surgical difficulty, considering the differences in bone density associated with age. Moreover, the increase in age is associated with complete root formation, which may be related to the higher rate of complications among patients over 25 years of age compared with younger patients. Bone density of the tooth has been described as important indicator for the prediction of surgical difficulty. Studies indicate that as one becomes older, third molars become more difficult to remove, may take longer to remove, and may result in an increased risk for complications associated with removal. The age of 25 years appears in many studies to be a critical time after which complications increase more rapidly. There are no studies indicating a decrease in complications with increasing age. It also appears that recovery from complications is more prolonged and is less predictable and less complete with increasing age. As such, many clinicians recommend removal of 3rd molars in young adults. [14]

2.3.13. Temporomandibular joint problems

Removal of third molars can cause or exacerbate pre-existing temporomandibular joint disorders (TMD), particularly internal derangements of the tmj. The relationship, however, is indirect because third molars are often removed in an age group of patients where internal derangements of the TMJ are relatively common. One study of 60 third molar referrals showed that 13% of patients having third molars removed had pre-existing TMJ dysfunction. A prospective case-control study involving 72 patients showed that, on examination of patients with TMJ dysfunction, there is either no increase or a statistically insignificantly higher instance of TMJ dysfunction in those who have undergone third molar removal versus those who have not. A case-control study involving 2217 patients with a history of third molar removal and 2217 subjects without third molar removal also showed an insignificant increase of TMJ symptoms in those with a history of third molar removal. Therefore it appears that third molar removal is not a significant factor in the initiation or exacerbation of TMJ problems. However, a longitudinal study of 34491, 15-year-old patients followed up for 5 years indicated that 23% of all TMJ dysfunction in this group might be due to third molar removal [15] Excessive mouth opening especially for a long period of time and use of excessive force upon extraction and failure to support the jaw may predispose to TMD.

2.3.14. Nerve involvement

Case studies have shown that the inferior alveolar nerve may be involved after third molar removal in anywhere from 0.5% to 5% of lower third molar removals. In many cases this can be predicted preoperatively from panoramic radiographs and, more recently, from cone beam computed tomography scanning, showing the relationship of the inferior alveolar nerve to the roots of the lower third molars. Lingual nerve involvement associated with third molar removal occurs less frequently but may be more problematic for patients. Estimates of the incidence of lingual nerve involvement from case series show an incidence of between 0.2% and 2% of lower third molar removals. [9]

Narrowing of the IAN canal increases the risk for postoperative IAN impairment. This information is new to the literature and the evidence is strong.

The absence of cancellous bone between the nerve and the tooth, in other words, direct contact between the 2 structures, is another independent factor.

Thus IAN position has a close association with the 2 independent predictors of injury, namely direct contact and narrowing of the IAN canal.[15]

Fully developed roots increase the risk for postoperative nerve impairment. This was expected because fully developed roots are likely to have closer contact to the IAN bundle. This is another argument for early removal of wisdom teeth.[15]

Patients meeting any of the known criteria:

Diversion of the IAN canal,

Darkening of the root where the IAN canal crosses the root, and

Interruption of the white line bordering the IAN canal where it crosses the root, may benefit from CBCT or 3D imaging. Moreover, the legal demand for more detailed information on the incidence of potential complications is met and automatically documented by the imaging study.[15]

Kim showed that age, impaction depth, and the 5 radiographic superimposition signs—darkening of the roots, deflection of the roots, narrowing of the roots, dark and bifid apex of the roots, and narrowing of the canal—were significantly associated with neurosensory deficits of the IAN after mandibular third molar extraction (Fig. 4).[16]

Doucet showed that removing mandibular third molars at the time of the BSSO procedure will minimize postoperative neurosensory disturbance of the IAN by decreasing its entrapment and manipulation. [17]

2.3.15. Coronectomy as an option

Coronectomy was developed as a relatively new preventive method to decrease the prevalence of IAN injury compared with the conventional total removal of the lower third molar. The crown of the impacted lower third molar is often the cause of the food impaction, dental caries, or pericoronitis that troubles the patients. By removing the crown and leaving the root(s) behind, the problems are solved and the risk of an IAN deficit is obviated.[18]

Coronectomy is performed when contact between the mandibular third molar apex and the inferior alveolar nerve is suspected. The efficacy of coronectomy compared with conventional tooth extraction has been recognized in recent years. The absence of transmission images indicative of periapical lesions and the presence of bone covering more than 99.2% of the retained roots showed a safe postoperative course at the 1- year follow-up after coronectomy. [19] It is stated that retained roots after coronectomy in the lower third molars produce no complications in terms of infection, pain, or the development of pathologies within the first 3 years. Root eruption can occur in a very small percentage of patients and may require reoperation to remove the root.[18]

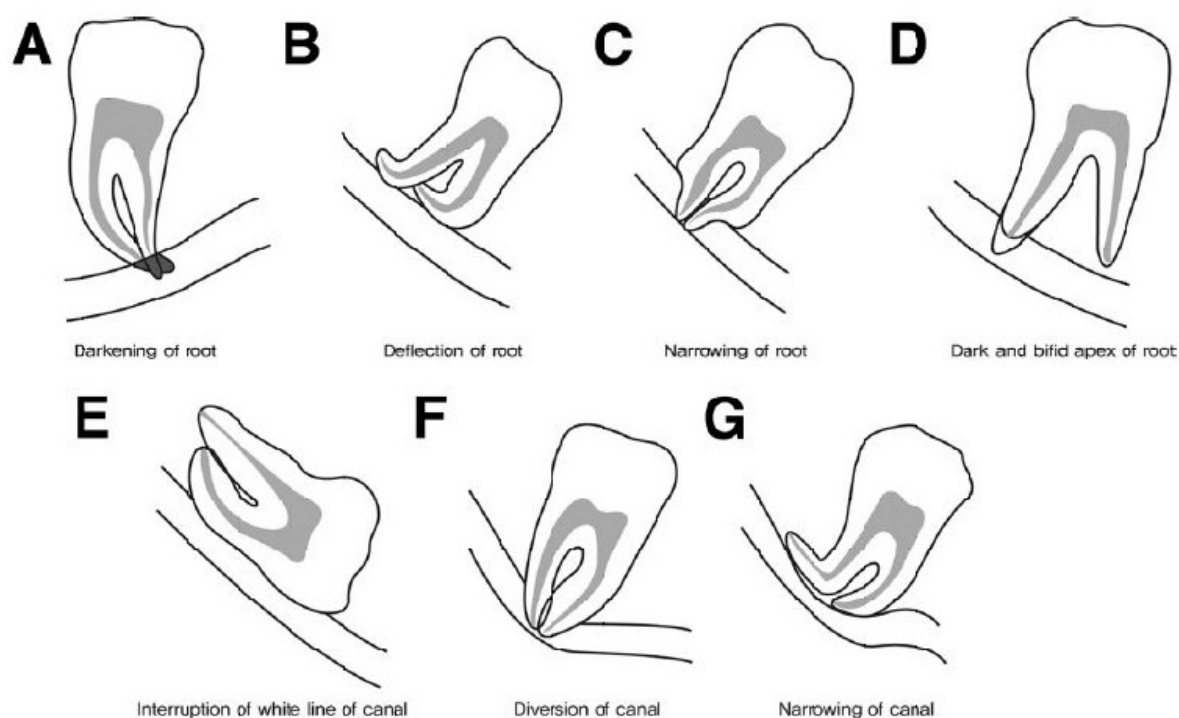


Figure 4. Signs significantly associated with neurosensory deficits of the IAN after mandibular third molar extraction.

In the rare event if after coronectomy, the retained roots erupt into the oral cavity and become infected. In such cases, it is appropriate to extract the retained roots after they move away from the mandibular canal (Fig. 5.).

2.3.16. Sinus communication

This is a complication encountered with upper 3rd molars; most communications close spontaneously without surgery. Chiapasco in a retrospective study of complications of 500 impacted maxillary third molars, reported that a sinus communication was seen in 0.8% ; none required surgery. A prospective cohort study of 684 patients indicated a sinus communication in 13% of patients following 3rd molar surgery. Another prospective cohort study of 389 upper third molar extractions showed a sinus perforation rate of 5.1%, with female patients, older patients, and more complicated extractions having a higher incidence.[9]

2.3.17. Flap design

Baqain showed probing depth was significantly greater with envelope flaps in the early postoperative period [20]

Erdogan et al. demonstrated a lower pain score. Alveolar osteitis was not reported in either group, whereas a previous randomized, prospective split mouth study demonstrated a higher

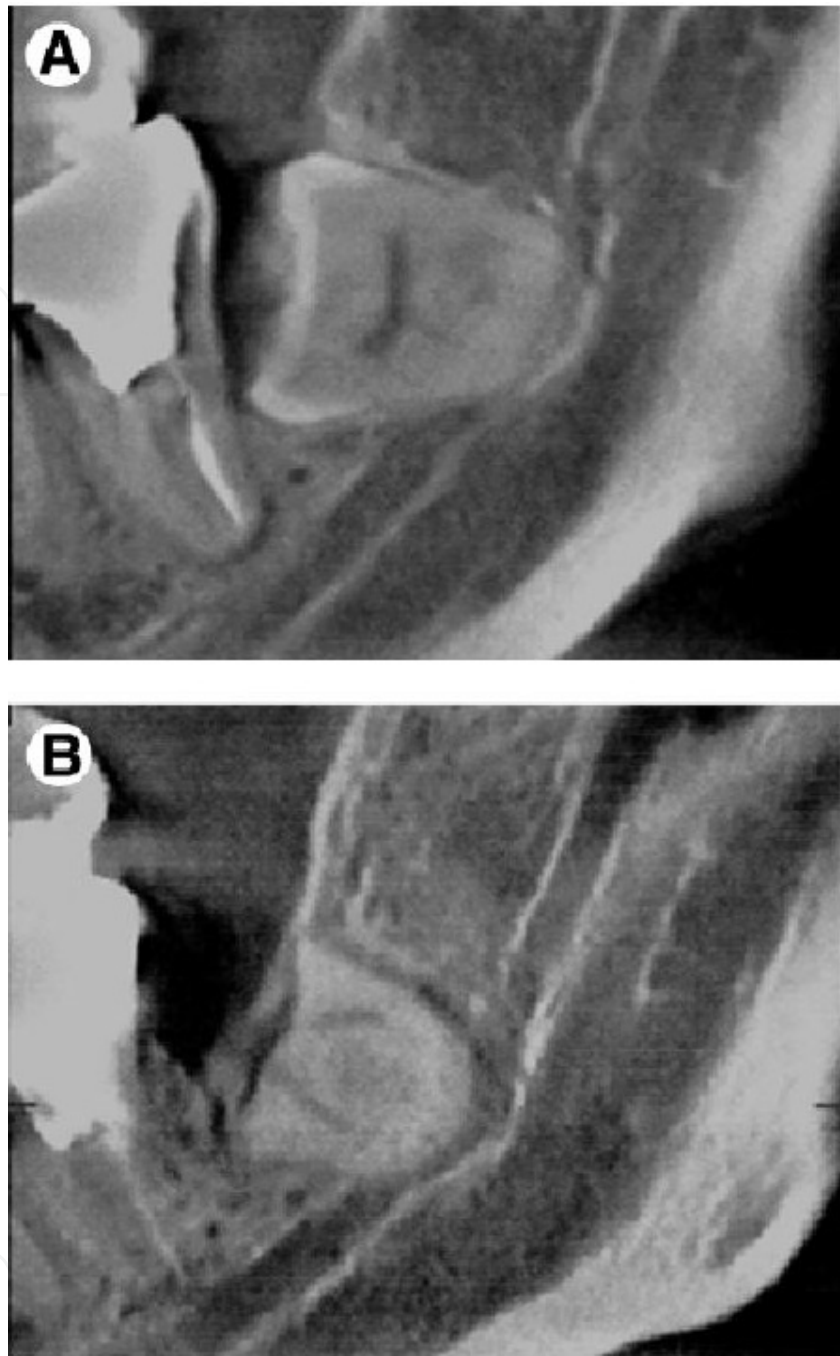


Figure 5. A. Coronectomy of an impacted 3rd molar with nerve involvement. B. One year later shows bone formation as well as root migration.

incidence of alveolar osteitis in the envelope flap group, even though the difference was not statistically significant.[20]This was also documented by Haraji.[21]

Chaves et al. in their study on young subjects with good oral hygiene showed that flap design, envelope or three cornered flaps, had no influence on periodontal health postoperatively; both caused shallow pocket depth. [20]

2.3.18. Periodontal defect

Periodontal defects have been a frequent occurrence postoperatively at the distal aspect of the mandibular second molar after the removal of impacted third molars. Among several studies, it was shown that 43.3% of the cases result in probing depths of 7mm or greater 2 years after removal of the third molar.[22]

Pocket formation behind the second molar after surgical removal of an impacted mandibular third molar is an occasional postoperative complication that cannot always be

Prevented (especially when present preoperatively). This complication may necessitate further surgical intervention to eliminate the pocket or to regenerate bone. Such interventions are fraught with difficulty and limited success.

However, in some cases that have fully bone-impacted third molar there is no clinical or radiographic evidence of a pocket distal to mandibular second molar even though the crown of the impacted tooth is in close contact with the distal root of the second molar. Since there is no distoproximal bone below the alveolar crest behind the second molar. Removal of this overlying alveolar crestal bone (to remove the impaction) may cause a deep bone defect distal to the second molar extending down to the base of the extraction socket. Thus, the alveolar crest must be preserved (Fig. 6).

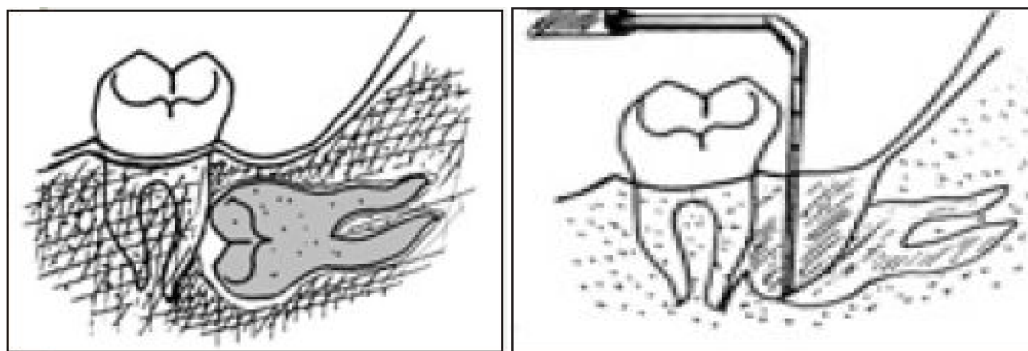


Figure 6. A. Fully bone impacted lower 3rd molar (crown to root impaction) with no pocket preoperatively. B. Resulting pocket if the crestal bone is removed to take out the impaction.

In 1999, Motamedi popularized a technique to prevent this occurrence in such cases and coined the term “buccal window”.

Technique. After-full thickness mucoperiosteal flap reflection and bone exposure, bone removal is started in the lateral cortex 2 to 3 mm below the bony crest using an electric surgical handpiece and a round surgical bur. An oval “window” of buccal bone is removed over the lateral aspect of the crown of the impacted wisdom tooth. The anterior part of the buccal window should be no closer than 1 to 2 mm from the distal root of the second molar (to prevent iatrogenic root damage). After the crown and cervical part of the impacted tooth and the upper third of its roots have been exposed, the tooth is sectioned vertically at the cemento-enamel junction using a rose or fissure bur; the gap created in this way should be sufficient to

accommodate movement of the sectioned crown. However, to prevent damage to the lingual or the alveolar nerve, the tooth is not sectioned completely. A straight elevator is placed in the groove to separate the crown from its roots. The crown is then sectioned horizontally and delivered buccally through the window (in pieces) using a hemostat. Next, the roots are sectioned at the bifurcation and removed. After removal of the dental follicle, the flap is sutured in place.[1,2 23] This technique ensures that no postoperative pocket is formed.

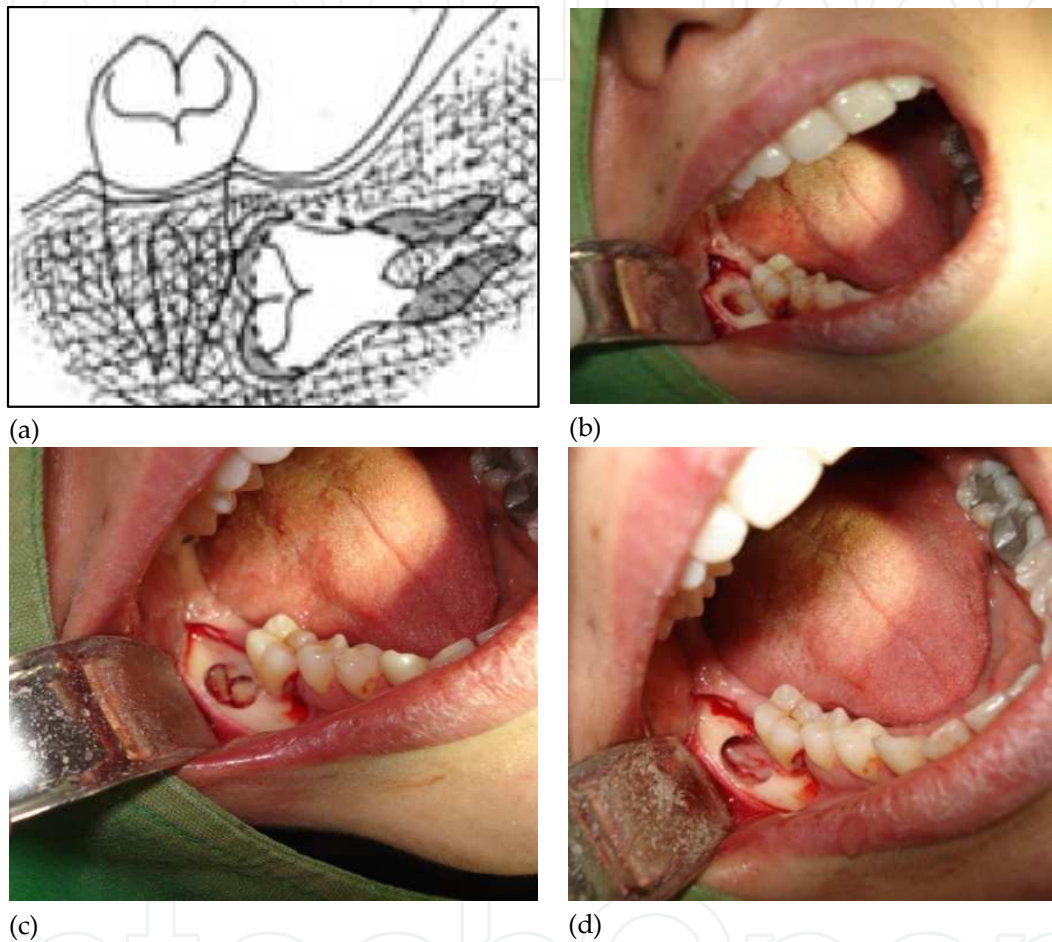


Figure 7. A. An oval “window” of buccal bone is removed over the lateral aspect of the crown of the impacted wisdom tooth. The anterior part of the buccal window should be no closer than 1 to 2 mm from the distal root of the second molar (to prevent iatrogenic root damage). B. A buccal window has been created over the crown of the impaction. C. After the crown and cervical part of the impacted tooth and the upper third of its roots have been exposed, the tooth is sectioned vertically at the cemento-enamel junction using a rose or fissure bur; the gap created in this way should be sufficient to accommodate movement of the sectioned crown. D. The tooth has been removed and the crest preserved.

2.4. Damage to the gingiva

Iatrogenic gingival damage is more apt to occur in young adolescents with tooth-sized arch-length discrepancies who have been referred for removal of impacted mandibular third molars for orthodontics. In these patients, the mandibular arches are often underdeveloped, and the

surgeon often finds the second molar only partially erupted. The distal part of this tooth is often adjacent to the anterior border of the ascending ramus with almost no distobuccal collar of keratinized gingiva clinically evident. The mandibular third molar is often incompletely formed and impacted in the ramus with no retromolar pad. Only a thin band of keratinized gingiva (often less than 1 mm in width) may be noticeable on the buccal aspect of the lower 2nd molar tooth. In such cases, flap reflection and removal of the impacted mandibular third molar occasionally lead to destruction of what little attached gingiva was present before surgery. Disruption of the gingival attachments of the second molar and destruction of the fragile attached gingival collar will cause an immediate loss in vestibular depth because of the pull of the buccinator muscle insertions on the flap. This often prevents cervical reattachment of the gingiva to the second molar, hindering healing of the remaining nonkeratinized gingiva, which leads to plaque retention, inflammation, and pocket formation, requiring periodontal therapy secondarily.[24]

Current techniques to regenerate or graft keratinized gingiva in the distobuccal region of the mandible are fraught with difficulty. The anatomy of the posterior mandible with the closeness of the external oblique ridge to the cervix of the second molar and the shallow sometimes nonexistent, buccal vestibule in this area make preparation of a bed for grafting very difficult. Additionally, after the mucoperiosteum has been reflected, the buccinator muscle insertions pull upward on the flap, preventing stabilization of free grafts.[24] In 2000 Motamedi presented the “lingual flap” technique to restore attached gingiva around second molar.

Technique. When the width of attached gingiva on the lingual aspect of the second molar is adequate, a posteriorly based finger flap of keratinized gingiva can be mobilized and used to increase or restore keratinized gingiva on the buccal and distal aspects of the tooth. The submarginal incision on the buccal aspect facilitates stabilization of the finger-flap and prevents displacement via the buccinator. By using a submarginal incision on the lingual aspect and remaining within the confines of the lingual attached gingiva, regeneration of the donor site is ensured. Periodontal dressing is placed (**Fig. 8**).

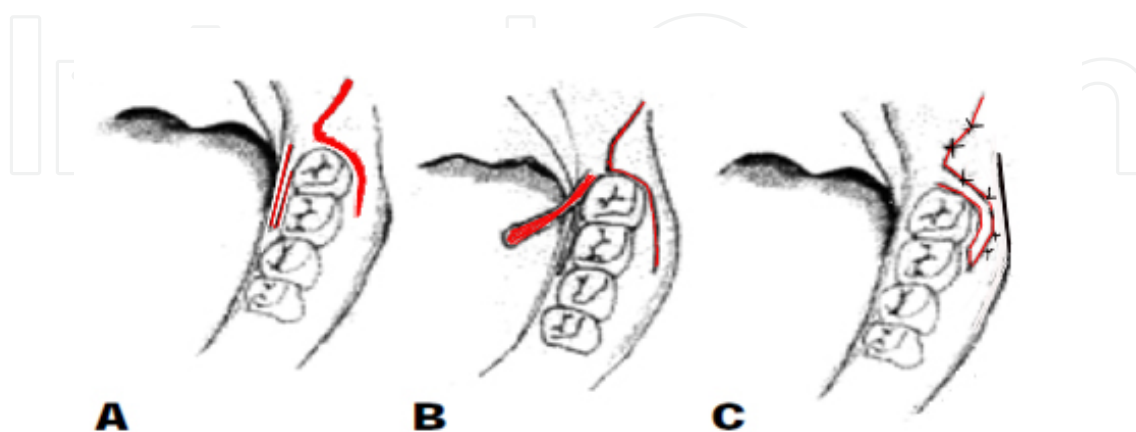


Figure 8. A. Finger flap incision on lingual side within the attached gingiva. Triangular flap on buccal side. Impacted 3rd molar has been removed. B. Flap raised on a pedicle. C. Flap transpositioned into the buccal flap incision.

Because of lingual retromolar anatomy, the surgeon must take into consideration the proximity of the lingual nerve to the third molar region. Damage to this nerve with its intimate relationship with the chorda tympani may result in loss of taste and lingual salivary gland secretion, in addition to loss of sensation in the anterior two-thirds of the tongue on the affected side. By averaging data from several recent studies, the mean vertical distance of the nerve from the distolingual alveolar crest in the region of the mandibular third molar was found to be about 4.45 mm, and the average horizontal distance of the nerve to the lingual cortex was 2.18 mm. But, in 10% to 15% of the cases, the nerve was reported at or above the lingual cortical crest in the most distal region of the third molar tooth.

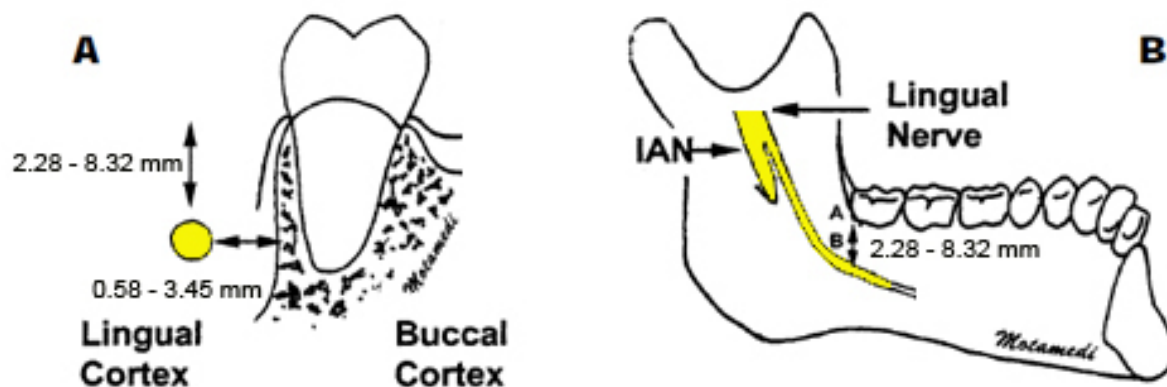


Figure 9. A. Distance of the lingual nerve to the lingual cortex. B. Distance of the lingual nerve to the lingual crest in the distolingual area of the 3rd molar.

However, in this technique, lingual damage is unlikely for 3 reasons. First, because the technique is executed anterior to the third molar socket while the course of the lingual nerve pursues a steep descending medial course into the tongue from the distal part of the third molar crest forward; thus nerve damage during lingual flap mobilization is unlikely anterior to this point. Second, the incisions used in mobilization of the lingual finger flap go back no farther than the distal aspect of the second molar and remain within the confines of the lingual attached gingiva; therefore, lingual nerve damage during the procedure is improbable because the nerve does not enter the attached gingiva. Third, the surgeon may opt to bring in a suprapariosteal lingual flap, which does not carry the risk of damaging the lingual nerve (Fig. 10).[24]

2.5. Double impactions

Simultaneously impacted mandibular second and third molars in adolescent patients with arch space deficiency, although relatively uncommon, may be encountered in clinical practice. The decision of which tooth to save and which to extract may be difficult. If the second molar is to be extracted—aside from the difficulty of the procedure to surgically remove the tooth from under the third molar while not displacing the third molar tooth bud—the orthodontic point of view presents the problem of waiting for mandibular third molar eruption to occur (18 years of age and above) and then bringing the mandibular third molar tooth forward and

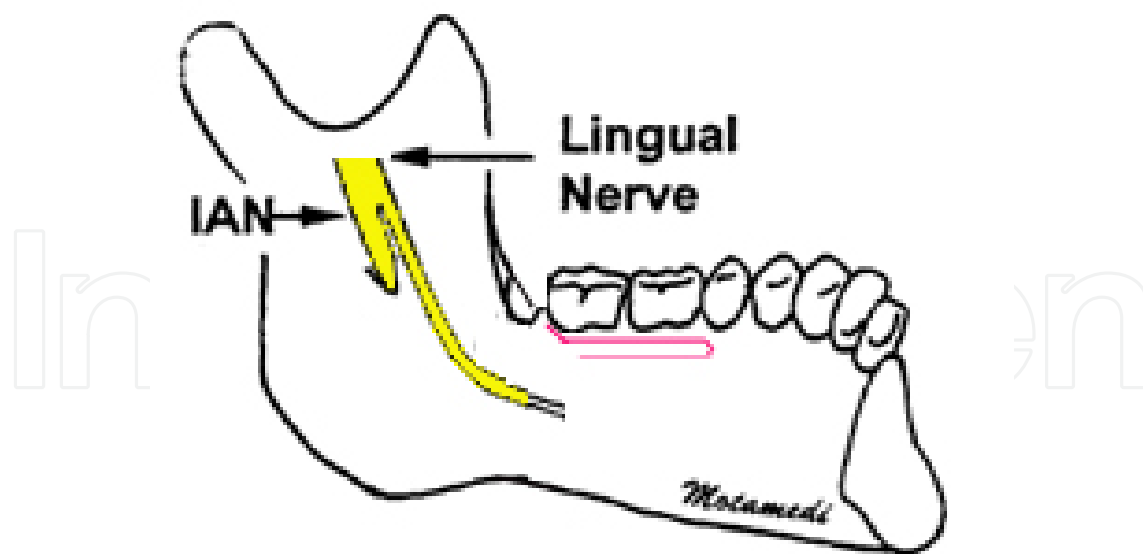


Figure 10. Finger flap incision on lingual side within the attached gingiva. Impacted 3rd molar has been removed.

upright into occlusion with the upper second molar. During this waiting period, we may encounter extrusion or supraeruption of the upper second molar, which has no opposing tooth. This will then be difficult to manage. In addition, the tooth anatomy of the third molar may not conform to the opposing maxillary second molar. [25]

From the surgical standpoint, removal of the impacted mandibular third molar is easier, but exposure and apical repositioning of the gingiva of the second molar for orthodontic bracketing is problematic because of the external oblique ridge and shallow vestibule in the posterior part of the jaw. Disruption of the gingival attachments and flap reflection of the attached gingiva to remove the third molar will cause an immediate loss in vestibular depth due to the upward pull of the buccinator muscle insertions on the flap. This prevents cervical reattachment of the gingiva to the second molar, preventing exposure of the second molar and precluding orthodontic bracket bonding. Current techniques to apically reposition the gingiva in the distobuccal region of the mandible are fraught with difficulty. The anatomy of the posterior mandible—with the closeness of the external oblique ridge to the cervix of the second molar—and the shallow, sometimes nonexistent, buccal vestibule in this area make flap stabilization difficult. Motamedi suggested a technique to anchoring the mucoperiosteal flap to the cortical bone in a manner that is effective in exposing the crown of the second mandibular molar and to prepare it for bracket bonding.[25]

Technique. After extraction of the impacted third molar, the buccal and crestal bone covering the second mandibular molar is removed. Then, a hole is drilled through the buccal cortex of the extracted third molar just distal to the impacted second molar. Next, a 3-0 silk or polyglactin suture is passed through the superior part of the flap and then through the buccal cortex and tied securely to anchor down the flap apically below the crown of the second molar. The crown of the second molar should now be exposed sufficiently for bracket bonding; orthodontic treatment is usually started 7 to 10 days postoperatively (**Fig. 11**).[25]

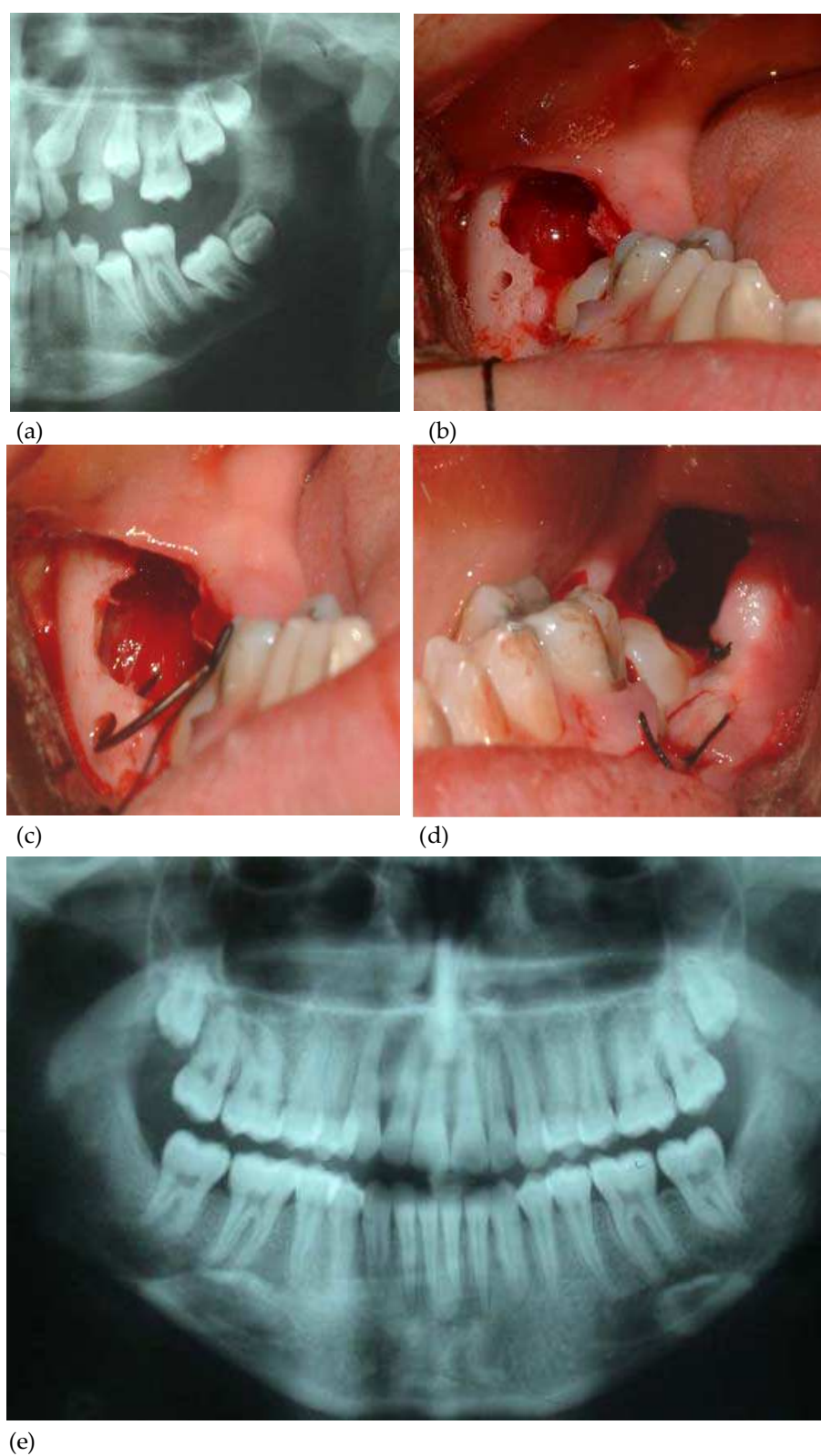


Figure 11. A. Radiograph of a double impaction in the mandible in a 13 year-old boy. B. The 32rd molar has been removed. A hole is drilled in the buccal cortex. C. 3-0 silk suture is passed through the superior part of the flap and then through the buccal cortex. D. the flap is tied down. E. Radiograph 2.5 years post-treatment.

3. Conclusion

Surgery for removal of impacted third molar surgeries may be associated with several postoperative complications; these complications are best prevented. However, the surgeon should be prepared to manage them should they occur. All third molars need not be removed independent of disease findings and patients need not unnecessarily have to accept adverse consequences associated with the surgery risks and discomforts in the absence of pain, radiographic findings of pathology, and or marked clinical evidence of disease. However, when surgery is indicated several new concepts and techniques presented in this chapter can prevent and or manage some of the common postoperative sequel of impacted third molar surgery.[1,2] The techniques presented herein are not for the novice.

Author details

Mohammad Hosein Kalantar Motamedi^{1*} and Farshid Kavandi¹

*Address all correspondence to: motamedical@lycos.com; farshid_kavandi@yahoo.com

1 Trauma Research Center, Baqiyatallah Medical Sciences University, Tehran, Iran

Oral and Maxillofacial Surgeon, Bouali Hospital, Tehran, Iran

References

- [1] Motamedi MH. Concepts to consider during surgery to remove impacted third molars. *Dent Today*. 2007 Oct;26(10):136, 138-41; quiz 141, 129.
- [2] Motamedi MH. Preventing periodontal pocket formation after removal of an impacted mandibular third molar. *J Am Dent Assoc*. 1999 Oct;130(10):1482-4.
- [3] Ventä I. How often do asymptomatic, disease-free third molars need to be removed? *J Oral Maxillofac Surg*. 2012 Sep;70(9 Suppl 1):S41-7.
- [4] Carvalho RW, do Egito Vasconcelos BC. Assessment of factors associated with surgical difficulty during removal of impacted lower third molars. *J Oral Maxillofac Surg*. 2011 Nov;69(11):2714-21. Epub 2011 Jul 12.
- [5] Freudlsperger C, Deiss T, Bodem J, Engel M, Hoffmann J. Influence of lower third molar anatomic position on postoperative inflammatory complications. *J Oral Maxillofac Surg*. 2012 Jun;70(6):1280-5. Epub 2012 Feb 4.

- [6] Lim AA, Wong CW, Allen JC Jr. Maxillary third molar: patterns of impaction and their relation to oroantral perforation. *J Oral Maxillofac Surg.* 2012 May;70(5):1035-9. Epub 2012 Apr 10.
- [7] Motamedi MH. Removal of a complex odontoma associated with an impacted third molar. *Dent Today.* 2008 Apr;27(4):76, 78-9; quiz 79, 68.
- [8] Motamedi MH. Impacted lower third molar and the inferior alveolar nerve. *Oral Surg Oral Med Oral Pathol Oral Radiol Endod.* 1999 Jan;87(1):3-4.
- [9] Pogrel MA. What are the risks of operative intervention? *J Oral Maxillofac Surg.* 2012 Sep;70(9 Suppl 1):S33-6. Epub 2012 Jun 16.
- [10] Aznar-Arasa L, Harutunian K, Figueiredo R, Valmaseda-Castellón E, Gay-Escoda C. Effect of preoperative ibuprofen on pain and swelling after lower third molar removal: a randomized controlled trial. *Int J Oral Maxillofac Surg.* 2012 Aug;41(8):1005-9. Epub 2012 Apr 20.
- [11] Suomalainen A, Apajalahti S, Vehmas T, Ventä I. Availability of CBCT and iatrogenic alveolar nerve injuries. *Acta Odontol Scand.* 2012 Feb 9. Pages1129-1130
- [12] Guerrero ME, Nackaerts O, Beinsberger J, Horner K, Schoenaers J, Jacobs R; SEDENTEXCT Project Consortium. Inferior alveolar nerve sensory disturbance after impacted mandibular third molar evaluation using cone beam computed tomography and panoramic radiography: a pilot study. *J Oral Maxillofac Surg.* 2012 Oct;70(10):2264-70. doi: 10.1016/j.joms.2012.04.015. Epub 2012 Jun 16.
- [13] Sanmartí-García G, Valmaseda-Castellón E, Gay-Escoda C. Does computed tomography prevent inferior alveolar nerve injuries caused by lower third molar removal? *J Oral Maxillofac Surg.* 2012 Jan;70(1):5-11. Epub 2011 Jul 27.
- [14] Pogrel MA. What is the effect of timing of removal on the incidence and severity of complications? *J Oral Maxillofac Surg.* 2012 Sep;70(9 Suppl 1):S37-40. Epub 2012 Jun 16.
- [15] Eyrich G, Seifert B, Matthews F, Matthiessen U, Heusser CK, Kruse AL, Obwegeser JA, Lübbers HT. 3-Dimensional imaging for lower third molars: is there an implication for surgical removal? *J Oral Maxillofac Surg.* 2011 Jul;69(7):1867-72. Epub 2011 Mar 21.
- [16] Kim JW, Cha IH, Kim SJ, Kim MR. Which Risk Factors Are Associated With Neurosensory Deficits of Inferior Alveolar Nerve After Mandibular Third Molar Extraction? *J Oral Maxillofac Surg.* 2012 Aug 15. [Epub ahead of print]
- [17] Doucet JC, Morrison AD, Davis BR, Robertson CG, Goodday R, Precious DS. Concomitant removal of mandibular third molars during sagittal split osteotomy minimizes neurosensory dysfunction. *J Oral Maxillofac Surg.* 2012 Sep;70(9):2153-63. Epub 2011 Nov 12.

- [18] Leung YY, Cheung LK. Coronectomy of the lower third molar is safe within the first 3 years. *J Oral Maxillofac Surg.* 2012 Jul;70(7):1515-22. Epub 2012 Apr 10.
- [19] Goto S, Kurita K, Kuroiwa Y, Hatano Y, Kohara K, Izumi M, Arijji E. Clinical and dental computed tomographic evaluation 1 year after coronectomy. *J Oral Maxillofac Surg.* 2012 May;70(5):1023-9. Epub 2011 Dec 30.
- [20] Baqain ZH, Al-Shafii A, Hamdan AA, Sawair FA. Flap design and mandibular third molar surgery: a split mouth randomized clinical study. *Int J Oral Maxillofac Surg.* 2012 Aug;41(8):1020-4. Epub 2012 Mar 15.
- [21] Haraji A, Motamedi MH, Rezvani F. Can flap design influence the incidence of alveolar osteitis following removal of impacted mandibular third molars? *Gen Dent.* 2010 Sep-Oct;58(5):e187-9. PubMed PMID: 20829150.
- [22] Hassan KS, Marei HF, Alagil AS. Does grafting of third molar extraction sockets enhance periodontal measures in 30- to 35-year old patients? *J Oral Maxillofac Surg.* 2012 Apr;70(4):757-64. Epub 2011 Dec 16.
- [23] Motamedi MH. Can an impacted mandibular third molar be removed in a way that prevents subsequent formation of a periodontal pocket behind the second molar? *J Can Dent Assoc.* 2006 Jul-Aug;72(6):532-3.
- [24] Motamedi MH. A technique to manage gingival complications of third molar surgery. *Oral Surg Oral Med Oral Pathol Oral Radiol Endod.* 2000 Aug;90(2):140-3.
- [25] Motamedi MH, Shafeie HA. Technique to manage simultaneously impacted mandibular second and third molars in adolescent patients. *Oral Surg Oral Med Oral Pathol Oral Radiol Endod.* 2007 Apr;103(4):464-6. Epub 2006 Oct 16.