

We are IntechOpen, the world's leading publisher of Open Access books Built by scientists, for scientists

6,900

Open access books available

185,000

International authors and editors

200M

Downloads

Our authors are among the

154

Countries delivered to

TOP 1%

most cited scientists

12.2%

Contributors from top 500 universities



WEB OF SCIENCE™

Selection of our books indexed in the Book Citation Index
in Web of Science™ Core Collection (BKCI)

Interested in publishing with us?
Contact book.department@intechopen.com

Numbers displayed above are based on latest data collected.
For more information visit www.intechopen.com



Microsurgical Reconstruction of Maxillary Defects

Shahram Nazerani

Additional information is available at the end of the chapter

<http://dx.doi.org/10.5772/52720>

1. Introduction

The maxilla is the functional and esthetic keystone of the midface, forming part of each of the key midfacial elements; these are the orbits, the zygomatico-maxillary complex, the nasal unit, and the stomatognathic complex. Maxillary reconstruction is a challenging endeavor in functional and esthetic restoration. Given its central location in the midface and its contributions to the midface, maxillary defects are inherently complex because they generally involve more than one midfacial component. Maxillary defects are composite in nature, and they often require skin coverage, bony support, and mucosal lining for reconstruction. Reconstruction of maxillary defects secondary to warfare, trauma, ablative tumor surgery, or congenital deformities must meet the following goals namely: (1) obliteration of the defect; (2) restoration of essential functions such as mastication and speech, (3) provision for adequate structural support to each of the midfacial units and (4) esthetic restoration of facial features. This chapter will discuss the anatomic considerations, the historical approaches to maxillary reconstruction as well as state-of-the-art techniques in use today.

2. Anatomy

Understanding the complex three-dimensional anatomy of the maxilla and its relationship to contiguous structures is critical to approaching reconstruction of the midface. Conceptually, the maxilla can be described as a geometric structure with six walls (a hexahedron, Figure 1).

The roof of the box is the floor of the orbit; the floor forms the anterior hard palate and alveolar ridge; the lateral walls form the lateral walls of the maxillary sinuses and are a part of the lacrimal system. The maxillary sinus, the largest of the paranasal sinuses, is contained within the central portion of the maxilla. Anteriorly it comprises the midface supporting the nose and anterior teeth. Overlying the posterior pterygoid region of the maxilla is the cranial base.

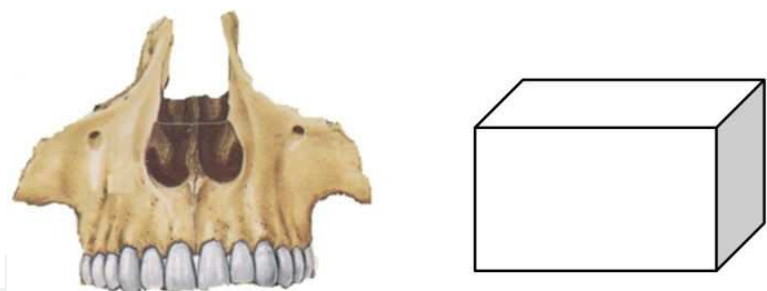


Figure 1. The maxilla and the schematic metaphor of a hexahedron.

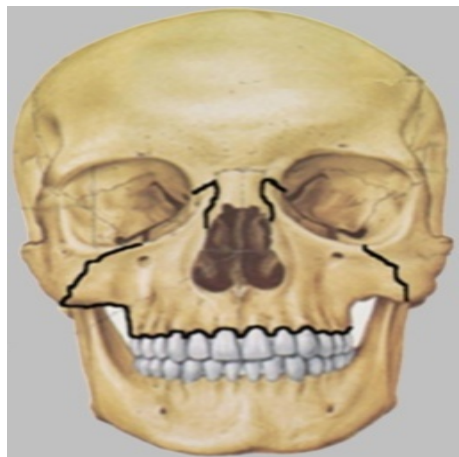

Figure 2. The maxilla with its surrounding bony structures.

The maxilla provides structural support between the skull base and the occlusal plane, supports the globe, separates the oral and nasal cavities and resists the forces of mastication. [1]

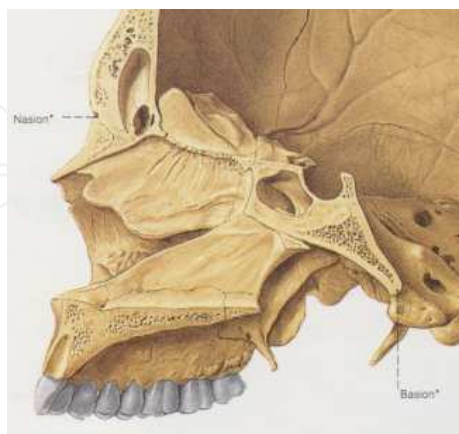


Figure 3. The maxilla with its projections create the bony foundation of the midface.

Finally, the overlying soft tissues, including the mimetic musculature of the midface, are supported by the maxilla and influence to a large extent one's unique facial appearance.

3. Historical procedures for maxillary reconstruction

Traditionally, reconstruction of large maxillary defects was accomplished by obturation of the defect with a prosthetic appliance. [2,3] Before the development of more sophisticated reconstructive techniques, prosthetic appliances were the only modality available to address the functional and esthetic requirements of such a complex defect. Both functional and esthetic results were far from optimal (Figure 4).

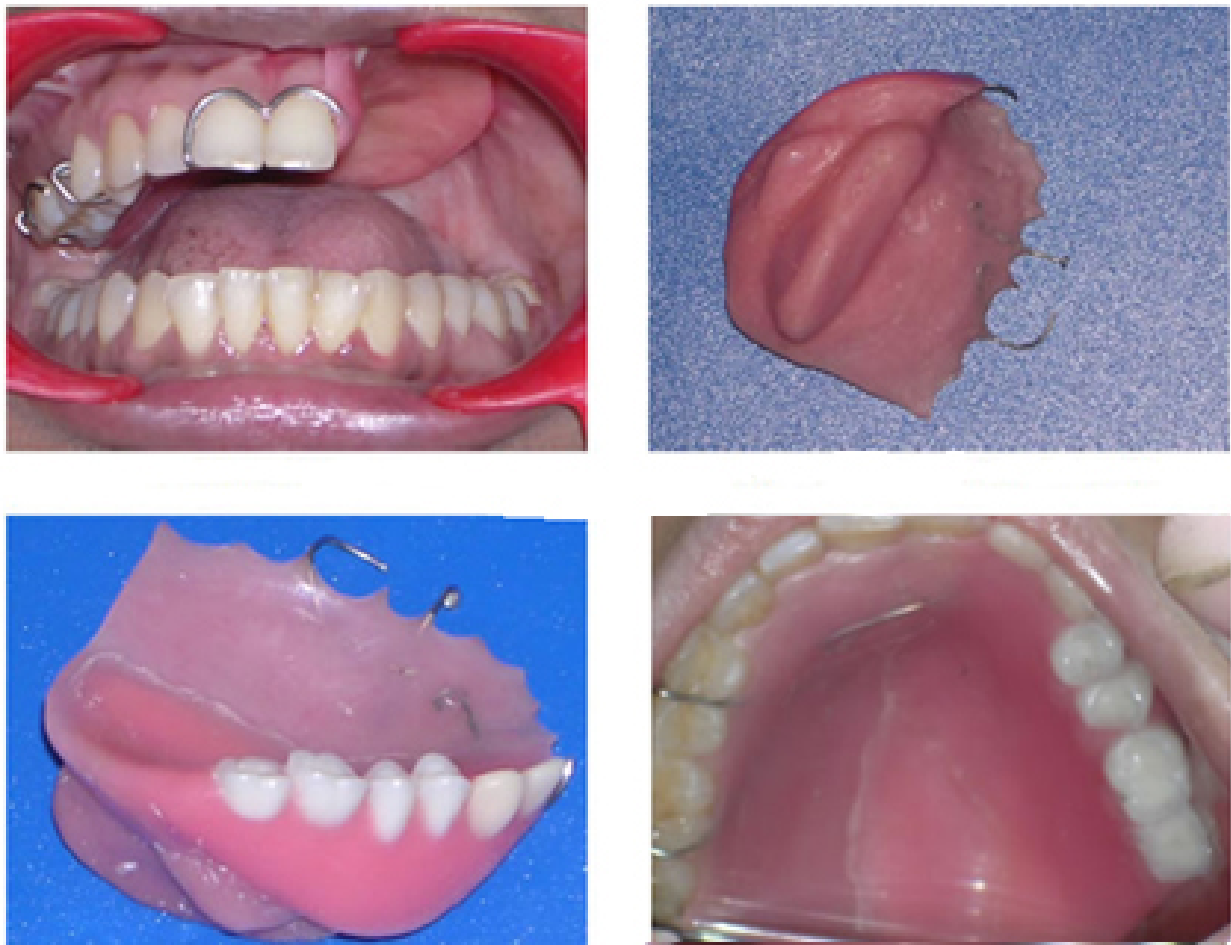

Figure 4. A hemi-maxillary obturator prosthesis.

Edgerton and Zovickian [4] reviewed early attempts at autogenous reconstruction of the maxilla and reported a palatal reconstruction technique using cervical flaps. These early reconstructive endeavors progressed from local flaps, such as forehead, upper lip, cheek, pharyngeal, turbinate, and tongue flaps, to tube flaps from the upper extremity, thorax, and abdomen. [5,6] Numerous other local flaps have been described for maxillary and palatal reconstruction. Generally, these have been useful for small defects or to augment other tissue-transfer techniques used to reconstruct larger defects. [7-17]

One of the earliest descriptions of a staged maxillary reconstruction with both soft tissue and bone was by Campbell in 1948. [18] He combined a temporalis muscle flap with a rotational palatal mucosal flap for soft-tissue reconstruction. An iliac bone graft was then placed in a second procedure; this was followed by the placement of a vestibular skin graft. The resulting reconstructed maxilla was capable of supporting a conventional maxillary denture. During the 1960s and 1970s, pedicled myocutaneous flaps were developed and replaced the more cumbersome tube flaps previously used in reconstructive surgery. However, these flaps tended to be quite bulky and were limited in their capacity to replicate the complexities of the resected maxillary structures. During the 1980s, a revolution in reconstructive surgery was brought about by the introduction of free tissue transfer techniques. These techniques have been widely applied in maxillary reconstruction, [18-25] and they have made possible the use of less bulky fascial or fasciocutaneous and osseous flaps. [26-36] Alongside the development of these tissue transfer techniques was the development of osseointegration pioneered by Branemark. [37-39] This technology, in combination with free tissue transfer, has made autogenous reconstruction of the maxilla and dentofacial rehabilitation possible. [40-45]

4. Classifying midfacial defects

Because of the disparate shapes and sizes of defects affecting the maxilla, the complex three-dimensional anatomy and the contiguous relationship of the maxilla to the surrounding structures, the broad category of maxillectomy constitute a wide spectrum of diverse defects. [46] Thus, a classification system to group this wide array of possible composite tissue defects was needed to facilitate clinical decision-making by outlining preferred reconstructive options and their common functional and esthetic sequelae. Attesting to both the variety and complexity of midfacial defects, numerous different classification schemes have been proposed. Based on a combined experience with 45 maxillectomies, Brown *et al.* developed a classification scheme allowing a very detailed description of 10 possible defects involving the palate; defects of the midface not involving the palate were excluded from the classification. [47] Unfortunately, the status of the orbital floor and zygoma, which play an important role in both the function and cosmesis of the midface, were not specifically addressed and specific recommendations for the reconstruction of each type was not given.

Wells and Luce proposed a classification system based on the extent of maxillary resections. [48] The schema allows the distinct classification of defects; however, proposed treatment focuses on the use of prosthetic obturators and/or the use of regional flaps rather than the specific use of microsurgical tissue transfer. In contrast, Yamamoto advocated the use of complex microsurgical procedures, specifically, the combined latissimus dorsi myocutaneous free flap with scapular bone based on the angular branch of the thoracodorsal artery and the rectus abdominis myocutaneous flap combined with costal cartilage based on the vascular connection between the eighth intercostal and deep epigastric vascular system. [49-50] Based on their 10-year experience with 38 maxillary reconstructions, they designed a complex reconstructive algorithm that ultimately culminates in nine different clinical scenarios based predominantly on the aforementioned vascularized, composite-tissue flaps. Futran and

Mendez presented an algorithm designed to depict options for midface reconstruction. Based on a thorough review of the literature, they classified defects as those involving the palate, the inferior maxilla, or the total maxilla with or without orbital exenteration. [46] Their algorithm was designed to delineate types of tissue required to reconstruct a particular defect, such as soft-tissue flaps or vascularized bone flaps rather than specific flap options. Spiro *et al.* proposed a relatively straightforward classification system that divides defects into three subtypes but does not specifically address the involvement of adjacent structures such as the orbit and zygoma. [51] based on a review of 108 patients, Davison *et al.* similarly divided patients into the two broad categories of “competent” or “partial” maxillectomy defects. [52] Although their group proposed a wide range of reconstructive techniques, the lack of a specific defect-oriented classification system outlining the remaining portion of the hard palate, dentition, orbit, and zygoma makes such an algorithm difficult to apply as a reconstructive guide. [53]

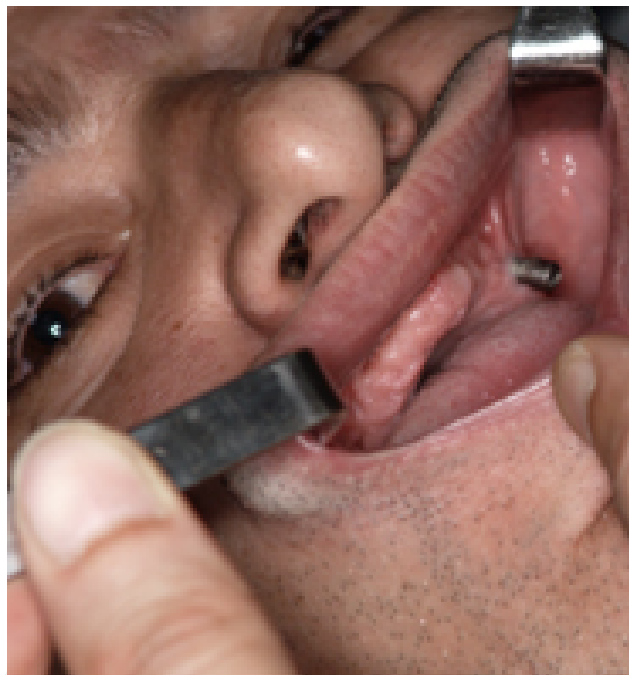

Figure 5. Maxillary atrophy after midface radiation for a small maxillary tumor 10 years back.

The same could be said for the classification proposed by Foster *et al.* [54] based on a single-surgeon series of 26 midfacial reconstructions; they classified defects into those involving soft-tissues and those involving bone. Bony midfacial defects were then subclassified into those involving more or less than half the palate. Triana *et al.* assessed 51 midfacial defects that had been treated with microvascular free-tissue transfer procedures. [55] The defects were classified as those seen after inferior partial maxillectomy, subtyped into the extent of palate lost and subdivided depending on the amount of malar bone and zygomatic arch lost. Okay *et al.* performed a retrospective review of 27 consecutive palatomaxillary reconstructions and designed a defect-oriented classification system designed to delineate the indica-

tion for prosthetic reconstruction, soft-tissue reconstruction, or vascularized bone-containing free flaps. [53] The authors concluded that the classification system does not address all factors required for decision-making. Although most of these classification systems allow for accurate descriptions of anatomical defects, many do not provide a clear algorithm for flap selection based on defect category. Others do not provide a comprehensive system for classifying defects of the midface that includes important structures such as the orbit or zygoma. One of the newer classifications has been proposed by McCarthy *et al.*⁵⁶ They classify the maxillary defect of oncologic surgery origin into five distinct types; it is a rather straightforward classification but there are some deficiencies in this classification i.e. maxillary atrophy after radiation therapy (Figure 5,6).

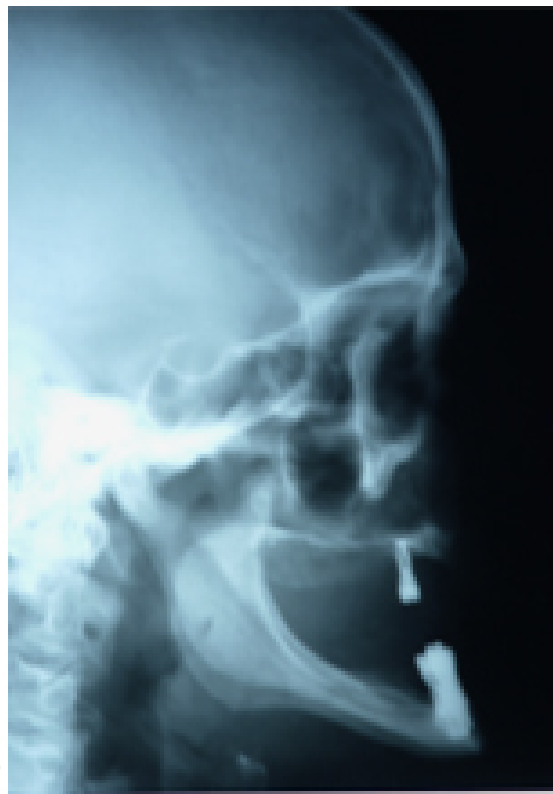

Figure 6. Lateral skull x-ray showing the extent of atrophy of the mandible and maxilla.

An all inclusive classification is yet to be found; but as a rule of thumb maxillary reconstruction can be divided into three groups :

- a. *Upper maxilla* which needs space filling or bulky flaps
- b. *Lowermaxillaoralveolarridge* for which the prefabricated bone flaps are the best solution C: *Combined or total maxillary defects* in this group a single flap addressing both the problems is yet to be found.

The McCarthy classification is as follows:

4.1. Type I: Limited maxillectomy

Type I defects include resection of one or two walls of the maxilla, excluding the palate. In most cases, the anterior wall is partially removed with either the medial wall and/or, occasionally, the orbital rim. In addition, these resections commonly involve the overlying cheek and can extend onto the lips, nose, or eyelids. Thus, type I or limited maxillectomy defects usually require a significant amount of skin for resurfacing with minimal associated bone volume (Figure 7).

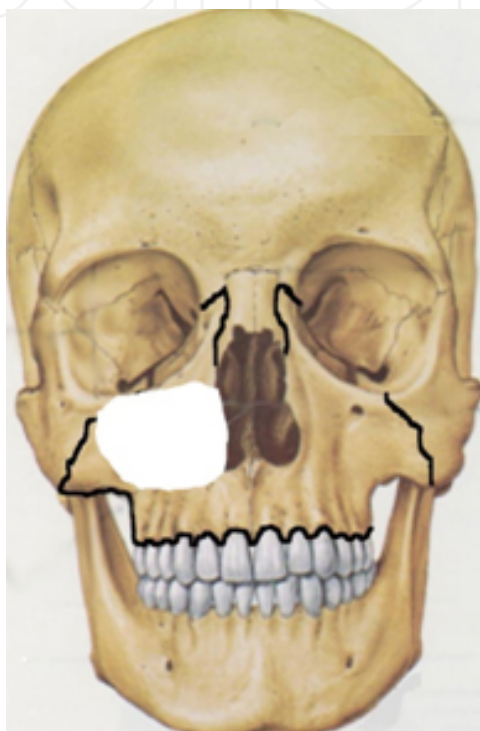

Figure 7. Type I defect of the right hemi-maxilla with the alveolar ridge intact.

4.1.1. Treatment

The radial forearm fasciocutaneous flap provides good external skin coverage and minimal bulk in this setting. Multiple skin islands can be designed and de-epithelialized when needed to wrap around bone grafts or supply nasal lining. If critical segments of bone are missing, such as the orbital rim or the anterior floor of the orbit, nonvascularized bone grafts can provide the needed support. Other flap options, depending on the amount of soft-tissue bulk required, include the lateral arm flap, anterolateral thigh flap, [57] and scapula flap. [58]

4.2. Type II: Subtotal maxillectomy

Type II defects include resection of the maxillary arch, hard palate, and anterior and lateral walls (five walls) with preservation of the orbital floor (Figure 8).

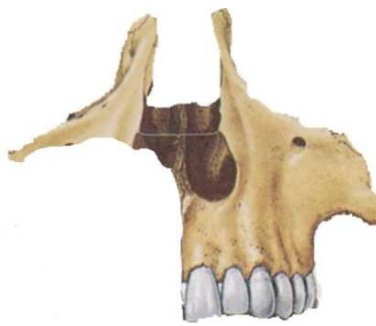


Figure 8. Type II defect, the alveolar ridge is removed but the floor of orbit is intact.

All type II defects involving more than 50 percent of the transverse palate require flaps that provide a substantial surface area with which to reline the nasal floor and palatal roof, and bone for structural support. [59-61] Similarly, in patients who do not have sufficient retentive surfaces and/or teeth to support a conventional prosthesis, vascularized bone-containing free flap reconstruction is indicated.

4.2.1. Treatment

The associated bulk provided by the skin and soft tissues is a significant disadvantage to using the fibula osteocutaneous flap, therefore we recommend the use of the prelaminate fibula free flap for the reconstruction of these defects (Figures 9-15).⁶²

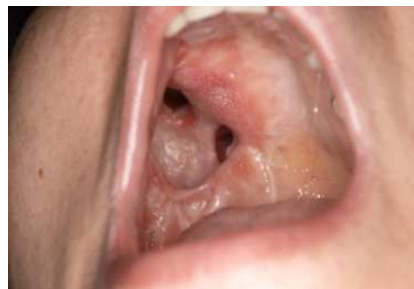

Figure 9. A defect created after a maxillary tumor with alveolar ridge loss (two years after surgery).

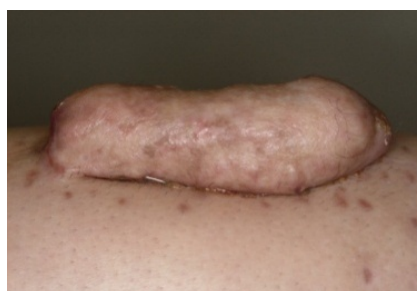

Figure 10. The prelaminate fibula created and matured on the leg.

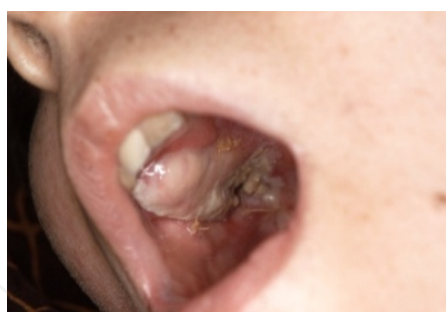


Figure 11. The flap has been transferred and the defect reconstructed.

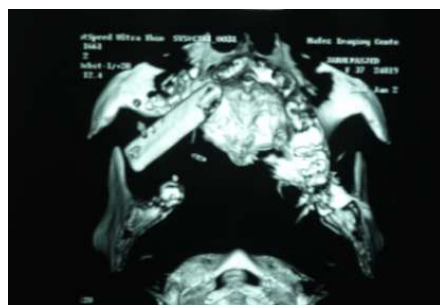


Figure 12. Axial CT scan showing the fibula in place.

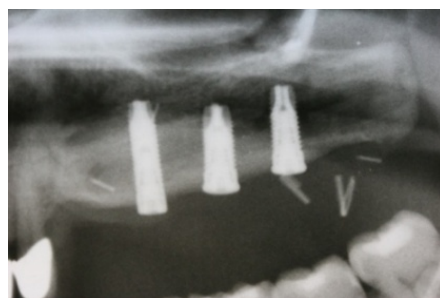

Figure 13. The x-ray after implant fixture insertion.

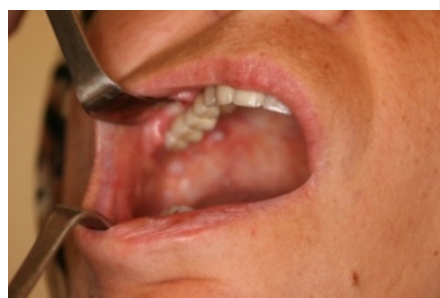

Figure 14. The fixed prosthesis in place.

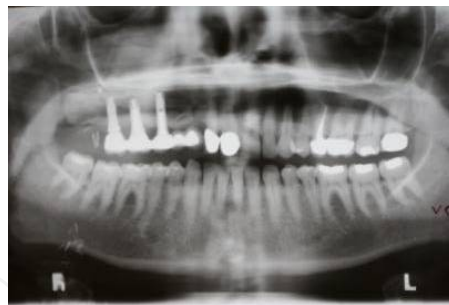

Figure 15. The panoramic view of the implant and the prelaminate fibula in place two years after surgery.

Various other donor sites have also been used to reconstruct these defects. Schliephake used a fasciocutaneous forearm flap followed by secondary bone grafting in two patients and reported that secondary nonvascularized bone grafting increases the risk of infection and is therefore not recommended. [63]

Use of the iliac crest free flap harvested with the internal oblique muscle has been reported by others. Iliac bone is plentiful and can provide a suitable bed for osseointegrated implants; however, its disadvantages include its short vascular pedicle and the potential for significant donor-site morbidity following its harvest. [58]

4.3. Type III: Total maxillectomy

Type III defects include resection of all six walls of the maxilla. These total maxillectomy defects are further subdivided into type III a defects, where the orbital contents are preserved; and type III b defects, where the orbital contents are exenterated.

4.3.1. Type IIIa

Reconstruction after total maxillectomy with preservation of the orbital contents is technically more challenging than maxillectomy with orbital exenteration. In this setting, reconstruction must: (1) provide support to the orbital contents, (2) obliterate any communication between the orbit and nasopharynx, and (3) reconstruct the palatal surface. When the orbital floor has been resected, support needs to be restored to the orbital contents; otherwise, the globe will prolapse downward, causing severe vertical dystopia with significant diplopia (Figure 16).

A variety of methods have been advocated to provide orbital support, including nonvascularized and vascularized bone grafts, alloplastic substitutes, and soft-tissue “slings.” [64-65] we strongly advocate the use of **nonvascularized bone grafts** to support the orbital contents. By contrast, the use of alloplastic substitutes in defects that potentially expose it to the oronasal cavity increase the opportunity for periprosthetic infection. The volume of a soft-tissue flap may change over time [66] secondary to muscle atrophy, scar contracture, or changes in nutritional status. In this setting, even minor changes in volume can translate into significant changes in the vertical position of the soft-tissue sling and consequently the volume of the orbital cavity.

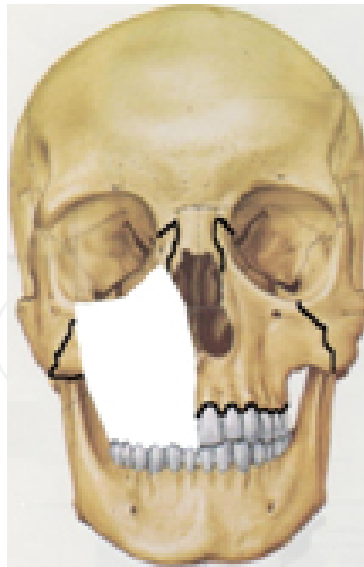

Figure 16. The defect created schematically shown; the floor of the orbit is intact.

By using the **rectus abdominis free flap** in combination with nonvascularized bone grafts, reconstruction of a three-dimensional defect is facilitated because the bone, skin, and soft-tissue components may be inset into their desired positions without compromising the microvascular aspect of the reconstruction. In addition, the rectus abdominis can be harvested easily during the resection and the pedicle can be extended up to 19 cm to reach the neck vessels.

Alternatively, the **temporalis flap** can be used to cover bone. Using this approach, however, requires the subsequent use of a palatal obturator; thus, the temporalis muscle flap is indicated primarily in older patients who are not candidates for free-tissue transfer. It is also useful for the patient who has an intact palate and preserved orbital contents (usually ethmoidal tumor resections), where access for free flap vessels is exceedingly difficult and muscle coverage is still needed to cover orbital bone grafts. [67] We however, support the use of vascularized bone flaps in this setting. The osteocutaneous free flap most frequently described for reconstruction of the maxillary region are the scapula, fibula, and radius. Each donor site has its own advantages and disadvantages.

The **osteocutaneous radial forearm flap** has been used for simultaneous reconstruction of the infraorbital margin and external skin in the midface. [68] Unfortunately, the volume of tissue transferred is rarely enough to obliterate the maxillary cavity completely, and palatal defects must be obturated with a prosthesis. [69]

Others have advocated the use of the **subscapular flap** to reconstruct defects caused by total maxillectomy with orbital preservation. Replacement of the alveolar arch inferiorly with the lateral scapular bone and the orbital floor and rim with the scapular tip has been described. [70] Schliephake reported difficulty however, in tailoring the scapular bone over the malar prominence, infraorbital rim, and maxillary wall at the same time that the lateral border of the scapula was to be positioned for placement of implants at the alveolar crest. [63] Yamamoto

et al. have similarly reported using the scapular bone in conjunction with costal cartilage for reconstruction of all the maxillary buttresses in extended midfacial defects. [49]

Several authors have described the use of **free fibula osteocutaneous flaps** to reconstruct combined maxillary and mandible defects. [71] we think that the prefabricated fibula can address the alveolar ridge and the palate but cannot reconstruct both the mandible and maxilla in one setting and also the prefabricated fibula cannot act as a space filling flap for upper maxillary defects (Figure 17,18).

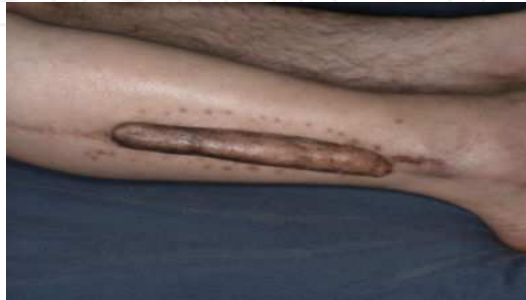

Figure 17. The matured fibula ready for transfer.

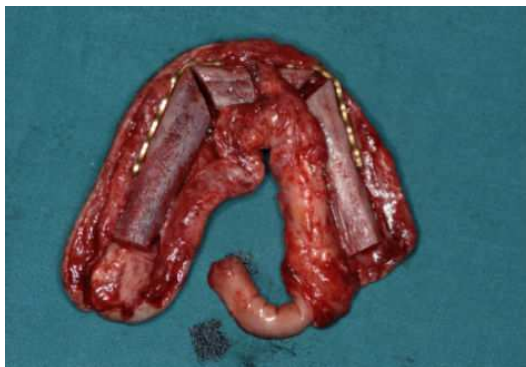


Figure 18. The "on table" preparation of the fibula has been done, the complete maxillary arch is created, the amount of soft tissue can only cover the palatal defect

However, Futran *et al.* found that as the need for reconstruction of the zygomatic complex, infraorbital rim, and the floor increased, the fibula flap was limited in its ability to restore the entire maxillary form. [67] In addition, it was difficult to osteotomize and orient the bone to restore both the palate and the infraorbital area. Even with the harvest of additional soleus muscle bulk, it was difficult to rotate the skin paddle to resurface the palate and provide zygomatic and infraorbital contour. Based on this experience, their group concluded that when orbitozygomatic support is the primary objective, use of the fibular free flap is not advocated.

Brown presented three cases of reconstruction with the **iliac crest myo-osseous flap** with favorable functional results. [47] A "block" of iliac bone was used to restore alveolus, zygomatic prominence, and orbital rim with success. Genden *et al.* Described use of the iliac crest–

internal oblique osteomusculocutaneous free flap in six patients, four of whom had type IIIa defects. [72] The iliac crest was fashioned to recreate the inferior orbital rim; the internal oblique muscle was used to reline the palate and resurface the ipsilateral lateral nasal wall. Based on their report, all four patients achieved facial symmetry and underwent placement of osseointegrated implants. Others have discouraged the use of this flap however, because of its potentially excessive bulk, limited soft-tissue mobility in relationship to the bone and short pedicle length. [70-73]

4.3.2. Type IIIb

Patients with type IIIb defects undergo resection of the entire maxilla in addition to exenteration of the orbit (also known as the extended maxillectomy). These defects are extensive and have both large-volume and large-surface area requirements. The palate needs to be closed; the medial wall of the maxilla often needs to be restored to maintain an adequate airway; and the often extensive external defect, which can involve the eyelids, cheek, and occasionally the lip, need to be reconstructed. In addition, the anterior cranial base in the area of the sphenoid is often exposed and coverage of the brain becomes essential (Figure 19).

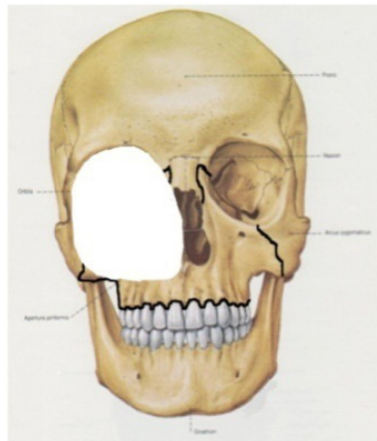


Figure 19. Type IIIb defect; the lower portion of maxilla is intact.

If the external skin of the cheek is intact, a rectus abdominis free flap with a skin island used to close the palate is a simple, straightforward solution. If the flap is not too bulky, a second skin island to restore the lateral nasal wall can be used. A third skin island can be used to provide closure of the external skin deficit if necessary.4 [73-75]

Shestak *et al.* successfully used the **latissimus dorsi flap** in three patients with type IIIb defects to fill the orbital cavity, seal the palate, and recontour the soft tissue of the face and cheek. [75] The latissimus dorsi was used because of its bulk, reliable anatomy, and ample pedicle length.

Palatal closure has its advantages and disadvantages in these reconstructions. If the palate is not closed (and muscle alone is used to cover the brain), the resultant massive intraoral defect requires a very large obturator, which can be difficult to support if there are no teeth left in the remaining maxilla. Palatal closure, although not ideal, makes sense because these patients can

usually speak well and eat soft solids without dentures. Denture fitting can be difficult if the skin bulges downward and there are no teeth to fit the prosthesis. However, because these patients would have similar difficulties with an open palate and function well even without a denture when closed, we feel that the palatal closure is generally advisable.

We do not attempt to reconstruct bony deficits in these patients because of the extensive nature of the defects. Bone-containing free flaps do not have the same versatility with regard to providing intraoral and extraoral lining and soft-tissue bulk and are therefore not generally indicated for the massive type IIIb resections.

4.4. Type IV: Orbitomaxillectomy

Type IV or orbitomaxillectomy defects include five walls of the maxilla and the orbital contents, leaving the dura and brain exposed. The palate is usually left intact with these resections. Reconstructive objectives include the provision of adequate soft tissue and the resurfacing of external skin defects where necessary. Thus, a flap that provides a medium volume of soft tissue and has the potential to cover a medium/large surface area with one or more skin islands is required (Figure 20).

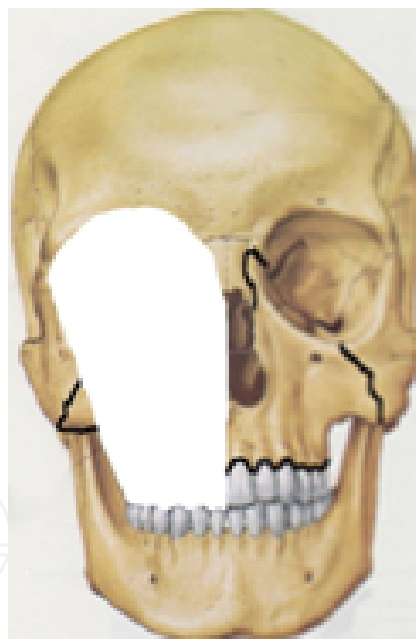


Figure 20. The complete defect with orbit involved.

The rectus abdominis flap can meet these requirements. These are conceptually simple reconstructive procedures, but the principal challenge is technical; one needs to anastomose the flap to a donor vessel in the neck, as temporal and facial vessels are usually resected or are unreliable. Dissection of the rectus pedicle extends the length up to 20 cm. A superficial tunnel in the face-lift plane allows transfer of the vessels; or, if the maxillary tubercle is resected, access can be gained by a parapharyngeal approach medial to the mandible. Maintaining the nasal

airway is often the most difficult problem in these patients; thus, a second skin island to address lateral nasal wall reconstruction is helpful. [76]

4.5. Reconstruction with vascularized autogenous tissue

Advances in tissue transfer techniques have made sophisticated reconstruction with autogenous tissues possible. In the past, it was thought that autogenous reconstruction after tumor surgery would interfere with examination for residual or recurrent disease. Advances in diagnostic techniques such as computerized tomography, magnetic resonance imaging, and endoscopy now enable the surgeon to evaluate the resection bed without direct inspection. [77-80] With the numerous free and pedicled flaps and the adjunctive modalities, such as enteral feeding tubes, tracheostomy, and osseointegrated dental prostheses now available to the reconstructive surgeon, many of the technical difficulties related to autogenous reconstruction can be circumvented, both in the perioperative period and over the long term.

The idea of “one wound one scar” has drastically altered our reconstructive approaches. Local flaps in extensive defects only make a defect a “larger” defect and a “larger scar” ensues and in extensive maxillary defects “new” tissue must be brought into the wound and enlarging the scar by local or adjacent flaps is not advisable. The free or prefabricated flaps are not the “last ditch measures” and they must be considered as the first line of treatment in these complex midfacial defects (Figure 21,22).

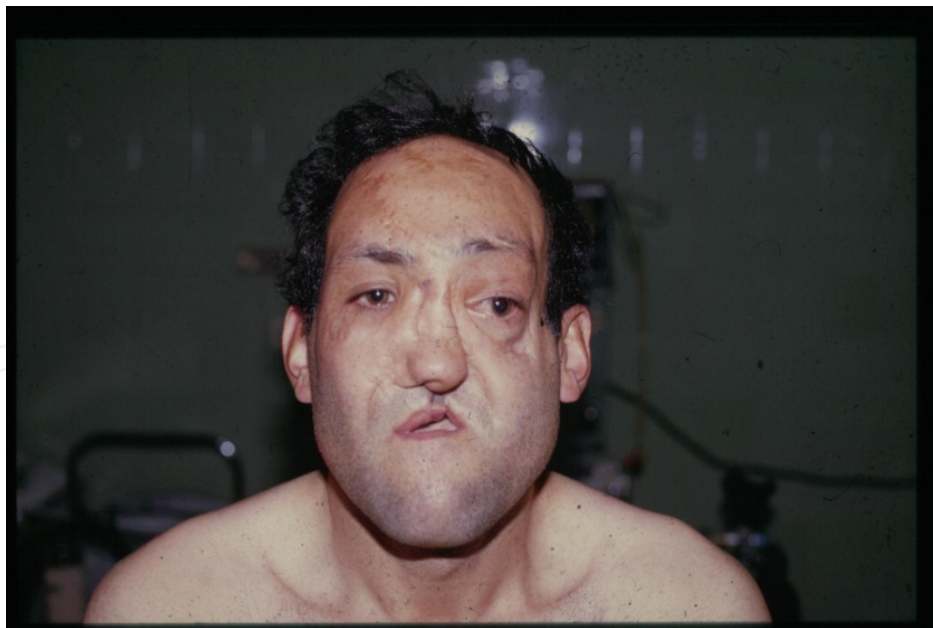

Figure 21. Frontal view, note the amount of forehead and upper lip scar.

Figure 21 shows a war-wounded veteran after 25 operations by world famous surgeons; the midface defect has been treated by local flaps, the maxillary defect remains and maxillary nonvascularized bone grafts, have all resorbed, the face and forehead are scarred.

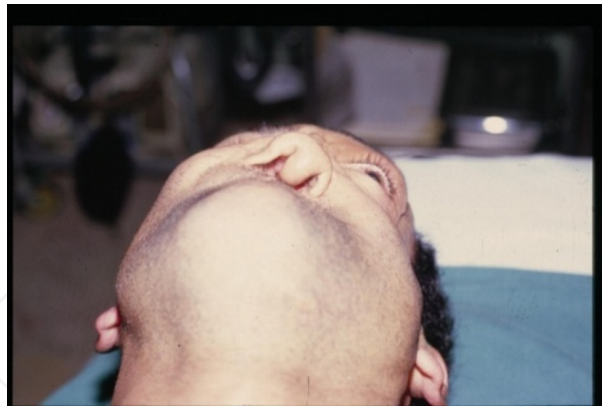

Figure 22. The maxillary defect from below.

5. State of the art procedures: Flap prefabrication and prelamination

Flap prefabrication is a term that was first introduced and later clinically applied by Shen in the early 1980s.⁸¹⁻⁸² Flap prefabrication and prelamination are two closely related concepts. Clinical applications of flap prefabrication and prelamination are relatively new to the field of reconstructive plastic surgery. Although the two terms are often used interchangeably in the literature, they are two distinctly different techniques. Understanding their differences is helpful in planning the reconstructive strategy. They are primarily used in reconstructing complex defects where conventional techniques are not indicated.

5.1. Flap prefabrication

Flap prefabrication starts with introduction of a vascular pedicle to a desired donor tissue that on its own does not possess an axial blood supply. After a period of neovascularization of at least 8 weeks, this donor tissue can then be transferred to the recipient defect based on the newly acquired axial vasculature (Figure 23).

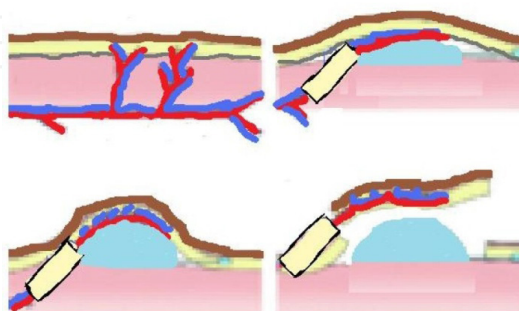


Figure 23. Flap prefabrication stages; vascular pedicle transferred under the skin paddle and the pedicle wrapped by either PTFE or silicone 62 and sometimes a tissue expander is inserted for expansion; the flap after proper expansion is transferred as a free or island flap.

Cartilage and bone can be incorporated into these flaps but they are mostly suitable for ear and nose reconstruction and for maxillary or mandibular reconstructions the prelamination method is the better choice. Flap prelamination, begins with building a three-dimensional structure on a reliable vascular bed. This composite structure, once matured in approximately 6-8 weeks can then be transferred to the recipient defect.

5.2. Flap prelamination

Flap prelamination is a term first coined by Pribaz and Fine in 1994. [83] The definition of “lamination” means bonding of thin sheets together to give a multilayered construction. In reconstructive surgery, the term “flap prelamination” has been used to describe a process of two or more stages for constructing a complex three-dimensional structure. The first stage involves adding different layers to an existing axial vascular territory as composite grafts, allowing time for the tissues to mature before being transferred (Figure 24-26).

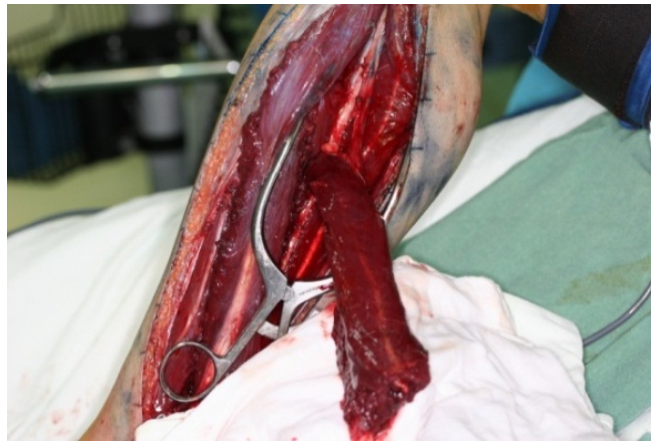

Figure 24. The fibula with the muscle cuff has been dissected and is attached to the leg via its vascular pedicle.

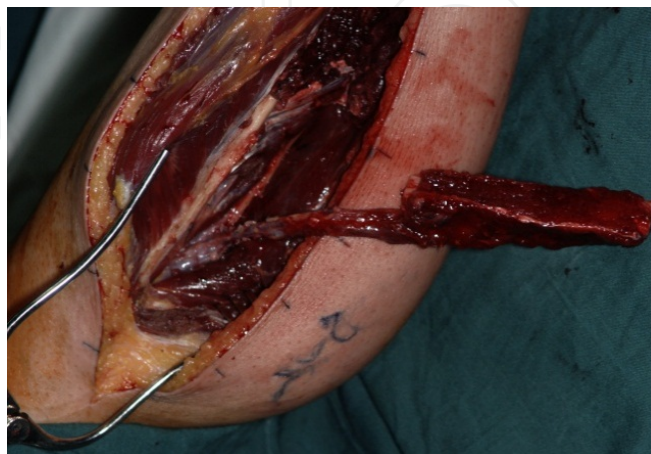

Figure 25. The pedicle has been prepared up to the trifurcation of the artery.

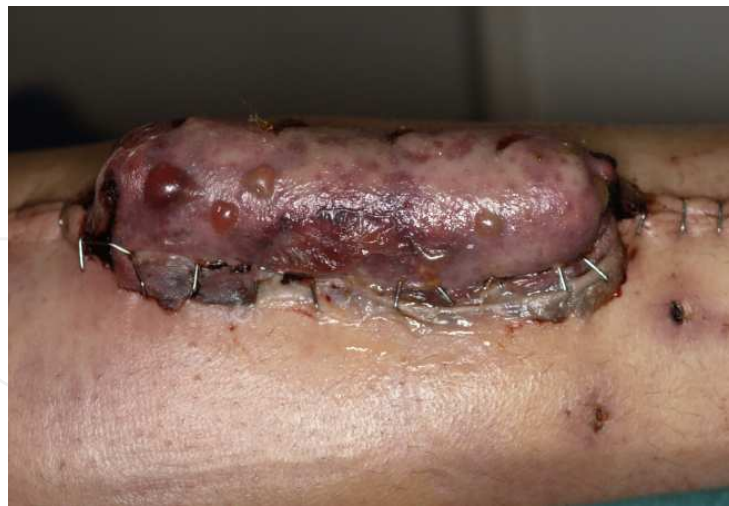

Figure 26. The pedicle is wrapped in silicone sheet and the bone flap is fixed to the leg surface and covered by a split-thickness skin graft, (postoperative day 10).

An intermediate stage may be needed to further modify the flap, such as thinning, delaying, or adding additional tissue. [84] At the next stage, when the remote composite flap is completed, it is transferred to the defect based on the original axial blood supply. As with any composite graft, these added layers have to be sufficiently thin or small for them to take. The rationale for prelaminating those layers at a different site before transfer results from the belief that this offers the best chance for the prelaminating layers to heal, stabilize, and assume their expected structures and positions if the construction is performed in a reliable vascular bed at a less conspicuous site instead of in situ, where local complicating factors can be numerous. This is particularly important for reconstruction of functional units that need to be transferred to complex local environments, where structural leaks may cause grave complications (e.g., neourethra in the perineum and neoesophagus in the mediastinum).

5.3. Flap maturation

Because the blood supply is not manipulated, the time for a prelaminated flap to mature is shorter than for a prefabricated flap, [85] usually between 4 and 6 weeks. Intuitively, this makes sense because it represents a similar amount of time for any composite graft to fully take, whereas in a prefabricated flap, neovascularization needs to take place over a much larger and sometimes thicker dimension of tissue. Intermediate manipulation may be required to obtain a thinner flap or to delay an extended portion of a flap or to add additional graft material (Figure 27).

5.4. Flap transfer

Because the layering of structures takes place in an established vascular territory, venous congestion is usually not a problem in a prelaminated flap as it is often in a prefabricated flap. However, all flaps, including prelaminated flaps, become edematous after transfer, and there is increased scarring at each tissue healing interface. In attempting to reconstruct complex

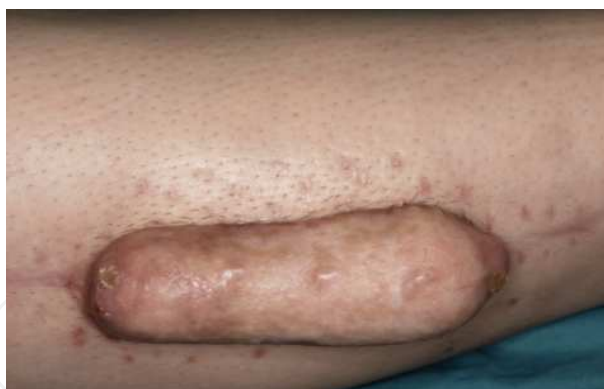

Figure 27. Postoperative week 8, the flap is completely matured and ready for transfer

three-dimensional structures, the multiple layers with scarring and contractile forces at each interface can result in distortion and loss of contour of the flap. Because of this, the initial result is often suboptimal, and generally several revisions are necessary. This occurs especially in the face, where prelamination is used for reconstruction of central facial features, such as the nose and surrounding tissues. Once the prelaminated flap is healed in place and a stable foundation has been obtained, the external part can be de-epithelialized and covered with local advancement flaps or, in the case of nostril reconstruction, with a forehead flap for final esthetic reconstruction (Figure 28,29).

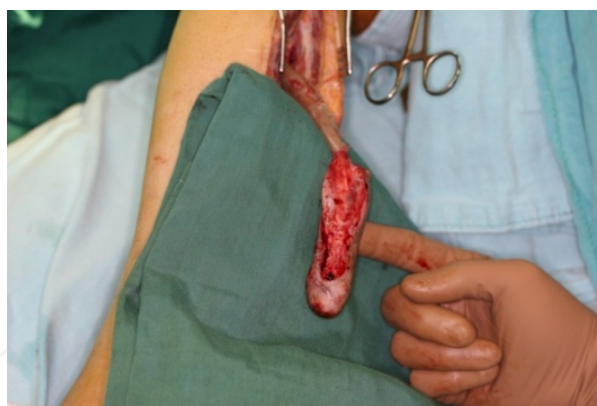

Figure 28. The flap has been dissected free from the leg and hangs on the pedicle which is wrapped in silicone, the dissection of the pedicle is facilitated by the silicone sheet

6. Osseointegration techniques

The development of osseointegrated implants has revolutionized the approach to the dental rehabilitation of patients requiring maxillary reconstruction. The work of Branemark [86] and others has resulted in the development of the materials and techniques necessary to provide predictable and reliable implants that can be completely incorporated into grafted bone and

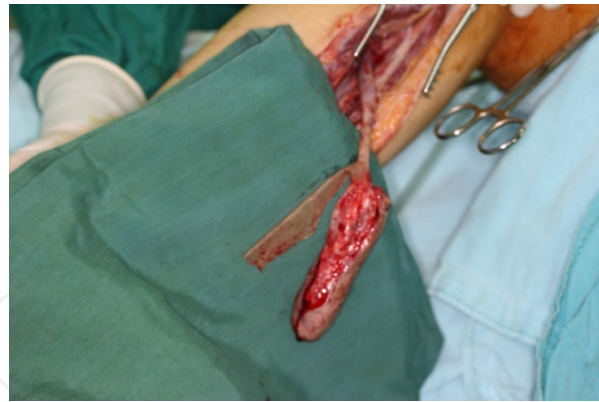

Figure 29. The silicone sheet is removed and the flap is ready for transfer.

support a fixed and stable dental prosthesis. [87-94] The use of osseointegrated implants in conjunction with free tissue transfer represents state-of-the-art reconstruction of large maxillary defects. The use of osseointegrated implants for dental rehabilitation has previously been much more extensively discussed in the context of mandibular reconstruction than that of maxillary reconstruction. [95] Some fundamental concepts of functional dental restoration with prosthetics should be understood. The reconstruction should provide for retention, support, and stabilization of the denture. Retention involves preventing the displacement of the prosthesis from the denture-bearing surface. Support implies that masticatory forces should not cause the prosthesis to impact vertically against the soft tissue of the load-bearing surface. Stabilization refers to the prevention of excessive lateral movement of the prosthesis. Dentures may be implant-borne, in which case the osseointegrated implants completely retain, support, and stabilize the prosthesis, or implant-retained, in which case the support and stabilization functions are shared by the denture-bearing surface and the retention of the prosthesis is completely dependent on the osseointegrated implants. Dentures that do not require osseointegrated implants are tissue-borne and tooth-supported, relying on the native tissues for retention and stabilization. [96]

Tissue-borne prostheses generally cannot be used in extensive maxillary defects because of insufficient residual palatal and alveolar tissues to provide support and retention. Funk *et al.* [96] defined such defects as those involving more than two-thirds of the maxillary arch. These defects typically require surgical reconstruction of the maxillary arch to provide neoalveolar bone of adequate thickness (approximately 10 mm) to accommodate osseointegrated implants, support a denture, and prevent its movement during mastication (Figure 30-34).

Bony reconstruction of the maxillary arch allows placement of the osseointegrated implants axial to the occlusal forces, a key factor for successful implant function. [96] Osseointegrated implants may be placed at the time of the reconstruction or secondarily, 6 to 8 weeks later. [96] Three to 8 months after placement, the osseointegrated implants are uncovered and prepared for final prosthetic reconstruction by a prosthodontist. [95]

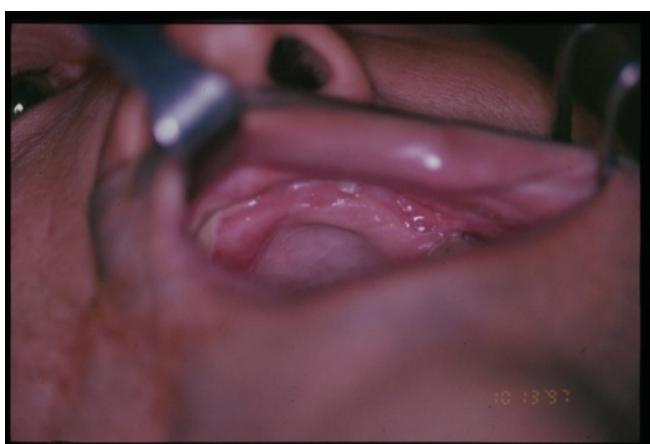


Figure 30. The maxillary defect after shrapnel injury.

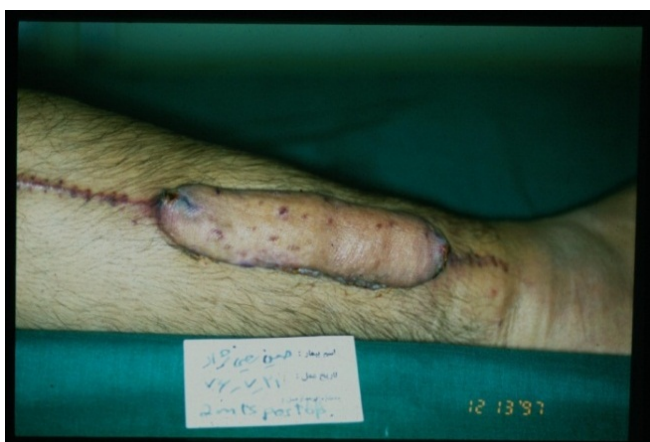

Figure 31. The matured fibula ready for transfer.

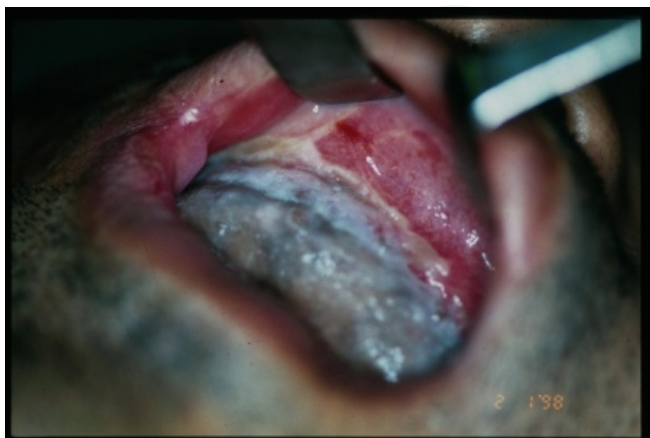

Figure 32. The fibula in place six months after surgery, please note the dark color of the grafted skin

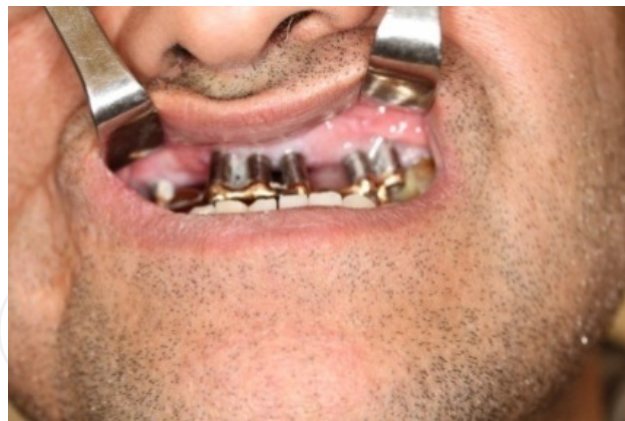

Figure 33. The patient ten years after surgery with implant in place, the skin graft has completely transformed into mucosa and is glistening and has the color of mucosa.

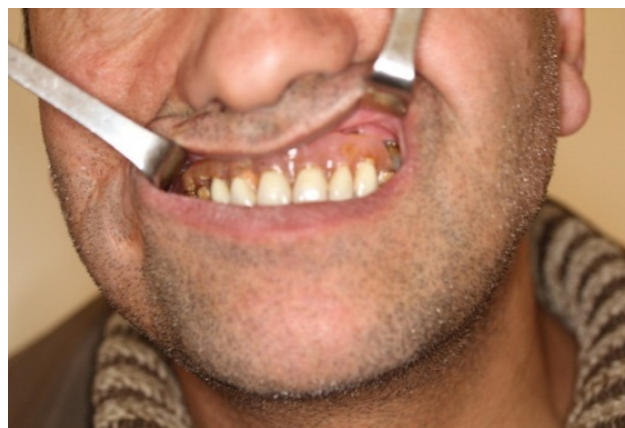

Figure 34. The dentures in place, ten year postoperatively.

The use of free tissue transfer techniques in combination with osseointegrated implants for maxillary reconstruction has been reported by various authors. [97] Holle *et al.* [98] described a two-stage procedure for the reconstruction of maxillectomy defects. Initially, an osseous flap was created from the lateral border of the scapula; it incorporated osseointegrated implants, was covered with skin grafts, and was protected with a PTFE membrane. Three months later, the flap was harvested and transferred to the face using a microsurgical technique. This procedure successfully restored facial contour and allowed full dental rehabilitation. Funk *et al.* [59] used free scapular osseocutaneous flaps with primary or secondary osseointegrated implants for large palatomaxillary defects in three patients. These patients all underwent successful dental rehabilitation, with 94 percent stability of the implants at an average of 18 months after the completion of rehabilitation. Nakayama *et al.* [99] reconstructed a bilateral maxillectomy defect with a free fibula osseocutaneous flap combined with osseointegrated implants. Igawa *et al.* [100] recently reported the use of a prefabricated iliac crest free flap, which was secondarily vascularized by a rectus abdominis muscle flap and covered by split-

thickness skin graft, with the secondary placement of osseointegrated implants for functional alveolar ridge reconstruction after hemimaxillectomy.

7. Summary

Maxillary defects are one of the most challenging problems facing the reconstructive surgeon. Microsurgical tissue transfers evolved from the groin flap transfer to the complicated flap prefabrication and prelamination approaches to difficult reconstructive needs. These sophisticated techniques are distinctively different and yet can be perfectly complementary. Prelamination can add virtually anything to where there is a good axial blood supply, and prefabrication can bring an axial blood supply to almost anywhere in the body. The two techniques can even be combined when certain complex reconstructive needs are present. Prefabrication and prelamination can also serve as a conduit through which products of tissue engineering and embryonic stem cell technologies can be applied to the reconstruction of head and neck defects. Tissues synthesized in vitro with better structural, color, texture, and functional match can be prelaminated to a site that has already been prefabricated. Prefabrication of a bioabsorbable matrix system can create a well perfused scaffold to which more and larger subunits can be prelaminated.

As our understanding of the techniques evolves, the breadth of their usage will also expand. These techniques will continue to be useful to help solve many difficult problems that baffle even the very best reconstructive surgeons, and the potential for these techniques may be used to bring tissue engineering from the laboratory to clinical reality. Lastly, as progress is made in transplant pharmacology, the immunologic barrier to feasible composite tissue allograft transplantation may be overcome. This represents the beginning of a new era in reconstructive surgery.

Author details

Shahram Nazerani^{1,2}

1 Associate Professor of Surgery, Firouzgar Hospital, Teheran, Iran

2 Tehran University of Medical Sciences, Tehran, Iran

References

- [1] Schendel, S. A., and Delaire, J. Facial Muscles: Form, Function, and Reconstruction in Dentofacial Deformities. In W. H. Bell (Ed.), *Surgical Correction of Dentofacial Deformities*, Vol. 3. Philadelphia: Saunders, 1985.

- [2] Hammond, J. Dental care of edentulous patients after resection of maxilla. *Br. Dent. J.* 120: 591, 1966.
- [3] Curtis, T. A., and Beumer, J. Restoration of Acquired Hard Palate Defects: Etiology, Disability, and Rehabilitation. In J. Beumer, T. A. Curtis, and M. T. Marunick (Eds.), *Maxillofacial Rehabilitation: Prosthodontic and Surgical Considerations*. St. Louis: Ishiyaku EuroAmerica, 1996.
- [4] Edgerton, M. T., Jr., and Zovickian, A. Reconstruction of major defects of the palate. *Plast. Reconstr. Surg.* 17: 105, 1956.
- [5] Converse, J. M. Early and late treatment of gunshot wounds of the jaw in French battle casualties in North Africa and Italy. *J. Oral Surg.* 3: 112, 1945.
- [6] Miller, T. A. The Tagliacozzi flap as a method of nasal and palatal reconstruction. *Plast. Reconstr. Surg.* 76: 870, 1985.
- [7] Miller, T. A. The Tagliacozzi flap as a method of nasal and palatal reconstruction. *Plast. Reconstr. Surg.* 76: 870, 1985.
- [8] Elliott, R. A., Jr. Use of nasolabial skin flap to cover intraoral defects. *Plast. Reconstr. Surg.* 58: 201, 1976.
- [9] Chambers, R. G., Jaques, D. A., and Mahoney, W. D. Tongue flaps for intraoral reconstruction. *Am. J. Surg.* 118: 783, 1969.
- [10] Jackson, I. T. *Local Flaps in Head and Neck Reconstruction*. St. Louis: Mosby, 1985.
- [11] Niederdellmann, H., Munker, G., and Lange, G. Reconstruction of a defect of the orbital floor with a rotated flap from the nasal wall: A case report. *J. Maxillofac. Surg.* 2: 153, 1974.
- [12] Crow, M. L., and Crow, F. J. Resurfacing large cheek defects with rotation flaps from the neck. *Plast. Reconstr. Surg.* 58: 196, 1976.
- [13] Edgerton, M. T., and DeVito, R. V. Closure of palatal defects by means of a hinged nasal septum flap. *Plast. Reconstr. Surg.* 31: 537, 1963.
- [14] Becker, D. W., Jr. A cervicopectoral rotation flap for cheek coverage. *Plast. Reconstr. Surg.* 61: 868, 1978.
- [15] Guerrerosantos, J., and Altamirano, J. T. The use of lingual flaps in repair of fistulas of the hard palate. *Plast. Reconstr. Surg.* 38: 123, 1966.
- [16] Wallace, A. F. Esser's skin flap for closing large palatal fistulae. *Br. J. Plast. Surg.* 19: 322, 1966.
- [17] Komisar, A., and Lawson, W. A compendium of intraoral flaps. *Head Neck Surg.* 8: 91, 1985.
- [18] Campbell, H. H. Reconstruction of the left maxilla. *Plast. Reconstr. Surg.* 3: 66, 1948.

- [19] Baker, S. R. Closure of large orbito-maxillary defects with free latissimus dorsi myo-cutaneous flaps. *Head Neck Surg.* 6: 828, 1984.
- [20] Matloub, H. S., Larson, D. L., Kuhn, J. C., *et al.* Lateral arm free flap in oral cavity reconstruction: A functional evaluation. *Head Neck Surg.* 11: 205, 1989.
- [21] Matloub, H. S., Sanger, J. R., and Godina, M. Lateral Arm Neurosensory Flap. In H. B. Williams (Ed.), *Transactions of the 8th International Congress on Plastic and Reconstructive Surgery*. Montreal: International Plastic and Reconstructive Surgery, 1983. P. 125.
- [22] Jones, N. F., Hardesty, R. A., Swartz, W. M., *et al.* Extensive and complex defects of the scalp, middle third of the face, and palate: The role of microsurgical reconstruction. *Plast. Reconstr. Surg.* 82: 937, 1988.
- [23] Inoue, T., Harashina, T., Asanami, S., and Fujino, T. Reconstruction of the hard palate using free iliac bone covered with jejunal flap. *Br. J. Plast. Surg.* 41: 143, 1988.
- [24] Panje, W. R., Krause, C. J., Bardach, J., and Baker, S. R. Reconstruction of intraoral defects with the free groin flap. *Arch. Otolaryngol.* 103: 78, 1977.
- [25] Vaughan, E. D. The radial forearm free flap in orofacial reconstruction: Personal experience in 120 consecutive cases. *J. Craniomaxillofac. Surg.* 18: 2, 1990.
- [26] Vuillemin, T., Raveh, J., and Ramon, Y. Reconstruction of the maxilla with bone grafts supported by the buccal fat pad. *J. Oral Maxillofac. Surg.* 46: 100, 1988.
- [27] Kruger, E. Reconstruction of bone and soft tissue in extensive facial defects. *J. Oral Maxillofac. Surg.* 40: 714, 1982.
- [28] McCarthy, J. G., and Zide, B. M. The spectrum of calvarial bone grafting: Introduction of the vascularized calvarial bone flap. *Plast. Reconstr. Surg.* 74: 10, 1984.
- [29] Cutting, C. B., McCarthy, J. G., and Berenstein, A. Blood supply of the upper craniofacial skeleton: The search for composite calvarial bone flaps. *Plast. Reconstr. Surg.* 74: 603, 1984.
- [30] Yaremchuk, M. J. Vascularized bone grafts for maxillofacial reconstruction. *Clin. Plast. Surg.* 16: 29, 1989.
- [31] Antonyshyn, O., Gruss, J. S., and Birt, B. D. Versatility of temporal muscle and fascial flaps. *Br. J. Plast. Surg.* 41: 118, 1988.
- [32] Serafin, D., Riefkohl, R., Thomas, I., and Georgiade, N. G. Vascularized rib periosteal and osteocutaneous reconstruction of the maxilla and mandible: An assessment. *Plast. Reconstr. Surg.* 66: 718, 1980.
- [33] Lind, M. G., Arnander, C., Gylbert, L., *et al.* Reconstruction in the head and neck regions with free radial forearm flaps and split-rib bone grafts. *Am. J. Surg.* 154: 459, 1987.
- [34] MacLeod, A. M., Morrison, W. A., McCann, J. J., *et al.* The free radial forearm flap with and without bone for closure of large palatal fistulae. *Br. J. Plast. Surg.* 40: 391, 1987.

- [35] Conley, J., and Patow, C. Cranio Osseo-Myofascial Flaps. In J. J. Conley (Ed.), *Flaps in Head and Neck Surgery*. New York: Thieme Medical Publishing, 1989.
- [36] Casanova, R., Cavalcante, D., Grotting, J. C., Vasconez, L. O., and Psillakis, J. M. Anatomic basis for vascularized outer table calvarial bone flaps. *Plast. Reconstr. Surg.* 78: 300, 1986.
- [37] Branemark, P. I. Osseointegration and its experimental background. *J. Prosthet. Dent.* 50: 399, 1983.
- [38] Jackson, I. T., Tolman, D. E., Desjardins, R. P., and Branemark, P. I. A new method for fixation of external prostheses. *Plast. Reconstr. Surg.* 77: 668, 1986.
- [39] Tjellstrom, A., and Jacobsson, M. The Bone Anchored Maxillofacial Prosthesis. In T. Albrektson and G. Zarb (Eds.), *The Branemark Osseointegrated Implant*. Chicago: Quintessence Publishing, 1989.
- [40] Holle, J., Vinzenz, K., Wuringer, E., *et al.* The prefabricated combined scapula flap for bony and soft-tissue reconstruction in maxillofacial defects: A new method. *Plast. Reconstr. Surg.* 98: 542, 1996.
- [41] Li, K. K., Stephens, W. L., and Gliklich, R. Reconstruction of the severely atrophic edentulous maxilla using Le Fort I osteotomy with simultaneous bone graft and implant placement. *J. Oral Maxillofac. Surg.* 54: 542, 1996.
- [42] Schmelzeisen, R., Neukam, F. W., Shiota, T., *et al.* Postoperative function after implant insertion in vascularized bone grafts in maxilla and mandible. *Plast. Reconstr. Surg.* 97: 719, 1996.
- [43] Nakayama, B., Matsuura, H., Ishihara, O., *et al.* Functional reconstruction of a bilateral maxillectomy defect using a fibula osteocutaneous flap with osseointegrated implants. *Plast. Reconstr. Surg.* 96: 1201, 1995.
- [44] Arcuri, M. R. Titanium implants in maxillofacial reconstruction. *Otolaryngol. Clin. North Am.* 28: 351, 1995.
- [45] Donovan, M. G., Dickerson, N. C., Hanson, L. J., and Gustafson, R. B. Maxillary and mandibular reconstruction using calvarial bone grafts and Branemark implants: A preliminary report. *J. Oral Maxillofac. Surg.* 52: 588, 1994.
- [46] Futran ND, Mendez E. Developments in reconstruction of midface and maxilla. *Lancet Oncol.* 2006;7:249–258.
- [47] Brown JS, Rogers SN, McNally DN, Boyle M. A modified classification for the maxillectomy defect. *Head Neck* 2000;22:17–26.
- [48] Wells MD, Luce EA. Reconstruction of midfacial defects after surgical resection of malignancies. *Clin Plast Surg.* 1995;22:79–89.

- [49] Yamamoto Y, Kawashima K, Sugihara T, Nohira K, Furuta Y, Fukuda S. Surgical management of maxillectomy defects based on the concept of buttress reconstruction. *Head Neck* 2004;26:247–256.
- [50] Yamamoto Y. Mid-facial reconstruction after maxillectomy. *Int J Clin Oncol*. 2005;10:218–222.
- [51] Spiro RH, Strong EW, Shah JP. Maxillectomy and its classification. *Head Neck* 1997;19:309–314.
- [52] Davison SP, Sherris DA, Meland NB. An algorithm for maxillectomy defect reconstruction. *Laryngoscope* 1998;108:215–219.
- [53] Okay DJ, Genden E, Buchbinder D, Urken M. Prosthodontic guidelines for surgical reconstruction of the maxilla: A classification system of defects. *J Prosthet Dent*. 2001;86:352–363.
- [54] Foster RD, Anthony JP, Singer MI, Kaplan MJ, Pogrel MA, Mathes SJ. Microsurgical reconstruction of the midface. *Arch Surg*. 1996;131:960–965; discussion 965–966.
- [55] Triana RJ Jr, Uglesic V, Virag M, *et al*. Microvascular free flap reconstructive options in patients with partial and total maxillectomy defects. *Arch Facial Plast Surg*. 2000;2:91–101.
- [56] McCarthy, Colleen M. M.D., M.S.; Cordeiro, Peter G. M.D. Microvascular Reconstruction of Oncologic Defects of the Midface, *Plastic & Reconstructive Surgery*. 2010 ;126 :6 ; 1947-1959
- [57] Amin A, Rifaat M, Civantos F, Weed D, Abu-Sedira M, Bassiouny M. Free anterolateral thigh flap for reconstruction of major craniofacial defects. *J Reconstr Microsurg*. 2006;22:97–104.
- [58] Archibald S, Jackson S, Thoma A. Paranasal sinus and midfacial reconstruction. *Clin Plast Surg*. 2005;32:309–325.
- [59] Funk GF, Arcuri MR, Frodel JL Jr. Functional dental rehabilitation of massive palato-maxillary defects: Cases requiring free tissue transfer and osseointegrated implants. *Head Neck* 1998;20:38–51.
- [60] Genden EM, Wallace DI, Okay D, Urken ML. Reconstruction of the hard palate using the radial forearm free flap: Indications and outcomes. *Head Neck* 2004;26:808–814.
- [61] Cordeiro PG, Bacilious N, Schantz S, Spiro R. The radial forearm osteocutaneous “sandwich” free flap for reconstruction of the bilateral subtotal maxillectomy defect. *Ann Plast Surg*. 1998;40:397–402.
- [62] Nazerani S, Behnia H, Motamedi MH . Experience with the prefabricated free fibula flap for reconstruction of maxillary and mandibular defects. *J Oral Maxillofac Surg*. 2008 Feb;66(2):260-4.

- [63] .Schliephake H. Revascularized tissue transfer for the repair of complex midfacial defects in oncologic patients. *J Oral Maxillofac Surg.* 2000;58:1212–1218.
- [64] Cinar C, Arslan H, Ogur S, Kilic A, Bingol UA, Yucel A. Free rectus abdominis myocutaneous flap with anterior rectus sheath to provide the orbital support in globe-sparing total maxillectomy. *J Craniofac Surg.* 2006;17:986–991.
- [65] .Askar I, Oktay MF, Kilinc N. Use of radial forearm free flap with palmaris longus tendon in reconstruction of total maxillectomy with sparing of orbital contents. *J Craniofac Surg.* 2003;14:220–227.
- [66] Sarukawa S, Okazaki M, Asato H, Koshima I. Volumetric changes in the transferred flap after anterior craniofacial reconstruction. *J Reconstr Microsurg.* 2006;22:499–505; discussion 506–507.
- [67] Futran ND, Haller JR. Considerations for free-flap reconstruction of the hard palate. *Arch Otolaryngol Head Neck Surg.* 1999;125:665–669.
- [68] McLoughlin PM, Gilhooly M, Phillips JG. Reconstruction of the infraorbital margin with a composite microvascular free flap. *Br J Oral Maxillofac Surg.* 1993;31:227–229.
- [69] Chepeha DB, Moyer JS, Bradford CR, Prince ME, Marentette L, Teknos TN. Osseocutaneous radial forearm free tissue transfer for repair of complex midfacial defects. *Arch Otolaryngol Head Neck Surg.* 2005;131:513–517.
- [70] Coleman JJ III. Osseous reconstruction of the midface and orbits. *Clin Plast Surg.* 1994;21:113–124.
- [71] Taylan G, Yildirim S, Akoz T. Reconstruction of large orbital exenteration defects after resection of periorbital tumors of advanced stage. *J Reconstr Microsurg.* 2006;22:583–589.
- [72] Genden EM, Wallace D, Buchbinder D, Okay D, Urken ML. Iliac crest internal oblique osteomusculocutaneous free flap reconstruction of the postablative palatomaxillary defect. *Arch Otolaryngol Head Neck Surg.* 2001;127:854–861.
- [73] Cordeiro PG, Disa JJ. Challenges in midface reconstruction. *Semin Surg Oncol.* 2000;19:218–225.
- [74] Taylan G, Yildirim S, Akoz T. Reconstruction of large orbital exenteration defects after resection of periorbital tumors of advanced stage. *J Reconstr Microsurg.* 2006;22:583–589.
- [75] Shestak KC, Schusterman MA, Jones NF, Johnson JT. Immediate microvascular reconstruction of combined palatal and midfacial defects using soft tissue only. *Microsurgery* 1988;9:128–131.
- [76] Cordeiro PG, Santamaria E. A classification system and algorithm for reconstruction of maxillectomy and midfacial defects. *Plast Reconstr Surg.* 2000;105:2331–2346; discussion
- [77] Boyne, P. J., Christiansen, E. L., and Thompson, J. R. Advanced imaging of osseous maxillary clefts. *Radiol. Clin. North Am.* 31: 195, 1993.

- [78] Metes, A., Hoffstein, V., Direnfeld, V., *et al.* Three-dimensional CT reconstruction and volume measurements of the pharyngeal airway before and after maxillofacial surgery in obstructive sleep apnea. *J. Otolaryngol.* 22: 261, 1993.
- [79] Remonda, L., Schroth, G., Ozdoba, C., *et al.* Facial intraosseous arteriovenous malformations: CT and MR features. *J. Comput. Assist. Tomogr.* 19: 277, 1995.
- [80] Bradrick, J. P., Smith, A. S., Ohman, J. C., and Indresano, A. T. Estimation of maxillary alveolar cleft volume by three-dimensional CT. *J. Comput. Assist. Tomogr.* 14: 994, 1990.
- [81] Shen ZY. Vascular implantation into skin flap: Experimental study and clinical application. A preliminary report. *Plast Reconstr Surg.* 1981;68:404–410.
- [82] Shen ZY. Microvascular transplantation of prefabricated free thigh flap (letter). *Plast Reconstr Surg.* 1982;69:568.
- [83] Pribaz JJ, Fine NA. Prelamination: Defining the prefabricated flap. A case report and review. *Microsurgery* 1994;15:618–623.
- [84] Walton RL, Burget GC, Beahm EK. Microsurgical reconstruction of the nasal lining. *Plast Reconstr Surg.* 2005;115:1813–1829.
- [85] Pribaz JJ, Fine NA. Prefabricated and prelaminated flaps for head and neck reconstruction. *Clin Plast Surg.* 2001;28:261–272.
- [86] Branemark, P. I. Osseointegration and its experimental background. *J. Prosthet. Dent.* 50: 399, 1983.
- [87] Jackson, I. T., Tolman, D. E., Desjardins, R. P., and Branemark, P. I. A new method for fixation of external prostheses. *Plast. Reconstr. Surg.* 77: 668, 1986.
- [88] Tjellstrom, A., and Jacobsson, M. The Bone Anchored Maxillofacial Prosthesis. In T. Albrektson and G. Zarb (Eds.), *The Branemark Osseointegrated Implant*. Chicago: Quintessence Publishing, 1989.
- [89] Holle, J., Vinzenz, K., Wuringer, E., *et al.* The prefabricated combined scapula flap for bony and soft-tissue reconstruction in maxillofacial defects: A new method. *Plast. Reconstr. Surg.* 98: 542, 1996.
- [90] Li, K. K., Stephens, W. L., and Gliklich, R. Reconstruction of the severely atrophic edentulous maxilla using Le Fort I osteotomy with simultaneous bone graft and implant placement. *J. Oral Maxillofac. Surg.* 54: 542, 1996.
- [91] Schmelzeisen, R., Neukam, F. W., Shiota, T., *et al.* Postoperative function after implant insertion in vascularized bone grafts in maxilla and mandible. *Plast. Reconstr. Surg.* 97: 719, 1996.
- [92] Nakayama, B., Matsuura, H., Ishihara, O., *et al.* Functional reconstruction of a bilateral maxillectomy defect using a fibula osteocutaneous flap with osseointegrated implants. *Plast. Reconstr. Surg.* 96: 1201, 1995.

- [93] Arcuri, M. R. Titanium implants in maxillofacial reconstruction. *Otolaryngol. Clin. North Am.* 28: 351, 1995.
- [94] Donovan, M. G., Dickerson, N. C., Hanson, L. J., and Gustafson, R. B. Maxillary and mandibular reconstruction using calvarial bone grafts and Branemark implants: A preliminary report. *J. Oral Maxillofac. Surg.* 52: 588, 1994.
- [95] Urken, M. L., Buchbinder, D., Weinberg, H., *et al.* Primary placement of osseointegrated implants in microvascular mandibular reconstruction. *Otolaryngol. Head Neck Surg.* 101: 56, 1989.
- [96] Funk, G. F., Arcuri, M. R., and Frodel, J. L., Jr. Functional dental rehabilitation of massive palatamaxillary defects: Cases requiring free tissue transfer and osseointegrated implants. *Head Neck* 20: 38, 1998.
- [97] Schmelzeisen, R., Neukam, F. W., Shiota, T., *et al.* Postoperative function after implant insertion in vascularized bone grafts in maxilla and mandible. *Plast. Reconstr. Surg.* 97: 719, 1996.
- [98] Holle, J., Vinzenz, K., Wuringer, E., *et al.* The prefabricated combined scapula flap for bony and soft-tissue reconstruction in maxillofacial defects: A new method. *Plast. Reconstr. Surg.* 98: 542, 1996.
- [99] Nakayama, B., Matsuura, H., Ishihara, O., *et al.* Functional reconstruction of a bilateral maxillectomy defect using a fibula osteocutaneous flap with osseointegrated implants. *Plast. Reconstr. Surg.* 96: 1201, 1995.
- [100] Igawa, H. H., Minakawa, H., and Sugihara, T. Functional alveolar ridge reconstruction with prefabricated iliac crest free flap and osseointegrated implants after hemimaxillectomy. *Plast. Reconstr. Surg.* 102: 2420, 1998.