

# We are IntechOpen, the world's leading publisher of Open Access books Built by scientists, for scientists

6,900

Open access books available

186,000

International authors and editors

200M

Downloads

Our authors are among the

154

Countries delivered to

TOP 1%

most cited scientists

12.2%

Contributors from top 500 universities



WEB OF SCIENCE™

Selection of our books indexed in the Book Citation Index  
in Web of Science™ Core Collection (BKCI)

Interested in publishing with us?  
Contact [book.department@intechopen.com](mailto:book.department@intechopen.com)

Numbers displayed above are based on latest data collected.  
For more information visit [www.intechopen.com](http://www.intechopen.com)



---

# Odontogenic Infections

---

Onur Gonul, Sertac Aktop, Tulin Satilmis,  
Hasan Garip and Kamil Goker

Additional information is available at the end of the chapter

<http://dx.doi.org/10.5772/54645>

---

## 1. Introduction

The incidence, severity, morbidity, and mortality of odontogenic infections have declined dramatically over the years. This reduction in mortality was not due to the first use of penicillin in the treatment of these infections. Rather, it was due to application of the principles of the initial establishment of airway security, followed by early and aggressive surgical drainage of all anatomical spaces affected by cellulitis or abscesses. Since then, with the use of antibiotics and advanced medical supportive care, mortality associated with Ludwig's angina has been further reduced, to 4% [1].

Determination of the severity of infection, evaluation of host defences, surgical management, medical support, administration of antibiotics, and frequent evaluations of the patient are the mainstays of the management of odontogenic infections. Three major factors must be considered when determining the severity of an infection of the head and neck: anatomical location, rate of progression, and airway compromise.

The host response to a severe infection can place a severe physiological load on the body. Fever can increase sensible and insensible fluid losses and caloric requirements. A prolonged fever may cause dehydration, which can, in turn, decrease cardiovascular reserves and deplete glycogen stores, shifting the metabolism to a catabolic state [2].

The surgeon should also be aware that elderly individuals are not able to respond to high fevers, as is often seen in children. Thus, an elevated temperature in a patient of advanced age is not only a sign of a particularly severe infection, but also an omen of decreased cardiovascular and metabolic reserve, due to the demands placed on the elderly patient's physiology [3].

White blood cell count at admission has been reported to be a significant predictor of the length of hospital stay. Thus, evaluation of leukocytosis is important in determining the severity of infection, as well as in estimating the length of hospital stay.

The physiological stress of a serious infection can also disrupt previously well-established control of systemic diseases, such as diabetes, hypertension, and renal disease. The increased cardiac and respiratory demands of a severe infection may deplete scarce physiological reserves in a patient with chronic obstructive pulmonary disease or atherosclerotic heart disease, for example. Thus, an otherwise mild or moderate infection may be a significant threat to a patient with pre-existing systemic disease, and the surgeon should be careful to evaluate and manage concurrent systemic diseases in conjunction with direct management of the infection.

## 2. Microbiology of dental infections

Recent reports have confirmed that oral/dental infections are polymicrobial, including facultative anaerobes, such as viridans-group streptococci and the *Streptococcus anginosus* group, with predominantly strict anaerobes, such as anaerobic cocci, *Prevotella* and *Fusobacterium* species. The use of sophisticated non-culture methods has identified a wider range of organisms, such as *Treponema* species and anaerobic Gram-positive rods such as *Bulleidia extructa*, *Cryptobacterium curtum*, and *Mogibacterium timidum* [4].

## 3. Anatomical Spread of Infection

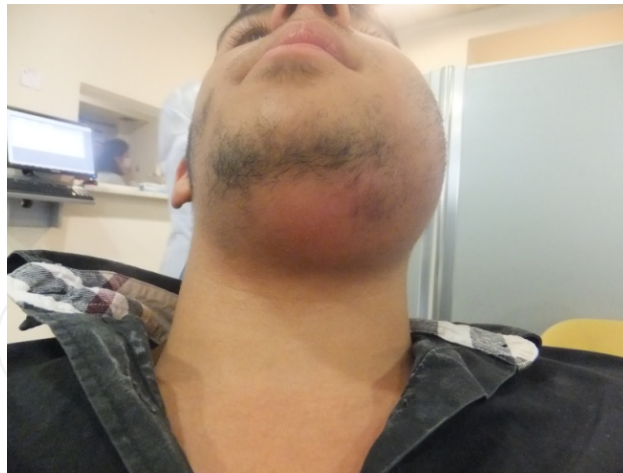
Bone, muscle, aponeurosis or fascia, neurovascular bundles, and skin can all act as barriers to the spread of infection. However, no tissue barrier or boundary is so restrictive or confining to universally prevent spread of infection into contiguous anatomical spaces[4,5]. [Figures: 1,2]

### 3.1. Upper lip

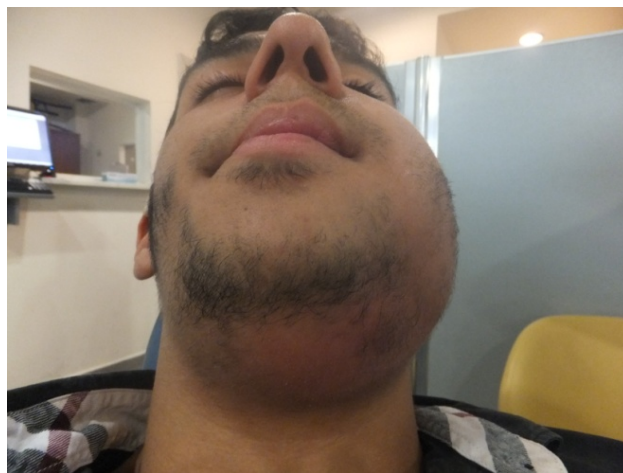Infection at the base of the upper lip typically originates from the upper anterior teeth. It spreads to the orbicularis muscle, from the labial sulcus between the levator labii superioris muscle and the levator angularis oris muscle.

### 3.2. Canine fossa

Spread of infection to the canine fossa usually originates from maxillary canine or upper premolar teeth, often presenting above the buccinator muscle attachment. These swellings obliterate the nasolabial fold. This space is in close proximity to the lower eyelids, and therefore early management is essential to avoid circumorbital infection. There is a risk of spread cranially, via the external angular vein, which may then become thrombosed.



**Figure 1.** Severe infection of several fascial spaces.



**Figure 2.** Submental view.

### 3.3. Buccal space

The attachment of the buccinator muscle to the base of the alveolar process can control the spread of infection in the region of the mandibular and maxillary molars. An infection spreads intraorally, superficial to the buccinator muscle, in front of the anterior border of the masseter muscle. Thus, the clinical manifestations of infection in this space are characterized by swelling confined to the cheek. However, infection may spread superiorly, towards the temporal space, inferiorly, to the submandibular space, or posteriorly, into the masseteric space. In some cases, infection may spread to the surface of the skin, leading to fistula formation

### 3.4. Palate

The palate is usually involved in infections originating from the maxillary lateral incisor or the palatal roots of the posterior teeth. The infection spreads from the apices of these teeth, perforating the palatal alveolar bone, and pus accumulates below the palatal mucoperiosteum.

It is important to be aware that although the lateral incisor is the most common source of palatal abscess, though most still present labially.

### **3.5. Pterygomandibular space**

Infection in this space is manifested by trismus, due to the involvement of the pterygoid muscles. This space is bounded medially by the medial pterygoid muscle and laterally by the medial surface of the mandible, anteriorly by the pterygomandibular raphe, and posteriorly by the deep lobe of the parotid gland. The lateral pterygoid muscle forms the roof of this space.

### **3.6. Submasseteric space**

The most common source of infection in this space is from lower third molar pericoronitis. This space is bound medially by the masseter muscle and laterally by the outer surface of the ramus of the mandible. It is in direct communication with the lateral pharyngeal space posteriorly. The temporalis muscle divides the superior part of this space into two portions, the superficial temporal space, which is bounded by temporalis muscle medially, and the deep temporal space, with the temporalis muscle laterally and the periosteum of the temporal bone medially. Severe trismus due to spasm of the masseter muscle is a characteristic feature of involvement of this fascial space.

### **3.7. Infratemporal space**

Extension of infection from maxillary molars can pass into this space. Infection may also spread from the pterygomandibular, parotid, or lateral pharyngeal region to the infratemporal space. The patient then complains of pain, particularly with mouth opening, some dysphagia, and difficulty with lateral mandibular movements. This space is located behind the zygomatic bone posterior to the maxilla and medial to the insertion of the medial pterygoid muscle. The infratemporal space is bounded superiorly by the greater wing of the sphenoid and is in close proximity to the inferior orbital fissure, with a possible risk of spread of infection to the orbit.

### **3.8. Parotid space**

Involvement of this space may be an extension of infection in the middle ear or the mastoid region. Infection in the masseteric or the lateral pharyngeal space may also spread to the parotid region. Thus, the most characteristic feature of involvement of this space is swelling of the parotid gland region, below the ear lobe. This space contains several important structures that may be affected by infections. These include the 7<sup>th</sup> cranial nerve, the auriculotemporal nerve, the facial vein, the parotid lymph node, and, more deeply, the external carotid with its branches.

### **3.9. Submandibular space**

This space is located below the mylohyoid muscle, medial to the ramus and the body of the mandible. It is bounded anteriorly by the attachments of the anterior belly of the digastric muscle and posteriorly by the posterior belly of digastric muscle and the stylomandibular

ligament. Infection from the posterior mandibular teeth may pass lingually, below the attachment of the mylohyoid muscle, into this space. Clinically, swelling of the submandibular regions tends to obliterate the angle of the mandible, causing pain and redness of the skin overlying this region. Dysphagia is also usually a marked symptom.

### **3.10. Submental space**

This space lies between the two anterior bellies of the digastric muscle. Anteriorly and laterally this space is bounded by the body of the mandible. It is contained, superficially, by the platysma muscle and, deeply and superiorly, by the mylohyoid muscle. Infection of this space usually arises from mandibular anterior teeth, where the infection perforates the lingual cortex; swelling of the submental region is a characteristic clinical feature. The skin over the swelling is stretched and hardened, and the patient experiences considerable pain and difficulty with swallowing. The infection may progress buccally, causing swelling in the labial sulcus and over the chin.

### **3.11. Sublingual space**

Infection spreads into this space as the result of perforation of the lingual cortex, above the attachment of the mylohyoid muscle. This space is bounded superiorly by the mucous membranes and inferiorly by the mylohyoid muscle. The genioglossus and geniohyoid muscles form the medial boundary. Laterally, this space is bounded by the lingual surface of the mandible. Infection in this space will raise the floor of the mouth and displace the tongue, medially and posteriorly. Such tongue displacement may compromise the airway and immediate intervention may be required. Dysphagia and difficulty with speech are also common.

### **3.12. Pharyngeal space**

This space is located on the lateral side of the neck, bounded medially by the superior constrictor muscle of the pharynx and posterolaterally by the parotid space. Infection in this space may originate from mandibular molars or third molar pericoronal suppuration. This could also be a site of spread of infection from the parotid space or fascial space around the body of the mandible. The lateral pharyngeal space contains the carotid sheath, glossopharyngeal nerve, accessory nerve, and the hypoglossal nerve, as well as the sympathetic trunk. Thus, spread of infection into this space carries a significant danger of spreading into a descending neck infection and involvement of the mediastinum. Clinically, stiffness of the neck, swelling of the lateral wall of the pharynx, medial displacement of the tonsils, dysphagia, and trismus are among the characteristic clinical features of involvement of this space.

### **3.13. Retropharyngeal space**

This space is located between the posterior wall of the pharynx and the prevertebral fascia. This space is in direct communication with the base of the skull, superiorly, and the media-



stinum, inferiorly. It has the same characteristic clinical features as infection of the lateral pharyngeal space and carries a significant complication risk of a descending neck infection.

## 4. Evaluation of patients with dentofacial infections

Patients with dentofacial infections may present with various signs and symptoms, ranging from less important to extremely serious. Quick assessment of the patient's situation is essential as the first step of therapy. If the patient shows central nervous system changes, airway compromise, or toxification, then immediate hospitalization, aggressive medical treatment, and surgical intervention may be necessary. Basic principles of patient evaluation must be followed. A complete patient history, physical examination, laboratory investigation, radiological investigation, and accurate and appropriate interpretation of findings must be made. Following these basic principles provides the best chance of accurate diagnosis and treatment [6,7].

### 4.1. History taking

History taking helps in obtaining information regarding the origin, extent, location, and potential threat of the problem. History taking can be defined briefly as determining the present situation of the patient, previous hospitalization history of the patient, previous trauma in the region, recurrent infections, and history of recent swelling and/or airway compromise.

### 4.2. Physical examination

Examination of the thorax, abdomen, extremities, cardiovascular system, recording of vital signs, and body temperature assessment are essential as part of the general patient evaluation. Next, the skin of the face, head, and neck, swellings, injuries, and areas of tenderness over maxillary and frontal sinuses, sinus tracts, fistula formation, enlargement of underlying bony structures, salivary glands, and lymph nodes must be examined. A comprehensive extraoral examination includes inspection of the skin of the face, head, and neck, and of any swelling, injuries, fixation of skin, sinus, or fistula formation. Palpation of the size of any swelling, tenderness, local temperature, fluctuation, enlargement or tenderness over maxillary and frontal sinuses, sinus tracts, fistula formation, enlargement and tenderness of underlying bony structure, salivary glands, and lymph nodes is also important. A comprehensive intraoral examination includes measurement of inter-incisal openings for the assessment of trismus, examination of the teeth, any localized fistula or swelling, sites of tooth extraction, percussion findings, heat and cold testing, electrical pulp testing, visualization of opening ducts of salivary glands, soft palate, tonsillar fossa, uvula, and oropharynx.

#### 4.2.1. Clinical features

Clinical features must be definitively identified to evaluate the patient's condition properly. Clinical features can be classified as follows.

#### **a. Signs of inflammation**

**Rubor:** This symptom is usually present when the infection is close to an external tissue surface, due to vasodilation.

**Tumor:** This may be present at an infection site, due to accumulation of inflammatory exudate or pus.

**Calor:** This is due to warm blood from deeper tissues at the site of the infection, increased velocity of blood flow, and an increased rate of metabolism.

**Dolor:** This is due to pressure on sensory nerve endings, caused by distension of tissues, caused by the action of liberated or activated factors, such as kinins and histamine.

**Loss of function:** This is due to mechanical factors or reflex inhibition of muscle movements, associated with pain. This is reflected in difficulty in chewing and swallowing and respiratory issues.

#### **b. Fever**

Fever is one of the most consistent signs of infection. However, other conditions that may manifest fever should also be considered. Non-infectious inflammatory disorders, like rheumatoid arthritis, excess catabolism, as in thyrotoxicosis, neoplastic disease, like lymphoma, and post-operative release of endogenous pyrogens, which stimulate the hypothalamic thermoregulation centers, should be considered.

#### **c. Repeated Chills**

Generally seen in the presence of bacteraemia and pyogenic abscesses.

#### **d. Lymphadenopathy**

The condition of the lymph nodes depend on whether the situation is acute or chronic. In acute infections, lymph nodes are soft, tender, and enlarged. Surrounding tissues are edematous and the overlying skin is erythematous. In chronic infections, lymph nodes are firm, non-tender, and enlarged. Edema of surrounding tissue may not be present. The location of affected lymph nodes may indicate the site of an infection.

#### **e. Headache**

This is usually associated with fever, and its thought to be due to stretching of sensitive structures surrounding dilated intracranial arteries.

#### **f. Other Clinical Features**

Other clinical features include the presence of draining sinuses or fistulae, difficulty in opening the mouth, difficulty in swallowing, increased salivation, changes in phonation, difficulty in breathing.

- Clinical Symptoms of Possibly Life-Threatening Infections are as follows:



Respiratory impairment, difficulty in swallowing, impaired vision or eye movement or both, change in voice quality, lethargy, decreased level of consciousness, agitation, hypoxia.

- Clinical Symptoms of Toxicity are as follows:

Pallor, increased rate of respiration, fever, lethargy, diaphoresis.

- Central Nervous System Changes Associated with Infection are as follows:

Decreased level of consciousness, evidence of meningeal irritation, severe headache, stiff neck, vomiting, and oedema of the eyelids and other abnormal eye signs.

### 4.3. Radiological examination

A radiological examination may be helpful in locating the offending teeth or other underlying causes. Various radiographs can be useful, such as intraoral periapical radiographs, orthopantomographs, and lateral oblique views of the mandible. A-P and lateral views of the neck can be helpful in detecting retropharyngeal space infections. Other imaging techniques, such as computed tomography, magnetic resonance imaging, and xeroradiography, are also used for detection of the localization of infection and infection-affected tissues. CT scanning is the gold standard in head and neck imaging. It is the advanced imaging modality most widely used in the evaluation of facial infections. A CT scan can show the extent of soft tissue involvement, such as the extent of the inflammatory process, the epicenter of the inflammatory process, differentiation between myositis-fasciitis and abscess formation, and can accurately demonstrate the airway status and lymph node involvement [8].

## 5. Antibiotic therapy in dentofacial infections

Choosing the appropriate antibiotic for treating an odontogenic infection must be done with care. When all factors are considered, the clinician may decide that no antibiotic is necessary at all, whereas in other situations, broad-spectrum or even combination antibiotic therapy may be indicated. Various factors must be considered when choosing an antibiotic from the nearly 70 that are currently available. Although appropriate use may result in dramatic resolution and cure of patients with infections, inappropriate use of antibiotics provides little or no benefit to offset the risks and expense associated with antibiotic administration. Recent studies have shown that even the administration of oral penicillin promotes the growth of penicillin-resistant organisms in the oropharyngeal flora of the patient. Thus, the following guidelines should be considered when choosing a specific antibiotic.

**Determination of the need for antibiotic administration.** A common misconception is that all infections, by definition, require antibiotic administration. This is not necessarily the case. In some cases, antibiotics are not useful and may even be contraindicated. In making this determination, three factors must be considered.

1. The seriousness of the infection.

2. Whether adequate surgical treatment can be achieved.
3. The state of the patient's host defenses.

When these three factors are balanced, several definite indications for antibiotic use become clear. These are:

- Swelling extending beyond the alveolar process
- Cellulitis
- Trismus
- Lymphadenopathy
- Fever
- Severe pericoronitis
- Osteomyelitis

Based on the same three criteria, antibiotic therapy is not indicated in other situations, such as:

- Patient demand
- Toothache
- Periapical abscess
- Dry socket
- Multiple dental extractions in a non-compromised patient
- Mild pericoronitis
- Drained alveolar abscess

In summary, antibiotics should be used when clear evidence exists of bacterial invasion into deeper tissues, which is greater than the host defenses can overcome. Patients who have an impaired ability to defend themselves against infection and patients who have infections that are not immediately amenable to surgical treatment should also be considered for antibiotic therapy. Antibiotics should not be used when no evidence of bacterial invasion of deeper tissues is found. It should be remembered that antibiotics do not improve wound healing and do not benefit non-bacterial infections.

- **Routine empirical antibiotic use.** Because the microbiology and antibiotic sensitivity of many oral pathogens is well-known, it is reasonable to use one of the effective antibiotics empirically. This means to give the antibiotic with the assumption that an appropriate drug is being given. The drug of choice is usually penicillin. Alternative drugs for use in a penicillin-allergic patient are clindamycin and azithromycin. Metronidazole is useful against anaerobic bacteria and should be reserved for a situation in which only anaerobic bacteria are suspected or used in combination with an antibiotic that has an anti-aerobic

bacteria effect, like penicillin. The most widely used, effective, orally administered antibiotics are:

- Penicillin
- Amoxicillin
- Clindamycin
- Azithromycin
- Metronidazole
- Moxifloxacin
- **Narrowest spectrum antibiotic use.** It is preferable to use an antibiotic with the narrowest spectrum that is effective against the organism(s) involved in the infection. The use of a broad-spectrum antibiotic should be avoided, because it increases the risk of the development of resistant microbial strains and also increases the risk of superinfections, by disrupting the normal bacterial flora in various body cavities and permitting ordinarily non-pathogenic bacteria to proliferate and cause disease.
- **Antibiotic usage with the lowest incidence of toxicity and side effects.** Most antibiotics have a variety of toxicities and side effects that limit their usefulness. These range from mild to so severe that the antibiotic cannot be used in routine clinical practice. The older antibiotics usually used for odontogenic infections have a surprisingly low incidence of toxicity-related problems. The more recent antibiotics, on the other hand, may have significant toxicities and drug interactions. Thus, it is becoming increasingly important for the clinician to understand the toxicities, side effects, and drug interactions of the drugs that are prescribed.
- **Use of a bactericidal antibiotic, if possible.** Antibiotics may either kill bacteria or interfere with their reproduction. Bactericidal antibiotics usually interfere with cell-wall production in newly forming or growing bacteria. The antibiotic actually kills the bacteria, while the white blood cells, complement, and antibodies of the host play a less important role. Bacteriostatic antibiotics interfere with bacterial reproduction and growth. This slowing of bacterial reproduction allows the host defenses to move into the area of infection, phagocytose existing bacteria, and kill them. Thus, bacteriostatic antibiotics require reasonably intact host defences. Therefore, for patients with compromised host defences, bactericidal antibiotics should be the drug of choice [9,10,11].

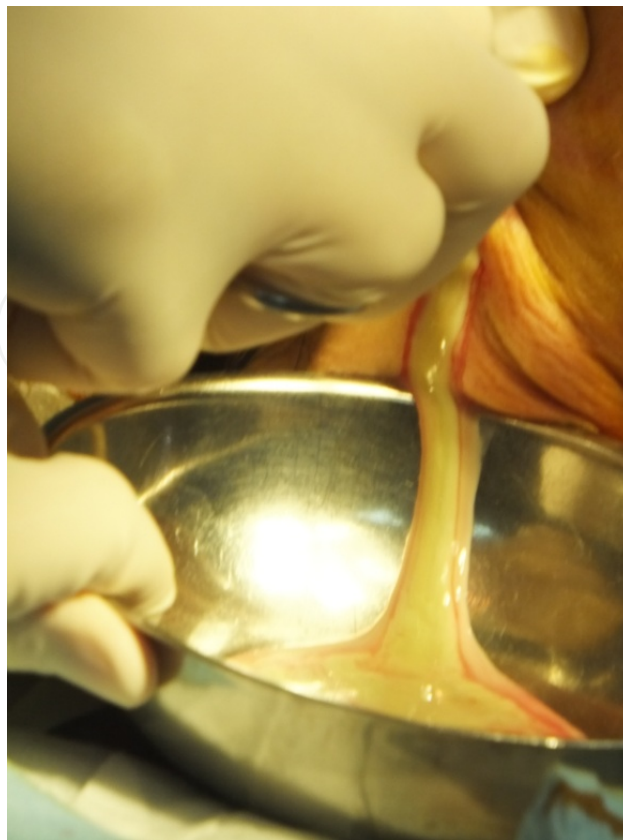
## 6. Surgical management of odontogenic infections

The primary principle of the surgical management of odontogenic infections is to perform surgical drainage and to remove the cause of the infection. Surgical management may range from something as simple as an endodontic extirpation of the necrotic tooth pulp to treatment as complex as the wide incision of soft tissue in the submandibular and neck regions for a

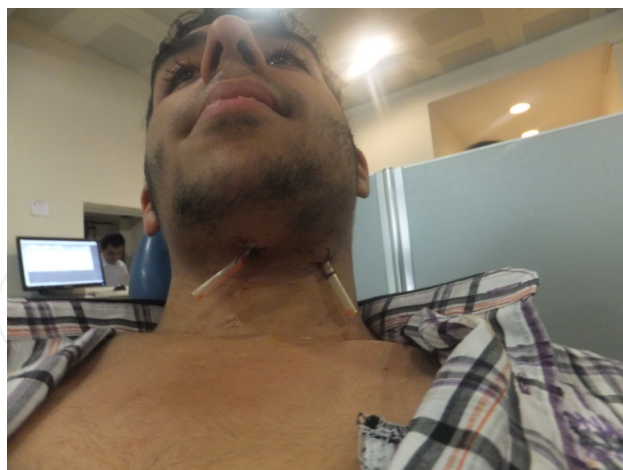
severe infection. The primary goal in surgical management of infection is to remove the cause of infection and to provide drainage of accumulated pus and necrotic debris. Surgical incision and drainage helps to get rid of toxic purulent material, to decompress edematous tissues, to allow better perfusion of blood, which contains antibiotic and defense elements, and to increase oxygenation of the infected area. When an abscess is drained surgically, appropriate dental treatment also should be instituted to achieve quick resolution. This may involve exploration of either the entire anatomical space or the abscess cavity. The abscess cavity is then irrigated with betadine and saline solution. A drain is inserted into the depth of the space. It may simply pass through a single incision and remain in the depth of the space, or it may be a through-and-through drain. The drain is typically secured to one of the margins of the incision with a suture. The method of opening an abscess ensures that no blood vessel or nerve in the region is damaged, and can be defined in ten steps:

1. **Topical anesthesia.** Local anesthesia is achieved with the help of ethyl chloride spray; local anesthesia can then be achieved by subcutaneous ring blockage using a local anesthetic solution, such as articaine + epinephrine or lidocaine + epinephrine.
2. **Incision.** This is made over a point of fluctuation in the most dependent area along the skin crease, through undamaged skin and subcutaneous tissue.
3. **If pus is not encountered,** further deepening of the surgical site is achieved with sinus forceps.
4. **Closed forceps** are pushed through the deep fascia and advanced towards the pus collection.
5. **The abscess cavity** is entered and forceps opened in a direction parallel to vital structures.
6. **Pus flows** along the sides of the incision. [Figure 3]
7. **Explore** the entire cavity for additional loci.
8. **Placement of a drain.** A soft corrugated rubber drain is inserted into the depth of the abscess cavity, and the external part is secured to the wound margin with the help of a suture. [Figure 4]
9. **The drain** is left in place for at least 24 h.
10. **A dressing** is applied over the site of the incision, without pressure.

The purpose of the drain is to allow the discharge of tissue fluids and pus from the wound by keeping it patent. The drain also allows debridement of the abscess cavity by irrigation. Tissue fluids flow along the surface of drain. Thus, it is not always necessary to make perforations in the drain, which could weaken and possibly cause fragmentation within the tissue. Drains should be removed when the drainage is nearly completed. Drains have been shown to allow *ingress* of skin flora along their surfaces. Some forms of drains, such as latex drains in particular, can be irritating to the surrounding tissues and may themselves stimulate some exudate formation. Thus, drains are usually left in infected wounds for 2–7 days. Removal is achieved by simply cutting the suture and slipping the drain from the wound.



**Figure 3.** Drainage of pus after incision.



**Figure 4.** Through and through drain placed.

It is critical to keep in mind that the primary method for treating odontogenic infections is surgical removal of the source of the infection and draining of anatomical spaces affected by indurated cellulitis or abscesses. Whenever an abscess or cellulitis is diagnosed, it must be drained by the surgeon. Failure to do so will result in worsening of the infection and failure



of the infection to resolve, even if antibiotics are given. Even if a tooth cannot be opened or extracted, an incision and drainage procedure should be performed [12,13].

## 7. Specific infections

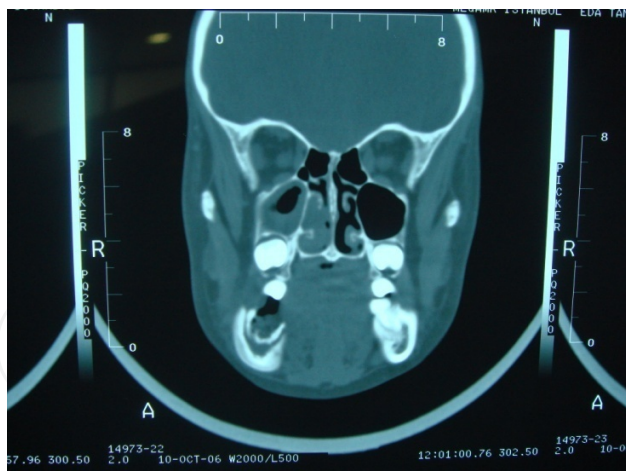
### 7.1. Osteomyelitis

Osteomyelitis is defined as inflammation of the bone. Different from other infectious circumstances seen in the jaws, it involves adjacent cortical plates and often periosteal tissues. The incidence of osteomyelitis is much higher in the mandible because of the dense, poorly vascularized cortical plates. It is much less common in the maxilla due to the excellent blood supply from multiple feeder vessels. In addition, the maxillary bone is much less dense than the mandible. Osteomyelitis has been associated with multiple systemic diseases, including diabetes, autoimmune states, malignancies, malnutrition, and acquired immunodeficiency syndrome [14]. Medications linked to osteomyelitis include steroids, chemotherapeutic agents, and bisphosphonates [15,16]. Local conditions that adversely affect the blood supply can also predispose the host to a bone infection. Radiation therapy, osteopetrosis, and bone pathology can alter the blood supply to the area and provide a potential foothold for osteomyelitis. The most common cause of suppurative osteomyelitis is an odontogenic infection [17]. Depending on the signs and symptoms, osteomyelitis can be classified as acute, subacute, and chronic forms. Radiographic changes do not appear immediately in the acute suppurative form of osteomyelitis, because it may take about 2 weeks for the trabecular pattern of bone to change and areas of radiolucency to start to appear, usually accompanied by periostitis. If acute osteomyelitis is not treated effectively, it can lead to chronic suppurative osteomyelitis. The infection may be a manifestation of lowered patient resistance; this sometimes occurs in immunosuppressed patients on medication or those suffering from an impaired immune defense, as in acute leukemia, human immunodeficiency virus (HIV) infection, poorly controlled diabetes mellitus, or malnutrition.

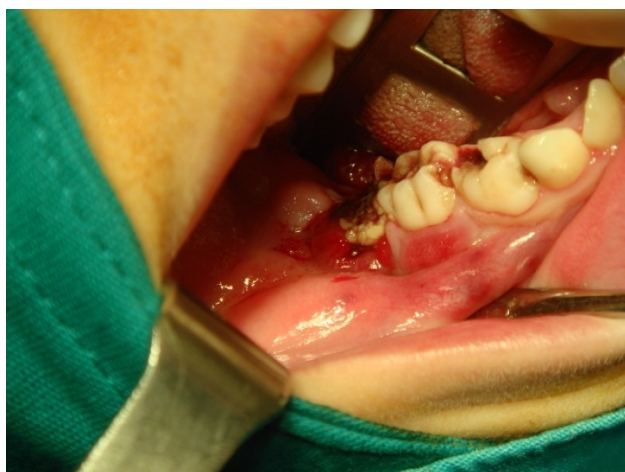Clinically, the disease is dominated by pain and the development of intraoral and/or extraoral sinuses. Induration of soft tissues overlying the infected segments of the jawbones is marked and distension of the periosteum with pus or inflammatory exudate, which may cause trismus and difficulty in swallowing. Regional lymph nodes are usually tender and enlarged. A pathological fracture may develop if the inferior border of the mandible is damaged by the infection process. The radiographic picture of chronic osteomyelitis is loss of detail of the trabecular pattern of the osseous architecture, giving the bone a mottled or moth-eaten appearance. The ischemic or necrotic islands of bone tend to sequester, appearing more radiopaque than the surrounding bone; these form a sequestrum of necrotic bone. [Figure 5,6]

In younger persons, subperiosteal new bone formation appears adjacent to the diseased area. This new bone, known as involucrum, tends to be structureless or granular in appearance radiographically and may surround the necrotic sequestrum and pus lying within the bone (18).



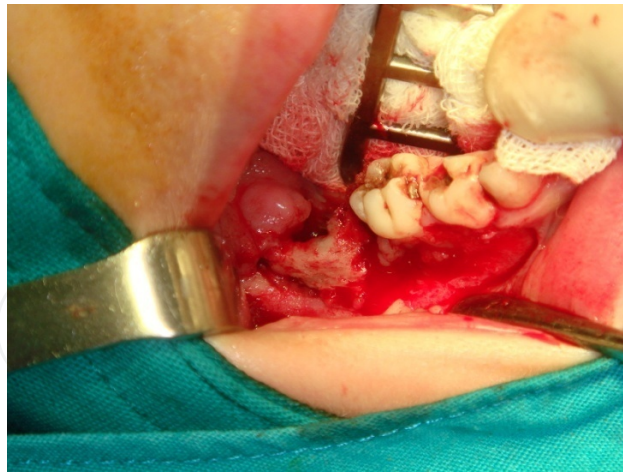


**Figure 5.** Osteomyelitis right mandible.

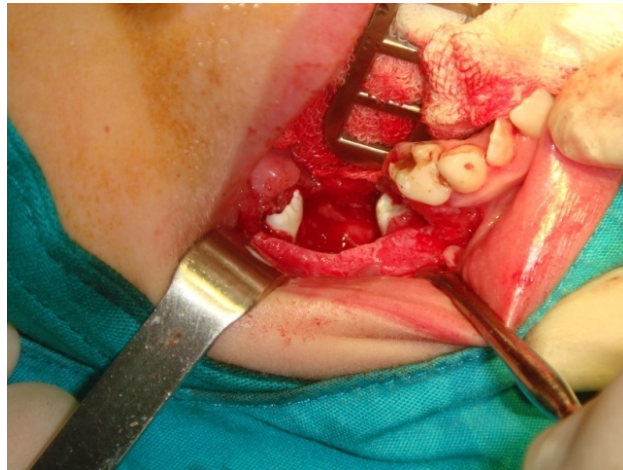

**Figure 6.** Sequestrum.

Management of osteomyelitis involves two aspects: medical and surgical. Clearly, the first step in the treatment of osteomyelitis is correct diagnosis of the condition. A tentative diagnosis is made from a clinical evaluation, radiographic evaluation, and tissue diagnosis. The clinician must be aware that malignancies can mimic the presentation of osteomyelitis and must be kept in the differential diagnosis until ruled out by tissue histopathology. Tissues from the affected site should be sent for Gram staining, culturing, sensitivity determination, and histopathologic evaluation. Empirical antibiotic treatment should be started, based on Gram staining results of the exudate or the suspected pathogens likely to be involved in the maxillofacial region. Definitive culture and sensitivity reports generally take several days or longer but are valuable in guiding the surgeon to the best choice of antibiotics, based on the patient's specific causative organism(s) [17]. Surgical aspects include drainage, debridement, and sequestrectomy, removal of the source of the infection and, if necessary, decortication of the mandible, and possibly resection and reconstruction of the affected bone after the infection is controlled [Figures 7,8,9].



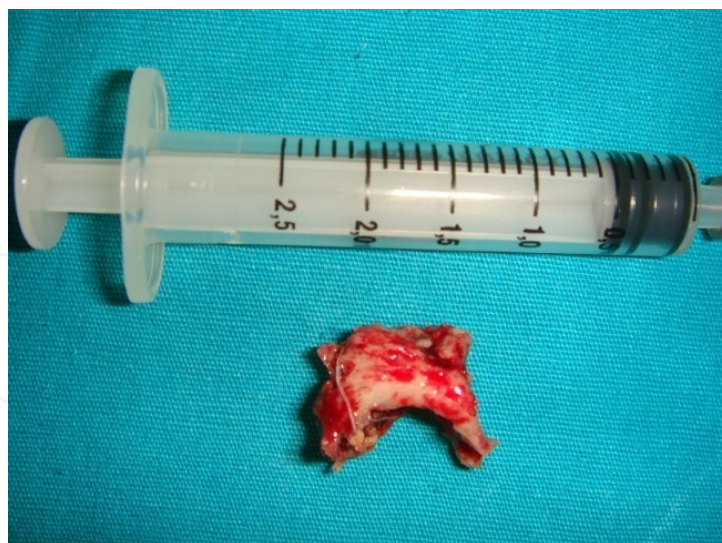**Figure 7.** Access to the sequestrum.



**Figure 8.** Removal.

## 7.2. Osteoradionecrosis

This type of bone necrosis occurs following radiotherapy to the jaw region and often becomes infected secondarily [19]. Radiotherapy induces endarteritis obliterans, which reduces vascularity and renders the bone vulnerable to infection. Once secondary infection develops, it typically spreads through the bone, but sequestration is delayed in these cases. Patients who have undergone radiotherapy are potentially at risk of developing this type of osteomyelitis, and the mandible is particularly at risk if it has received more than 55 Gy of radiation. Extraction and other surgical procedures should be carried out as atraumatically as possible. Primary closure of the socket and pre- and postoperative antibiotic treatment, antiseptic mouthwash, and good oral hygiene are essential. The use of hyperbaric oxygen to increase the blood supply to the affected bone has proven successful in the management of these cases, as have other new and experimental treatments [20]. Better collimation of the radiation beam and



**Figure 9.** Removed sequestrum.

protection of tissues adjacent to tumors have reduced, although not eliminated, this unpleasant sequel.

### 7.3. Osteonecrosis secondary to bisphosphonate therapy

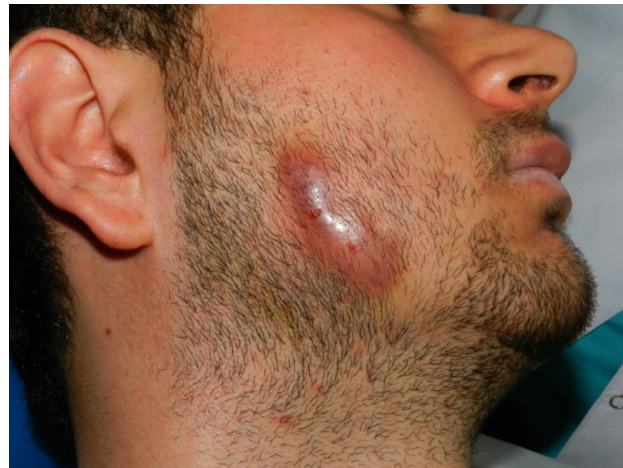Bisphosphonates reduce pain and bone destruction due to metastatic disease, particularly in patients with multiple myeloma, breast, and prostate carcinoma. The medication inhibits bone resorption by reducing osteoclastic activity [21]. Long-term administration of high-dose intravenous bisphosphonates may lead to osteonecrosis of the jaw bones. This is due mainly to a reduction in vascularity, which, together with inhibition of osteoclastic activity, reduces bone turnover. Both are required to protect the bone from the risk of necrosis and added superinfection. There is a lesser risk of this condition occurring in patients taking oral bisphosphonates to prevent osteoporosis. The mandible is most often affected and the disease usually arises after dental treatment. The patient may present with either a non-healing extraction socket or exposed bone, which does not respond to conservative management and antibiotic therapy. Extraction of infected or periodontally involved teeth should be carried out before the administration of bisphosphonates, if possible, and surgery should be avoided whenever possible. It has been suggested that the reparative ability of the bone can be assessed by measuring the serum C-terminal telopeptide (CTX) [22]. Peri- and postoperative antibiotics are essential for extractions. Chlorhexidine mouthrinse pre- and post-extraction is also considered valuable. In non-urgent cases, the risk may be reduced if the bisphosphonate is withheld for 3 months prior to surgery. This must, however, be done in consultation with the physician prescribing the drug.

### 7.4. Actinomycosis

This is a chronic suppurative granulomatous infective process, characterized by the development of swelling in the face and neck region. It is normally a soft tissue infection but can



occasionally involve bone. The causative microorganism is *Actinomyces israelii*, which is present in the normal oral flora. Damage to the tissue, resulting from either lower tooth extractions or jaw fractures, creates a condition of low oxygen tension in which the organism becomes invasive. The condition starts as a swelling, which may occur up to several weeks after the trauma, usually within the submandibular region [Figure 10]. The swelling appears first as a firm and indurated lesion and the overlying skin is usually inflamed and firm, but may also have a bluish color. Within the swelling, multiple abscesses may form with sinuses draining fluid containing yellow granules (so-called sulfur granules) that appear microscopically as a mass of Gram-positive mycelia and polymorphs. Radiographic examination may reveal little destruction of affected bone because the infection is essentially one of the soft tissue. Penicillin is the drug of choice, in addition to adequate incision and drainage. The organism is penicillin-sensitive but it takes time for the antibiotic to penetrate the granulomatous reaction of the body. Antibiotic treatment must be continued for at least 6 weeks. Surgical removal of any infection will facilitate recovery [4].



**Figure 10.** Actinomycosis.

## 7.5. Syphilis

This is a chronic infectious disease, caused by the spirochete *Treponema pallidum*. Although now rare, primary (the chancre), secondary (skin rashes, lymphadenopathy, mucous patches, and snail track ulcers), and tertiary (gumma or syphilitic leukoplakia) may be found in the oral cavity. The first and second stages are highly infectious. Bony changes may occur during the tertiary stage of syphilis. The periosteum is a common site for the development of gumma, with the midline of the palate being classically involved, leading, in time, to oronasal fistula. This appears radiographically as peeling of the periosteum, away from the underlying bone, and the formation of sclerotic bony margins at the periphery. Gumma may extend to the underlying bone and cause syphilitic osteomyelitis. The condition is diagnosed by the identification of *Treponema pallidum* using dark-field microscopy, serological tests, and biopsy of the granulomatous tissue. Long-term penicillin is the drug of choice, in addition to local

measures to deal with damaged soft tissue, sequestered bone, and involved teeth. The fourth stage of syphilis is rare; it affects the cardiovascular system, causing aortic aneurysms or aortic valve incompetence. The central nervous system may also become involved, which may lead to dementia or spinal cord disease [4].

## Author details

Onur Gonul\*, Sertac Aktop, Tulin Satilmis, Hasan Garip and Kamil Goker

Department of Oral and Maxillofacial Surgery, Marmara University, Istanbul, Turkey

## References

- [1] Hought RT, Fitzgerald BE, Latta JE, Zallen, RD. Ludwig's angina: report of two cases and review of the literature from 1945 to January 1979. *J Oral Surg* 1980;38:849–55.
- [2] Miloro M. Peterson's Principle of Oral and Maxillofacial Surgery. Second Edition.. In Miloro M., Ghali G. E., Larsen P. E., Waite P. Editors. BC Decker Inc. 2004 p.277-79
- [3] Flynn TR, Topazian RG. Infections of the oral cavity. In: Waite D, editor. Textbook of practical oral and maxillofacial surgery. 3rd Ed. Philadelphia (PA): Lea & Febiger; 1987. p. 273–310.
- [4] Andersson L. Oral and Maxillofacial Surgery. In Andersson L., Kahnberg K. E., Pogrel M.A. editors Wiley Blackwell 2010 p.280-314
- [5] Flynn T. Anatomy and surgery of oral and maxillofacial infections. *J Oral Maxillofac Surg* 2006; 64: 100–5
- [6] Malik N. A. Textbook of Oral and Maxillofacial Surgery. Secpnd Edition. Jaype Brothers Medical Publishers (P) Ltd. India 2008 p. 587-636
- [7] Hupp J. R. Contemporary Oral and Maxillofacial Surgery. In Hupp J. R., Ellis III E., Tucker R. M. Editors. Fifth Edition. Mosby Elsevier 2008
- [8] Miller WD, Furst IM, Sandor GKB, et al. A prospective blinded comparison of clinical examination and computed tomography in deep neck infections. *Laryngoscope* 1999; 109:1873–9
- [9] Flynn TR, Halpern LR. Antibiotic selection in head and neck infections. *Oral Maxillofac Surg Clin North Am* 2003;15:17–38.
- [10] Kuriyama T, Karasawa T, Nakagawa K, Nakamura S, Yamamoto E. Anatomical susceptibility of major pathogens of orofacial odontogenic infections to 11  $\beta$ -lactam antibiotics. *Oral Microbiol Immunol* 2002; 17: 285–9

- [11] Fazakerley MW, McGowan P, Hardy P, et al. A comparative study of cephadrine, amoxycillin and phenoxymethylpenicillin in the treatment of acute dentoalveolar infection. *Br Dent J* 1993;174:359–63.
- [12] Flynn T. Surgical management of oral infections. *Atlas Oral Maxillofac Surg Clin North Am* 2000; 8: 77–100.
- [13] Flynn TR. The timing of incision and drainage. In: Piecuch JF, editor. *Oral and maxillofacial surgery knowledge update 2001*. Rosemont (IL): American Association of Oral and Maxillofacial Surgeons; 2001. p. 75–84.
- [14] Marx RE. Chronic osteomyelitis of the jaws. *Oral Maxillofac Surg Clin North Am* 1991;3:367–81.
- [15] Marx RE. Pamidronate and zoledronate induced avascular necrosis of the jaws. *J Oral Maxillofac Surg* 2003;61:1115–8.
- [16] Migliorati CA. Bisphosphonates and oral cavity avascular bone necrosis. *J Clin Oncol* 2003;21:4253–4.
- [17] Koorbush GF, Fotos P, Goll TK. Retrospective study of osteomyelitis. Aetiology, demographics, risk factors and management in 35 cases. *Oral Surg Oral Med Oral Pathol* 1992; 74: 149–54.
- [18] Cierny G, Mader J, Pennick J. A clinical staging system for osteomyelitis. *Contemp Orthop* 1985;10:17.
- [19] Marx RJ. Osteonecrosis: a new concept of its pathology. *J Oral Maxillofac Surg* 1983; 41: 283–8.
- [20] Marx RE, Johnson RP, Kline SN. Prevention of osteoradionecrosis: a randomized prospective clinical trial of hyperbaric oxygen versus penicillin. *J Am Dent Assoc* 1985; 111:49–54.
- [21] Mavrokokki T, Cheng A, Stein B, Goss A. Nature and frequency of bisphosphonate associated osteonecrosis of the jaws in Australia. *J Oral Maxillofac Surg* 2009; 65: 415–23.
- [22] Lyons A, Ghazali N. Oral bisphosphonate induced osteonecrosis, risk factors, prediction of risk using CTX testing, prevention, and treatment. *Br J Oral Maxillofac Surg* 2008; 46: 653–61.



